Review of Cornea & Contact Lenses

MAY 2009

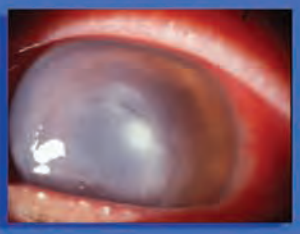
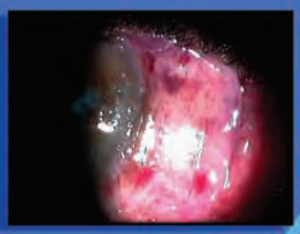


The Pharmaceutical Issue

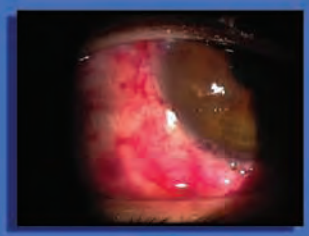
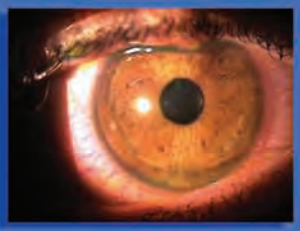


SUPPLEMENT TO
REVIEW OF OPTOMETRY
MAY 2009

IN THIS ISSUE:

By Joseph P. Shovlin, O.D., F.A.A.O.

The Latest in Nanotechnology

Let's examine a few of the ARVO 2009 abstracts on novel technologies and consider their clinical implications.

Nanotechnology (or nanotech) is defined as "Manipulation of atoms, molecules and materials to form structures on the scale of nanometres."[1] It deals with structures of 100 nanometers (or smaller) and involves developing materials and devices at that scale. Nanotechnology has the potential to impact medicine, electronics and energy production with a wide range of applications.

Future advances in ophthalmic clinical practice will surely hinge on the innovative designs, lens features and drug delivery systems developed in the realm of nanotechnology. At ARVO this year, a section on nanotechnology featured a wide array of topics sure to pique your interest.

Delivery System

Nanoparticles may be used for focal delivery of drugs, cells and plasmids to aid in healing and treating assorted anomalies of the eye in a "Trojan Horse" concept. One of the main impediments to this form of treatment is the potential for toxicity. One study shows that intravitreal or anterior chamber injections of magnetic nanoparticles showed little to no signs of toxicity on retinal structure, photoreceptor function or interference with aqueous drainage.[2] Nanoparticle injections appear safe for intraocular use and may provide benefits in delivery of plasmids, drugs and cells directly into the eye.

Extended Release

Anti-VEGF medications have been beneficial in treating subretinal neovascularization, but they require repeated injections to achieve the desired result. Extended-release Avastin (bevacizumab, Genentech) conjugated with gold nanoparticles has been shown to function as an extended-release device for intraocular delivery of Avastin—and, potentially, other medications as well. This technology shows potential for treatment of patients with intraocular neovascularization and may remove the need for frequent injections.[3]

Gene Transfer

Gold nanoparticles may be a potential vector for gene transfer in the cornea, such as plasmid DNA and nucleotides/peptides conjugated to polyethyleneimine or gum arabic.[4] Toxicity profiles, in vivo uptake and corneal clearance are the next steps in making this approach a reality in practice.

Contact Lens Communication

Contact lenses that incorporate electronics, sensors and optoelectronics provide a unique opportunity to continuously monitor health status and dynamically alter visual fields. This group reports the successful design and construction of GHz-range antennae on contact lenses that can be used for radio frequency, energy transmission and communication through a stand-alone contact lens.[5] This technology has far-reaching potential and might be applied to a wide range of areas within healthcare or communication.

Nanotech Controversy

Nanotechnology raises many of the same issues as any introduction of novel technology, including concerns about the toxicity and environmental impact of nanomaterials and their potential effects on global economics.[6] These concerns have led to a debate among advocacy groups and governments on whether special regulation of nanotechnology is warranted.[6]

I hope you see ARVO abstracts, not as a cure for insomnia, but rather as a way to get a glance of the future. Studies you read this year will likely be used to manage and treat eye anomalies in the not-too-distant future. It will be fascinating to watch the role nanotechnology plays in the eye-care field over the next decade. Stay tuned! Additional abstracts appear in *Review of Optometry*'s ARVO Report *(May 2009, pg 41)*. RCCL

1. Britannica. Nanotechnology. Available at: www.britannica.com/EBchecked/topic/962484/nanotechnology. (Accessed Mar 2009).
2. 2429-A517. Raju HB, Hu Y, Vedulla A, Goldberg JL. Ocular toxicity of magnetic nanoparticles.
3. 2426-A514. Shukla R, Nune SK, Kannan R, et al. Extended release Avastin conjugated gold nanoparticles.
4. 2415-A503. Sharma A, Hansen ET, Newman JT, et al. Gold nanoparticles as potential vectors for gene transfer in the cornea.
5. 2414-A502. Parvis BA, Liao LT, Lingely A, et al. Integration of ultra-high frequency antennas on contact lenses: steps toward energy harvesting and telecommunications.
6. Buzea C, Pacheco I, Robbie K. Nanomaterials and nanoparticles: sources and toxicity. Biointerphases 2 (1007) MR17-MR71.

Joseph P. Shovlin, O.D., F.A.A.O., Clinical Editor

VOL. 146, NO. 4

IN THE NEWS

• A new Web site from Alcon, www.patanase.com, provides **education** on signs and symptoms of **seasonal allergies** and offers a **mail-in rebate** for nasal allergy sufferers who try **Patanase** nasal spray. The new online resource includes facts about the causes of seasonal allergies as well as an interactive symptoms poll to prepare patients for an educated visit with their doctor.

• **Visioneering Technologies Inc.**, a startup company with a breakthrough **technology for correcting presbyopia** through contact lenses and other on eye/in eye applications, has **raised** nearly **five million dollars** and added investment partners to fund completion of its clinical trials. The company's unique patented approach to vision correction utilizes induced aperture optics to improve the optical efficiency of the eye's vision system. The technology has on-eye and in-eye applications, including contact lenses, LASIK, intraocular lenses and corneal inlays.

• **ABB CONCISE** has received the **Contact Lens Manufacturers Association's** (CLMA) **Seal of Excellence Award for 2009-2010**, an award ABB has received for the past 16 consecutive years. The award recognizes excellence in **quality and expertise in the manufacturing of gas-permeable contact lenses** produced at the company's Massachusetts and California labs. CLMA awards its Seal of Excellence every two years to manufacturers that meet or exceed ANSI 280.20 standards, as verified by an independent testing laboratory.

Product Line Expansion

Biofinity Toric is the newest addition to CooperVision's line of monthly silicone hydrogel contact lenses. These lenses feature the same material characteristics as Biofinity Sphere and are FDA-approved for both daily and extended wear. Biofinity Toric features Aqua- form technology, which creates a naturally wettable lens material without the need for wetting agents or surface treatments, the company says. The lens is made of comfilcon A material; its Dk is 128 and Dk/t is 116 with a water content of 48%. It features a base curve of 8.7mm, a diameter of 14.5mm and sphere powers from plano to -6.00D. The Biofinity Toric is available in cylinder powers of -0.75D, -1.25D and -1.75D, and an axis of 10 degrees to 180 degrees in 10-degree steps. This summer, CooperVision will expand the parameters of Biofinity Toric to include plus powers, high minus powers, and a -2.25D cylinder.

For more information, visit www.coopervision.com.

New Colors

The FreshLook brand from CIBA Vision is adding three new colors: Brilliant Blue, Gemstone Green and Sterling Gray. Patients can "try on" the new FreshLook colors before they visit their eyecare practitioner's office by visiting www.freshlookcolorstudio.com, where they can upload their photo, select the FreshLook color they'd like to see on their eyes and preview their look. FreshLook lenses are recommended for daily wear and a two-week replacement schedule. These lenses come in a median base curve with a 14.5mm diameter. The lens power range will include +2.00D to -6.00D in 0.25D steps, and -6.50D to -8.00D and +2.50D to +6.00D in 0.50D steps.

Review of Cornea & Contact Lenses

Jobson Medical Information LLC
11 Campus Blvd., Suite 100
Newtown Square, PA 19073
Telephone (610) 492-1000
Fax (610) 492-1049

Editorial inquiries (610) 492-1003
Advertising inquiries (610) 492-1011
E-mail rcl@jobson.com

New Presbyopic Lenses

Acuvue Oasys for Presbyopia, a new multifocal lens from Vistakon, is made of senofilcon A and features the wetting agent Hydraclear Plus and Stereo Precision Technology, giving the lens a zonal aspheric front surface and an aspheric back surface. The lens is currently available from -0.50D to -9.00D in 0.25D steps, with add powers ranging from +0.75D to +1.75D. It blocks more than 96% of UV-A rays and 99% of UV-B rays, the company says.

Call 1-800-843-2020, or go to www.jnjvisioncare.com.

Parameter Expansion

SynergEyes has expanded the parameters for SynergEyes Multifocal and the SynergEyes PS.

The SynergEyes Multifocal, for presbyopic patients, is now available in sphere powers from +5.00D to -8.00D in 0.25D steps and -8.50D to -20.00D in 0.50D steps. Additional base curves—7.0mm, 8.1mm and 8.2mm—are also now available.

The SynergEyes PS, for post-surgical patients, now comes in sphere powers from +6.00D to -8.00D in 0.25D steps and -8.50D to -12.00D in 0.50D steps. It is now offered in base curves from 7.2mm to 9.0mm in 0.2mm steps.

Call 1-877-733-2012, or go to www.synergeyes.com.

Case and Timer Set

The LensAlert! case and timer set now includes two replacement lens cases, intended to encourage the patient to replace the case monthly. Six- and 12-case packs are also available.

Call 314-721-LENS, or go to www.lensalert.com

Advertiser Index

contents

Review of Cornea & Contact Lenses | May 2009

The Pharmaceutical Issue

ON THE COVER

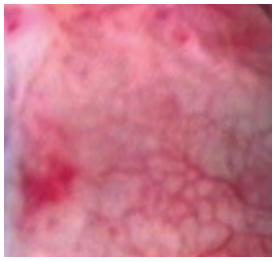

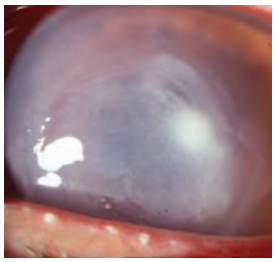

Departments

By Mark B Abelson, M.D., C.M., F.R.C.S.C.; Amanda J. Howe; Paul J. Gomes, M.S.; and Abha Guhlati, M.D.

More Than 'Just an Annoyance'

What are the roles of mast cells outside allergy?

A German scientist, Paul Ehrlich, first described mast cells during a medical school project in 1877. He thought they looked "over-fed,"but were, in fact, secretory granules filled with histamine and pro-allergic and pro-inflammatory mediators.[1] We now know that the density of conjunctival mast cells in normal individuals is estimated to be between 5,000/mm^3 and 6,000/mm^3.[2] During the allergy season, mast cell counts in symptomatic patients have been shown to increase by over 60% when compared to normal individuals.[3] A single conjunctival mast cell contains about 0.0045ng of histamine, the hallmark pro-allergic mediator, in contrast to 0.0238ng/cell of tryptase, along with over 50 other proteases.[2] Observed histamine levels between 5ng/mL and 10ng/mL in the tear film of non-atopic individuals suggest that mast cells are implicated in not only the allergic cascade but also in normal immune function. While known for releasing allergic mediators, mast cells are also involved in wound healing and immune defense, and these functions are important to remember when dealing with patients who have inflammatory conditions or post-surgical concerns.

Activation

It's well known that once IgE-sensitized mast cells are exposed to allergen, FCεRI receptors cross-link and activate them, inciting mediator release.[2] Histamine binds to H1 receptors, resulting in itching, and to H2 receptors, causing redness and other signs and symptoms of allergic conjunctivitis. Mast cell activation can also occur via complement proteins, neuropeptides and microbial/viral/parasitic products.[1] In response to these factors, mast cells release not only histamine but also leukotrienes, proteases, growth factors, cytokines and chemokines. The specific combination and quantity of released mediators determines the ensuing signaling cascade and the extent of the symptomatic response.[2] Varying combinations of pre-formed and newly synthesized mediators can lead to vascular permeability, cell recruitment, cell adhesion, mastocytosis, angiogenesis and wound repair and remodeling.[1,2]

Ocular Wound Healing

The inflammation associated with tissue trauma is crucial, as it facilitates the wound healing process through recruitment of mast cells and leukocytes. Mast cell mediators, such as tryptase, tumor necrosis factor alpha and interleukin-4 (IL-4), induce the proliferation of fibroblasts, which in turn improve mast cell survival. In this symbiotic relationship, the release of further fibrotic constituents is enhanced.[1] Mediators contribute greatly to the regulation of epithelialization, tissue remodeling and angiogenesis, but even well-meaning processes such as these can become malevolent. Fibrosis of the cornea may lead to corneal opacification, disruption of the visual axis and impairment of visual function.[4]

Homeostasis in the Face of Autoimmunity

Mast cells function as a double-edged sword, orchestrating positive as well as negative regulators of immunity. They can not only present antigen themselves but can also affect the migration and function of specialized antigen presenting cells.[5] Negative immunomodulatory function of mast cells is mediated by the production of the anti-inflammatory cytokine IL-10.[6]

Mast cells are foremost involved in homeostasis; however, when tight regulation is disturbed, they are also implicated in autoimmune diseases. Studies in mice have demonstrated that mast cell deficiency elicits resistance to inflammatory diseases, as far-reaching as erosive arthritis.[6] Even though a reduction in mast cell activity could hinder the presentation of such diseases, mast cell knockout is not the goal, as they are requisite for immune function.

Although their pharmacological mechanism of action is not fully understood, popular mast cell stabilizers could find new potential in providing reprieve from mast-cell mediated disease.[7] Mast cells are integral to immunoregulation, so targeting the signaling cascade rather than eliminating them altogether should be the aim. RCCL

1. Krishnaswamy G and Chi D. Mast cells: Methods and Protocols. Humana Press. Totowa, N.J. 2005.
2. Leonardi A. The central role of conjunctival mast cells in the pathogenesis of ocular allergy. Curr Allerg & Asthma Rep 2002 Jul;2(4):325-31.
3. Anderson DF, MacLeod JD, Baddeley SM, et al. Seasonal allergic conjunctivitis is accompanied by increased mast cell numbers in the absence of leukocyte infiltration. Clin Exp Allerg 1997 Sep;27(9):1060-6.
4. Friedlander M. Fibrosis and diseases of the eye. J Clin Invest 2007 Mar;117(3):576-86.
5. Rao KN, Brown MA. Mast cells: multifaceted immune cells with diverse roles in health and disease. Ann NY Acad Sci 2008 Nov;1143:83-104.
6. Galli SJ, Grimbaldeston M, Tsai M. Immunomodulatory mast cells: negative, as well as positive, regulators of immunity. Nature Immunol 2008 Jun;8(6):478-86.
7. Woolley DE. The mast cell in inflammatory arthritis. New England J Med 2003 Apr 24;348(17):1709-11.

By John M. Rinehart, O.D., F.A.A.O.

Large-Diameter Lens Solutions

Resolve irregular cornea challenges with the use of large-diameter GP lenses.

This month, Bart Pemberton, O.D., F.A.A.O., shares his experience in fitting large-diameter lenses on patients with irregular corneas.

Irregular corneas can be quite challenging to fit successfully. One potential weapon in our armamentarium is a larger-diameter GP lens. Such a lens can be used to vault as much of the irregular cornea as possible, taking into account the peripheral cornea as much as, or more than the central cornea. I will present two cases, in both of which it was determined that a large-diameter GP would serve the patient best. In both cases, the Zenith LD (Lensco) was used. Most GP manufacturers offer large-diameter lens options.

Case One

The first case involves a 42-year-old male, "John," who had radial keratotomy (RK) O.U. in the 1990s. His manifest refraction was +5.00-1.50X045 O.D., 20/60-, and +9.00-1.50X125 O.S., 20/40-, with a +1.50 add O.U. Central keratometry readings were as follows: 38.50/56.50 @ 106/056 O.D. and 35.75/61.00 @ 167/077 O.S.

With these numbers in mind, what factors should we consider when choosing an initial lens for this patient? Should we look at the central Ks, peripheral Ks, mid-peripheral Ks, elevation data, corneal diameter or sagittal depth? Or, should we consider various combinations of those criteria? Does it matter?

In order to properly care for irregular corneas, a topographer is almost indispensable. With modern topographers, most of the data listed above can be obtained. Of course, there's also the old saying about the best topography being a fluorescein pattern.

John's topography is shown in figure 1. A smaller-diameter GP did not center well on the cornea. It decentered and moved excessively with each blink. A larger-diameter lens vaulted the most severe irregularities centrally, and it aligned fairly well with the mid-peripheral and peripheral cornea; however, a bubble formed centrally. This issue was resolved and an optimal fit was achieved through the use of a reverse-geometry design. But, due to GP intolerance, it was decided to piggyback the large-diameter rigid lenses over disposable silicone-hydrogel soft contact lenses.

John's final contact lens prescription was as follows: piggybacked reverse-geometry Zenith LD/Optimum Extra GPs over Acuvue Oasys lenses (Vistakon) 8.4/+0.50 O.U. His GPs were 8.90/-1.12/11.0 Diam/9.4 OZ/8.50 SC/9.80 PC O.D. and 8.90/-2.00/11.0 Diam/9.4 OZ/8.30 SC/9.30 PC O.S. His final best-corrected

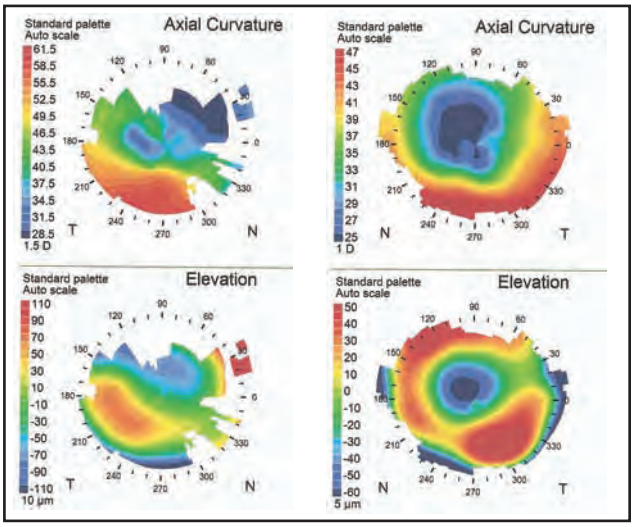

1. These topography mires show a quite irregular cornea in general, with a very oblate surface centrally, O.S. > O.D.

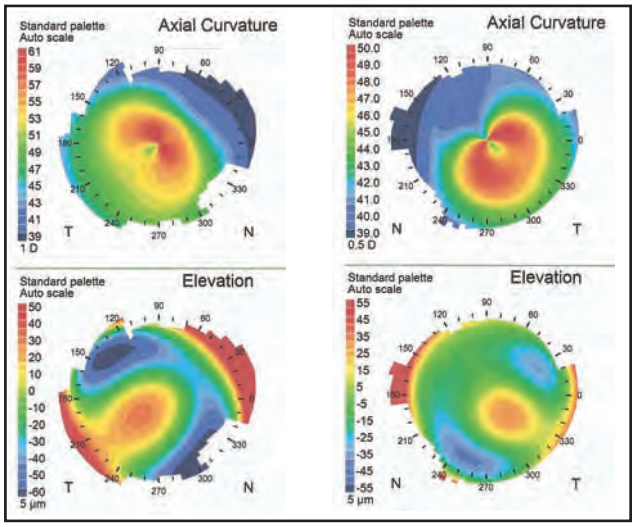

2. These results show a distortion pattern consistent with PMD. O.S. > O.D. (i.e., a butterfly pattern or "kissing birds" pattern).

visual acuity was 20/25-1 O.D. and 20/25-1 O.S. As of last month's follow up appointment, John was still successfully wearing the lenses.

Case Two

"Kyle" was a 17-year-old male with pellucid marginal degeneration (PMD) *(figure 2)*. Manifest refraction yielded the following results: Pl-3.50 x 050 O.D. 20/80 and +1.00-1.25 x 120 O.S. 20/40. Keratometry readings were 52.50/57.50 @ 042/132 O.D. and 42.75/47.50 @131/041 O.S.

With cases of PMD, a smaller-diameter GP lens will often decenter inferiorly. Given this and the fact that Kyle engaged in many outdoor activities, we decided that a larger-diameter GP would serve him better. A larger design would cover more of the cornea and be less likely to get foreign bodies lodged between it and the cornea on windy days. Furthermore, it would be less likely to decenter. Younger patients tend to have larger pupils, and a larger lens allows for a larger optical zone, which leads to less halos and better overall vision—especially in low light conditions.

Kyle's final lenses were Zenith LD/Optimum Extra 7.70/pl/11.3 Diam/9.3 OZ/8.70 SC/9.70 PC O.D. and Zenith LD/Optimum Extra8.15/ +2.00/11.8 Diam/9.15 SC/10.15 PC O.S. His best-corrected visual acuity was 20/30+2 O.D. and 20/30+2 O.S. After going through the initial adaptation process, Kyle reported good comfort and vision with these lenses for most of his waking hours.

Manage Irregularity with Ease

These are just two examples of the possible applications for larger-diameter GP lenses. As more lens design options becoming available, the eye-care practitioner has more choices than ever to fit irregular corneas with a high degree of success. RCCL

Dr. Pemberton practices in a large contact lens group practice in Tucson, Ariz. He has extensive experience caring for patients with irregular corneas, and I'd like to thank him for his willingness to share his expertise.

By Gary Gerber, O.D.

Webinar's the Word

Learn all about this high-tech way to spread your message to potential, new and existing patients.

Imagine inviting a few hundred of your current patients along with another few hundred prospective patients from your community into your office for a seminar titled, "What's New in Vision Correction?" Whether your office is the typical 1,200 square feet or the size of a Home Depot, it's going to be crowded. But, with a few hundred patients and prospective patients in the audience, you're bound to generate a hefty amount of business and invariably fit a lot of contact lenses. So, what's the best way of organizing a seminar without cramming hundreds of people into your office?

My recent Google search of the term "Webinar" produced over 7.6 million hits. By creating a Webinar, you can reach your existing and prospective patients from the comfort of your home or office. The content you deliver would be essentially the same as that which you would present in a live presentation. But, it usually costs less, and because attendees only need a computer to attend, you have a chance at a significantly larger audience.

Establish a Goal

Start designing your Webinar the same way you would a live meeting. Outline the key content points you wish to communicate and the goals you hope to achieve. For example, you could focus on letting viewers know about your expertise in fitting patients with complex ocular histories and those who may have been previously unsuccessful with lenses. In stating this, your goal would be to attempt to convert certain attendees into patients. You could invite current successful patients to participate by answering questions from the audience. The format can be live, via a telephone conference call, or virtual, via a chat room with questions keyed in by attendees.

Keep Their Attention

Your content should be delivered via audio and video. Be creative; your audience will not pay attention to PowerPoint slides with you doing a voice-over. Instead, use video and links to appropriate Web sites as needed. If you are focusing on one main topic, which is what I'd recommend, keep the content section short and to the point. I'd aim for no more than 15 to 20 minutes and, of course, invite questions. If attendance is high (Webinar software tells you how many people are tuned in), say greater than 50, you might ask that people hold their questions until the end of the presentation. This way, you won't be thrown off course and will be able to finish on time, thereby keeping attendees present, alert and interested. One big challenge of Webinars is that it's easier for attendees to walk out than it would be in a live venue.

Save for Future Use

Record the Webinar and archive it on your Web site for later viewing. Depending on the exact format and content, you may also want to save it as a podcast. When patients or prospective patients ask, "Can I wear contact lenses if I have astigmatism?" you can direct them to your Web site and have them view the Webinar, or e-mail them a link. In this manner, you will get a lot of extra mileage out of a single presentation by using it over and over again.

To market the Webinar and help boost attendance, e-mail your current patient base and ask them to forward the e-invitation to anyone they think may be interested. Have a notice on your Web site, advertise it on any bills you send out and have in-office signage directing patients to the Internet address. If the Webinar proves successful, consider offering a series and list them on any communication you send out. If you can schedule them with any sort of recurring date (i.e., the 8th of each month at 8 p.m.), that would be preferred.

Finally, since attendees have to register to attend, make sure you follow up with a quick thank-you e-mail, and ask if they have any questions that relate to their particular situation. RCCL

By Kelly Kerksick, O.D.

Choosing the Right Contact Lens Solution For the Right Reasons

Choosing the right contact lens solution for our patients is at the forefront of every eye-care practitioner's mind. Contact lens technologies have continued to progress, and silicone hydrogel lenses have transitioned from being utilized as a specialty or niche lens to being readily utilized for most patients. Because of this change in eye-care professionals' contact lens fitting habits, it is crucial to understand the importance of positioning contact lens solutions appropriately in our practices.

It is easy for clinicians to become creatures of habit and recommend the same contact lens solution to all their contact lens patients. But, this "what's good for the goose is good for the gander" approach could be very risky, especially with regards to hydrogen peroxide-based solutions.

There is no denying that in a very small percentage of contact lens wearers, preservatives in contact lens solutions can create discomfort, dryness and even allergic reactions. However, the likelihood that preservatives in solutions will cause these problematic issues for patients is very low, making it difficult to understand why so many practitioners use this as their reason for not prescribing multipurpose contact lens solutions for their silicone hydrogel wearers. It is even more disconcerting that many practitioners are using hydrogen peroxide solutions as their "go-to" solution or solution of choice for their patients, since this care regimen can be less than ideal for patients who do not wear their contact lenses every day.

When efficacy and disinfection rates are compared, multipurpose solutions and hydrogen peroxide solutions have similar, highly effective properties early in the disinfection process of a contact lens. But, when comparing the long-term storage capabilities of these two different types of contact lens solutions, OPTI-FREE® RepleniSH® MPDS is designed to provide 30 days of safe storage in the lens case. Hydrogen peroxide loses its anti-microbial properties as it goes through the chemical reaction and becomes buffered water. As a result, it is easy to see why a hydrogen peroxide solution could potentially be a sound choice for one patient and a very risky choice for another.

Additionally, it is important to prescribe a lens care regimen that will promote compliant behavior in patients. A multipurpose solution, such as OPTI-FREE® RepleniSH® MPDS, will provide patients with the flexibility to leave their lenses in the solution safely for more than just a few nights. If you think about it, even our daily wearers will occasionally decide to wear their glasses; but most of the time, this decision is made in an instant—rather than planned in advance. Typically, this can be the result of a late night out, the start of a common cold, a long night with little sleep because of a sick child, etc. It is in instances such as these that patients can very innocently be non-compliant with a hydrogen peroxide-based solution regimen.

I encourage all of you to very carefully evaluate and educate each of your patients on the importance of solution compliance. In addition, remember that contact lens solutions should be chosen and prescribed with the same care and time spent on choosing the ideal contact lens for each patient.

By Mile Brujic, O.D., and Jason Miller, O.D., M.B.A.

Don't Overlook Lids

When a patient suffers from chronic discomfort, you may need to look beyond the lens to treat the underlying cause of the problem.

Contact lens practitioners today are able to choose from a variety of new contact lens materials, lens care solutions, moisturizing eye drops and prescription therapies to help with various contact lens-related comfort issues. But, some patients continue to complain of discomfort, regardless of the lens material, modality or solution prescribed.[1] In these cases, the culprit may be in the eyelids.

Identifying Issues

The anterior surface of the eyelids should warrant significant attention. Evaluate the eyelashes for any absence or misdirection. Additionally, it's important to identify any debris along the base of the lashes because it could be produced by bacteria that occupy the lid margins. If not treated, this may result in chronically irritated lids that will often manifest as tylotic margins, which may present with telangiectatic vessels.

Meibomian gland health is critical to the successful production of a robust tear film. Meibomian glands are sebaceous glands that secrete the lipid layer of the tear film. This layer prevents evaporation of the underlying aqueous layer. A recent study has shown that contact lens wearers experience structural changes of the meibomian glands, resulting in shorter glands when compared to their non-contact lens wearing counterparts.[2] When chronically irritated or inflamed, meibomian glands may demonstrate certain signs, such as involuted and/or capped orifices, glands that are difficult to express upon application of mechanical pressure and seborrheic foam at the eyelid margin.[3]

Let's categorize the inflammation according to its location, with signs manifesting on the anterior surface of the lids described as anterior blepharitis and signs manifesting on the posterior surface of the lids (meibomian glands) described as posterior blepharitis. Clinically, these two conditions are usually seen concomitantly and rarely occur mutually exclusive of one another.

The quality of lipids secreted by the meibomian glands affect the flora on the anterior lid margin. And, those exotoxins, lipases and esterases produced by bacteria on the anterior surface of the lid certainly affect the quality of the meibomian gland secretions. Thus, we must treat both anterior and posterior components to prevent either from exacerbating signs and symptoms of the other.

Treatment Options

Patients with underlying eyelid disease may present with a plethora of symptoms. Because inflammatory events harbor on the closed eye, patients may complain that their eyes seem to burn or are irritated shortly after waking up. Additionally, an insufficient tear film can result due to the alteration in lipid composition. These patients may also manifest classic "aqueous deficient" symptoms (e.g., dry eyes in the evening or after reading/computer use) secondary to the evaporative effects of a poor lipid layer.

The most common form of initial treatment is applying heat to the lids in combination with manual massage in an attempt to melt some of the oils produced by the meibomian glands and help return fluidity to these lipid secretions. This can be done with the help of a warm moist facial cloth, for example. But, regardless of the technique that is chosen, compliance is key. Patients who comply with a regular regimen of applying warmth to the eyes—q.d. to q.i.d., depending on the severity of the disease—will likely experience significant improvement in symptoms.

Treating any underlying anterior component of the blepharitis is another key part in treatment success as well. Commercially available lid scrubs give patients a convenient way to keep the bacterial flora at low levels, likely controlling the inflammatory response. Individually-packaged lid scrubs from Cynacon/OcuSoft and SteriLid Eyelid Cleanser (Advanced Vision Research) are just two of the many over-the-counter products available that patients can use to reduce microbial loads.

But, in certain instances, a prescription product may also be necessary. The goal in adding prescription products is twofold: to help decrease the inflammatory reaction and to control bacterial populations through the anti-microbial properties. Both goals will help return meibomian gland secretions to a normal state. There has been significant interest concerning the use of AzaSite, (topical azithromycin 1%, Inspire Pharmaceuticals), which contains both antibacterial and anti-inflammatory properties, making it a viable

adjunct for patients who experience poorly controlled blepharitis. It is prescribed b.i.d. for two days, then q.d. until the bottle is empty. Many will include one refill in their prescription in order to keep the patient's symptoms at bay for 30 days or more. (Please note: This drop utilizes a proprietary drug delivery vehicle that enables greater tissue penetration. Make sure to educate patients about the viscosity and have them either store the bottle upside down or hold it upside down for five to 10 seconds before administering the drop.)

Doxycycline (or another tetracycline derivative) has long been the standard for controlling posterior blepharitis. It is an oral antibiotic that has been shown to have strong anti-inflammatory activity that helps normalize meibomian gland secretions. Doxycycline is usually prescribed in doses that range from 20mg to 100mg and is either taken in a q.d. or b.i.d. dosing regimen. With these drugs, patients should avoid excessive sun exposure. Dairy products and indigestion medications can inactivate this class of medication, so these should be avoided as well. Tetracycline derivatives are contraindicated in pregnancy. Your discretion and clinical judgment of disease severity should guide you on the dose that should be utilized.

Nutraceuticals also play a role in promoting the health of meibomian gland secretions. The omega-3 fatty acids are a critical nutrient, decreasing inflammatory mediators and increasing meibum fluidity. The effects of omega-3 fatty acids (fish oil supplements) have been shown to be beneficial in patients with dry eyes.[4] Fish oil supplements support ocular health, improve circulation, support the body's natural anti-inflammatory response and aid in the production of bioactive lipid mediators that protect the body from free radical damage.[5,6]

Combining all these strategies, commercially available convenience packs make patient compliance with treatment regimens relatively easy. NutriDox Convenience Kit (Advanced Vision Research) is one such kit that contains doxycycline monohydrate 75mg capsules (q.d., p.o.), omega-3 softgels composed of fish and flax seed oils, and a portable heating system for the eyelids.[7] The system allows for simple application of heat to the lids via small packets that heat when activated and are easily inserted into the eye pads. Alodox (Cynacon/ Ocu-Soft) is another convenience kit that also contains a portable heating system, doxycline 20mg capsules (b.i.d., p.o.) and lid scrubs.

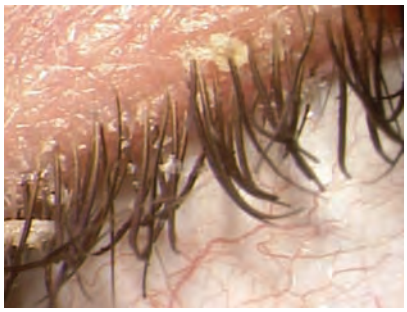

Eyelid debris due to chronic inflammation of the lid margin in a 15-year-old resulted in chronic discomfort with lens wear.

Think Beyond the Lens

The health of the lids is certain to affect lens wear. It is incumbent on you to identify the underlying issues and treat them accordingly to maximize the likelihood of comfortable contact lens wear. Sometimes, keeping your contact lens wearers happy requires thinking outside the lens!

A Case In Point

A new patient, "Max," was a 15-year-old male contact lens wearer who presented complaining of recurrent irritation. He was experiencing itching, burning and irritated eyes. He also has a chronic mild injection O.U. and has been treated multiple times for allergies. His previous eye-care practitioner refit him with monthly contact lenses, due to these issues and deposit problems. He was diagnosed with a combination of anterior and posterior blepharitis. We initiated treatment that day with a course of AzaSite 1gt q.h.s. O.U. for 30 days and initiated eyelid hygiene, which included warm compresses b.i.d. and use of Ocu-Soft lid scrubs daily.

He liked his current contact lenses, so he was kept in the same brand and wearing schedule. As part of my protocol, I had him return three weeks later, at which time he reported that his symptoms were significantly improved. He had relief from the burning and irritation, while his blepharitis was greatly reduced. RCCL

1. Young G, Veys J, Pritchard N, et al. A multi-centre study of lapsed contact lens wearers. Ophthalmic Physiol Opt 2002 Nov;22(6):516-27.
2. Arita R, Itoh K, Inoue K, et al. Contact lens wear is associated with decrease of meibomian glands. Ophthalmology 2009 Mar;116(3):379-84.
3. Jackson WB. Blepharitis: current strategies for diagnosis and management. Can J Ophthalmol 2008 Aug 43(2):170-9.
4. Miljanoviç B, Trivedi KA, Dana MR, et al. Relation between dietary n-3 and n-6 fatty acids and clinically diagnosed dry eye syndrome in women. Am J Clin Nutr 2005 Oct;82(4):887-93.
5. Studer M, Briel M, Leimenstoll B, et al. Effect of different antilipidemic agents and diets on mortality: a systematic review. Arch Intern Med 2005 Apr 11;165(7):725-30.
6. Durrington PN, Bhatnagar D, Mackness MI, et al. An omega-3 polyunsaturated fatty acid concentrate administered for one year decreased triglycerides in simvastatin treated patients with coronary heart disease. Heart 2001 May;85(5):544-8.
7. Mastrota K. Novel formulation targets lid margin infections. Optometry Times 2009 Mar;14.

By Christine W. Sindt, O.D., F.A.A.O.

Without Batting an Eyelash

Growing thicker lashes couldn't be easier with the help of this newly approved topical formulation.

For a century, women have curled lashes, applied mascara and used eyelash extensions to achieve longer, fuller lashes. But prostaglandin analogues have the ability to actually grow lashes, rather than making them appear longer.

Such agents as bimatoprost, travoprost and latanoprost, stimulate lashes to grow thicker, darker and longer. But, Latisse (bimatoprost ophthalmic solution 0.03%, Allergan) is the only drug FDA-approved for the treatment of eyelash hypotrichosis.

Patient Use

Clinical studies of Latisse found a statistically significant increase in lash length, thickness and darkness after eight weeks. However, eyelash growth returns to baseline with product discontinuation.[1]

The drug is applied once nightly to the clean skin at the base of the upper lashes. Latisse should only be applied after the removal of contact lenses to prevent absorbance of the drug into the lens. Excess solution beyond the lid margin should be blotted away to avoid hair growth in undesired places. It is preserved with benzalkonium chloride (BAK) and therefore, should not be used in patients with a known BAK allergy.

Prostaglandin analogues should also be used with caution in patients with active ocular inflammation, although recent studies indicate that they can be used without an increased risk of exacerbation in patients with uveitis.[2]

Cystoid macular edema (CME) has been reported with the use of prostaglandins in treating glaucoma, which is why aphakic or pseudophakic patients with torn posterior lens capsules may be at an increased risk for CME. Latisse is a pregnancy category C drug, meaning at extremely high doses, animal fetuses were harmed. But, the effects of Latisse have not been evaluated in the pediatric population.[1]

Safety and Side Effects

The ocular safety of Latisse has also been examined. With this product, there is a potential for eyelid skin darkening, which may be reversible after discontinuation.[1] In a study looking at topical ocular instillation for glaucoma, periocular pigmentation was found in 1% of patients treated with latanoprost and 6% of patients treated with bimatoprost within 12 months of beginning treatment.[3] A more "troubling" side affect, at least according to the women posting on the numerous Web forums, is the potential for iris darkening.[4]

With topical ocular application use in glaucoma management, hazel or heterochromic eyes have been established as most at risk for developing iris color changes. One large-scale study of latanoprost showed that 12.4% of study subjects had increased iris pigmentation.[5] Iris pigmentation was not reported in the Latisse clinical trials, but patients should be warned about the potential for increasing brown pigmentation, since it is likely to be permanent.[1]

Approximately 4% of patients will experience itching, burning or redness when using Latisse compared to 37.9% using bimatoprost use for glaucoma.[6] The IOP lowering effects of bimatoprost—when applied topically for lash growth—are negligible, although caution should be advised when this product is used on patients who are being treated for glaucoma.[5]

Things to Come

So, for your patients who want the vitality of long, thick lashes without the use of clumpy mascara, prostaglandin analogues may be the answer. It is unlikely that many insurance companies will pay for use of this cosmetic drug (average price is approximately $120 per month). But, if Internet sales of the over-the-counter prostaglandin-containing eyelash growth products are any indication, people may be willing to pay significantly more ($140 to $160 per month).[7,8] Latisse may not be legal for ODs to prescribe in all 50 states, so check with your state board before writing the Rx. RCCL

1. Allergan. Package Insert. Latisse. (Mar 2009).
2. Chang JH, McCluskey P, Missotten T, et al. Use of ocular hypotensive prostaglandin analogues in patients with uveitis: does their use increase anterior uveitis and cystoid macular edema? Br J Ophthalmol 2008 Jul;92(7):916-21.
3. Sharpe ED, Reynolds AC, Skuta GL, et al. The clinical impact and incidence of periocular pigmentation associated with either latanoprost or bimatoprost therapy. Curr Eye Res 2007 Dec;32(12):1037-43.
4. The Eyelash Growth Blog. Available at: www.eyelashgrowth.com. (Accessed Mar 2009).
5. Goldberg I, Li XY, Selaru P, Paggiarino D. A 5-year, randomized, open-label safety study of latanoprost and usual care in patients with open-angle glaucoma or ocular hypertension. Eur J Ophthalmol 2008 May-Jun;18(3):408-16.
6. How AC, Kumar RS, Chen YM, et al. A randomized cross-over study comparing bimatoprost and latanoprost in subjects with primary angle closure glaucoma.Br J Ophthalmol 2009 Mar 30 [Epub ahead of print].
7. Revitalash. Available at www.Revitalash.com. (Accessed Mar 2009).
8. Lilash. Available at:www.lilash.com. (Accessed Mar 2009).

This Year's Hits: New Drugs, Drops and Lenses

Learn how these additions to the ophthalmic armamentarium can help you provide improved care and better vision solutions for your patients.

By Ernie L. Bowling, O.D., M.S., F.A.A.O., Dipl., and Gregg E. Russell, O.D., F.A.A.O., Dipl.

Dr. Bowling is center director at VisionAmerica, a surgical comanagement center in Gadsden, Ala. He is also a diplomate in the Primary Care Section of the American Academy of Optometry.

Dr. Russell is in group practice with the Marietta Eye Clinic in Georgia. He is a diplomate in the Section on Cornea, Contact Lenses and Refractive Technologies of the American Academy of Optometry.

As primary eye-care providers, clinicians should always be on the lookout for new ways of providing better care for our patients, whether it's the newest in technology or the latest in medicines. The diagnostic industry is always working to develop better techniques and machines, and their pharmaceutical counterparts are likewise always looking out for the next great drug formulation. In their continual desire to build a better mousetrap, they consistently bring new and improved products to our doorsteps.

While many of us are comfortable with what is currently available and have come to know the indications, side effects and dosages of the medications that we use regularly, it is always helpful to keep up with those drugs that are newly approved. This information is readily available through the Web site of the U.S. Food and Drug Administration (FDA), www.fda.gov, but in this article, we've done the legwork for you. So, let's take a few moments to see what drugs and ophthalmic devices have just come down the pipeline and are now ready for use.

The Latest in Pharmaceuticals

While providing excellent corneal anesthesia, the current topical anesthetic solutions are not always effective. One new product claims to address this shortcoming. Last October, the FDA approved Akten topical ophthalmic gel (3.5% lidocaine, Akorn). It is the only FDA-approved lidocaine product available for topical ocular use. This product is indicated for anesthesia in corneal procedures and is formulated in a viscous gel to provide prolonged contact with the ocular tissues.

In our tertiary care clinic, this medication has quickly become popular. The retina surgeons use it for anesthesia prior to intraocular injections and before laser procedures, and we use it in gonioscopy and foreign body removal—especially for those foreign bodies located near the limbus or in the conjunctiva. We also use the medication in punctal occlusion procedures. Akten provides a deep anesthesia of the lacrimal puncta and canaliculus, and it makes procedures much more comfortable for the patient. Similarly, consider applying this anesthetic to the base of lashes prior to epilation in cases of trichiasis—anecdotal reports suggest improved patient comfort here as well. The typical dose is two drops in the affected eye. Onset of the drug's action is between 20 and 60 seconds, and it lasts anywhere from 5 to 30 minutes. Its active ingredient is 35mg of lidocaine hydrochloride per mL, and inactive ingredients include hypromellose, sodium chloride and purified water. It is preservative-free, has a 24-month shelf life and is supplied in a 5mL clear plastic ophthalmic dropper bottle. Other than any known allergy, Akten has no known contraindications. Common adverse reactions are conjunctival hyperemia, corneal epithelial changes, headache and burning upon instillation.[1]

On the last day of 2008, the FDA approved Latisse (0.03% bimatoprost, Allergan), a prescription treatment for hypotrichosis, in which the patient's eyelashes are noticeably thin and short. The active ingredient is the same as that in Lumigan (Allergan), a medication currently available to all therapeutically certified eye-care practitioners for treating glaucoma. The package insert for Latisse describes lash growth, pigmentary changes of the iris and increased darkening of the tissues around the eyelid.

Prostaglandin analogues are lipid compounds derived from fatty acids and are designed to bind to prostaglandin receptors. These receptors are present in hair and are thought to be involved in the development and regrowth of hair follicles. Using this finding, Allergan acquired a label for Latisse for use in making the eyelashes longer, darker and thicker.[2] The solution is applied q.d. to the base of the upper eyelash with a sterile, "single use per eyelid" disposable applicator. Latisse solution is intended for use at the base of the eyelashes, on the skin of the upper eyelid margins and should not be applied to the lower eyelid. According to the manufacturer, the drug yields results two to four months after initiating therapy. Once the treatment is stopped, the lash growth will return to pre-treatment levels. Side effects are the same as those associated with the topical prostaglandin analogues—namely redness, itching and darkening of the eyelids and iris. There is a single reference of trichiasis with the use of prostaglandins in the treatment of glaucoma.[3]

On December 5, 2008, the Dermatologic and Ophthalmic Drugs Advisory Panel of the FDA voted unanimously to recommend approval of besifloxacin 0.6% (Bausch & Lomb) ophthalmic suspension for the treatment of bacterial conjunctivitis. Optura developed this broad-spectrum, anti-infective drop specifically for ophthalmic use. The dermatologic

and ophthalmic drugs advisory panel agreed that the antibiotic's benefits outweighed its risks. One study of besifloxacin demonstrated higher exposure in ocular tissues than moxifloxacin or gatifloxacin, while systemic exposure was lower for besifloxacin than the other two fluoroquinolones.[4] The drug has also been tested in cases of methicillin-resistant *Staphylococcus aureus* (MRSA) and proven successful.[5] Interestingly, besifloxacin acts as an anti-inflammatory agent on monocytes in vitro, which is precisely the attribute that may enhance its efficacy in inflammatory ocular infections.[6] Besifloxacin ophthalmic suspension 0.6% appears to be clinically equivalent to moxifloxacin ophthalmic solution 0.5% in the treatment of bacterial conjunctivitis, according to research presented at the American Academy of Ophthalmology (AAO) annual meeting.[7] When released, the drug will make use of the DuraSite (InSite Vision) drug delivery system. Simply stated, this gel-like adhesive binds to ocular tissues for longer contact times and presumably, more effective treatments. Practitioners are familiar with the DuraSite delivery system, as it is currently found in AzaSite (azithromycin, Inspire).[8]

Bepreve (bepotastine besilate 1.0 % anti-allergy drop, ISTA Pharmaceuticals) was recently approved by the FDA.[9] The drug has three primary mechanisms: It suppresses the histamine 1 (H1) receptor, stabilizes mast cells and suppresses the migration of eosinophils into inflamed ocular tissues. The compound's primary mechanisms of action are believed to make it an effective treatment for the signs and symptoms of allergic conjunctivitis. The U.S. Phase II and III clinical studies of bepotastine for the treatment of allergic conjunctivitis evaluated two concentrations of bepotastine, each dosed once or b.i.d. The studies assessed the efficacy of bepotastine in treating ocular itching and redness.[10] Preliminary results demonstrate that both concentrations significantly reduced ocular itching. In addition, both concentrations and dosing regimens produced statistically significant differences in the rapidity of response and the improvement in total nasal symptoms vs. placebo. The company is evaluating two different concentrations for allergic conjunctivitis, each dosed once daily and twice daily.

In June 2008, the FDA granted Durezol (difluprednate ophthalmic emulsion, Sirion Therapeutics) 0.05% a new drug application (NDA). Durenzol is a topical steroid for the treatment of postoperative ocular inflammation and pain. It is the first innovation in the strong steroid class in more than 35 years, and it is the first steroid to acquire an indication for the treatment of postoperative pain. Durezol is a difluorinated derivative of prednisolone and has potent anti-inflammatory activity. Prior to U.S. approval, the efficacy and safety of Durezol in ocular inflammatory diseases had been demonstrated in an extensive preclinical and clinical program in Japan.[11] In two Phase III trials evaluating Durezol in patients diagnosed with significant postoperative inflammation (more than 10 anterior chamber cells), Durezol rapidly reduced inflammation and pain.[12] Mean intraocular pressure for all study groups remained within the normal range throughout the study. Dosage is one drop into the conjunctival sac of the affected eye(s) q.i.d. beginning 24 hours after surgery and continuing throughout the first two weeks of the postoperative period, followed by b.i.d. dosing for a week, and then tapered based on the response. The drug comes in 2.5ml and 5ml bottles.

Tobradex ST (tobramycin 0.3%/dexamethasone 0.5%, Alcon) was approved this February. The original formulation was tobramycin 0.3%/dexamethasone 1.0%, but Alcon has determined that a new suspension of the medication reduces viscosity and prevents settling of the components in the container, thus making the product even more effective in the clinic at a lower concentration.[13]

Allergan is seeking a new label for Acular LS (ketorolac tromethamine 0.4%) for use after cataract surgery. Currently, it is only approved for use post-corneal refractive procedures. In many practices, Acular LS is routinely prescribed for the treatment of cystoid macular edema and prescribed prior to surgery for at-risk patients, including those with diabetic retinopathy or preretinal membranes.

Innovations in Lenses

New developments in the contact lens arena are going to be centered on presbyopic designs and new materials. Vistakon is currently deploying the new

Oasys for Presbyopia design for low and mid range add needs. With its completely revamped fitting approach, the lens is Vistakon's first new design for presbyopia since the Acuvue Bifocal, which is available in etafilcon. With the new design comes a new fitting approach geared toward reducing chair time and providing fitting success. Other silicone hydrogel multifocal designs are expected by the end of the year.

Paragon Vision Sciences and Contamac have both introduced new rigid lens materials with higher refractive indexes. Simply stated, this allows for a thinner design and lower-than-average specific gravity, offering the advantages of presbyopic designs and higher-powered adds that don't decenter inferiorly due to weight. The lower lens mass should also be beneficial for patients with higher myopic and hyperopic prescriptions.

SynergEyes will be launching a new lens design for keratoconus, ClearKone, in September 2009. SynergEyes also expects to receive FDA approval on the new SynergEyes A and multifocal lens designs that incorporate a new center material and a silicone hydrogel skirt.

The FDA has also approved some new devices that may be of interest to both eye-care practitioners and the patients we serve. The AcrySof IQ ReSTOR +3D intraocular lens (Alcon) has been approved for implantation in patients with cataract and presbyopia. This intraocular lens (IOL) is similar to the original ReSTOR +4D lens, including the aspheric design, but features a different optimal reading distance that is three to seven inches further out, yielding a greater near point distance of 16 to 20 inches.[14] In the FDA trial, night vision was better with the +3D lens; nearly four times the number of patients had 20/20 vision at all three distances, as compared to the +4D lens.[14] Presumably, this lens will reduce one of the most common patient complaints encountered with the +4D lens: having to hold objects very close in order to see them. This was especially challenging for those individuals with longer arms, since the +4D lens required the patient to adopt a shorter working distance, or in cases where the patient needed more intermediate visual quality. The +3D lens provides a greater range of flexibility and options for the patient.

The Tecnis multifocal IOL (Abbott Medical Optics) uses a full-aperture diffractive design to divide light into near and far images. The near addition is +4.00D, and the IOL requires a 2.75mm incision size. This lens is based on the principle of spherical aberration correction. The Tecnis IOL has a wavefront-designed, modified prolate anterior-surface optic that neutralizes the positive spherical aberration of the human cornea.[15] Its design is based on the average corneal-surface wavefront-derived spherical aberration in a group of patients, and the optic neutralizes this aberration.

Bausch and Lomb's Crystalens HD has been available since late 2008 and continues to be embraced by surgeons. The HD represents the fourth evolutionary design with a 5.0 optic and squared optics to lessen the incidence of asymmetric capsular fibrosis. Functional improvements of the newest design were created to expand near vision.

Strive for Higher Levels of Care

New products keep us current and capable in this ever-evolving industry by improving our ability to care for patients. Since most practitioners are creatures of habit, we are not always aware of the newest medications and products. With the developments in medications, contact lens designs, and surgical implants, we hope this information will help you to be familiar with which new products might be most beneficial to your patients. RCCL

1. Akorn. Package Insert. Akten. (Mar 2008).
2. Manufacturer Web site. Allergan. Highlights of prescribing information. Available at: www.allergan.com/assets/pdf/latisse_pi.pdf. (Accessed Mar 2009).
3. Bearden W, Anderson R. Trichiasis associated with prostaglandin analog use. Ophthal Plastic Reconstr Surg 2004 Jul;20(4):320-2.
4. Chappa AK, Proksch JW, Ward KW. Comparison of the ocular and systemic pharmacokinetics of besifloxacin, a novel fluoroquinolone antibiotic, with moxifloxacin and gatifloxacin in pigmented rabbits. ARVO Poster. Ft. Lauderdale, 2007.
5. Zhang J, Ward KW. Efficacy of besifloxacin in a rabbit model of methicillin-resistant *Staphylococcus aureus*-induced endophthalmitis. ARVO Poster. Ft. Lauderdale, 2007.
6. Zhong-Zang J, Ward KW. Besifloxacin, a novel fluoroquinolone antimicrobial agent, exhibits potent inhibition of pro-inflammatory cytokines in human THP-1 monocytes. J Antimicrob Chemother 2008 Jan;61(1):111-6.
7. Hitt E. Clinical and microbial efficacy of besifloxacin compared to moxifloxacin in the treatment of bacterial conjunctivitis. Available at: www.docguide.com/news/content.nsf/news/852571020057CCF6852574FE0073FBFF. (Accessed Mar 2009).
8. FDA advisory committee unanimously recommends approval for new ophthalmic product enabled by InSite's DuraSite technology. Medical News Today. Available at: www.medicalnewstoday.com/articles/134133.php. (Accessed Mar 2009).
9. Manufacturer Web site. Bepotastine. Available at: www.istavision.com/research/products_bepotastine.asp. (Accessed Mar 2009).
10. Medical News Today. ISTA pharmaceuticals announces new phase III clinical findings to support bepreve NDA filing. Available at: www.medicalnewstoday.com/articles/105886.php. (Accessed Mar 2009).
11. Medical News Today. Sirion therapeutics highlights pivotal trial results of durezol at the american society of cataract and refractive surgery annual symposium. Available at: www.medicalnewstoday.com/articles/103260.php. (Accessed Mar 2009).
12. Korenfeld MS, Silverstein SM, Cooke DL, et al. Difluprednate ophthalmic emulsion 0.05% for postoperative inflammation and pain. J Cataract Refract Surg 2009 Jan;35(1):26-34.
13. Scoper SV, Kabat AG, Owen GR, et al. Ocular distribution, bactericidal activity and settling characteristics of Tobradex ST ophthalmic suspension compared with Tobradex ophthalmic suspension. Adv Ther 2008 Feb; 25(2):77-88.
14. Manufacturer Web site. Alcon. The AcrySof ReSTOR Lens. Available at: www.acrysofrestor.com. (Accessed Mar 2009).
15. Manufacturer Web site. Abbott Medical Optics. Tecnis 1-piece IOL. Available at: www.amo-inc.com/products/cataract/monofocal-iols/tecnis-1-piece-iol. (Accessed Mar 2009).

Balanced Nutrition Quells Inflammation

Prevent and manage patients' anterior surface and lid inflammation by suggesting lifestyle changes and essential nutrient supplementation.

By Larry J. Alexander, O.D., F.A.A.O.

When our health is invaded or compromised in some way, inflammation—the result of an immune system reaction—often helps us to recover. But at times, the inflammatory process is unchecked, resulting in such chronic issues as rheumatological conditions, heart disease and dementia disorders. It is becoming more apparent that inflammation is the "fire within," not only related just to systemic disorders, but also to dry eye, lid disease, uveitic disorders, glaucoma, optic neuropathies and age-related macular degeneration (AMD).[1] One recent study speaks to the fact that just filling a prescription for the category of anti-inflammatory drugs reduces the risk for development of AMD.[2]

When managing inflammatory disorders, most important is the realization that pharmaceutical intervention is only one part of the puzzle. Lifestyle modification and utilization of supplements both play a critical role in controlling inflammation. Most inflammation is chronic, and as such, a long-term plan must be developed to minimize the likelihood that the smoldering

Dr. Alexander is the director of clinical education at Optovue, Inc., and a consultant to the John-Kenyon American Eye Care Institute.

"fire within" will rekindle and grow into a full-fledged flame.

The Inflammatory Cascade Simplified

While the immune system is quite complex, the essential inflammatory pathway is not. Figure 1 demonstrates an algorithm of that pathway as it relates to the effects of omega-3 and omega-6 free fatty acids (FFAs). The basic understanding is that omega-3 FFAs are anti-inflammatory, and when consumed in excess, omega-6 FFAs are pro-inflammatory. With that said, omega-6 FFAs must still be obtained through diet, just like omega-3 FFAs, and are necessary for bodily function. But, in the typical poorly balanced American diet, the ratio of omega-6 to omega-3 is excessive, allowing for the genesis of the inflammatory process.

The Role of Aspirin

Many agents are available to fight the inflammatory process within both the body and the eye. The use of aspirin in minimizing the risk of cardiovascular disease has been recognized for some time. Mistakenly, the blood-thinning effect had been understood as the reason for risk reduction, when in fact, risk is reduced because the inflammatory process that precipitates plaque formation on the vessels is limited.Unfortunately, aspirin as well as some of the other cyclooxygenase (COX) inhibitors block both the beneficial and harmful arms of the inflammatory cascade, because they act very early in the process. The ultimate inflammatory modulator would minimize harmful inflammatory potentiators while enhancing beneficial portions of the inflammatory cascade.

Diet and Exercise

The evidence for the benefits of a proper diet in relation to modulation of inflammation—especially as it relates to cardiovascular events—is indisputable, though the utilization of supplements is still controversial.[3] Proper diet and effective gastrointestinal activity modify absorption of many nutrients and supplements.

Follow these diet recommendations from the *Journal of the American College of Cardiology* to lessen the risk of of coronary artery disease and diabetes.[4]

- The glycemic index of a food is defined as the incremental increase in the area under the postprandial glucose curve after ingestion of 50g of a specific amount of food vs. that associated with 50g of oral glucose. Ideal carbohydrates with a low glycemic index include green leafy vegetables, such as broccoli and spinach, and fruits, such as grapefruits and cherries. Select high-fiber carbohydrates with a low glycemic index, including vegetables, fruits, whole grains, legumes and nuts.
- Excess intake of processed carbohydrates leads to transient spikes in blood glucose levels, increased insulin production and reactive hypoglycemia. Avoid highly processed foods and beverages, particularly those containing sugar, high-fructose corn syrup, white flour or trans fats.
- Berries, dark chocolate, red wine, tea and pomegranates all reduce postprandial oxidant stress and inflammation. Cacao beans contain a subclass of flavonoids that have been reported to augment endothelial nitric oxide synthase (eNOS) and thereby nitric oxide (NO).[5] This improves endothelium-dependent vasorelaxation.[5] One study demonstrated that one square of dark chocolate (6.3g) represented only 30kcal per day. Previous studies showed that 100g of dark chocolate lowers blood pressure by 12/8mm Hg, but with the risk of increased caloric intake that may create weight gain.[6]
- Coffee contains antioxidants and can improve insulin sensitivity. Consumption of black tea reduces platelet activation and plasma levels of C-reactive protein. But, previous research has not demonstrated a consistent reduction in the risk for stroke associated with coffee or tea consumption. One study suggests that higher levels of coffee and tea consumption can reduce the risk for cerebral infarction among male smokers but not rates of intracranial hemorrhage.[7]
- When paired with a high glycemic-index meal, cinnamon slows gastric emptying and reduces postprandial glucose excursion.
- Nuts also slow gastric emptying and can reduce the impact of high glycemic-index carbohydrates by as much as half.[4] They also reduce postprandial oxidative protein damage, and consumption of nuts at least five times weekly can reduced the risks for coronary artery disease and diabetes by 20% to 50%. Eat approximately one handful of nuts daily (using a closed fist) with vegetables, grains, berries or other fruits.
- Vinegar can reduce postprandial glycemia and promote a sense of "fullness." Eat salads that consist of leafy greens with dressing of vinegar and virgin olive oil daily.
- Lean protein also reduces postprandial glucose excursion and improves satiety. Such protein includes egg whites, game meat, skinless poultry breast meat and

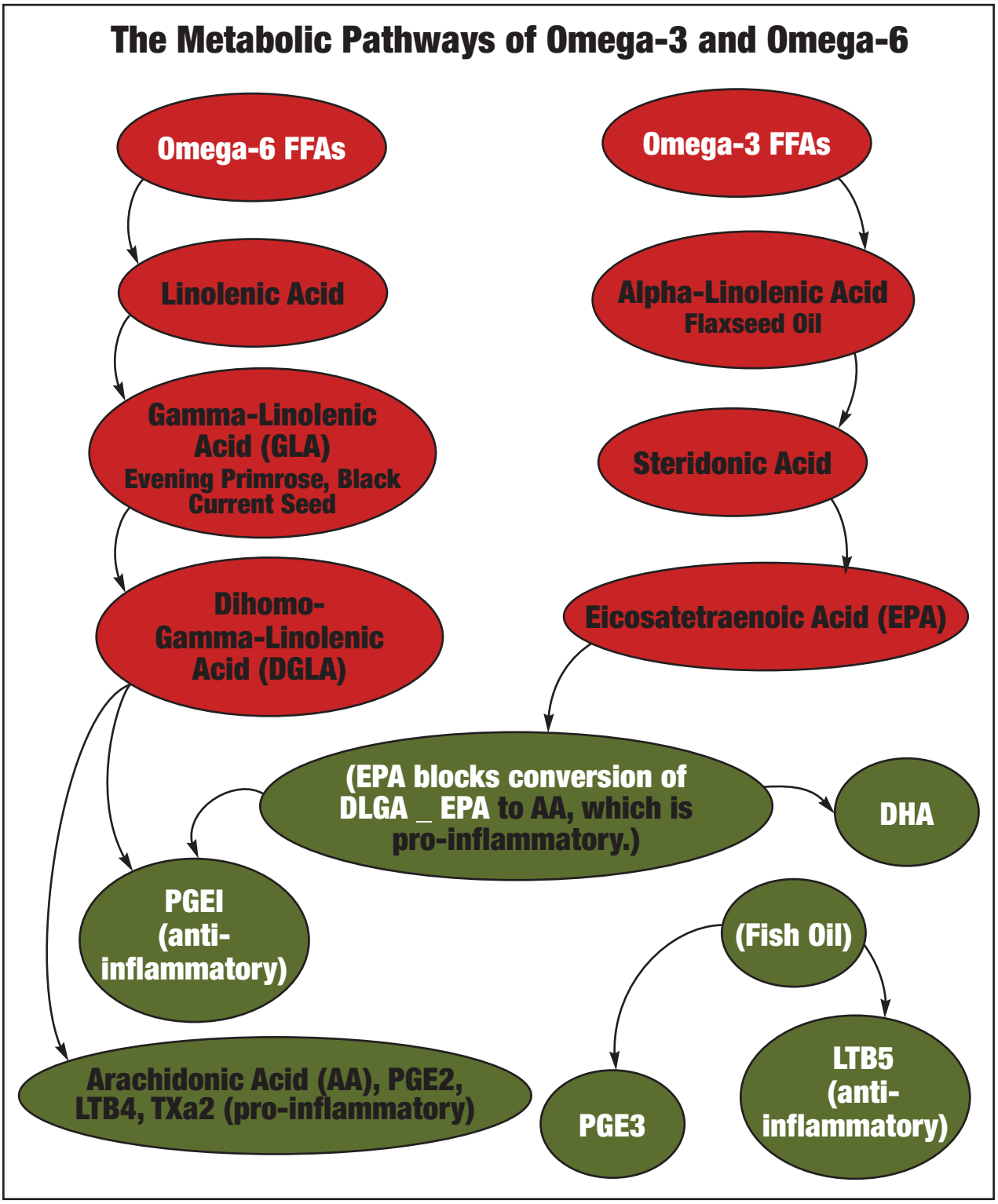

1. Inflammation is a check and balance issue. The good must outweigh the bad to minimize inflammation. Omega-6 FFAs naturally flow to the pro-inflammatory activity. In the omega-3 FFA pathway, flaxseed oil is very high up in the cascade and must undergo multiple conversions to reach the beneficial stage of EPA and DHA, while fish oils have natural EPA and DHA at the start of the process. The further down in the cascade you go, the more specific and concentrated the effect of intervention to minimize the inflammatory process.

whey protein or other nonfat dairy protein. At all three meals, consume lean protein.

• Drinking about one alcoholic drink per day for women and one to two alcoholic drinks per day for men can reduce cardiovascular risk. In fact, one to two drinks before a meal can reduce postprandial glucose and insulin levels. Higher levels of drinking can impair glucose metabolism.

• Exercise acutely lowers glucose and triglyceride levels in a dose-dependent fashion. Get involved in physical activity for at least 30 minutes or more daily

• Maintain normal weight and avoid overweight or obesity. Waist circumference should be less than one half of height in inches.

While a proper diet is ideal, it is often not easily attainable. For those who may need a little help, there are supplements available that may decrease the inflammatory process and assist in both overall improvements in general and ocular health when coupled with diet modification and exercise.

Omega-3 FFAs

To quote a friend of mine, Michael Gross, M.D., "This country is suffering from an epidemic of omeganemia." His point is that Americans consume foods that significantly decrease the availability of critical omega-3 fatty acids, which are the cornerstone of modulation of the anti-inflammatory process within our bodies. The imbalance of omega-3 and omega-6 sets us up for onset of the inflammatory process. Most recommendations advise that fish consumption is the best method to obtain FFAs, but there is the issue of cost and potential contamination with heavy metals when considering a diet dominated by fish. This is when fish oil supplements come into play.

Fish oil supplements are indisputably beneficial to minimizing the inflammatory process through out the body. What is disputable is the source of the fish oil and the potential contamination from heavy metals, such as mercury. When choosing a fish oil supplement to recommend to a patient, investigate the lengths to which the companies go to assure purity, pharmaceutical grade quality and that the content matches the intent. So, which fish oil supplements are good for anterior segment disorders, such as dysfunctional tear syndrome, corneal disorders and anterior or posterior blepharitis? Currently, the argument about the most optimal fish oil surrounds the issue of the synthetic ethyl ester form of fish oil vs. the natural triglyceride form.

Evidence suggests that omega-3 FFAs from plant sources do not have the same beneficial effects as marine-derived eicosapentaenoic acid (EPA) and docosahexaenoic acid (DHA).[8,9] A general consensus among most nutritionists is that adults would benefit from consuming a minimum of 500mg of combined EPA and DHA daily.[10] The American Heart Association recommends that individuals at defined risk for cardiovascular disease consume 1g per day, and those with elevated triglycerides 2g to 4g per day.[11] From this, we can deduce that whatever supplement is recommended, it should be derived from fish rather than plant matter and must contain defined amounts of EPA and DHA.

The next point in the decision-making process regarding the best type of omega-3 to take would be based on the difference between the synthetic ethyl ester form, which is less expensive to manufacture, and the natural triglyceride form. Omega-3 FFAs occur naturally in fish in the triglyceride form with a three-carbon glycerol backbone linked to a fatty acid. In the manufacture of fish oil concentrate, the fatty acids are removed from the backbone by hydrolysis and then distilled. At this point, they are unstable and have to be modified to prevent oxidation in humans. Now, the FFAs may be enzymatically reattached to the glycerol backbone or may be allowed to react with ethanol, creating the ethyl-ester fatty acid. This ethyl group must then be modified by the body and purportedly takes much more time to affect utilization, as this form does not occur naturally in the body.[12-14] Clinical studies on the bioavailability issues with triglyceride vs. ethyl-ester forms are controversial, with four studies reporting better absorption with triglyceride and two showing no particular difference.[15-21]

The essence of the issue is that omega-3 and omega-6 have to stay in balance to maximize health and supplementation. Inflammation is reduced and risk of systemic disease is minimized. If a patient has any systemic condition that could conflict with excessive fat intake, consult the primary physician prior to recommending fish oil supplementation.

Omega-3 supplementation in the form of EPA and DHA should be a component of the management of anterior segment inflammation. The caveat is that there are potential side effects—primarily gastrointestinal—that are minimized by the utilization of high quality fish oil supplements. When considering recommending a particular omega-3 supplement for your patients, take a sample

yourself to assess the effects. Consider the extent of the gastrointestinal distress. Another great test is to bite the capsule and assess the presence or absence of noxious taste.

Another tip regarding the use of omega-3 and omega-6 FFAs is that these supplements are very prone to rapid oxidation. When consuming these supplements, the addition of Vitamin E is beneficial in minimizing the potential of oxidation.

Turmeric

Curcumin is a component of turmeric, the yellow spice in curry, and it has been shown to be a potent immunomodulatory agent that affects activation of T-cells, B-cells, macrophages, neutrophils, natural killer cells and dendritic cells. It also down-regulates various pro-inflammatory cytokines, including tumor necrosis factor alpha (TNF-a), interleukin (IL) 1, IL-2, IL-6, IL-8, IL-12 and chemokines, while concurrently enhancing the antibody responses.[22,23] It is a phytophenolic compound with proven antioxidant, anti-inflammatory, anti-infectious and anticancer activity that is potentially beneficial as an anti-inflammatory agent in the treatment of malignancies, diabetes, allergies, arthritis, Alzheimer's, Crohn's disease, inflammatory bowel disease, psoriasis, idiopathic inflammatory orbital pseudotumors, chronic anterior uveitis, pterygia, chronic obstructive pulmonary disease, experimental abdominal aortic aneurysms and other chronic diseases.[24-32] There is even one report suggesting that curcumin may be beneficial in the prevention of posterior capsular opacification.[33] One of the more obvious applications is in the management of dysfunctional tear syndrome, which is known to have an immune-related inflammatory response. In this application, the effect is to mediate the transcription factor NF-kappa B, which has the ability to block the inflammatory and apoptotic effect of TNF-a.[34] Its activity is thought to occur by inhibition of prosta-glandin E2.[35] The suggested daily dosage for this supplement is 500mg to 1000mg. Toxicities were not experienced at levels of 3,600mg to 8,000mg per day for four months, with the exception of nausea and diarrhea.[36] There are, however, issues with bioavailability and methods to enhance this are under investigation.[37]

In addition to using supplements such as omega-3 FFAs for anterior ocular inflammation, other systemic and topical treatments are available.

Topical and Local Steroids

Localized management of ocular surface and lid disease can be attained through the utilization of topical and oral steroids. There is no doubt that these agents must be used at times to get inflammation under control, but even the soft steroids carry the risk of complications when used over a prolonged period of time. Steroids should be used with the "quick in, hit it hard, then get out" mentality. After steroids control the process, other agents may be employed to control the inflammation over a prolonged period of time.

Topical Immunomodulators and Anti-Inflammatories

Massage and lid cleansing are well-established modalities of treatment of anterior segment disorders. The use of Restasis (Allergan) is also recognized as an effective method of immunomodulation of anterior segment inflammatory disorders, especially when combined with other methods of management of these chronic disorders.

AzaSite (azithromycin, Inspire) is a 1% sterile aqueous topical ophthalmic solution of azithromycin formulated in DuraSite that functions as a macrolide antibiotic. The application is for the treatment of bacterial conjunctivitis with high and prolonged tissue concentrations. AzaSite also displays anti-inflammatory activity and suppresses matrix metalloproteinases (MMPs) with activities similar to doxycycline.[38-44] Topically applied, AzaSite can be a very effective adjunct to therapy for inflammatory processes of the lids and corneal surface. A recent report demonstrated that warm compresses for five minutes followed by lid massage with topical azithromycin twice daily for the first two days, followed by once

daily for the next 12 days created a 68% improvement in lid disease. The results were compared with no significant change in a group treated with only warm compresses.[45]

Oral Cyclines

Another choice for an anti-inflammatory mechanism is the use of oral cyclines, whose antibiotic effect is minimal especially at lower doses. Oral cyclines are very effective matrix MMPs inhibitors, which in effect minimize the destruction of collagen throughout the body. This MMP suppressive activity is critical in the inhibition of destruction as related to multiple ocular disorders.[46-48] Standard dosages range from 20mg to 200mg per day, but potential side effects limit long-term application. Side effects include gastrointestinal distress, photosensitivity, compromise of the effects of oral contraceptives, alteration of coagulatability and idiopathic intracranial hypertension.

A Life-Long Commitment

Inflammation is at the root of most anterior segment issues that we face in everyday practice. Armed with the modalities mentioned in this discussion, the practitioner will be able to better manage conditions, such as dysfunctional tear syndrome and blepharitis and other ocular disorders. Inflammation and inflammatory disorders are chronic, and management must be approached as a lasting challenge. Lifestyle modification and supplementation with appropriate nutrition should serve as the basis for the management of these nagging and recurring conditions. RCCL

1. Gorman C, Park A, Dell K. The fires within. Time Magazine 2004 Feb;163(8):38-45.
2. Swanson MW, McGwin G. Anti-inflammatory drug use and age-related macular degeneration. Optom Vis Sci 2008 Oct;85(10):947-50.
3. Wierzbicki AS. A fishy business: omega-3 fatty acids and cardiovascular disease. Int J Clin Pract 2008 Aug;62(8):1142-6.
4. O'Keefe JH, Gheewala NM, O'Keefe JO. Dietary strategies for improving post-prandial glucose, lipids, inflammation, and cardiovascular health. J Am Coll Cardiol 2008 Jan 22;51(3):249-55.
5. Karim M, McCormick K, Kappagoda CT. Effects of cocoa extracts on endothelium-dependent relaxation. J Nutr 2000 Aug;130(8S Suppl):2105S-8S.
6. Taubert D, Roesen R, Lehmann C, et al. Effects of low habitual cocoa intake on blood pressure and bioactive nitric oxide: a randomized controlled trial. JAMA 2007 Jul 4;298(1):49-60.
7. Larsson SC, Mannisto S, Virtanen MJ, et al. Coffee and tea consumption and risk of stroke subtypes in male smokers. Stroke 2008 Jun;39(6):1681-7.
8. Pawlosky RJ, Hibbeln JR, Lin Y, et al. Effects of beef- and fish-based diets on the kinetics of n-3 fatty acid metabolism in human subjects. Am J Clin Nutr 2003 Mar;77(3):565-72.
9. Davis BC, Kris-Etherton PM. Achieving optimal essential fatty acid status in vegetarians: current knowledge and practical implications. Am J Clin Nutr 2003 Sep;78(3 Suppl):640S-646S.
10. Simopoulos AP, Leaf A, Salem N Jr. Workshop on the essentiality of and recommended dietary intakes for omega-6 and omega-3 fatty acids. J Am Coll Nutr 1999 Oct;18(5):487-9.
11. Kris-Etherton PM, Harris WS, Appel LJ. American Heart Association. Nutrition Committee. Fish consumption, fish oil, omega-3 fatty acids, and cardiovascular disease. Circulation 2002 Nov 19;106(21):2747-57.
12. Bézard J, Blond JP, Bernard A, Clouet P. The metabolism and availability of essential fatty acids in animal and human tissues. Reprod Nutr Dev 1994;34(6):539-68.
13. Yang LY, Kuksis A, Myher JJ. Lipolysis of menhaden oil triacylglycerols and the corresponding fatty acid alkyl esters by pancreatic lipase in vitro: A reexamination. J Lipid Res 1990 Jan;31(1):137-47.
14. Reicks M, Hoadley J, Satchithanandam S, Morehouse KM. Recovery of fish oil-derived fatty acids in lymph of thoracic duct-cannulated Wistar rats. Lipids 1990 Jan;25(1):6-10.
15. Lawson LD, Hughes BG. Human absorption of fish oil fatty acids as triacylglycerols, free acids, or ethyl esters. Biochem Biophys Res Commun 1988 Apr 15;152(1):328-35.
16. Lawson LD, Hughes BG. Absorption of eicosapentaenoic acid and docosahexaenoic acid from fish oil triacylglycerols or fish oil ethyl esters co-ingested with a high-fat meal. Biochem Biophys Research Comm 1988 Oct 31;156(2):960-3.
17. Beckermann B, Beneke M, Seitz I. Comparative bioavailability of eicosapentaenoic acid and docasahexaenoic acid from triglycerides, free fatty acids and ethyl esters in volunteers. Arzneimittelforschung 1990 Jun;40(6):700-4.
18. Visioli F, Rise P, Barassi MC, et al. Dietary intake of fish vs. formulations leads to higher plasma concentrations of n-3 fatty acids. Lipids 2003 Apr;38(4):415-8.
19. Hong DD, Takahashi Y, Kushiro M, Ide T. Divergent effects of eicosapentaenoic and docosahexaenoic acid ethyl esters, and fish oil on hepatic fatty acid oxidation in the rat. Biochim Biophys Acta 2003 Nov 30;1635(1):29-36.
20. Nordoy A, Barstad L, Connor WE, Hatcher L. Absorption of the n-3 eicosapentaenoic and docosahexaenoic acids as ethyl esters and triglycerides by humans. Am J Clin Nutr 1991 May;53(5):1185-90.
21. Krokan HE, Bjerve KS, Mork E. The enteral bioavailability of eicosapentaenoic acid and docosahexaenoic acid is as good from ethyl esters as from glyceryl esters in spite of lower hydrolytic rates by pancreatic lipase in vitro. Biochim Biophys Acta 1993 May 20;1168(1):59-67.
22. Jagetia GC, Aggarwal BB. "Spicing up" of the immune system by curcumin. J Clin Immunol 2007 Jan;27(1):19-35.
23. Matteucci A, Frank C, Domenici MR, et al. Curcumin treatment protects rat retinal neurons against excitotoxicity: effect on N-methyl_D;-aspartate-induced intracellular Ca(2+) increase. Exp Brain Res 2005 Dec;167(4):641-8..
24. Aggarwal BB, Sundaram C, Malani N, et al. Curcumin: the Indian solid gold. Adv Exp Med Biol 2007;595:1-75.
25. Shishodia S, Sethi G, Aggarwal BB. Curcumin: getting back to the roots. Ann N Y Acad Sci 2005 Nov;1056:206-17.
26. Parodi FE, Mao D, Ennis TL, et al. Oral administration of diferuloylmethane (curcumin) suppresses proinflammatory cytokines and destructive connective tissue remodeling in experimental abdominal aortic aneurysms. Ann Vasc Surg 2006 May;20(3):360-8.
27. Holt PR, Katz S, Kirshoff R. Curcumin therapy in inflammatory bowel disease: a pilot study. Dig Dis Sci 2005 Nov;50(11):2191-3.
28. Lal B, Kapoor AK, Agrawal PK, et al. Role of curcumin in idiopathic inflammatory orbital pseudotumours. Phytother Res 2000 Sep;14(6):443-7.
29. Zhang M, Bian F, Wen C, et al. Inhibitory effect of curcumin on proliferation of human pterygium fibroblasts. J Huazhong Univ Sci Technolog Med Sci 2007 Jun;27(3):339-42.
30. Clarke JO, Mullin GE. A review of complementary and alternative approaches to immunomodulation. Nutr Clin Pract 2008 Feb;23(1):49-62.
31. Rahman I. Antioxidant therapies in COPD. Int J Chron Obstruct Pulmon Dis 2006;1(1):15-29.
32. Mancuso C, Bates TE, Butterfield DA, et al. Natural antioxidants in Alzheimer's disease. Expert Opin Investig Drugs 2007 Dec;16(12):1921-31.
33. Huang XR, Qi MX, Kang KR. Apoptosis of lens epithelian cell induced by curcumin and its mechanism. Zhonghua Yan Ke Za Zhi 2006 Jul;42(7):649-53.
34. Kimura K, Teranishi S, Fukuda K, et al. Delayed disruption of barrier function in cultured human corneal epithelial cells induced by tumor necrosis factor-a in a manner dependent on NF-B. Invest Ophthalmol Vis Sci 2008 Feb;49(2):565-71.
35. Moon Y, Glasgow WC,Eling TE. Curcumin suppresses interleukin 1beta-mediated microsomal prostaglandin E synthase 1 by altering early growth response gene 1 and other signaling pathways. J Pharmacol Exp Ther 2005 Nov;315(2):788-95.
36. Hsu CH, Cheng AL. Clinical studies with curcumin. Adv Exp Med Biol 2007;595:471-80.
37. Anand P, Kunnumakkara AB, Newman RA, et al. Bioavailability of curcumin: problems and promises. Mol Pharm 2007 Nov-Dec;4(6):807-18.
38. Scaglione F, Rossoni G. Comparative anti-inflammatory effects of roxithromycin, azithromycin, and clarithromycin. J Antimicrob Chemother 1998 Mar;41 Suppl B:47-50.
39. Ianaro A, Ialenti A, Maffia P, et al. Anti-inflammatory activity of macrolide antibiotics. J Pharmacol Exper Ther 2000 Jan;292(1):156-63.
40. Amsden G. Anti-inflammatory effects of macrolides: an underappreciated benefit in the treatment of community-acquired respiratory tract infections and chronic inflammatory pulmonary conditions? J Antimicrobial Chemother 2005 Jan;55(1):10-21.
41. Hodge S, Hodge G, Brozyna S, et al. Azithromycin increases phagocytosis of apoptotic bronchial epithelial cells by alveolar macrophages. Eur Resp J 2006 Sep;28(3):486-95.
42. Aghai ZH, Kode A, Saslow JG, et al. Azithromycin suppresses activation of nuclear factor-kappa B and synthesis of pro-inflammatory cytokines in tracheal aspirate cells from premature infants. Pediatr Res 2007 Oct;62(4):483-8.
43. Piacentini GL, Peroni DG, Bodini A, et al. Azithromycin reduces bronchial hyperresponsiveness and neutrophilic airway inflammation in asthmatic children: a preliminary report. Allergy Asthma Proc 2007 Mar-Apr;28(2):194-8.
44. Jacot JL, Jacot TA, Sheppard JD, et al. Evaluation of MMP 2/9 modulation by AzaSite and DuraSite in human corneal epithelial cells and bovine corneal endothelial cells in vitro. Poster. ARVO 2008.
45. Luch J. Efficacy of topical azithromycin ophthalmic solution 1% in the treatment of posterior blepharitis. Adv Ther 2008;25(9):858-870.
46. Sapadin A, Fleischmajer R. Tetracyclines: Nonantibiotic properties and their clinical implications. J Am Acad Dermatol 2006 Feb;54(2):258-65.
47. Smith R, Flowers, CW. Chronic blepharitis: a review. CLAO 1995 Jul;21(3):200-7.
48. Yoo S, Lee D, Chang M. The effect of low-dose doxycycline therapy in chronic meibomian gland dysfunction. Kor J Opthalmol 2005 Dec;19(4):258-63.

Stabilization Factors of Toric Contact Lenses

Help astigmatic patients achieve stable, comfortable lens wear by matching the ideal toric lens design with each patient's individual ocular and visual demands.

By Brian R. Kirschling, O.D., F.A.A.O.

Many of my new patients have been told that they couldn't wear contact lenses because of their astigmatism. How could this be? Haven't toric lenses been on the market for decades? From rigid gas-permeable (RGP) toric lenses to traditional hydrogel toric lenses and, now, silicone hydrogel toric lenses, there is an array of choices for the contact lens practitioner to select from. While it will surely take a little more time and effort to fit the astigmatic patient with some of these lenses, others can be quite easily fit with a high degree of success on the first attempt. In today's contact lens world, there really is no sound reason not to fit these astigmatic patients.

Each lens modality has a different philosophy regarding the stabilization of the lens on the astigmatic eye. Designing a contact lens that moves with the blink but doesn't rotate (thus providing clear and stable vision) is really an impressive feat of engineering. But, making the lens comfortable and affordable for the patient is another issue entirely.

In this article, we'll look at the various designs and fitting philosophies associated with toric contact lenses, as well as the patient factors involved in selecting a toric lens design.

Demographics

As much as 45% of the contact lens-seeking population has astigmatism of 0.75D or greater.[1] Generally, in patients with less than 0.75D, a spherical contact lens fit that utilizes the spherical equivalent (sphere + 1/2 refractive cylinder) of a patient's spectacle refraction vertexed to the corneal plane will provide the patient with visual acuity nearly equivalent to that of spectacles.

In patients with refractive cylinder greater than 0.75D, the residual uncorrected astigmatism

Release Date: May 2009
Expiration Date: May 31, 2010
Goal Statement: Having a thorough understanding of the various toric designs currently available, practitioners are able to offer astigmatic patients the benefits of comfortable lens wear.
Faculty/Editorial Board: Brian R. Kirschling, O.D., F.A.A.O.
Credit Statement: This course is COPE approved for 2 hours of CE credit. COPE ID: 24886-CL. Check with your local state licensing board to see if this counts toward your CE requirement for relicensure.
Joint-Sponsorship Statement: This continuing education course is joint-sponsored by the University of Alabama.
Disclosure Statement: Dr. Kirschling has no relationships to disclose.

This course is supported by an unrestricted educational grant from

THE VISION CARE INSTITUTE™, LLC
a Johnson & Johnson company

often creates enough visual blur that patients remain unsatisfied with their vision when compared to spectacles. In these patients, it is critical to consider a toric contact lens. In order to understand the different lens options available, let's review the different types of astigmatism.

Defining Astigmatism

Astigmatism is the refractive anomaly resulting from an unequal refraction of incident light rays by the dioptric system of the eye in different meridians.[2] The two refractive meridians (90º apart in a regular cornea) are compared to determine the amount of astigmatism present. In minus cylinder format, if the axis of astigmatism is between 150º and 30º, it is considered with-the-rule. Against-the-rule astigmatism is when the minus cylinder axis is between 60º and 120º.

Refractive astigmatism represents the total amount of astigmatism as measured with retinoscopy and subjective refraction. Corneal astigmatism represents the difference in curvature between two separate meridians of the cornea as measured by corneal topography or keratometry. Residual astigmatism shows the difference between the refractive and corneal astigmatism. Residual astigmatism is composed of both physiological and induced factors. The physiological factors include crystalline lens tilt and posterior corneal surface curvature variations. Induced astigmatism may result from the tilt or decentration of the contact lens, the toric surfaces of the contact lens and warpage or flexure of the contact lens.[3]

Remember: Corneal astigmatism + residual astigmatism = total refractive astigmatism. Understanding the patient's astigmatism will help to determine which type of lens to select first.

Correction with toric contact lenses should be considered whenever the total refractive astigmatism is greater than approximately one-fourth of the patient's sphere power. For example, a patient with the refraction of -0.50-0.75x180 would likely benefit visually from a toric contact lens design. A patient with a refraction of -3.50-0.75x180 would likely do well with a spherical equivalent lens because the total refractive astigmatism is only one-fifth of the total sphere power.[4]

When evaluating patients whom we fit with any toric lens modality, we must evaluate the rotational stability of the contact lens. In order to help monitor lens rotation, markings are placed on the lens. While slight vertical movement is desirable with the blink, rotational movement is not and should be limited to less than 5º to 10º. But, patients with greater amounts of astigmatism are less tolerant of greater lens rotation or misalignment caused by normal blinking and eye movements.

Table 1. Toric RGP Contact Lenses[6]

Toric RGP Design	Corneal Cylinder	Residual/Induced Cylinder
Front Toric	Less than 2.50D	Greater than 1.00D
Back Toric	Greater than 2.50D	Less than 1.00D
Bitoric	Greater than 2.50D	Greater than 1.00D

Fitting RGP Torics

With RGP lenses, the practitioner must select the lens design based on both the amount of corneal astigmatism and the amount of residual astigmatism. Spherical RGPs can mask much of the astigmatism in patients with little residual astigmatism and low corneal astigmatism (<2.50D). This is due to the tear lens power formed in the space between the spherical back surface of the contact lens and the astigmatic cornea.

In patients with significant residual astigmatism and low corneal astigmatism (<1.00D), a front-surface RGP toric lens may work well. Front toric lenses utilize a technique called prism-ballasting in order to prevent the RGP lens from rotating. The back surface of the lens is spherical and usually fit slightly steeper than the flat K. The front surface of the lens is thicker with a small amount of base down prism (1.00PD to 1.50PD) ground into the lens. The weight differential between the superior and inferior portion of the lens acts to keep the lens from rotating with the thicker base down portion of the lens, settling at roughly the six o'clock position. Nasal rotation is frequently seen due to horizontal lid forces caused by the lateral to medial zipper-like motion of the lids created by the blink. But, front-toric RGP lenses are

rarely fit now that there are excellent, stable soft lens options available.

Back-toric RGP lenses are used for patients with high (>2.00D) amounts of corneal toricity, and the back surface of the lens is fit slightly flatter than the keratometric readings of corneal curvature. This leaves a small, nearly spherical tear lens power. The toricity of the back surface of the contact lens provides both rotational stability and astigmatic correction for the patient.

At times with back toric RGP lenses, induced cylinder is created by the difference in the refractive index of the contact lens and the refractive index of the tear lens. This induced minus cylinder often compounds the residual astigmatism.[5]

If the corneal astigmatism is high and there is high residual astigmatism, a bitoric design should be considered. Bitoric RGP lenses provide rotational stability by utilizing a toric back surface that coincides with corneal toricity. These lenses also incorporate toricity of the front surface predominantly to correct residual/induced astigmatism.

Rarely, a patient with moderate corneal astigmatism and moderate residual astigmatism will require a bitoric lens with prism ballast in order to provide adequate rotational stability.[6] These lenses incorporate a nonspherical posterior and anterior surface, as well as a 1.00PD to 1.50PD prism ballast to achieve rotational stability on the eye.

Soft Hydrogel Torics

Rotational stability of a soft toric lens on the eye is critical to fitting success. As with RGP lenses, it is vital that the cylinder correction on the lens aligns with the axis of astigmatic error on the eye. And, although hydrogel toric lenses are quickly being replaced by modern silicone hydrogel materials and lens designs, it is important to understand how today's designs have evolved.

The two most common ways of controlling rotation of the soft hydrogel toric lens are prism ballast and dynamic stabilization.[7] Clinical trials of these two designs suggest that stability is comparable and that visual performance should be roughly equal.[8] Unlike RGP lenses, soft lenses conform to the curvature of the corneal surface when placed on the eye. For this reason, selecting a soft toric lens design is directly related to each patient's corneal curvature.

As with RGP prism ballast designs, soft toric prism ballast designs incorporate base down prism in order to create a thicker inferior portion of the lens, which should orient itself at the six o'clock position. Gravity is the key factor in ensuring that the lens settles in the correct orientation.

But, there are disadvantages to prism ballasting soft lenses. The inferior portion of the lens can be somewhat less comfortable for some patients due to the increased thickness. Many of the more modern designs incorporate methods to decrease this lens awareness.

As with RGP lenses, the lateral-to-medial motion of the lids during a blink can cause lens rotation nasally. This is often minimized by utilizing larger diameter lenses to stabilize the lens by allowing it to "skirt" onto the 1mm to 2mm of conjunctiva beyond the limbus. In large-diameter, low oxygen-permeable, prism-ballasted hydrogel toric lenses, the inferior cornea may become hypoxic, resulting in complications such as neovascularization, corneal edema, limbal hyperemia and endothelial polymegathism.[9] More modern hyper-dK silicone hydrogel materials and designs very effectively address this issue.

Other disadvantages include incorrect settling of the lens when the patient is not vertically oriented (e.g., lying on one's side watching television) and binocular vertical prism imbalance when prescribed monocularly.[10] One study reported prism-ballasted lenses as having a minimal effect on binocular vision in normal patients. But, the researchers concluded that care should be taken when fitting these lenses monocularly in patients with vertical phoria-related problems.[11]

The concept of dynamic lens stabilization, known as "double thin zones" or "dual thin zones," was originally developed by Peter Fanti in 1975.[12] With this technique, the dominant lens orientation effect is achieved by pressure from the upper and lower lids. In 1983, Anthony Hanks used the analogy of the "watermelon seed," in which pressure applied to the thin end of a watermelon seed by one's fingers causes the seed to move away from the fingers.[13] In this lens design, the superior and inferior portions of the lens are thinner, with the toricity of

the lens confined to the central region. Lid forces act to "hold" the lens from rotating as they exert pressure on the superior and inferior "thinned" portions of the lens.[12]

Less common means of stabilizing a soft toric lens include truncation of the lower portion of the lens, so that the flat inferior edge of the lens aligns with the lower lid; chamfering, or creating a uniform edge thickness by slabbing off the anterior surface of the lens to reduce rotation; and using back-surface toric designs that utilize prism ballasting and thin zones to provide an aligned fit to the corneal curvature.[3] Most modern toric soft lens designs use a combination of stabilization factors to achieve good comfort, clear vision and minimal lens rotation.

While standard hydrogel toric lenses are being quickly replaced by silicone hydrogel (SiHy) toric lenses, it is not uncommon to still see many toric lenses of these designs being fit by practitioners. Some examples include SofLens 66 Toric (alphafilcon A, Bausch & Lomb), the Biomedics Toric (ocufilcon D, CooperVision), Focus Toric Monthly (vifilcon A, CIBA Vision) and the Focus Dailies Toric with AquaRelease (nelfilcon A, CIBA Vision).

In the SofLens 66 Toric, there is a low-torque prism ballast design, which is essentially a combination of prism ballast, a 360° chamfering of the edge for comfort and optic zone sizes based on lens power.[14] A wider prism ballast design is also used in the Biomedics Toric, but in addition to the prism ballast, the lens sports uniform thickness horizontally across any portion of the lens to minimize lens-eyelid interaction.[15]

In the Focus Toric Monthly, a back-surface toric design is used. This lens has a prism ballast and is cast-molded with a circumferential bevel. This is different from the Focus Dailies Toric with AquaRelease, in which the dual thin zone design forces the lid to squeeze the thinner superior and inferior portions of the lens, thus orienting the lens with the thicker central portion in the interpaplebral region.[16]

It is important to note that in patients with high amounts of refractive astigmatism, conventional quarterly or annual replacement soft toric lenses may still be prescribed. These lenses predominantly utilize one or more of these traditional stabilization techniques.

Silicone Hydrogel Toric Contact Lenses

The latest generation of high-dK disposable toric lenses has brought about a revolution in not only toric lens design, but also in improved comfort and corneal health. While many of the underlying stabilization properties still remain a vital part of the new lens designs, the improvements in rotational stability are noteworthy.

The Purevision Toric (balafilcon A, 99 dK/t, Bausch & Lomb) utilizes a low-torque design,which is similar to that of the SofLens 66 Toric. In this lens, a prism ballast is created by increasing the lens thickness incrementally from the top of the lens to the inferior mid-periphery. In addition, a 360° comfort chamfer is used to create a thin and uniform edge profile for comfort and stability. The optic zones are refined according to lens power to provide consistent lens thickness for every prescription, which is

Table 2. Silicone Hydrogel Toric Contact Lenses[21]

Brand	Replacement Schedule	dK	Material	Stabilization Design
Acuvue Advance for Astigmatism	Two weeks	60	Galyfilcon A	Accelerated Stability Design
Acuvue Oasys for Astigmatism	Two weeks	103	Senofilcon A	Accelerated Stability Design
PureVision Toric	Monthly	99	Balafilcon A	low-torque prism ballast
Air Optix for Astigmatism	Monthly	100	Lotrafilcon B	Precision Balance 8/4

important when considering the increased oxygen transmission of this material. The Purevision Toric also uses an aspheric front surface to decrease spherical aberrations.[17]

CIBA Vision's Air Optix for Astigmatism (lotrafilcon B, 108 dK/t) represents a departure from the company's traditional toric lens designs. With this lens, the manufacturer has created a design they call Precision Balance 8/4. This design utilizes a thinned back surface prism ballast design with the thickest portions at the four and eight o'clock positions. This design minimizes interaction with the lower lid, which in turn improves comfort and decreases rotation. The design also improves the oxygen transmission at the six o'clock position while allowing for high oxygen permeability across most of the lens. Finally, the seamless front surface allows for excellent stability and comfort.[18]

Vistakon's newest toric lens designs are the Acuvue Advance for Astigmatism (galyfilcon A, dK = 60) and the Acuvue Oasys for Astigmatism (senofilcon A, dK = 103). Both of these lenses utilize Vistakon's Accelerated Stability Design (ASD), which has grown out of the traditional dynamic stabilization designs. Making ASD unique is its four thickened stability zones at the two, four, right and 10 o'clock regions, which become positioned within the inter-palpebral fissure through interaction with normal lid forces. These lenses work with the lids to balance the lens when the eye is open and to realign the lens quickly if it rotates.[19,20]

In addition to controlling rotation, another key element evident in all of the new hyper-dK toric lenses is the maximization of oxygen transmission.

Each company has made strides to build upon last-generation stability, while improving comfort, vision and most importantly, oxygen transmission to the cornea.

Comparison Studies

With such a vast array of different silicone hydrogel lens designs, the question still remains as to which one works best. Because most of the new designs combine many different stabilization philosophies, it may be more enlightening to look at how previous designs compare to understand where we are now. In addition, many of the new design comparison studies are industry funded and therefore, may have questionable conclusions.

Obviously a number of different forces affect toric soft lenses and influence orientation. The role of the eyelid is significant, but recent studies suggest that other factors are involved as well. One study attempted to predict orientation in prism-ballasted toric lenses from the configuration of the lids and other ocular dimensions.[22] Although the study established some significant correlations, most notably between orientation and the intercanthal angle, the associations were weak, and study findings fell short of allowing the accurate prediction of lens orientation.[23]

In experiments where wearers adopt a horizontal recumbent position, we see that prism-ballasted lenses are, in fact, influenced by gravity.[24] However, the effect of gravity begins to subside once the lens rotates to within 30º of the intended base-down position, indicating that gravity has little effect on toric lenses when the orientation position is close to the typical equilibrium position. This explains why, as lenses reorient toward their equilibrium position, the process slows as the lens settles.[22] Lid forces appear to take over in the final phase of lens reorientation with much of the equilibration seen during the blinking action rather than between blinks, suggesting that dynamic lid forces are more influential than static lid forces pressing against the lens.

For the purpose of gauging lens stability, the most important factor is, of course, measuring lens rotation on the eye when the lens has reached equilibrium. To do this, we must consider both lens orientation, by which we can judge the likelihood of a lens to correctly align itself with the astigmatic axis of the eye, and stability, which is the likelihood that the alignment does not change over time. There are many methods to evaluate this clinically.

One method is to use subjective patient judgments using a ten-point vision rating scale.[25] Another approach is to assess the amount of rocking or oscillation observed with the blink.[26]

Yet another method is to measure orientation over a longer period of hours or days and then calculate the standard deviation of the mean values as an indication of stability.[8,27]

Other methods include assessing time until the lens reorients itself to the correct position after deliberate lens mislocation. Hanks referred to this as "rotational velocity," whereas Mike Covey used the term "reorientation speed."[26,28]

Tan and associates recently published a study in which a clearly defined set of toric soft contact lens descriptors were established to judge performance and to establish a means of predicting clinical success.[29] In this study, lenses were assessed by three measures: subjective comfort, lens orientation after equilibration, and rotational recovery after deliberate mislocation both nasally and temporally.[22] If, perhaps, these three parameters were to be applied in future studies, some uniformity could be established in measuring toric lens stability standards.

In yet another recent study, the rotation of an accelerated stability design lens was compared to the low-torque prism ballast design under natural viewing conditions.[23] In this study, the Eyetrack Monitoring System (ETMS) was utilized. The ETMS consists of infrared video-based monitoring of the contact lens. The lens stability was then measured during four different tasks involving saccadic movements. Both lenses were judged to provide acceptable performance in terms of induced astigmatism produced by off-axis lens rotation.[23] More importantly, the ETMS may provide significant improvements in objective means of assessing lens stability in future studies.

What the Future Holds

As manufacturing techniques continue to evolve, the ability to produce patient-specific custom toric parameters in hyper-dk materials nears reality. It is not difficult to imagine that in the very near future, we will be able to customize lenses for patients that are rotationally stable, healthy and provide crisp, clear vision for nearly all corrections.

Practitioners now enjoy the option of many hyper-dk toric lenses that provide excellent rotational stability and visual clarity as well as good comfort and health. Fitting sets are compact and make first-lens fitting success achievable with a high degree of patient satisfaction. Making lenses available in higher astigmatic powers appears to be one of the last barriers to fully customizable rotationally stable contact lenses. When this is achieved, there will be no logical reason that all patients shouldn't have stable, comfortable lenses for any amount of astigmatism.

The author thanks Trish Duffel, of the University of Iowa Hospitals and Clinics Department of Ophthalmology and Visual Sciences, for her aid in researching this course.

1. Holden BA. The principles and practice of correcting astigmatism with soft contact lenses. Aust J Optom 1975;58:279-99.
2. Mandell RB, Blaze P. Toric hydrogel lens correction. In: Bennett ES, Weissman BA, editors. Clinical contact lens practice. Philadelphia: Lippincott;1991.
3. Russell CH, Slonim CB. The correction of astigmatism with soft contact lenses. Ophthalmol Clin North Am 2003 Sep;16(3):353-8.
4. Jurkus JM. Toric soft lenses. In: Schwartz CA, ed. Specialty contact lenses: a fitter's guide. Philadelphia: WB Saunders; 1996.
5. Bennett, ES. Back toric rigid gas permeable lenses. In Schwartz CA, ed. Specialty contact lenses: a fitter's guide. Philadelphia: WB Saunders; 1996.
6. Kastl PR. Correction of astigmatism with rigid gas permeable lenses. Ophthalmol Clin Ophthalmol Clin North Am. 2003 Sep;16(3):359-63.
7. Tomlinson A, Ridder WH, Watanabe R. Blink-induced variations in visual performance with toric soft contact lenses. Optom and Vision Sci 1994 Sep;71(9):545-9.
8. Hanks AJ, Weisbarth RE, McNally JJ. Clinical performance comparisons of toric soft contact lens designs. ICLC 1987;14:16-21.
9. Forister J, Chao J, Khy K, et al. Predicted tear layer oxygen tensions under two designs of silicone hydrogel toric lenses. Cont Lens Anterior Eye 2008 Oct;31(5):228-41.
10. Young G. Toric lenses, gravity, and other forces. Contact Lens Spect. Available at: www.clspectrum.com/article.aspx?article=13174. (Accessed Jan 2009).
11. Nilsson M, Stevenson SB, Leach N, et al. Vertical imbalance induced by prism-ballasted soft toric contact lenses fitted unilaterally. Ophthalmic Physiol Opt 2008 Mar;28(2):157-62
12. Lindsay RG. Soft toric lens design and fitting (Chapter 10). In: Efron N, ed. Contact Lens Practice. London: Butterworth-Heinemann, 2002.
13. Hanks AJ. The watermelon seed principle. Contact Lens Forum 1983;8(9):31-5.
14. Bausch & Lomb. Contact lenses and care: soflens toric contact lenses. Available at: www.bausch.com/en_US/ecp/visioncare/product/softcontacts/sftoric_ecp.espx. (Accessed Feb 2009.
15. Coopervision. Biomedics toric. Available at: www.coopervision.com/US/practitioner/contactlenses/brands/biomedics/biomedicstoric. (Accessed Feb 2009).
16. CIBA Vision. Focus Toric Monthly. Available at: www.us.cibavision.com/lenses/astigmatism.shtml. (Accessed Feb 2009).
17. Bausch & Lomb. Contact lenses and care: Purevision toric. Available at: www.bausch.com/en_US/ecp/visioncare/product/softcontacts/purevision_toric.aspx. (Accessed Feb 2009).
18. CIBA Vision. Air Optix for Astigmatism. Available at: www.airoptix.com/ecp/toric/toric_overview.shtml. (Accessed Feb 2009).
19. Johnson & Johnson Family of Companies. Acuvue Advance brand contact lenses. Available at: www.acuvue.com/acuvue_astig.htm. Accessed February 14, 2009.
20. Russell, GE. Clinical aspects of toric silicone hydrogel lenses: material and fitting considerations. Review of Optometry 2007 Sept: 6-11.
21. Thompson TT. Tyler's quarterly soft contact lens parameter guide 2008 Dec 26(1): 9-11.
22. Young G, Hunt C, Covey M. Clinical evaluation of factors influencing toric soft contact lens fit. Optom and Vis Sci 2002 Jan;79(1):11-9.
23. Young G. Toric contact lens designs in hyper-oxygen materials. Eye & Contact Lens 2003 Jan;29(1 Suppl):S171-3.
24. Young G. Factors influencing toric soft lens fit. Paper presented at the British Contact Lens Association Conference, Brighton, UK, 2001.
25. Remba MJ. Clinical evaluation of contemporary soft toric lenses. Inter Cont Lens Clin 1985;12:294-303.
26. Covey M. A clinical evaluation of Frequency 55 toric. Optician 2000;219:24-8.
27. Castellano CF, Myers RI, Becherer PD, Walter DE. Rotational characteristics and stability of soft toric lenses. J Am Optom Assoc 1990 Mar;61(3):167-70.
28. Tan J, Papas E, Carnt N, et al. Performance standards for toric soft contact lenses. Optom and Vis Sci 2007 May;84(5):422-8.
29. Zikos GA, Kang SS, Cuiffreda KJ, et al. Rotational stability of toric soft contact lenses during natural viewing conditions. Optom and Vis Sci 2007 Nov;84(11): 1039-45.

Self-Assessment Examination: Stabilization Factors of Toric Contact Lenses

DIRECTIONS: To obtain 2 hours of continuing education credit, complete the exam by recording the best answer to each self-assessment question on the Examination Answer Sheet on Page 32. Mail the answer sheet to Optometric CE, P.O. Box 488, Canal Street Station, New York, NY 10013. A minimum score of 70 is required to obtain a certificate of completion. There is no fee for this course.

1. Which of the following statements is true?
a. Refractive astigmatism is affected by residual astigmatism.
b. Residual astigmatism is affected by corneal astigmatism.
c. Corneal astigmatism is the only factor in refractive astigmatism.
d. Refractive astigmatism does not include corneal astigmatism.

2. Roughly what percentage of contact lens wearers have astigmatism over 0.75D?
a. 25%.
b. 60%.
c. 45%.
d. 33%.

3. Which equation is correct?
a. Corneal Astigmatism + Refractive Astigmatism = Residual Astigmatism.
b. Refractive Astigmatism – Corneal Astigmatism = Residual Astigmatism.
c. Refractive Astigmatism + Residual Astigmatism = Corneal Astigmatism.
d. Induced Astigmatism + Residual Astigmatism = Corneal Astigmatism.

4. Which of the following is true?
a. Spherical RGP lenses can mask astigmatism in patients with little residual astigmatism and low corneal astigmatism.
b. Spherical RGP lenses are a good choice for patients with >2.50D of corneal astigmatism.
c. Bitoric RGP lenses are indicated when corneal astigmatism is less than 1.00D.
d. Spherical RGP lenses are never a good choice for astigmatic patients.

5. Which of the following statements is true?
a. Front toric RGP lenses are used in patients with corneal cylinder greater than 2.50D.
b. Bitoric RGP lenses are always used in patients with less than 2.50D corneal cylinder.
c. Back toric RGP lenses are used in patients with greater than 2.50D residual cylinder.
d. Bitoric RGP lenses are used in patients with corneal cylinder over 2.50D and residual cylinder over 1.00D.

6. Lid forces during the blink often cause a front toric lens to experience:
a. Clockwise rotation.
b. Counterclockwise rotation.
c. Temporal rotation of the six o'clock position.
d. Nasal rotation of the six o'clock position.

7. The purpose of the back surface in a bitoric lens is to:
a. Provide correction of residual astigmatism.
b. Allow for rotation of the lens.
c. Provide rotational stability.
d. Improve comfort.

8. Which of the following is one of the more common means of controlling rotation of soft hydrogel torics?
a. Truncation.
b. Posterior surface torics.
c. Chamfering.
d. Dynamic stabilization.

9. The thicker inferior portion of a prism-ballast soft hydrogel lens would not contribute which of the following?
a. Improved comfort.
b. Neovascularization.
c. Endothelial polymegathism.
d. Corneal edema.

10. Prism-ballast lenses in hydrogel materials do not:
a. Incorrectly settle when lying horizontally.
b. Cause a vertical prism effect if fit monocularly.
c. Cause limbal hyperemia.
d. Create a rainbow effect by scattering light of different wavelengths.

11. The "watermelon seed" theory suggests that:
a. Small lenses can cause big problems.
b. Lenses with a more oval shape would be more stable.
c. Lid forces squeeze thinner portions to decenter the lens.
d. Lid forces put pressure on the thinner portions of the lens for stabilization.

12. Double thin zones were first described by:
a. Nilsson.
b. Holden.
c. Hanks.
d. Fanti.

13. Which of the following statements is true?
a. Truncation is commonly used in stabilizing toric contact lenses.
b. Most modern torics use a combination of stabilization factors.
c. Today's toric lenses are no more stable than lenses from five years ago.
d. Refractive cylinder has nothing to do with corneal cylinder.

14. Markings on the toric lens are not used to:
a. Determine lens parameters.
b. Identify a lens manufacturer and brand.
c. Assess rotation of the lens.
d. Determine refractive astigmatism.

15. Soft toric lenses are NOT stabilized by:
a. Chamfering.

b. Truncating.
c. Lathing.
d. Prism-ballasting.

16. In clinical studies, it was found that:
a. Although gravity may play a role in lens orientation, it is much less when the lens nears equilibrium.
b. Tear film volume is more influential in toric lens stability than lid forces.
c. Interstudy uniformity would not help in comparing toric lens designs.
d. All hydrogel toric lenses work the same.

17. The time it takes for a lens to reorient itself after deliberate mislocation is termed:
a. Spin speed.
b. Rotational velocity.
c. Twist time.
d. Circumferential reorientation.

18. Which is not a good way to measure toric lens stability?
a. Subjective comfort.
b. Lens orientation after equilibrium.
c. Binocular balance.
d. Rotational recovery after deliberate mislocation.

19. Which statement is true regarding prism ballast lenses?
a. Gravity has no effect on these lenses.
b. Gravity's greatest effect is seen in the final stages of lens settling.
c. Lid forces do not help to stabilize prism ballast lenses upon insertion.
d. Lid forces have the greatest effect in the final phase of lens orientation.

20. Methods of assessing rotational stability do not include:
a. Subjective patient judgments.
b. Watermelon seeds.
c. Reorientation speed.
d. Infrared video-based monitoring.

Examination Answer Sheet

Valid for credit through May 31, 2010

Stabilization Factors of Toric Contact Lenses

Directions: Select one answer for each question in the exam and completely darken the appropriate circle. A minimum score of 70% is required to earn credit.

Mail to: Optometric CE, PO Box 488, Canal Street Station, New York, NY 10013

COPE approved for 2 hours of CE credit. COPE ID 24886-CL

This course is joint-sponsored by the University of Alabama School of Optometry and supported by an unrestricted educational grant from **The Vision Care Institute™, LLC**.

There is an eight-to-ten week processing time for this exam.

1. Ⓐ Ⓑ Ⓒ Ⓓ
2. Ⓐ Ⓑ Ⓒ Ⓓ
3. Ⓐ Ⓑ Ⓒ Ⓓ
4. Ⓐ Ⓑ Ⓒ Ⓓ
5. Ⓐ Ⓑ Ⓒ Ⓓ
6. Ⓐ Ⓑ Ⓒ Ⓓ
7. Ⓐ Ⓑ Ⓒ Ⓓ
8. Ⓐ Ⓑ Ⓒ Ⓓ
9. Ⓐ Ⓑ Ⓒ Ⓓ
10. Ⓐ Ⓑ Ⓒ Ⓓ
11. Ⓐ Ⓑ Ⓒ Ⓓ
12. Ⓐ Ⓑ Ⓒ Ⓓ
13. Ⓐ Ⓑ Ⓒ Ⓓ
14. Ⓐ Ⓑ Ⓒ Ⓓ
15. Ⓐ Ⓑ Ⓒ Ⓓ
16. Ⓐ Ⓑ Ⓒ Ⓓ
17. Ⓐ Ⓑ Ⓒ Ⓓ
18. Ⓐ Ⓑ Ⓒ Ⓓ
19. Ⓐ Ⓑ Ⓒ Ⓓ
20. Ⓐ Ⓑ Ⓒ Ⓓ

21. The goal statement was achieved:
◯ Very Well ◯ Adequately ◯ Poorly

22. The information presented was:
◯ Very Useful ◯ Useful ◯ Not Very Useful

23. The difficulty of the course was:
◯ Complex ◯ Appropriate ◯ Basic

24. Your knowledge of the subject was increased:
◯ Greatly ◯ Somewhat ◯ Hardly

25. The quality of the course was:
◯ Excellent ◯ Fair ◯ Poor

How long did it take to complete this course?

Comments on this course:

Topics you would like in the future CE articles:

Please retain a copy for your records. Please print clearly.

You must choose and complete one of the following three identifier types:

① SS # ___ - __ - ____

② Last 4 digits of your SS # and date of birth ____ - ____

③ State Code and License #: (Example: NY12345678) _____

First Name

Last Name

E-Mail

The following is your: ☐ Home Address ☐ Business Address

Business Name

Address

City State

ZIP

Telephone # ___ - ___ - ____

Fax # ___ - ___ - ____

By submitting this answer sheet, I certify that I have read the lesson in its entirety and completed the self-assessment exam personally based on the material presented. I have not obtained the answers to this exam by any fraudulent or improper means.

Signature _____ Date _____

Lesson 106090 **RCCL-UAB-0509**

Modern Management of Pterygia

Know what signs and symptoms to look for pre- and postoperatively and how to properly co-manage and educate patients.

By Lori Vollmer, O.D., F.A.A.O.

We often read articles on rare and interesting cases that present to our colleagues' practices; but, what about the patients with more common conditions who end up in our chairs? One such common ocular surface condition is the pterygium.

A pterygium is a benign growth of bulbar conjunctival epithelium and hypertrophied subconjunctival connective tissue within the palpebral fissure. It typically grows in a characteristic triangular wedge and invades the cornea from the medial and lateral bulbar conjunctiva.[1] In many cases, pterygia are associated with an iron line (Stocker's line) or a growth plate *(figure 1)*. They are most often seen nasally, but may also occur temporally, both nasally and temporally or, rarely, inferiorly.[2] It is believed to be caused by irritation, producing a chronic inflammatory cell infiltration with resultant edema and angiogenesis.[3] Common causes of environmental irritants include ultraviolet radiation, wind and dust.[1,2,4] Other factors reported to be associated with pterygium development include genetics, anti-apoptotic mechanisms, action of cytokines and growth factors, extracellular matrix remodeling, immunologic mechanisms and viral infections.[1,5] So what approach can practitioners take in treating this common condition? In patients with a pterygium, establishing a differential diagnosis is the key. Then, the condition is managed through careful observation, topical therapy or surgery.

Non-Invasive Therapy

Observation is the most appropriate management option for patients who are not symptomatic and those who are not bothered by their appearance cosmetically. Observation is also employed in those whose pterygium shows 2mm of corneal extension or less and presents no encroachment of the visual axis. Re-examination every 6 to 12 months, depending on the initial size, is appropriate since these lesions tend to grow very slowly. Photo documentation of the lesion or measurements recorded in millimeters of extension onto the cornea from the

Dr. Vollmer is an assistant professor of optometry and director of residency programs at Nova Southeastern University. She is a Fellow in the American Academy of Optometry, a Fellow in the Optometric Retina Society, a member of the American Optometric Association and Secretary of the Broward County Optometric Association.

All photos courtesy of Arnulfo Mansur, M.D.

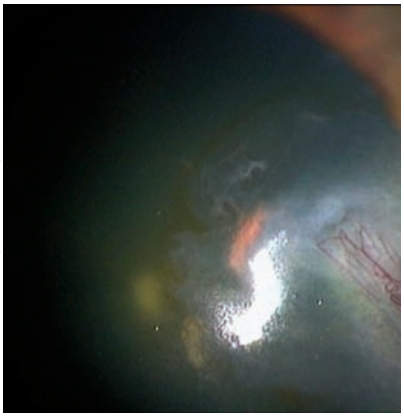

1. This pterygium demonstrates Stocker's line, a growth plate and seeding. The growth plate is the white avascular area leading the pterygium.

limbus as well as the vertical height will aid in future monitoring for growth. Practitioners may also utilize keratometry or topography, since many patients may have induced astigmatism from pterygia.

Topical Therapy

Interventional therapies are indicated when the patient complains of discomfort, often related to poor surface wetting and dry eye, or if inflammation occurs. Potentially beneficial topical therapies include artificial tears and cool compresses for minimal ocular surface discomfort, or nonsteroidal anti-inflammatory drugs (NSAIDs) such as Acular LS (ketorolac tromethamine, Allergan), Voltaren (diclofenac, Novartis), Nevanac (nepafenac, Alcon) or Xibrom (bromfenac, Ista Pharmaceuticals) for mild-to-moderate inflammation. Topical steroids, such as Alrex (loteprednol etabonate ophthalmic suspension 0.2%, Bausch & Lomb) may also be used for mild inflammation. For more significant inflammation, viable options include Pred Forte (prednisolone acetate, Allergan) and Lotemax (loteprednol etabonate ophthalmic suspension 0.5%, Bausch & Lomb), particularly if intraocular pressure (IOP) elevation is a concern. Since the condition is chronic and inflammation may recur, it is important to watch patients closely and educate them on the side effects of long-term steroid use. In these patients, topical therapy is generally seen as a short-term option rather than chronic management; if long-term steroid use is necessary, consider surgical intervention.

Surgery for Pterygia

When the pterygium causes visual disturbance through irregular astigmatism or uncorrectable aberration, is a source of chronic inflammation, induces formation of corneal dellen, or endangers the visual axis (greater than 2mm of corneal extension), surgery becomes necessary. It is best to remove these lesions prior to involvement of the visual axis in order to minimize postoperative corneal scarring within the visual axis and the possibility of permanent reduction in visual acuity.

Various methods have been used for surgical excision in the past, including bare sclera excision with or without mitomycin C or beta-irradiation, as well as excision with conjunctival sutures. But, these techniques are no longer used due to the extremely high rate of recurrence.[1,2,6]

Currently, the favored surgical technique is a complete excision of all involved tissue with a limbal conjunctival autograft (LCA) and fibrin glue rather than sutures *(figure 2)*. Some surgeons may also perform a superior conjunctival reconstruction *(figure 3)*. With this technique, the use of LCA significantly reduces the chance of regrowth.[1,2,7] The recurrence rate with LCA and sutures varies depending on the study cited and patient compliance with postoperative steroid therapy, ranging from 0% to 14.6%.[1,2,7-9] Grafts with human amniotic membrane (HAM) have also been shown to have low rate of recurrence and lack of serious complications. HAM is recommended when an LCA is not a viable option. In these cases, either an LCA has already been performed, the surgical area is large, scarring is present from a previous surgery or the patient may need trabeculectomy surgery in the future and the superior bulbar conjunctiva needs to be preserved *(figure 4)*.[10]

Pterygium surgery may also be combined with an anti-metabolite agent, such as mitomycin-C (MMC) to enhance outcome. But, due to the high success rate and low recurrence rate of pterygium excision combined with LCA, this technique is often used without the addition of MMC in an effort to avoid anti-metabolite-induced complications. MMC is typically used when initial surgery has failed or the patient has a particularly thick or aggressive pterygium.[11,12] Beta irradiation, often employed prior to the advent of antimetabolites, is rarely used due to the risk of radiation-induced complications. Complication associated with the

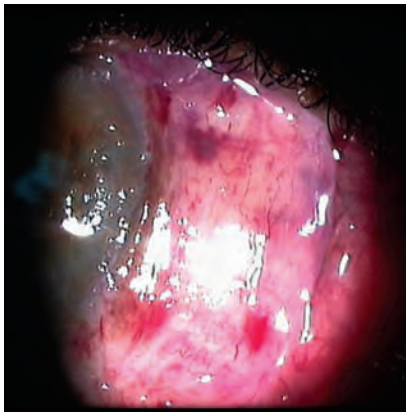

2. A well-placed limbal conjunctival autograft (LCA) secured with fibrin glue in the immediate postoperative period.

use of anti-metabolites and beta irradiation may include corneoscleral melt, cataracts, uveitis and secondary glaucoma.[1,2]

Newer surgical options now involve the use of fibrin (tissue) glue rather than sutures. Tissue glue has been used surgically in the past for repair of corneal lacerations and globe perforations, leaking trabeculectomies or cataract surgery wounds and lamellar keratoplasty.[1,2,13] One commonly used fibrin sealant is TISSEEL Duo Quick (Baxter). This agent includes two components; fibrinogen and thrombin. The human extracted fibrinogen, obtained via a plasma donor, is mixed with factor XIII and bovine aprotinin. The thrombin and calcium chloride solution is a sealer protein concentrate and mediates the conversion of fibrinogen to fibrin, cross-linked by factor XIII, creating a stable clot.[1,14] Though the risk of disease transmission or anaphylactic reaction theoretically exists, it has never been reported—the substance is screened to prevent contamination and viral transmission.[14,15]

The use of sutures to secure autografts, though successful, involves longer and more complicated surgeries as well as increased levels of postoperative inflammation and pain. The use of fibrin glue decreases surgical time, postoperative inflammation, discomfort and recovery time, and it removes the chance of complications that may arise from sutures.[1,8,15,16] Sutures may act as a portal for infection or a nidus for additional inflammation.[9,15] It also makes comanagement easier, because patients do not need to return for suture removal following surgery.

Patients with sutures in the graft postoperatively must have the sutures removed following surgery. These cause the patient to experience foreign body sensation, tearing and photophobia. Graft edema and subconjunctival hemorrhage are also common when sutures are used *(figure 5)*. Patients whose autografts are secured by fibrin glue experience less discomfort and can usually return to work within 48 hours *(figure 6)*.

It is normal for the conjunctiva to have some degree of hemorrhage and chemosis with either technique. Regardless of the method used to secure the autograft, the first week post-op involves topical steroids, antibiotics and copious artificial tears. After the first week, there is a long course of steroids used to decrease inflammation and discourage graft rejection or the likelihood of recurrence. The tapering process is typically over a period of one month.

It has also been suggested that the amount of postoperative inflammation plays an important role in the rate of recurrence. In the case of LCA secured with sutures, the sutures act as irritants to the graft and increase inflammation postoperatively. Since inflammation is lower in the absence of sutures, most studies report that pterygium surgery using tissue sealant is associated with a lower recurrence rate.[2,8,13] Furthermore, the use of fibrin glue has been demonstrated to be a safe and effective means of securing conjunctival autografts during pterygium surgery excision.[2,8,9,13-15,17]

Comanagement

When comanaging patients after pterygium excision, it is important to ensure compliance with all medications, monitor for potential complications of prolonged topical steroid treatment (such as IOP elevation and cataract formation) and watch for graft complications or regrowth. It is important to refer the patient back to the surgeon at the first sign of possible regrowth for early intervention. In some cases, postoperative intralesional injection of 5 fluorouracil (5-FU) is

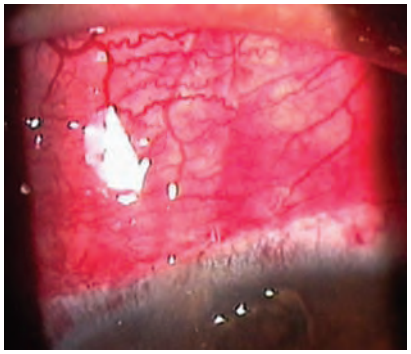

3. A demonstration of superior conjunctival reconstruction with fibrin glue following the excision of the autograft from the superior bulbar conjunctiva.

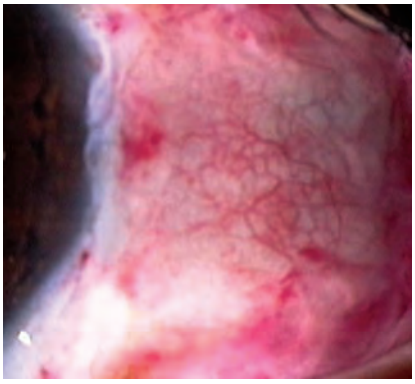

4. A healthy appearing graft with human amniotic membrane approximately one week after surgery.

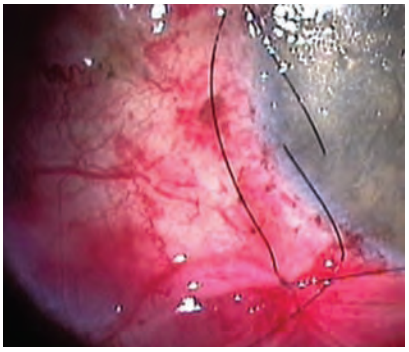

5. An autograft secured with sutures in the immediate postoperative period. The sutures will remain in the eye for approximately one week.

effective in inhibiting the recurrence of pterygium regrowth by halting the progression of fibrovascular tissue. This may be a treatment option for patients with impending pterygium regrowth.[18-20] Other potential complications to be aware of postoperatively include graft dehiscence, graft edema, graft necrosis and corneal dellen formation.

Differential Diagnoses

Though pterygia are common and easily identified, practitioners should keep in mind other possible conditions when looking at an atypical lesion. These include symblepharon; ocular cicatricial pemphigoid (OCP), an autoimmune disease that affects mucus membranes; Steven-Johnson Syndrome, which results in destruction of goblet cells and lack of conjunctival mucus leading to keratinization and scarring; chemical burns, which may result in conjunctival scarring; and conjunctival intraepithelial neoplasm (CIN), which is a slowly progressive proliferation of dysplastic squamous epithelium.

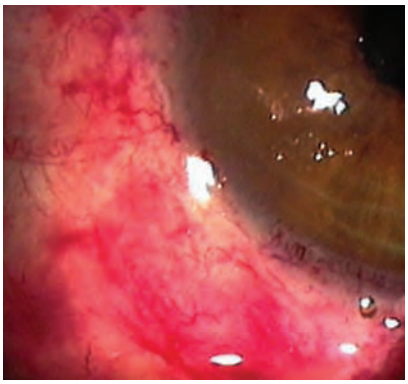

6. An autograft secured with fibrin glue rather than sutures in the immediate postoperative period.

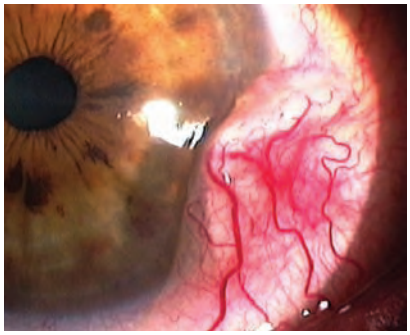

7. This photograph reveals conjunctival intraepithelial neoplasm (CIN), which may be commonly confused with a pterygium. This lesion has a more gelatinous appearance than a pterygium.

Of these, CIN is likely the most commonly confused with pterygium. In CIN, the conjunctiva appears more gelatinous and possibly leukoplakic. It is associated with feeder vessels that do not grow in an organized pattern of a triangular wedge with horizontally stretched vessels, as in pterygium. The lesions may also appear to originate from an atypical location, such as the inferior or superior conjunctiva, and are more commonly limbal *(figure 7)*. Suggested risk factors for this condition involve sun exposure, human papilloma virus and HIV infection.[21]

Management of CIN may involve surgical excision with cryotherapy, topical 5-FU, topical MMC, or topical interferon (INF alpha 2-,).[22-25] In advanced cases, enucleation may be necessary. Any suspicious or atypical appearing pterygia should be referred for further evaluation and possible biopsy.

Recognize the Signs

Pterygium is a common condition that presents in our practices on a regular basis. It is important for the physician to understand the surgical techniques involved in caring for these patients and to properly educate patients about what to expect once referred.

In addition, when managing patients postoperatively, it is important for the clinician to recognize complications or regrowth early in the postoperative period and refer the patient for additional care immediately, which will result in a better outcome for your patient. RCCL

1. Kim H, Mun H, Park Y, Lee K, Shin J. Conjunctival autografts using a fibrin adhesive in pterygium surgery. Kor J Ophthalmol 2008 Sep;22(3):147-54.
2. Koranyi G, Seregard S, Kopp ED. The cut-and-paste method for primary pterygium surgery: long term follow-up. Acta Ophthalmol Scand 2005 Jun;83(3):298-301.
3. Hill JC, Maske R. Pathogenesis of pterygium. Eye 1989;3(Pt 2):218-26.
4. Moran DJ, Hollows FC. Pterygium and ultraviolet radiation: a positive correlation. Br J Opthalmol 1984 May;68(5):343-6.
5. Kria L, Ohira A, Amemiya T. Immunohistochemical localization of basic fibroblast growth factor, platelet derived growth factor, transforming growth factor-beta and tumor necrosis factor-alpha in the pterygium. Acta Histochem 1996 Apr;98(2):195-201.
6. Sanchez-Thorin JC, Rocha G, Yelin JB. Meta-analysis on the recurrence rates after bare sclera resection with and without mitomycin C use and conjunctival autograft placement in surgery for primary pterygium. Br J Ophthalmol 1998 Jun;82(6):661-5.
7. Hirst LW. Prospective study of primary pterygium surgery using pterygium extended removal followed by extended conjunctival transplantation. Ophthalmology 2008 Oct;115(10):1663-72.
8. Karalezli A, Kucukerdonmez C, Akova YA, Borazan M. Fibrin glue versus sutures for conjunctival auto-grafting in pterygium surgery: a prospective comparative study. Br J Ophthalmol 2008 Sep;92(9):1206-10.
9. Marticorena J, Rodríguez-Ares MT, Touriño R, et al. Pterygium surgery: conjunctival autograft using a fibrin adhesive. Cornea 2006 Jan;25(1):34-6.
10. Solomon A, Pires RT, Tseng SC. Amniotic membrane transplantation after excessive removal of primary and recurrent pterygium. Ophthalmology 2001 Mar;108(3):449-60.
11.Lam DS, Wong AK, Chew S, et al. Intraoperative mitomycin C to prevent recurrence of pterygium after excision: a 30-month follow-up study. Ophthalmology 1998 May;105(5):901-4.
12.Anduze AL, Burnett JM. Indications for and complications of mitomycin C in pterygium surgery. Ophthalmic Surg Lasers 1996 Aug;27(8):667-73.
13. Bahar I, Weinberger D, Gaton DD, Avisar R. Fibrin blue versus vicryl sutures for primary conjunctival closure in pterygium surgery: long term results. Curr Eye Res 2007 May;32(5):399-405.
14. Jackson MR. Fibrin sealants in surgical practice: an overview. Am J Surg 2001 Aug;182(2 Suppl):1S-7S.
15. Pfister RR, Sommers CI. Fibrin sealant in corneal stem cell transplantation. Cornea 2005 Jul;24(5):593-8.
16. Watts MT, Collin R. The use of fibrin glue in mucous membrane grafting of the fornix. Ophthalmic Surg 1992 Oct;23(10):689-90.
17. Uy HS, Reyes JM, Lim-Bon-Siong R. Comparison of fibrin glue and sutures for attaching conjunctival autografts after pterygium excision. Ophthalmology 2005 Apr;112(4):667-71.
18. Prabhasawat P, Tesaribul N, Leelapatranura K, Phonjan T. Efficacy of subconjunctival 5 fluorouracil and triamcinolone injections in impending recurrent pterygium. Ophthalmology 2006 Jul;113(7):1102-9.
19. Bekibele CO, Baiyeroju AM, Ajayi BG. 5 fluorouracil vs. beta irradiation in the prevention of pterygium recurrence. Int J Clin Pract 2004 Oct;58(10):920-3.
20. Akarsu C, Taner P, Ergin A. 5 fluorouracil as chemoadjuvant for primary pterygium surgery: preliminary report. Cornea 2003 Aug;22(6):522-6.
21. Kiire CA, Dhillon B. The aetiology and associations of conjunctival intraepithelial neoplasia. Br J Ophthalmol 2006 Jan;90(1):109-13.
22. Schallenberg M, Niederdraig N, Steuhl KP, Meher D. Topical mitomycin C as a therapy for conjunctival tumors. Opthalmologe 2008 Aug;105(8):777-84.
23. Schechter BA, Schner A, Naglar RS, Smith EF, Velasquez GE. Regression of presumed primary conjunctival and corneal intraepithelial neoplasia with topical interferon alpha-2b. Cornea 2002 Jan;21(1):6-11.
24. Poothullil AM, Colby KA. Topical medical therapies for ocular surface tumors. Semin Ophthalmol 2006 Jul-Sep;21(3):161-9.
25. Peksayar G, Altan-Yaycioglu R, Onal S. Excision and cryosurgery in the treatment of conjunctival malignant epithelial tumors Eye 2003 Mar;17(2):228-32.

An Eye Under Attack

How do you differentiate between the various types of corneal infiltrates and prevent sight-threatening consequences?

By Ellin Chen, O.D., and Barry A. Weissman, O.D., Ph.D., F.A.A.O., Dipl.

Imagine this scenario: You are beginning your fourth year in optometry school. A 30-year-old female soft contact lens wearer presents to your school's clinic for a "red eye" emergency visit and is now in your chair. Your attending advises you not to consider other history. From across the room, you note that her left eye has mild conjunctival injection.

Upon biomicroscope examination, her right eye appears unremarkable, but her left eye shows mild conjunctival injection, especially in the superior-temporal sector. You also note one white, hazy, lesion just beneath the epithelium—it's about 1mm round in diameter and located about 2mm inward from the superior-temporal limbus. There is no cell or flare in her anterior chamber. The patient's upper lids show mild meibomian gland dysfunction with scruff/collarettes on the lashes, and mild papillae are seen upon lid eversion, but no frank giant papillae are noted; the left upper lid, however, is trace edematous. Use of sodium fluorescein dye reveals slight disruption of the epithelial cell layer overlying the white lesion, but no significant epithelial defects are found.

So, what is your diagnosis and treatment plan?

This case presents quite a challenge. Patients almost always present with a history that will help to guide the clinician to likely diagnoses, which then can be further refined by appropriate additional investigations. Without a history, visual evaluation of an eye in isolation only provides signs but no symptoms.

The attending and you now decide to take the patient's history. You learn that she awoke with pain in her left eye at 2 a.m. this morning and subsequently removed her lenses, but both the pain and anxiety kept her awake. Her soft contact lenses were prescribed through an eye-care chain store about two

Dr. Chen is a contact lens fellow at the Jules Stein Eye Institute and Department of Ophthalmology of the David Geffen School of Medicine at UCLA. Dr. Chen has been supported, in part, by an educational grant from The Vision Care Institute LLC, a Johnson & Johnson Company.

Dr. Weissman is a professor of ophthalmology and chief of Contact Lens Service, at the Jules Stein Eye Institute and Department of Ophthalmology of the David Geffen School of Medicine at UCLA. He has been supported, in part, by a grant from Dr. Mavin Smotrich.

years previously; she reports no subjective problems, but also no follow-up care. She obtains her replacement lenses through the Internet and changes them every two to three weeks, as she is aware that she has "two-week" lenses. She also knows that they have been "approved" for extended wear, so she occasionally sleeps, showers and swims with the lenses on her eyes.

But, what if she presented with a history involving gardening as a hobby and a foreign body sensation in that eye a few hours before it became red? Then, the history would point you toward a different diagnosis and treatment plan. The former suggests microbial keratitis (MK), while the latter indicates a fungal keratitis, or even herpes simplex keratitis.

The bottom line: You must always be alert to the possibility of *Acanthamoeba* or fungal infection masquerading as herpes simplex or a solution-related complication.

The Many Faces of Infiltrates

When dealing with corneal infiltrates, keep several factors in mind. First, note the size and shape of the lesions. Are they dendritic? Round? Large or small? Do they have feathery edges and perhaps "satellite" changes? Do they have such "fellow travelers" as decreased corneal sensitivity, anterior chamber inflammation, radial perineuritis, lid edema or follicles? Are they unilateral or bilateral? What are the specifics of disruption and staining of the epithelium?

The answers to these questions, added to the patient's history, will point you in the direction of both the appropriate diagnosis and your initial treatment plan.

Corneal infiltrates may be signs of solution sensitivity, hypoxia, true corneal microbial infection—or unrelated complications, such as adenoviral infection.[1-3] Corneal infiltrates are defined as aggregates of inflammatory cells, such as polymorphonuclear leukocytes or macrophages recruited by an inflammatory cascade and/or microbial antigens (bacteria, fungi, amoebae, viral particles, etc). Perhaps the two classic infiltrates are the dendritic lesions of herpetic keratitis and the round (nummular) infiltrates of epidemic keratoconjunctivitis (EKC), which are now known to be caused by various types of adenovirus. Corneal infiltrates similar in appearance to those of EKC are also classically seen in one form of corneal graft rejection and other infections. Such infiltrates occasionally can also be seen in normal eyes due to normal ongoing "surveillance" activities of the immune system.[4] The peripheral corneal infiltrates associated with blepharitis (phlyctenules and catarrhal ulcers) are also common and considered sterile.[5]

Sterile vs. Infectious

Perhaps the most important consideration is to distinguish between sterile and presumed infectious infiltrates. Infiltrates are likely considered to be infectious if they are single (rather than multiple) and large (>1mm) rather than small (<1mm), occur with increasingly severe pain and photophobia, and are associated with an overlying epithelial defect. Adnexal inflammation—such as injected conjunctiva, swollen lid, anterior chamber reactions—are also more suggestive of infection than non-infectious inflammation.[6]

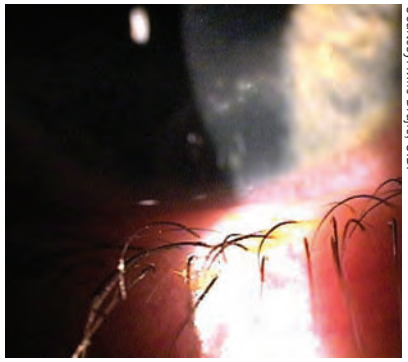

Courtesy: Mile Brujic, O.D.

There are corneal infiltrates above the inferior lid. A possible early microbial keratitis should be considered until proven otherwise.

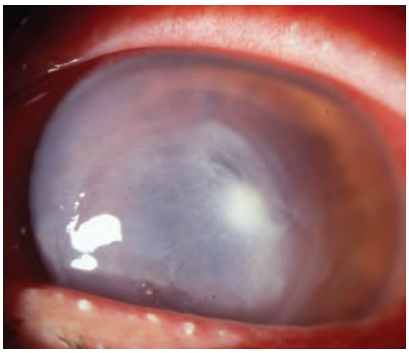

This is a culture-positive microbial corneal infection (*Pseudomonas aeruginosa*).

But, there are always exceptions to the rule. One study details the treatment of nine contact lens patients, who presented with presumably sterile peripheral corneal infiltrates, with topical corticosteroid drops. Eight improved, but one developed a culture-positive *Pseudomonas aeruginosa* corneal infection.[7]

Although rarely caused by hypoxia, most corneal infiltrates not associated with microbial infection or hypersensitivity reactions to bacterial toxins or solution preservatives likely result from non-contact lens-related viral infections (e.g., adenovirus, herpes).

The most devastating and sight-threatening infiltrate associated with lens wear is that of a microbial corneal ulcer. Microbes seen most commonly include

Pseudomonas aeruginosa and other gram-negative and gram-positive bacteria (associated with extended soft lens wear) and *Acanthamoeba* (associated with daily wear and water exposure).

Almost a decade ago, this classification scheme dividing corneal infiltrates into three categories was developed:[8]

• *Asymptomatic events*, which are relatively benign and clinically non-significant events, such as asymptomatic infiltrative keratitis (lesions are around 0.4mm) and asymptomatic infiltrates (lesions are around 0.2 mm).

• *Symptomatic events*, such as lesions that are likely to be non infectious but are still clinically significant and deserving of management. Contact lens-induced peripheral ulcers (CLPU) (a misnomer as these are not really ulcerated) are round corneal stromal infiltrates that are up to 2mm in size with overlying epithelial disruption and associated conjunctival injection. They can cause patient discomfort (foreign body irritation and pain) and tearing. Also in this category is contact lens-related acute red eye (CLARE), which is an acutely inflamed eye following extended wear. These patients present with corneal infiltrates, conjunctival injection, ocular irritation, pain and photophobia. The last event in this category is infiltrative keratitis (IK) with multiple corneal infiltrates that are not associated with eye closure.

• *Sight-threatening microbial keratitis (MK) and accompanying symptoms*.

More recent research has shown, however, that only 20% of infiltrates could be unambiguously divided into four categories (MK, CLPU, CLARE and infiltrative keratitis).[9] And, as described above, what may appear to an experienced clinician as a sterile CLPU can turn out to be microbial keratitis.[7]

Treatment Options

Regardless of initial classification, all contact lens associated corneal infiltrates, including asymptomatic ones, should be considered infectious until proven otherwise. Treatment should begin with discontinuing lens wear in both eyes—to decrease the risk of infection spreading to the uninvolved fellow eye—and aggressive use of topical antibiotics with close professional care until the clinician is sure of the etiology.[10,11]

A collateral issue is the debate about the concomitant use of topical steroids in the initial treatment of corneal infiltrates. Early use of steroids in noninfectious disease is helpful in quickly alleviating patient discomfort and improving vision. This approach may, in theory, limit scarring by blunting overactive host defense mechanisms in cases of corneal infection. But, use of steroids and patching while active infection is present may suppress the necessary host defense and lead to longer and more destructive corneal disease.[7,12] Current literature urges conservative use of steroids in the face of corneal infiltrates.

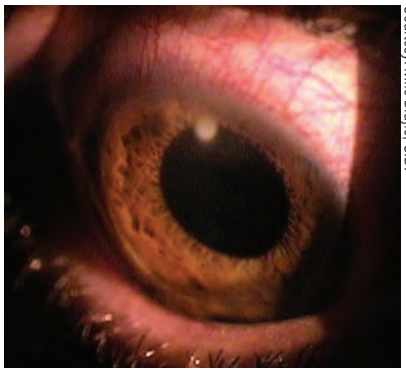

Courtesy: Mile Brujic, O.D.

This is an example of a probable "sterile" corneal infiltrate (CLPU) with surrounding injection near the superior limbus.

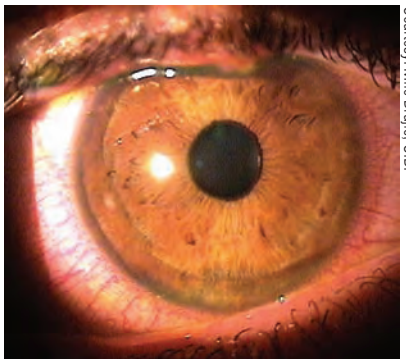

Courtesy: Mile Brujic, O.D.

A picture of a Contact Lens Acute Red Eye (CLARE) as described as by Sweeney et al (2003).

To return to our initial case above, we recommend conservative treatment. If our patient is only minimally symptomatic with no epithelial compromise, MK is unlikely. In such a case, we think that close supervision in 24 hours may be appropriate. Contact lens wear should be discontinued; patching or bandage lens treatment are likewise contraindicated. We usually prescribe topical antibiotic drops q.i.d.—e.g., a fluoroquinolone or Polytrim (polymyxin/trimethoprim, Allergan)—and culture the patient's contact lenses and solutions if suspicion is in any way heightened. Some clinicians will add or substitute a topical steroid or antibiotic/steroid combination like Zylet (loteprednol/tobramycin, Bausch & Lomb) or Tobradex (tobramycin/dexamethasone, Alcon) after 24 to 48 hours of antibiotic treatment if symptoms/signs are decreasing, and only if they are absolutely certain there is no infection.

On the other hand, more severe signs and symptoms suggest MK. Management starts with additional corneal cultures (e.g., blood and chocolate agars for bacteria, heart and blood infusion for fungi, thioglycolate medium or Eugenic broth for anaerobes) and gram-staining of smears for microscopic evaluation.[10,11]

Gram-negative bacteria—and *Pseudomonas* in particular—should be the initial consideration in extended wear contact lenses. Gram-positive bacteria, *Acanthamoeba* or *Fusarium* should be additionally considered, particularly in lesions associated with poor compliance and daily-wear contact lens patients.[13,14]

The standard of care for bacterial infection treatment involves dual therapy with fortified aminoglycosides (e.g., gentamicin, tobramycin, amikacin) and cephalosporins. Fourth-generation fluoroquinolones (in off-label use, as these agents are only FDA-approved for treatment of conjunctivitis) have been used as monotherapy treatment without cultures, particularly for suspected small and peripheral infections. An initial loading dose is given in-office with one drop every fifteen minutes during the first hour, then one drop every hour while the patient is awake.[15,16] Follow-up care should be frequent—at 24-hour intervals if not less.

Aggressive treatment for central corneal ulcers, before the causative organism has been positively identified, involves dual coverage. Treat the gram-negative bacteria with specially prepared fortified topical aminoglycosides (e.g., gentamicin, tobramycin, amikacin), and handle the gram-positive bacteria with cephalosporins (e.g., cefazolin) or vancomycin. Treatment should then be modified with laboratory culture results and course of healing.[11]

The clinician should always be suspicious of *Acanthamoeba* infections in any contact lens related keratitis, especially in cases with negative culture results and failure to respond to antibiotics.[13] Be attentive to such symptoms as intense ocular pain or a history of exposure to non sterile waters (which would point to *Acanthamoeba*). Such clinical signs as radial perineuritis or an unusual epitheliopathy, which can be mistaken for herpetic epithelial disease, can occur. Tissue biopsy and/or confocal microscopy is often helpful. Current treatment for Acanthameoba varies but can include propamidine 0.1%, miconazole nitrate 1% and neomycin. Aromatic diamidine (propamidine isethionate) along with a cationic antiseptic (polyhexamethylene biguanide or chlorhexidine) are commonly used as first line agents.[17]

Fungal corneal infections, especially *Fusarium*, also sometimes elude the clinician initially. Fungal keratitis has been very rare in cosmetic contact lens wear, except in the recent solution-related *Fusarium* epidemic.[14] Previous reports involved bandage contact lenses or chronic treatment with topical steroids in patients who were suffering from concurrent ocular disease (e.g., neurotrophic epithelial defects, diabetes, trauma). The recent epidemic was associated with one particular solution and inadequate patient hygiene practices, such as "topping off" solutions instead of use of fresh solutions in clean cases. Antifungal ophthalmic treatments are available.

Medical treatment of both *Acanthamoeba* and fungal keratitis is often quite difficult and prone to failure, which ultimately leads to corneal transplantation. Aggressive medical treatment of MK may include subconjunctival injections and/or systemic antibiotic treatment with hospitalization; corneal transplantation may be necessary in indolent cases. Successful treatment includes improved patient comfort, reduced pain and inflammatory signs and closing of epithelial defects. When dealing with a severe, central or refractory inflammatory or infectious ocular disease that isn't healing with proper treatment, a referral to a corneal fellowship trained specialist is prudent.

Safeguard Your Patients

While rare, MK remains a prominent issue in contact lens wear. Of couse, non-infectious corneal infiltrates are more common. It is often difficult to definitively distinguish sterile infiltrates from MK. A thorough history as well as the physical exam are crucial in making a differential diagnosis and devising an appropriate treatment plan. Practitioners must exercise caution and heightened suspicion when caring for contact lens patients who present with corneal infiltrates. RCCL

1. Josephson JE, Caffrey BE. Infiltrative keratitis in hydrogel lens wearers. Int Cont Lens Clin 1979;6:47-70.
2. Mondino BJ, Groden LR. Conjunctival hyperemia and corneal infiltrates with chemically disinfected soft contact lenses. Arch Ophthalmol 1980 Oct;98(10):1767-70.
3. Fuchs E. Lehrbuch der Augenheilkunde. Leipzig and Wien: Franz Deuticke, 1889.
4. Hickson S, Pappas E. Prevalence of idiopathic corneal anomalies in a non-contact lens wearing population. Optom Vis Sci 1997 May;74(5):293-7.
5. Mondino BJ, Kowalski R, Ratajczak HV, et al. Rabbit model of phlyctenulosis and catarrhal infiltrates. Arch Ophthalmol 1981 May;99(5):891-5.
6. Stein RM, Clinch TE, Cohen EJ, et al. Infected vs. sterile corneal infiltrates in contact lens wearers. Am J Ophthalmol 1988 Jun 15;105(6):632-6.
7. Baum J, Dabezies OH. Pathogenesis and treatment of "sterile" mid peripheral corneal infiltrates associated with soft contact lens use. Cornea 2000 Nov;19(6):777-81.
8. Sweeney DF, Jalbert I, Covey M, et al. Clinical characterization of corneal infiltrative events observed with soft contact lens wear. Cornea 2003 Jul;22(5):435-42.
9. Efron N, Morgan PB. Can subtypes of contact lens-associated corneal infiltrative events be clinically differentiated? Cornea 2006 Jun;25(5):540-4.
10. Baum JL, Jones DB. Initial therapy of suspected microbial corneal ulcers. Surv Ophthalmol 1979 Sep-Oct;24(2):97-116.
11. Shlers JP, Shah CP. The Wills Eye Manual, 5th ed. Philadelphia: Lippincott, Williams & Wilkins; 2008:62-69.
12. Clemons CS, Cohen EJ, Arentsen JJ, et al. *Pseudomonas* ulcers following patching of corneal abrasions associated with contact lens wear. CLAO J 1987 May-Jun;13(3):161-4.
13. Joslin CE, Tu EY, Shoff ME, et al. The association of contact lens solution use and *Acanthamoeba* keratitis. Am J Ophthalmol 2007 Aug;144(2):169-180.
14. Ng AS, Lau WW, Yu DK, et al. Clinical features and outcomes of *Fusarium* keratitis associated with contact lens wear. Eye Contact Lens 2008 Mar;34(2):113-6.
15. McLeod SD, Kolahdouz-Isfahani A, Rostamian K, et al. The role of smears, cultures and antibiotic sensitivity testing in the management of suspected infectious keratitis. Ophthalmology 1996 Jan;103(1):23-8.
16. McLeod SD, DeBacker CM, Viana MA. Differential care of corneal ulcers in the community based on apparent severity. Ophthalmology 1996 Mar;103(3):479-84.
17. Crum-Cianflone NF. *Acanthamoeba*: Treatment and Medication. E-medicine. Available at: http://emedicine.medscape.com/article/211214-treatment. (Accessed Dec 2008).