


RCCL

REVIEW OF CORNEA
& CONTACT LENSES

MARCH/APRIL 2024

CORNEAL TOPOGRAPHY: GET TO NEW HEIGHTS




Times Change

Address the dynamic vision needs of today's
presbyopes with **INFUSE® Multifocal**.



FIND OUT HOW



RCCL

REVIEW OF CORNEA
& CONTACT LENSES

MARCH/APRIL 2024

CORNEAL TOPOGRAPHY: GET TO NEW HEIGHTS

See how elevation data reveals the greatest truths about corneo-scleral shape.

PAGE 14

ALSO

Custom vs. Standard Soft Lenses for the Irregular Cornea: How to Choose, PAGE 22

Soft Toric Lenses: Harness This Valuable Practice Opportunity, PAGE 28

GO AHEAD. MAKE MYDAY.[®]

You're at the top of your game, which is why you prescribe lenses with top of the line performance.

ADVANTAGE 01 Unsurpassed Comfort¹

ADVANTAGE 02 Optimized Design

ADVANTAGE 03 Unparalleled Range^{2,3,4}

ADVANTAGE 04 Net Plastic Neutral⁵

ADVANTAGE 05 Simply Satisfied Guarantee[™]



When you prescribe the MyDay[®] family of lenses, you'll make their day.



Christi Locke, OD, MS, FAAO
Thomas Eye Group | Atlanta, GA

1. CVI data on file, 2013, 2015 & 2017. MyDay[®] clinical studies 1-week DW compared to 1-DAY ACUVUE[®] MOIST, DAILIES TOTAL[®] and ACUVUE[®] OASYS 1-Day. 2. CooperVision data on file 2020. Rx coverage database n=120,406 eyes for Rx with <0.75DC; 14 to 70 years. 3. CVI data on file, 2021. Based on number of prescription options available in the USA across all soft 1-day toric lenses as reported by the 4 main manufacturers. 4. CVI data on file, 2021. Based on prescription option combinations (sph and add) available across all daily disposable multifocal soft lenses from CVI, J&J, B+L and Alcon in USA May 2021. 5. MyDay[®] daily disposable orders includes MyDay[®] daily disposable, MyDay[®] daily disposable toric, MyDay[®] daily disposable multifocal product sold and distributed by CooperVision in the US. Net plastic neutrality is established by purchasing credits from Plastic Bank. A credit represents the collection and conversion of one kilogram of plastic that may reach or be destined for waterways. CooperVision purchases credits equal to the weight of plastic in MyDay[®] daily disposable orders in a specified time period. MyDay[®] daily disposable plastic is determined by the weight of plastic in the blister, the lens, and the secondary package, including laminates, adhesives, and auxiliary inputs (e.g. ink). CVI Data on file, 2022. ©2023 CooperVision 14678A 4/23

Study Identifies Tomographic Risk Factors for Corneal Hydrops

Steep keratometry and thin corneas predispose patients to this complication.

As if keratoconus wasn't bad enough, some patients develop the serious complication of acute corneal hydrops, where Descemet's membrane ruptures and allows aqueous inflow into the cornea. Stromal edema and corneal opacification follow. To better understand the risk factors of this rare complication, researchers assessed clinical and tomographic factors that predispose keratoconus patients and found this may include steep keratometry, thin corneas and Down syndrome.

The retrospective study included patients seen at a single institution between 2015 and 2023 with advanced keratoconus (controls) and those that developed acute corneal hydrops. In total, 23 eyes of 19 patients developed acute corneal hydrops during follow-up. The hydrops group and control group had similar incidence of known clinical associations, such as seasonal allergies, eye rubbing, snoring, asthma and eczema. The hydrops group had a higher incidence of Down syndrome.

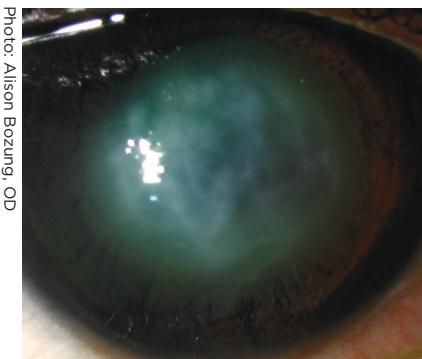


Photo: Allison Bozung, OD

Despite the challenges of obtaining data through edematous corneas, the researchers still recommend routine corneal tomography to assess changes over time in eyes after hydrops.

The researchers also reported that despite similar BCVA on initial exam, the hydrops eyes had steeper keratometry values and thinner corneas than controls at baseline. Right after hydrops development, there was “expected decline in visual acuity in the setting of corneal edema,” they noted. As the corneal edema resolved, these patients had progressive corneal flattening and reduced maximum keratometry over time. The hydrops group showed significant reduction in maximum keratometry at the final follow-up visit.

“While corneal flattening is expected to be associated with improved vision, unfortunately, BCVA remained markedly poor compared with controls on final examination,” the researchers wrote in their *Cornea* paper. The final BCVA was worse than at baseline before hydrops development and worse than control eyes. Ultimately, 12 of 21 hydrops eyes underwent penetrating keratoplasty.

The researchers concluded that steep keratometry and thin corneas predispose keratoconus patients to acute corneal hydrops, but only having Down syndrome was significant. “It’s been difficult to distinguish these [clinical risk] factors from general risk factors of keratoconus progression,” they wrote.

As to why only Down syndrome was found to be significant, they suggested that “this may be because of more aggressive eye rubbing habits with Down syndrome. These individuals have higher likelihood of developing bilateral acute corneal hydrops with chronic recurrent corneal edema.”

Yu SN, Gad R, Kutler R, et al. Scheimpflug-based tomographic risk factors for the development of acute corneal hydrops in keratoconus. *Cornea*. 2024;00:1-4.

IN BRIEF

■ A recent study found that **OTC artificial tears not only replenish aqueous fluid, but they also help break the hyperosmolar status of the ocular surface.** Researchers evaluated five unique preservative-free lubricants (two US and three non-US brands) and their immediate effects on dry eyes. **Each drop showed a decrease in osmolarity 15 minutes after instillation;** recorded post-treatment values ranged from 205mOsm/L to 285mOsm/L. The untreated control group registered a small increase in mean osmolarity of 0.98mOsm/L.

“It is crucial to emphasize that disrupting the hyperosmolar environment on the ocular surface **can break the cycle of inflammation, damage to the microvilli of ocular surface cells, desiccation and apoptosis, preventing the vicious circle that perpetuates dry eye,**” reported the researchers in their paper for the *Cornea* journal.

Muñoz EC, Patiño AO, Marín DJ, et al. Immediate impact on tear osmolarity following the application of different ocular lubricants in patients experiencing moderate dry eye symptoms. Cornea. March 15, 2024. [Epub ahead of print].

■ In 2020, Alcon introduced a **web-based fulfillment platform called Marlo to help contact lens wearers take advantage of convenient online product ordering from their eyecare providers.** The new Marlo iPhone app, which debuted last month at SECO, allows patients to order contact lenses, receive exam reminders, access educational resources, track their next appointment and—if the practitioner agrees to enable it—use a vision screener to test their visual acuity in real-world environments outside the doctor’s office.

The basic tier of the service—online ordering, direct shipping, exam reminders and product discounts—is **free to practices and allows 24/7 online ordering,** while a Pro level adds the customized app interface branding, the vision screener and the inclusion of Alcon OTC product sales, for a charge to the practice of \$25/month or \$250/year.

19 Campus Blvd., S. 101, Newtown Square, PA 19073
Telephone: (610) 492-1000, Fax: (610) 492-1049

Editorial inquiries: (610) 492-1006
Advertising inquiries: (610) 492-1011

EDITORIAL STAFF

EDITOR-IN-CHIEF

Jack Persico jpersico@jobson.com

SENIOR EDITOR

Julie Shannon jshannon@jobson.com

SENIOR ASSOCIATE EDITOR

Mark De Leon mdeleon@jobson.com

ASSOCIATE EDITORS

Leanne Spiegle lspiegle@jobson.com

Rachel Rita rrita@jobson.com

CLINICAL EDITOR

Joseph P. Shovlin, OD jpshovlin@gmail.com

ASSOCIATE CLINICAL EDITOR

Christine W. Sindt, OD christine-sindt@uiowa.edu

ART DIRECTOR

Lynne O'Connor lyoconnor@jobson.com

GRAPHIC DESIGNER

Jaine Kopala jkopala@jobson.com

DIRECTOR PRODUCTION/MANUFACTURING

Rebecca Slebodnik rslebodnik@webmd.net

AD PRODUCTION MANAGER

Karen Lallone klallone@jhihealth.com

BUSINESS STAFF

PUBLISHER

Michael Hoster mhoster@jobson.com

SENIOR MANAGER, STRATEGIC ACCOUNTS

Michele Barrett mbarrett@jobson.com

REGIONAL SALES MANAGER

Jon Dardine jdardine@jobson.com

EXECUTIVE STAFF

CEO, INFORMATION SERVICES GROUP

Bill Scott bscott@jobson.com

VICE PRESIDENT,

CREATIVE SERVICES & PRODUCTION

Monica Tettamanzi mtettamanzi@jhihealth.com

CREATIVE DIRECTOR

Louise Koenig lkoenig@mdedge.com

SENIOR VICE PRESIDENT, HUMAN RESOURCES

Tammy Garcia tgarcia@jhihealth.com

VICE PRESIDENT, CIRCULATION

Jared Sonners jsonners@jhihealth.com

EDITORIAL REVIEW BOARD

- James V. Aquavella, MD
- Edward S. Bennett, OD
- Aaron Bronner, OD
- Brian Chou, OD
- Kenneth Daniels, OD
- S. Barry Eiden, OD
- Desmond Fonn, Dip Optom, MOptom
- Robert M. Grohe, OD
- Susan Gromacki, OD
- Patricia Keech, OD
- Bruce Koffler, MD
- Pete Kollbaum, OD, PhD
- Jeffrey Charles Krohn, OD
- Jerry Legerton, OD
- Kelly Nichols, OD
- Robert Ryan, OD
- Jack Schaeffer, OD
- Charles B. Slonim, MD
- Kirk Smick, OD
- Mary Jo Stiegemeier, OD
- Loretta B. Szcotka, OD
- Michael A. Ward, FCLSA
- Barry M. Weiner, OD
- Barry Weissman, OD

Softer Corneas Associated With Thinner RNFLs

Biomechanical assessments could help diagnose optic neuropathy, study finds.

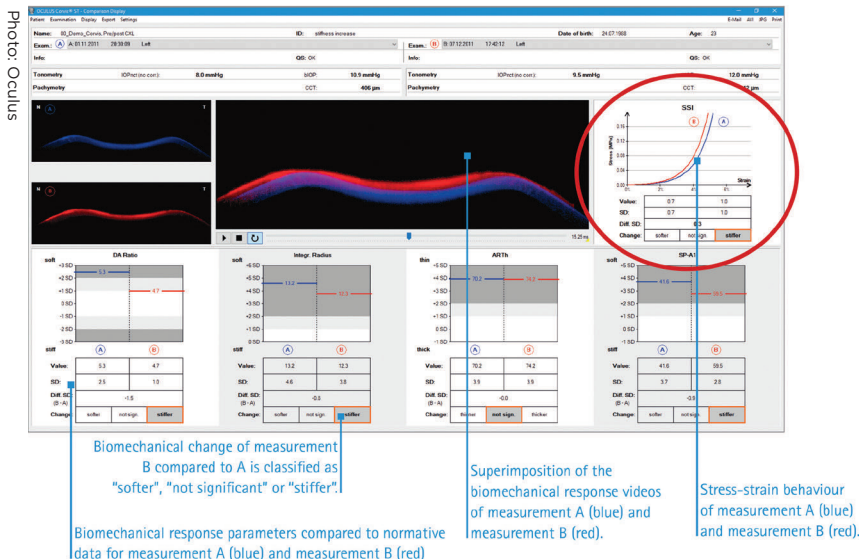
Since various properties of corneal biomechanics have been associated with ocular diseases such as corneal ectasia, its use is widespread in clinical diagnosis and treatments such as pre- and post-op evaluation of refractive surgery. Researchers in China attempted to use the stress-strain index (SSI) provided by the Corvis ST to minimize the impact of IOP. Their findings added novel evidence of the relationship between corneal biomechanics and retinal ganglion cell damage. Eyes with lower SSI had thinner RNFL thickness after covariate adjustment, especially those with higher biomechanical-corrected IOP.

A university-based study contributed to the analysis. In 1,645 healthy students (mean age: 19), RNFL thickness and axial length (AL) were measured, along with corneal biomechanics including SSI, biomechanical-corrected IOP and central corneal thickness (CCT).

Lower SSI was associated with thinner RNFL thickness, after adjusting for age, CCT, biomechanical-corrected IOP and AL. A significant association between SSI and RNFL was found in women in the fully adjusted model, but not in men. The association was significant in the non-high myopic group but not in the highly myopic group. Eyes with greater biomechanical-corrected IOP and lower SSI had significantly thinner RNFL thickness.

“Corneal biomechanical examination, especially stress-strain index measurement, could assist in preventing and clinically diagnosing optic neuropathy,” the study authors wrote in their paper. “Moreover, our study adds novel clues for the pathology of ocular diseases such as glaucoma and other optic neuropathies.”

Liu MX, Yin ZJ, Li YZ, et al. Corneal stress-strain index in relation to retinal nerve fiber layer thickness among healthy young adults. Eye (Lond). February 24, 2024. [Epub ahead of print].



The association between the stress-strain index and RNFL thickness was significant in the non-high myopic group but not in the highly myopic group.



Reconsider GPs for Presbyopia

Contact lens correction for this condition has evolved.

I had the pleasure of participating in a SECO specialty lens panel in Atlanta this year. Always trying to modify or break any short-sighted habits, I took the opportunity to take a fresh look at all the GP options available for presbyopia. I had the pleasure of working with Ashley Wallace-Tucker, OD, and Julie DeKinder, OD, both of whom are highly skilled, exceedingly capable clinicians. They presented useful tips on helping to assure success when using GP materials and lenses in correcting presbyopia.

By now, we all know the many benefits of using a rigid GP material such as wonderful acuity/vision especially when correcting astigmatism, less inflammation most of the time when fitted properly, reduced long-term cost, more durability, easier handling and insertion/removal and, in many situations, a better option for the marginally dry eye. Unfortunately, despite their many advantages they only comprise about 1% of all fits.¹ The reality is GP lenses take longer for patients to adapt to, but with newer lens options (sclerals and hybrids), this may no longer be true. In addition, replacement time and cost are different than with soft lens presbyopic options.

Let's look at the many GP options available today for your presbyopes and younger patients who might benefit from myopia control. I'd like to especially highlight scleral and hybrid options since they are relatively new and provide exceptional comfort for most patients.

CORNEAL GPs

Three basic designs exist: aspherics, concentrics and translating. Each

category has its advantages and disadvantages. For example, aspherics must center well for simultaneous vision and essentially work best for patients who need lower add powers. Translating lenses must hydroplane effectively, and patients must have the right anatomical features to support this requirement. These lenses can be problematic for heavy computer usage.

Nevertheless, all of these options, especially the concentric designs, are mostly pupil dependent but offer excellent lens options for a wide range of presbyopic patients.

SCLERALS

Although these lenses require different solutions with unusual insertion requirements and more chair time, scleral lens options for presbyopia provide incredible vision and comfort. Many manufacturers now offer both concentric and aspheric scleral lens designs. Recent concentric lens options now allow for decentered optics to provide excellent vision.

Think about scleral lenses when patients are dry. Always remember to check for flexure or residual astigmatism when reasonable acuities are not obtained and keep in mind oxygen demands for each cornea are different.

HYBRID LENSES

The obvious advantages of the hybrid group include excellent vision with its GP material and soft lens comfort provided by the skirt, with its covalent bonding for added strength. Again, these lenses are a great option for myopia control—although not a labeled indication—using a high add power and the option of slightly over-minusing at distance. The SynergEyes lenses

are available in a concentric (Duette hybrid) and EDOF (iD hybrid) design. Both designs include UV protection and are available with a Tangible Hydra-PEG coating. Empirical fitting allows for an amazing first fit percentage (84%) by just providing the manifest refraction with add power, horizontal visible iris diameter and keratometry. A wide range for refractive powers, zone sizes on concentric designs (Duette hybrid) and add powers are available.

TAKEAWAYS

The best candidates for the options discussed here are motivated individuals, previous GP lens wearers, monovision failures and those who desire more clarity at distance and near. Key points in prescribing any of these lenses are to avoid abrupt or early changes and always test in the “real world” setting with binocular vision. Remember to set expectations after a careful assessment of the patients' needs, both inside the workspace and outside of work with hobbies or sports. Time spent on the computer is always important to consider as well.

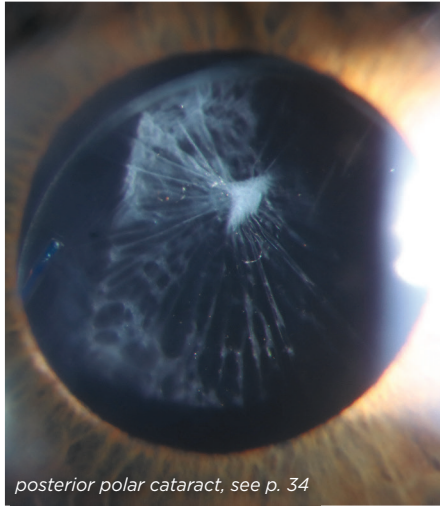
Consider taking another look at the GP lens options for your presbyopes. They have many wonderful advantages and, now that most are fitted empirically, there is less chair time involved and they are much easier to fit than in the past. I'm excited to try more of the scleral and hybrid lens options. You'll likely be impressed with patient loyalty as well. **BCCL**

1. SECO Contact Lens Summit PART I: GPs, Sclerals and Hybrids for Presbyopia. February 28, 2024. SECO 2024.

contents

Review of Cornea & Contact Lenses | March/April 2024

features



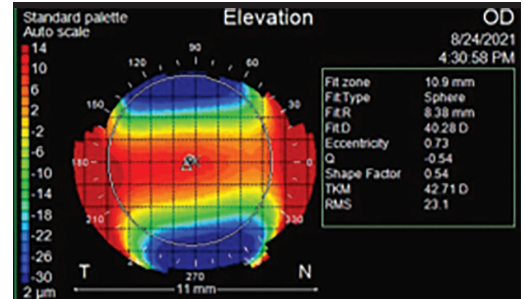
posterior polar cataract, see p. 34

14

Corneal Topography: Get to New Heights

See how elevation data reveals the greatest truths about corneo-scleral shape.

By Aaron Wolf, OD



departments

3 News Review

Study Identifies Tomographic Risk Factors for Corneal Hydrops

Softer Corneas Associated with Thinner RNFLs

5 My Perspective

Reconsider GPs for Presbyopia

By Joseph P. Shovlin, OD

8 The GP Expert

Seeing Clearly

By Lindsay A. Sicks, OD

10 Fitting Challenges

Double-edged Sword

By Marcus R. Noyes, OD, Becky Su, OD, Travis M. Pfeifer, OD, and John D. Gelles, OD

32 Corneal Consult

Don't Chicken Out with These Pox

By Suzanne Sherman, OD

34 The Big Picture

Polar Opposites

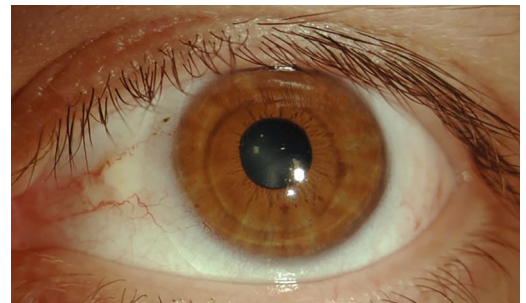
By Christine W. Sindt, OD

22

Custom vs. Standard Soft Lenses for the Irregular Cornea: How to Choose

Learn which approach works best in this case-based article.

By Tiffany Andrzejewski, OD, and Lindsay Sicks, OD

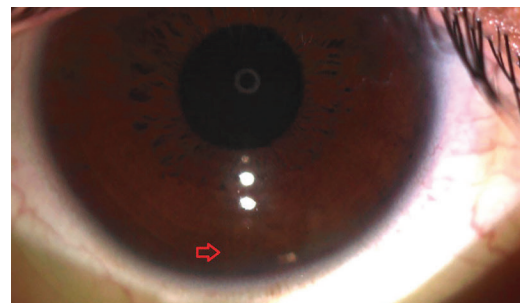


28

Soft Toric Lenses: Harness This Valuable Practice Opportunity

Experts demystify common misconceptions and offer fitting pearls.

By Catlin Nalley, Contributing Editor



Looking for ways to recapture lost revenue?



Estimated
826 million

suffer from vision impairment caused by unaddressed presbyopia*

Recapture the feeling of youthful vision.

The number of people with presbyopia is projected to increase to 2.1 billion by year 2030*. With presbyopes living longer and engaging in more active lifestyles, contact lenses are an excellent choice, recreating youthful vision without the use of glasses.

X-Cel's portfolio of presbyopia contact lenses give patients the freedom, flexibility, and confidence they deserve.

From sclerals to corneal GP's and custom soft contact lenses, we have your presbyope patients covered.

Scan to learn more



Available in Paragon materials

© 2021 X-Cel Specialty Contacts. *Data on file.



800.241.9213 | xcelspecialtycontacts.com

Seeing Clearly

Set yourself up for success the next time you interact with a GP lens consultant.

Fitting patients with GP lenses is a fairly routine task these days that may require speaking with a lens consultant. When seeking consultation regarding any type of GP lens, it may help to keep the following information at the ready:

1. Your lab account number. Yes, they can look it up, but it's often faster if you have it handy. Watch out for Ls that look like Is and Os that look like Os! Consider making a list so they're all in one spot.

2. The name of the patient you're fitting, but also their birthday. There are probably a lot of John Smiths in the lab's database. Maybe only one John Smith, but maybe that was a typo. The date of birth helps sort out any administrative slip-ups.

3. If making an exchange, have the previous invoice number. See No. 1. Yes, they can look it up for you, but saving time in the long-term is the strategy here. The faster you get off the phone, the faster you can see the next patient (or go home). If you can't locate the original invoice, you can often request a copy via customer service or the lab's website login.

4. The type of cornea you are fitting. Is it normal, keratoconic (and what shape of cone?), pellucid, post-trauma, etc.? Bonus points if you have a topography map. Double bonus points if you have a tomography map for some cases. Super double bonus points if you have profilometry, not to say that you need that instrumentation all the time; keratometry values (auto or even manual, if yours is still kickin' it) will often suffice to start.

a. Also, garbage in = garbage out. Make sure your maps are quality. Use

artificial tears and take several maps, choosing the best, most reliable ones.

b. Consider this your public service announcement on when to fit a scleral vs. a corneal GP lens. On your elevation map, if the height differential along any given meridian exceeds 350µm, the patient may be a better candidate for a scleral lens design.¹ Should you neglect to assess this and place a GP lens on a cornea with an elevation difference >350µm, you will quickly find the lens teeter-tottering on the cornea. The fit will likely be poor, the patient will be unhappy and you will be frustrated.

5. While you're at the slit lamp, take a look at the corneal size and measure the horizontal visible iris diameter.

Yes, your topographer can do this, but it may not be accurate. This information can help you troubleshoot any number of lenses! For corneal GPs, it can help you determine starting overall diameter and optic zone size.

6. Refractive information. It's important to have the following on-hand:

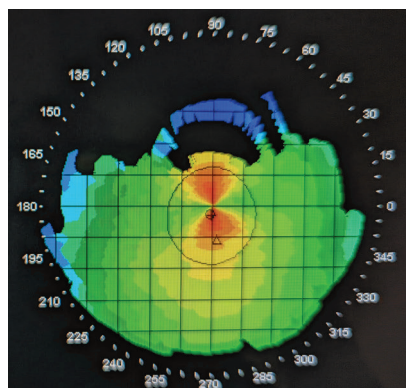


Fig. 1. An unreliable topography map. The superior portion of the topography shows missing data. Despite repeated attempts, no improvement could be made and this topography was successfully used to rehabilitate a poor-fitting lens; however, I would not recommend relying on such subpar maps.

refraction, the add (if presbyopic) and the overrefraction (push plus!) if you have a lens on-eye. Otherwise, you are likely to have a disappointed patient.

a. If you find an overrefraction, think critically. Do you want to incorporate it? Did it truly improve the patient's vision or visual efficiency?

b. If you have a sphero-cylindrical overrefraction, is it large enough (typically >0.75D cyl) to make changes to the lens, and does it also improve VA? Is the lens flexing?

c. If fitting a multifocal lens, remember to do your overrefraction in free space, with loose lenses, assessing one eye at a time. Anything you put over the patient's eye at distance will ultimately affect their near vision.

7. If you're fitting diagnostically, what parameters did you use to fit? Which lenses from the fitting set? By the way, did you verify those lenses? And maybe you should just verify the entire fitting set while you're at it... it's hard for a consultant to help you if your diagnostic lenses are mixed up (those laser-engraved lenses are a life-saver!) and "nothing makes sense." Record the lens base curve (and/or sagittal height), power, diameter and other customizations. Some laboratories have fitting assessment forms you can download from the website for this purpose (especially helpful with toric haptic/quad specific scleral lenses).

8. What did the sodium fluorescein pattern look like on-eye? Did you examine it with a Wratten filter? Bonus points if you have photos. Double bonus points if you have a video to share. A quick description of the fit would include if it is interpalpebral or lid-attached; whether the lens is centered (and, if decentered, which direction and how much; that is, where

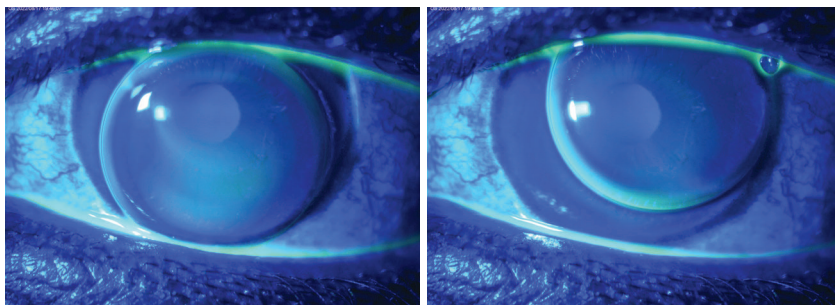


Fig. 2. Assessing this aphakic GP lens was more challenging because the dynamic fit meant it was lid-attached on one blink and interpalpebral on the next blink.

is the lens relative to the center of the cornea?); the amount of movement on blink; movement on lateral gaze; and the fluorescein pattern assessment.

a. Regarding movement, it helps to know whether the movement is consistent (does the lens go back to the same place after the blink?). Recall that lenses always rock or move along the steepest meridian of the cornea. Don't know where that is? Check your topography map.

b. Photos can be helpful here, but also can be misleading. Remember a photo is a snapshot in time. A fluorescein pattern assessment is often dynamic in nature.

9. If fitting a scleral lens, it's good to know the parameters of the lens you're looking at. This includes whether it has a toric landing, front surface toric, oblate profile, multifocal optics, edge vault, etc.

10. When describing the edge appearance to the consultant, use clock hours to describe the edge appearance, noting any blanching/impingement or edge lift off. When analyzing that pattern, does it appear asymmetric (and maybe therefore toric)? That is, does it appear to be lifting off in one meridian and too steep in the opposite meridian? If so, the candidate may need some toricity in the edge of the

corneal lens or in the landing zone of the scleral lens.

11. When assessing scleral lenses, there are a couple basic things to consider being more detailed about: location and time.

a. With location, it's best to estimate the central tear reservoir thickness centrally but also look in the mid-peripheral part of the central zone (where there may be less clearance if the cornea is oblate or more clearance if the cornea is prolate), as well as in the transition (read: limbal) zone. Is there a little sliver of sodium fluorescein over the limbus as you transition your slit lamp beam to the sclera? It can be helpful here to note the apex

of the cornea or highest point of elevation (and it's not always central). This would be a key location to assess the tear reservoir under the lens.

b. It helps to assess sclerals over time—at the time of application, 30 minutes later and after four or more hours of wear are some time points to consider. At the time of application, the central tear reservoir will tend to be

larger than it is after lens settling has occurred. It is helpful to note the time of lens application in your medical record and you can compare that to the time any assessments (slit lamp or anterior segment OCT) of the central tear reservoir are made.

12. Are there any markings on the lens? If so, what and where? Are they stable? This is where it can be super helpful to have a photo of the lens in case you forget. If you are fitting front toric GP lenses, provide the direction of rotation to the lab. Using a standard clockwise or counter-clockwise notation is helpful for cylinder axis orientation.

I don't write all of this to tell you I am a perfect GP lens fitter. In fact, my email exchanges with consultants often bring up these exact requests. My goal is to save you some time so you don't have an endless thread of questions in your inbox. Now, go see your next patient! **RCCL**

Caroline PJ, Andre MP. Initial Selection of Corneal Versus Scleral GP Lenses. *Contact Lens Spectrum*. April 1, 2015. Accessed March 13, 2024. www.clspectrum.com/issues/2015/april/contact-lens-case-reports.

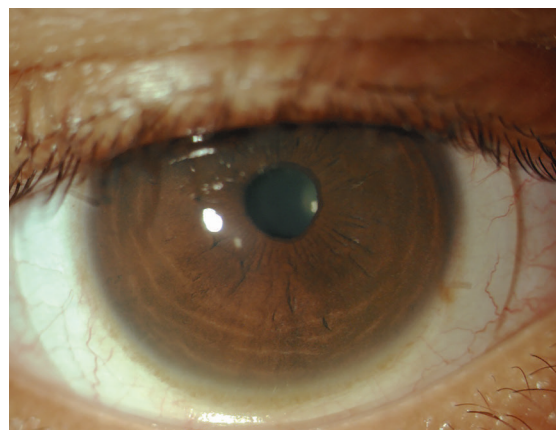


Fig. 3. In this scleral fit, it was helpful to note that the markings were at the 4 and 10 o'clock position.

Double-edged Sword

Scleral lenses for ocular surface disease and complications when care is ignored.

A 30-year-old patient presented to the contact lens (CL) clinic with a history of Stevens-Johnson syndrome (SJS). His chief complaints included chronic pain, blurry vision and dryness of the left eye. His entering best-corrected visual acuity (BCVA) was 20/20 OD and 20/200 OS. Slit lamp findings OD were grossly normal; however, the left eye revealed diffuse peripheral interstitial neovascularization and pannus with diffuse punctate epithelial erosions and a central, round opacity about 0.75mm in diameter. He was then fit into a scleral lens in the left eye only, achieving a BCVA of 20/60 (*Figures 1 and 2*). He successfully underwent proper insertion and removal training along with lens hygiene instructions.

CONSIDERATIONS

Here, we highlight our thought process and consider how we would proceed:

Dr. Noyes: Ocular surface disease patients, such as those with SJS, can be very difficult to manage, especially when there are high levels of inflammation. The eye is a living, breathing tissue and can easily change shape when inflammation is present. This can sometimes go as far as causing the development of symblepharon, nodules, significant corneal thinning and/or scarring. These patients require close observation to maintain the integrity of their ocular surface, and proper lens care instructions are vital to prevent further inflammation and infection.

Dr. Su: One of the most distressing aspects of SJS is its impact on the eyes, causing SJS-associated ocular surface disease. This can lead to significant complications, including severe dry eye, conjunctivitis, corneal erosions and scarring. Scleral lenses can play a crucial role in managing these patients—they offer several benefits by providing a smooth optical surface that masks the irreg-

ularities on the cornea, improving visual outcomes. The reservoir of saline solution under the lens helps to maintain a stable tear film, reduce dryness and protect the surface by allowing healing. Large-diameter soft lenses can also be helpful in providing relief by covering a greater area of the cornea and surrounding sclera.

In addition to CLs, other treatments of lubricating or serum tears, amniotic membranes, anti-inflammatory medications and surgical interventions may be necessary to manage ocular complications and optimize visual outcomes in individuals with SJS. A multidisciplinary approach involving eyecare practitioners and rheumatologists is essential to address the complex visual and ocular health needs of these patients.

Dr. Pfeifer: Working with patients suffering from SJS and examining their eyes can reveal how difficult dealing with the condition can be. Many of these patients are so desperate for relief of their symptoms. They will often need numerous therapies from drops to plugs to amniotic membranes and beyond. In addition to symptoms of dryness and pain, insults to the cornea may result in opacities or irregularities that cause visual distortion or blur. Luckily, one treatment modality aims to combat both of these challenges, that being scleral lenses.

Ideally, patients with SJS will be fit using a “large and loose” philosophy to cover as much of the ocular surface as possible. A looser fitting lens or one with incorporated fenestrations or channels will ensure a greater supply of oxygen to the cornea to reduce the stimulus for

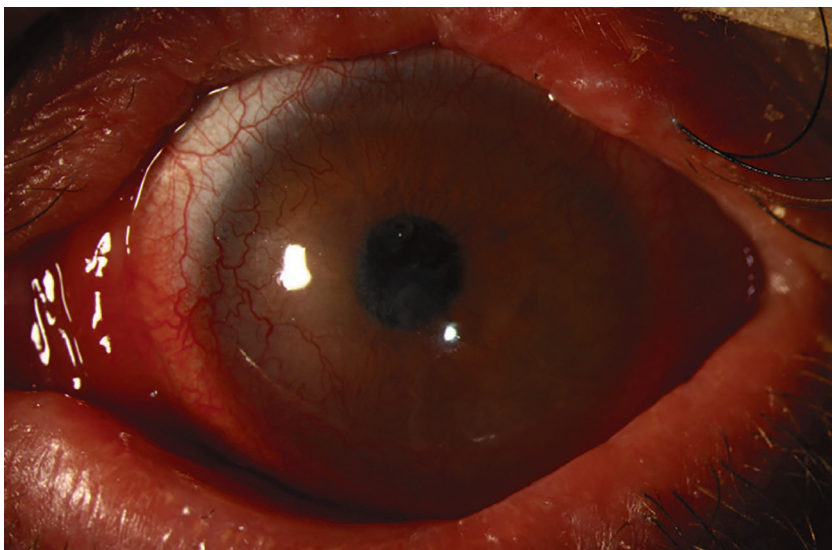

Fig. 1. Slit lamp photo of the patient's left eye with a scleral lens in place.

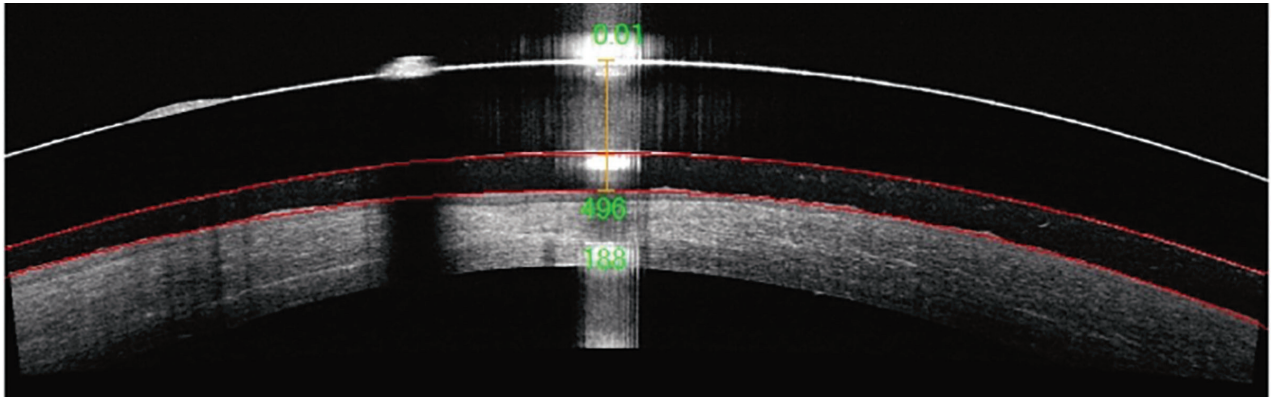


Fig. 2. OCT of the patient's scleral lens fit on the left eye.

greater neovascularization. As many patients feel relief in these lenses, it's important to stress that they should not overwear the lens and should refresh the scleral filling solution multiple times throughout the day to ensure good quality and clarity of the post lens tear film. Cleaning should be emphasized, with importance placed on rubbing the lens to ensure removal of deposits. Patients should also be educated on the importance of monitoring for any change in their symptoms, including redness, tearing, pain and light sensitivity, as well as be advised to seek urgent care if change or worsening occurs.

These patients should be followed closely, and frequent communication with doctors comanaging their condition will give them the best chance at stabilization and improvement.

Dr. Gelles: SJS patients go through a lot, and lifelong issues can be a lot to bear; being able to provide improved comfort and vision can improve their quality of life more than you may imagine. SJS patients are generally in some level of pain, so relieving it and allowing the ocular surface some time to heal is our number one goal—if we can improve

vision too, this will be an especially impactful treatment.

In these cases, scleral lenses are my first choice. The large diameter provides significant protection from the trichiasis, scarred lids and scarred palpebral conjunctiva. The fluid reservoir underneath can provide an opportunity for the cornea to heal and break the pain cycle. Generally, the more tissue covered the better, but some of these patients

will have formed a symblepharon that can limit lens diameter. The big issue to look out for is interaction with symblepharon and resting on the limbus, causing further exacerbation of limbal stem cell deficiency—this is the double-edged sword of scleral lenses. If a scleral lens is just not possible, I would consider either large diameter soft lenses to achieve protection by ocular surface coverage or standard bandage soft lenses.

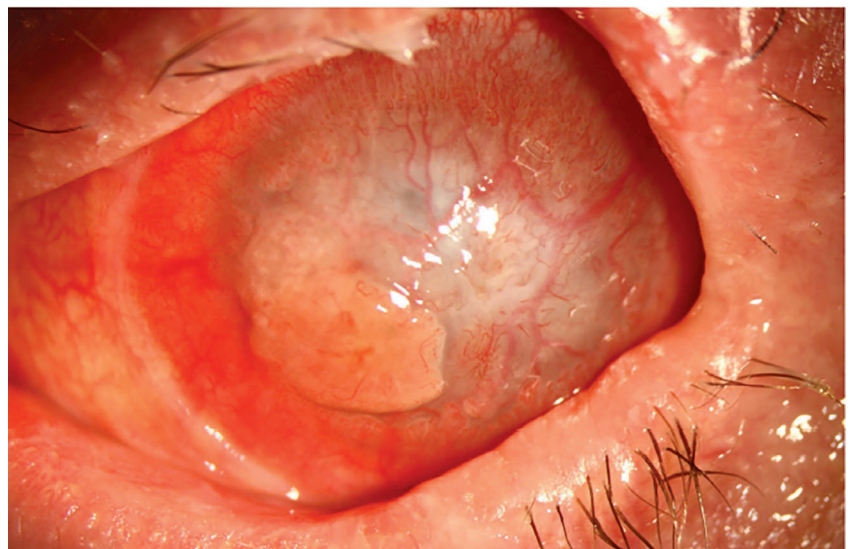


Fig. 3. Slit lamp photo of the patient's left eye six years later, showing conjunctivalized cornea and pyogenic granuloma.

Double-edged Sword

(continued from previous page)

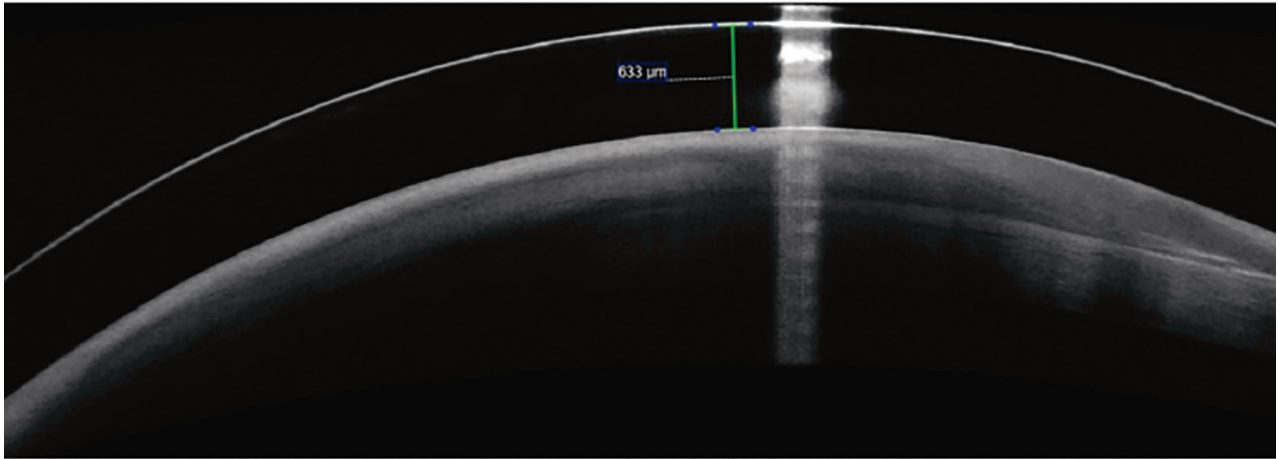


Fig. 4. OCT of a scleral lens over the patient's left eye. The corneal surface has become completely conjunctivalized.

RESULTS

The patient was unfortunately lost to follow-up but returned six years later for another evaluation with the chief complaint of reduced vision. His entering BCVA was light perception and he reported that he had not removed his scleral lens since his previous visit six years prior. His entire cornea had become conjunctivalized, diffusely opaque and he had a large pyogenic granuloma concentrated inferiorly (Figures 3 and 4). At this point, he was referred to our cornea and oculoplastics services for evaluation and treatment, ultimately ending in complete tarsorrhaphy OS. The final outcome remains unknown but may include transplantation or even keratoprosthesis.

DISCUSSION

SJS is an acute, severe and potentially fatal mucocutaneous hypersensitivity reaction causing widespread epidermal detachment and necrosis. This blistering of the skin and mucous membranes is immunologically

mediated and most commonly caused by medications—specifically anticonvulsants, antibiotics, sulfonamides, acetaminophen and nonsteroidal anti-inflammatory drugs.

SJS is characterized by the extent of surface area of the body affected. When less than 10% of the body is involved, the reaction is called SJS; when more than 30% of the body is involved, it is called toxic epidermal necrolysis (TEN), and SJS/TEN is the classification for cases that fall between 10% and 30% of affected area.

Acute management relies on intensive care, but mostly supportive therapies with wound care, pain control and fluid resuscitation. The most critical part of acute management is identifying the cause of the reaction and stopping exposure. Long-term issues associated with SJS are mostly the result of significant scarring of affected areas. Those with ocular sequelae suffer from a variety of issues, from symblepharon, conjunctival and corneal scarring, conjunctivalization of the cornea, trichiasis and even

sequelae of each of those conditions. The result is pain, and any lens that can act as a bandage can be a miracle for the patient.

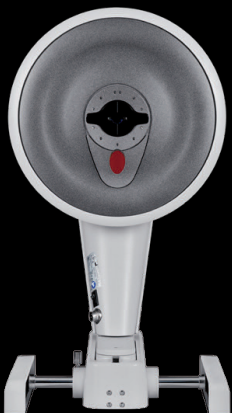However, this relief can lead to **H**overwear and complications—too much of a good thing. Seeing these cases can often be disheartening from a practitioner perspective, as this outcome can be entirely avoided by maintaining proper follow-up on the condition and care of the CLs. All CLs require a proper care regimen, as poor hygiene can lead to a plethora of complications, from giant papillary conjunctivitis, inflammatory infiltrates, microbial keratitis, limbal stem cell deficiency and more. We must remind our patients that contact lenses are medical devices, and in this case a medical device crucial in restoring ocular health and reducing ocular pain, but if not cared for correctly, one which can worsen the situation. In this scenario, the resultant lack of care and follow-up led to a disastrous outcome. **ACCA**

BOOST FIRST-FIT SUCCESS

Corneal
GP

OrthoK

Scleral



Drive ROI with the OCLUS Pentacam®

Increase your first-fit success rate while reducing chair time. Conveniently order custom lenses via direct links to state-of-the-art design software. Discover how the Pentacam® can enhance your specialty lens fitting at pentacam.com.

The OCLUS Commitment:

Focus on Innovation. Finest German Engineering. Unparalleled Support.

Toll free 888-519-5375



ads@oculususa.com oculususa.com pentacam.com



25
YEARS
in the USA

Corneal Topography: *GET TO* NEW HEIGHTS

See how elevation data reveals the greatest truths about corneo-scleral shape.

By Aaron Wolf, OD

There's been increasing evidence in recent years that manufacturers of anterior segment imaging technologies, the contact lens industry and practitioners globally are changing from a mindset based on corneal curvature to one with its foundations in sagittal height elevation data. Is this just a new trend in the ever-evolving landscape of cornea and contact lens practice or a sign of the times that curvature data is becoming obsolete?

The truth lies somewhere in the middle, but it is a notable evolution and one that the eyecare community should be comfortable with and supportive of. How does this affect the way we are practicing and characterize what technology we should have

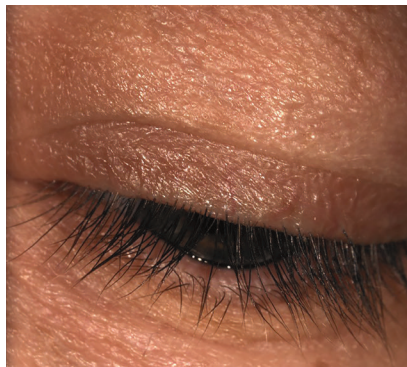

Fig. 1. Munson's sign in keratoconus.

available for our patients? How does this affect the way corneal imaging manufacturers innovate and the larger contact lens industry? All these categories have been changing for years, away from the radius of curvature and dioptric power measurements to topographical shape measurements based on elevation data.

This two-part series will review the tools available to practitioners today to best understand the shape of the cornea and sclera. Part one will take a diagnostics perspective, while part two (in the May/June issue) will discuss how to use these technologies to assist our lens fitting practices.

PURPOSE OF TOPOGRAPHY

The word *topography* comes from the Greek words “topo,” meaning a place or area, and “graphia,” meaning to chart or record. Although corneal topography is a staple in many eyecare clinics, it may be valuable to take a broader look at topography used else-

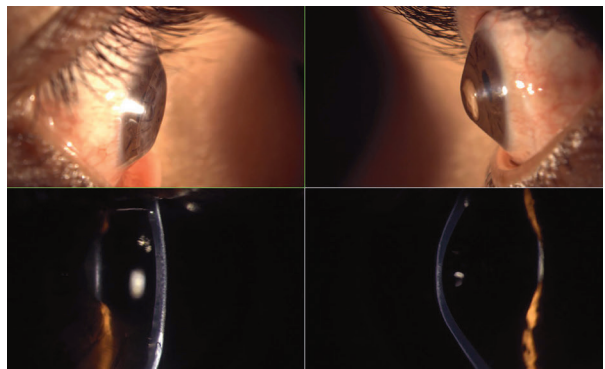


Fig. 2. Severe oblate (left) and prolate (right) corneas with lateral gross observation and optic section biomicroscopy—interestingly, from the same patient.

ABOUT THE AUTHOR



Dr. Wolf, FAAO, FSLs, FIAOMC, received his Doctor of Optometry from the University of Houston in 2009. He is the owner of the private practice Austin Optometry Group in Austin, TX, focusing on ocular surface disease and specialty contact lenses, including scleral lenses and orthokeratology. Dr. Wolf provides topography-guided and tomography-guided corneal, scleral and orthokeratology lenses, ocular impression-based lenses and custom HOA-correcting lenses. He is the first doctor in Texas to earn all the following clinical fellowships: Fellow of the American Academy of Optometry, Fellow of the Scleral Lens Society and Fellow of the International Academy of Orthokeratology and Myopia Control. He has served as a speaker, consultant or provided case reports for Eaglet Eye, Medmont Intl., Oculus Wave, Ovitz, EyeXY and Acculens.

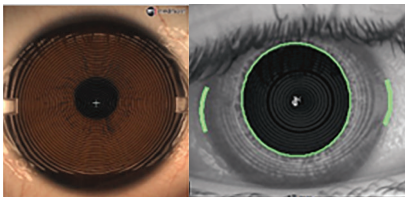


Fig. 3. Small-cone topography (left) with greater number of Placido rings and capture diameter than large-cone topography (right).

where, as the goal is to understand changes in terrain and landscape in an area of interest. Common everyday uses of topography include land surveys, outdoors activities (hiking, mountain climbing), civil engineering and city planning, evaluating flood plains and more.

The overall purpose of corneal topography is to understand the shape of the cornea and, from that, to assess its overall effect on the vision of that

eye. The most obvious and discussed indications for corneal topography are in contact lens fitting and for detecting keratoconus with subsequent monitoring. Other uses include preoperative evaluation of irregular astigmatism or potential ectasia prior to LASIK, implantable collamer lens surgery or lens replacement surgery; it may also be used to determine postsurgical topography after corneal transplants, corneal dystrophies, peripheral corneal degenerations, bullous keratopathy, pterygium or even monocular diplopia.

TECHNOLOGIES TO EVALUATE CORNEAL SHAPE

The most basic method of shape evaluation is simply direct observation of the eye from a perpendicular viewpoint. From a superior viewpoint

while in downgaze, one can assess corneal shape and sagittal height protrusions; this would indicate a positive Munson's sign (Figure 1). Munson's sign is commonly seen in keratoconus and with proud penetrating keratoplasty (PKP) corneal grafts. Additionally, from a lateral viewpoint, prolate shape, oblate shape (Figure 2) and irregular corneal/ocular features may be seen. A similar qualitative measurement of corneal shape can be obtained from the slit lamp biomicroscope with an optic section beam and the oculars offset 45° to 60° (Figure 2) wherein the contour of the corneal front and back surfaces are observed.

Although these are nice and easy techniques to routinely evaluate all corneas, they offer no measurable quantitative data to monitor for change.

KERATOMETRY

Some of our earliest quantitative measurements of corneal curvature came from manual keratometry. This advancement allowed practitioners to measure the radius of curvature and subsequently the dioptric power of the cornea; however, this was limited to a fixed chord of only 2mm or 3mm within the central optic zone of the cornea and only along two principal meridians. Distortion to the keratometry mires attributed to dryness or corneal irregularities were qualitative

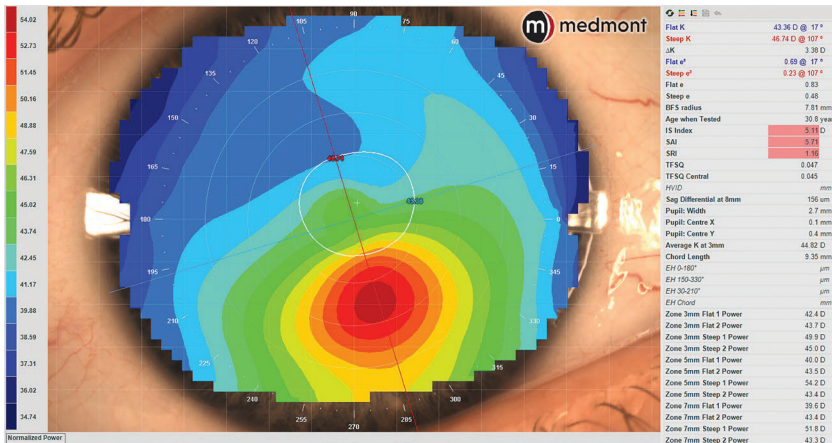


Fig. 4. Axial corneal topography map of keratoconus demonstrating normal Sim K values of the central corneal zone but irregular curvature inferiorly with abnormal symmetry analytics.

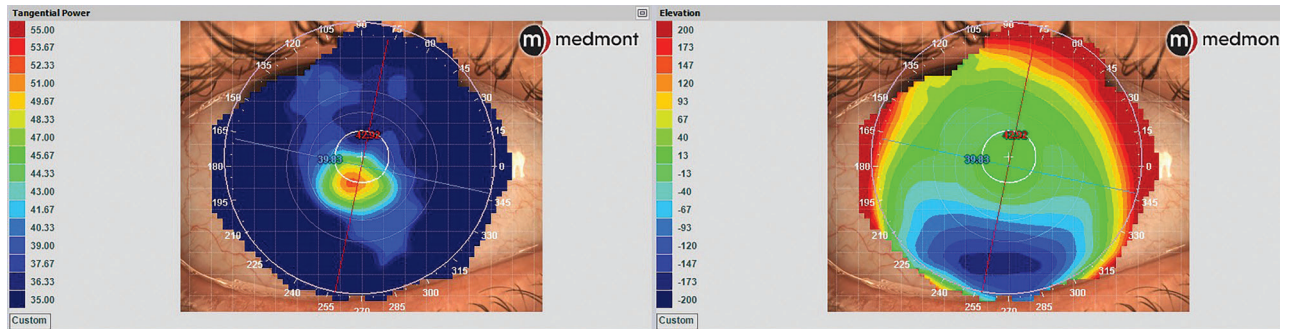


Fig. 5. Placido disc corneal topography of keratoconus showing marked color scale differences and patterns between tangential dioptric power (left) and elevation (right) maps, demonstrating how the same ocular surface will have very different map appearances between curvature and elevation data.

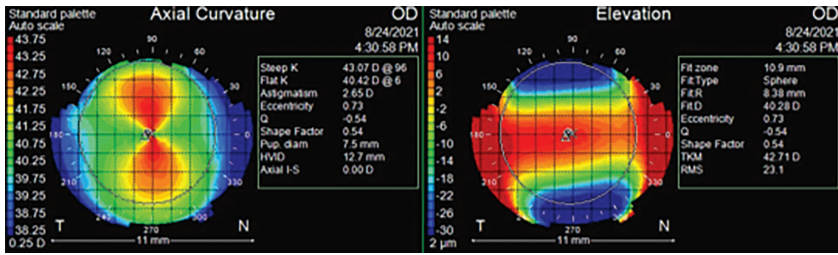


Fig. 6. Corneal topography color scales of axial curvature and elevation maps showing opposite colors per same meridian.

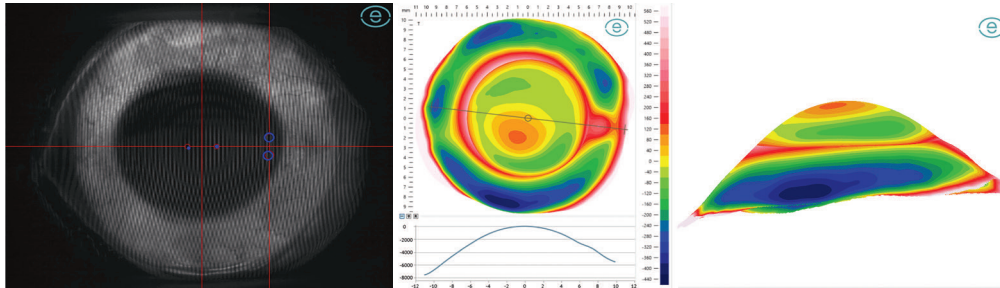


Fig. 7. Fourier projection grid (left), 20mm profilometry elevation map with meridian profile (center) and three-dimensional reconstruction (right) of eye with keratoconus and pinguecula.

instead of quantitative but could be useful clinically, for instance, in evaluating contact lenses *in situ* for lens flexure. Subsequent automated keratometers likewise provide central curvature data limited to a 3mm to 4mm zone and are often more time-efficient and require essentially no technical skill or knowledge, but they lack the qualitative analysis provided by the automated keratometry projected mires.¹ Neither manual nor automated keratometry provide elevation data, nor are they clinically useful in assessing the mid-peripheral to peripheral cornea where many pathologies occur.

PLACIDO DISC TOPOGRAPHY

The most commonly used corneal assessment devices in eyecare practices since the latter part of the 20th century, and with the greatest number of manufacturers and models, are Placido disc corneal topographers. By measuring the distance and variations of concentric rings that are projected onto the cornea (keratoscopy)

compared with a reference calibration sphere, the curvature of the cornea is mapped in a color-coded scale (keratography), with warmer colors representing steeper curvatures and cooler colors representing flatter curvatures.²

Placido disc devices can be separated into two categories: small-cone and large-cone (Figure 3). Small-cone devices may be more accurate and provide more data, as they use more projection rings with far more data points, but they operate at a closer imaging distance, which may be

challenging with prominent brow and orbital bone structures.³

Sophisticated algorithms are used to calculate curvature and power data relative to the optical axis line of reference between the topographer

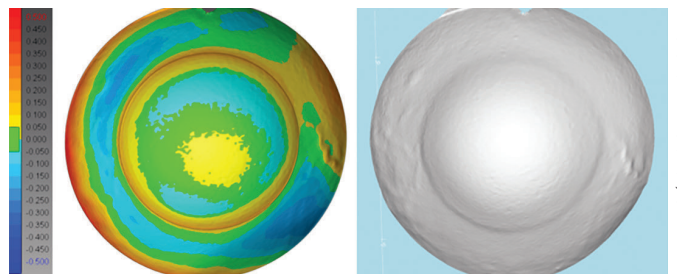


Fig. 8. Ocular impression elevation map and 3D scan of impression of eye with prominent vasculature.

Photo: Christine Sindt, OD

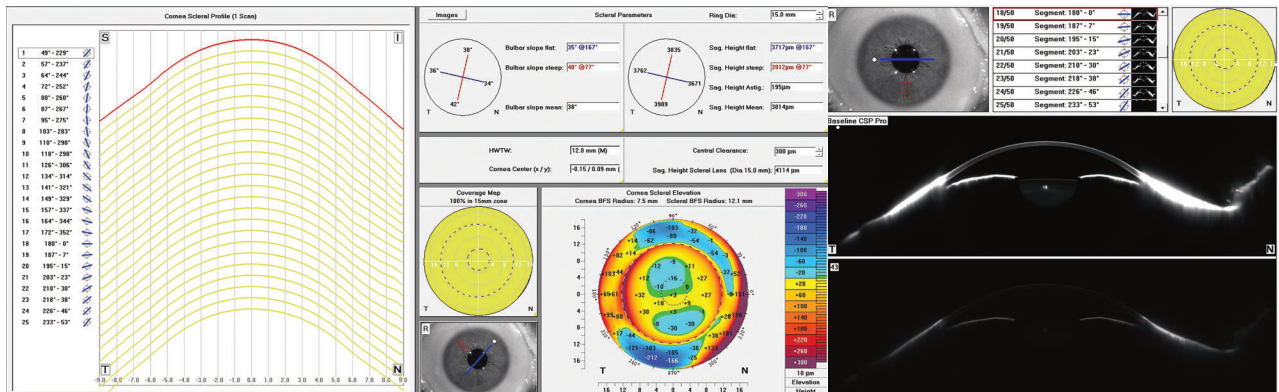


Fig. 9. Scheimpflug tomography with corneo-scleral profilometry elevation map and anterior segment imaging.

	Anterior Cornea	Posterior Cornea/Thickness	Cornea & Sclera	Tear Film Independent	Angle Kappa Independent	Corneal Opacity Independent
Keratometry	✓	✗	✗	✗	✗	✓
Placido Disc Topography	✓	✗	✗	✗	✗	✓
Fourier Projection Profilometry	✓	✗	✓	✗	✓	✓
Scheimpflug	✓	✓	✓	✓	✓	✗
AS-OCT (SD, SS, HP)	✓	✓	✓	✓	✓	✗
Ocular Impression	✓	✗	✓	✓	✓	✓

camera and the cornea (e.g., axial or sagittal maps) or relative to points not centered on the optical axis (e.g., tangential or instantaneous maps). As in keratometry, distortions in the projected rings, referred to as “ring jam,” can be caused by tear film dryness, punctate keratopathy, corneal scarring, sutures or abrupt curvature changes (e.g., PKP graft-host junction). Topography likewise may be used to measure contact lens flexure as well as image multifocal optics or prism of a lens *in situ*.

With many tens of thousands of data points across the cornea, a much more accurate representation of corneal shape can be achieved than with keratometry. While older versions of Placido disc topographers could only measure 6mm to 9mm of the cornea, newer models can capture up to or including the limbus in a single capture or as a multi-image composite.⁴ As seen in *Figure 4*, simulated keratometry (Sim K) values will still be limited to the central 3mm to 4mm zone and will still miss typical inferior ectasias; however, there will be algorithmic symmetry analytics to help identify irregularities as well as a more complete visual representation of the corneal geography.

In Placido disc topography, curvature data can be considered as

the primary language. It is from this curvature data that algorithms will infer elevation change characteristics relative to a best-fit sphere line. As such, it is fair to think of elevation data like a secondary language in Placido disc topography. Due to this secondary elevation inference,

though, Placido disc topography may not be as accurate or sensitive in detection of early pathology as primary elevation measuring technologies (e.g., Scheimpflug tomography, anterior segment OCT and Fourier profilometry); however, it does have its greatest strengths in contact lens fitting. Despite elevation data being calculated from curvature data, the maps may look very different while representing the same corneal shape (*Figure 5*).

Of important note, the color patterns for elevation maps and curvature maps are opposite of each other (*Figure 6*). A flatter curvature meridian, expressed by cooler colors in curvature maps, would be at a greater sagittal height, expressed by warmer colors in elevation maps and vice-versa with the steeper curvature meridian of lower sagittal height. This elevation map color pattern is universal across technologies.¹

Analytic	Description	Normal Value
I-S Index	The difference in dioptric power between the inferior and superior cornea 3mm from the corneal apex	<1.4
Corneal Irregularity Measurement (CIM)	The deviation of surface from the best-fit line	<0.68µm
Keratoconus Prediction Index (KPI)	A multivariate analysis of anterior surface prediction of keratoconus based on several metrics	<20%
KMax/RMin	Regards to the steepest point in an axial curvature map; often used more in monitoring progression of keratoconus or the postoperative effects of collagen crosslinking than as an early diagnostic indicator	
Central K	The curvature at the very center of the cornea on an axial map	<47.2D
Surface Asymmetry Index (SAI)	The radial symmetry of 128 meridians 180° equally distant from the center of the cornea	<1.0
Surface Regularity Index (SRI)	The regularity of power progression of 256 semi-meridians outwards within the central 4mm	<0.57

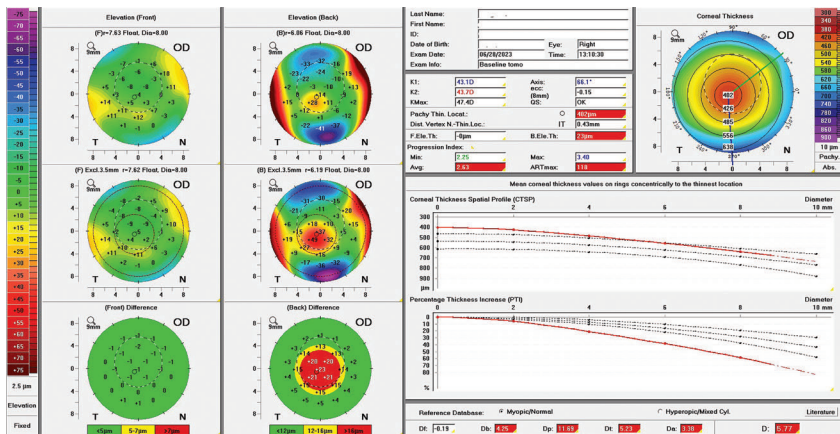


Fig. 10. Scheimpflug tomography elevation-based Belin-Ambrosio ectasia analysis showing mild keratoconus.

PROJECTION CORNEO-SCLERAL PROFILOMETRY

There are other projection-based devices used for ocular surface topography, but the main distinction in these is that, contrary to previously discussed projection devices, they are designed to derive their principal data from sagittal height elevation differences, not curvature. From elevation data, they use algorithms to determine curvature; with these instruments, it is best to think of elevation as their primary language and curvature as secondary. With elevation data, these devices can reconstruct a 3D surface, a technique called profilometry, and since they can obtain data from most of the ocular surface, they are also referred to as corneo-scleral profilometers. There are three main projection-based profilometry technologies: Fourier analysis, triangulation and line scanning.

Fourier projection devices have a central camera with two projectors 45° laterally from the center that project overlapping grids onto the fluorescein coated ocular surface, able to image over 20mm in a single image capture with over 500,000 data points (Figure 7).⁵ Triangulation devices are essentially the opposite—there is a central projector that overlays vertical and horizontal lines onto the fluo-

rescein coated ocular surface and two cameras about 30° laterally displaced that capture three separate images in three positions of gaze, then use triangulation between the two cameras and image stitching to create an ocular surface elevation map.⁶ Lastly, a slit-scanning device uses one camera and one projector that emits a series of rapidly changing—less than 0.25 seconds—various-spaced vertical line projections over 18mm and also uses triangulation between the projector and camera to form a single profilometry map, either with or without fluorescein.⁷

Elevation data is derived by comparing a best-fit sphere through the corneal points and another through the scleral points (a.k.a. bisphere map). Microns of elevation above and below these respective best-fit spheres are recorded as the profilometry map, with standard warm colors for points higher than the reference line and cooler colors for points lower, with data presented as deviation from the reference line or as total sagittal height. Fourier projection software, uniquely, does not interpolate data points whereas other methods do.

Projection profilometry devices offer a dramatically better representation of 3D modeling of the eye than prior projection topographers but notably are limited to the anterior surface only and therefore are likewise not as sensitive in detecting early pathology as devices that image the posterior cornea. Corneo-scleral profilometry is particularly valuable in scleral lens fitting for both simple and complex ocular geographies.

OCULAR IMPRESSION

Arguably the most reliable way of obtaining elevation data is by

Table 3. New Elevation-based and Pachymetric Algorithms ¹⁶⁻¹⁹		
Algorithm	Description	Normal Value
Belin-Ambrosio display	Determines deviation of normality of the front elevation, back elevation, pachymetric progression, corneal thinnest point and relational thickness of the cornea; likely the most notable and referenced metric today in keratoconus analysis	<1.6 standard deviations
Pachy Min	The thinnest pachymetric value	>511um
Front and Back Elevation	Refers to the highest deviation as reported as standard deviations from that front or back surface, respectively, from a best-fit sphere line within the central 8mm	<1.6 standard deviations
Pachymetric Progression Index Average (PPIA)	Measures progression of the thinnest point to the periphery	Up to 1.0 standard deviations

physical ocular impression of the ocular surface with polyvinylsiloxane material and subsequent 3D scanning of the impression (Figure 8). This technology can obtain up to 26mm of corneal and scleral data. Provided steady patient fixation and application technique, it may be superior to projection or scan-based technologies because it eliminates potential artifacts caused by tear film dryness and lash shadowing, and can obtain data otherwise obstructed, such as under the lids. Elevation color maps and 3D reconstruction are possible as well.⁸

This method is less common than projection or scan-based measurements due to practitioner training and skill, materials costs and longer process duration compared to image acquisition technologies. The ocular surface impressions likewise do not obtain posterior corneal data and have their greatest strength in fitting scleral lenses for any ocular geography and for eyes in which data cannot be reliably obtained by optical methods.

CORNEAL TOMOGRAPHY

Tomography is the mapping and reconstruction of an area using slices through said structure. This technology is foundational in our modern evaluation of the posterior segment, but in recent years has also become foundational in our evaluation of the anterior segment from the cornea, sclera, anterior chamber to crystalline lens. Anterior segment OCT (AS-OCT) and Scheimpflug tomography use scanning technology to map elevation points of the corneo-scleral ocular surface as well as posterior corneal elevation, by which corneal thickness maps are derived.

Like profilometry, tomography's primary language is in elevation, with curvature data secondarily calculated, but its ability to scan and map the entire cornea makes these devices more sensitive to early and subtle structural changes of the

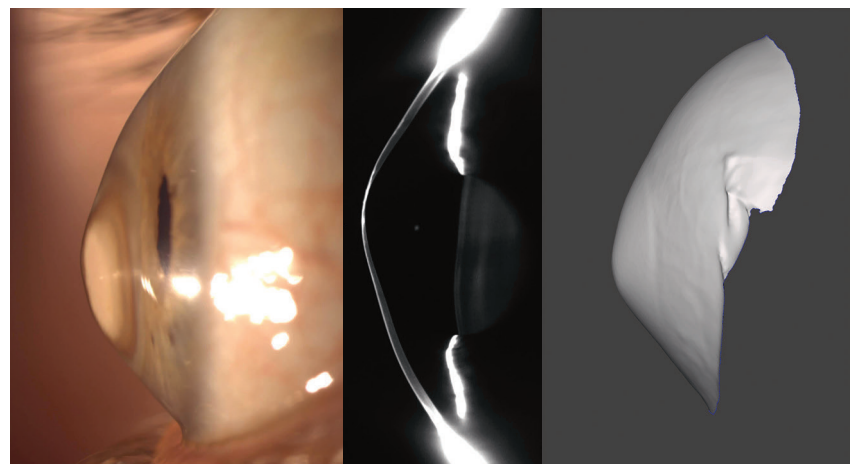
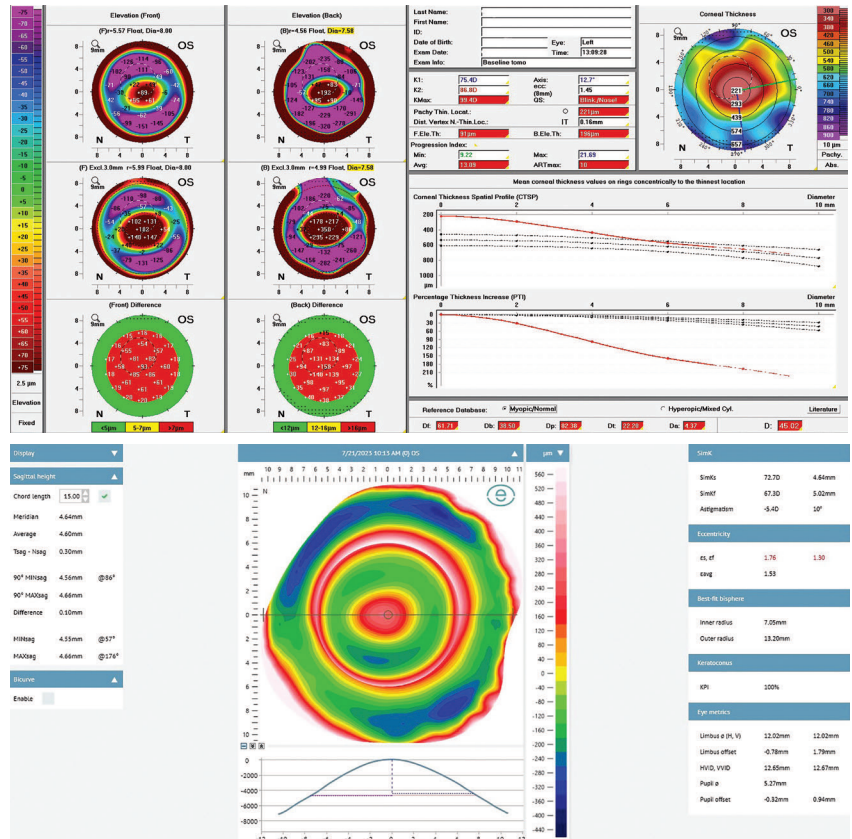


Fig. 11. Severe keratoconus with extreme corneal shape irregularities yet very normal scleral shape with near spherical properties irrespective of corneal properties, as imaged by Fourier projection profilometry, Scheimpflug tomography, lateral observation and impression.

cornea, therefore making it preferred for pathology detection and monitoring.

Scheimpflug tomography combines a rotating camera with a slit beam and a static camera to measure over 25,000 elevation data points of

both front and back corneal surfaces as well as the sclera and anterior segment (Figure 9).⁹ AS-OCT can be categorized by increasingly high-resolution imaging. Spectral-domain OCT uses about 25,000 A-scans/second, swept-source OCT about 50,000

CORNEAL TOPOGRAPHY: GET TO NEW HEIGHTS

A-scans/second and new hyper-parallel OCT over 300,000 A-scans/second to reconstruct the anterior segment.^{10,11} Like the profilometry data, the elevation maps are compared to a best-fit sphere line to create microns of elevation data represented in deviation to reference line or in total sagittal height. With this ability to obtain anterior elevation, thickness and posterior elevation data, more sophisticated and comprehensive algorithmic symmetry and ectasia analytics are possible and a more complete representation of the eye is obtained. *Table 1* outlines specific features of each technology.

CURVATURE PAST, ELEVATION PRESENT

Regarding corneal evaluation, there have been many helpful algorithm analytics based on curvature data within corneal topography systems. Some of the most common include I-S Index, CIM, KPI, KMax/RMin, Central K, SAI and SRI among others, with their descriptions and typical values outlined in *Table 2*.

With the rise of these sagittal height elevation-based technologies, more sensitivity to corneal structural changes and variation from

normative databases can be detected over time. As we know, keratoconus presents first in the posterior cornea, often years before it may be apparent on the anterior cornea.¹⁵

New elevation-based and pachymetric algorithms may soon be the standard in ectasia prediction and detection, including the Belin-Ambrosio display, front elevation and back elevation, pachymetric minimum and pachymetric progression index average outlined in *Table 3*. Belin-Ambrosio ectasia analysis is displayed in *Figure 10*.

ILLUMINATING CASES

The following are a series of examples where what we may assume to be true about the ocular surface based on corneal curvature data proves to be misleading:

Case 1. This is an example of severe keratoconus with a KMax of 99D, a max front elevation deviation of around 100 μ m above best-fit sphere, a minimum pachymetry of 201 μ m and a Belin-Ambrosio display over 45 standard deviations. As demonstrated by gross observation and Scheimpflug tomography imaging, this corneal shape is severely warped (*Figure 11*), so it stands to reason to expect

the sclera to be similarly severely warped.

Although this is a severe case of corneal elevation abnormalities, the sclera has a very minimal 100 μ m of toricity at a 15mm chord. A chord of 15mm is a useful diameter to measure scleral toricity because it coincides within the scleral landing zone of most scleral lenses and is easily and reliably measured by all profilometry devices. At a 15mm chord, studies have found the average scleral angle to range between 35° to 38°.²⁰

Despite this patient's severe keratoconus steepening and elevation, they had a very normal average scleral angle of 38° at the 15mm chord; this demonstrates that elevation shape patterns of the cornea do not necessarily carry over into the shape of the sclera in all cases. This discovery was made possible by elevation-based imaging.

Case 2. Curvature data does not necessarily correlate with sagittal depth (*Figure 12*). Each of the following corneas are similarly shaped with more oblate profiles, having mean Ks ranging from 36D to 44D. However, each one has a markedly different overall ocular shape and elevation profile. Patient A has a mean K of 36D with a mean sagittal height at 15mm of 3,810 μ m. Patient B has a similar mean K of 42D but with a significantly higher mean sagittal height at 15mm of 4,220 μ m. Patient C also has a similar mean K of 44D but with a drastically higher mean sagittal height at 15mm of 5,130 μ m.

All three corneas look quite similar by topographical curvature data standards, yet they have an almost 40% variance in height between them, again demonstrating that assumptions in ocular shape based on curvature topography has little value and only with elevation-based imaging can each eye be assessed individually. In *Figure 12*, notice how precisely the profilometry

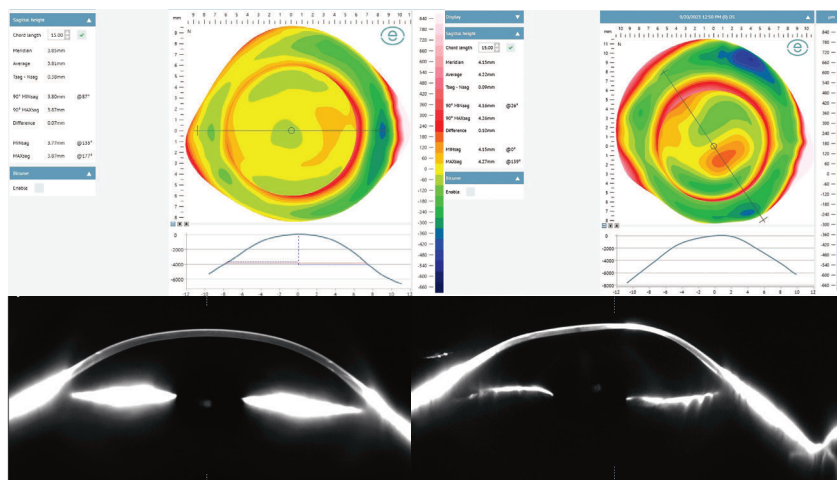


Fig. 12a. Patients A and B demonstrate similar corneal curvatures but with different sagittal heights. Corneo-scleral profilometry map, meridian profile simulation and actual meridian profile as imaged with Fourier projection profilometry and Scheimpflug tomography, respectively.

Topography vs. Tomography: What's in a Name?

Both modalities are used to understand the landscape of the cornea. Topography is the understanding of the curvature or elevation of a surface, while tomography penetrates through the scanned surface area to create an entire structural map. Corneal topography will give added data such as tear film performance and the imaging and measurements needed to evaluate contact lens front surface optics (e.g., multifocal). Corneal tomography will give added data of corneal opacity density, global pachymetry, as well as structural data of the anterior chamber, iris and crystalline lens.

profile beneath each elevation map correlates to the Scheimpflug tomography slice at the same meridian, confirming the accuracy of profilometry in representing ocular shape.

TAKEAWAYS

As Heraclitus observed, “the only constant in life is change,” and that is certainly the case in optometry today. Thinking about the cornea in terms of curvature is of little use to describe ocular shape, contrary to prior assumptions. Elevation-based topographical data is the only true way to

achieve a full picture for managing the refractive and ocular health of our patients to the best of our ability.

For those who have the technology in your clinic to map the cornea with Placido disc topography, I would encourage you to start looking carefully at those elevation maps alongside your usual routine of axial and tangential maps and look carefully at your anterior curvature symmetry metrics.

Those practitioners who have elevation-based instruments may be at an advantage in gaining a more comprehensive picture of the ocular surface anatomy. Particularly for elevation-based tomography technology, this appears to be the standard for which ocular shape, corneal thickness, corneal pathology detection and treatment will be conducted for the foreseeable future.

For those who have not yet adopted these technologies in your practice, I'd encourage you to hop on board or risk getting left behind. **RCLE**

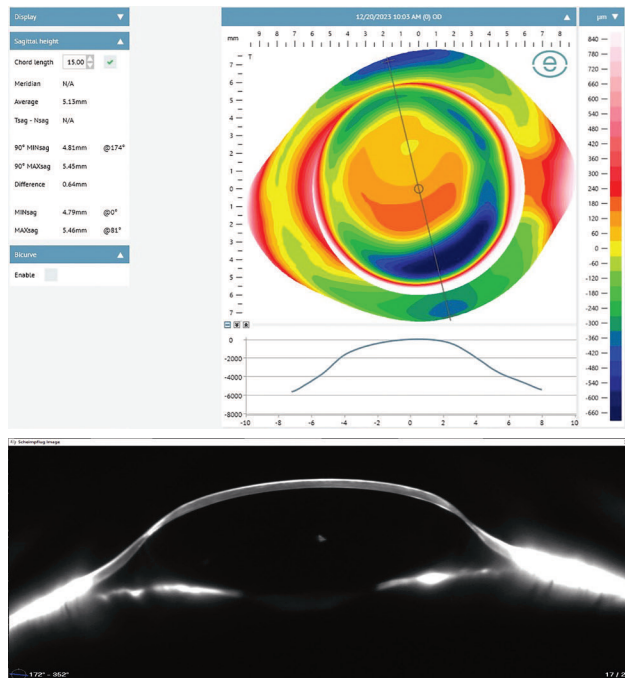


Fig. 12b. Patient C demonstrates similar corneal curvatures to Patients A and B but with a drastically higher mean sagittal height.

- Gurnani B, Kaur K. Keratometer. In: StatPearls. Treasure Island (FL): StatPearls Publishing. June 11, 2023.
- Sridhar U, Tripathy K. Corneal topography. In: StatPearls. Treasure Island (FL): StatPearls Publishing. Updated September 4, 2023.
- Kanclerz P, Khoramnia R, Wang X. Current developments in corneal topography and tomography. *Diagnostics* (Basel). 2021;11(8):1466.
- Fadel D. Medmont Meridia: much more than a corneal topographer. *Clin Optim* (Auckl). 2023;15:283-301.
- Bandlitz S, Esper P, Stein M, Dautzenberg T, Wolffsohn JS. Corneoscleral topography measured with Fourier-based profilometry and Scheimpflug imaging. *Optom Vis Sci*. 2020;97(9):766-74.
- DeNaeyer G, Sanders DR. sMap3D corneo-scleral topographer repeatability in scleral lens patients. *Eye Contact Lens*. 2018;44 Suppl 1:S259-64.
- Zou Y, Niu L, Su B, Sun Y, Liu J. Calibration of 3D imaging system based on multi-line structured-light. *Proc*. 2018;10845(108450C).
- Sciafani L, Slater D, Lay B, Sindt CW. Topographic elevation data to design scleral lenses. *Invest Ophthalmol Vis Sci*. 2017;58(8):3550.
- Ambrósio R Jr, Lopes BT, Faria-Correia F, et al. Integration of Scheimpflug-based corneal tomography and biomechanical assessments for enhancing ectasia detection. *J Refract Surg*. 2017;33(7):434-43.
- Asam JS, Polzer M, Tafreshi A, Hirnschall N, Findl O. Anterior segment OCT. 2019. In: Bille JF, editor. High resolution imaging in microscopy and ophthalmology: new frontiers in biomedical optics. Cham (CH): Springer; 2019. Chapter 13.
- Frisken S, Anderson T, Segref A, Lorensen D, Frisken G. Anterior and posterior imaging with hyperparallel OCT. *Biomed Opt Express*. 2023;14(6):2678-88.
- Rabinowitz YS, Rasheed K. KISA% index: a quantitative videokeratography algorithm embodying minimal topographic criteria for diagnosing keratoconus. *J Cataract Refract Surg*. 1999;25(10):1327-35.
- Cavas-Martínez F, De la Cruz Sánchez E, Nieto Martínez J, Fernández Cañavate FJ, Fernández-Pacheco DG. Corneal topography in keratoconus: state of the art. *Eye Vis (Lond)*. 201;3:5.
- Gomes JAP, Tan D, Rapuano CJ, et al. Group of Panelists for the Global Delphi Panel of Keratoconus and Ectatic Diseases. Global consensus on keratoconus and ectatic diseases. *Cornea*. 2015;34(4):359-69.
- Khachikian SS, Belin MW. Posterior elevation in keratoconus. *Ophthalmology*. 2009;116(4):816, 816.e1; author reply 816-7.
- Doctor K, Vunnavva KP, Shroff R, et al. Simplifying and understanding various topographic indices for keratoconus using Scheimpflug based topographers. *Indian J Ophthalmol*. 2020;68(12):2732-43.
- Belin MW, Duncan JK. Keratoconus: the ABCD grading system. *Klin Monbl Augenheilkd*. 2016;233(6):701-7.
- Ambrósio R Jr, Caiado ALC, Guerra FP, et al. Novel pachymetric parameters based on corneal tomography for diagnosing keratoconus. *J Refract Surg*. 2011;27(10):753-8.
- Villavicencio O, Belin MW, Ambrósio R Jr, Steinmueller A. Corneal pachymetry: new ways to look at an old measurement. *J Cataract Refract Surg*. 2014;40(5):695-701.
- Ritzmann M, Caroline PJ, Bórret R, Korszen E. An analysis of anterior scleral shape and its role in the design and fitting of scleral contact lenses. *Cont Lens Anterior Eye*. 2018;41(2):205-13.

CUSTOM vs. STANDARD SOFT LENSES FOR THE Irregular Cornea: HOW TO CHOOSE

Learn which approach works best in this case-based article.

By Tiffany Andrzejewski, OD, and Lindsay A. Sicks, OD

The standard approach to correcting irregular astigmatism is reaching for a specialty lens design that incorporates gas permeable (GP) optics, whether that be a corneal GP, a piggyback system, a hybrid design or a scleral lens. Each option provides superior optics and visual acuity in cases of corneal irregularity. While these designs might seem like an obvious “go-to” for the practitioner, they may not be the optimal choice for every patient. Perhaps the patient doesn’t like the performance of the lens, they find aspects of the handling/care inconvenient or there are additional barriers at play. Soft contact lenses can be an alternative for select patients, despite the presence of irregular astigmatism. While custom soft lens options exist, often commercially available standard options can suffice, as they come in a wide array of materials and refractive powers.

The key questions that arise are: (1) when should practitioners opt for a soft lens fitting over a different specialty lens with GP optics, and (2) when is a custom soft lens indicated over a standard design?

How do I know when to choose a soft lens for the irregular cornea?

- **Assess the corneal profile.** When examining the eye from the side view, is the cornea prolate or oblate? If it’s not too extreme, a soft lens may work out.

- **Examine the topography.** If there is a mild to moderate level of irregular astigmatism, the chances are better. You also want to focus on the visual axis/pupillary region—if astigmatism is fairly regular in that area, that bodes well for a soft lens design.

- **Consider the refraction.** If the vision through a new refraction is fairly good (20/40 or better), there is a better chance that vision in a soft lens will be adequate. Conversely, if the refractive result yields poor VA, this option is less likely to markedly improve that acuity.

- **Ensure the expectations are realistic.** The patient needs to understand what they will realistically receive in terms of comfort, handling and vision.

THE STANDARD

These lenses cannot mask or hide any corneal irregularity. Their best application is in cases of mild corneal irregularity, where the topography is somewhat symmetrical centrally and patients are satisfied with their acuity after manifest refraction. Standard

soft lenses benefit the patient and practitioner by providing a readily available product that is comfortable and carries a lower cost burden than a specialty lens. Due to the availability of extended-range refractive parameters, this can be a convenient and viable option.

Case #1: A 29-year-old woman with a history of traumatic aphakia and a corneal scar from a laceration that occurred in her right eye at the age of 12 had been unable to tolerate wearing glasses due to high anisometropia and failed in the past with a unilateral corneal GP lens due to discomfort.

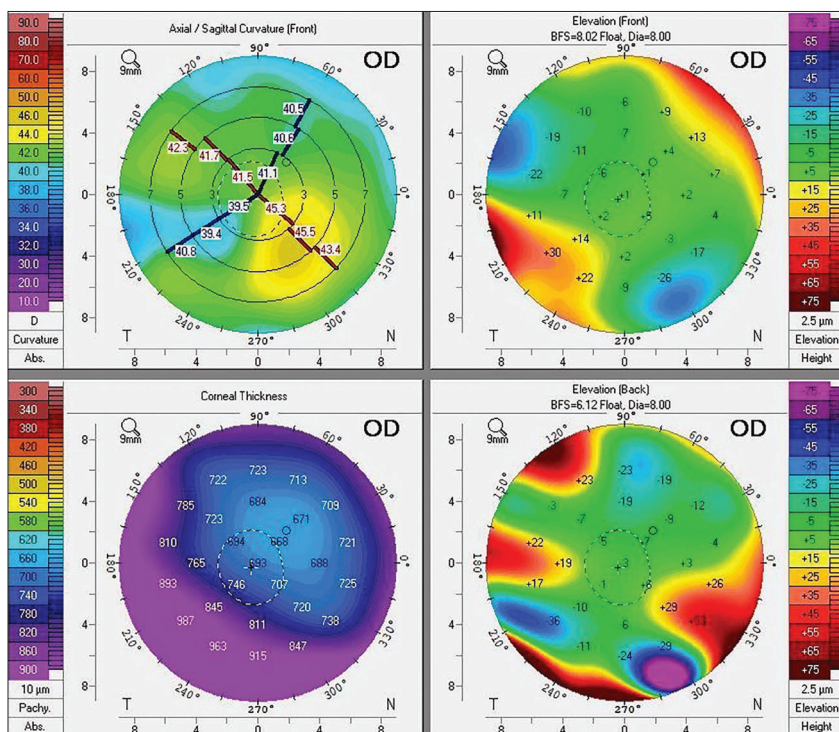
ABOUT THE AUTHORS



Dr. Andrzejewski practices at Chicago Cornea Consultants and serves as an adjunct assistant professor of optometry at the Illinois College of Optometry (ICO) as well as the Chicago College of Optometry. She is a consultant/speaker for Bausch + Lomb Specialty Vision Products, Contamac, CooperVision Specialty EyeCare and Essilor Contacts.



Dr. Sicks is an associate professor at ICO and serves as a clinical attending in the Cornea and Contact Lens Center for Clinical Excellence at the Illinois Eye Institute. She is a consultant/speaker for Alcon Laboratories.



Pentacam of patient in Case #1 with traumatic aphakia.

She desired a simple yet cost-effective option that provides comfortable wear from the outset.

Manifest refraction:

OD: +9.00D -1.50 x 060 VA 20/30

OS Plano VA 20/20

To determine if a standard soft toric lens would be sufficient, the closest power available from a silicone hydrogel toric diagnostic fitting set was placed on the eye: +4.00D -1.75 x 060. The lens decentered slightly inferior-temporally but with full corneal coverage and 0.5mm of movement. The toric marking was rotated 10° to the right but the rotation was stable. The patient was comfortable and pleased with the vision achieved through a +5.50DS over-refraction. A diagnostic lens with the appropriate resultant power: +10.00D -1.75 x 050 was ordered and dispensed yielding 20/25⁻³ final BCVA. The patient was happy that she was able to see clearly and comfortably.

In this case, if the standard soft lens was severely decentered yielding

corneal exposure, or if there had been excessive or unstable lens rotation, then a custom soft lens may be a superior choice. Remember that standard soft lenses are a “one-size-fits-all” approach and may not always work because irregular corneas are just that, *irregular*. Fortunately, this was not such a case.

CUSTOM OPTIONS

Standard soft lenses usually come in one or two base curve (BC) options, one diameter option and a finite range of powers. These lenses are manufactured with a sagittal height range that fits the average ocular sagittal height and horizontal visible iris diameter (HVID) of 11.8mm to 12.0mm, which applies to approximately 77% of eyes.¹ It follows, then, that the remaining 23% (almost a quarter of your patient base) are outliers for standard SCLs based on corneal size alone, absent any additional irregularities.¹

This is where custom options can help, as they can be manufactured

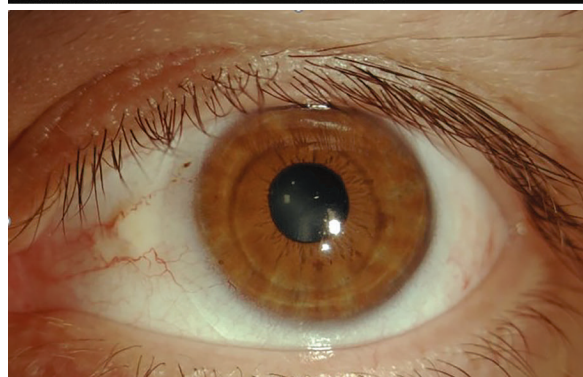
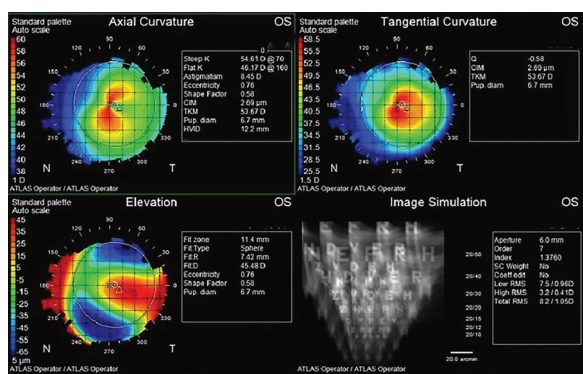
with a wide range of parameters, allowing the practitioner to customize the diameter, BC, optic zone, center thickness (CT) and lens power for each patient. Power options cover almost any conceivable sphere (in 0.12D steps), cylinder (in 0.25D steps) and axis (down to 1° steps) combination independently of one another to maximize both patient and practitioner success.

For the irregular cornea, fitting soft lenses often requires reaching for a specialty soft design that incorporates one of two fitting premises: 1) an aspheric design limits aberrations or 2) an increased CT masks irregular astigmatism. These specialty soft lenses are custom-manufactured but are generally fit using a diagnostic fitting set. In cases where the practitioner has advanced imaging technology and profilometry, they may be fit empirically.² For each specialty soft design, it is recommended to follow the manufacturer’s fitting guide for initial lens selection, evaluation and troubleshooting.

The specialty soft lens modality for the irregular cornea encompasses 15 different designs (Table 1), available in hydrogel or silicone hydrogel materials. A specialty soft lens can offer better initial comfort than a corneal GP, along with good centration and adequate vision if, or when, standard SCLs fail. However, they are not without drawbacks: more time to fit and manufacture, while also carrying a higher annual supply cost. They typically have a less frequent replacement schedule than standard soft lenses, and in some instances, patients experience reduced comfort due to the increased CT of a specialty soft lens design.

The initial specialty soft lens is selected based on sagittal depth, not on BC, as the goal is to match the sagittal depth of the lens to the ocular sagittal height to ensure adequate draping of the soft lens and also enhance on-eye stability and comfort.³

CUSTOM VS. STANDARD SOFT LENSES FOR THE IRREGULAR CORNEA: HOW TO CHOOSE



Case #2's topography map showing skewed radial axes on the axial map, and an oval cone on the tangential map (top). The final FlexLens ARC fit (bottom).

The lens should typically be 3mm larger than the patient's HVID so that it extends 1.0mm to 1.5mm beyond the limbus in both directions to allow for complete corneal coverage and stability. The HVID can be measured manually with a ruler or obtained from a topography map. Since the corneal diameter/HVID is the most important factor affecting sagittal depth, measure this prior to fitting any custom lens.³ This is important to consider because for the same corneal curvature, a larger HVID will carry a higher sagittal depth and vice versa, a smaller HVID will carry a shallower sagittal depth.

In addition to assessing the sagittal depth of the eye, observe the corneal profile and whether it is prolate (as in corneal ectasia) or oblate (as in post-refractive surgery). The corneal profile can be crucial to initial diagnostic lens selection as some specialty soft lenses have separate prolate or oblate

designs. If the corneal apex is within the central 4mm, a standard prolate lens will often give a superior result; however, if the apex is outside the central 4mm, an oblate (reverse geometry) design may be superior. In these reverse geometry specialty soft lenses, the central BC is flatter than the secondary curve, allowing the lens to more closely align to an oblate cornea profile. This advantage is useful in post-transplant, pellucid marginal degeneration or previously myopic refractive surgery patients.

Patients with a higher degree of corneal irregularity also typically have higher amounts of astigmatism that need correction with lenses. To aid in correcting irregular astigmatism, some specialty soft lens designs allow the CT to be customized with a range from 0.30mm to 0.60mm thickness. This provides some level of "pseudo-rigidity" and a smoothing effect of the irregularity, thus improving vision. The downside of this increased thickness is reduced oxygen transmission. With these designs, choose a silicone hydrogel material where available to aid in oxygen transmission. If only a hydrogel material is available, it is crucial to ensure adequate lens movement (sometimes 1.0mm to 2.0mm worth) to facilitate tear exchange and reduce the risk of cornea hypoxia.

The designs are all unique. They're available in double slab-off or prism-ballast for the stabilization of front toric optics, full-diameter or central thick zones, and either variable

BC or dual-curve (BC and separate peripheral curve) designs.⁴

In a dual-curve design, the BC and the peripheral curves can be adjusted independently with the central BC impacting vision while the periphery impacts the fit, centration and movement of the lens. If the BC is too steep, the patient will note that their vision is clearest immediately following a blink and then is worse. If the BC is too flat, the patient will report vision gets worse right after the blink and improves with staring. The vision can also fluctuate significantly due to excessive movement and/or unstable lens rotation. In dual-curve designs, the periphery of the lens can be modified to help eliminate the presence of air bubbles or fluting as well as to achieve the appropriate amount of lens movement to facilitate tear exchange.⁵ In a few designs, the peripheral curve can incorporate a quadrant-specific modification to ensure proper lens centration.⁵

Higher amounts of cylinder correction in soft lenses make patients more sensitive to visual fluctuations and excessive rotation can yield a higher cross-cylinder effect. Therefore, assessing the stability of vision and lens movement/rotation on the blink is imperative for success with both custom soft and specialty soft lens designs. Informing patients about this potential hurdle prior to starting the fitting process can set appropriate expectations for visual success and the number of visits it will take to complete the fitting process. If your patient has a history of GP lens wear, additional discussion of the visual limitations of specialty soft designs may be warranted.

MORE CASES: HOW TO CHOOSE?

As practitioners, we must look at our exam data and the patient's visual demands when deciding which lens modality to fit. We often primarily consider that which we can measure: the patient's incoming acuity, visual

WHY CHOOSE CUSTOM SOFT LENSES?



**HIGH CYL?
HANDLED.**

intelliwave®
PRO

**KERATOCONUS?
COVERED.**

KERA(SOFT)THIN®

**Rx DISCONTINUED?
DUPLICATED.**

intelliwave®

**PRESBYOPIA?
PERFECTED.**

intelliwave®
PRO
multifocal

WHY NOT?

Made to order in virtually unlimited parameter combinations, a full range of design options, and material/replacement schedules chosen by you, custom soft lenses are a great way to manage tough prescriptions and satisfy more patients. Perfect for new fits or as an upgrade to discontinued brands, our soft lens designs feature advanced technologies like aberration control, peripheral balancing zones for rapid stabilization, custom aligned optics, and more. Plus - custom lenses are a great way to build patient loyalty and protect your practice from alternative sales channels. From a standard Rx, to irregular corneas, astigmatic presbyopes, or extreme cylinder and high power needs, we've got you covered.

WHY WAIT?

Custom soft lenses ship in just 48-72 hours, and like all of our specialty designs, are fully supported by expert consultants and backed by our industry-best no-worry warranty program. Call or log-on to learn more about precise prescribing with custom soft lenses today!

Manufactured in

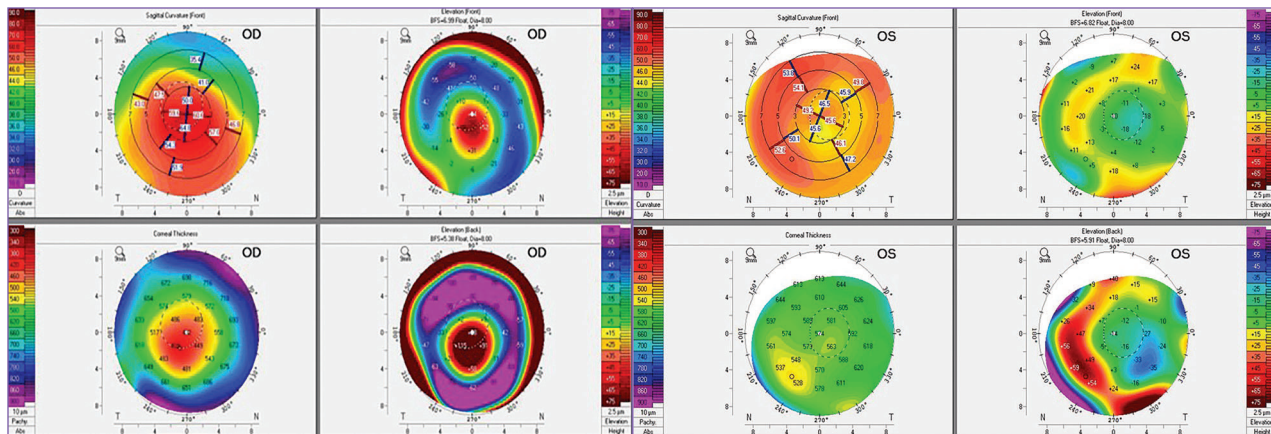
DEFINITIVE

BY **Contamac**®

ARTOptical
contact lens, inc.

ARTOPTICAL.COM | 800.253.9364

CUSTOM VS. STANDARD SOFT LENSES FOR THE IRREGULAR CORNEA: HOW TO CHOOSE



Pentacam maps of patient in Case #3 showing keratoconus OD and a corneal transplant OS.

potential, refractive data, corneal profile, HVID, topography, the severity of irregularity, and ocular health; however, we can't neglect the rest of the patient's story. To provide patient-centered care, ask about the patient's occupation, hobbies, visual symptoms, visual goals, and past CL history, while also considering their level of manual dexterity when making lens recommendations.

Case #2: A 32-year-old man with bilateral keratoconus presented complaining of visual distortion OU in his habitual spectacles. He last wore GP lenses four years prior and discontinued wear due to discomfort. He works as a butcher and enjoys watching professional soccer. At work, he is mostly focused on near and interme-

diolate tasks but wants freedom from spectacles in that environment.

The patient's anterior segment exam was remarkable for signs of keratoconus and allergic conjunctivitis, along with a nasal pinguecula in each eye.

Refraction:

OD: -1.50D -7.00 x 027 VA 20/30

OS: -1.25D -10.50 x 150 VA 20/60

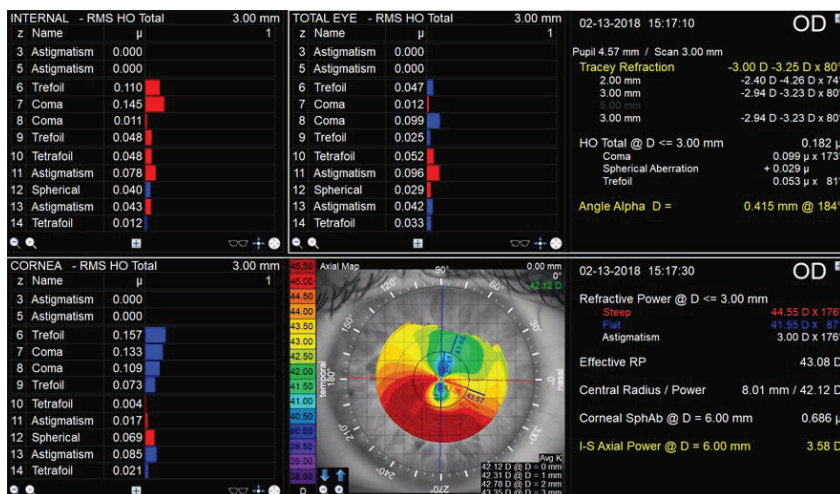
The patient was fit in a specialty soft lens. For the right eye, a FlexLens ARC Toric 6.9/14.5/0.50T was trialed with an over-refraction of plano -5.00 x 025 and a BCVA of 20/25+. For the left eye, a FlexLens ARC Toric 6.6/14.5/0.50T was trialed with an over-refraction of -4.25 -1.50 x 150 and a BCVA of 20/50. Frankly, we expected more cylinder and a better

best-corrected acuity. Since the acuity improvement OS was minimal at only one line better than the spectacle acuity through a diagnostic specialty soft lens, we trialed a scleral lens OS. Through an Atlantis scleral 7.67/15.0/-3.00/std periphery and an over-refraction of +4.00 -0.75 x 060, the patient's vision improved to 20/30-2 OS.

After discussing the options, the patient opted for the soft lens despite better visual potential with the scleral lens OS. At the dispensing visit, the OD specialty soft lens fit well and achieved the expected acuity. The OS lens was well centered with 1.0mm movement and no rotation but only gave VA of 20/70; however, a careful over-refraction yielded +1.25D -3.75 x 160 and a BCVA of 20/40+2. The cross-cylinder result was calculated and ordered giving a final specialty soft contact lens power of -3.00D -5.25 x 157 OS.

At the dispensing visit, the patient's vision improved to 20/30- OS and he was thrilled (our more careful over-refraction here paid off). He denied any issues with lens handling and only had mild dryness while at work, which was relieved with the use of artificial tears.

Case #3: A 48-year-old man with keratoconus and INTACs OD, s/p PKP OS presented wearing no correction OD and a Proclear Toric XR OS. He is a firefighter who works overnight shifts and needs the flexibility to fall



Topography and aberrometry readings from the right eye of the patient in Case #4.

Table 1. Specialty Soft Contact Lens Designs for the Irregular Cornea

ABB Optical Group (www.abboptical.com)	Concise K, Kerasoft IC, Kerasoft Thin
Art Optical (www.artoptical.com)	Kerasoft IC Thin
AVT (www.avtlens.com)	Soft K, SH Soft K II, Naturasoft, Continental Soft
Bausch + Lomb Specialty Vision Products (www.bauschsvp.com)	NovaKone
Gelflex (www.gelflex.com)	Gelflex Reverse Geometry Post-Surgical
Metro Optics (www.metro-optics.com)	RevitalEyes Post-Surgical, Kerasoft IC Thin
United Contact Lens (www.unitedcontactlens.net)	UCL-55 Keratoconus
X-Cel (www.xcelspecialtycontacts.com)	Flexlens ARC, Flexlens TriCurve, Flexlens Piggyback, Flexlens PRS

asleep in his lenses. He was previously fit with a corneal GP OD that he was unable to tolerate. He was refit into a scleral OD but cannot wear it to work because he cannot sleep in it, but he loves the vision and comfort of the scleral when not at work. At work, he's not been wearing any corrective lenses OD and habitually wears a Proclear Toric XR 8.4BC/14.4/-2.25-3.75x075 OS, but that lens had been shifting more than once a day for the last six months. Upon slit lamp evaluation there was significant fluting nasally and unstable rotation of 40° to 60° to the right.

Entering VA with correction:

OD: 20/500; OS CL: 20/50-2

Refraction:

OD: -10.25D -3.00x045 VA 20/80-2

OS: -4.75D -1.75x120 VA 20/30

For a simplistic approach, a standard soft toric diagnostic trial was placed on each eye with the closest power available to the vertex converted prescription; however, both lenses exhibited excessive fluting indicating a custom soft toric contact lens would be needed. Silicone hydrogel custom soft toric lenses were empirically ordered based off of manifest refraction,

HVID and tomography:

OD: 7.10BC/15.0/-9.25-2.25x045 with a CT of 0.2mm VA 20/70-2

Over-refraction: Plano, no rotation

OS: 7.60BC/15.0/-4.50-1.50x030 with a CT of 0.2mm VA 20/30+2

Over-refraction: -0.25-1.00x045, no rotation

Cross-cylinder calculation OS yielded a final resultant power of: -4.75-2.50x036 and VA of 20/20-3

Custom soft lenses proved to be a suitable alternative for the demands of his occupation.

Case #4: A 28-year-old man with keratoconus OS>OD and a history of crosslinking presented wearing scleral lenses OU. He didn't like the right lens, as he feels like his vision is worse in the scleral than in his glasses. The lenses were two years old, and he would like to get them updated, in hopes of improving vision OD.

VA (in scleral) OD: 20/30+2

VA (in scleral) OS: 20/25

Refraction:

OD: -4.25-2.75x080 VA 20/20

OS: -3.00-4.50x080 VA 20/40

The patient's total higher-order aberrations (HOAs) were less than those of the corneal and internal

HOAs, making him a poor candidate for a scleral or specialty soft lens with any rigidity; these designs will cause the residual internal aberrations to become more apparent. This explains what he's been experiencing with his scleral for his right eye. When this eye was refit into an aspheric custom soft contact lens, the BCVA improved to 20/15.

It may be tempting to offer a universal solution by fitting every patient with corneal irregularity into a GP lens; however, clinicians must carefully assess the unique needs of each

patient. Soft lenses really can and do have a place in vision rehabilitation for patients with irregular corneas and can improve their quality of life.⁶ As with any lens modality, it's about choosing the appropriate candidate and counseling them about expectations. Furthermore, keeping up-to-date with diagnostic instrumentation and advancements in contact lens designs and materials is also important in order to continue to provide the best care to these patients. **RCCL**

1. Caroline P, André M. The effect of corneal diameter on soft lens fitting, part 1. Contact Lens Spectrum 2002;17(4):56.

2. Chang C, DeNaeyer GW. Specialty contact lenses: treat your keratoconus patients right. RCCL. 2017;154(2):14-7.

3. Young G. Ocular sagittal height and soft contact lens fit. Cont Lens Anterior Eye. 1992;15(1):45-9.

4. Gelles J. Specialty lenses for irregular cornea and ocular surface disease. Contact Lens Spectrum. 2020;35(2):20-5;49.

5. Andrzejewski T. Managing irregular corneas with soft lenses. RCCL. 2020;157(1):12-6.

6. Yildiz EH, Erdurmus M, Elilob ES, Acar B, et al. Contact lens impact on quality of life in keratoconus patients: rigid gas permeable vs. soft silicone-hydrogel keratoconus lenses. Int J Ophthalmol. 2015;8(5):1074-7.

Soft Toric Lenses: Harness This Valuable Practice Opportunity

Experts demystify common misconceptions and offer fitting pearls.

By Catlin Nalley, Contributing Editor

Staying abreast of the latest technologies and innovations is paramount for the delivery of comprehensive and effective patient care. It is also critical for the ongoing growth and success of optometry. Soft toric contact lenses have emerged as a valuable tool to address the unique needs of individuals with astigmatism (*Figure 1*). As optometrists, harnessing the full potential of these lenses can enhance patient outcomes and satisfaction as well as your own clinical practice.

“Modern toric technologies give us the ability to correct vision in a predictable way that we weren’t able to in the past,” notes Mile Brujic, OD, who practices in Bowling Green, OH. “Today, we have a host of stable lens options that ensure we can deliver the best possible visual outcomes to our patients with astigmatism.

“Optimal patient outcomes are always what’s in the best interest of the practice,” he adds. “Toric lenses are another example of a specialized offering that adds value for both patients and optometrists alike.”

Nonetheless, some ODs remain hesitant to integrate these services into clinical practice. “The NHANES

study determined that in the US, about one-third (36%) of the population have 1.00D or more astigmatism.¹ However, only 21% of all contact lens fits were for soft toric lenses in 2023,” points out Thomas Stokkermans, OD, an associate professor at the Case Western Reserve School of Medicine and director of optometric services at University Hospitals Cleveland Medical Center.² “This gap identifies an unmet need that we have the tools to meet,” he notes. “And this doesn’t include all those patients with less than 1D of astigmatism that may also benefit from the increased clarity that astigmatic contact lenses can provide.”

MISAPPREHENSIONS AND MISCONCEPTIONS

There are a variety of reasons why an optometrist might not be taking full advantage of the benefits of soft toric lenses. Below, optometrists discuss some of the concerns surrounding this modality and why they shouldn’t stop ODs from integrating toric lenses into their practices.

“Misapprehensions regarding soft toric contact lenses include poor lens performance (unstable rotation), discomfort with lens wear and

lack of parameter availability,” says Jennifer Harthan, OD, a professor at the Illinois College of Optometry and chief of the Cornea Center for Clinical Excellence at the Illinois Eye Institute. “Some practitioners elect to fit astigmatic patients with the spherical equivalent power to try to avoid these misapprehensions,” she explains. “However, this can lead to more vision complaints such as blur, glare, halos and ghosting of images, particularly for those with higher levels of astigmatism.”

Another common concern is increased chair time. However, Dr. Stokkermans has not found this to be the case. Research suggests that the average chair time is actually similar.³ In fact, he notes, not offering astigmatic correction can compromise a patient’s vision and may increase chair time while trying to find a lens that meets the patient’s visual expectations.

The cost associated with toric lenses is also a reason for hesitation among ODs. A recent study showed that toric lenses are about 30% more expensive than their spherical counterparts, notes Dr. Stokkermans; however, the same study found that patients were willing to pay up to

50% more for the improved vision and similar comfort of toric lenses.⁴ Although cost is an important consideration, it shouldn't be used as a reason not to explore this option with your patients.

As mentioned above, the comfort of toric lenses has long been a point of contention. While there are different reports on whether toric soft contact lenses cause more discomfort, the general consensus today is that comfort is similar.⁴

“With the availability of so many new materials and designs, the first step, if comfort appears to be an issue, is to change the design, replacement regimen and/or lens material,” says Dr. Stokkermans. “I may check for papillae (Figure 2) if I have a patient with an atopic profile (e.g., history of eczema, asthma or perennial allergies) or someone with a history of contact lens intolerance to avoid inducing GPC.” He advises, “It is always essential to carefully check the eyelids for anterior and posterior blepharitis and check the tear film.” In certain cases, Dr. Stokkermans says he may perform additional dry eye testing.

There may also be apprehension surrounding the fitting of patients who require a higher contact lens power or who have parameters outside commercially available lenses, notes Dr. Harthan. “There are several custom soft toric contact lens designs available that can be customized for these patients,” she points out (Figure 3).

Consultation, she adds, can be a great resource.

UNDERSTANDING THE VALUE

Soft toric lenses offer improved visual acuity, particularly under low light conditions, as well as improvements in ocular comfort and eye health. They can also build confidence in the practitioner and practice, thereby

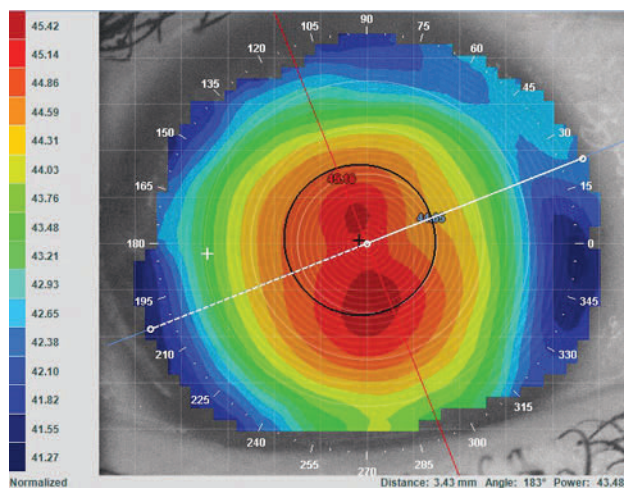


Fig. 1. Soft toric lenses can correct various levels of astigmatism. Patients with central corneal astigmatism are often better candidates than those with limbal astigmatism due to the geometry of the lens.

increasing profitability and patient retention, says Dr. Harthan.

“You will be able to fit more patients in contact lenses if you remove the perceived barrier of astigmatism,” adds Dr. Stokkermans, while noting that this barrier applies both to the patient, who believes they cannot wear contact lenses because they have astigmatism, and to the eyecare provider, who won't offer contact lenses as a refractive option because of astigmatism.

Dr. Stokkermans also warns against the dangers of commoditization. “Whether it's contact lenses or glasses, commoditization of your services and the goods you sell is a potential threat to customer loyalty and repeat business.” He suggests, “An effective counter to commoditizing your products and services is to offer the newest technology, including products that correct for astigmatism, providing patients with clear and comfortable vision without spectacles. Equally important is educating the patient on which valuable services you provide, covering vision, health, convenience and anything else that sets you apart from other providers and vendors of contact lenses.”

Photo: Jennifer S. Harthan, OD, and Michelle K. Man, OD

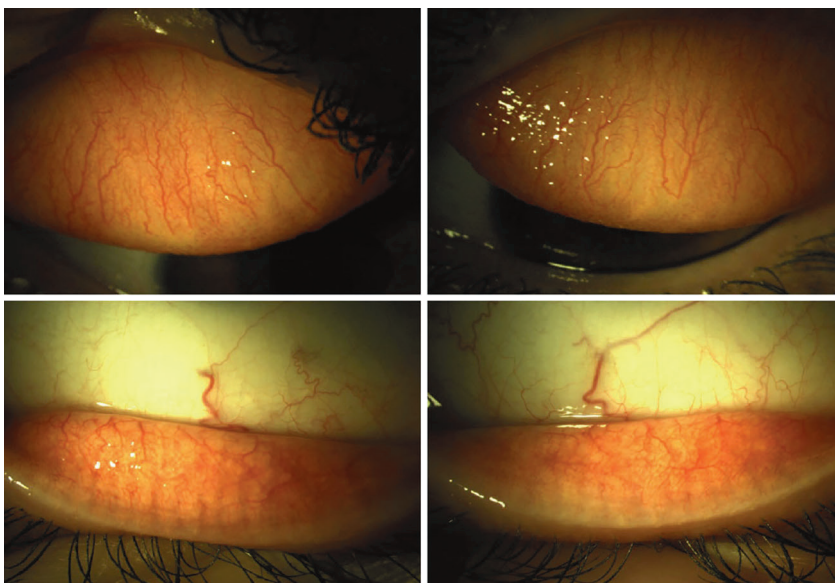


Fig. 2. Everting the upper and lower eyelids can reveal signs of ocular surface issues (such as papillae, shown here) that may either be a result of contact lens wear or have implications for its success.

SOFT TORIC LENSES: HARNESS THIS VALUABLE PRACTICE OPPORTUNITY

Photo: Matthew Lampa, OD




Fig. 3. Irregular astigmatism patients may benefit from custom-fit soft toric contact lenses due to the increased central thickness of the lens.

FITTING TIPS

Whether you are tackling toric lenses for the first time or looking for ways to maximize the benefits of this modality, there are numerous ways to improve your techniques for toric lens correction.

Maximizing the immediate on-eye experience is a key component of soft toric lens success, according to Dr. Stokkermans.⁵ “The office should have a variety of trial lenses in different modalities (daily disposables, frequent replacement, multifocals, etc.) so that patients can try the different lenses while they are at your clinic,” he suggests. “Even for smaller amounts of astigmatism, let the patient judge whether a toric lens improves vision over a spherical one by trying out spherical lenses immediately followed by toric lenses,” he recommends.

While 0.75D is typically considered the minimum amount of astigmatism that can be corrected, Dr. Brujic argues that there is a case to be made for soft toric lenses in patients where 0.50D to 0.75D of astigmatism is present.

“Often, we will opt not to introduce the astigmatism for these patients; however, what I’ll do is demonstrate, in their spherical equivalent, the 0.75D of astigmatism even if I’ve recorded as a final prescription 0.50D,” he says. “I’ll show them 0.75D

in front of their eyes and ask, ‘Would you prefer it with this, which is technically a little bit more astigmatism than you need, or would you prefer it without the astigmatism?’”

Dr. Brujic finds, more times than not, that his patients prefer that astigmatism correction even if it is slightly overcorrected. “The reason why I recommend this is because oftentimes we’ve been taught that if the astigmatism is less than 0.75D, we don’t introduce it into the correction, when in actuality, there are opportunities to maximize vision even if you don’t hit that minimum requirement.”

Additionally, Dr. Stokkermans recommends having at least one trial set with -2.75D cylinder trial lenses available for the higher astigmatic corrections, some of which include Acuvue Oasys for Astigmatism (J&J Vision), Ultra for Astigmatism (Bausch + Lomb) and Biotrue Oneday (Bausch + Lomb). Additionally, he notes, optometrists should have a toric multifocal fitting set in the office. “Do not hesitate to fit higher astigmats in readily available Biofinity and Proclear XR toric and multifocal toric brands (up to 5.75 cylinder at 5° increments around the clock).”

Optometrists need to be cognizant of the effect that uncorrected astigmatism has on the presbyopic patient, according to Dr. Brujic. “There

are wonderful opportunities to correct astigmatism in the multifocal wearer thanks to advancements in toric lenses,” he says. “We now have the ability to correct these patients’ vision. So, we need to be thinking more strategically, even about our presbyopic patients, as well, to give them the best vision possible.”

Another pearl from Dr. Harthan: “Don’t forget the importance of the LARS adjustment/calculation when evaluating a soft toric contact lens,” she says. “The LARS adjustment/calculation will not prevent the lens from rotating or change the location of the orientation markings. The orientation marking on a lens that has been compensated with LARS will be at the same location as the original diagnostic lens.”

The LARS adjustment/calculation allows for modification of the prescription when a lens has been determined to have stable off-axis rotation. However, when the rotation of a soft contact lens is unstable, Dr. Stokkermans urges caution. “You have to be very sure that the off-axis lens rotation is stable,” he explains. “If a lens is rotated, I generally prefer to fit a different brand instead, potentially with a different stabilization mechanism” (Figure 4).

He recommends that optometrists become familiar with the different types of stabilization (*e.g.*, thin zones, stabilization zones or prism ballast, as well as the location of these zones). “Remember, if you have to order a new lens based on LARS, this delays the fitting process, which can be a major inconvenience,” he adds.

While soft toric lenses are suitable for a wide range of patients, others may reap a greater benefit from hybrid lenses (such as that from SynergEyes), corneal gas-permeable (GP) lenses (spherical, toric) and scleral GPs; however, Dr. Stokkermans emphasizes the

importance of first discussing the upfront investment of time and money to gauge if the patient is motivated to try one of these alternate modalities.

“We can’t forget the value and benefit of a rigid surface on a toric patient,” emphasizes Dr. Brujic. “We often use scleral lenses for the irregular or diseased cornea, and we have opportunities for those patients, even with high cylinders, to actually correct their vision.

“We have patients whose cylinder is so high that their best-corrected visual acuity with glasses is about 20/30, and we can get them down to 20/15 when we put a scleral lens on,” he says. “When we think outside of the box, there are opportunities to help deliver better visual outcomes for these individuals.”

PATIENT SELECTION PEARLS

When it comes to selecting the right patients, several considerations must be made. “We have to take a step back and first ask ourselves, ‘Is this

patient a good contact lens candidate?’” says Dr. Brujic, who notes that one of the most important factors for success is patient motivation.

“There is a learning curve (*e.g.*, insertion, removal, cleaning regimens, etc.), and if a patient lacks the motivation to invest the necessary time and effort, toric lenses may not be the right option,” he explains. “As with any intervention, patients need to understand the full picture. Optometrists must ensure patients receive appropriate education before moving forward.”

When determining if your patient may be a candidate for soft toric contact lenses, Dr. Harthan says to look at the patient’s spectacle refraction, horizontal visible iris diameter and corneal topography/tomography. “Also,” she adds, “remember to vertex convert both meridians for any prescription greater than or equal to a $\pm 4.00D$. Many manufacturers have fitting calculators and there are other great online resources available to help with the fitting process.”

To initiate a fit or refit for astigmatic contact lenses—or any contact lenses for that matter—optometrists must also address any underlying condition affecting the ocular surface, such as severe allergies, dry eye, eyelid disease and corneal disease, Dr. Stokkermans notes.

Another pearl he offers ODs when fitting soft torics is to let the lenses settle—for fewer than five minutes—and then ask the patient for feedback on their vision. “If the patient reports fluctuations in vision, constant blur, reduced near vision, glare or flare, we may need to try other lens brands or modalities,” he says.

TAKEAWAYS

By embracing soft toric lenses, optometrists can elevate their practice standards while also empowering their astigmatic patients by offering an option that can significantly improve their quality of life.

“There is a wider range of soft toric contact lens designs, replacement schedules and material options to choose from now compared to ever before to accommodate the needs of patients with astigmatism,” concludes Dr. Harthan. “Manufacturers have made improvements in quality control, quality of vision, oxygen transmissibility and edge designs, so if you think a patient might benefit from a soft toric contact lens design, fit it!” **RCC**

1. Vitale S, Ellwein L, Cotch MF, et al. Prevalence of refractive error in the United States, 1999-2004. *Arch Ophthalmol*. 2008;126(8):1111-9.
2. Nichols JJ, Fisher D. Contact lenses 2023. *Contact Lens Spectrum*. January/February 2024.
3. Smith S, Cameron I, Johnston J, et al. Chair time required for the fitting of various soft contact lens designs. *Cont Lens Anterior Eye*. 2022;45:101615.
4. Morgan OA, Mirza AA, Parmar KR, et al. Clinical performance and willingness to pay for soft toric contact lenses in low and moderate astigmats. *Cont Lens Anterior Eye*. 2023;46(5):101887.
5. Stokkermans T, Louie D. Boost your first fit success rate. *Review of Optometry*. August 2023.

Photo: Vivian P. Shibayama, OD

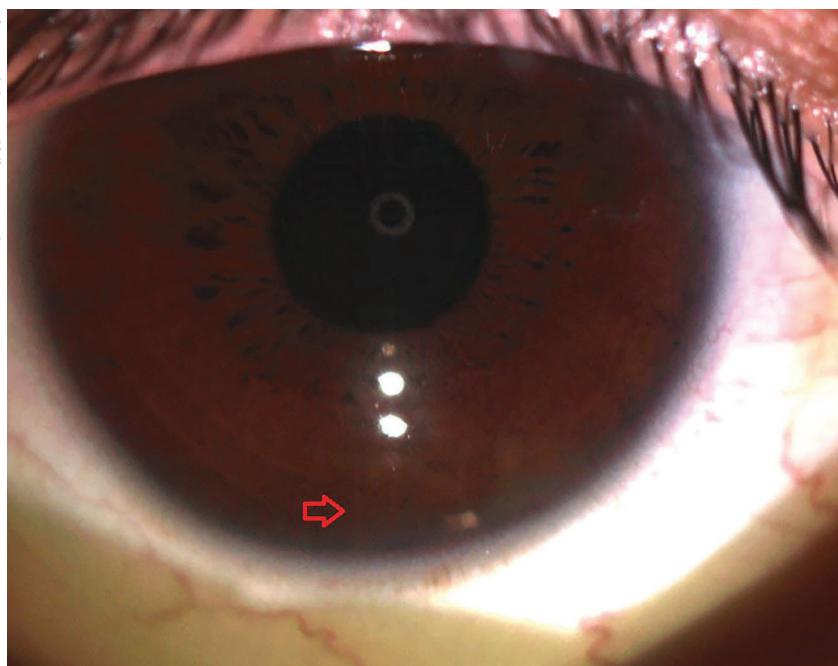


Fig. 4. Soft contact lenses must be aligned at the proper axis and have stable rotation to modify the Rx using LARS adjustment, as well as to promote optimal vision and comfort. The lens shown here is aligned at six o'clock.

Don't Chicken Out with These Pox

Recurrent or chronic herpes zoster ophthalmicus can worsen patient quality of life.

A 63-year-old male presented to the emergency room (ER) for onset of pain experienced two days prior, starting with left ear pain that radiated over to the left temporal side of his face, including his jaw. He reported “the muscles in his eye hurt” and had pain on eye movement. He also reported his eyeball was “irritated” and had tearing.

At the ER, the patient had a CT orbit with contrast; results were unremarkable. He had no ocular history and had not received the shingles vaccine, but reported exposure to varicella-zoster infection by his grandchild. Differentials included giant cell arteritis due to the patient's age and symptoms; however, his inflammatory markers (erythrocyte sedimentation rate/C-reactive protein) turned out to be low. Vision was 20/30 OD and OS with no afferent pupillary defect and intraocular pressures (IOPs) reading 12mm Hg OD and 13mm Hg OS. Slight erythema and early vesicle formation was seen on the lids OS.

During the ER bedside exam, an epithelial defect was reported with the posterior segment unremarkable. The patient was put on oral acyclovir 800mg five times daily, preservative-free artificial tears every hour to the left eye, erythromycin ointment to skin lesions and the left eye BID, warm compresses to periocular skin TID and cool compresses to the left eye BID. Gabapentin was also prescribed for pain and a varicella-zoster virus (VZV) IgM was ordered.

Two days later, the patient reported to our clinic. His entering uncorrected acuity was 20/20 OD and 20/50 OS with no afferent pupillary defect. At this visit, we couldn't obtain IOP read-

ings due to pain. The slit lamp exam revealed the patient was status post-LASIK many years ago and an inferior dendritiform lesion; the posterior segment was unremarkable to the extent seen. He continued all medications and increased his erythromycin ointment to QID.

He returned one week after his visit, reporting significant improvement of his ocular symptoms but was still suffering greatly from skin lesions. His uncorrected vision OS was 20/30 with IOP elevated to 26mm Hg. On this visit, the slit lamp exam revealed mild inferior microcystic edema and an almost resolved dendritiform lesion. A dilated fundus exam revealed no inflammation. The patient was started on timolol and prednisolone BID while also told to continue the oral acyclovir and erythromycin ointment. At the one-week follow-up visit, he was able to stop timolol, starting a slow taper of the PredForte (prednisolone acetate ophthalmic, Allergan) due to resolved herpes zoster ophthalmicus (HZO) OS.

HZO

This is an infection from VZV commonly occurring in childhood and is usually spread by airborne, droplet or contact transmission. When a patient has a HZ infection, it is from a reactivation of the latent VZV lying dormant in the sensory nerve ganglion. Any patient that has had chickenpox is at risk for HZ development. Outbreaks often occur with weakened immunity; this is referred to as shingles. The condition usually appears unilaterally and often as a maculopapular or vascular rash along a single dermatomal distribution.

HZO, which our patient was diagnosed with, is defined as the

viral involvement of the ophthalmic division (V1) of the trigeminal cranial nerve (V). The V1 is subdivided into three branches: the frontal nerve, nasociliary nerve and lacrimal nerve branches, any or all of which can be affected by HZO. Main risk factors for development include age greater than 50 and immunocompromised status.¹ Our patient fit both demographics, being older and undergoing cancer treatment.

In the US, approximately one per 1,000 individuals have HZ per year; however, this rate rises closer to one per 100 those 60 years or older.² One million new cases of HZ are reported annually, making it important to discuss with your patients that lower incidence occurs in those who had either the live attenuated or inactive recombinant zoster vaccines.^{2,3} In this case, the patient had not received either.

WARNING SIGNS

Before ocular involvement, these patients often present with prodromal pain in a unilateral V1 dermatomal distribution, then with an erythematous vesicular or pustular rash in the same area. Patients often describe the sensation as burning or shooting, and occasionally, they experience fever, malaise and/or headaches before the herpetic rash. Our patient experienced the shooting sensation without other symptoms.

Another non-ocular association is Hutchinson's sign, a rash involving the tip of the nose, which can develop from innervation of the nasociliary fibers. This sign is associated with a higher HZO risk, but around 30% of HZ patients without the sign will still develop HZO.³



Most HZ cases occur along truncal dermatomes, with only around 10% stimulating the trigeminal nerve, causing HZO.³ In cases of HZO, eye involvement is not required but is involved about 50% of the time. Most commonly, ocular manifestations include conjunctivitis, uveitis, episcleritis, keratitis and retinitis.² Differential diagnoses for HZO are migraine, giant cell arteritis and herpes simplex virus.

Most adults already have antibodies to chickenpox and therefore will have antibodies against VZV, making serology less helpful. Diagnosis can be made by clinical presentation or a polymerase chain reaction test of the tear film, which detects the herpes virus DNA. However, this is not widely available and is expensive.

TREATMENT

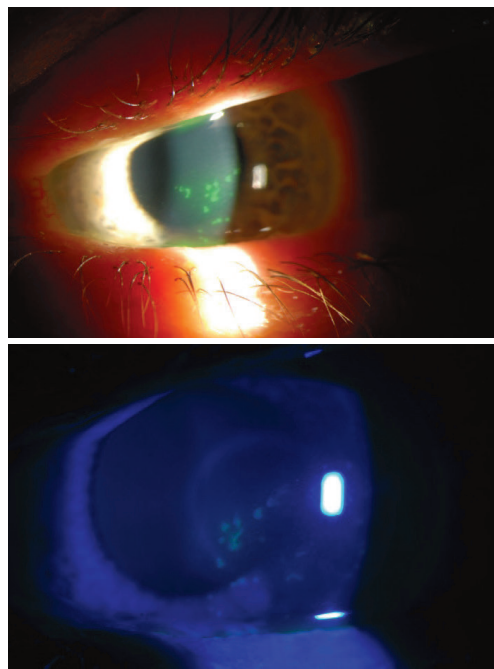
Management of HZO is not fully agreed upon. Patients are most commonly prescribed oral acyclovir tablets (either 800mg five times a day for seven days, valacyclovir 1g or famciclovir 500mg three times a day). Intravenous treatment is reserved for patients with HIV/AIDs. If this antiviral treatment is given within 72 hours of initial symptoms—specifically blisters—it is thought to reduce risk of chronic ocular complications by 20% to 30%, as well as aid in pain reduction and speeding of rash-healing time.⁴

If HZO involves dendritic keratitis or uveitis, chronicity should be addressed. Should this occur, one may opt to treat the cornea with topical acyclovir 3% ointment or ganciclovir 0.15% five times a day for at least five days. Most clinicians do not add topical treatment if the patient is already taking oral treatment. Steroids

should be added with stromal involvement or uveitis, then slowly tapered off. Be aware that tapering prior to full inflammatory resolution can result in prolonged healing. If treated properly, it is estimated that ocular HZO complication rates decrease from 39% to 2%.³

Sequelae can range from ocular to full-body effects. Once acute signs and symptoms have resolved, keep in mind that these patients can end up developing corneal anesthesia or neurotrophic keratitis. Neurotrophic keratitis can lead to epithelial defects, infections and scarring; therefore, frequent lubrication and monitoring is essential. Increase in IOP can be caused by disease or the steroid treatment used. In severe cases, posterior segment complications, including ocular apex syndrome, optic neuritis and acute retinal necrosis, can occur.¹

There is no evidence-based treatment for chronic and recurrent HZO. The most common practice pattern is to treat with a combination of oral antivirals and topical corticosteroids. Risk factors for chronic HZO include ocular hypertension and uveitis, while risk factors for recurrent HZO are female sex, an age greater than 50, immunocompromised status, more than 30 days of pain, autoimmune conditions, ocular hypertension and uveitis. The Zoster Eye Disease Study is assessing whether 1,000mg daily reduces ocular complications for chronic HZO. In the study, the researchers found that over half of respondents use prolonged antivirals



An example of herpetic keratitis.

for HZO treatment, with the dosage of 400mg oral acyclovir twice daily often being used.

This patient did very well with the initial oral antiviral, ocular hypertension drops and steroids; he was off all medications and scheduled for follow-up. Three to four weeks later, he returned for his follow-up, having noticed a shift in vision of one to two weeks. Any ideas what happened? **RCCL**

1. Liesegang TJ. Herpes zoster ophthalmicus natural history, risk factors, clinical presentation, and morbidity. *Ophthalmology*. 2008;115(2 Suppl):S3-12.
2. Minor M, Payne E. Herpes zoster ophthalmicus. In: StatPearls. Treasure Island (FL): StatPearls Publishing. Last updated August 14, 2023.
3. Tran KD, Falcone MM, Choi DS, et al. Epidemiology of herpes zoster ophthalmicus: recurrence and chronicity. *Ophthalmology*. 2016;123(7):1469-75.
4. Tuft S. How to manage herpes zoster ophthalmicus. *Community Eye Health*. 2020;33(108):71-2.



Polar Opposites

This rare cataract carries a higher risk of posterior capsular rupture and requires different surgical and post-op management strategies than more traditional cases.

A 45-year-old woman with a highly myopic eye with posterior staphyloma, glaucoma and keratoconic corneas presented for evaluation to improve vision. Upon exam, 4+ posterior cortical cataract with 2+ posterior subcapsular cataract was noted in both eyes; she was referred for retina evaluation and cataract surgery.

During surgery, it was discovered that she had posterior polar cataracts (PPC); however, the surgery remained uncomplicated and an IOL was placed in the bag. On follow up for contact lens fitting, it was noted her IOL was decentered inferior nasal and there was dense posterior fibrosis with contraction of the capsule. It was determined that nd:YAG laser was contraindicated secondary to zonular dehiscence, her poorly controlled IOP and the risk of retinal detachment. Her best scleral lens corrected vision is 20/40.

PPC is thought to be an autosomal dominant congenital cataract arising from hyaloid artery persistence or lenticular invasion by mesoblastic tissue.¹ Positive family history has been reported in about 40% to 50%, with an incidence of three to five per 1000.² It is bilateral in 65% to 85% of cases, with male:female ratio equal. There are associations of PPC with retinitis pigmentosa, Wilms tumor, aniridia, anterior polar cataract, microcornea and microphthalmia, as well as dermal conditions such as scleroderma, ectodermal dysplasia, Rothmund syndrome and dyskeratosis congenita.

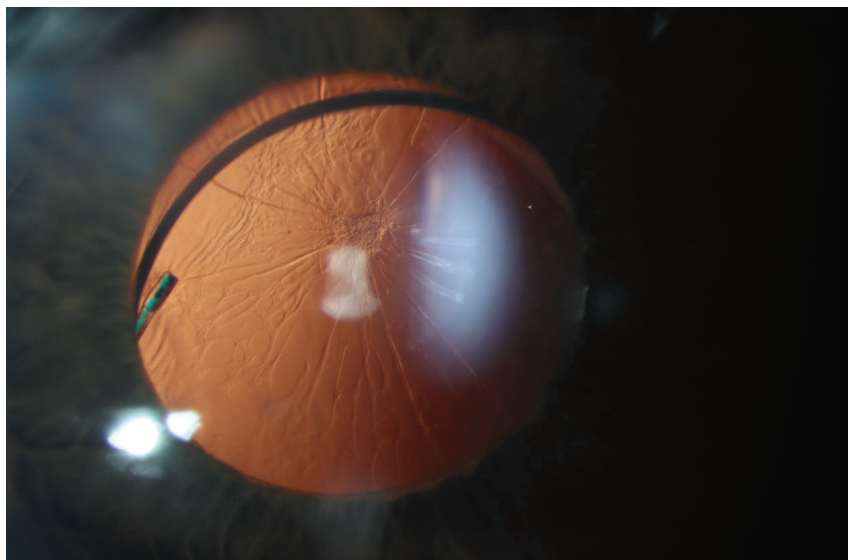
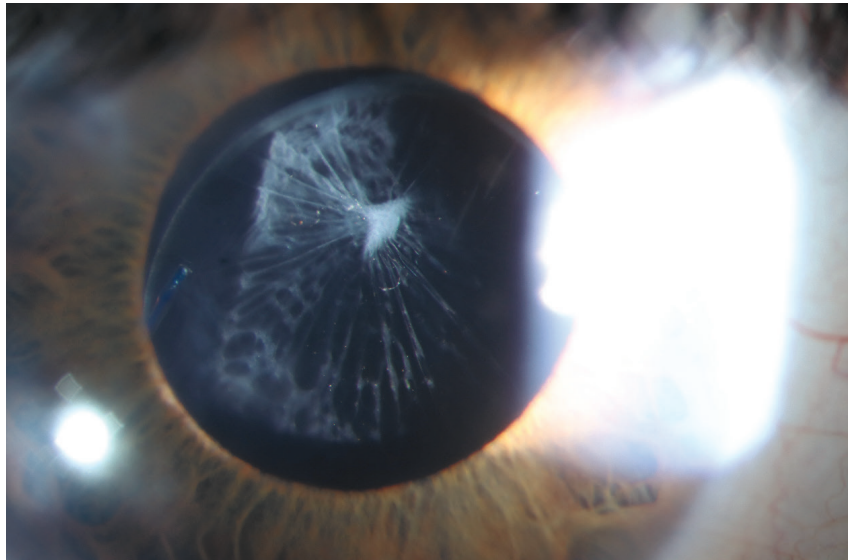
PPC is densely adherent to the posterior capsule, making it weak and increasing the odds of posterior capsular rupture during surgery. In

this case, it was felt the PPC plaque was densely attached to the posterior capsule and the surgeon should not dissect it by viscodissection. The risk of posterior capsular breach includes vitreous prolapse into the anterior chamber, nucleus drop and failure to implant IOL due to lack of capsular support. Our patient remains unhappy

with her final vision, despite a positive surgical outcome. **BCCL**

1. Gurnani B, Kaur K. Posterior Polar Cataract [Updated 2023 Jun 11]. In: StatPearls. Treasure Island: StatPearls Publishing; 2024 Jan. Available from www.ncbi.nlm.nih.gov/books/NBK574549.

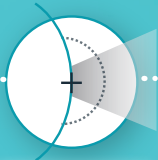2. Osher RH, Yu BC, Koch DD. Posterior polar cataracts: a predisposition to intraoperative posterior capsular rupture. J Cataract Refract Surg. 1990 Mar;16(2):157-62.



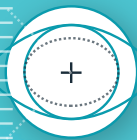LOOKING FOR A BETTER FIT FROM YOUR SCLERAL LENS?



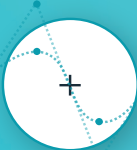Built-in oval optic zones
better centration



SmartSight®
superior visual acuity



Smart360®
free form digital lens design



SplineCurve®
*parameter independence
in a quad specific manner*



SmartChannel®
*vault anatomical obstacles
and reduce suction*

16-19mm Diameters

Extra Customization

- with Smart Features

Less than 2 cuts

- on average per eye

3 out of 4

- fits achieved with the standard lens in the FitKit®



Unique never felt so good.

Unique pH™ is a highly effective multipurpose solution for gas permeable contact lenses that cleans, conditions, and disinfects in one bottle.

Unique pH™ conditions lenses by adjusting to the eye's natural tear pH to enhance the wettability and comfort of gas permeable contact lenses on insertion. The formula is designed to provide a soothing effect during lens wear.

Complimentary starter kits available!

ORDER ONLINE



www.meniconwebstore.com

