

RCCL®

REVIEW OF CORNEA & CONTACT LENSES

NOVEMBER/DECEMBER 2022

**SURGERY
ISSUE**

EARN 2 CE CREDITS

Tackling Corneal Transplants *in Clinical Practice*

A comprehensive understanding of these procedures is critical to ensure optimal patient care and outcomes, *p. 22*

By Aaron Bronner, OD

- PTK: The Role it Plays Today, *p. 10*
- Optimizing the Ocular Surface Before Surgery, *p. 16*

MiSight® 1 day

is the **FIRST** and **ONLY** one for myopia control
in age-appropriate children*†

On average, children
wearing MiSight® 1 day
progressed **less than**
-1.00D over 6 years^{1‡}



**NOW
AVAILABLE
up to
-7.00D**



FDA-Approved*

How can myopia control with
MiSight® 1 day benefit your practice?

Learn more at [CooperVision.com](https://www.CooperVision.com).



CooperVision®

MiSight® 1 day
for daily wear

***Indications for use:** MiSight® 1 day (omafilcon A) soft (hydrophilic) contact lenses for daily wear are indicated for the correction of myopic ametropia and for slowing the progression of myopia in children with non-diseased eyes, who at the initiation of treatment are 8-12 years of age and have a refraction of -0.75 to -4.00 diopters (spherical equivalent) with ≤ 0.75 diopters of astigmatism. The lens is to be discarded after each removal.

† Soft contact lens designed for myopia control in the U.S.

‡ Fitted at 8-12 years of age at initiation of treatment.

References: 1. Chamberlain P, Arumugam B, Jones D et al. Myopia Progression in Children wearing Dual-Focus Contact Lenses: 6-year findings. *Optom Vis Sci* 2020;97(E-abstract): 200038.

J&J Myopia Prototype Relies on Different Optics

The company hopes that using a ring of focus, rather than a point of focus, can break the tradeoff between efficacy and visual quality typical of existing dual-focus products.

Myopia is a hot topic in eye care as the fastest-growing vision condition worldwide. Researchers are continually proposing new techniques such as novel contact lens designs that aim to reduce axial elongation, with varying levels of success. Most contact lenses for myopia management work by increasing add power in the treatment zone, thereby introducing myopic defocus in the visual field. However, increasing add power beyond a certain range may potentially degrade vision in the long term.

Hoping to develop a method that also helps preserve visual performance, Johnson & Johnson Vision recently began investigating soft contact lens prototypes featuring what it calls a “ring-focus design.”

Unlike existing multifocal or dual-focus (DF) designs, the plus power in the lens is created without a coaxial point focus, explains a new report in *Ophthalmology Science*.¹ “Rays passing through concentric annular zones of the prototype lenses form a ring focus in front of the retina,” the authors wrote. “The dispersal of these rays is such that the impact on vision is modulated compared to existing coaxial multifocal designs, while still controlling myopia progression.”

In a patent filing, the company asserts that “the significant benefit of such design is that visual acuity is less affected, interference with normal accommodation is minimized, and the halo effect is reduced. A larger treatment zone area and higher add power may be utilized as a result.”²

To test the trade-off between myopia reduction efficacy and vision quality, J&J developed two test lenses: one designed to enhance efficacy (EE) and the other to enhance vision (EV). “EE was designed to increase myopia control efficacy via the introduction of a greater amount of plus power than conventional multifocal or DF lens designs while maintaining comparable visual performance,” the researchers wrote. “EV was designed to optimize vision while maintaining similar myopia control efficacy to a standard DF lens. Both lenses include two concentric, annular zones with +7D non-coaxial plus power for myopia control treatment, but these annular treatment zones in the EE lens are positioned closer to the center of the lens than in EV. EE also includes a +10D coaxial treatment zone that was designed to further ‘boost’ myopia control efficacy while limiting its impact on vision.”

The team reported on a study, funded by J&J, comparing the efficacy of the two prototypes with a DF multifocal (in

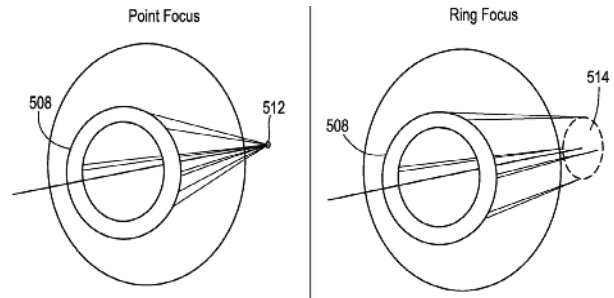


Photo: Johnson & Johnson

This J&J study touts the advantage of optics that create a ring focus (right) rather than the point focus (left) of existing lenses.

effect, the benchmark for myopia control) and a single-vision (SV) lens (the benchmark for visual quality). The study evaluated 185 patients wearing the various lens designs over the course of 26 weeks (n=44, 49, 45 and 47 for EE, EV, DF and SF, respectively).

Patients wearing EE, EV or DF lenses had less axial elongation than those wearing SF lenses (EE: 0.08mm, EV: 0.12mm, DF: 0.14mm, SV: 0.19mm). Both EE and EV lenses resulted in less axial elongation than DF lenses, but only the difference between EE and DF lenses was significant (-0.05mm).

When comparing EE and SF lenses, EE alone had less progression (-0.12D vs. -0.35D), but in EV vs. DF lenses, no difference was shown. The authors concluded from their research on the lens prototypes that “EE was more efficacious in slowing axial elongation than DF with comparable vision performance, while EV produced comparable efficacy to DF with similar vision performance to SF.”

The researchers argue that lenses with a non-coaxial ring-focus design might “offer an alternative approach [for myopia control] with potential to mitigate some of the limitations of conventional presbyopic coaxial principles.”

Last year, J&J launched in Canada a soft lens for myopia using this system of optics, called Acuvue Abiliti 1-Day. The company currently anticipates a US launch sometime in 2024. The commercial product in the Canadian market is indicated for children aged seven to 12 with myopia between -0.75D and -4.50D and 1.00D or less of astigmatism.

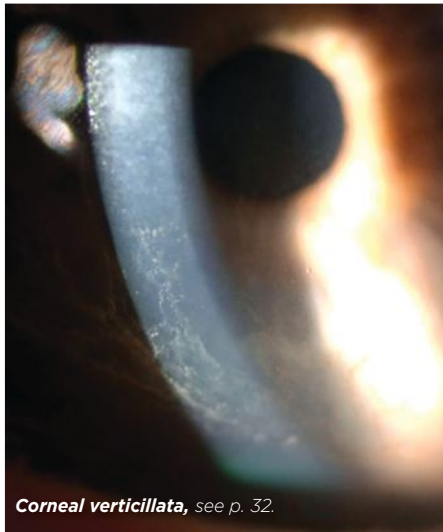
1. Cheng X, Xu J, Brennan NA. Randomized trial of soft contact lenses with novel ring focus for controlling myopia progression. *Ophthalmol Sci*. October 18, 2022. [Epub ahead of print].

2. Brennan NA, Cheng X, Hernandez JV, et al. Ophthalmic lens with an optically non-coaxial zone for myopia control. Assignee: Johnson & Johnson. 2021. US Patent No. 10901237.

contents

Review of Cornea & Contact Lenses | November/December 2022

features



Corneal verticillata, see p. 32.

departments

3 News Review

J&J Myopia Prototype Relies on Different Optics

6 My Perspective

Consider Serology for HSV
By Joseph P. Shovlin, OD

8 The GP Expert

The Simple Things
By Lindsay A. Sicks, OD

32 Corneal Consult

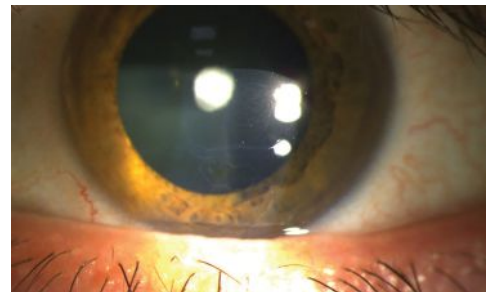Don't Be Scared by the Whirlwind
By Suzanne Sherman, OD

10

PTK: The Role it Plays Today

Many anterior corneal pathologies can respond well to this versatile procedure, potentially sparing the patient from undergoing a transplant.

By Lawrence Nguyen, OD,
and Mitch Ibach, OD

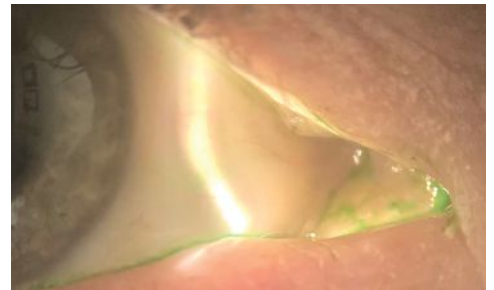


16

Optimizing the Ocular Surface

Properly treating DED prior to surgery is key for the best postoperative outcomes.

By Pam Theriot, OD

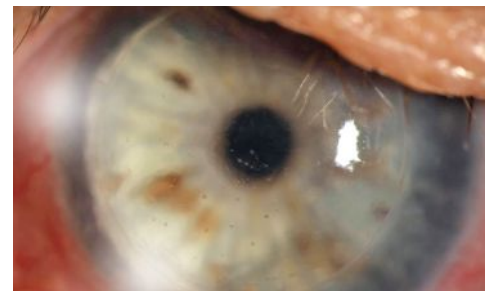


22

CE: Tackling Corneal Transplants in Clinical Practice

A comprehensive understanding of these procedures is critical to ensure optimal patient care and outcomes.

By Aaron Bronner, OD





KERATOCONUS and CROSS-LINKING

Practice Considerations in Managing Keratoconus and Cross-Linking



Nicole Albright, OD
Clinic Director,
Moses Eyecare Center
An independent optometry
practice in Merrillville, IN

KEY TAKEAWAYS

- Managing keratoconus (KC) meets patients' needs as part of a medical-model optometric practice.
- There is no global period for cross-linking; each follow-up visit is billed as an office visit.
- The progressive KC patients I have referred for cross-linking have become loyal patients.

Many optometrists are shifting towards a medical model of practice, managing chronic conditions with ocular manifestations, including dry eye, glaucoma, and diabetes. Diversifying the services you offer can better meet the needs of your patients.

Managing keratoconus (KC) is a great way to "lean in" to that more comprehensive medical model of optometric care. About 70% of KC patients first present to an optometrist's office,¹ which means

that we have a unique opportunity to identify this progressive disease and refer patients for the FDA-approved iLink® cross-linking procedure in the early stages, before there is permanent vision loss. After treatment, we can continue to address the patient's vision needs over time.

Collaborating with cornea specialists in the care of KC patients has provided comprehensive patient care and strengthened my relationships with ophthalmologists in the community. When they realize that we share a common goal of helping our KC patients, it opens the door not only to specialty contact lens fitting and follow-up care after cross-linking, but to collaboration and referrals in other areas, as well.

Follow-up care after iLink® cross-linking is similar to that required for PRK, with five or more visits and one or more contact lens re-fittings in the first year being typical. After that, KC patients will continue to need vision care and annual medical eye care appointments to monitor for any further corneal changes. While the timing and frequency of office visits may vary by patient and at the doctor's discretion, there is no global period for cross-linking. Any necessary post-treatment visits and diagnostic tests, such as pachymetry and topography, are typically billed separately.

I personally find scleral lens fitting and the management of progressive KC patients who are undergoing cross-linking to be among the most rewarding things I do as an optometrist. First and foremost, we offer them a treatment that can slow or halt KC progression. Furthermore,

patients are so very appreciative when you can pinpoint the cause of and address their visual quality problems with contact lenses.

Modeling suggests that iLink® cross-linking saves the average patient nearly \$9,000 in direct medical costs and nearly \$44,000 in lifetime costs²—and that doesn't even include the impact on their mental health and well-being. In addition to the cost savings, it is very fulfilling to me to know that I can help protect a young person with early progressive KC from progressing to the advanced stages of the disease, potentially avoiding a lifetime of vision loss and the need for corneal transplant surgery. One study showed a 25% drop in corneal transplants after the introduction of cross-linking.³

Our KC patients are grateful for this care. They will rave about you on social media, refer family and friends—and generally become loyal patients. ■

REFERENCES:

1. Eisenberg JS. First Treatment for Keratoconus Itself. *Optometry Times*, June 1, 2012.
2. Lindstrom RL et al. *J Med Econ* 2021;24:410.
3. Godefrooij DA, Gans R, Imhof SM, et al. *Acta Ophthalmol* 2016; 94:675-678.

INDICATIONS

Photrex® Viscous (riboflavin 5'-phosphate in 20% dextran ophthalmic solution) and Photrex® (riboflavin 5'-phosphate ophthalmic solution) are indicated for use with the KXL System in corneal collagen cross-linking for the treatment of progressive keratoconus and corneal ectasia following refractive surgery.

IMPORTANT SAFETY INFORMATION

Corneal collagen cross-linking should not be performed on pregnant women. Ulcerative keratitis can occur. Patients should be monitored for resolution of epithelial defects. The most common ocular adverse reaction was corneal opacity (haze). Other ocular side effects include punctate keratitis, corneal striae, dry eye, corneal epithelium defect, eye pain, light sensitivity, reduced visual acuity, and blurred vision.

These are not all of the side effects of the corneal collagen cross-linking treatment. For more information, go to www.livingwithkeratoconus.com to obtain the FDA-approved product labeling. You are encouraged to report all side effects to the FDA. Visit www.fda.gov/medwatch, or call 1-800-FDA-1088.

With your medical management and cross-linking referrals, modeling² suggests that patients benefit:

\$8,677

DIRECT MEDICAL COST SAVINGS PER PATIENT

\$43,759

REDUCTION IN LIFETIME COSTS PER PATIENT

1.88

INCREASE IN PATIENT QUALITY-OF-LIFE-YEARS

SCAN WITH PHONE

Learn more about iLink corneal cross-linking here





Consider Serology for HSV

This test might make sense for tackling the great masquerader.

Clinicians frequently face diagnostic challenges when herpes simplex virus (HSV) is part of the list of differentials. Unfortunately, ocular HSV infections are often not diagnosed in a timely fashion, initially presenting as blepharitis or conjunctivitis. To add to the confusion, although the majority of HSV infections are unilateral, a significant number can be bilateral. Clinicians will commonly look at an array of corneal signs—or even keratouveitis—wondering if it might be HSV.

A DECEPTIVE VIRUS

Of course, there are classic features such as corneal dendrites (ulcerative) that make the diagnosis easy, but even then, other branching lesions, “pseudodendrites,” will represent a different disease anomaly. The differential is long and includes the nonulcerative dendritiform with a wide range of etiologies, such as *Acanthamoeba* keratitis, healing abrasions, and herpes zoster keratitis, to name a few.¹

Many have nicknamed HSV the “great masquerader” for good reason. This virus can present and actually linger with many different clinical presentations well beyond the classic dendrite. For example, a simple cluster of punctate staining can desquamate down to form a dendrite later. Also, note that an anterior chamber reaction with an uncharacteristically high intraocular pressure is often HSV in disguise. The sage clinician will always say, “if I don’t know what that might be with the slit lamp, it’s commonly HSV.”

A USEFUL TEST

Does HSV serology make sense? A quick review of what serology tells us about this patient is in order. Remember the time required for the development of IgG antibodies for HSV exposures/infections will range from three to six weeks and up to several months if antiviral medications have been used.² So, nonreactive IgG levels do not always indicate the absence of infection.

However, most patients have detectable IgG antibodies after exposure in three to four weeks. But, once established, life-long detection of IgG is likely forever.² IgM antibody detection is generally considered detectable around 10 days after recent exposure and will only last for one to two weeks signifying current exposure.^{2,3}

Contrary to popular belief, positive serology for HSV1 and/or HSV2 does not exceed more than 60% in most population-based studies in the United States. In a recent study, seroprevalence was 42.6% (HSV-1) and 18.5% (HSV-2).⁴ This finding means that, if a clinician does not detect IgG/IgM antibodies with appropriate timing, the chance that they are dealing with a HSV infections is virtually zero!

Serology with IgG detection won’t guarantee a definitive diagnosis since many patients have positive antibodies to HSV-1 and/or HSV-2 due to past exposure(s). But, knowing what it isn’t (in this case, a negative serology if performed properly) can be valuable in managing vexing presentations. Although a HSV diagnosis is most

often made clinically, laboratory testing is available for confirmation using cytology, cell cultures and polymerase chain reaction testing, the “gold standard,” to confirm a diagnosis.

Commercial type-specific enzyme-linked assays are currently available to detect antibodies for HSV exposures.³ They have relatively good sensitivity for both HSV-1 and HSV-2. Please take note of the caveats listed above, specifically not relying on IgG positivity to pinpoint current exposure or infection (the patient might have life-long IgG levels without current infection). Additionally, assays may have indeterminate levels of antibody with borderline reactivity or equivocal findings.³

Our practice uses this rather inexpensive testing since it is widely available and useful in the clinic for suspected HSV. It helps in the differential especially when there is an atypical or chronic presentations. Negative serology will allow for avoidance of unnecessary antiviral medication and direct the clinician to another etiology. **RCCL**

1. Rapuano C, Shovlin J. Herpes simplex virus dendritic epithelial keratitis. www.zirganpro.com/siteassets/pdf/bl-wp-zirgan.pdf. Accessed October 15, 2022.

2. Herpes simplex—immunity serology. Public Health Ontario. Updated October 7, 2020. [www.publichealthontario.ca/en/laboratory-services/test-information-index/herpes-simplex-immunity-serology](http://www.publichealthontario.ca/en/laboratory-services/test-information/index/herpes-simplex-immunity-serology). Accessed October 15, 2022.

3. Corey L, Spear PG: Infections with herpes simplex viruses. *N Engl J Med*. 1986;314:686-91.

4. Wang J, Cherlan DG, Goshe JM. Utility of HSV serology for chronic corneal pathology. *Eye Contact Lens*. 2020;46(3):190-3.



PROGENT

Biweekly cleaning for gas permeable lenses

**ORDER
ONLINE**



www.meniconwebstore.com

Say **goodbye** to
protein and deposits

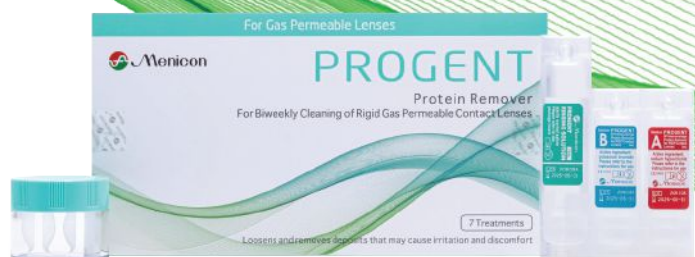
IN 30 MINUTES



NO mechanical rubbing

NO abrasive cleaners

NO wasted time



Biweekly use of **Menicon PROGENT** removes protein build up and helps maintain deposit-free lenses without the mechanical rubbing or abrasive cleaners that can damage plasma treated lenses or complex surface geometries.



© 2022 Menicon Co. Ltd. See instructions for use in the package insert. Manufactured by Menicon Co. Ltd.
Menicon PROGENT should not be used on lenses treated with Tangible Hydra-PEG. US-WS110



meniconamerica.com

The Simple Things

More often than not, the explanation and solution to a patient's problem is a simple one.

A few recent cases have reminded me of Occam's razor—the idea that the simplest explanation is usually the correct one (also known as the “law of parsimony”). The first patient presented with a sudden-onset painful eye and the second presented with sudden-onset blurry vision in both eyes. Can you guess the culprit in each case?

IS IT A FOREIGN BODY?

A 25-year-old male presented to our Urgent Care service complaining of a sudden-onset painful right eye since applying his habitual GP lens. He noted associated light sensitivity, redness and tearing with pain rated a seven out of 10. After removing the lens, the pain improved to a four out of 10. He thinks he may have scratched his eye.

The patient has a history of keratoconus OU with associated scarring OS>OD. He only wears a

GP lens OD, which improves vision to 20/25. He does not wear a lens OS, and vision is 20/500. He was using a GP multipurpose solution to clean the lens and rinsed it with water before application. A penetrating keratoplasty had been recently recommended for the OS, but the patient is deferring the procedure due to work obligations.

He was wearing a ComfortKone (Metro Optics) design with parameters OD 5.40/8.5/-22.50/A24. One of our ocular disease residents was concerned about a curvilinear pattern of staining on the cornea that looked like a foreign body. However, no foreign body was visible in white light. The upper lid and lower lid were everted with no foreign body present. The resident had already irrigated the eye with no improvement in symptoms.

After consulting with the resident, the main concern was the corneal staining pattern. They had several lofty ideas of what may have caused the staining, including threads in the eye, an eye injury or even *Acanthamoeba* because of the water use. After a few open-ended questions, I asked the resident if the patient had brought the lens in question and asked they retrieve it.

I carefully removed the lens from the case and placed it on our 7x magnifier. Sure enough, there were several cracks through the lens, one of which matched—almost ex-

actly—the staining pattern present. Problem solved!

A cracked or damaged GP lens is obviously undesirable and not suitable for wear. Clinicians should remind patients to inspect their lenses for damage each day before application. This means visually inspecting the lens on the finger for any cracks, edge chips or foreign material. Once the overall integrity of the lens is confirmed, it can be conditioned and applied to the eye. Any cracks or damage can cause eyelid or corneal irritation or injury.

If a lens is damaged on the eye or during wear, the patient will usually notice a sudden change in vision. They may have been able to remove only part of the lens fragments. Should this occur, obtain a sufficient case history to piece together the situation at the time of lens loss, but also then instill sodium fluorescein to aid in locating any remaining lens fragments. Upper and lower lid eversion and careful evaluation are crucial. Irrigation may also help clear any additional foreign debris from the fornices.

This patient's corneal abrasion was treated, a new lens was reordered and lens aftercare procedures were reviewed, with stress on avoiding contact with tap water moving forward.

IS IT SUPPOSED TO BE “LEFT BLUE?”

A patient with keratoconus called the emergency line to report sudden onset blurry vision OU after applying a new pair of duplicate lenses they had recently picked up from the office. To try and fix the problem, he removed the lenses,



Curvilinear pattern highlighted by sodium fluorescein dye. It is overlying an area of existing corneal scarring from keratoconus.



EDITORIAL STAFF

EDITOR-IN-CHIEF

Jack Persico jpersico@jobson.com

SENIOR EDITOR

Julie Shannon jshannon@jobson.com

SENIOR ASSOCIATE EDITORS

Catherine Manthorp cmanthorp@jobson.com

Mark De Leon mdeleon@jobson.com

ASSOCIATE EDITORS

Leanne Spiegle lspiegle@jobson.com

Rachel Rita rrita@jobson.com

CLINICAL EDITOR

Joseph P. Shovlin, OD jpshovlin@gmail.com

ASSOCIATE CLINICAL EDITOR

Christine W. Sindt, OD christine-sindt@uiowa.edu

SENIOR ART DIRECTOR

Jared Araujo jaraujo@jhihealth.com

GRAPHIC DESIGNER

Lynne O'Connor lyoconnor@jobson.com

AD PRODUCTION MANAGER

Karen Lallone klallone@jhihealth.com

BUSINESS STAFF

PUBLISHER

Michael Hoster mhoster@jobson.com

SENIOR MANAGER, STRATEGIC ACCOUNTS

Michele Barrett mbarrett@jobson.com

REGIONAL SALES MANAGER

Jon Dardine jdardine@jobson.com

EXECUTIVE STAFF

CEO, INFORMATION SERVICES GROUP

Marc Ferrara mferrara@jhihealth.com

SENIOR VICE PRESIDENT, OPERATIONS

Jeff Levitz jlevitz@jhihealth.com

SENIOR VICE PRESIDENT, HUMAN RESOURCES

Tammy Garcia tgarcia@jhihealth.com

VICE PRESIDENT, CREATIVE SERVICES & PRODUCTION

Monica Tettamanzi mtettamanzi@jhihealth.com

VICE PRESIDENT, CIRCULATION

Jared Sonners jsonners@jhihealth.com

CORPORATE PRODUCTION MANAGER

John Caggiano jcaggiano@jhihealth.com

EDITORIAL REVIEW BOARD

James V. Aquavella, MD

Edward S. Bennett, OD

Aaron Bronner, OD

Brian Chou, OD

Kenneth Daniels, OD

S. Barry Eiden, OD

Desmond Fonn, Dip Optom, MOptom

Robert M. Grohe, OD

Susan Gromacki, OD

Patricia Keech, OD

Bruce Koffler, MD

Pete Kollbaum, OD, PhD

Jeffrey Charles Krohn, OD

Jerry Legerton, OD

Kelly Nichols, OD

Robert Ryan, OD

Jack Schaeffer, OD

Charles B. Slonim, MD

Kirk Smick, OD

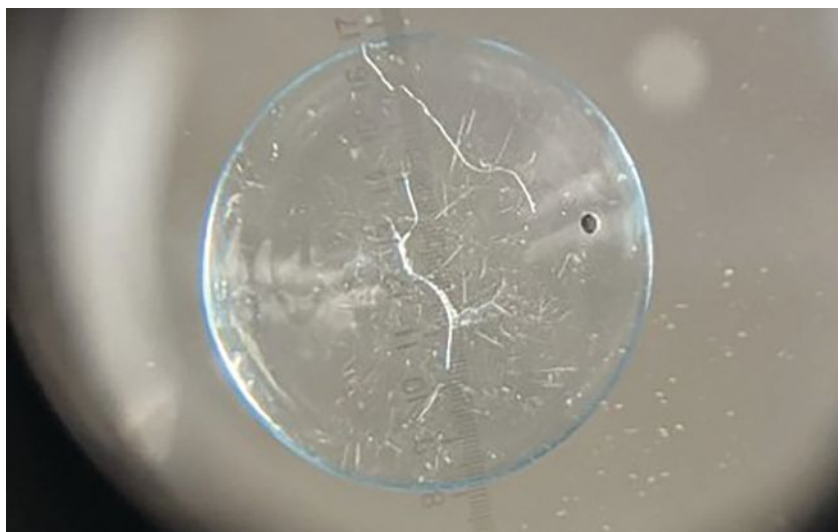
Mary Jo Stiegemeier, OD

Loretta B. Szczotka, OD

Michael A. Ward, FCLSA

Barry M. Weiner, OD

Barry Weissman, OD



A cracked lens (seen here, concave side down on a 7x magnifier) caused the corneal staining pattern with the previous image.

cleaned them and re-applied but to no avail.

He tried putting in his old lenses and reported clear vision. He inquired as to whether his lenses can be exchanged with the lab or if he should come in for a follow-up visit.

We arranged to see the patient and he denied any issues with lens comfort. He had worn the lenses about four hours on this day and felt like vision was now worse OS. The lenses ordered were a spherical GP lens (Art Optical) design with parameters OD: 8.25/9.2/-2.50/Optimum Extra/green and OS: 8.25/9.2/-1.75/Optimum Extra/blue. The patient had seen 20/20 out of these lenses in each eye at his most recent annual evaluation, at which time the prescription was duplicated.

One of our students worked up the patient and found entering vision of OD 20/25+2 and OS 20/40 with an over-refraction of OD -0.25 and OS +1.00 which improved VA to

20/20 OD and 20/20-3 OS. The student evaluated the lenses on-eye, noting an appropriate fit. After the patient removed the lenses, the student astutely noticed the lens on the right side of the case appeared blue and the lens on the left side of the case appeared green, suggesting the lenses were switched.

Indeed, the simplest explanation strikes again! We reviewed how the over-refraction result and improvement in vision seen confirms that the lenses were swapped. We proceeded to switch the lenses back, and our (somewhat embarrassed) patient returned home none the worse for wear.

When troubleshooting patient complaints, look for the horses—not the zebras. The fix may be relatively simple on our end, providing major relief to our patients at a time of great concern and worry on their end. **RCCL**

PTK: THE ROLE IT PLAYS TODAY

Many anterior corneal pathologies can respond well to this versatile procedure, potentially sparing the patient from undergoing a transplant.

By Lawrence Nguyen, OD, and Mitch Ibach, OD

Phototherapeutic keratectomy (PTK) requires the use of a 193nm excimer laser to treat superficial corneal lesions. This type of photoablation provides a minimally invasive approach to removing lesions while ablating less than 20% of the corneal tissue. The goal is to improve the corneal clarity, enhance visual quality and reduce future corneal sequelae.¹

As the world of eye care continues to grow, so are the types of surgical procedures. PTK first gained FDA approval back in 1995. Prior to the laser, a deep anterior lamellar keratoplasty was a first surgical consideration over a penetrating keratoplasty (PKP) for anterior corneal diseases. This procedure involves replacing the patient's cornea down to Descemet's membrane. However, normal endothelial function is required, otherwise a PKP is necessary to prevent corneal decompensation. Even then, a PKP carries its own list of complications and an average lifespan of 15 years.²

PTK offers patients a less invasive alternative to keratoplasties.

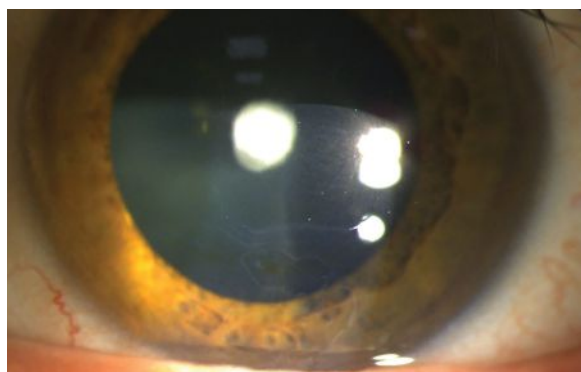


Fig. 1. Slit lamp photo of a patient with EBMD OS and a history of multiple RCEs. Patient is scheduled to undergo PTK surgery OS. A polar cataract is also captured in this photo.

An added advantage includes earlier recovery times and the ability to repeat the procedure in the case of recurrence. Studies observing the long-term efficacy of PTK have found that most recurrences take place, on average, within the first year, and 14% to 36% of patients who had a PTK required a second PTK.^{1,3,4} Mitomycin-C, an antifibrotic agent, can be used intraoperatively to reduce recurrence and minimize postoperative scarring.⁵

This procedure can be used in tandem with superficial keratectomy (SK), which is the manual dissection of the corneal epithelium without disrupting Bowman's layer and using a surgical blade

or diamond burr. Elevated opacities, like Salzmann's nodular degeneration, respond well to this mechanical technique with the excimer laser to polish the underlying stroma.

COMMON INDICATIONS

PTK is suitable for patients with corneal pathologies within the anterior third of the cornea. The most common pathologies that require treatment with PTK involve stromal lesions, elevated epithelial lesions or recurrent corneal erosions.⁵ In our practice, patients commonly undergo PTK due to visually significant epithelial basement membrane dystrophy (EBMD) or recurrent corneal erosions.

ABOUT THE AUTHORS



Both Drs. Ibach and Nguyen work at Vance Thompson Vision in Sioux Falls, SD. There, Dr. Ibach is a residency trained optometrist and is the residency co-coordinator. Dr.



Nguyen is currently completing her advanced clinical training in ocular disease with an emphasis in ocular and refractive surgery, glaucoma and anterior segment.

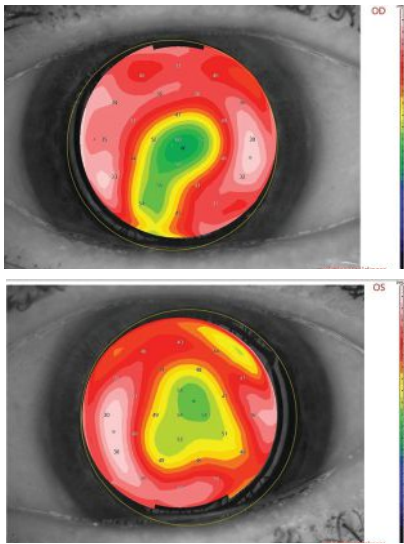


Fig. 2. Shown here is an epithelial thickness map of a patient with significant EBMD located centrally. An average epithelial thickness is 50 μ m. Differences greater than 5 μ m are considered abnormal.

To assess whether a patient is a good candidate for PTK, a slit lamp examination is required, although an anterior segment OCT can be an even more powerful tool. Opacities and lesions are often clearly visible and can aid in quantifying the depth of the lesion. This is especially helpful in cases of depressed corneal scars.

If corneal topography is available, this can also map out the cornea anteriorly. Patients are more likely to be visually symptomatic if the corneal pathology is within the

central 5mm zone. If your practice has epithelial thickness mapping, this can enhance the predictability of healing post-PTK and highlight how the epithelium will respond to corneal pathologies.

ELEVATED LESIONS

Salzmann's nodular degeneration is a corneal disease that responds well to a combination of PTK and SK. Often, patients with these nodules remain asymptomatic and can be monitored. However, it can create irregular astigmatism and/or discomfort if the nodules increase in size. Since these elevated lesions are anterior to Bowman's layer, SK alone can be enough to leave a smooth underlying surface. If irregularities remain underneath, then the excimer laser can help polish the underlying stroma.

EBMD AND RECURRENT CORNEAL EROSIONS

Among the corneal dystrophies, EBMD is the most common anterior dystrophy.⁶ It is characterized by an irregular epithelial appearance due to thickening of the basement membrane and weakened hemidesmosomes. This can lead to corneal erosions or be visually significant, depending on its severity. Based on

the location of the EBMD, patients may be uncorrectable to 20/20 or have visual complaints. In these cases, a rigid gas permeable (RGP) over-refraction is an underused tool for determining whether the cornea is the source of visual complaints. If the patient displays subjective improvement, this can be the best evidence in support of proceeding with a PTK.

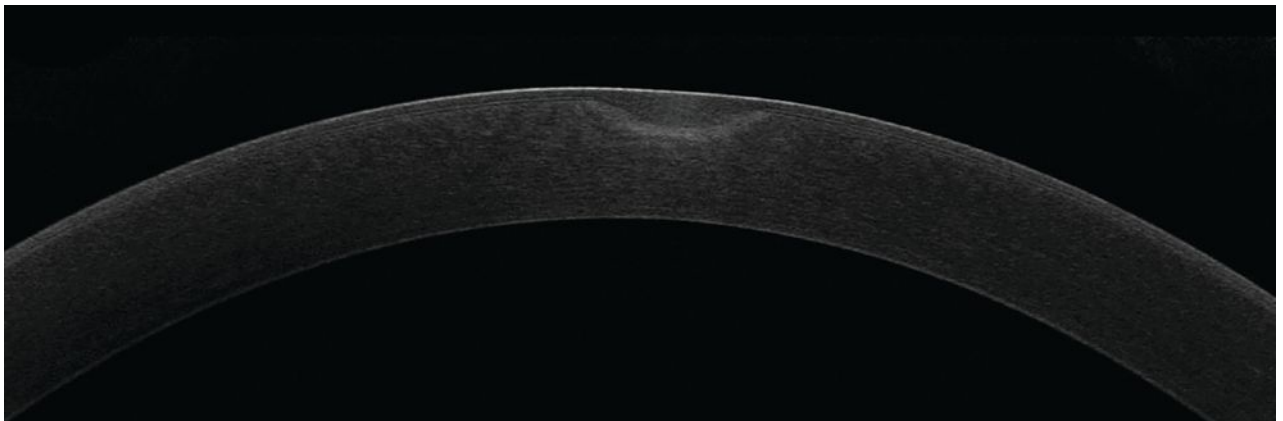Patients with a history of corneal abrasion or trauma are also more susceptible to an RCE. As optometrists, we can manage this conservatively with a punctal occlusion, artificial tears, gel or ointment and a bandage contact lens (BCL). Loose epithelium can also be debrided behind the slit lamp. However, these conservative treatments often have a higher recurrence rate and lead to multiple visits for the patient.⁷ Due to the reduced recurrence rate with PTK, this can be a great first-line option to manage patients.

STROMAL LESIONS

Other anterior corneal dystrophies include Reis-Bücklers, granular dystrophy and lattice dystrophy. If they are visually significant, they can also respond well to PTK.

In cases where PTK is intended for spot treatment, there is a risk

Fig. 3. Here is an example of a depressed corneal scar nearly missing the visual axis. This patient had complaints of visual disturbances but was not a good candidate for PTK due to the depth of the scarring.



PTK: THE ROLE IT PLAYS TODAY

for unintended refractive changes. For central lesions, excessive localized laser treatment can induce a hyperopic shift because of a central flattening effect. In comparison, peripheral lesions may result in central steepening and induce an unintended myopic shift. Generally, PTK is considered a refractive neutral procedure due to the minimal surface ablation involved.

CORNEAL SCARS

Rarely will a scar respond well to the excimer laser. Again, an anterior segment OCT is best for determining the depth of the scar. To minimize hyperopic shifts and stromal haze, depressed scars should not encompass more than 20% depth of the corneal tissue. Otherwise, you are running a high risk for stromal haze.

CASE A. PTK ON A SUPERFICIAL SCAR

A 70-year-old female presented for a cataract evaluation. BCVA was 20/25 OD and 20/30 OS. Slit lamp examination revealed a mild cataract OD and OS with a central 2mm depressed corneal scar OS. The patient was educated on a guarded visual prognosis following cataract surgery due to the central scar in her left eye (Figs. 4 & 5). After further diagnostic testing, the patient was determined to be a candidate for PTK (Fig. 6). Based on the superficial nature of the scar, the patient elected to proceed with PTK prior to cataract surgery to attempt improvement of her visual potential. After the cornea heals, the patient will proceed with a small-aperture (IC-8; Acufocus) IOL OS to reduce corneal aberrations.

PTK COMPLICATIONS

Watch out for the following adverse events after the procedure:

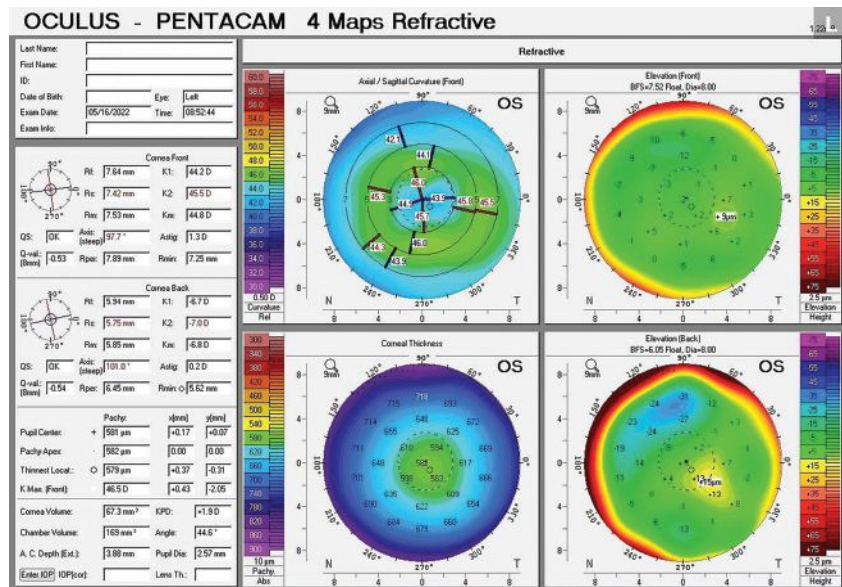


Fig. 4. Pentacam of patient from Case A with a history of a corneal ulcer infection OS resulting in a central corneal scar. The depressed corneal scar can be appreciated with the axial curvature map.

- Recurrence of disease
- Infections
- Reactivation of herpes simplex virus
- Delayed healing of epithelium
- Corneal haze or scarring
- Hyperopic shift

POSTOPERATIVE MANAGEMENT

We as optometrists play a crucial role in the postoperative management of PTK. As the referring doctor, trust has been established. Patients will likely choose to return to be comanaged. Initially, these patients should be educated and advised about the first four days after surgery. Burning, stinging, irritation, light sensitivity and overall discomfort is to be expected since a large epithelial defect is present. Individuals with a history of herpes simplex keratitis should be prophylactically treated with oral antivirals to prevent reoccurrence.

Similar to photorefractive keratectomy (PRK), patients will have a BCL after the procedure. Our practice schedules post-op visits

at four days and one month after surgery.

At the day-four visit, a healed epithelium or epithelial ridge should be present. If an epithelial defect is still visible, it is not advised to remove the BCL at that time. The patient should return at a later date; otherwise, there is a risk of an iatrogenic corneal erosion during the removal of the BCL.

As a tip, if a patient's BCL continues to fall out without any manipulation from the patient, try using a larger diameter lens or recommend a temporary tape tarsorrhaphy. This can alleviate a patient's concern and prevent multiple trips back to the office.

Patients are prescribed a combination antibiotic/anti-inflammatory eye drop for two weeks. We use Pred-Moxi (prednisolone acetate and moxifloxacin; Imprimis) QID for one week, then BID for one week. The patient is also advised to heavily lubricate with preservative-free artificial tears, especially during the first week. Oral NSAIDs are recommended for patients in

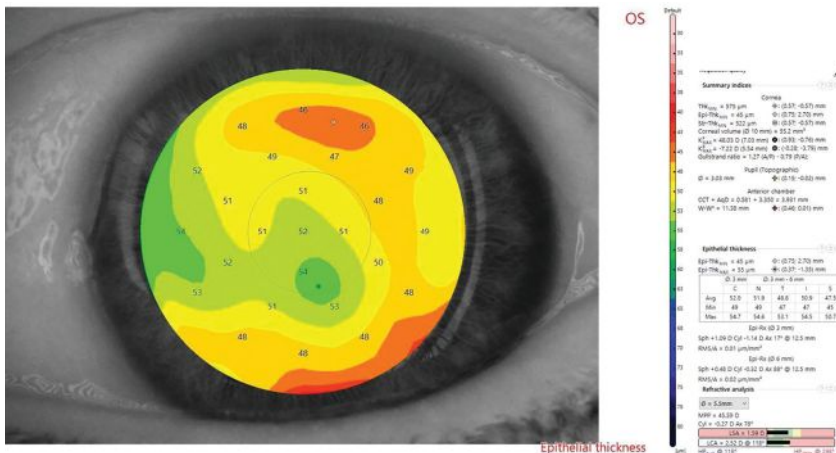


Fig. 5. Epithelial thickness mapping in Case A shows thickening overlying the depressed corneal scar.

a considerable amount of pain. Topical anesthetic is handed out to patients for rare circumstances. We do not dilute the bottle and advise patients to discard by day two postoperatively. Patients need to be well educated prior to using these drops, as instilling more than six times a day can result in delayed wound healing. Remember, compared to PRK, there is a higher risk for poor healing, infection and haze after PTK since these corneas are routinely not “normal.”

WHICH FIRST: PTK OR CATARACT SURGERY?

When patients with cataracts present to your office, they will have complaints of decreased BCVA, increased glare and halos at night

and/or struggles with their daily living activities. Accurate biometry and keratometry is essential for calculating an appropriate IOL to ensure the best postoperative visual outcome.

Corneal pathologies like EBMD can affect the reliability of these measurements. If an irregularity visualized on slit lamp examination is supported by abnormal topography or epithelial thickness mapping, an RGP over-refraction is a crucial next step. The RGP over-refraction utilizes the tear film to mask the corneal surface, diagnostically ruling out whether the cornea, cataract or both are impeding vision. If there

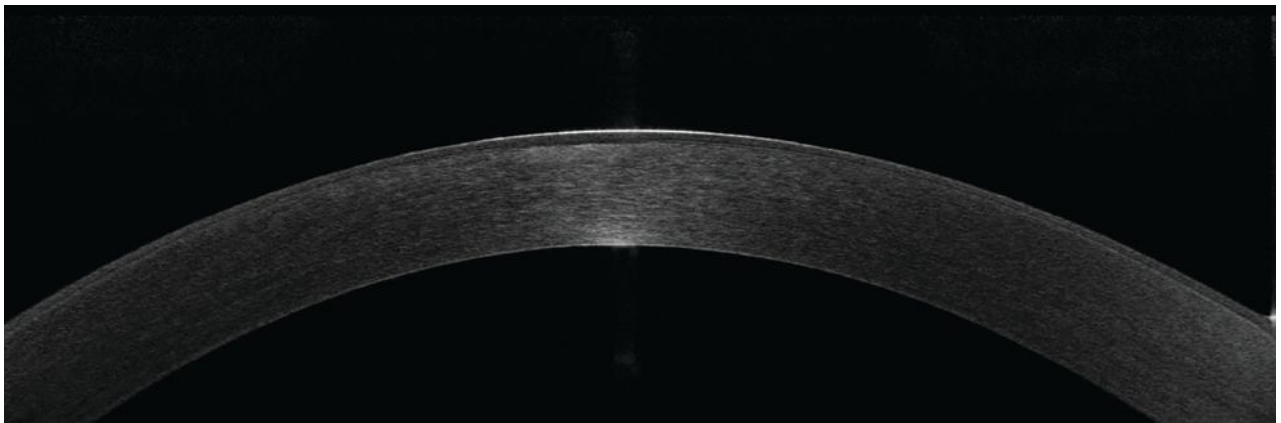
is subjective improvement, it is worth optimizing the ocular surface with a PTK first. Not only will this smooth the surface to aid in IOL calculations, but patients may see enough of an improvement to defer cataract surgery.

PTK should also be considered if a patient is motivated to be more independent from glasses. For these individuals, a premium diffractive multifocal IOL is a great option. However, any retinal or corneal pathologies can limit their candidacy. To avoid missing subtle epithelial changes, make sure to lift your patients’ lids up while behind the slit lamp. Sodium fluorescein staining can additionally help highlight areas of negative staining in EBMD.

Once a PTK is performed, patients will wait a minimum of three months before repeating measurements and proceeding with cataract surgery. This provides the cornea enough time to heal, and our patients have been successful with this implemented timeline. It is often a longer journey, but a patient’s visual outcome can improve from 20/25 to 20/30 down to 20/20.

While a patient with superficial corneal irregularities can elect to have cataract surgery first, it is important to consider and recommend

Fig 6. Anterior segment OCT reveals a subtle stromal haze centrally. The overlying scar is not well depicted. Due to the location of this opacity lying within the anterior third of the cornea, it would respond well to PTK.



PTK: THE ROLE IT PLAYS TODAY

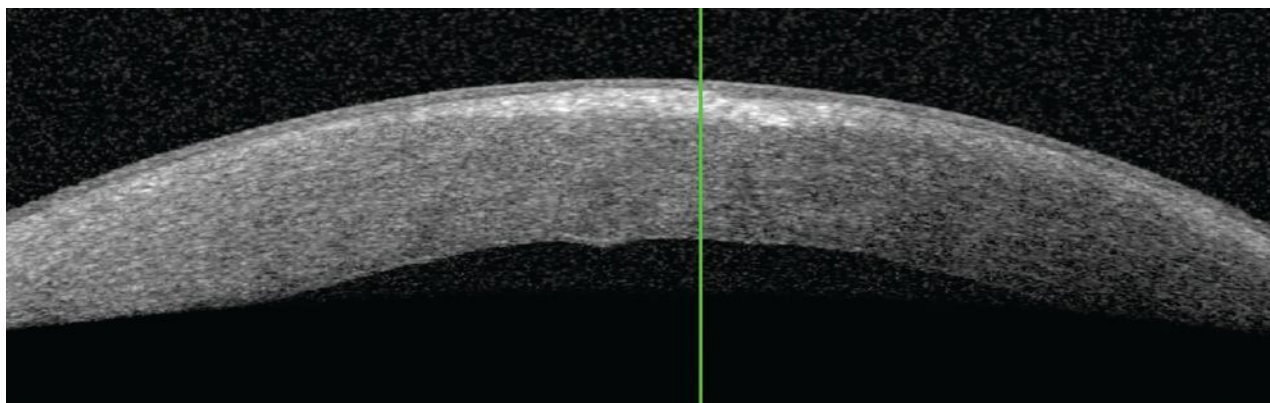


Fig. 7. Anterior segment OCT of the left cornea with visually significant stromal haze.

PTK if an RGP over-refraction subjectively improves vision. PTK is a powerful tool and option for patients motivated to improve their visual outcome. At the cataract evaluation, it is important to manage patient expectations and help them understand that while this may be a long journey, it will ultimately improve the patient's success in IOLs.

CASE B. REPEAT PTK ON STROMAL HAZE

An 84-year-old female presented to our clinic with complaints of

“viewing through a haze” in the left eye (Fig. 7). The patient had a history of a DMEK OS and a corneal abrasion OS that left a central scar, which had previously been treated with PTK in 2016 (Fig. 8).

At this visit, an RGP over-refraction improved her vision OS from 20/30 to 20/20. The source of her visual complaints was determined to be primarily from her stromal haze. Due to her motivation and subjective improvement noted, she elected to proceed with a repeat PTK OS.

CONCLUSION

Phototherapeutic keratectomy is a versatile procedure with an excellent risk/benefit ratio. Many anterior corneal pathologies can respond well to the excimer laser. This procedure can reduce the rate of recurrences and potentially prevent a patient from undergoing a corneal transplant.

If a reduced image quality is partially due to a form of corneal involvement amenable to excimer laser treatment, PTK should be considered first for your patients and prior to cataract surgery to optimize IOL calculations. **RCCL**

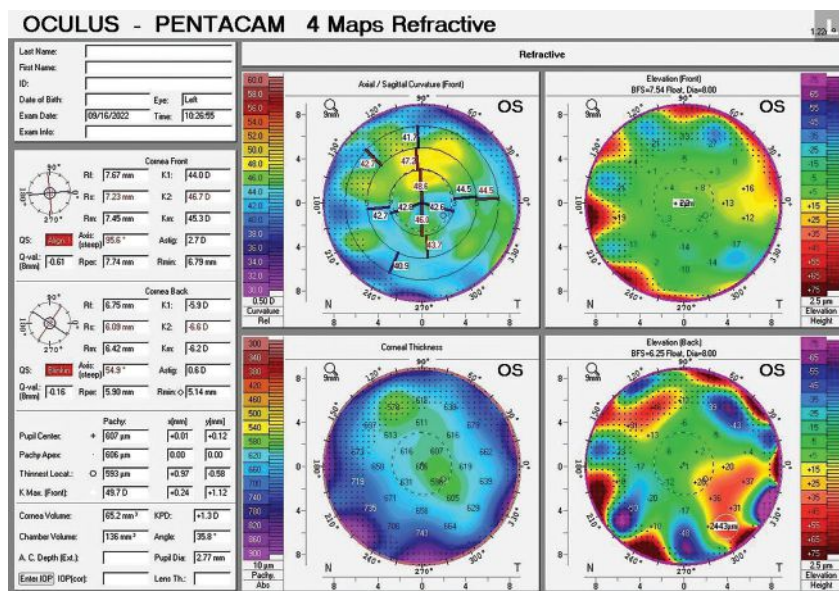


Fig. 8. Pentacam of this patient with a history of a DMEK who presented with stromal haze. Axial curvature highlights the irregularity on the anterior cornea.

- Dinh R, Rapuano CJ, Cohen EJ, Laibson PR. Recurrence of corneal dystrophy after excimer laser phototherapeutic keratectomy. *Ophthalmol.* 1999;106(8):1490-7.
- Keane M, Coffey N, Jones V, et al. The Australian corneal graft registry: 2021/22 report. *Flinders Univ.* 2022.
- Baryla J, Pan YI, Hodge WG. Long-term efficacy of phototherapeutic keratectomy on recurrent corneal erosion syndrome. *Cornea.* 2006;25(10):1150-2.
- Cavanaugh TB, Lind DM, Cutarelli PE, et al. Phototherapeutic keratectomy for recurrent erosion syndrome in anterior basement membrane dystrophy. *Ophthalmol.* 1999;106(5):971-6.
- Spaeth GL, Danesh-Meyer H, Goldberg I, Kampik A. *Ophthalmic surgeries principles and practice* (4th ed.). Elsevier-Saunders. 2012.
- Waring GO 3rd, Rodrigues MM, Laibson PR. Corneal dystrophies. I. Dystrophies of the epithelium, Bowman's layer and stroma. *Surv Ophthalmol.* 1978;23(2):71-122.
- Miller DD, Hasan SA, Simmons N, Stewart MW. Recurrent corneal erosion: A comprehensive review. *Clin Ophthalmol.* 2019;13:325-35.

Study Highlights Role of Emotional Readiness for Cataract Surgery

By Amy Hellem, MLA; Sara LaBelle, PhD; Cynthia Matossian MD, FACS; and Paul Karpecki, OD, FAAO

From the patient's perspective, learning about cataracts and preparing for and undergoing surgery is an emotional journey as much as it is a physical one. With that in mind, it's vital that the cataract care team offer support that promotes comprehensive wellbeing.

As new research indicates, helping patients participate in their care early in the cataract journey can help ensure that they receive timely surgery under improved conditions. Specifically, research shows that when patients are afraid of surgery, they avoid having cataract surgery for as long as possible, enduring poor acuity that could lead to other potential dangers, including falls. However, this same research shows that most patients are willing to engage in a daily ocular surface hygiene routine in the weeks leading up to surgery. This activity gives patients agency as they emotionally adjust to their need for surgery. In addition, by minimizing apprehension, patients may be better prepared to make important decisions about premium surgical options, such as presbyopia and astigmatism correction.

STUDY DETAILS

This noninterventional, cross-sectional investigation of 278 U.S. adults age 65 and older sought to identify cataract surgery candidates' knowledge, beliefs, desires and emotions as well as their behavioral intent to adhere to their doctors' pre-surgical recommendations.¹ In this mixed methods study, two key variables of interest—fear and uncertainty—were measured both quantitatively and qualitatively, providing specific insights into how patients feel so that researchers could extrapolate best practices for mitigating these undesirable emotions.

Specifically, the report, which was recently published in *Clinical Ophthalmology* found that fear is the predominant emotion in one out of every three study participants. Importantly, there is also a notable correlation ($r = .44$) between fear and intention to delay having surgery for as long as possible. This is potentially troublesome when an ECP tells a patient that they are developing cataracts and that patient silently worries and reacts by putting off future visits until their vision becomes unmanageable. The authors strongly recommend prescribing a pre-surgical prep-kit as a way to combat fear and uncertainty while giving the patient greater agency and autonomy, in effect preparing them both emotionally and physically at a time when they might otherwise avoid proper care and delay surgery.

PATIENT PREFERENCE

There's a common misconception that patients are in a big hurry to have cataract surgery, but this research modifies such reasoning. Specifically, patients who have yet to present for their consult are more likely to be avoiding care. Only 20% of participants in the study said they wanted to have cataract surgery at all and only 8% said they wanted to have cataract surgery as soon as possible.

A second misconception addressed in the study is that cataract surgery candidates are unwilling to participate in a pre-operative prep routine. However, 87% of participants in the study say they would use a pre-surgical prep kit if their doctor gave them one and 83% said they would use a pre-surgical prep kit if they were asked to buy one.

87% of participants in the study say they would use a pre-surgical prep kit if their doctor gave them one.

83% said they would use a pre-surgical prep kit if they were asked to buy one.

IMPLICATIONS

The benefits of a healthy ocular surface prior to cataract surgery are well established, but this is the first study to inquire about the potential emotional benefits of pre-surgical prep. To that end, the authors are initiating future studies to investigate the clinical and emotional outcomes of prep, as well as the impact that initiating a prep routine may have on patient apprehension and intraocular lens selection. Participants will use a moist heat eye compress, lid wipes, and hypochlorous acid solution in the weeks leading up to surgery. As each of these have been shown to improve ocular surface health and limit bacteria, surgeons can offer these conveniently now. Bruder Healthcare makes this easy with its all-in-one prep package that you can recommend to patients in advance of their surgical consultation appointment.



LEARN MORE

¹Clin Ophthalmol. 2022; 16:1003-1008. <https://doi.org/10.2147/OPH.S356895>

©2022 Bruder Healthcare Company Alpharetta, GA 30004

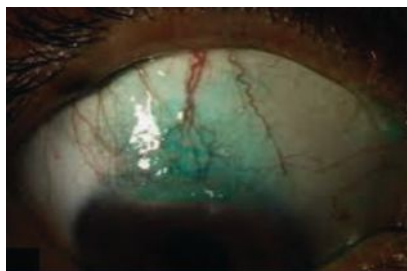
Optimizing the *Ocular Surface*

Learn how to properly treat DED prior to surgery to get the best postoperative outcomes.

By Pam Theriot, OD

Since their first arrival on the market in 1997, presbyopia-correcting intraocular lenses (IOLs) have had our patients demanding more from their cataract surgeries.¹ The greatest causes of dissatisfaction after presbyopia-correcting IOL implantation are residual refractive error and dry eye, both of which can be corrected by identifying and treating the eye before the surgery.² Treating dry eye disease (DED) will stabilize the tear film, capture more accurate measurements and reduce residual refractive error.³

Researchers on behalf of the Prospective Health Assessment of Cataract Patients' Ocular Surface (PHACO) study group found the incidence of dry eye in patients scheduled to undergo cataract surgery in a real-world setting is



Pictured here is a 3+ lissamine green stain on conjunctiva from dry eye.

higher than anticipated.⁴ And, in a 2017 study, it was found that when DED was tested for, more than half of patients were diagnosed with definite or probable DED before cataract surgery.⁵ Dry eye is common and can be exacerbated by cataract surgery.

Eyecare practitioners should assess for pre-existing DED and initiate treatment before surgery.⁶ A healthy tear film is prerequisite for optimal visual performance, especially in patients receiving multifocal IOLs.⁷ Any ocular surface disease (OSD), including DED, can reduce visual acuity and adversely affect refractive measurements before ocular surgeries.⁸

DOES CATARACT SURGERY CAUSE DRY EYE DISEASE?

Cataract surgery has been reported in the literature to induce dry eye and to exacerbate pre-existing dry eye.⁹ Both ophthalmologists and the referring optometrist need to assess for pre-existing DED.⁶ Several factors during ocular surgery can have a profound effect on exacerbating or initiating OSD.

The detrimental effects of cataract surgery on the ocular surface can both directly cause and exacer-

bate pre-existing DED.¹⁰ There are multiple mechanisms resulting in exacerbation of surface disease after cataract surgery.¹¹ These factors include:

- The corneal incision causes decreased sensation over the incision width extending in a wedge-shaped sector.¹² This sensory loss may take months to return to normal and is likely to upset tear film homeostasis while compromised.¹³ The incision itself can potentially cut through the nerves responsible for innervating the corneal surface and, by doing so, may delay the epithelial wound healing.¹⁴ Effects on the cornea caused by cataract surgery which can lead to dry eye are greater in eyes that already have symptoms of DED.¹⁵

ABOUT THE AUTHOR



Dr. Theriot practices at a multi-specialty eye clinic in Shreveport, LA. Her clinical practice covers a broad spectrum of ocular care with a unique clinical focus on ocular surface disease and dry eye. She received her doctorate in optometry from the University of California at Berkeley, School of Optometry, and completed her residency at the State University of New York, College of Optometry. She is a consultant for Novartis and key opinion leader for Sun Pharmaceuticals and Kala Pharmaceuticals.

CLINICAL EXAM: LLPP TECHNIQUE			
LOOK	LIFT	PULL	PUSH
Blink, lids, lashes, interpalpebral surface	Upper lid, examine superior surface	Assess lid laxity 'floppy eyelids', fornices	Meibomian gland expression
STAIN (dye instillation): corneal straining? TBUT? +/- Schirmer's			

An algorithm developed by the ASCRS to assess the ocular surface prior to cataract surgery. This can help guide optometrists in knowing when to refer patients to an ophthalmologist.

- Meibomian gland function may be altered without accompanying structural changes after cataract surgery.⁹ Lid margin abnormalities were found at three months post cataract surgery.¹⁶
 - Increased inflammation due release of postoperative inflammatory mediators.¹¹
 - Photokeratitis due to light from the operating microscope during surgery.¹¹ Such exposure can also be a contributing factor to the patient's dry eye syndrome.¹⁷ Excessive light exposure during ophthalmic procedures could be a pathogenic factor in dry eye syndrome after a surgery is performed.¹⁸
 - Chemical toxicity from preservatives such as benzalkonium chloride (BAK) used in postoperative eye drops. BAK can cause tear film instability and reduce the number of mucin-expressing cells.^{11,19}

THE OD'S ROLE IN SURGERY

We now know that cataract surgery alone can induce and worsen OSD.⁹ Having pre-existing DED will be reduced accuracy of measurements for surgical planning.⁶ Studies have shown that dry eye symptoms, such as blurred vision, are sometimes erroneously attributed to the cataract. This may contribute to the higher postoperative incidence of DED diagnosis.²⁰

Precise topography and biometric measurements are prereq-

uisites for postoperative visual performance.²¹ These measurements require a healthy and stable precorneal tear film, as it is the first refractive component of the eye.²²

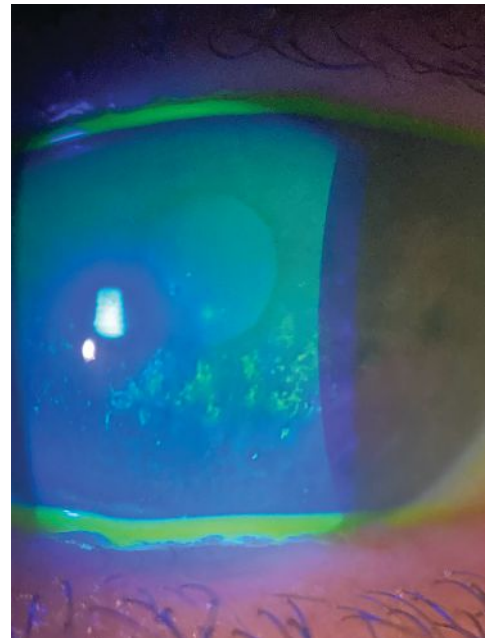
The American Society of Cataract and Refractive Surgery (ASCRS) developed an algorithm to assess the ocular surface prior to surgery.⁸ The first step is biometry measurements. If you are not working alongside a surgeon, you may not have access to the equipment needed for this step. However, the algorithm can still be used to guide optometrists when to refer to an ophthalmologist for surgery.

You could use the testing protocol developed by investigators in the PHACO study. Here, researchers sought to identify DED prior to cataract surgery. They used a simple battery of tests that can be performed without needing expensive devices, including tear break-up time (TBUT), fluorescein stain, lissamine green stain, Schirmer's test and the Ocular Symptom Disease Index (OSDI).²³

Ideally, the measurement scales used to identify clinical change in the patients should track progression of disease.²⁴ Use corneal staining to track the progress of treatment. Fluorescein stain

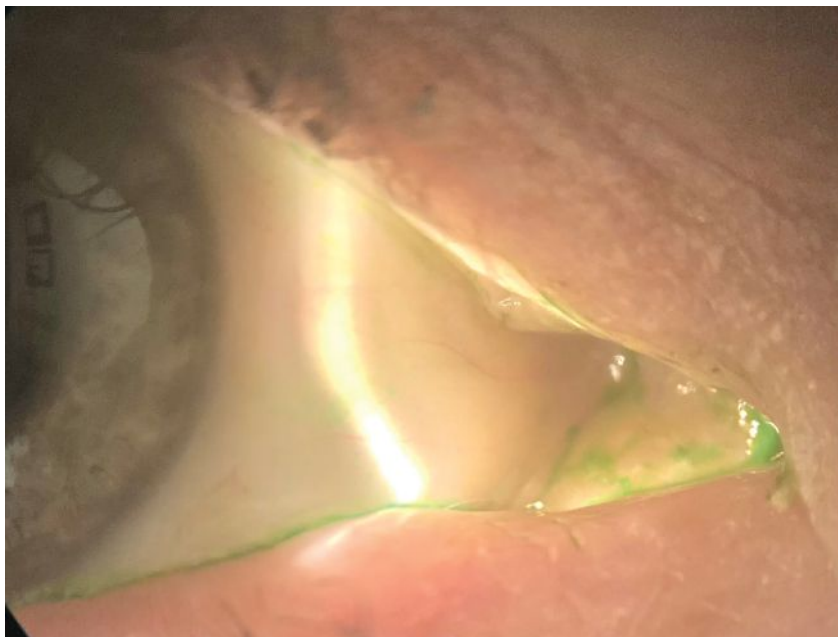
is used to elucidate corneal punctate staining, as it shows small area of pooled dye in a space where the cell surface is disrupted or completely missing.²⁵ Lissamine green dye, on the other hand, penetrates membrane damaged conjunctival cells to stain the nucleus.²⁵

If your clinic does not have any additional testing devices, you can still perform testing based on both the ASCRS Algorithm and the PHACO study. In both studies, a screening survey (OSDI or SPEED) and a slit lamp examination that include fluorescein and lissamine green stain, TBUT and Schirmer's are recommended.



Pictured here is a 2+ fluorescein stain.

OPTIMIZING THE OCULAR SURFACE



Another lissamine green stain seen on a patient.

Treat the eyes based on the subtype and severity of the OSD and have the patient return in two to four weeks and repeat the exam. Only when OSD is ruled out during a normal exam without signs, symptoms or staining, should IOL calculation and surgery proceed.⁸

TREAT OSD BEFORE REFERRING FOR SURGERY

Let's examine the most common OSDs and how to treat them effectively to prepare the patient for surgery.

- **DED.** The PHACO study found almost 60% of patients undergoing screening for routine cataract surgery showed signs of DED, including a reduced TBUT and central corneal staining with fluorescein dye.²³

Preoperative use of artificial tear therapy alone has not been shown to prevent DED postoperatively.⁶ However, patients who used liftegrast 5% (Xiidra, Novartis) BID for four weeks preoperatively showed improvements in higher-order aberrations, accuracy of pre-operative

biometry, symptom scores (SPEED), TBUTs and corneal fluorescein staining.²⁶

Another randomized clinical trial (RCT) showed use of Cequa (cyclosporine 0.09%, Sun Pharmaceuticals) BID for 28 days gave significant improvement in the prediction error of the spherical equivalent outcome of surgery.²⁷

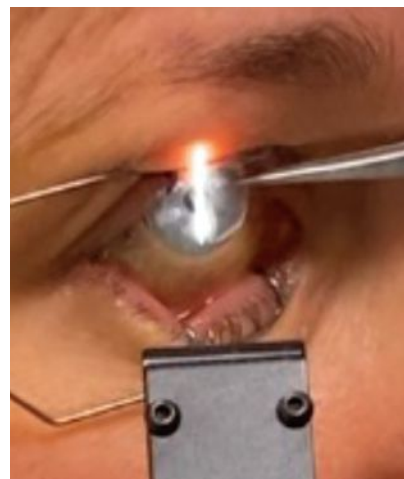Cryopreserved amniotic membrane (CAM) is useful in treating DED, as its short-term efficacy is attributed to its potent anti-inflammatory effect.²⁸ DED treatment with CAM also increases corneal nerve density, which correlates to increased corneal sensitivity and reduced dry eye symptoms.²⁹

The results of the retrospective DREAM (Dry Eye Amniotic Membrane) study demonstrated that CAM treatment can accelerate the recovery of corneal surface in patients with moderate and severe DED. The DREAM study used CAM for three to seven days and showed significant improvement of both DED signs (corneal staining) and symptoms (ocular discomfort

score).³⁰ Optimal duration of CAM placement was five days to achieve an average symptom-free duration of four months in patients with DED.²⁸ The expediency of this treatment in stabilizing the ocular surface makes it an excellent treatment prior to cataract surgery.

- **Epithelial basement membrane dystrophy (EBMD) and recurrent corneal erosion (RCE).** Ocular surface disease encompasses a broad variety of conditions, including EBMD, RCE, Salzmann's nodular degeneration (SND), ocular allergy and conjunctivochalasis, and they all share inflammation as the common underlying etiology.³¹ EBMD, also known as map-dot-fingerprint dystrophy, is the most common corneal dystrophy.³² It affects over 2% of the population worldwide.³³

Long-standing inflammation and elevation of key matrix-metalloproteases and cytokines associated with DED may ultimately lead to disorganization of the basement membrane seen in EBMD and SND.³⁴ CAM is known to contain potent anti-inflammatory mediators and growth factors, as well as potent anti-fibrotic, anti-angiogenic, pro-healing effects important in promoting regenerative healing.³⁵



A patient undergoing epithelial debridement.

Meibomian gland dysfunction (MGD). This may be altered even without structural changes of the gland after cataract surgery.⁹ Preoperative at-home management of MGD should include warm compressors, lid hygiene and anti-inflammatory treatment.³⁶ The anti-inflammatory and antimicrobial effects of treatment of MGD oral tetracycline antibiotics and topical azithromycin may reduce bacterial proliferation and improve meibum secretion.¹⁶

In addition to at-home therapy, studies have shown that thermal pulsation treatment prior to cataract surgery is also beneficial to postoperative outcomes. Thermal pulsation treatments such as LipiFlow (TearScience, Johnson & Johnson) showed significant improvement in meibomian gland patency, meibum quality, increased TBUT and reduced corneal staining, as well as symptoms reported

Options to treat dry eye may include:			
Drug	Brand Name	Dosing	Preservative-free
Loteprednol 0.5% Ophthalmic ung	Lotemax Ointment	TID	Yes
Ketorolac 0.45%	Acuvail	TID	Yes
Bromfenac 0.07% solution	Prolensa	QDay	No
Bromfenac 0.075% solution	BromSite	QDay	No
Bromfenac 0.09% solution	BromDay	QDay	No

on the OSDI. In fact, even patients without preoperative MGD who were treated with thermal pulsation showed less worsening or improvement of MGD and DED induced by surgery.³⁷

In a separate RCT, TearCare (Sight Sciences) was shown to be equally effective to LipiFlow in significantly reducing the signs and symptoms of DED in patients with MGD prior to cataract surgery.³⁸

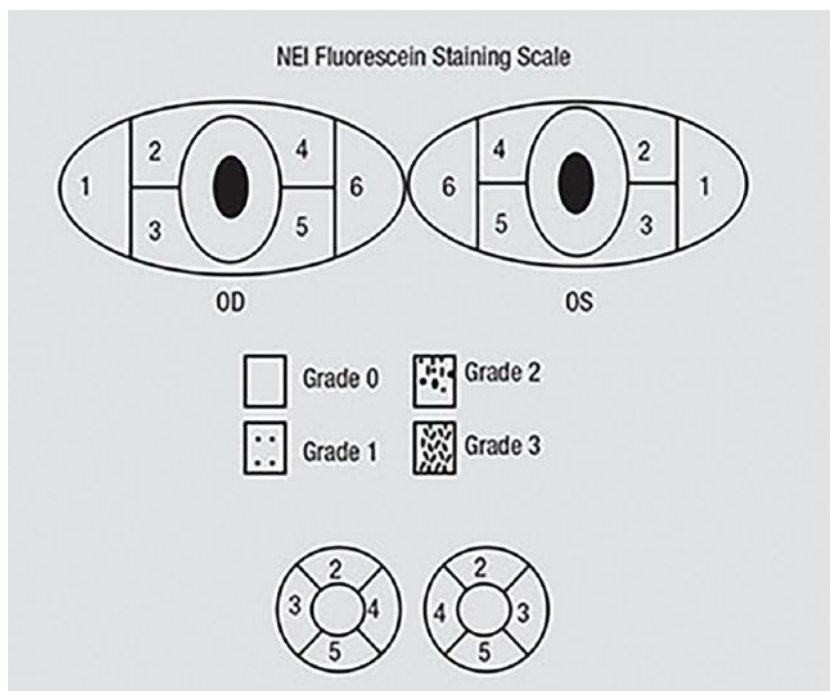
TREATING DED AFTER CATARACT SURGERY

Even with the ocular surface evaluation performed preoperatively, the incidence of dry eye after phacoemulsification has been reported to be 9.8%.⁴¹ The use of eye drops during and after surgery, because of the harmful effects of preservatives, may lead to injury to corneal epithelial and conjunctival epithelial and goblet cells.¹¹

Following routine cataract surgery, patients are typically given treatment regimens of topical steroid, nonsteroidal anti-inflammatory and antibiotic drops as part of standard care.⁴² Such topical medications usually contain preservatives. Both laboratory and clinical studies have demonstrated the toxic properties of eye drop preservatives on the ocular surface.⁴³

Opting for alternative delivery methods of the necessary post-op medications is a great way to mitigate the effects of BAK preserved drops on the ocular surface. Clinical signs associated with the use of BAK-preserved drops include superficial punctate keratitis, conjunctival hyperemia, staining and follicles, increased osmolarity, decrease in tear production and a reduction in TBUT.⁴⁴

An RCT of 80 patients supported the use of preservative-free drops after cataract surgery to minimize



The NEI scale for grading fluorescein staining divides the corneal and conjunctival surfaces to help measure fluorescein uptake. A standardized grading system of 0 to 3 is used for each of the five areas on each cornea. Grade 0 is specified when no staining is present.

OPTIMIZING THE OCULAR SURFACE

DED.⁴⁵ Switching to a preservative-free formulation removes the potential harmful effects of introducing a preservative to the ocular surface.¹⁷

Reducing the dosing of postoperative drops is another way to protect the ocular surface. Bromfenac 0.075% (BromSite) outcomes from dosing BID were equivalent to the outcomes from dosing with 0.075% bromfenac QD in an uncomplicated postoperative cataract surgery.⁴

Alternatively, “dropless cataract surgery” is a great way to eliminate or reduce the burden of topical medications. It involves intravitreal injection of a single-use, compounded combination of antibiotics and corticosteroids.³⁹

The side effects of postoperative drop use can also be minimized using intracameral antibiotics and

sub-Tenon’s injection of steroids. Intracameral use of antibiotics during surgery is a safe and effective method to prevent post-cataract endophthalmitis.⁴⁶ This in conjunction with a single sub-Tenon’s intracameral triamcinolone to control inflammation following cataract surgery will reduce postoperative drop burden.⁴⁷

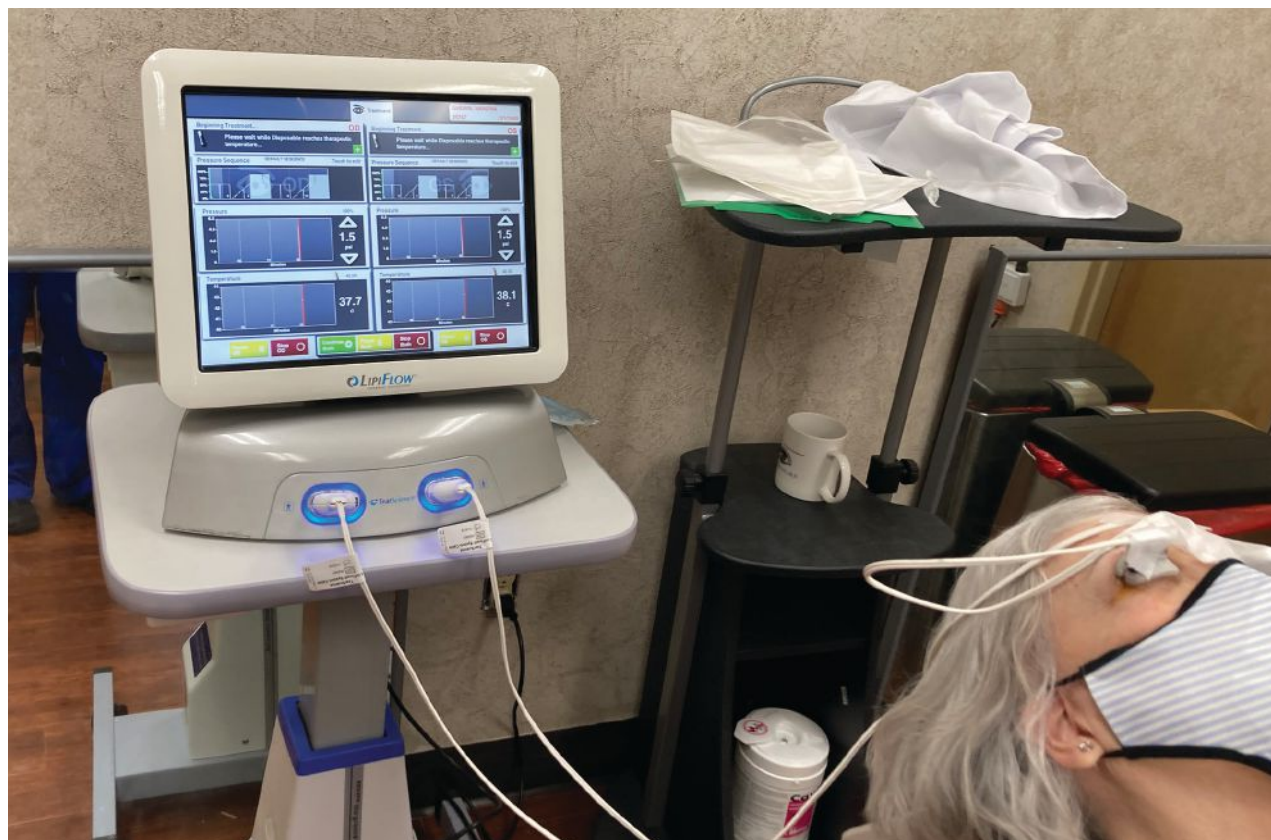Even with the best preoperative screening and postoperative care, some patients will still experience new or exacerbated symptoms of DED. Postoperative management of DED is crucial in ensuring that tear film homeostasis is preserved as much as possible and to avoid long-term adverse effects of the ocular surface.⁶

Two clinical trials have shown that using cyclosporine 0.05% drops to optimize tear film function

after cataract surgery may have protective effects on the ocular surface after cataract surgery.^{48,49} A separate RCT indicated that receiving omega-3 supplements (1000mg TID PO for one month after cataract surgery) had better symptoms (OSDI scores) and signs (higher TBUTs) than patients who did not take omega-3s.⁵⁰

TAKEAWAYS

Dry eye disease can have a negative impact on the mental well-being of a patient. A systematic review demonstrated that patients with DED have higher rates of anxiety and depression compared to controls.⁵¹ DED also carries a high economic burden at an estimated annual cost of treating a single dry eye patient in the United States to be \$11,302.⁵²



LipiFlow treatment has shown improvement in meibomian gland patency, meibum quality, increased TBUT and reduced corneal staining prior to cataract surgery.

Ocular surgery can exacerbate or induce OSD, leading to worsened vision, increased symptoms and overall dissatisfaction.⁸ Preoperative screening and assessment for DED is essential to ensure that patients receive appropriate treatment prior to surgery. This will also ensure that accurate biometry measurements are obtained for surgical planning.⁶ Treating OSD preoperatively will ensure postoperative visual outcomes and patient satisfaction can be significantly improved.⁸ [nccl](#)

1. Hiraoka T, Asano H, Ogami T, et al. Influence of dry eye disease on the measurement repeatability of corneal curvature radius and axial length in patients with cataract. *J Clin Med.* 2022;11(3):710.
2. Gibbons A, Ali T, Waren D, Donaldson K. Causes and correction of dissatisfaction after implantation of presbyopia-correcting intraocular lenses. *Clin Ophthalmol.* 2016;10:1965-70.
3. Matossian C. Impact of thermal pulsation treatment on astigmatism management and outcomes in meibomian gland dysfunction patients undergoing cataract surgery. *Clin Ophthalmol.* 2020;14:2283-9.
4. Trattler W, Hosseini K. Twice-daily vs. once-daily dosing with 0.075% Bromfenac in DuraSite: outcomes from a 14-day phase II study. *Ophthalmol Ther.* 2017;6(2):277-84.
5. Miyake K, Yokoi N. Influence on ocular surface after cataract surgery and effect of topical difluprost on postoperative dry eye: a multicenter prospective randomized study. *Clin Ophthalmol.* 2017;11:529-40.
6. Naderi K, Gormley J, O'Brart D. Cataract surgery and dry eye disease: a review. *Eur J Ophthalmol.* 2020;5(5):840-55.
7. Woodward MA, Randleman JB, Stulting RD. Dissatisfaction after multifocal intraocular lens implantation. *J Cataract Refract Surg.* 2009;35:992-7.
8. Starr CE, Gupta PK, Farid M, et al. An algorithm for the preoperative diagnosis and treatment of ocular surface disorders. *J Cataract Refract Surg.* 2019;45(5):669-84.
9. Han KE, Yoon SC, Ahm JM, et al. Evaluation of dry eye and meibomian gland dysfunction after cataract patient (PHACO) study: the effect of dry eye. *Clin Ophthalmol.* 2017;11:1423-30.
10. Ishrat S, Nema N, Chandravanshi SCL. Incidence and pattern of dry eye after cataract surgery. *Saudi J Ophthalmol.* 2019;33(1):34-40.
11. Li XM, Hu L, Hu J, Wang W. Investigation of dry eye disease and analysis of the pathogenic factors in patients after cataract surgery. *Cornea.* 2007;26(9 Suppl 1):S16-20.
12. John T. Corneal sensation after small incision, sutureless, one-handed phacoemulsification. *J Cataract Refract Surg.* 21(4):425-8.
13. Lyne A. Corneal sensitivity after surgery. *Trans Ophthalmol Soc U K* 1982; 102(pt. 2):302-5.
14. Chester T. Treat the front before the cut. *Rev Optom.* 2020.
15. Ram J, Gupta A, Brar G, Kaushik S, Gupta A. Outcomes of phacoemulsification in patients with dry eye. *J Cataract Refract Surg.* 2002;28(8):1386-9.
16. Baudouin C, Messmer EM, Aragona P, et al. Revisiting the vicious circle of dry eye disease: a focus on the pathophysiology of meibomian gland dysfunction. *Br J Ophthalmol.* 2016;100:300-6.
17. Sutu C, Fukuoka H, Afshari N. Mechanisms and management of dry eye in cataract surgery patients. *Curr Opin Ophthalmol.* 2016;27:24-30.
18. Hwang, Hyung & Kim, Hyun. (2014). Phototoxic Effects of an Operating Microscope on the Ocular Surface and Tear Film. *Cornea.* 33:82-90.
19. Wilson WS, Duncan AJ, Jay JL. Effect of benzalkonium chloride on the stability of the precorneal tear film in rabbit and man. *Br J Ophthalmol.* 1975;59(11):667-9.
20. Lemp MA, Crews LA, Bron AJ, et al. Distribution of aqueous-deficient and evaporative dry eye in a clinic-based patient cohort: a retrospective study. *Cornea.* 2012;31(5):472-8.
21. Koh S. Irregular astigmatism and higher-order aberrations in eyes with dry eye disease. *Invest Ophthalmol Vis Sci.* 2018;59(14):DES36-40.
22. Koh S, Tung C, Inoue Y, et al. Effects of tear film dynamics on quality of vision. *Br J Ophthalmol.* 2018;102(12):1615-20.
23. Trattler W, Majmudar P, Donnenfeld E, et al. The prospective health assessment of cataract patient (PHACO) study: the effect of dry eye. *Clin Ophthalmol.* 2017;11:1423-30.
24. Abelson M, Smith L, Hollander D, Usner D. How do you quantify the qualitative? *Rev Ophthalmol.* 2016;5(8).
25. Bron AJ, Argueso P, Irkec M, Bright FV. Clinical staining of the ocular surface: mechanisms and interpretations. *Prog Retin Eye Res.* 2015;44:36-61.
26. Hovanesian J, Epitropoulos A, Donnenfeld ED, Holladay JT. The effect of Liftegrast on refractive accuracy and symptoms in dry eye patients undergoing cataract surgery. *Clin Ophthalmol.* 2020;14:2709-16.
27. Hovanesian JA, Epitropoulos A, Holladay JT. Effect of Cyclosporine 0.09% treatment on accuracy of preoperative biometry and higher order aberrations in dry eye patients undergoing cataract surgery. *Clin Ophthalmol.* 2021;15:3679-86.
28. Cheng AM, Zhao D, Chen R, et al. Accelerated restoration of ocular surface health in dry eye disease by self-retained cryopreserved amniotic membrane. *Ocul Surf.* 2016;14:56-63.
29. John T, Tighe S, Sheha H, et al. Corneal nerve regeneration after self-retained amniotic membrane in dry eye disease. *J Ophthalmol.* 2017;6404918.
30. McDonald MB, Sheha H, Tighe S, et al. Treatment outcomes in the Dry Eye Amniotic Membrane (DREAM) study. *Clin Ophthalmol.* 2018;12:677-81.
31. Acera A, Rocha G, Vecino E, et al. Inflammatory markers in the tears of patients with ocular surface disease. *Ophthalmic Res.* 2008 Oct;40(6):315-21.
32. He J, Bazan HE. Corneal nerve architecture in a donor with unilateral epithelial basement membrane dystrophy. *Ophthalmic Res.* 2013;49(4):185-91.
33. Lee WS, Lam CK, Manche EE. Phototherapeutic keratectomy for epithelial basement membrane dystrophy. *Clin Ophthalmol.* 2017;11:15-22.
34. Miller DD, Hasan SA, Simmons NL, Stewart MW. Recurrent corneal erosion: a comprehensive review. *Clin Ophthalmol.* 2019;13:325-35.
35. Huang Y, Sheha H, Tseng SCG. Self-retained amniotic membrane for recurrent corneal erosion. *J Clin Exp Ophthalmol.* 2013;4:272-6.
36. Song P, Sun Z, Ren S, et al. Preoperative management of MGD alleviates the aggravation of MGD and dry eye induced by cataract surgery: a prospective, randomized clinical trial. *Biomed Res Int* 2019;2019:2737968.
37. Park J, Yoo YS, Shin K, et al. Effects of Lipiflow treatment prior to cataract surgery: a prospective, randomized, controlled Study. *Am J Ophthalmol.* 2021;230:264-75.
38. Gupta PK, Holland EJ, Hovanesian J, et al. TearCare for the treatment of meibomian gland dysfunction in adult patients with dry eye disease: a masked randomized controlled trial. *Cornea.* 2022;41(4):417-26.
39. Lindstrom RL, Galloway MS, Grzybowski A, Liegner JT. Dropless cataract surgery: an overview. *Curr Pharm Des.* 2017;23(4):558-64.
40. Zhang Z, Thomas LW, Leu SY, et al. Refractive outcomes of intraoperative wavefront aberrometry versus optical biometry alone for intraocular lens power calculation. *Indian J Ophthalmol.* 2017;65(9):813-7.
41. Kasetsuwan N, Satitpitakul V, Changul T, Jariyakosol S. Incidence and pattern of dry eye after cataract surgery. *PLoS One.* 2013;8(11):e78657.
42. Solomon KD, Sandoval HP, Potvin R. Comparing combination drop therapy to a standard drop regimen surgery: a prospective, randomized, controlled study. *Am J Ophthalmol.* 2021;230:264-75.
43. Epstein SP, Ahdoot M, Marcus E, Asbell PA. Comparative toxicity of preservatives on immortalized corneal and conjunctival epithelial cells. *J Ocul Pharmacol Ther.* 2009;25(2):113-9.
44. Walsh K, Jones L. The use of preservatives in dry eye drops. *Clin Ophthalmol.* 2019;13:1409-25.
45. Jee D, Park M, Lee HJ, et al. Comparison of treatment with preservative-free versus preserved sodium hyaluronate 0.1% and fluorometholone 0.1% eyedrops after cataract surgery in patients with preexisting dry-eye syndrome. *J Cataract Refract Surg* 2015;41:756-76.
46. Titiyal, Jeewan S; Kaur, Manpreet. Role of intracameral antibiotics in endophthalmitis prophylaxis following cataract surgery. *Ind J Ophthalmol.* 2020;68(5):688-91.
47. Kim SY, Yang J, Lee YC, Park YH. Effect of a single intraoperative sub-Tenon injection of triamcinolone acetonide on the progression of diabetic retinopathy and visual outcomes after cataract surgery. *J Cataract Refract Surg.* 2008;34(5):823-6.
48. Donnenfeld ED, Solomon R, Roberts CW, et al. Cyclosporine 0.05% to improve visual outcomes after multifocal intraocular lens implantation. *J Cataract Refract Surg.* 2010;36:1095-100.
49. Ganesh S, Brar S, Bagare SN. Topical cyclosporine (0.05%) for management of dry eyes in patients undergoing cataract surgery—a comparative study. *Open Ophthalmol J.* 2019;13(1):3442.
50. Mohammadpour M, Mehrabi S, Hassanpoor N, et al. Effects of adjuvant omega-3 fatty acid supplementation on dry eye syndrome following cataract surgery: a randomized clinical trial. *J Current Ophthalmol.* 2017;29(1):33-8.
51. Wan KH, Chen LJ, Young AL. Depression and anxiety in dry eye disease: a systematic review and meta-analysis. *Eye.* 2016;30(12): 1558-67.
52. Yu J, Asche CV, Fairchild CJ. The economic burden of dry eye disease in the United States: a decision tree analysis. *Cornea.* 2011;30:379-87.

Tackling Corneal Transplants in Clinical Practice

A comprehensive understanding of these procedures is critical to ensure optimal patient care and outcomes.

By Aaron Bronner, OD

Corneal transplants are the oldest and most successful solid tissue transplants in medicine.¹ Despite the frequency with which these are performed, many ODs feel daunted when encountering a transplant in the clinic, especially if there is a concern with the health of the graft. This discomfort may be due to a lack of clear didactic education on transplant science, the relatively high risk of complications and the wide array of transplant procedures available.

Developing a solid grasp of transplants starts with looking at the overarching themes that govern the behavior of all transplants and then applying those rules to the specific transplant you are dealing with. First, a deep understanding of the immunology of transplants, specifically the role the transplant plays in modulating immune responses, is critical.

In a penetrating keratoplasty (PK), the most important layer is the transplanted endothelium. Understanding its importance and influence on graft survival, both in the presence and absence of rejection, is the second key. Finally, understanding the optical and immunologic effects of sutures on the transplant can help you better manage patients in the postoperative phase.

With a solid understanding of these three broader topics, the behavior of all the currently available transplants, as well as any future transplants, can be easily understood. Cutting edge advances in transplantation—for example, decellularized animal tissue as a transplant—are best understood with this background knowledge of corneal graft immunology.

KEY 1: IMMUNOLOGY OF TRANSPLANTS

Understanding how the host immune system responds to the presence of foreign graft material helps predict rejection risk and graft survival. There are several broad types of transplants: xenografts (a transplant from one species to the next), allografts (a transplant from one member of the same species to a different individual) and autografts (a transplant from another location on the patient's own body).

In general, xenografts have extremely high rates of immunologic reaction and aren't used, barring acellular tissue transplants. Allografts, which may be either HLA-matched or unmatched (as is the case with corneal transplants in the United States) from donor to host, carry a risk of rejection that varies with the organ or tissue transplanted. Autografts have no risk of immunologic rejection.

Nearly all corneal transplants are allografts, though the most common limbal transplant, simple limbal epithelial transplant, is an autograft from one eye to the other.

Within an organ or solid tissue transplant, the immune response is only able to identify graft cells (via HLA-antigens) as foreign, and so only transplants containing cells can stimulate a rejection episode. This is why xenografts of animal connective tissue/collagen can be used without risk of rejection.¹ In a full-thickness corneal transplant, the targets of rejection are the epithelium, keratocytes and endothelium.

The epithelium makes up the bulk of the antigenic cellular load; however, epithelial cells are fully replaced by host cells via limbal replenishment (and the limbus falling outside the margins of the graft) within the early months postoperatively.^{2,3} Therefore, the epithelium is only a target of rejection for a short window. The longevity of keratocytes is in question, but they may persist for up to five years (though some estimates are much shorter).

ABOUT THE AUTHOR



Dr. Bronner practices at Pacific Cataract and Laser in Boise, ID. He has no financial interests to disclose.

Keratocytes express little HLA-antigen and are the least antigenic of transplanted corneal cells.^{2,3} The corneal endothelium persists indefinitely, thereby the endothelium always remains a possible target for rejection. Compounding this is the non-miotic nature of the endothelium. Unlike the epithelium or keratocytes, which can be replaced with new host cells if affected by rejection, the donor endothelium affected by an immune response does not regenerate. If a case of endothelial rejection is severe or treatment is delayed, the endothelial pump mechanism can collapse, causing corneal decompensation and edema. As such, endothelial rejection (in grafts containing endothelium) is a primary indication for repeat transplant in these eyes.⁴⁻⁶

Since rejection is a clinical manifestation of the immune system's response to the cells of a transplant, white blood cells (WBCs) will be present within the graft. Vascularization may develop with or without rejection, but graft vascularization alone (though increasing the risk of rejection) is not a strong indication of active rejection.⁷ As there are three different cellular targets for rejection, there are a few different common

ways transplant rejection will manifest.^{8,9}

If epithelial rejection occurs in the short few-week window following a transplant, it will manifest as a gray edematous zone of epithelial tissue across the graft. Ultimately, there will be sloughing of the rejected donor epithelium. The host limbus will then fill in this zone with host epithelium. This is a non-terminal form of rejection, but it does mean the host immune system has acquired a sensitivity to the graft and a more severe form of rejection may subsequently develop.^{8,9}

Rejection involving the keratocytes leads to stromal rejection. Usually, stromal rejection manifests as nummular lesions in the stroma as WBCs cluster around donor keratocytes—similar in appearance to the nummular keratitis seen in herpes zoster ophthalmicus and the somewhat larger and deeper subepithelial infiltrates often seen following adenoviral infection. Occasionally, acute stromal rejection will occur, appearing as sudden and prominent corneal edema without evidence of WBCs. As with

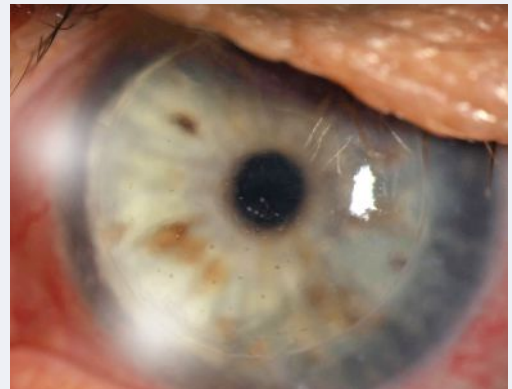

Fig. 1. This PK is suffering from an endothelial rejection. This can be visualized as KP scattered across the endothelium of the graft. The episode was successfully treated, but the patient's graft failed two years later likely as a result of this rejection episode.

epithelial rejection, stromal rejection seldom leads to optical failure of the transplant but may mean a more severe form of rejection could develop.^{8,9}

Endothelial rejection manifests as diffusely distributed keratic precipitates (KP), usually with overlying edema. Occasionally, a linear migratory front of KP known as a Khodadoust line forms. Both forms are typically accompanied by substantial corneal edema. Endothelial rejection may lead to graft failure via immune-mediated collapse of the endothelial pump and subsequent corneal edema (Figure 1).^{8,9}

Release Date: November 15, 2022
Expiration Date: November 15, 2025
Estimated time to complete activity: two hours

Jointly provided by the Postgraduate Institute for Medicine (PIM) and Review Education Group.




Educational Objectives: After completing this activity, the participant should be better able to:

- Recognize the various corneal transplant options.
- Make appropriate referrals for these patients.
- Educate and support their corneal transplant patients.
- Effectively manage corneal transplant patients with ophthalmologists.
- Participate in the postoperative care of corneal transplants.

Target Audience: This activity is intended for optometrists engaged in managing corneal transplant patients.

Accreditation Statement: In support of improving patient care, this activity has been planned and implemented by PIM and the Review Education Group. PIM is jointly accredited by the Accreditation Council for Continuing Medical Education, the Accreditation Council for Pharmacy Education and the American Nurses Credentialing

Center to provide CE for the healthcare team. PIM is accredited by COPE to provide CE to optometrists.

Reviewed by: Salus University, Elkins Park, PA 
Faculty/Editorial Board: Aaron Bronner, OD

Credit Statement: This course is COPE-approved for two hours of CE credit. Activity #124924 and course ID 81513-PO. Check with your local state licensing board to see if this counts toward your CE requirement for relicensure.

Disclosure Statements: PIM requires faculty, planners and others in control of educational content to disclose all their financial relationships with ineligible companies. All identified conflicts of interest are thoroughly vetted and mitigated according to PIM policy. PIM is committed to providing its learners with high-quality, accredited CE activities and related materials that promote improvements or quality in healthcare and not a specific proprietary business interest of an ineligible company.

Those involved reported the following relevant financial relationships with ineligible entities related to the educational content of this CE activity: **Author**—Dr. Bronner has no financial interests to disclose. **Managers and Editorial Staff**—The PIM planners and managers have nothing to disclose. The Review Education Group planners, managers and editorial staff have nothing to disclose.



Primary treatment of any corneal graft rejection consists of topical corticosteroids (start at Q1h dosing initially and observe the response over a week). Oral corticosteroids and periocular injections of steroid and topical compounded immunomodulatory agents (tacrolimus 0.03% and cyclosporine 0.5% to 2.0%) can all be used to supplement, but not replace, topical steroids in severe/high-risk cases.¹⁰⁻¹²

Corneal edema within a transplant is both a frequent manifestation of rejection and the end result of endothelial graft failure (whether due to rejection or exhausted lifespan). Any endothelium-containing transplant with new-onset edema should be presumed to be amidst a rejection episode and thus treated with increased dosing of topical corticosteroids.⁴ Resolution of edema and the ability to visualize KP confirms an endothelial rejection. Resolution of edema without underlying KP would confirm acute stromal rejection. If the edema fails to clear over a few weeks, this would confirm failure of the graft and need for a subsequent transplant.

This brief overview of rejection and graft immunology highlights two key pearls for practitioners. First, grafts containing endothelium carry an indefinite risk for rejection, as donor endothelium is never replaced by host tissue. Second, any rejection of transplanted endothelium can induce graft failure. Thus, grafts containing endothelium need long-term topical steroid therapy to prevent rejection.

KEY 2: INFLUENCE OF ENDOTHELIUM

The transplanted endothelium always limits the lifespan of a corneal graft, even in the absence of rejection. Since the transplanted endothelium carries prolonged potential for graft rejection, endothelial rejection is the only common way rejection leads to graft failure (via collapse of the endothelial pump).

Endothelial cell density reduces as we age, a trend which is accelerated when the endothelium is transplanted. Up to 40% of graft endothelium can be lost simply due to the surgical process, and further decompensation occurs over time.^{4,13,14}

Assuming an uneventful recovery, this accelerated decompensation (primarily caused by trauma from the surgery itself) will lead to a finite life expectancy of any graft containing endothelium of, on average, between 10 and 20 years (though outliers exist).⁴

Once the graft endothelium reaches the end of its functional life, the graft becomes edematous and a new transplant is needed. Although this process will proceed in the absence of rejection, cases of endothelial rejection that are successfully treated and result in clearing of the cornea

will still result in further reduction in endothelial cell density and thus a shorter graft lifespan. Anytime the endothelium is transplanted, the patient should be aware of the graft's average life expectancy and the potential necessity of subsequent re-graft procedures.

KEY 3: EFFECT OF SUTURES

The process of suturing select corneal transplants into place is a primary cause of astigmatism that can affect a patient's refractive outcome. The average topometric astigmatism following PK is between 4.00D and 6.00D, with 20% of patients having over 8.00D even following suture removal.^{15,16} The astigmatism is often irregular, which leads to frequent reliance on specialty contact lenses fit postoperatively to achieve good vision.

The need for contact lenses postoperatively highlights two main considerations: (1) intolerance to lenses is a poor indication for proceeding to a transplant, as the patient may end up back in specialty lenses following surgery and (2) elderly patients may have dexterity limitations that make specialty lenses a challenge, thus creating a substantial barrier to achieving good vision after a PK (Figure 2).

Sutures can be adjusted or removed to modify both the magnitude of toricity and the degree of irregularity postoperatively; however, the effectiveness of these manipulations is not predictable and can vary significantly from patient to patient. While limited interrupted suture removal can begin as early as weeks following surgery, widespread removal cannot occur prior to the graft being fully healed. This takes several years following transplant for a PK, though with a deep anterior lamellar keratoplasty (DALK), sutures can generally be removed in about half the time.

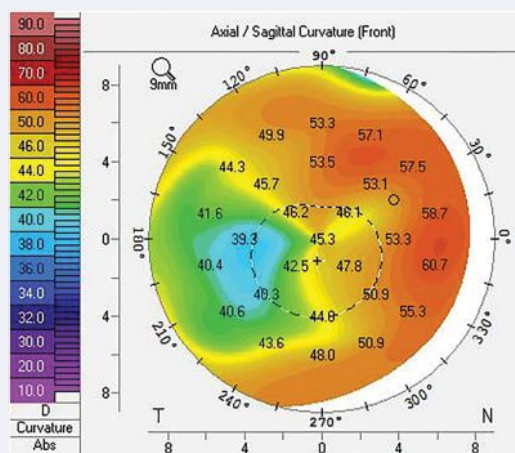


Fig. 2. Sutures and trephination of both the host and donor tissue introduce the possibility of high and irregular astigmatism. This may be mitigated with specialty contact lenses or procedures, including CRIs or PTK, that also slow down the visual rehabilitation of the transplant.

Determining total healing is difficult and involves a somewhat subjective assessment of fibrosis of the deep graft-host interface. This decision is best left in the hands of the operating surgeon.

Following targeted suture removal or adjustment, or full suture removal, if high astigmatism persists, further reduction of astigmatism can be performed with phototherapeutic keratectomy (PTK), corneal relaxing incisions (CRIs) or compression sutures. These procedures often take weeks to months to stabilize, which can further delay achievement of best-corrected vision. On average, it takes two to five years for a PK patient to stabilize, with longer times for patients who require further surgical procedures to reduce astigmatism (Figure 3).¹⁷

Corneal sutures induce obvious effects on vision and optical quality, but they also create a subtle yet important effect on corneal immunology. The body responds to the placement of corneal sutures by immediately upregulating all VEGF isoforms.^{18,19} This results in immediate corneal neovascularization and lymphangiogenesis at the margins of the graft, a process which obviously erodes the immune privilege of the graft. This upregulation of VEGF is short-lived, and the vessels created in this period regress; however, studies have shown that despite the endothelial graft antigen persisting indefinitely, rejection is most likely to occur in the first several months following surgery—a fact that indicates this early upregulation of VEGF may be important.²⁰⁻²²

Sutures not only impact the early immune response but also create a lasting pro-inflammatory stimulus, where mechanical irritation leads to recurrent suture infiltrates at the peripheral bite of the suture

(Figure 4). These infiltrates create photophobia and discomfort but, more importantly, in bringing the immune system to the margins of the graft, they increase the risk of subsequent rejection. Fortunately, these infiltrates also respond well to topical corticosteroids. If recurrent, however, the suture needs to be removed as soon as is feasible.

In summary, much of the challenging recovery associated with a corneal transplant—highlighted by a slow visual recovery, high amounts of irregular corneal astigmatism and subsequent need for a specialty contact lens—can be attributed to the presence of corneal sutures. The sutures also negatively affect corneal immunology by increasing the risk of rejection and the severity of that rejection.

When you put these key concepts together in general transplant immunology, considering the importance of the endothelium, and include the influence of sutures on immunology, one thing is clear: a graft that both contains endothelium and is sutured in place creates the greatest erosion of immune privilege and has the greatest risk of rejection and risk of that rejection leading to failure. These transplants have the greatest need for ongoing topical corticosteroid therapy. This carries with it the potential side effects of chronic corticosteroid use, including increased risk of glaucoma, cataract and rejection. Should any of these adverse events occur, their treatment and prognosis are worse in the setting of a transplant than if encountered alone.

Finally, even if an endothelium-containing trans-

plant successfully avoids rejection and steroid-related side effects, the grafted endothelium limits the life expectancy of that graft to approximately 10 to 20 years, and it will eventually need to be replaced.

So, what types of transplant satisfy all of these features (sutured and endothelium transplanted)? PK alone. Newer lamellar transplants improve on one or both of these risk factors resulting in reduced risk of rejection, an improved visual recovery or both. As we review each specific transplant type, based on the tissues that are transplanted, consider the influence of the endothelium and sutures on the anticipated recovery of that graft.

PK INS AND OUTS

This procedure was first successfully performed in 1903 by Dr. Edward Zirm on a patient with an alkaline burn.¹ The procedure itself was notable as it was performed prior to eye banking, modern suture material (only cat gut and silk were available), the discovery of penicillin—and thus antibiotics—and

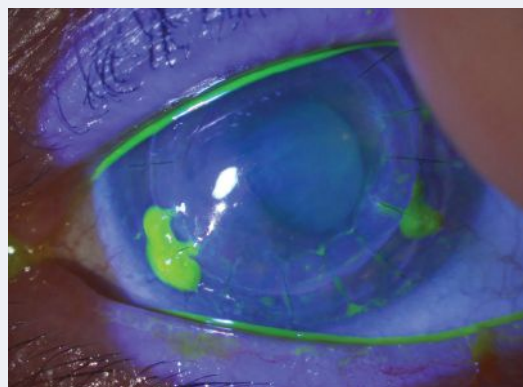


Fig. 3. Loose/exposed sutures pick up fluorescein dye. In this example, sutures at five, seven and eight o'clock are all loose and should be removed. Late in the postoperative course, this can be done with low risk of any problem. In the early postoperative period, however, given that you'd be removing adjacent sutures at seven and eight, the patient should be referred back to the surgery center, as they may need that zone reinforced with a new suture.



the pharmacologic use of glucocorticoids. It's truly remarkable that a PK was able to overcome these limitations, illustrating just how well the cornea is positioned to accept allografts when compared with other tissues and organs.

A PK involves full-thickness transplantation of all layers of the central cornea and was the only widely available transplant option for nearly a century. Of all corneal transplant techniques, PKs disrupt the normal anatomy, optics and immunology of the cornea the most; therefore, they have the lengthiest and most fraught postoperative recovery period. While its indications have dwindled with the development of more targeted lamellar transplants, PKs still account for approximately 35% of corneal transplants performed in the United States today.¹

During a PK, the graft button is usually 7.5mm to 9.5mm in size (depending on the host's native corneal diameter), and the host is trephined (cut in a circular fashion) in a slightly smaller diameter (0.25mm).²³ Larger transplants are associated with better optical outcomes, with the influence of irregularity induced by suture tension diminishing the

further away from the visual axis. This should be tempered by the fact that larger grafts (those closer to the host limbus) are associated with higher rates of rejection and other unwanted immune-related sequela.²⁴ The central cornea maintains a state of immune privilege, but that privilege wanes further out toward the limbus. Once the graft is secured by sutures, which may be "running" or "interrupted" (though all grafts receive at least four intraoperative interrupted sutures), the patient is sent home to begin the recovery process, the visual component of which can take years.^{17,23}

With knowledge of the influence of sutures and transplanted endothelium on risk and recovery, it is easy to predict that, on average, PKs carry the slowest visual recovery, the greatest risk of steroid-related side effects and the greatest risk of rejection leading to failure. Even with these limitations, a PK is the only surgical option for any full-thickness pathology and is generally felt to be the most straightforward transplant surgery. Despite the availability of deep anterior lamellar keratoplasty (DALK), Descemet stripping automated endothelial keratoplasty (DSAEK) and Descemet membrane endothelial keratoplasty (DMEK) for various indications, PK is still the second most common transplant technique in the United States, likely owing to its surgical "simplicity"—at least relative to other options.²⁴

DSAEK, DMEK DEEP DIVE

Endothelial keratoplasty has its roots in Charles Tillet's attempt in the 1950s to suture in a posterior lamellar transplant. After this early attempt failed, the field was left fallow for decades. It wasn't until Dr. Garrit Melles's early work in

the 1990s, followed by adjustments in technique by Mark Terry, Mark Gorovoy, Francis Price and others, that we were able to arrive at the two modern iterations of posterior lamellar transplants: DMEK and DSAEK.²⁵ By the time Descemet stripping endothelial keratoplasty (DSEK), a predecessor to DSAEK, arrived in the early 2000s, these endothelial procedures almost immediately replaced PK as the graft of choice for endothelial disease. In 2005, deep lamellar endothelial keratoplasties (DLEK), the only available posterior lamellar graft at the time, accounted for 4.5% of transplants in the United States, compared with 2010 when DSEK (more recently developed) accounted for 40% of all corneal transplants in the country.²⁶

Widespread adoption of the techniques among surgeons was driven by several factors. Endothelial disease is a primary indication for corneal transplantation, and the availability of targeted endothelial transplant options carries several recovery advantages over PK. By eliminating the securing sutures used in PK, endothelial keratoplasty achieves rapid recovery of vision relative to PK and a very modest and predictable refractive effect, does not create irregular astigmatism and has a smaller influence on corneal immune privilege, leading to less rejection and less rejection-induced graft failure.

When the technically complicated DLEK advanced to DSEK, the process was simplified and could be adopted by more cornea specialists. The more tedious and delicate DLEK required the surgeon to perform a posterior dissection of the host stroma and was the domain of the handful of surgeons who dedicated their careers primarily to corneal transplants whereas this step was abandoned with DSEK.²⁵

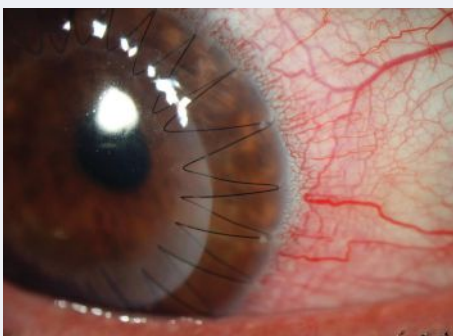

Fig. 4. Small infiltrates can be seen at the peripheral edges of the half past one, two and three o'clock suture bites. These respond well to corticosteroids and don't represent a rejection episode but, given that they bring the immune system into proximity with the graft, they may increase the risk of rejection.

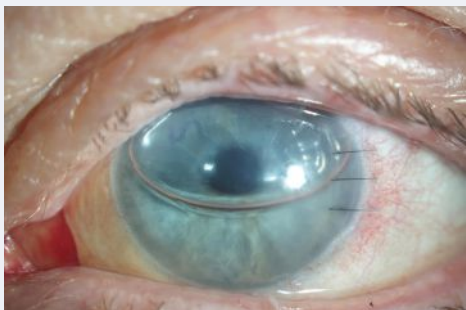

Fig. 5. This typical DMEK one-day postoperative appearance has a large gas bubble present in the anterior chamber. When the patient is supine, the gas bubble will press the donor graft into place. The bubble will limit vision to 20/400 or worse until it reabsorbs out of the visual axis. An “S” stamp, which can be placed by the eye bank upon surgeon request, can also be seen, indicating the graft is in the correct orientation. An inverted “S” would mean the transplant is upside down.

DSAEK and DMEK are similar modern procedures for endothelial transplantation. During surgery, the host Descemet membrane and endothelium are removed. The 8.5mm to 9.0mm graft is then inserted into the anterior chamber, unfolded and positioned centrally. It is then supported with a gas bubble (depending on the surgery center, this bubble may be air or a high-density gas mix), and the patient is sent home with supine positioning restrictions over the first several days postoperatively to allow the air bubble to press the graft into place (*Figure 5*).

Both of these transplants have some risk of graft dislocation in the first week following surgery. Dislocation may require a repeat bubble or even repeat transplant (usually after a repeat bubbling fails). Thus, the first several days following a DSAEK or DMEK carry the greatest risk of complications. If a patient makes it out of this time period without complications, the visual recovery is usually smooth over the next three to six months.

DSAEK is more widely performed than DMEK, for purely mechanical

reasons.²³ DMEK has slightly superior visual outcomes, more rapid time to visual stability and a significantly lower risk of rejection (which is paradoxical considering there isn't much difference in theoretic antigenicity between the two graft types); however, due to scrolling of the DMEK graft as it is placed in the eye, it is a more challenging procedure with greater risk of graft dislocation and early graft failure. For these reasons alone, DSAEK is the more frequently performed of the two surgeries.²³

Since endothelial transplants erode immune privilege less than PK, the rate of rejection is smaller as is the severity of rejection. These procedures also respond better to medical therapy resulting in less frequent failure.²⁷ However, although both of these endothelial grafts have a lower risk of rejection than PK, the risk isn't eliminated altogether.²⁷

DALK DISCUSSION

Clinically, a DALK appears just like a PK and has the same sutures that limit PKs, but it also carries some significant advantages over a PK. A DALK procedure transplants all tis-

sue anterior to the endothelium and is used for keratoectasia, stromal dystrophies and non-full-thickness corneal scarring. The anterior graft is sutured into place like a PK and, also as with a PK, the securing sutures create a number of optical and immunologic consequences. However, leaving the host Descemet membrane and endothelium in place promotes faster healing and better tectonics, which leads to quicker optical stability. Further, the importance of the immunologic influence of sutures is blunted by the fact that the endothelium is not transplanted, so there is close to no long-term risk of rejection leading to failure. This allows a more rapid elimination of topical steroids which limits the risk of steroid-related side effects.^{28,29}

Despite these advantages and the surgery's relatively wide set of indications, DALK is by far the least frequently performed transplant surgery.²³ This is primarily due to the demanding nature of the surgical procedure itself. Achieving a dissection plane down to the Descemet membrane without perforating it is a challenging skill. In many cases, the tissue is damaged or torn in the dissection phase. If the tears are large enough, the procedure may

DALK Case Study

Let's use a case to illustrate the advantages of this procedure. A 20-year-old patient with keratoconus plans to undergo bilateral PK. We anticipate frequent and sustained dosing of steroids, which increases the risk of glaucoma, cataract and infection. Further, even barring a rejection episode, that graft will likely fail due to endothelial decompensation by around the time the patient is 40. At that point, a DSAEK or DMEK may be attempted under the failed PK.

With an uneventful recovery, that endothelium will likely fail by the time this patient is 60, requiring yet another transplant. The graft is then repeated every 10 to 20 years. If the patient initially underwent DALK, they would have less need for topical steroids and a lower risk of rejection, and they would keep their own endothelium, which will likely last the rest of their life. This is in comparison to the predicted three to four transplants a young PK patient may need during their lifetime. While DALK has a lot of surgical challenges, it carries such substantial long-term advantages. Its use should at least be considered for patients with anterior pathology requiring transplant.



need to be aborted and conversion to a PK can be required. On the other hand, if dissection is not deep enough (to the level of the Descemet membrane), a scarred interface may occur, limiting the visual outcome. For this reason, DALKs have a slightly worse average postoperative best-corrected visual acuity compared with PKs (Figure 6).³⁰

DECELLULARIZED TRANSPLANTS

A recent publication in *Nature Biotechnology* highlighted the potential for bioengineered porcine dermal collagen to mimic the human cornea. The publication resulted in a number of popular media articles suggesting (perhaps prematurely) that such corneal transplants could restore vision in patients with keratoconus.

After being heavily processed, porcine collagen from either pig skin or eyes can be decellularized (killing the cells) and transplanted into patients with keratoconus who are too far advanced to crosslink and losing the ability to achieve good vision with their contact lenses. By placing this acellular tectonic graft in a stromal pocket, the risk of rejection is eliminated, progression of the disease stops (and may even slightly regress) and there is minimal impact on refraction since there are no sutures.^{31,32}

The concept is similar to Bowman's layer (BL) transplants, but decellularized animal transplants have the added benefit of not requiring human tissue, which would increase access to tissue in countries without eye banking capability sufficient to meet the needs of the population.

DWEK DOS AND DON'TS

Descemetorhexis without endothelial keratoplasty (DWEK) or Descemet stripping only is a proce-

dures exclusive to those with Fuchs' endothelial corneal dystrophy (FECD) and best suited for those with heavy centralized guttata. In FECD, guttata can affect vision even in the absence of edema if they accumulate heavily in the visual axis. Central guttata also put the surrounding endothelial cells on stretch, which is thought to induce apoptosis, thereby speeding up the process of decompensation. Guttata also prevent the migration of healthy endothelium into spaces of endothelial cell loss—a normal step in endothelial cell injury.

DWEK involves stripping 3.0mm to 4.0mm of the central Descemet membrane, endothelium and accompanying guttata. After the procedure, the patient's peripheral endothelium may be able to fill that empty space following normal migration and removal of the deleterious effects of the guttata. Of course, these patients will suffer from prominent corneal edema until this process is completed, so the visual recovery can be quite slow.

Advantages of this procedure are that it does not require transplant tissue (reducing both cost and the risk of rejection) and eliminates the need for supine positioning postoperatively that comes with DMEK and DSAEK. The procedure is better suited for younger patients with central guttata.^{33,34}

BL TRANSPLANT

This is the acellular layer of connective tissue immediately posterior to the epithelial basement membrane. Its role has not been fully elucidated, but it is thought to be primarily tectonic. Patients with keratoglobus, for example, are believed to have an aberrant BL.³⁵ Surgeons in Europe have experimented with transplant-

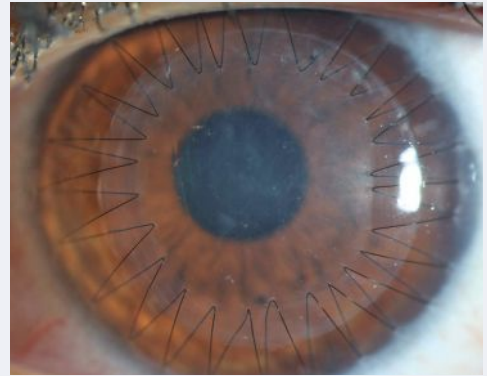


Fig. 6. This DALK had an incomplete dissection to Descemet's membrane in surgery that resulted in a hazy interface. The patient later went on to require a PK to remove this haze.

ing donor BL into a stromal pocket in a host with severe keratoconus.³⁶ The use of a tectonic acellular graft avoids immunologic risks of rejection while at the same time halting progression of the disease and possibly inducing modest regression.

The target population for this procedure is relatively small. Certainly, corneal crosslinking is the procedure of choice for most patients with progressive keratoconus, and when the disease is too advanced for success with specialty contact lenses, we should consider a transplant. However, patients who are successful contact lens wearers, yet too thin for crosslinking, may be prime candidates for BL transplantation in order to avoid more traditional keratoplasty and continue with their contact lens wear.

ULTRATHIN DSAEK

The difference between DSAEK and DMEK is the inclusion of posterior stroma to the DSAEK graft. DMEK grafts contain only Descemet membrane and endothelium. The inclusion of posterior stroma in DSAEK insulates the endothelium from intraoperative damage and makes the graft easier to handle and place than DMEK. The elasticity of DM without stroma causes DMEK

grafts to scroll, which can be difficult to open during surgery. They often want to scroll at the edges postoperatively, leading to a more difficult surgery and a graft that is more likely to detach earlier on. The lack of posterior stroma in DMEK is also speculated to be a significant contributor to the superior optical outcomes of DMEK (no hyperopic shift like in DSAEK and greater odds of achieving best-corrected acuity of 20/20).

To achieve the optical benefits of DMEK while retaining the surgical benefits of DSAEK, many surgeons have experimented with more thinly cut DSAEK grafts. The average DSAEK graft is approximately 130µm to 150µm thick. Ultrathin DSAEK grafts are thinner than 130µm but thicker than 50µm, while nanothin grafts are 50µm.^{37,38} Some research suggests DMEK patients still may achieve, on average, superior visual function compared with ultrathin DSAEK patients.³⁹

TAKEAWAYS

The outcome and use of corneal transplants are governed by the immunology and longevity of the transplanted cells, the optical and immunologic influence of any sutures that are used and the surgical complexity. Challenges facing all existing and future transplant options will be governed by these same principles. **RCCL**

1. Niederhorn JY. Mechanisms of corneal graft rejection: the sixth annual Thygeson Lecture presented at the Ocular Microbiology and Immunology Group meeting. October 21, 2000. *Cornea*. 2001;20:675-9.
2. Kim SW, Lee HY, Kim TI, et al. The survival of donor-derived cells in a successfully grafted corneal button 10 years after penetrating keratoplasty for lattice dystrophy. *Ophthalmologica*. 2009;223:396-400.
3. Lagali N, Stenevi U, Claesson M, et al. Survival of donor-derived cells in human corneal transplants. *Invest Ophthalmol Vis Sci*. 2009;50:2673-8.
4. Patel SV, Hodge DO, Bourne WM. Corneal endothelium and postoperative outcomes 15 years after penetrating keratoplasty. *Trans Am Ophthalmol Soc*. 2004;102:57-66.

5. Cheng YY, Visser N, Schouten JS, et al. Endothelial cell loss and visual outcome of deep anterior lamellar keratoplasty vs. penetrating keratoplasty: a randomized multicenter clinical trial. *Ophthalmology* 2011;118:302-9.
6. Bourne WM, Nelson LR, Hodge DO. Central corneal endothelial changes over a ten-year period. *Invest Ophthalmol Vis Sci*. 1997;38:779-82.
7. Bachman B, Taylor RS, Cusiefen C. Corneal neovascularization as a risk factor for graft failure and rejection after keratoplasty; an evidence-based meta-analysis. *Ophthalmology*. 2010;117: 1300-5.
8. Panda A, Vanathi M, Kumar A, et al. Corneal graft rejection. *Surv Ophthalmol*. 2007;52:375-96.
9. Alldredge OC, Krachmer JH. Clinical types of corneal transplant rejection. *Arch Ophthalmol*. 1981;99:599-604.
10. Sinha R, Jhanji V, Verma K, et al. Efficacy of topical cyclosporine A 2% in prevention of graft rejection in high-risk keratoplasty: a randomized controlled trial. *Graefes Arch Clin Exp Ophthalmol*. 2010;248:1167-72.
11. Javadi MA, Feizi S, Karbasian A, et al. Efficacy of topical cyclosporin A for treatment and prevention of graft rejection in corneal grafts with previous rejection episodes. *Br J Ophthalmol*. 2010;94:1464-7.
12. Magalhaes OA, Marinho DR, Kwitko S. Topical 0.03% tacrolimus preventing rejection in high-risk corneal transplantation: a cohort study. *Br J Ophthalmol*. 2013;97:1395-8.
13. Patel SV. Graft survival and endothelial outcomes in the new era of endothelial keratoplasty. *Exp Eye Res*. 2012;95:40-7.
14. Bourne WM. Cellular changes in transplanted human corneas. *Cornea*. 2001;20:560-9.
15. Lim L, Pesudovs K, Coster DJ. Penetrating keratoplasty for keratoconus: visual outcome and success. *Ophthalmology*. 2001;107:1125-31.
16. Riddle HK, Parker S, Price FW. Management of postkeratoplasty astigmatism. *Curr Opin Ophthalmol*. 1998;9:15-28.
17. Hopkinson C, Tole D, Chow SP, et al. Stability of visual outcome after corneal transplantation. *ARVO* 2016. Seattle, WA; May 1-5, 2016.
18. Cursiefen C, Cao J, Chen L, et al. Inhibition of hemangiogenesis and lymphangiogenesis after normal-risk corneal transplantation by neutralizing VEGF promotes graft survival. *Invest Ophthalmol Vis Sci*. 2004;45:2666-73.
19. Cursiefen C, Chen L, Dana MR, et al. Corneal Lymphangiogenesis: evidence mechanisms and implications for corneal transplant immunology. *Cornea*. 2003;22:273-81.
20. Williams KA, Coster DJ. The immunobiology of corneal transplantation. *Transplantation*. 2007;84:806-13.
21. Dana MR, Qian Y, Hamrah P. Twenty-five year panorama of corneal immunology: emerging concepts in the immunopathogenesis of microbial keratitis, peripheral ulcerative keratitis, and corneal transplant rejection. *Cornea* 2000;19:625-43.
22. Maguire MG, Stark WJ, Gottsch JD, et al. Risk Factors for corneal graft failure and rejection in the collaborative corneal transplantation studies. *CCTSRG. Ophthalmology*. 1994;101:1536-47.
23. Eye Bank Association of America. 2019 Eye Banking Statistical Report. 2020 www.restoresight.org.
24. Chan C, et al. Penetrating keratoplasty: the fundamentals. In: Krachmer JH, Mannis MJ, Holland EJ, eds. *Cornea*. 4th ed. St. Louis: Elsevier; 2017:1265-82.
25. Anshu A, Price MO, Tan DTH, et al. Endothelial keratoplasty: a revolution in evolution. *Surv Ophthalmol*. 2012;57: 236-52.
26. Tan D, Ang M. Surgical technique for DSEK. In: Krachmer JH, Mannis MJ, Holland EJ, eds. *Cornea*. 4th ed. St. Louis: Elsevier; 2017:1438-48.
27. Anshu A, Price MO, Price F. Risk of corneal transplant rejection significantly reduced with Descemet's membrane endothelial keratoplasty. *Ophthalmology*. 2012;119:536-40.
28. Cheng YY, Visser N, Schouten JS, et al. Endothelial cell loss and visual outcome of deep anterior lamellar keratoplasty vs. penetrating keratoplasty: a randomized multicenter clinical trial. *Ophthalmology* 2011;118:302-9.
29. Wu SQ, Zhou P, Zhang B, et al. Long-term comparison of full-bed deep lamellar keratoplasty with penetrating keratoplasty in treating corneal leucoma caused by herpes simplex keratitis. *Am J Ophthalmol*. 2012;153:291-9.
30. Reinhart WJ, Musch DC, Jacobs DS, et al. Deep anterior lamellar keratoplasty as an alternative to penetrating keratoplasty. A report by the American Academy of Ophthalmology. *Ophthalmology*. 2011;118:209-18.
31. Rafat M, Jabbarvand M, Sharma N, et al. Bioengineered corneal tissue for minimally invasive vision restoration in advanced keratoconus in two clinical cohorts. *Nat Biotechnol*. 2022; <https://doi.org/10.1038/s41587-022-01408-w>.
32. Holland G, Pandit A, Sanchez-Abella L, et al. Artificial cornea: past, current, and future directions. *Front Med*. 2021;8:770780.
33. Franceschino A, Duthiel F, Pereira B, et al. Descemetorhexis without endothelial keratoplasty in Fuchs endothelial corneal dystrophy: a systemic review and meta-analysis. *Cornea*. 2022;41:815-25.
34. Moloney G, Petsoglou C, Ball M, et al. Descemetorhexis without grafting for Fuchs endothelial dystrophy - supplementation with topical ripasudil. *Cornea*. 2017;36:642-8.
35. Gupta PK, Kim MJ, Kim T. Developmental corneal anomalies of size and shape. In: Krachmer JH, Mannis MJ, Holland EJ, eds. *Cornea*. 4th ed. St. Louis: Elsevier; 2017:599-609.
36. Tong CM, Dijk K, Melles GRJ. Update on Bowman layer transplantation. *Curr Opin Ophthalmol*. 2019;30:249-55.
37. Busin M, Scordia V. Ultrathin DSEK. In: Krachmer JH, Mannis MJ, Holland EJ, eds. *Cornea*. 4th ed. St. Louis: Elsevier; 2017:1461-67.
38. Kurji KH, Cheung AY, Eslani M, et al. Comparison of visual acuity outcomes between nanothin Descemet stripping automated endothelial keratoplasty and Descemet membrane endothelial keratoplasty. *Cornea*. 2018;37:1226-31.
39. Chamberlain W, Lin CC, Austin A, et al. Descemet endothelial thickness comparison trial: a randomized trial comparing ultrathin Descemet stripping automated endothelial keratoplasty with Descemet membrane endothelial keratoplasty. *Ophthalmology*. 2018;126:19-26.



TACKLING CORNEAL TRANSPLANTS IN CLINICAL PRACTICE

CE TEST - JANUARY/FEBRUARY 2022

You can obtain CE credit by completing the test form and returning it with the \$35 fee to: Jobson Healthcare Information, Attn: CE Processing, 395 Hudson Street, 3rd Floor New York, NY 10014. To be eligible, return the card within three years of publication. You can also access the test form and submit your answers and payment via credit card at Review Education Group online, www.revieweducationgroup.com.

You must achieve a score of 70 or higher to receive credit. Allow four weeks for processing. For each course you pass, you earn two hours of credit. Check with your state licensing board to see if this approval counts toward your CE requirement for relicensure.

- 1. What is the definition of an autograft?**
 - a. A transplant from one species to the another.
 - b. A transplant from one member of the same species to another individual.
 - c. A transplant from one part on a patient's body to another location on the same person.
 - d. A transplant from sibling to sibling.
- 2. Which best describes traditional corneal transplants?**
 - a. They are allografts.
 - b. They are xenografts.
 - c. They are autografts.
 - d. They are none of the above.
- 3. Which accurately describes the longevity of donor cells within a PK?**
 - a. Donor endothelial cells are replaced in the early months after PK with host endothelial cells.
 - b. Donor epithelial cells are replaced in the early months after transplant with new donor epithelium.
 - c. Keratocytes are non-miotic and so donor keratocytes are never replaced.
 - d. Endothelium is non-miotic and so donor endothelium is never replaced.
- 4. Which of the following statements about corneal graft rejection is false?**
 - a. Donor nucleated cells identified by the host immune system via their HLA-antigen are the target.
 - b. Epithelial cells are most likely to generate rejection later than a year after transplant.
 - c. Fulminant endothelial rejection leads to corneal edema.
 - d. WBCs in the graft are the primary clinical manifestation of rejection.
- 5. Which does not match rejection type with one of its primary manifestations?**
 - a. Epithelial rejection—corneal neovascularization.
 - b. Stromal rejection—nummular keratitis.
 - c. Endothelial rejection—corneal edema.
 - d. Endothelial rejection—KPs.
- 6. Which is not a clinical manifestation of endothelial rejection?**
 - a. An epithelial defect.
 - b. Corneal edema.
 - c. A Khodadoust line.
 - d. KPs.
- 7. Which is not inherently a hazard of transplanting corneal endothelium?**
 - a. Long-term risk of rejection leading to failure.
 - b. Finite lifespan of the transplant even barring rejection.
 - c. Greater need for corticosteroid and thus greater risk of steroid-associated side effects.
 - d. High corneal cylinder.
- 8. Which is not an impact of sutures on the recovery of a corneal transplant?**
 - a. Increases risk and severity of rejection.
 - b. Increases possible need for scleral or rigid gas permeable lenses.
 - c. Promotes immune tolerance.
 - d. Prolongs visual recovery.
- 9. Which is true of suture adjustment following a PK?**
 - a. Widespread suture removal can usually occur a month after surgery.
 - b. A continuous running suture cannot be adjusted to reduce astigmatism.
 - c. Sutures can be added in the form of compression sutures to reduce astigmatism.
 - d. Sutures do not influence corneal astigmatism following a transplant.
- 10. Which is not a possible direct sequela of sutures in the cornea?**
 - a. Upregulation of VEGF isoforms.
 - b. Cataract development.
 - c. Increased risk of infection when sutures are loose.
 - d. Suture infiltrates.
- 11. Which is true regarding loose sutures?**
 - a. Isolated loose interrupted sutures can usually be removed shortly after transplantation.
 - b. Loose running sutures can usually be removed shortly after surgery.
 - c. Full suture removal can proceed at any point without risk of destabilizing the graft.
 - d. Loose sutures do nothing to impact corneal immune privilege.
- 12. Which is not true of a sutured transplant that contains endothelium?**
 - a. They have a reduced risk of rejection compared with other transplants.
 - b. They have shorter visual recovery compared with other transplants.
 - c. They have less need of steroid compared with other transplants.
 - d. Rejections are likely to be more severe compared with other transplants.
- 13. When endothelium is transplanted, what is an average life expectancy of the graft, assuming no other complications during recovery?**
 - a. Three to five years.
 - b. Five to 10 years.
 - c. Ten to 20 years.
 - d. Indefinite lifespan.
- 14. What is a possible consequential sequela of using a smaller PK?**
 - a. Generally better optics than a large transplant.
 - b. Generally smaller risk of rejection than a large transplant.
 - c. Greater risk of glaucoma.
 - d. There is no impact of graft size.
- 15. Which is a benefit of a DSAEK over a PK?**
 - a. Better average visual recovery.
 - b. Quicker average visual recovery.
 - c. Less risk of rejection.
 - d. All of the above.
- 16. Which is a benefit of a DMEK over a DSAEK?**
 - a. Generally lower risk of rejection.
 - b. A DMEK is less likely to dislocate compared with a DSAEK.
 - c. A DMEK is less likely to suffer early failure compared with a DSAEK.
 - d. All of these are advantages of DMEK over DSAEK.
- 17. Which is not a benefit of DALK over PK?**
 - a. Dramatically lower risk of rejection leading to failure with a DALK compared with a PK.
 - b. Better tectonics to the cornea following DALK compared with PK.
 - c. Better average visual outcome with a DALK compared with a PK.
 - d. Barring complications, a longer graft survival with a DALK compared with a PK.
- 18. What feature does Bowman layer and decellularized pig corneal transplantation share?**
 - a. Both are primarily thought to be useful in early stages of keratoconus.
 - b. Theoretically, neither has a risk of rejection.
 - c. Both are sutured in place.
 - d. Both are advocated to replace corneal crosslinking.
- 19. What is an indication for DWEK?**
 - a. Pseudophakic bullous keratopathy.
 - b. Keratoconus.
 - c. A failed PK.
 - d. FECD.
- 20. Which is true regarding the various iterations of DSAEK?**
 - a. Thinner DSAEKs are thought to aid in surgical handling compared with traditional DSAEKs.
 - b. Thinner DSAEKs are thought to reduce risk of graft detachment compared with traditional DSAEKs.
 - c. Thinner DSAEKs are thought to improve the visual ceiling compared with traditional DSAEKs.
 - d. Thinner DSAEKs are thought to not require as much supine positioning compared with traditional DSAEKs.

Examination Answer Sheet

Tackling Corneal Transplants in Clinical Practice

Valid for credit through November 15, 2025

Online: You can take this exam online at www.revieweducationgroup.com. Upon passing the exam, you can view the results immediately and download a real-time CE certificate. You can view your test history any time on the website.

Directions: Select one answer for each question in the exam and completely darken the appropriate circle. A minimum score of 70% is required to earn credit.

Mail to: Jobson Healthcare Information, LLC, Attn.: CE Processing, 395 Hudson Street, 3rd Floor New York, New York 10014.

Payment: Remit \$35 with this exam. Make check payable to Jobson Healthcare Information, LLC.

Credit: This course is COPE-approved for two hours of CE credit. Course ID 81513-PO.

Jointly provided by PIM and the Review Education Group.

Salus University has sponsored the review and approval of this activity.

Processing: There is a four-week processing time for this exam.

Answers to CE exam:

1. A B C D
2. A B C D
3. A B C D
4. A B C D
5. A B C D
6. A B C D
7. A B C D
8. A B C D
9. A B C D
10. A B C D
11. A B C D
12. A B C D
13. A B C D
14. A B C D
15. A B C D
16. A B C D
17. A B C D
18. A B C D
19. A B C D
20. A B C D

Post-activity evaluation questions:

Rate how well the activity supported your achievement of these learning objectives:

1=Poor, 2=Fair, 3=Neutral, 4=Good, 5=Excellent

21. Recognize the various corneal transplant options. ① ② ③ ④ ⑤
22. Make appropriate referrals for these patients. ① ② ③ ④ ⑤
23. Educate and support their corneal transplant patients. ① ② ③ ④ ⑤
24. Effectively manage corneal transplant patients with ophthalmologists. ① ② ③ ④ ⑤
25. Participate in the postoperative care of corneal transplants. ① ② ③ ④ ⑤
26. Based upon your participation in this activity, do you intend to change your practice behavior? (choose only one)
 A I do plan to implement changes in my practice based on the information presented.
 B My current practice has been reinforced by the information presented.
 C I need more information before I will change my practice.
27. Thinking about how your participation in this activity will influence your patient care, how many of your patients are likely to benefit? (please use a number):
28. If you plan to change your practice behavior, what type of changes do you plan to implement? (check all that apply)
 a Apply latest guidelines b Change in pharmaceutical therapy c Choice of treatment/management approach
 d Change in current practice for referral e Change in non-pharmaceutical therapy f Change in differential diagnosis
 g Change in diagnostic testing h Other, please specify: _____
29. How confident are you that you will be able to make your intended changes?
 a Very confident b Somewhat confident c Unsure d Not confident
30. Which of the following do you anticipate will be the primary barrier to implementing these changes?
31. Additional comments on this course: _____
 a Formulary restrictions e Lack of interprofessional team support
 b Time constraints f Treatment related adverse events
 c System constraints g Patient adherence/compliance
 d Insurance/financial issues h Other, please specify: _____

Please retain a copy for your records. Please print clearly.

First Name

Last Name

E-Mail

The following is your: Home Address Business Address

Business Name

Address

City State

ZIP

Telephone # - -

Fax # - -

Rate the quality of the material provided:

1=Strongly disagree, 2=Somewhat disagree, 3=Neutral, 4=Somewhat agree, 5=Strongly agree

32. The content was evidence-based.

① ② ③ ④ ⑤

33. The content was balanced and free of bias.

① ② ③ ④ ⑤

34. The presentation was clear and effective.

① ② ③ ④ ⑤

By submitting this answer sheet, I certify that I have read the lesson in its entirety and completed the self-assessment exam personally based on the material presented. I have not obtained the answers to this exam by any fraudulent or improper means.

Signature _____ Date _____

Lesson 123298, RO-RCCL-1122




Don't Be Scared by the Whirlwind

Let's discuss when to intervene with the mostly benign condition of vortex keratopathy.

A 64-year-old female presented to my clinic for an anterior segment follow-up with minimal complaints. The patient reported that she had seen her retina specialist the day before and he told her she had some “very rare” changes to her cornea. I looked back through previous exams and everything had been unremarkable. The patient had no relevant medical history, although her ocular history was significant, as the patient had primary open-angle glaucoma in both eyes, moderate stage. The patient also had a history of intolerance to Travatan (travaprost, Novartis) and Rhopressa (netarsudil, Aerie) due to medicamentosa. Her current drop regimen was Rocklatan (netarsudil & latanoprost, Aerie). The patient was also being followed for blepharitis and dry eyes.

Her entering acuity OD and with correction was 20/25+2 20/25+2 OS. Her intraocular pressure taken with applanation was 12mm Hg OD and 14mm Hg OS. The slit lamp exam revealed meibomian gland dysfunction of the right and left upper and lower lids. Mild injection of the bulbar conjunctiva was seen OU. The cornea revealed a bilateral whorl-like pattern



Corneal epithelial deposits on the inferior half of the cornea.

of powdery, whitish yellow-brown epithelial defects OS more than OD located in the inferocentral cornea. The whorl pattern swirled outward but did not cross onto the limbus OU. The iris had regular, absent ruff with some pigmented dots, and the lens had nuclear sclerosis OU.

This patient had been closely followed for a year by both myself and a glaucoma specialist in our practice. Over the last year and half, the patient was on Rocklatan^(1,1) and no corneal abnormalities were observed by either provider. At this visit, the patient was diagnosed with corneal verticillata, known otherwise as whorl keratopathy or vortex keratopathy.

VORTEX KERATOPATHY

There are numerous medications that can cause corneal epithelial changes that are often characterized by deposits that may present as vortex keratopathy, diffuse corneal haze, punctate keratopathy and/or crystalline precipitates. Literature reveals most drug-induced corneal epithelial changes are drug-specific. These drugs vary in differing pharmacologic actions and most are amphiphilic and cationic (hydrophobic ring structures on the molecule and a hydrophilic side chain with a charged cationic amine group). The reason they produce a vortex or whorl-like pattern is because of the accumulation of lipids or iodine.¹ The vortex pattern of corneal deposits is caused by normal epithelial turnover and migration.

ASSOCIATED DRUG RISK

There are some drugs, including several antibiotics, that produce corneal epithelial changes; however, they do not cause a whorl-like keratopathy.

Instead, they can cause corneal toxicity, conjunctival pseudomembrane and delays in corneal reepithelization.

• Cationic amphiphilic drugs.

Amiodarone is the most widely studied drug that causes corneal epithelial changes. In almost all patients, it causes bilateral vortex keratopathy, described as a pattern of ocher to golden corneal deposits in a vortex configuration. These do not often interfere with visual acuity, although patients do report eyelid irritation, photophobia and halos. The onset of corneal changes becomes apparent as soon as two weeks after beginning treatment, but symptoms more commonly appear between one and four months.¹ Deposits occur in 98% of patients on approximately 200-300mg/day and 99% of patients on 200-1200mg five days a week.² Around 50% to 60% of cases result in keratopathy or lens opacities, causing drug discontinuation or modification.³

For aminoquinolines, including antimalarials (amodiaquine, chloroquine, mepacrine/quinacrine and hydroxychloroquine), the initial onset of presentation is similar to amiodarone, beginning after two to three weeks or after a few months of drug use.⁴ Unlike the retinopathy caused by these agents, the keratopathy reverses with cessation of treatment.⁴

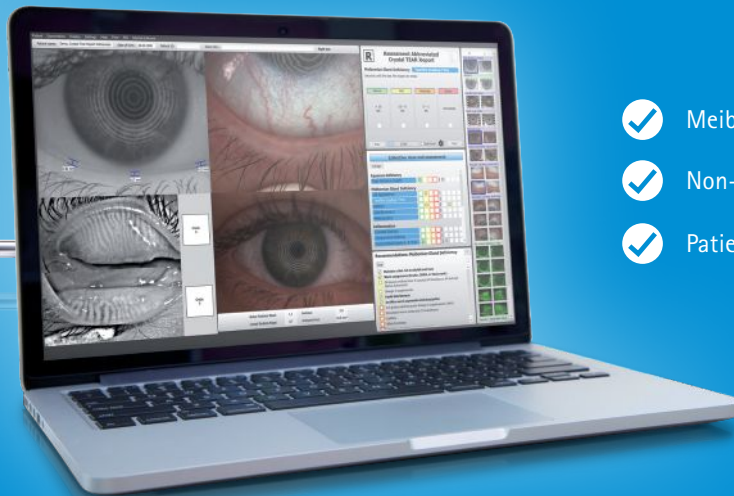Chlorpromazine, an antipsychotic medication, has been known to cause vortex-like corneal deposits when prescribed at a higher or lower dosage long-term. However, these deposits more typically occur in the stroma or the endothelium.¹

• Antineoplastic agents (cationic amphiphilic). Tamoxifen is a selective estrogen receptor modulator

(Continued on p. 34)

Searching for Dry Eye?

Find out in
60 seconds



- ✓ Meibography
- ✓ Non-invasive break-up time
- ✓ Patient education and compliance

OCULUS Keratograph® 5M: More than Meibography

Streamline your dry eye analysis with the baseline data of the tear film quality, quantity, or gland structure. This comprehensive assessment enhances patient care and outcomes.

Contact us today to learn more!



Scan here or visit
www.oculususa.com/dryeye

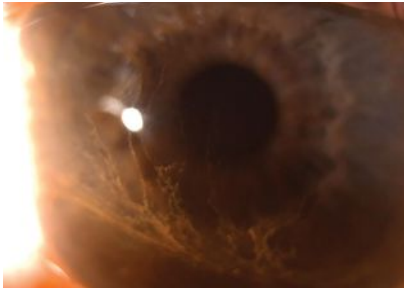Toll free 888-519-5375
ads@oculususa.com





Don't Be Scared by the Whirlwind

(Continued from p. 32)



Corneal epithelial deposits encroaching the visual axis, although not visually significant.

used for breast cancer treatment and prophylaxis. It has been reported to induce subepithelial deposits, vortex keratopathy and linear opacities even at very low dosages for prophylaxis (20mg/day) in around 11% of patients.⁵ These corneal changes are reversible when the medication is discontinued but, as with hydroxychloroquine, the retinal changes may not be reversible.

- **Nonsteroidal anti-inflammatory drugs (NSAIDs).** Ibuprofen, naproxen and indomethacin have all been described to cause intracellular deposits in the epithelium. These deposits appear quickly when the dosage is high (for example, 1200mg/day of ibuprofen) and resolve rapidly. NSAID cases have been reported in a small series of patients and the majority are in patients on prolonged indomethacin treatment.⁶

- **Antibiotics.** Aminoglycosides typically cause superficial punctate lesions, although subconjunctival gentamicin can produce vortex keratopathy.⁷

The macrolide clarithromycin, which is cationic but not amphiphilic, has been shown in single case reports to produce subepithelial corneal deposits. This is true of both oral and topical versions of the drug.¹

The specific fluoroquinolone ciprofloxacin is associated with white, crystalline corneal epithelial deposits that are precipitates of the drug.⁸ If the epithelium is compromised, vision can decrease, but the deposits resolve within two weeks to a few months once the drug is discontinued.⁹

- **Glaucoma medications.** Rhopressa, a combination rho-kinase inhibitor used in the Rocket clinical trials, showed corneal verticillata (vortex keratopathy) after one month in about 21% of patients given Rhopressa once a day. The brownish gray subepithelial deposits radiate in the central cornea in the whorl pattern. In the follow-up study on Rhopressa, 45 patients who had corneal verticillata experienced resolution after discontinuation, and three patients did not. These corneal changes did not cause meaningful changes to visual function.¹⁰ As a reminder, these changes will also be seen with Rocklatan because of the Rhopressa component.

There are many other categories of drugs that can cause corneal epithelial changes, including but not limited to gold salts, antineoplastic agents and antibody-drug conjugates.

ENDOGENOUS CAUSES

There are a number of endogenous causes of corneal epithelial changes, one being Fabry disease. With this condition, these patients are usually already diagnosed before any corneal changes are identified. A carrier of the disease, though, may see vortex keratopathy as the first indication.¹ Similarly, clinicians can identify paraproteinemia on slit lamp exams due to corneal epithelial changes before the systemic disease has been diagnosed.¹ Additionally, a low incidence

of gout can cause crystalline corneal deposits.

Superficial corneal dystrophies, such as Meesmann corneal dystrophy and Lisch corneal dystrophy, can present with a vortex pattern of corneal deposits. In Meesmann, the corneal deposits are central and peripheral and caused by intraepithelial cysts which appear during infancy. Lisch corneal dystrophy presents with feather-shaped opacities and microcysts arranged in a band or vortex pattern.¹¹

MANAGEMENT

In most cases, it is not recommended to alter a treatment regimen due to drug-induced epithelial corneal changes on the basis of keratopathy since the findings are usually benign. Many cases are asymptomatic, and most do not result in decreased visual acuity. It should be noted that this is not the same treatment and management protocol as medications that result in retinal toxicities. **BCCL**

1. Raizman MB, Hamrah P, Holland EJ, et al. Drug-induced corneal epithelial changes. *Surv Ophthalmol.* 2017;62(3):286-301.
2. Ghosh M, McCulloch C. Amiodarone-induced ultrastructural changes in human eyes. *Can J Ophthalmol.* 1984;19(4):178-86.
3. Mäntyjärvi M, Tuppurainen K, Ikäheimo K. Ocular side effects of amiodarone. *Surv Ophthalmol.* 1998;42(4):360-6.
4. Dosso A, Rungger-Brändle E. In vivo confocal microscopy in hydroxychloroquine-induced keratopathy. *Graefes Arch Clin Exp Ophthalmol.* 2007;45(2):318-20.
5. Nayfield SG, Gorin MB. Tamoxifen-associated eye disease a review. *J Clin Oncol.* 1996;14(3):1018-26.
6. Fitt A, Dayan M, Gillie RF. Vortex keratopathy associated with ibuprofen therapy. *Eye.* 1996;10(1):145-6.
7. Hollander DA, Aldave AJ. Drug-induced corneal complications. *Curr Opin Ophthalmol.* 2004;15(6):541-8.
8. Fraunfelder FW. Corneal toxicity from topical ocular and systemic medications. *Cornea.* 2006;25(10):1133-8.
9. Zawar SV, Mahadik S. Corneal deposit after topical ciprofloxacin as postoperative medication after cataract surgery. *Can J Ophthalmol.* 2014;49(4):392-4.
10. BusinessWire. Aerie Pharmaceuticals announces FDA advisory committee vote in favor of Rhopressa (netarsudil ophthalmic solution) 0.02%. October 13, 2017.
11. Klintworth GK. Corneal dystrophies. *Orphanet J Rare Dis.* 2009;4:7.

NOW HERE

MYDAY[®] TORIC
PARAMETERS NOW MATCH
BIOFINITY[®] TORIC
PARAMETER RANGE 100%

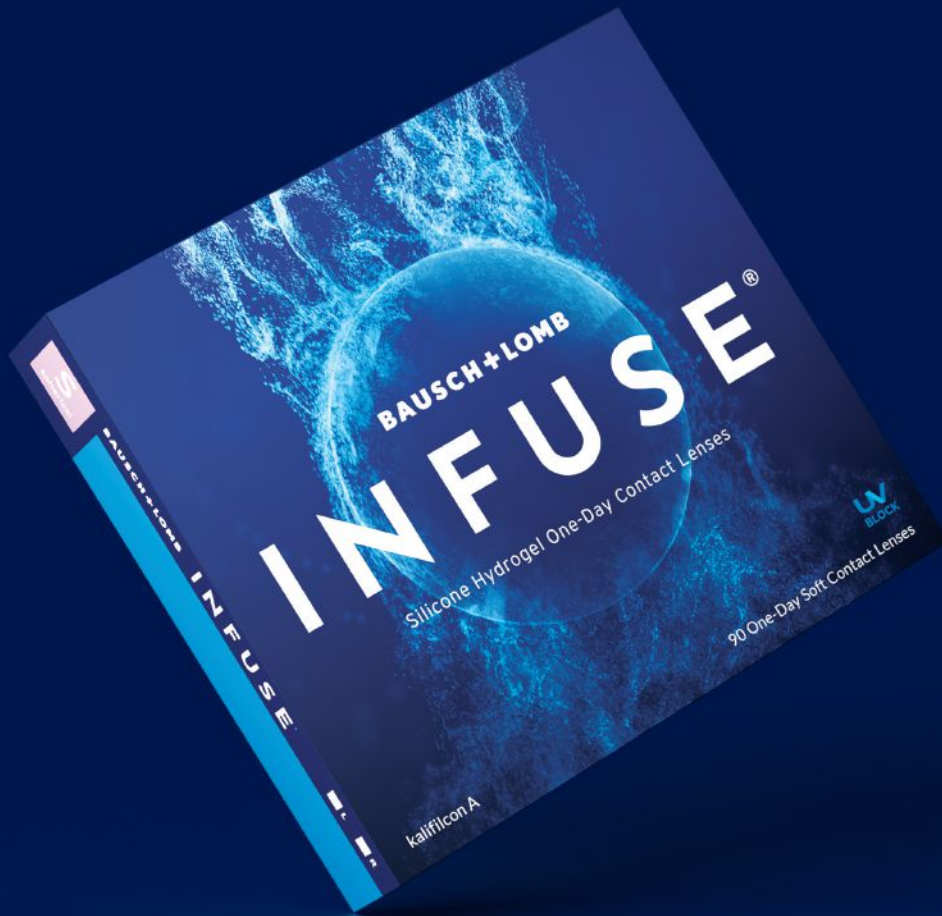

Announcing an unparalleled parameter expansion¹ to MyDay[®] toric, featuring around the clock axes and a core range from +8.00 to -10.00, giving you 4,392 prescription options. The greatest toric range² just got greater.

1. CVI data on file, 2021; Rx coverage database n=83,540 aged 14 to 70 years.

2. CVI data on file, 2021. Based on number of prescription options available in the USA across all soft 1-day toric lenses as reported by the 4 main manufacturers.





INFUSED FOR BALANCE

Next-generation material + ProBalance Technology™
working together to help maintain ocular surface homeostasis
to aid in minimizing symptoms of contact lens dryness.¹



Next-Generation Material



Ocular Surface
Homeostasis



ProBalance Technology™

Find balance at [BauschInfuseECP.com](https://www.BauschInfuseECP.com)

REFERENCE: 1. Data on file. Bausch & Lomb Incorporated, Rochester, NY.

®/™ are trademarks of Bausch & Lomb Incorporated or its affiliates.
©2020 Bausch & Lomb Incorporated or its affiliates. INF.0243.USA.20

BAUSCH+LOMB
See better. Live better.