

# RCCL<sup>®</sup>

REVIEW OF CORNEA  
& CONTACT LENSES

CLOSE  
ment



## INFUSED FOR BALANCE

The only silicone hydrogel daily disposable with a next-generation material infused with ProBalance Technology™ to help maintain ocular surface homeostasis<sup>1</sup>

Find balance at [BauschINFUSE.com](https://www.BauschINFUSE.com)

REFERENCE: 1. Data on file. Bausch & Lomb Incorporated, Rochester, NY.

®/™ are trademarks of Bausch & Lomb Incorporated or its affiliates.  
©2020 Bausch & Lomb Incorporated or its affiliates. INF0151.USA.20

**BAUSCH + LOMB**  
See better. Live better.



# RCCL<sup>®</sup>

REVIEW OF CORNEA  
& CONTACT LENSES

## ARVO UP CLOSE

Learn about the most clinically relevant anterior segment studies presented at this year's research showcase.

Page 14

2022  
abstract  
review

ALSO:

- The Spectrum of Ocular Allergic Diseases, **p. 20**
- Best Practices in Contact Lens Care, **p. 24**
- From Basics to Biologics: Selecting Drops for Every Dry Eye Patient, **p. 28**

BEFORE

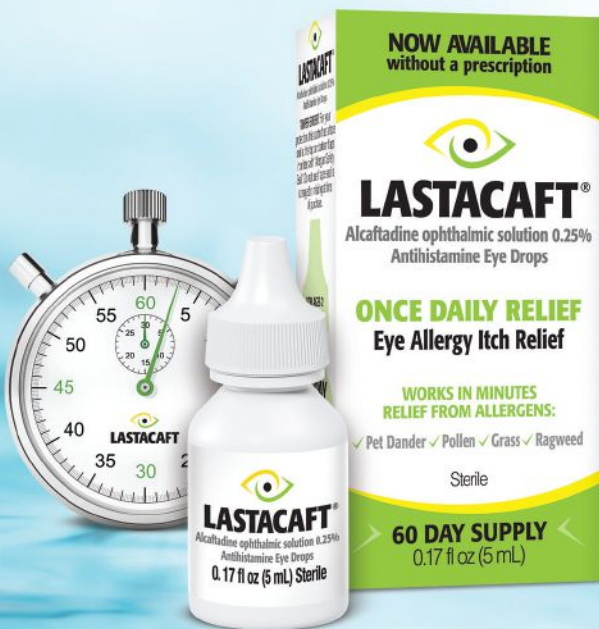AFTER



**LASTACRAFT**<sup>®</sup>

**SAME Rx STRENGTH  
NOW AVAILABLE OTC**

FOR PATIENTS WITH ITCHING DUE TO ALLERGIC CONJUNCTIVITIS



**FAST-ACTING:** Effective at 3 Minutes

**LONG-LASTING:** One Drop Lasts All Day\*

- Works against common allergens: pet dander, pollen, grass, and ragweed
- For ages 2+
- 2x the amount per bottle than the leading brand<sup>†</sup>

\*Lasts 16 hours

<sup>†</sup>Compared to the leading Once Daily Eye Allergy Itch Relief brand

IT'S **LASTACRAFT**<sup>®</sup> SEASON  
[lastacraft.com/doc](http://lastacraft.com/doc)

© 2022 AbbVie. All rights reserved. All trademarks are the property of their respective owners.  
US-LAS-210018 01/22

 **Allergan**  
an AbbVie company



# Doing More With Less

How the eyecare community is addressing donor tissue shortages for corneal transplants.

**T**here is a chronic under-supply of corneal tissue worldwide. It's estimated that there is only one donor cornea for every 70 diseased eyes that would benefit from transplant surgery.<sup>1</sup> Estimates show there are up to 30 million patients around the world in need of corneal restoration.<sup>1</sup> Luckily, recent advances in corneal surgery are helping to ease these shortages and hopefully will aid in streamlining the surgical process.

Every year, hundreds of corneas donated to eye banks are disqualified from being used due to deferral policies by FDA and the Eye Bank Association of America, mostly out of concern for potential disease transmission.<sup>2</sup>

This month, I'd like to highlight new trials that could address the worldwide shortage of corneal tissue needed for restoration. Partial-thickness procedures should benefit from the advances that allow one donor to be used for multiple patients.<sup>1,2</sup> In addition, new harvesting techniques for corneal surface limbal stem cell-deficient patients can show fabulous results, and artificial corneas appear to be a viable reality.

## INJECTABLE THERAPY

The IOTA study is looking at using an injectable corneal endothelial cell therapy.<sup>1</sup> The overarching goal is to treat more patients with fewer corneas and may ultimately be the preferred procedure for all corneal endothelial disease. In an earlier phase, two donor corneas treated 50 patients with endothelial disease.<sup>1</sup> Patients experienced both an improvement in acuity and a decrease in corneal thickness. Equally

exciting, this cell therapy is easily accessible to surgeons, minimally invasive for patients and is less complicated than doing posterior lamellar surgery.<sup>1</sup>

A new polymer film (synthetic endothelial layer) that acts as a barrier preventing excess fluid from entering the cornea is being investigated. EndoArt (EyeYon Medical) provides a minimally invasive procedure to reduce and prevent corneal edema.<sup>3</sup>

## TISSUE HARVESTING

Several investigators have found a way to harvest tissue to be used in patients with limbal stem cell deficiency.<sup>4,5</sup> Recently, methods of stem cell transplantation use *ex vivo* cells. Limbal tissue can come from a relative, cadaver or the normal fellow eye and expanded in culture before grafting. Cell farming using limbal-derived mesenchymal produces collagen for biosynthetic corneas, and adipose mesenchymal with liquid cornea for clinical application may be an alternative used in the future.<sup>5</sup>

New technologies include pluripotent stem cell use, seeding stem cells on amniotic membrane transplantation and using plasma-coated lenses or other alternate scaffolds for *in vivo* culture and transfer of transplanted cells.<sup>4,5</sup> SMILE lenticules treated with recipient donor human induced pluripotent stem cells have been attempted as well.<sup>5</sup>

## A NEW ARTIFICIAL CORNEA

The AlphaCor, a synthetic polymer, has addressed some of the complications (glaucoma, extrusion, endophthalmitis and membrane formation) of first-generation keratoprosthesis devices. AlphaCor was the first kera-

toprosthesis to obtain FDA approval nearly 20 years ago, but this device often results in stromal melting and optics degradation over time.<sup>3</sup>

An Israeli company, CorNeat Vision, has developed a new artificial cornea (CorNeat KPro) that has already been successfully implanted in several patients around the world. The device—a synthetic, non-degradable nanofibric skirt—is designed to integrate with ocular tissue (under the conjunctiva). This device takes advantage of bio-integrating with the highly vascularized and fibroblast-rich conjunctival tissue.<sup>3</sup> It seems to provide immediate visual performance, doesn't require donor tissue and can't transmit disease.

**C**orneal regeneration procedures with advanced harvesting techniques and artificial devices will continue to improve. We look forward to the day when no patient in need of restorative corneal surgery goes without a viable procedure. In the meantime, perhaps another look at donor tissue disqualification by our regulatory agencies is in order. **RECL**

1. Aurion Biotech announces IOTA cell therapy trials. [aurionbiotech.com/aurion-biotech-announces-iota-cell-therapy-trial-2](http://aurionbiotech.com/aurion-biotech-announces-iota-cell-therapy-trial-2). July 25, 2021. Accessed April 19, 2022.

2. Linnehan R. FDA policy turns away thousands of potential cornea donations each year. Association for Research and Ophthalmology. [www.healio.com/news/ophthalmology/20200529/fda-policy-turns-away-thousands-of-potential-cornea-donations-each-year](http://www.healio.com/news/ophthalmology/20200529/fda-policy-turns-away-thousands-of-potential-cornea-donations-each-year). May 29, 2020. Accessed April 19, 2022.

3. Holland G, Pandit A, Sanchez-Abella L, et al. artificial cornea: past, current and future directions. *Front Med (Lausanne)*. 2021;8:770780.

4. Le-Bel G, Guerin LP, Carrier P et al. Grafting of an autologous tissue-engineered human corneal epithelium to a patient with limbal stem cell deficiency (LSCD). *Am J Ophthalmol*. 2019;15:100532.

5. Karakus S. Limbal stem cell deficiency. EyeWiki. [eyewiki.aao.org/limbal\\_stem\\_cell\\_deficiency](http://eyewiki.aao.org/limbal_stem_cell_deficiency). July 30, 2021. Accessed April 19, 2022.

## IN BRIEF

■ Researchers initiated a systematic review and meta-analysis to **determine the global prevalence of Fuchs' endothelial corneal dystrophy (FECD)**. Among the 4,746 patients included, they identified 269 FECD cases (6%) and **estimated the global prevalence of FECD to be as high as 7.33%**. The analysis also showed statistically significant gender-related differences in disease prevalence.

The total number of people, older than 30 years, with FECD worldwide **will increase from 300 million in 2020 to 415 million in 2050**, which the study authors noted is due to the expected growth in the number of older individuals.

*Aiello F, Afflitto GG, Ceccarelli F, et al. Global prevalence of Fuchs endothelial corneal dystrophy (FECD) in adult population: a systematic review and meta-analysis. J Ophthalmol. April 14, 2022. [Epub ahead of print].*

■ A recent study looked at a group of 294 myopic children aged 7-11 who wore soft contact lenses for three years and found that **although adverse events were common, very few required meaningful treatment and none led to discontinuation of lens wear**.

On average, participants wore their lenses 73 hours per week, and 74.8% experienced at least one adverse event. There were 432 total adverse events observed among the cohort over the study period, 75.2% of which were ocular and 24.8% of which were non-ocular. **None of the ocular adverse events were serious, severe or caused permanent contact lens discontinuation.**

**"The three most common diagnoses were 91 (28.0%) cases of solution-induced corneal staining, 46 (14.2%) cases of ocular allergies and 23 (7.1%) cases of hordeola/chalazia,"** they noted. In addition, they found that adverse events were mild in nearly 75.0% of cases and moderate in 26.2% of cases.

**The incidence of moderate ocular adverse events determined to be definitely or likely related to use of contact lenses was 405 cases per 10,000 patient-years of wear.**

*Giannoni AG, Robich M, Berntsen DA, et al. Ocular and non-ocular adverse events during three years of soft contact lens wear in children. Optom Vis Sci. April 12, 2022. [Epub ahead of print].*

## Older Contact Lens Candidates Could Use More Guidance

**T**he market is saturated with contact lens options, but people older than 40 especially tend to be more unwilling to try them. A recent study attempted to identify how to increase contact lens usage among these patients.

Data from 1,540 participants 40 years and older with presbyopia who were existing contact lens wearers or willing to try contact lenses were included.

Overall, 50.8% of the participants wore contact lenses, but lens wear was less common among older participants. Some of the usage data supported findings of earlier studies; notably, just 25% used multifocal contact lenses.

The reasons the participants wanted to try contact lenses were similar to those of younger patients, such as sports and cosmesis factors. There was a drop-off in contact lens use in patients over 50 due to poor visual performance and an increased likelihood of age-related dry eye and other ocular issues.

A large number of the participants were already using multifocal spectacles, which the study authors said shows a good awareness of this product range. "There may be an opportunity to dispense multifocal spectacles to the others offering them dual wear, where they use both spectacles and contact lenses as required and are not solely using one or the other," the researchers noted in their paper.

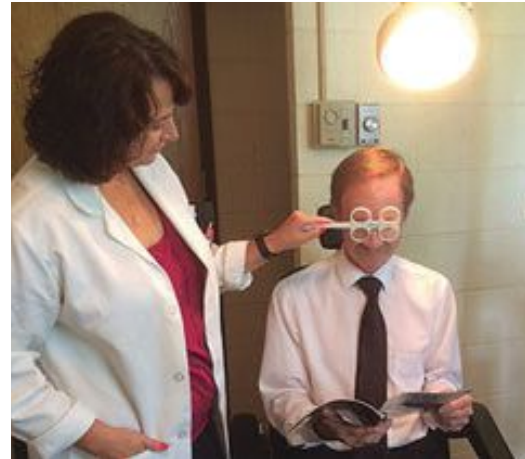

Photo: Julie Dekinder: 00

**Teaching patients over 40 about new contact lens options may help them branch out to find one better suited for them.**

The investigators also suggested the biggest opportunity seems to be with multifocal contact lenses, since only a quarter of the participants were currently wearing them, especially considering those who already wore multifocal spectacle lenses.

Lastly, the study highlights some failings by eyecare practitioners in the management of patients with presbyopia. "It seems that patients of this age group are seeking suggestions and recommendations from their eyecare practitioner including upgrading contact lenses and dual wear options," the authors suggested. "The day-to-day problems encountered by the contact lens wearers in this study seem to be, in the main, things that could be easily tackled by additional counseling and instruction from eyecare practitioners."

*Naroo SA, Nagra M, Retallic N. Exploring contact lens opportunities for patients above the age of 40 years. Cont Lens Anterior Eye. April 16, 2022. [Epub ahead of print].*

**EDITORIAL STAFF**

**EDITOR-IN-CHIEF**  
Jack Persico [jpersico@jobson.com](mailto:jpersico@jobson.com)  
**SENIOR EDITOR**  
Julie Shannon [jshannon@jobson.com](mailto:jshannon@jobson.com)  
**SENIOR ASSOCIATE EDITOR**  
Catherine Manthorp [cmanthorp@jobson.com](mailto:cmanthorp@jobson.com)  
**SENIOR ASSOCIATE EDITOR**  
Mark De Leon [mdeleon@jobson.com](mailto:mdeleon@jobson.com)  
**ASSOCIATE EDITOR**  
Leanne Spiegle [lspiegle@jobson.com](mailto:lspiegle@jobson.com)  
**CLINICAL EDITOR**  
Joseph P. Shovlin, OD [jpshovlin@gmail.com](mailto:jpshovlin@gmail.com)  
**ASSOCIATE CLINICAL EDITOR**  
Christine W. Sindt, OD [christine-sindt@uiowa.edu](mailto:christine-sindt@uiowa.edu)  
**SENIOR ART DIRECTOR**  
Jared Araujo [jaraujo@jhihealth.com](mailto:jaraujo@jhihealth.com)  
**AD PRODUCTION MANAGER**  
Farrah Aponte [faponte@jobson.com](mailto:faponte@jobson.com)

**BUSINESS STAFF**

**PUBLISHER**  
Michael Hoster [mhoster@jobson.com](mailto:mhoster@jobson.com)  
**SENIOR MANAGER, STRATEGIC ACCOUNTS**  
Michele Barrett [mbarrett@jobson.com](mailto:mbarrett@jobson.com)  
**REGIONAL SALES MANAGER**  
Jon Dardine [jdardine@jobson.com](mailto:jdardine@jobson.com)

**EXECUTIVE STAFF**

**CEO, INFORMATION SERVICES GROUP**  
Marc Ferrara [mferrara@jhihealth.com](mailto:mferrara@jhihealth.com)  
**SENIOR VICE PRESIDENT, OPERATIONS**  
Jeff Levitz [jlevitz@jhihealth.com](mailto:jlevitz@jhihealth.com)  
**SENIOR VICE PRESIDENT, HUMAN RESOURCES**  
Tammy Garcia [tgarcia@jhihealth.com](mailto:tgarcia@jhihealth.com)  
**VICE PRESIDENT, CREATIVE SERVICES & PRODUCTION**  
Monica Tettamanzi [mtettamanzi@jhihealth.com](mailto:mtettamanzi@jhihealth.com)  
**VICE PRESIDENT, CIRCULATION**  
Jared Sonners [jsonners@jhihealth.com](mailto:jsonners@jhihealth.com)  
**CORPORATE PRODUCTION MANAGER**  
John Caggiano [jcaggiano@jhihealth.com](mailto:jcaggiano@jhihealth.com)

**EDITORIAL REVIEW BOARD**

James V. Aquavella, MD  
Edward S. Bennett, OD  
Aaron Bronner, OD  
Brian Chou, OD  
Kenneth Daniels, OD  
S. Barry Eiden, OD  
Desmond Fonn, Dip Optom, MOptom  
Robert M. Grohe, OD  
Susan Gromacki, OD  
Patricia Keech, OD  
Bruce Koffler, MD  
Pete Kollbaum, OD, PhD  
Jeffrey Charles Krohn, OD  
Jerry Legerton, OD  
Kelly Nichols, OD  
Robert Ryan, OD  
Jack Schaeffer, OD  
Charles B. Slonim, MD  
Kirk Smick, OD  
Mary Jo Stiegemeier, OD  
Loretta B. Szczołka, OD  
Michael A. Ward, FCLSA  
Barry M. Weiner, OD  
Barry Weissman, OD

# Multifocals Act to Reduce Accommodation Stimulus

In an effort to slow myopia progression, multifocal contact lenses are often used to decrease axial lengthening by focusing peripheral light in front of the retina among young myopic children. However, a researcher using optical imaging calculations recently found that these lenses may act more by reducing the stimulus to accommodation.

Gerald Westheimer, OD, PhD, of the University of California Berkeley's division of neurobiology, wrote in his paper that it's unclear how much actual change in the peripheral retinal image is taking place when patients have plus-power rings added to their regular refractive correction, as there is a dearth of information regarding retinal light spread in multifocal contact lenses. Retinal light spread is needed to understand how eye length-regulating mechanisms are triggered by light, he explained.

To estimate retinal image spread at different visual distances, he

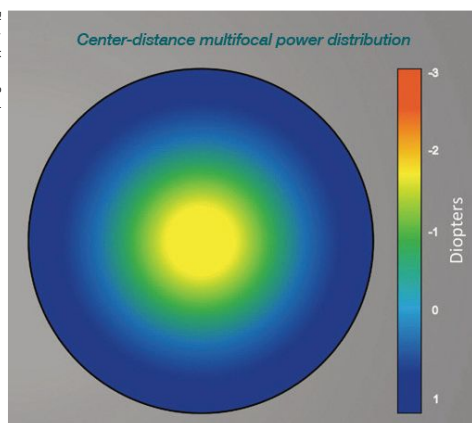
turned to "through-focus" diffraction computations in contact lens and eye models with normal parameters (e.g., polychromatic light, chromatic aberration, M-cone phototransduction layer). Based on the point- and edge-spread distributions of activation of phototransduction in the central retina, he concluded that adding multifocal zones creates "some veiling for in-focus viewing and substantial improvement of image quality for near targets in the unaccommodated eye." These findings were reduced in the retinal periphery.

Referring to the retinal distance graph in the study, Dr. Westheimer wrote that "In the in-focus condition,  $D=0$ , multifocals show little impairment of resolution and some extra outlying light spread." He continues, "When the unaccommodated eye views a target at 1m or closer, the multifocal zone confers a decided advantage."

Challenging the conventional wisdom on the mechanisms of myopic intervention, Dr. Westheimer wrote, "Whatever therapeutic value there is in prescribing multifocal contact lenses for myopia control, it's not particularly dependent on the precise configuration of the multifocal zones, nor can it be ascribed to changes in image quality specific to the retinal periphery. Its origin is more likely less blur for near targets, reducing the stimulus to accommodation."

Westheimer G. Multifocal contact lens myopia control: central and peripheral retinal image quality. *Clin Exp Optom*. May 9, 2022. [Epub ahead of print].

Photo: Kenur Savita

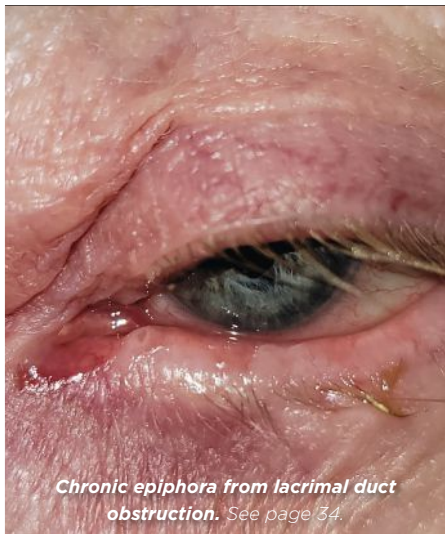


**New research suggests the efficacy of multifocals in controlling myopia may arise from their ability to reduce the accommodative response.**

# contents

Review of Cornea & Contact Lenses | May/June 2022

## features



Chronic epiphora from lacrimal duct obstruction. See page 34.

## departments

### 3 My Perspective

Doing More With Less  
By Joseph P. Shovlin, OD

### 4 News Review

Older Contact Lens Candidates  
Could Use More Guidance;  
Multifocals Act to Reduce  
Accommodation Stimulus

### 8 The GP Experts

Those Stubborn Deposits  
By Lindsay A. Sicks, OD

### 12 Fitting Challenges

Troubleshooting Traumatic Corneal  
Irregularity  
By Marcus R. Noyes, OD,  
and John D. Gelles, OD

### 32 Corneal Consult

Attacking *Acanthamoeba* Keratitis  
By Suzanne Sherman, OD

### 34 The Big Picture

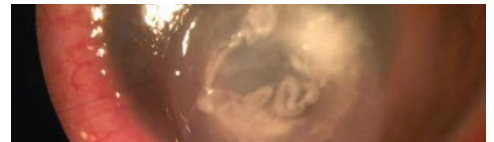Flood Zone  
By Christine W. Sindt, OD

## 14

### 2022 Abstract Review: ARVO Up Close

Learn about the most clinically relevant  
anterior segment studies presented at this  
year's research showcase.

By Review of Optometry/RCCL Staff

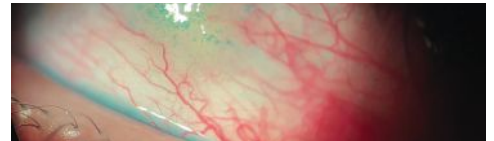


## 20

### The Spectrum of Allergic Ocular Diseases

A breakdown of the science and  
treatments behind these common  
conditions.

By Milton Hom, OD

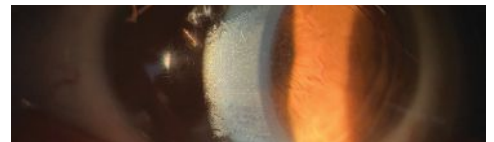


## 24

### Best Practices in Contact Lens Care

Patient education on storage, handling  
and application goes a long way.

By Manveen Bedi, OD

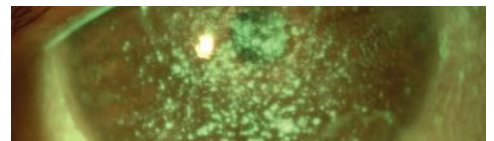


## 28

### From Basics to Biologics: Selecting Drops For Every Dry Eye Patient

Take a look at the indications and  
options for specific situations, from the  
rudimentary to the extreme.

By Mahnia Madan, OD, and Mark Eltis, OD







# Optometry's Role in the Patient Journey



**Gloria Chiu, OD, FAAO, FSLA**

Associate Professor of Clinical Ophthalmology  
USC Roski Eye Institute,  
USC Keck School of Medicine  
Los Angeles

## KEY TAKEAWAYS

- Cross-linking with the only FDA-approved iLink™ System can stop or slow progressive keratoconus.
- Early diagnosis and treatment are essential to preserve as much vision as possible.
- Optometrists are uniquely positioned to change lives and protect vision by identifying at-risk patients in the mild stages of the disease.

**K**eratoconus (KC) is a degenerative condition with onset in early adolescence. It is characterized by gradual thinning of the corneal stroma, causing a cone-shaped protrusion and worsening vision. As doctors of optometry, our top priority with these patients should be to manage their disease—and only secondarily to correct their vision.

A referral for corneal collagen cross-linking, which has been shown to halt progression in 92%-100% of cases<sup>1</sup>, may be able to preserve vision. As

it becomes a debilitating disease that affects every aspect of their lives. Worsening KC severity is associated with significant declines in reading, mobility, and emotional well-being quality of life (QoL) scores.<sup>3</sup> The impact on QoL can be even greater than that of retinal diseases and can be felt even when one eye still has good vision<sup>4</sup> so it is important that patients get help as early as possible.

In the U.S., when cross-linking is performed with the iLink™ platform (Glaukos), the only FDA-approved cross-linking system, it is generally covered by insurance for 96% of those with commercial insurance. In a recent simulation model, treatment with iLink™ was found to be highly cost effective, resulting in a 26% reduction in PKPs and patients spending 28 fewer years in the advanced stages of KC.<sup>5</sup> Young patients who can be treated

Advanced tomography/topography provides the most sensitive and accurate diagnostic information. However, there are a number of signs and symptoms that should heighten suspicion of KC and prompt further testing, either in the practice or by referral. These include myopic shift, rapidly changing astigmatism, vision that won't correct to 20/20 (with no other known reason), distorted mires on manual keratometry, and scissoring or an irregular retinoscopy reflex. Patients with a history of eye rubbing, connective tissue disease, Down syndrome, or a family history of KC are also at higher risk.

By promptly referring these patients for further testing and, if warranted, iLink™ cross-linking treatment, optometrists are uniquely positioned to protect and preserve patients' vision over their entire lifetime. ■

## REFERENCES:

1. Koller T et al. J Cataract Refract Surg 2009;35:1358.
2. Davidson AE et al. Eye (Lond) 2014;28:189.
3. Tan JCK, et al. Cornea 2019;38:600.
4. Kandel H, et al. Clin Exp Ophthalmol 2022;Epub ahead of print.
5. Lindstrom RL et al. J Med Econ 2021;24:410.
6. American Academy of Ophthalmology Preferred Practice Pattern, Corneal Ectasia, 2018

## INDICATIONS

Photrexa Viscous (riboflavin 5'-phosphate in 20% dextran ophthalmic solution) and Photrexa (riboflavin 5'-phosphate ophthalmic solution) are indicated for use with the iLink System in corneal collagen cross-linking for the treatment of progressive keratoconus and corneal ectasia following refractive surgery.

## IMPORTANT SAFETY INFORMATION

Corneal collagen cross-linking should not be performed on pregnant women.

Ulcerative keratitis can occur. Patients should be monitored for resolution of epithelial defects. The most common ocular adverse reaction was corneal opacity (haze). Other ocular side effects include punctate keratitis, corneal striae, dry eye, corneal epithelium defect, eye pain, light sensitivity, reduced visual acuity, and blurred vision.

These are not all of the side effects of the corneal collagen cross-linking treatment. For more information, go to [www.livingwithkeratoconus.com](http://www.livingwithkeratoconus.com) to obtain the FDA-approved product labeling.

You are encouraged to report all side effects to the FDA.

Visit [www.fda.gov/medwatch](http://www.fda.gov/medwatch), or call 1-800-FDA-1088.

## With Cross-Linking<sup>5</sup>

**26%** fewer PKPs | **28** fewer years in late-stage KC

with any surgical procedure, there is the potential for complications and cross-linking may not be right for everyone. After treatment, patients will still need regular optometric care. Follow-up care is similar to that required for PRK. However, there is no global period, so each follow-up visit is charged as a regular exam.

Without cross-linking treatment, progressive KC typically continues to worsen until around age 40 (and sometimes longer), with 10%-20% of cases requiring a penetrating keratoplasty (PKP).<sup>2</sup> When patients reach the advanced stages of keratoconus,

early while their vision is still good have the most to gain.

That's where optometrists' role becomes so critical. Our awareness of early progressive KC signs and risk factors can be nothing short of life changing for that young myope in our chair. There is no need to wait until a patient has lost vision or has slit lamp signs (e.g., thinning or striae) to refer for a more in-depth KC evaluation. It is standard of care to intervene with cross-linking upon detection of progression.<sup>6</sup>

**SCAN WITH PHONE**

Learn more about iLink corneal cross-linking here



# Those Stubborn Deposits

Two insidious manifestations underscore the importance of on-time lens replacement.

Incredibly, I saw two patients with heavily deposited lenses in back-to-back appointments on the same day. Each one was fairly asymptomatic and overdue for an annual exam.

The importance of regular lens replacement and proper cleaning, as well as annual visits to reinforce these procedures, is critical to ensure patients can maintain clear vision and continue contact lens wear without complications. One goal of contact lens management is prevention of unwanted changes to the anterior segment that could affect vision and comfort, including giant papillary conjunctivitis and other adverse events that are mechanical (lens binding, corneal warpage, discomfort) or inflammatory (corneal staining) in nature.<sup>1</sup>

## CASE ONE

A 58-year-old female presented wearing the same corneal lenses for the past three years reporting good, stable vision. Her last eye exam was one year ago at an outside practice where she purchased updated spectacles but did not bring her lenses for evaluation. She is using +1.75DS over-the-counter readers over the lenses for near and wears the lenses 12 to 14 hours per day. She notes that she has some irritation at the end of the day, which is relieved with lens removal. Solutions include Boston Advance Comfort (Bausch + Lomb) and weekly

Boston one-step liquid enzymatic cleaner (Bausch + Lomb).

The patient also complains of itching of eyelids and associated dryness symptoms that have been occurring for over two years. She reports the dryness and itching are relieved with artificial tears and azelastine as needed. She has a history of lattice degeneration OU with a round retinal hole OS without elevation or subretinal fluid. She also has chronic allergic conjunctivitis and dry eye OU. She is taking flaxseed oil and a variety of vitamins.

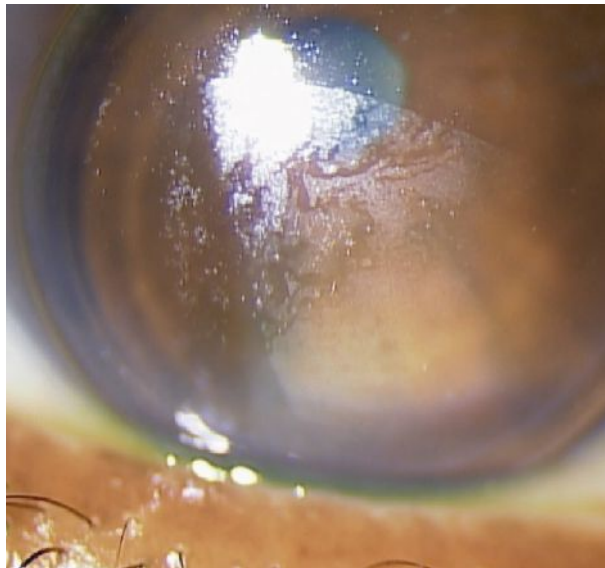
Entering VA was 20/20 in each eye. The patient's habitual GP lenses are OD 7.40/9.0/-8.25DS and OS 7.40/9.0/-8.75DS corneal lenses in Boston XO2, a third-generation fluorosilicone acrylate (FSA) material with a Dk of 141.

The fit was lid-attached OD and more interpalpebral OS. There was evidence of incomplete blinking in each eye consistent with the pattern of deposits. The fluorescein pattern showed apical alignment and adequate mid-peripheral bearing in each eye with good centration and movement. The patient accepted an over-refraction of +0.75DS over each eye.

Each corneal lens demonstrated an acquired mucoprotein film over the anterior lens surface, causing a hazy appearance (*Figure 1*). Typically, this film develops over several weeks or months of wear. The deposits can be caused by a variety of factors including poor tear quality, improper blinking, inadequate compliance with lens replacement or solution use, foreign contaminants (such as residue not

removed by proper hand-washing practices), surface scratches and poor surface wetting.<sup>2</sup> When tear film quality is poor, its continuity over the lens surface is not maintained and lens surfaces become dry. This allows for the formation of deposits on the lens—sites where protein and lipids can become attached to the lens, causing discomfort and reduced wearing time for the patient.<sup>3</sup>

There was trace fluorescein staining nasal and temporal OD and temporal and inferior OS on the cornea after lens removal. The tear break-up time was instant in each eye. The most recent



**Fig. 1. Corneal lens with acquired mucoprotein film on the anterior lens surface in case one patient. Her incomplete blink pattern is evident, as the upper third of the lens is more clear.**



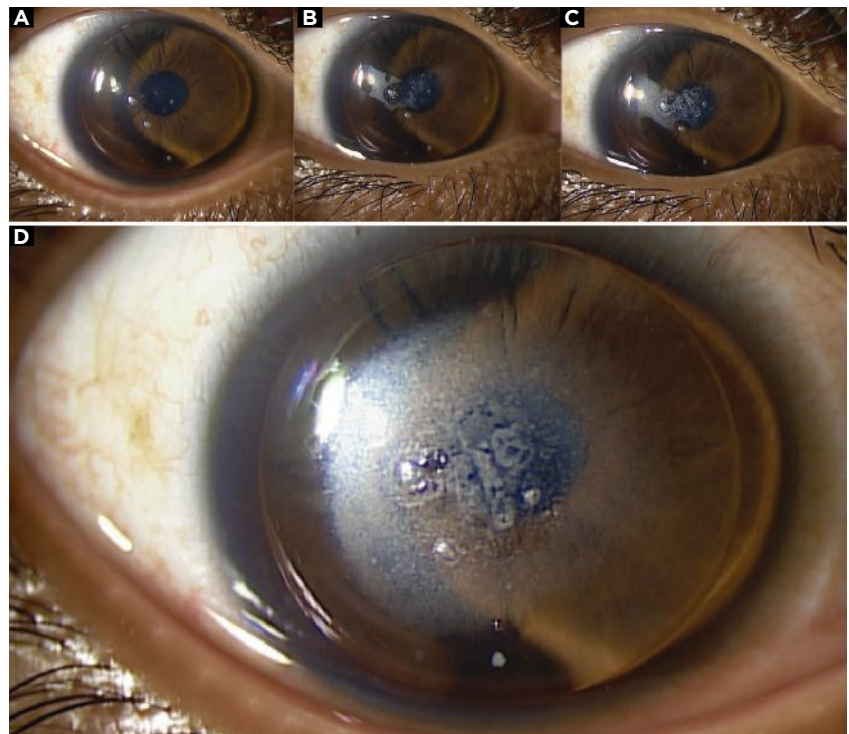
refraction was relatively stable to previous visits at OD -7.75 -1.50 x 155 and OS -7.75 -1.00 x 160 with a BCVA of 20/20 in each eye. The spectacle add was +2.25DS. The dilated fundus evaluation revealed stable findings OU.

The lenses were cleaned in-office with Boston Laboratory Lens Cleaner (Bausch + Lomb) and the patient was advised to replace the lenses. In addition, it was recommended she continue using Boston Advance Comfort two-step cleaning system as it is specifically designed for FSA lenses, which are more prone to lipid deposits.<sup>2</sup> The patient was also asked to continue weekly use of the one-step preservative-free liquid enzymatic cleaner containing subtilisin (a proteolytic enzyme) and glycerol.<sup>3</sup>

She was advised to continue using contact lens-compatible rewetting drops QID OU and was switched from generic azelastine to olopatadine 0.7% ophthalmic solution (Pataday Extra Strength, Alcon) once each morning in both eyes. We also discussed blink exercises and the need to return within one month for further dry eye evaluation in order to consider additional treatment options. New lenses were ordered. The plus over-refraction was not incorporated into the new lenses due to the deposits; however, it should be re-checked once new lenses are dispensed.

### CASE TWO

A 32-year-old male presented with long-standing blurry vision OU but denied any changes since his last exam. He says he sees well with his



**Figs. 2a-d. Time-lapse compilation of photos showing inter-blink non-wetting OD in case two patient. Figure 2a shows lens just after blink with lipid deposits. Photos from moments after that reveal formation of front surface haze (2b and 2c) with full extent of non-wetting visible in 2d.**

habitual pair of 18-month-old GP corneal lenses and reported using Boston Advance Comfort, but not on a daily basis. He denies the use of any conditioning or soaking solutions. He admits to sleeping in his lenses nightly and essentially wearing them 24 hours a day. He only removes the lenses when his eyes are irritated, at which time he cleans them with Boston Advance Cleaner, rinses with water and reapplies them.

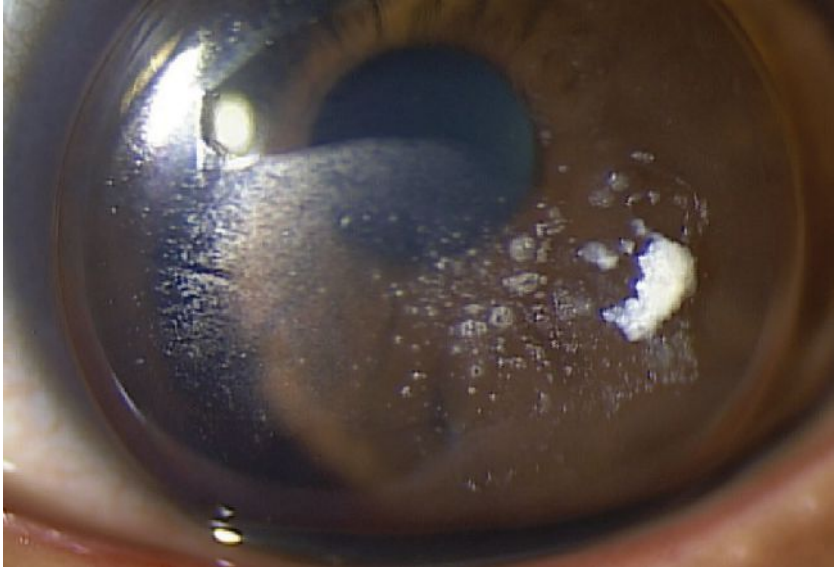
He denies any comfort or vision issues at this time. The last eye examination was 18 months prior where he was noted to have myopic

degeneration. He was unsure of his last medical exam but denies having any systemic conditions. He has a history of lattice degeneration. He has no allergies and is not taking any medications.

Entering VA was OD 20/70 (pinhole 20/50) and OS 20/50 (no improvement with pinhole). The patient's habitual GP lenses are OD 7.67/9.0/-17.75DS and OS 7.65/9.0/-14.50DS corneal lenses in Boston XO2. The fit was lid-attached OU. The fluorescein pattern showed mild central pooling and adequate mid-peripheral bearing in each eye with good centration and

# Those Stubborn Deposits

(continued)



**Fig. 3. Assortment of lens deposits OS found in case two, which were not improved after extensive in-office lens cleaning. Lens replacement was recommended.**

movement. The patient accepted an over-refraction of  $-0.75DS$  in each eye which improved vision to 20/40 OD, OS. We confirmed that he could reach the expected BCVA of 20/25 in each eye with contact lenses through the application of a clean diagnostic lens with the appropriate base curve.

Each corneal lens demonstrated heavy lipid and protein deposition in several areas across the front surface (Figure 2). The patient was advised to purchase new lenses at this visit. In an attempt to clean the habitual lenses in-office, we chose the Progent cleaning system (Menicon). The lenses were placed in sodium hypochlorite-potassium bromide mixture for 30 minutes then rinsed with the provided saline. Unfortunately, this did not remove the deposits and the patient's vision did not improve. An additional attempt was

made to clean the lens with Boston Laboratory Lens Cleaner, which also did not yield any improvement to the lens nor the patient's vision.

Slit-lamp examination revealed mild vessel encroachment at the limbus nasal and temporal in each eye. There was no fluorescein staining in either eye after lens removal. Today's refraction was relatively stable to previous visits at OD  $-19.75DS$  with VA 20/30 and OS  $-17.25 -2.50 \times 165$  with VA 20/25. The dilated fundus evaluation revealed stable white-without-pressure and lattice degeneration OU.

We re-educated the patient on the importance of nightly lens removal and cleaning procedures. He was advised to replace his lenses as the deposits are extensive and were not removed with our in-office cleaning procedures. We also discussed the limitations on the patient's vision.

Though he stated he was happy with his entering acuity, it was reduced to 20/70 in the poorer seeing eye. We also discussed the importance of having backup glasses in order to limit lens wear time.

In both of these cases, the patients will benefit from lens replacement. Particular attention should be given to discussing the benefits of nightly lens removal and cleaning in order to prevent lens deposits from forming on new lenses. Routine lens cleaning allows for effective deposit removal and the protection of lens surface integrity.<sup>2</sup> The use of specialized cleaning solutions containing both non-ionic (lipid-specific) and anionic (protein-specific) surfactants prior to lens conditioning will ensure the new lenses stay clear and deposit-free. The addition of a weekly enzymatic cleaner can also help remove additional protein deposits.

Another consideration would be the addition of a polyethylene glycol coating to new lenses to enhance lens wettability; however, this would require a change away from abrasive lens care products and discontinuation of weekly enzymatic cleaner. Interim visits (for example, a six-month follow-up) can also ensure that the patient is staying on track with the proper cleaning procedures, the lenses remain clear, and their anterior segment condition has not deteriorated. **RCCL**

1. Bennett ES, Henry VA. Gas-permeable lens problem solving. *Clinical Manual of Contact Lenses*. 4th ed. Lippincott Williams & Wilkins, 2014.

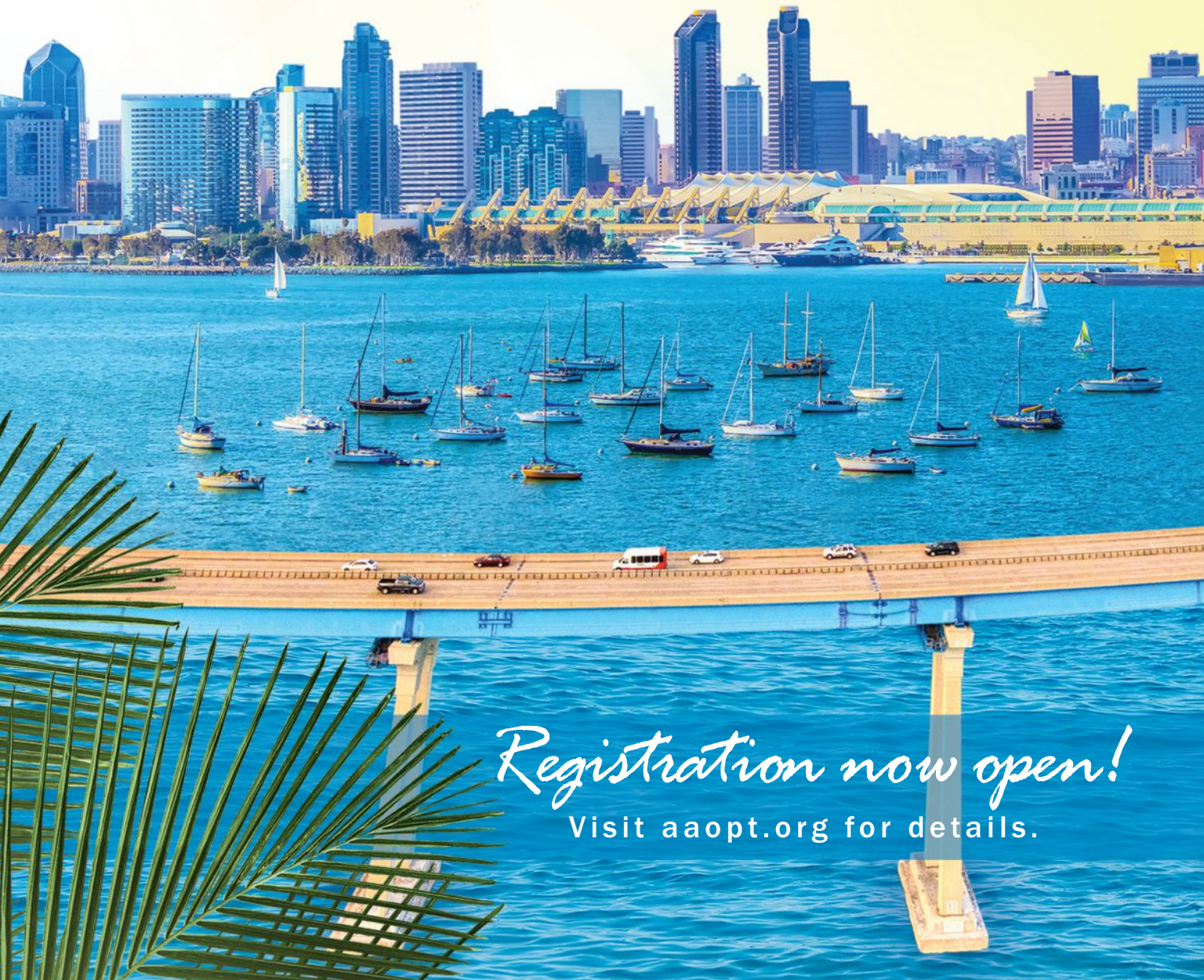2. Boston Materials and Solutions Guide. [www.fit-boston.eu/downloads/pdf/ProductGuideEN.pdf](http://www.fit-boston.eu/downloads/pdf/ProductGuideEN.pdf). 2011. Accessed April 25, 2022

*Centennial Celebration*

# ACADEMY **20** san diego **22**

OCTOBER 26-29, 2022

*Presented by* AMERICAN ACADEMY of OPTOMETRY



*Registration now open!*

Visit [aaopt.org](http://aaopt.org) for details.

# Troubleshooting Traumatic Corneal Irregularity

This patient presented after a firework went off in his hand. Let's review how to proceed.

**A** 20-year-old Caucasian male presented to the clinic as a referral from our cornea service for trauma-induced corneal scarring of the left eye. He was launching fireworks with his friends when one “didn’t go off.” He picked it up to inspect the problem and the firework exploded in his hand, resulting in chemical, thermal and shrapnel-based trauma to the left eye.

The patient’s initial presentation involved the following findings: soot embedded in his upper and lower eyelids and corneal limbus and diffuse corneal scarring of the left eye. His right eye was normal. On presentation, best-corrected visual acuity was 20/20 OD and 20/30 OS, though he struggled intensely with glare, particularly at night. His injuries remained superficial, and all other ocular structures were unaffected and healthy.

Let’s discuss considerations, which lens design might be most ideal for a patient in this scenario and then what was ultimately done for this individual.

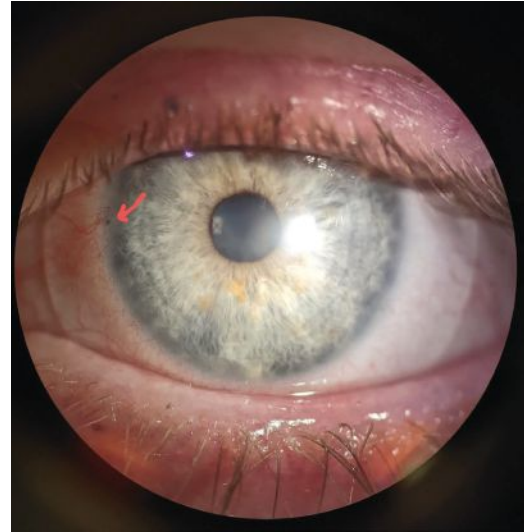
## CONSIDERATIONS

Here, we highlight how we would proceed.

*Dr. Noyes.* I think the first thing to consider in a case like this is evaluation of the ocular surface with sodium fluorescein (NaFl). One key aspect that drives the decision behind which contact lens modality to pursue is the health and integrity of the corneal limbus, especially in trauma or chemical burns. If a patient exhibits any signs of limbal stem cell deficiency (LSCD), this could limit your treatment options, as rubbing on the affected area will worsen findings such as scarring, neovascularization and pannus, and likely promote further stem cell morbidity.

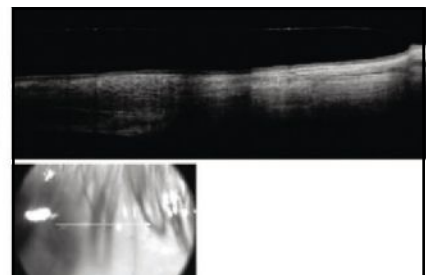
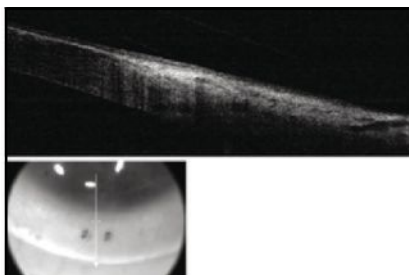
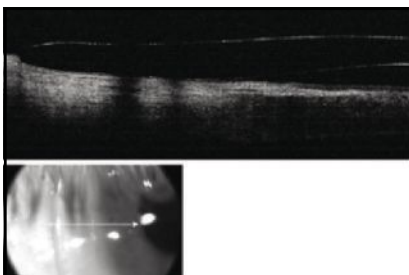
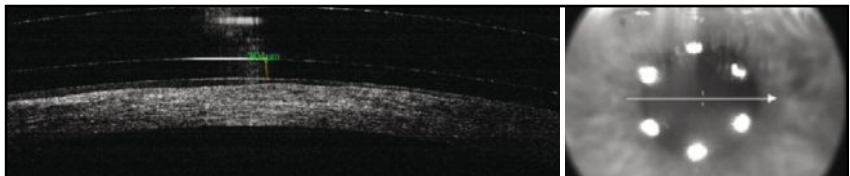
If the corneoscleral limbus looks acceptable, then any choice of contact lens could potentially be an option. If LSCD is present, scleral options are usually the best choice, as they are the only option that

completely vaults the limbus while also providing hydration, staving off potential future problems. In some cases, you may be able to get by with a corneal gas permeable lens; however, heed caution that the lens has a small enough diameter where either (1) it does not cross the limbus or (2) the point at which it crosses the limbus is further away from the affected area.



Soot is evident in the limbus (red arrow).

The series to the right and below demonstrates multiple views of OCT imaging of the patient following trauma to the left eye.





**Dr. Gelles.** After evaluating the integrity of the limbus, determining the severity of the irregularity can provide lots of options for this patient. If the irregularity is minor, great options will include soft, custom soft, corneal gas permeable and hybrid lenses. For those with more severe irregularity, scleral lenses and piggyback systems are my go-to. Trauma cases like this can be challenging, and addressing the patient's chief complaint may not be as simple as masking the irregular surface.

Depending on the severity of scarring that is present, it's possible the glare the patient is describing is not actually aberration from an irregular corneal shape but rather scatter from stromal scarring.

Aberrations can be addressed with a rigid lens, and residual aberrations can be further addressed with wavefront-guided optics, currently only available for scleral lenses. But with scatter, the only way to really improve vision further is to clear the media with surgical interventions, which in this case would be a superficial keratectomy, phototherapeutic

keratectomy and anterior lamellar keratoplasty. Several case studies have reported on scleral lenses reducing corneal opacity over time, making this an excellent option for this individual. Try going the non-surgical route first; if no visual improvement is noted, move on to weighing surgical considerations.

#### DISCUSSION

There are several ways to evaluate aberration vs. scatter, including a rigid lens over-refraction, wavefront aberrometry and even glare testing, the latter of which is the same as you would perform during a cataract evaluation. If glare is resolved by a rigid lens over-refraction, then it's all aberration. If not, use a wavefront aberrometer to measure the residual aberration, and remember to evaluate the spot diagram. The spacing or displacement of the spots relative to a normal grid indicates aberration vs. scatter, which is the quality of the individual spot and should correspond with the location of media

#### Want to Have Your Case Evaluated in the Next Issue?

Submit your case, complete with history, imaging and results, to [cmanthorp@jobson.com](mailto:cmanthorp@jobson.com) with the subject line, "Noyes and Gelles Troubleshooting." In an upcoming issue, Drs. Noyes and Gelles will weigh in on how they would each handle the case.

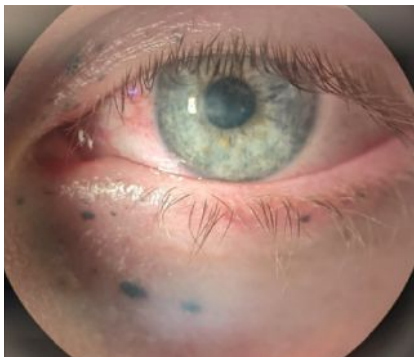
opacities. There are forms of visual quality evaluation that can deliver an objective scatter index number quantifying the spot quality.

Finally, glare testing with a brightness acuity test is also an option. If vision is reduced with this method, then it can be concluded that there is a significant amount of scatter affecting the patient's vision.

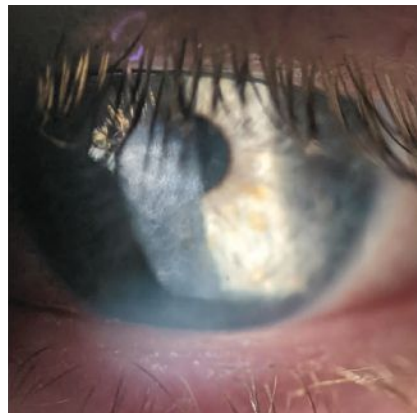#### RESULTS

This patient exhibited signs of LSCD in the left eye, and his slit lamp exam and tomography imaging determined his scleral shape and corneal surface to be moderately irregular. These factors led to the decision to fit him with a scleral lens in the left eye only.

A freeform, ocular impression-based scleral lens (EyeFitPro, Eye Print Prosthetics) made from ultra-high Dk material (Optimum Infinite, Contamac) was designed for the patient. The 17.5mm diameter combined with the freeform shape allowed for excellent alignment to the irregular scleral contour without compression and with full limbal clearance, as well as rotational and translational stability. With this lens, the patient was able to achieve 20/20 vision with complete resolution of his glare issues and improvement in LSCD signs. RCCL



**Anterior segment photos of the patient.**



## 2022 Abstract Review:

## ARVO UP CLOSE

Learn about the most clinically relevant anterior segment studies presented at this year's research showcase.

By Review of Optometry/RCCL Staff

**E**ach year, the Association for Research in Vision and Ophthalmology (ARVO) annual meeting gifts the eye care profession with a cornucopia of new research that lets us see where the winds are blowing clinically. Here, we've compiled research specific to cornea and contact lens care we feel may be most impactful for practicing optometrists.

This year, the meeting opted for a hybrid format after an all-virtual conference in 2021, gathering in Denver May 1-4 and streaming virtually May 11-12. The theme of ARVO 2022 was "accelerating discovery through team science." The findings summarized here are only a snippet of those presented at the meeting, but show the rich expanse of insights ARVO generates each year.

### CORNEA

Many teams of researchers presented their findings on treatments focused on this part of the eye.

- **Multidrug-resistant *Staphylococcus*.** In a recent study examining common ocular antibiotics' susceptibilities toward *Staphylococcus*, researchers collected 67 isolates from patients. The antibiotics examined in the study included levofloxacin,

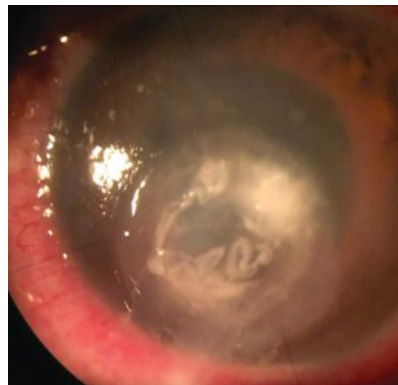


Photo: Paul C. Aghaian, OD

**Cefazolin sodium and fusidic acid could be used as alternative treatments for multidrug-resistant *Staphylococcus* in the ocular surface.**

tobramycin, clindamycin fusidic acid and cefazolin sodium. **Cefazolin sodium and fusidic acid were reliable options for managing this condition in the ocular surface.**<sup>1</sup>

"Our results indicate that cefazolin sodium and fusidic acid may be considered a reliable alternative for the treatment of multidrug-resistant *Staphylococcus* in the ocular surface, especially of beta-lactamase drug-resistant *Staphylococcus*," the study authors noted in their abstract.

The major isolate in the eyelid margin and conjunctival sac was drug-resistant *Staphylococcus epidermidis*. Drug-resistant *Staphylococcus aureus* was the

major isolate in the lacrimal sac and cornea, according to the abstract. Also, the susceptibility of cefazolin sodium and fusidic acid against beta-lactamase isolates were higher when compared with methicillin-resistant isolates.

"Multi-drug resistant *Staph.* remains a major clinical practice concern. Fortunately, earlier generation cephalosporins (in particular cefazolin sodium) are still very effective for treating these infections," says Joseph Shovlin, OD, of Northeastern Eye Institute in Scranton, PA. "Combining cefazolin sodium and fusidic acid appears to be a reliable alternative to vancomycin."

- **Impact of hormones on keratoconus.** In a recent study, researchers sought to establish the relationship between sex hormones and their receptors in healthy and keratoconus corneal stromal cells. The study authors used a 3D *in vitro* self-assembled extracellular matrix model. The *in vivo* analysis measured androgen/estrogen ELISA expression before and after corneal crosslinking (CXL) among a small cohort of patients with keratoconus.<sup>2</sup>

Estrone and estriol stimulation among healthy women revealed significant up-regulation of the andro-



gen receptor, progesterone receptor and estrogen receptor beta compared with healthy men. The data also showed higher expression of estrogen receptor alpha and estrogen receptor beta in women with keratoconus vs. their male counterparts.

“Systemic and local hormonal levels may be important biomarkers in the assessing treatment options for keratoconus,” Dr. Shovlin notes.

Following CXL, DHEA sulfate levels were lower while estrone and estrinol levels were higher. These *in vivo* findings indicate this treatment affects the corneal tissue and modulates hormonal levels in the bloodstream.

“Our data suggests that the human cornea is a sex-dependent and a hormone-responsive tissue. We posit that keratoconus is a systemic disease, at least initially, and is heavily dependent on systemic and local hormone alterations,” the study authors concluded in their abstract.

• **Ocular bacteria and HSK treatment.** An ocular bacterium that produces immune-regulating cytokines that could one day be used to limit the inflammation effects of vision-threatening herpes stromal keratitis (HSK).<sup>3</sup>

A team of researchers from the University of Pittsburgh hypothesized, “Delivering IL-10 using a genetically modified ocular commensal, *Corynebacterium mastitidis* (*C. mast*), will reduce immunopathology associated with HSK.”

The team found that the genetically engineered bacteria were able to produce and secrete functional murine IL-10. They explained, “IL-10 from *C. mast* regulates T-cell responses by suppressing proliferation and IFN- $\gamma$  production. Conversely, IL-10 from *C. mast* does not affect IL-17, which prevents *C. mast* from becoming a pathobiont.” Therefore, this ocular therapeutic appeared to successfully reduce HSK *in vivo*.

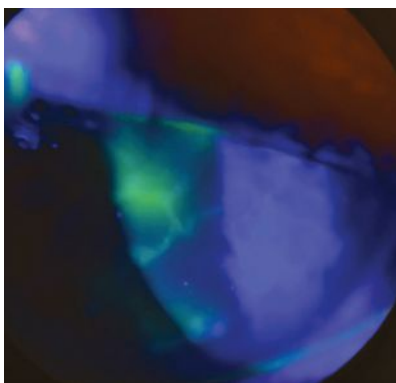


Photo: Alexander Martinez, OD

**Researchers are developing an ocular bacterium that is able to produce and secrete functional murine IL-10, regulating T-cell responses and reducing inflammation in HSK patients.**

The team concluded, “This study illustrates the first steps in engineering an ocular bacterium that can control excessive inflammation at the ocular surface.”

• **Corneal guttata in Hispanic cohort.** Are some populations more vulnerable to corneal endothelial compromise than others? Researchers in Mexico recently assessed the central corneal specular microscopy of healthy Hispanic adults and found a high prevalence of corneal guttata, outgrowths of Descemet’s membrane produced by distressed endothelial cells, with a higher preponderance in females.<sup>4</sup>

The study included 702 eyes from 356 patients (55% female). The mean age was 70. The researchers considered endothelial pleomorphism if <50% of cells were hexagonal and polymegethism if the coefficient of variation was >40%.

Mean endothelial cell density and cell hexagonality in this Hispanic population was lower than in other reports. The study determined that 76% of the patients had a pleomorphic endothelium, with a significant difference in cell hexagonality between male and female patients.

Also, 48% of patients had polymegethism, and 18% had corne-

al guttata, with 64% of the corneal guttata patients being female.

“Morphologic characteristics appears to be a more viable marker for cell function than even the actual number of endothelial cells for maintaining corneal transparency,” Dr. Shovlin proposes.

“Knowing the average endothelial parameters in our population can allow us to predict whether the endothelial pump function will tolerate surgery performed on the eye before affecting corneal transparency,” the researchers wrote in their abstract.

• **RCE characteristics.** Recurrent corneal erosion (RCE) presents a long-standing challenge, with patients experiencing a wide range of symptoms and cure rates. To better define its epithelial symptomatology and evaluate the subjective efficacy of proposed treatments, researchers queried members of an international RCE support group for data on their experiences. The team designed a 24-question poll covering demographics, clinical data and therapies, then shared it with 1,856 participants of an online support group.<sup>5</sup>

Only 27% of RCE cases mentioned were seen by a corneal specialist, but 92% were referred to a healthcare professional of some sort. The predominant symptom was acute awakening pain (77%). **RCE significantly impaired patients’ quality of life (68%).** Some respondents believed that daily wear of a mask while COVID-19 mandates were in place may have increased the frequency of episodes (16%).

Regarding surgical procedures, **manual debridement was the most performed (22%), effective in 30% of patients. Phototherapeutic keratectomy was performed in 20% of patients, effective in 60%. Almost 70% of patients were treated with hypertonic gel, which was the most efficient medical treatment, according to the patients (59%).**

## 2022 ABSTRACT REVIEW: ARVO UP CLOSE

**OCULAR SURFACE**

Several studies elaborated on risk factors and the efficacy of treatments for dry eye and related conditions.

- **Meibomian gland (MG) atrophy factors.** Upon evaluating MG morphology (atrophy and tortuosity) and risk factors in children ages four to 18, researchers found that **high BMI, an unhealthy diet and reduced outdoor activity may induce abnormal changes.**<sup>6</sup>

“MG abnormalities are not just found at high rates in older individuals but also show high prevalence in children,” Dr. Shovlin noted.

A total of 160 children at the Illinois Eye Institute were recruited. The team reported that the mean tear meniscus height was 0.23mm OD and 0.36mm OS. Mean noninvasive tear breakup time was 15.60 seconds OD and 15.96 seconds OS. No association was found between MG morphology and screen time.

“Eyecare practitioners should consider routine evaluation of the MGs in children during comprehensive eye exams, in addition to encouraging a healthy diet and time spent outside,” the study authors concluded in their abstract.

- **Finasteride risks.** Long-term effects of the anti-androgenic hair loss medication should be considered before use in dry eye patients as it **heightens meibomian gland dysfunction (MGD) risk, in addition to conjunctival and corneal abnormalities.**<sup>7</sup> Researchers noted that the androgen-sensitive meibomian glands may be altered in those taking anti-androgen medications, especially finasteride, given its unique potency and targeted effects compared with other anti-androgens.

The work included a retrospective chart review of 116 dry eye disease (DED) patients on finasteride (average age: 67.9, 95% male, 86% Caucasian). Analysis assessed clinical characteristics and Ocular Surface

Disease Index (OSDI) scores among patients on varying doses of finasteride (23 patients were taking 1mg or 2.5mg, and 93 were taking 5mg).

Comparing exam findings during the initial and follow-up exams, the latter visit saw a significantly greater percentage of patients present with MGD and conjunctival and corneal abnormalities. Mean OSDI score was 24.4 and was slightly higher in patients taking 5mg of finasteride, though not statistically significant. Low-dose finasteride use was significantly associated with a greater frequency of cyclosporine use at the first and last exams. Otherwise, treatment modalities were no different between low- and high-dose groups.

“This study reinforces the importance of considering the long-term effects of finasteride use on DED as part of the systemic sequelae of androgen depletion and provides anticipatory guidance for patients and ophthalmologists,” the study authors concluded in their paper.

- **Mediterranean diet and dry eye risk.** Consuming high amounts of unsaturated fats and oils, such as a traditional Mediterranean diet, is generally considered healthy, but unfortunately this one may not necessarily help to reduce the risk of DED, according to one study.

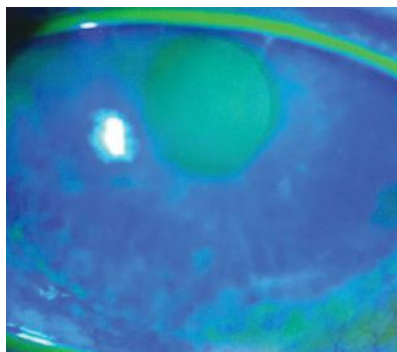


Photo: Chandra Mickles, OD

**A dry eye patient cohort treated with rhNGF eye drops experienced significant symptom improvement. Researchers believe it could be a promising therapy.**

While otherwise considered healthy, this approach seemed to increase a patient’s risk for the condition. Those with strongest adherence to the diet’s basics had a greater risk of symptomatic DED.<sup>8</sup>

A total of 58,993 participants from the Dutch Lifelines population-based cohort were included in the study (60% female). The researchers administered the Women’s Health Study dry eye questionnaire to assess DED outcomes and quantified the level of adherence to a Mediterranean diet using a modified Trichopoulou’s Mediterranean diet score. They reported that 9.1% of participants had DED as defined by the Women’s Health Study and that greater adherence to a Mediterranean diet wasn’t associated with a decreased risk of dry eye.

Interestingly, they noted that higher Mediterranean diet score values (*i.e.*, stronger adherence) were significantly associated with an increased risk of DED in all statistical models. Higher scores were also associated with a greater risk of symptomatic dry eye across all models after excluding participants with a DED diagnosis.

The researchers wrote in their abstract that the causes of this observed effect need further exploration.

- **Growth factor drops improve dry eye.** Neurosensory abnormalities have been increasingly recognized as a key feature of DED, so improving nerve health may be critical to restoring ocular homeostasis. **Researchers recently found that recombinant human nerve growth factor (rhNGF) eye drops were well-tolerated in patients with moderate to severe dry eye as a promising therapy option.**<sup>9</sup>

This randomized, vehicle-controlled Phase II study enrolled adult patients who had experienced moderate to severe dry eye for six months or longer. The researchers

randomized the 261 participants into three treatment groups that received the following drops in both eyes for four weeks plus 12 weeks follow-up: 20µg/mL rhNGF TID, 20µg/mL rhNGF BID plus vehicle treatment once a day or vehicle TID.

The mean change from baseline in Schirmer testing at week four was higher in the growth factor drops BID than the vehicle control arm (4.0mm vs. 1.7mm). Rates of response at week four were also higher in the TID (25.9%) and BID (29.3%) arms compared with the vehicle (11.9%) arm.

During follow-up, the TID arm had significantly greater Symptom Assessment in Dry Eye score reductions, indicating better symptom improvement, than the vehicle control arm at weeks eight, 12 and 16. More patients in the rhNGF drop arms than the vehicle arm reported one or more ocular adverse events in weeks one through four; the most common was eye pain. Mild eye pain was commonly reported but was generally transient and not reported after treatment discontinuation.

“Recombinant human growth factor addressing neurosensory abnormalities seems to help restore ocular homeostasis with only mild transient discomfort,” Dr. Shovlin says. “Clinicians may be able to rely upon this modality in the near future for the treatment of DED.”

• **Gut microbiota and Sjögren's.** Gut health has important implications for the ocular surface, especially in Sjögren's patients. Using metagenomic sequencing, researchers from Baylor College of Medicine were able to identify differential bacterial species from stool samples. They confirmed that the Sjögren's syndrome gut microbiome is less diverse and associated with increased ocular disease severity.<sup>10</sup>

The study included 20 healthy subjects as well as four patients with

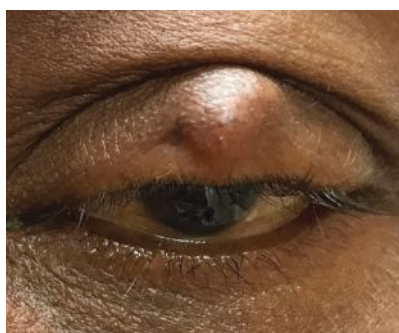

Photo: Joseph W. Sowka, OD

**Chalazion incision/excision was found to be more common among patients of male sex and those with rosacea.**

dry eye and seven with Sjögren's syndrome (age-matched, all female). The researchers used the International Dry Eye Workshop guidelines to score ocular disease severity and prepared high-quality DNA for metagenomic sequencing and analysis from the collected stool samples.

The researchers reported significantly decreased organism diversity in Sjögren's syndrome patients, a finding inversely correlated with ocular severity score. Interestingly, they found a significant difference between the healthy and Sjögren's syndrome groups but not between the healthy and dry eye groups.

At the species level, Sjögren's syndrome patients also had significantly less *Bifidobacterium bifidum*, a beneficial probiotic bacterial species commonly found in mammals, compared with healthy controls.

The researchers concluded that these species changes correlated with disease severity. Dr. Shovlin says he is hopeful that these findings can lead to future treatment approaches.

• **Effects of glaucoma drops.** Preservatives in topical glaucoma medications have long been known to cause ocular surface inflammation, but researchers suggested that not all preservatives do. They observed significant changes in the microbial composition of the ocular surfaces of patients using preserved glaucoma medications.

In the study, 17 patients (10 with unilateral glaucoma using preserved drops on just one eye and seven age-matched healthy controls with no history of ocular surface disease or eye drop use) had both eyes swabbed for V3-V4 16S rRNA sequencing. The researchers used air swabs as negative controls and compared the microbial diversity and composition of the swabs.

They found that samples from treated and untreated patient eyes had greater organism diversity and a distinct microbial composition compared with controls.<sup>11</sup> Eyes treated with preserved glaucoma drops had various gram-negative bacteria (mainly *Akkermansia*), which the researchers wrote in their abstract was significantly different from the mainly gram-positive microbes found in the healthy control eyes.

“These compositional differences were associated with decreased tear film measures and distinct inferred protein synthesis pathways, suggesting a potential link between microbial alterations and ocular surface inflammation,” the investigators concluded in their abstract.

## MYOPIA

Multiple studies offered new findings on approaches to diagnosis and treatment.

• **Initial myopic defocus.** A relative peripheral hyperopia has been suggested as a myopia trigger in children. To better validate this finding, researchers measured high-resolution two-dimensional peripheral refraction maps during two years of myopia progression in a group of Chinese children. The team determined that **relative refraction in the superior retina can be used as a predictor of central myopia.**<sup>12</sup>

After the study concluded, 214 children's data (ages nine to 16) were available after one year and 152 children's data were available after

## 2022 ABSTRACT REVIEW: ARVO UP CLOSE

two. The peripheral refraction maps covered a field from nasal 30° to temporal 30° of every 1° and from superior 20° to inferior 16° of every 4°. The participants were classified into three refraction progression groups based on their refractive change in hyperopia, emmetropia and myopia.

After the first year, a refraction pattern significantly different from baseline was found in emmetropes. Baseline peripheral defocus in the central vertical field (horizontally, within  $\pm 15^\circ$ ) was found to be significantly correlated with central myopic shift, especially in the superior retina.

Linear regression revealed that **emmetropic subjects with more myopic defocus in the superior retina had more myopic progression.** The researchers found no obvious difference in baseline refraction pattern in the hyperopes and myopes.

“This type of relative refraction in the superior retina could be used as a predictor of central myopia,” the team concluded in their abstract. “Devices for keeping the superior retina emmetropic in children might be a myopia control strategy.”

• **Dexamethasone affects eye growth.** A recent study suggests **systemic use of dexamethasone interrupts emmetropization to slow myopia progression in children.**<sup>13</sup>

The researchers administered dexamethasone or vehicle daily to chicks during the development of monocular form deprivation myopia (the last seven days of a 17-day period). Occluders were removed on the last day of treatment, and chicks experienced unrestricted vision for a recovery period of about 20 hours.

Data showed a significant decrease in choroidal IL6 gene expression in recovering eyes treated with dexamethasone vs. vehicle-treated chicks. The study authors detected no significant differences in IL6 gene expression in the choroids of control

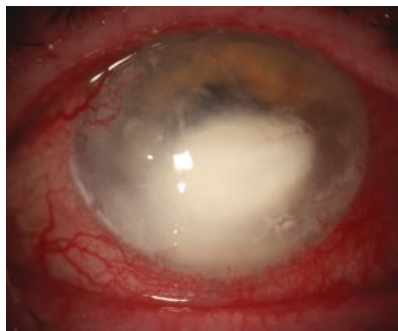

Photo: Dataray/Kent, OD

**High rates of *in vitro* resistance has only slightly decreased over 13 years.**

eyes between chicks treated with dexamethasone vs. vehicle.

“Dexamethasone treatment reduced choroidal gene expression of IL6 in recovering eyes, resulting in a disinhibition of scleral proteoglycan synthesis during recovery from induced myopia,” the study authors noted in their abstract. “These results provide additional support for a role of inflammation in visually regulated eye growth.”

Dr. Shovlin believes agents that reduce inflammation may someday help control myopia. “Unfortunately, systemic corticosteroids are not without their side effects, especially in a young population of users,” he notes. “Additional concerns should be focused on any viable option that may led to a significant increase in scleral proteoglycan synthesis in recovering eyes.”

• **Posterior scleral strain.** Imaging biomarkers (measuring deformability) may efficiently assess **posterior eye wall strain for predicting risk for staphyloma formation.**<sup>14</sup>

The study included 58 myopic eyes of 29 subjects (ages range: 37 to 87). To study the posterior shape and rigidity of each eye, researchers performed ultrasound B-mode scans in primary gaze across 100 frames.

Relative stiffness of several regions of interest in the retina-choroid-sclera interface was measured across the 100 frames using strain elastography. Orbital fat was the baseline. At an

interval of before-and-after compression, the researchers observed a significant difference between change in average relative stiffness for one region of interest and across two different regions of interest when compared with baseline.

The data showed that axial length and spherical error ranged from 22.59mm to 30.72mm and 0.7D to -15.7D, respectively. Also, the study authors reported that an increase in axial length (per 1mm) showed a decrease in average relative stiffness for a retina-choroid-sclera layer region of interest during compression of -0.283 as well as no compression of -0.0139. An increase of spherical error during compression revealed an increase in average relative stiffness of 0.00783 for a retina-choroid-sclera layer region of interest.

“Our qualitative and semiquantitative measure of posterior eye wall strain shows promise as an imaging biomarker identifying regions in myopic eyes that are less stiff and more susceptible to deformability that, when combined with other metrics (axial length, spherical error), may help assess at an early stage the risk of progression of a stable high myopia eye to pathologic myopia with staphyloma,” the study authors concluded in their abstract.

## CHALAZION

More information is needed to better understand the variables associated with chalazion diagnosis and surgical intervention. A recent study analyzed chalazion patients and healthy controls to identify common risk factors.<sup>15</sup>

A large United States claims database of 134,959 chalazion patients was compared 1:5 with matched controls (6,878,160). The researchers identified the variables correlated with diagnosis and surgical excision.

The data revealed that **risk factors linked to chalazion diagnosis**

included female sex, non-white race, Northeast location and smoking. An increased risk was also associated with conditions that affect the periocular skin and tear film, such as blepharitis, MGD, rosacea and pterygium, as well as several non-ocular inflammatory conditions. These included gastritis, inflammatory bowel disease, sarcoidosis, seborrheic dermatitis and Grave's disease. Conversely, diabetes and systemic sclerosis reduced the odds of diagnosis.

**The likelihood of undergoing surgery for chalazion was increased among male patients as well as those with rosacea.** Anxiety, diabetes, gastritis, seborrheic dermatitis, Sjögren's syndrome and smoking decreased the odds of surgical intervention.

"This prompts further study of these variables and their relationship to chalazion diagnosis to understand physiology and improve clinical outcomes," the authors concluded.

## OCULAR INFECTION

The newest Antibiotic Resistance Monitoring in Ocular microorganisms (ARMOR) study data helps inform clinicians when choosing a therapy. Two analyses of the ongoing study found that this resistance remains prevalent.

A nationwide surveillance study of *in vitro* antibacterial resistance levels among ocular pathogens, ARMOR is currently in its 13th year. As part of this trial, *Staphylococcus aureus* and coagulase-negative staphylococci (CoNS) from ocular infections were collected each year and sent to a laboratory to confirm the species.<sup>16</sup>

In one analysis, researchers examined longitudinal trends of the staphylococcal isolates collected, which included 2,847 *S. aureus* and 2,416 CoNS. Over the course of the 13-year collection period, data revealed that methicillin/oxacillin resistance decreased among both

*S. aureus* and CoNS.<sup>16</sup> The study authors also observed decreases in resistance for azithromycin, ciprofloxacin and tobramycin among *S. aureus* and for ciprofloxacin among CoNS.

The researchers reported increases in resistance for chloramphenicol among *S. aureus* and for trimethoprim among CoNS. **When examining the staphylococci collected in 2021 specifically, they found that more than 80% of methicillin-resistant isolates exhibited resistance to three or more antibiotic classes.**<sup>16</sup>

Preliminary findings from an analysis of 446 isolates collected in 2021 were also presented. Among *S. aureus*, *in vitro* resistance was 53% to azithromycin, 37% to oxacillin/methicillin and 31% to ciprofloxacin. Among CoNS, *in vitro* resistance was 60% to azithromycin, 37% to oxacillin/methicillin, 20% to ciprofloxacin and 29% to trimethoprim.<sup>17</sup>

The data showed multi-drug resistance among 32% of *S. aureus* and 40% of CoNS isolates. Additionally, the rate of multi-drug resistance more than doubled in methicillin-resistant isolates. These initial findings revealed **high rates of *in vitro* antibiotic resistance in ocular staphylococci collected in 2021 and are consistent with 2020 ARMOR data**, according to the investigators.

"Analyses of antibiotic resistance among staphylococci collected over 13 years in ARMOR indicate that ***in vitro* resistance has decreased only slightly over this timeframe for several antibiotics and is still prevalent in 2021**," the study authors wrote in their abstract.<sup>17</sup> "Although the clinical relevance of *in vitro* data is unclear without consideration of the ocular pharmacokinetics of tested antibiotics, these findings warrant attention when choosing empiric therapy for the management of ocular staphylococcal infections."

**T**hese informative findings will help ODs devise new ways to help their patients. Check out ARVO's full listing of abstracts and posters to see for yourself the latest advances in eye and vision care. [RCLL](#)

1. Wang C, Yue J, Niu Y, et al. Ocular antibiotics susceptibility of multidrug-resistant *Staphylococcus* isolated from ocular anterior segment. ARVO 2022 annual meeting.
2. Karamichos D, Escandon P, Nicholas S, et al. The surprising impact of hormones on keratoconus. ARVO 2022 annual meeting.
3. Shane J, Rigas Y, Shanks R, St. Leger A. Probiotics: cytokine producing therapeutic ocular commensals. ARVO 2022 annual meeting.
4. Quiroga-Garza M, Ortiz Morales, Bastán-Fabián D, et al. Prevalence of corneal endothelial pleomorphism, polymegathism and guttata in a Hispanic population. 2022 ARVO annual meeting.
5. Lama H, Bourges JL, Brézín A. Collecting data from a social network as a new method to explore recurrent corneal erosions syndrome. ARVO 2022 annual meeting.
6. Parikh M, Pang Y, Sicks L. Risk factors for meibomian gland morphology changes in children aged 4 to 18 years. ARVO 2022 annual meeting.
7. Nguyen B, Meer E, Gupta A, et al. The effect of finasteride on dry eye disease. ARVO 2022 annual meeting.
8. Magno M, Moschowits E, Beining M, et al. The relationship between adherence to a Mediterranean diet and dry eye disease. ARVO 2022 annual meeting.
9. Toyos M, Wirta D, Goosey J, et al. Phase II study of the efficacy and safety of recombinant human nerve growth factor (rhNGF) in patients with moderate-to-severe dry eye. ARVO 2022 annual meeting.
10. Schaefer L, Midani F, Trujillo-Vargas C, et al. Metagenomic sequencing of Sjögren syndrome and healthy gut microbiota reveals differential bacterial species that correlate with disease severity. ARVO 2022 annual meeting.
11. Chang C, Somohano K, Zemsky C, et al. Topical glaucoma therapy is associated with alterations of the ocular surface microbiome. ARVO 2022 annual meeting.
12. Lin Z, Lan W, Wen L, et al. Two-years evolution of two-dimensional peripheral refraction in children. ARVO 2022 annual meeting.
13. Summers J, Soriano D, Martinez E. Emmetropization is associated with a modified inflammatory response in the eye. ARVO 2022 annual meeting.
14. Lim SY, Ito K, Dan YS, et al. Assessment of stiffness of posterior eye wall in myopic eyes with an ultrasound-based algorithm using strain elastography. ARVO 2022 annual meeting.
15. Kim D, McGeehan B, Briceno C, et al. Demographic variables and systemic comorbidities associated with diagnosis of chalazion and chalazion incision/excision from a US claims database. ARVO 2022 annual meeting.
16. Asbell P, Sanfilippo C, DeCory H. Antibiotic resistance among ocular staphylococcal pathogens: longitudinal trends in the ARMOR study. ARVO 2022 annual meeting.
17. Sanfilippo C, DeCory H, Asbell P. Preliminary antibiotic resistance data among ocular bacterial pathogens in the ARMOR 2021 study. ARVO 2022 annual meeting.



# THE SPECTRUM OF ALLERGIC OCULAR DISEASES

A breakdown of the science and treatments for these common conditions.

By Milton Hom, OD

**W**hen we think of allergy, we think of inflammation. We often consider inflammation a bad thing, but in actuality it's a good thing—part of the natural process. Without it, we have no healing, and inflammation is necessary to start the healing process. But what is the difference between good and bad inflammation? Time. Inflammation is meant to go away, but when it becomes chronic and doesn't leave, it becomes a bad thing.

Allergy is chronic inflammation. It goes on and on and, many times, it becomes worse—this is known as the allergy cascade. Allergy is a glitch in the immune system, as it doesn't work as it was meant to. Inflammation is triggered but does not stop; it keeps going.

Our immune system is our defense against pathogens, microbial antigens, allergens and other threats. When a pathogen is present, our immune system kicks in. The first line of defense is physical, with one response being to itch and rub our eyes. Rubbing our eyes is meant to physically remove the pathogen that is invading. In the case of allergy, it is usually grains of pollen. Itch is part of the physical defense system. Of

course, in the case of allergic conjunctivitis, the itch becomes chronic because there is the glitch.

Once a pathogen gets into the eye, another defensive physical action would be to flush it out. When irritation hits, one reaction is to wash it out. For the ocular surface, there is a built-in plumbing system: the pathogen enters, irritates the eyes and tear flushing happens, which is why our eyes get watery.

Using fluid on the external surface is one manner of getting rid of a allergen. Internal fluid is another method. A defensive move of the immune system is to send fluid to the point of attack, which physically blocks the invader. It also serves to help send inflammatory cells to the point of attack. Inflammatory cells are the soldiers that combat the pathogen, and sending fluid to the area manifests as swelling.

Getting the inflammatory cells to the right location requires efficient transport. They need open pathways (blood vessels) to get to their destination. When called upon, the inflammatory cells travel through the vessels to the point of attack. In order to facilitate this, the vessels get larger or widen. We see this clinically as hyperemia or redness (*Figure 1*).

All of these immune defense strategies comprise the signs and symptoms we see in allergic conjunctivitis: itch, watery, swelling and redness. Many times vital dyes staining, such as lissamine green and fluorescein, will also be seen (*Figures 2 and 3*).

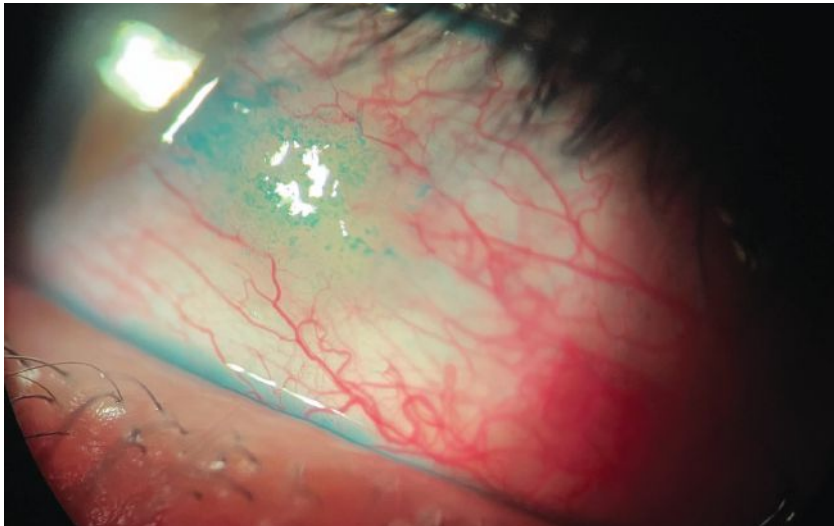
## OCULAR ALLERGY

Itching, wateriness, swelling and redness are all domains in the Total Ocular Symptom Score (TOSS) questionnaire.<sup>1,2</sup> TOSS is part of new guideline recently published in *Annals of Allergy, Asthma and Immunology*, the official publication of the American College of Asthma Allergy and Immunology.<sup>3</sup> I was part of their ocular allergy committee that created a guideline for treatment and management of allergic conjunctivitis geared for allergists (or as some of them prefer to be referred to, clinical immunologists).

## ABOUT THE AUTHOR



Dr. Hom is an internationally recognized expert and researcher in therapeutics, dry eye, contact lenses, allergy and glaucoma. He has written four books and published over 200 papers and peer-reviewed abstracts. He does research support for AbbVie, Allergan, Novartis, Vyluma and Surface Pharmaceuticals.



**Redness seen in ocular allergy. This patient also had a pinguecula and lissamine green staining.**

Ocular allergy affects 36% of the United States population, and it worsens each year.<sup>4,5</sup> The classifications of the disease are seasonal allergic conjunctivitis (SAC), perennial allergic conjunctivitis (PAC), vernal keratoconjunctivitis (VKC), atopic keratoconjunctivitis (AKC) and contact blepharoconjunctivitis, with 95% to 98% of cases being SAC and PAC.<sup>6</sup> Allergic conjunctivitis symptoms overlap with those of dry eye—more than 50% of patients with ocular allergy also having dry eye.<sup>7</sup> Differentials also include irritative conjunctivitis, *Demodex* and infectious conjunctivitis, among others.

Allergists depend on many different testing modalities, most not specific to the eye. Skin prick testing is the first-line approach to diagnose immunoglobulin E (IgE)-mediated sensitivity owing to its sensitivity, efficacy, safety and feasibility, and is performed for pollens, mites, animal dander and mold.<sup>8,9</sup> Blood tests such as serum-specific IgE measurements should be considered when skin prick testing is inconsistent with the patient history, cannot be performed or to quantify specific IgE to naive allergens.<sup>9</sup>

Simple allergen avoidance measures such as eyewear protection, frequent washing of clothes, hypoallergenic bedding and bathing before bedtime may all help to halt disease progression. It's also helpful to reduce exposure to pet dander by keeping animals out of the bedroom and using both high-efficiency particulate absorbing (HEPA) air filters and HEPA vacuums; using just an air filter or vacuum alone is not as effective as both.

Telling patients to avoid eye rubbing is easier said than done. They will unknowingly rub their eyes at night when sleeping, which is even more reason to prescribe an allergy drop. Some practitioners recommend washing hair regularly, but that can be quite time consuming for some patients. Instead, we recommend covering their hair if washing is too difficult.

Cold compresses and refrigerated artificial tears may also provide symptomatic relief.<sup>10</sup> Avoidance and non-pharmaceutical interventions are preferred by some patients. I have found younger adults are more likely to try non-pharmaceutical treatments first before drug therapies.

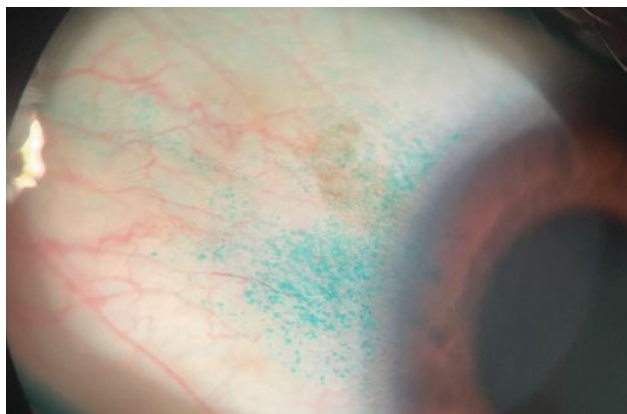
## TREATMENTS

There are numerous treatment options for ocular allergy. Refrigerated artificial tears help wash away allergens and dilute inflammatory mediators on the eye. Preservative-free compounds are preferred to minimize toxic effects. Artificial tears may be low, mid or high viscosity. Low-viscosity tears, usually prescribed for mild conditions, cause little interference with vision and offer great comfort. However, with a low residence time, the retention of benefits is less than mid or higher viscosity tears. The latter have greater blurring effects, however, and are reserved for more severe cases. They can be best used at night.<sup>9,10</sup>

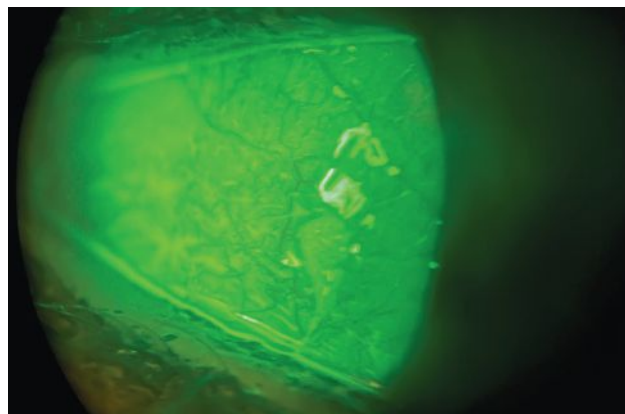
Ocular decongestants are usually over-the-counter and can reduce ocular erythema, but unfortunately, they have little effect on decreasing itching. Personally, we rarely prescribe ocular decongestants, if at all.

Oral antihistamines are frequently used by patients before seeking medical attention; however, the use and especially overuse of oral antihistamines—particularly first-generation antihistamines—may worsen dry eye syndrome.<sup>9</sup> Topical antihistamines are preferable to oral forms because of rapid onset and relief. With their high efficacy and safety margin, topical antihistamines are often used as first-line treatment for allergic conjunctivitis.

Singulair (montelukast, Merck) has been reported to be more efficacious than placebo in treating seasonal allergic conjunctivitis.<sup>11</sup> Mast cell (MC) stabilizers inhibit degranulation of MCs and prevent the release of mast cell mediators. With the availability of newer agents that possess both antihistamine and MC-stabilizing properties, the use of single-action MC stabilizers is not prescribed often. Many newer topical ophthalmic drugs work both as antihistamines and MC stabilizers.



Lissamine green staining in allergic conjunctivitis.



Fluorescein staining in allergic conjunctivitis with dry eye.

They require less frequent instillation owing to longer duration of action and have better tolerability than single-action antihistamines.<sup>12</sup>

Topical non-steroidal anti-inflammatory drugs, such as ketorolac (Toradol, Sagent Pharmaceuticals), is FDA-approved to treat SAC.<sup>9</sup> These drugs have pretty much fallen off the map in terms of prescribing for allergic conjunctivitis, but topical steroids are highly efficient. Older ocular corticosteroids such as prednisolone, dexamethasone or fluorometholone may induce cataract formation and IOP spikes. Loteprednol, in which the ketone group at carbon-20 has been substituted with an ester group, does not increase the risk of cataracts, but these drugs also may be associated with IOP spikes.<sup>12</sup>

Topical calcineurin inhibitors such as cyclosporine or tacrolimus may be considered in severe or refractory allergic conjunctivitis, VKC and AKC.<sup>13</sup> I routinely prescribe cyclosporine or other dry eye medications for allergic conjunctivitis, usually in concert with an antihistamine or antihistamine MC stabilizing drop.

As previously mentioned, most of ocular allergy also has a dry eye component. Prescribing both a dry eye and allergy topical medication will treat both conditions simultaneously; I have found this approach highly efficacious.

### IMMUNOTHERAPY

This treatment is outside the range of most eye care professionals, but on the flip side, it's the backbone treatment for clinical immunologists. It is a good option for patients with inadequate symptom control. Despite using pharmacotherapy and allergen avoidance, immunotherapy can work when those fail. Sometimes, patients are unable to tolerate medications or find long-term compliance difficult. These patients can also be successful with immunotherapy.

There are currently two modalities for allergen immunotherapy: subcutaneous and sublingual. Three sublingual therapy tablets have been approved by FDA, which can probably be prescribed by some ODs in certain states: Grastek (Timothy extract), Oralair (cross-reacting sweet vernal, orchard, perennial rye) and Ragwitek (ragweed extract).

Allergen immunotherapy increases the sensitivity threshold and helps decrease ocular symptoms and medication use.<sup>11</sup> My personal experience with immunotherapy has been highly successful. After suffering with allergies since childhood, immunotherapy greatly reduced my symptoms over the course of treatment and it was efficient at helping ocular allergy symptoms, too. Immunotherapy also is an opportunity to promote a team

approach with pediatricians and allergists.

There is controversy among allergists regarding management by those who aren't allergy-trained. Companies offer to come into non-allergy practices and set up skin prick testing along with immunotherapy. The controversy lies in the outcomes of these set-ups. Allergists contend the amount of allergen used is minimal and not very effective. The reasoning behind using minimal amounts is to avoid anaphylaxis in non-allergy practices, but outcomes are not as efficient as when it is closely monitored by an allergist.

### MAINTENANCE THERAPY

Within my area of practice, SAC and PAC seem to have merged into one subtype. As a result, we have many patients on topical maintenance therapy. Because of the high safety margin of topical antihistamines and combination drops, maintenance therapy is very safe.

What are the advantages? As stated previously, there is something called the allergy cascade. In the early stages, allergy can be mild, but as time goes on, the condition (left untreated) worsens; more inflammation yields more inflammation. The key is to keep chronic conditions under control. When uncontrolled, greater severity happens. I tell my



**Table 1. Preservative-free Ocular Lubricants**

Category	Brand name	OTC or Rx	Dosing
CMC containing	<i>Allergan:</i> Refresh Optive, Refresh Optive Advanced, Refresh Tears Plus, Refresh Liquigel, Refresh Celluvisc. <i>TheraTears:</i> TheraTears	OTC	As needed
HPMC containing	<i>Alcon:</i> Tears Naturale Free, Bion Tears	OTC	As needed
Hyaluronic acid containing	<i>J&amp;J:</i> Blink Tears. <i>Hylo Eye Care:</i> Hylo-Comod, Hylo-Tear, Hylo-Fresh, Hylo Gel, Hylo-Care, Hylo-Parin (also contains heparin), Hylo-Dual	OTC	TID/as needed
Glycerin containing	<i>Oasis Tears:</i> Oasis Tears, Oasis Tears Plus. <i>Allergan:</i> Refresh Optive, Refresh Optive Advanced, Refresh Digital	OTC	As needed
Mineral oil or petrolatum containing (ointments)	<i>Akorn:</i> Akwa Tears. <i>Allergan:</i> Refresh PM, <i>Bausch + Lomb:</i> Soothe XP. <i>Alcon:</i> Systane Nighttime	OTC	Once a day at bedtime
Polyethylene glycol containing	<i>J&amp;J:</i> Blink Tears. <i>Alcon:</i> Systane, Systane Ultra	OTC	As needed
PVA containing	Refresh classic, Optics mini drops	OTC	As needed

patients that maintenance therapy will save a lot of time and prevent suffering. Life is much easier for both the patient and doctor when ocular allergy is kept under control with maintenance therapy.

Keep in mind that there will be times when flare-ups occur. When we see these in allergic conjunctivitis, we usually add a topical steroid such as loteprednol BID and we always keep immunotherapy as an option. Future directions for treatment include leukotrienes blockers, platelet activating factor inhibitors (ISV-611), anti-IgE therapy—primarily to reduce and diminish the amount of allergen/antibody response—and regulation of adhesion molecules and chemokines (ICAM-1, ICAM-3, VCAM-1).

Now that you understand the clinical implications of ocular allergy, it's time to implement this knowledge into your practice and help get your patients' symptoms under control with the many treatments and therapies available today. [RCLL](#)

- Bielory L. Ocular symptom reduction in patients with seasonal allergic rhinitis treated with the intranasal corticosteroid mometasone furoate. *Ann Allergy Asthma Immunol.* 2008;100(3):272-9.
- Bielory L, Hom M, Nguyen A. Relationship between TOSS questionnaire and two dry eye questionnaires (OSDI and SEsoD). *Invest Ophthalmol Vis Sci.* 2012;53:537.
- Rodrigues J, Kuruvilla ME, Vanijcharoenkarn K, et al. The spectrum of allergic ocular diseases. *Ann Allergy Asthma Immunol.* 2021;126(3):240-54.
- Singh K, Axelrod S, Bielory L. The epidemiology of ocular and nasal allergy in the United States, 1988-1994. *J Allergy Clin Immunol.* 2010;126(4):778-83.e6.
- Meng Q, Nagarajan S, Son Y, et al. Asthma, ocular symptoms and skin test sensitivity across National Health and Nutrition Examination

- Surveys. *Ann Allergy Asthma Immunol.* 2016;116(2):118-25.e5.
- Ono SJ, Abelson MB. Allergic conjunctivitis: update on pathophysiology and prospects for future treatment. *J Allergy Clin Immunol.* 2005;115(1):118-22.
- Hom MM, Nguyen AL, Bielory L. Allergic conjunctivitis and dry eye syndrome. *Ann Allergy Asthma Immunol.* 2012;108(3):163-6.
- Cibella F, Ferrante G, Cuttitta G, et al. The burden of rhinitis and rhinoconjunctivitis in adolescents. *Allergy Asthma Immunol Res.* 2015;7(1):44-50.
- Leonardi A, Bogacka E, Fauquert JL, et al. Ocular allergy: recognizing and diagnosing hypersensitivity disorders of the ocular surface. *Allergy.* 2012;67(11):1327-37.
- Varu DM, Rhee MK, Akpek EK, et al. Conjunctivitis preferred practice pattern. *Ophthalmology.* 2019;126(1):P94-169.
- Gane J, Buckley R. Leukotriene receptor antagonists in allergic eye disease: a systematic review and meta-analysis. *J Allergy Clin Immunol Pract.* 2013;1(1):65-74.
- Bielory L, Meltzer EO, Nichols KK, et al. An algorithm for the management of allergic conjunctivitis. *Allergy Asthma Proc.* 2013;34(5):408-20.
- Cornish KS, Gregory ME, Ramaesh K. Systemic cyclosporin A in severe atopic keratoconjunctivitis. *Eur J Ophthalmol.* 2010;20(5):844-51.

**Table 2. Selected Artificial Tears by Viscosity**

Low viscosity	Medium viscosity	High viscosity	Emulsion
Alcon: Systane Ultra and Classic, Tears Naturale  Allergan: Refresh Tears, Refresh Optive, Refresh Plus, Refresh Relieva  TheraTears: TheraTears  J&J: Blink Tears	Allergan: Refresh Gel drops, Refresh Liquigel  Alcon: Systane Gel drops	Allergan: Refresh Celluvisc, Refresh PM  Alcon: Systane Nighttime (eye ointment)	Bausch Health: Soothe XP  Allergan: Refresh Mega 3, Refresh Optive Advanced, Refresh Digital  Alcon: Systane Balance, Systane Complete  Santen: FreshKote

# BEST PRACTICES IN CONTACT LENS CARE

Patient education on storage, handling and application goes a long way.

By Manveen Bedi, OD

Contact lens care is a complex topic. With a recent surge in contact lens brand, modality and solution availability, there are important considerations at play in determining an optimal contact lens care regimen for patients to enhance comfort, maintain ocular surface health and reduce contact lens dropout. Despite the increasing trend toward fitting soft daily disposable contact lenses, there are still patients continuing with bi-weekly and monthly soft lenses, as well as those wearing custom soft lenses for aphakia with a quarterly replacement schedule.

Annual modalities include hybrid lenses and rigid gas permeable (GP) lenses such as corneal and scleral GPs. Different lenses with different replacement schedules necessitate an understanding of the associated care regimens to reduce patient discomfort, lens dropout and adverse events such as microbial keratitis (MK) and inflammatory events.

## SOFT CONTACT LENS SOLUTIONS

With daily disposable contact lens use on the rise, we have even

more of a duty to our patients who rely on biweekly, monthly and quarterly soft lens modalities. For instance, pediatric patients with congenital pathologies and patients with high refractive powers outside the range of dailies are often fitted in monthly to quarterly soft lenses for vision rehabilitation. This increases the importance of prioritizing lens disinfection to prevent incidences of MK and ocular surface compromise.

**Multipurpose solution (MPS).** This option is excellent for its ease and convenience of use. However, there has been an ongoing debate on the biocompatibility of soft contact lens material and these solutions and their impact on corneal health. Corneal staining grids across multiple lens brands and solution types highlight the solution-induced corneal staining after two to four hours of lens wear.<sup>1,2</sup> Initially, it was believed that solutions with PHMB preservatives were the cause of damaged epithelial cells resulting in corneal staining. However, further research shows that MPS can cause alterations to the cell membrane in its uptake of fluorescein without causing cell death.<sup>3,4</sup> Another study

noted that the surfactants, not the preservatives, impact the active transport of fluorescein across the epithelial membrane.<sup>5</sup>

MPS is a one-step system that is effective in cleaning, disinfecting and storing contact lenses. The different formulations play a significant role in improving patient comfort, minimizing risk of ocular infection and optimizing longer wear time with wetting agents. The presence of buffers, surfactants and chelators optimizes compatibility of the solution with the tear film to allow for homeostasis of the ocular surface.<sup>6</sup> Some products have received FDA clearance for rinse-only instead of the traditional rub and rinse technique; however, studies have shown that rinse-only MPS is ineffective in removing

## ABOUT THE AUTHOR

Dr. Bedi completed a residency in cornea and contact lenses at the Southern California College of Optometry at Marshall B. Ketchum University after graduating from the Illinois College of Optometry. She focused on specialty contact lens fitting for corneal pathologies, aphakia and prosthetics. She is a fellow of both the Scleral Lens Society and the American Academy of Optometry.



### The IER Matrix Study: Corneal Staining

*Solution-Induced Corneal Staining per Month with the Combination\**

Lens/Solution	Clear Care	AQuify	Opti-Free Express	Opti-Free RepleniSH
Acuvue Advance	0.0%	0.9%	0.0%	0.0% (2W)
Acuvue Oasys	0.9% (2W)	2.6% (2W)	6.2%	7.1% (2W)
O <sub>2</sub> Optix	0.5%	3.2%	5.9%	6.7%
PureVision	0.9%	23.2%	11.3%	14.2%
Night & Day	1.7%	0.9%	7.2%	6.7%

■ Lower quartile ■ Inner two quartiles ■ Upper quartile

\*percentage of patients per month showing lens care-related staining in the first three months of lens wear 2W=two weekly replacement

#### Corneal staining occurs as a result of an incompatibility between the lens solution and material.

protein deposits from the lens surface, leaving up to 40% behind.<sup>7-10</sup> Presence of denatured proteins on the lens surface can result in clinically significant concerns such as contact lens-induced papillary conjunctivitis.<sup>9</sup> The newer generation of MPS contains dual disinfectants, which boast excellent biocompatibility and a robust disinfection and cleaning capability.<sup>11</sup>

**Hydrogen peroxide.** This other popular system is a great choice for soft, hybrid and GP lenses. The stabilized 3% hydrogen peroxide system is protective against bacteria, viruses, fungi and protozoan through oxidation.<sup>12-14</sup> Unlike some MPS, it is effective and can penetrate several microbial biofilms.<sup>15</sup>

The main concerns with this disinfection system are twofold: chemical burn of the ocular surface in cases of incomplete neutralization of the peroxide and potential contamination of lenses that are bathed in neutralized, unpreserved solution following completion of the neutralization process. Therefore, it is important to educate patients about the proper way to use the solution and discuss re-disinfecting the lenses if they are left soaking in the solution for longer than one to two days.<sup>16</sup> This

system is perfect for patients with ocular allergies and sensitivities as they might develop a delayed hypersensitivity response to preservatives and other agents in MPS.

#### HYBRID CONTACT LENS SOLUTIONS

The unique category of lenses that have a rigid GP center and a surrounding soft skirt are known as hybrids. These lenses are compatible with hydrogen peroxide or MPS approved for soft contact lenses. For patients with concerns of lens deposits, soft lens daily cleaners can be added to the regimen for thorough lens disinfection. Caution is needed when using abrasive or alcohol-based cleaners as they can strip the hybrid lens surface coating.

#### GP CONTACT LENS SOLUTIONS

Similar to soft contact lenses, GP lenses require a good disinfecting and conditioning regimen to improve their longevity, provide comfort and minimize the risk of infection. Since these lenses have an annual replacement schedule, it becomes even more important to thoroughly educate patients on lens hygiene and care.

**One-step MPS.** Similar to soft lenses, solutions for GP lenses have also headed toward multipurpose cleaners. All-in-one products that allow for cleaning, disinfecting, conditioning and rinsing provide ease and convenience for patients. One-step MPS usually contains preservatives, viscosity and cushioning agents to improve surface wettability and a low concentration of surfactants.<sup>10,16-18</sup>

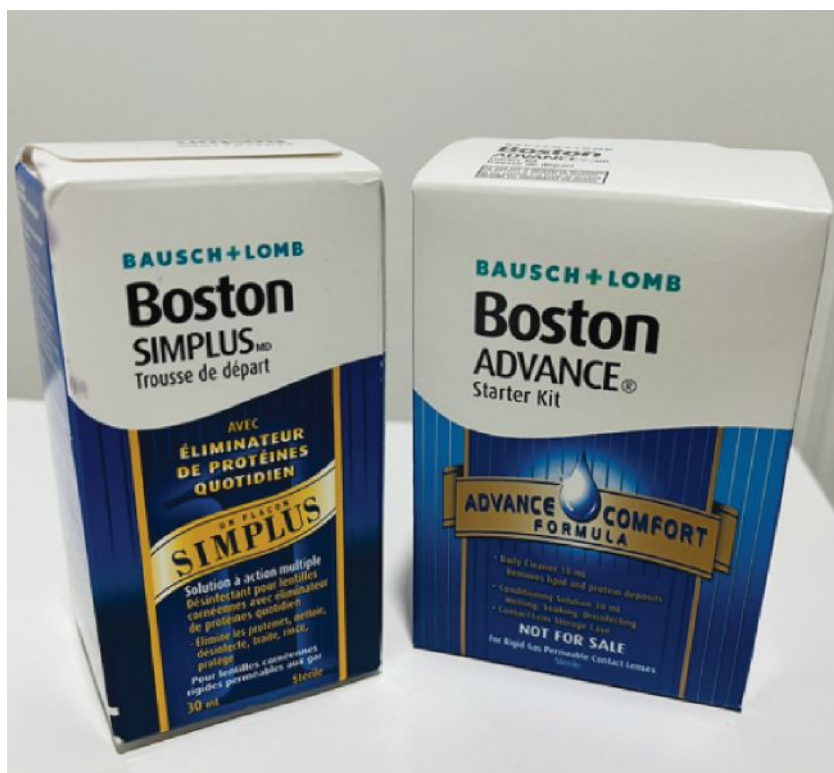These products are especially helpful when working with children who require

GP lenses for ocular pathologies or orthokeratology lenses. Since MPS is generally non-abrasive in nature, it is compatible with lens coatings on corneal and scleral GPs such as plasma treatment and polyethylene glycol (PEG) surface coating.<sup>10</sup> However, caution should be taken when working with patients with a pre-existing history of ocular allergies and sensitivities as they may experience adverse effects with the preservatives in MPS.

#### Multistep cleaning system.

There are a range of multistep products. Two-step GP lens cleaning systems involve the use of a cleaning solution and a disinfecting/conditioning agent. Usually the cleaning solution is an abrasive, concentrated surfactant solution containing silica gel beads that maximize cleaning but are incompatible with plasma and PEG surface treatments. Some manufacturers offer three-step systems that involve a cleaning/disinfecting/soaking solution containing benzyl alcohol, an extra-strength cleaner and a wetting solution. The soaking solution needs to be rinsed off and the lenses need to be re-wetted with the wetting solution prior to use. The presence of benzyl alcohol

## BEST PRACTICES IN CONTACT LENS CARE



For GP lenses, Boston Simplus is a one-step multipurpose system, whereas Boston Advance is a multistep cleaning system.

makes the cleaner effective against lipid deposits.<sup>10,16-18</sup>

Multistep systems are an excellent choice for patients with ocular surface disease that results in heavy protein and lipid deposits on the lens surface. In addition, the use of extra-strength cleaners may prevent the long-term deposit buildup on the lens surface that can reduce the lifespan of the lens and may require more frequent replacement.

**Protein cleaners.** Contact lens materials have changed dramatically over the past few years. The addition of silicone-containing monomers resulted in increased oxygen permeability of the lens; however, it also increased the material's propensity for protein deposits.<sup>19</sup> With the newer fluoro-silicone materials, there is improved oxygen permeability with the added advantage of the ma-

terial's ability to resist mucin and other deposits.<sup>19</sup> However, patients with ocular surface disease have a tear film imbalance that can result in surface buildup with long-term wear.

Daily protein removers and treatments like a 30-minute progent procedure are effective in removing lens deposits. Progent treatment can be performed bi-weekly at home for clearing protein buildup and disinfecting against viruses, *Acanthamoeba* and other microorganisms.

### DIGITAL CONTACT LENS RUBBING

This method can remove dirt, debris and cosmetics that might adhere to the lens surface (both soft and GP lenses). There is strong evidence that digital rubbing of lenses can help with removing biofilms and preventing

*Acanthamoeba*, *Pseudomonas aeruginosa*, *Staphylococcus aureus*, *Fusarium solani* and *Candida albicans*.<sup>20,21</sup> One study examined the amoebicidal activity of disinfecting agents containing hydrogen peroxide, chlorhexidine, thimerosal, chlorhexidine, thimerosal-polyquaternium and polyaminopropyl biguanide-ploxamine.<sup>22</sup> The researchers noted that the cleaning agents were ineffective in removing all *Acanthamoeba* cysts during the 17-hour experiment and reinforced the need for mechanical rubbing of the lenses.<sup>22</sup> Rubbing the lens surface for approximately 10 seconds on each side is usually recommended for thorough cleaning.

### CONTACT LENS CASE REPLACEMENT

Contact lens cases contain microorganisms such as micrococcaceae *Pseudomonadaceae*, *Enterobacteriaceae* and amoeba. Improper handling of contact lenses can result in contamination and corneal infection.<sup>23</sup> The incidence of microbial burden within storage cases ranges from 24% to 81%.<sup>24</sup>

Once a biofilm forms from coalesced microbial colonies, it creates resistance to lens care products. Studies have shown that the polyquaternium-preserved solution is effective in reducing transfer of bacterial microbes from a lens case to a silicone hydrogel lens that was soaked in the case.<sup>24,25</sup> Frequent lens case replacement can prevent microbial activity and reduce the risk of MK.<sup>6</sup>

### TAKEAWAYS

Contact lens hygiene and care is a crucial part of the contact lens fitting process. Not all solutions are made the same way, and patients can develop sensitivities or reactions to certain chemicals in them.

Working with patients to develop a customized cleaning regimen to fit their personal needs can make a world of difference. Education on solution options, digital rubbing and replacement schedules helps build a strong foundation for good habits, patient compliance and minimized risks. **RCCL**

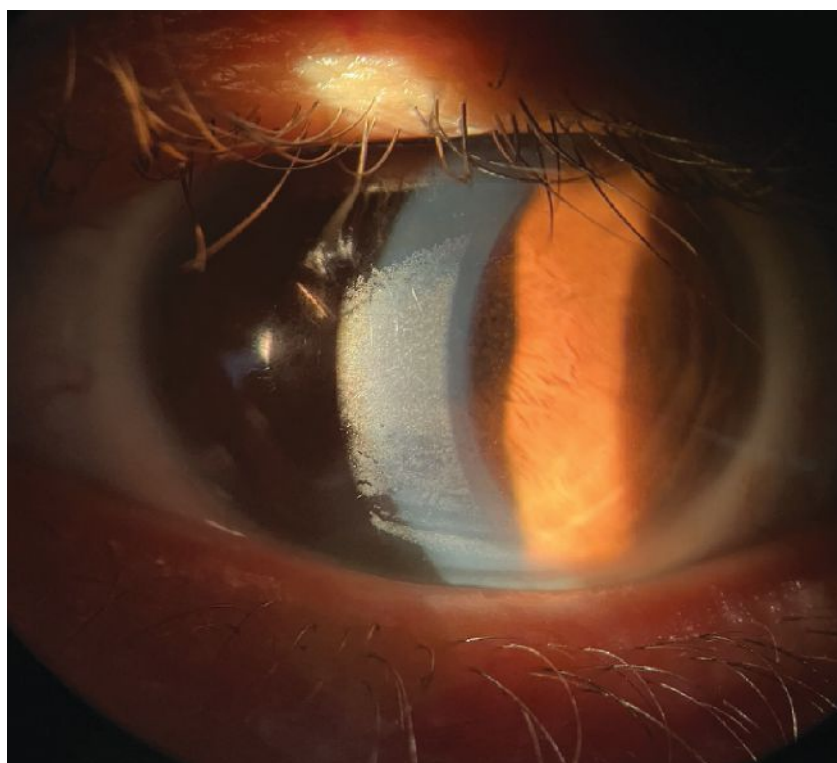1. Andrasko G, Ryen K. Corneal staining and comfort observed with traditional and silicone hydrogel lenses and multipurpose solution combinations. *Optometry*. 2008;79(8):444-54.
2. Carnt N, Willcox MD, Evans V, et al. Corneal staining: the IER Matrix study. *Contact Lens Spectrum*. September 1, 2007.
3. Bandamwar KL, Papas EB, Garrett Q. Fluorescein staining and physiological state of corneal epithelial cells. *Cont Lens Anterior Eye*. 2014;37(3):213-23.
4. Bakkar MM, Hardaker L, March P, et al. The cellular basis for biocide-induced fluorescein hyperfluorescence in mammalian cell culture. *PLoS ONE*. 2014;9(1):e84427.
5. Khan TF, Price BL, Morgan PB, et al. Cellular fluorescein hyperfluorescence is dynamin-dependent and increased by Tetronic 1107 treatment. *Int J Biochem Cell Biol*. 2018;101:54-63.
6. Bright FV, Burke SE, Chalmers RL, et al. Contemporary research in contact lens care. *Cont Lens Anterior Eye*. 2013;36(S1):S22-7.

## Recommendations For Contact Lens Care

Keep these tips and tricks in mind when performing your care routine:

- Handwashing is key to maintaining good contact lens hygiene.
- Frequent replacement of contact lens storage cases helps to avoid buildup of biofilms.
- Digital rubbing of contact lens surfaces is important in removing debris and protein buildup on the surface.
- Using fresh disinfecting solution without introducing tap water makes for a more thorough cleaning.

7. Mok KH, Cheung RWL, Wong BKH, et al. Effectiveness of no-rub contact lens cleaning on protein removal: a pilot study. *Optom Vis Sci*. 2004;81(6):468-70.
8. Pucker AD, Nichols JJ. Impact of a rinse step on protein removal from silicone hydrogel contact lenses. *Optom Vis Sci*. 2009;86(8):943-7.
9. Eiden B. Does one contact lens solution fit all? *Review of Cornea & Contact Lenses*. May 18, 2011.
10. Quinn TG. Making sense of contact lens care. *Contact Lens Spectrum*. November 1, 2017.
11. Reindel W, Merchea MM, Rah MJ, Zhang L. Meta-analysis of the ocular biocompatibility of a new multipurpose lens care system. *Clin Ophthalmol*. 2013;7:2051-6.
12. Johnston SP, Sriram R, Qvarnstrom Y, et al. Resistance of *Acanthamoeba* cysts to disinfection in multiple contact lens solutions. *J Clin Microbiol*. 2009;47:2040-5.
13. Hughes R, Kilvington S. Comparison of hydrogen peroxide contact lens disinfection systems and solutions against *Acanthamoeba polyphaga*. *Antimicrob Agents Chemother*. 2001;45:2038-43.
14. Lever AM, Sutton SVW. Antimicrobial effects of hydrogen peroxide as an antiseptic and disinfectant. In: *Handbook of Disinfectants and Antiseptics*. Ascenzi JM, ed. CRC Press, 1995.
15. Linley E, Denyer S, McDonnell G, et al. Use of hydrogen peroxide as a biocide: new consideration of its mechanisms of biocidal action. *J Antimicrob Chemother*. 2012;67:1589-96.
16. Ward M. Corneal and scleral GP contact lens care. *Contact Lens Spectrum*. November 1, 2018.
17. Benoit DP. Proper care of modern GP lenses. *Contact Lens Spectrum*. May 1, 2015.
18. Watanabe RK, Rah MJ. Preventative contact lens care: Part III. *Contact Lens Spectrum*. August 1, 2001.
19. Young, R. The evolution of contact lens materials. *Contact Lens Spectrum*. November 1, 2017.
20. Zhu H, Bandara M, Kumar A, et al. Contribution of regimen steps to efficacy of multipurpose solutions used to disinfect silicone hydrogel contact lenses. XVIII International Congress of Eye Research, Beijing, September 24-29, 2008.
21. Butcko V, McMahon TT, Joslin CE, Jones L. Microbial keratitis and the role of rub and rinsing. *Eye Contact Lens*. 2007;33(6):421-3.
22. Cancrini G, Iori A, Mancino R. *Acanthamoeba* adherence to contact lenses, removal by rinsing procedures, and survival to some ophthalmic products. *Parasitologia*. 1998;40:275-8.
23. Pens CJ, Costa MD, Fadanelli C, et al. *Acanthamoeba* spp. and bacterial contamination in contact lens storage cases and the relationship to user profiles. *Parasitol Res*. 2008;103:1241-5.
24. Szczotka-Flynn LB, Pearlman E, Ghanoum M. Microbial contamination of contact lenses, lens care solutions, and their accessories: a literature review. *Eye Contact Lens*. 2010;36(2):116-29.
25. Vermeltfoort PB, Hooymans JM, Busscher HJ, et al. Bacterial transmission from lens storage cases to contact lenses—effects of lens care solutions and silver impregnation of cases. *J Biomed Mater Res B Appl Biomater*. 2008;87:237-43.



**Build-up on a scleral lens surface can form from a poor tear film.**



# FROM BASICS TO BIOLOGICS: SELECTING DROPS FOR EVERY DRY EYE PATIENT

Take a look at the indications and options for specific situations, from the rudimentary to the extreme.

By Mahnia Madan, OD, and Mark Eltis, OD

**A**ddressing meibomian gland dysfunction, and blepharitis in general, is the key to suppressing the inflammatory nature of dry eye disease (DED). However, artificial tears (ATs) still play a pivotal role in managing the condition. They are particularly effective at providing symptomatic relief to patients, especially during flare-ups. Advise DED patients to use tears regularly “like a lip balm” and not wait until their ocular surface is compromised and symptomatic. DED can’t easily be categorized in a binary classification of evaporative or aqueous deficient: TFOS DEWS II found up to 70% of sufferers have a mix of the two. Aside from symptomatic relief, artificial tears can reduce inflammation and help prevent epithelial cell death. When chosen carefully, eye drops can play a significant role in the management of dryness.

The amount of eye drops available can make selection overwhelming for a doctor (let alone a patient). Let’s explore some favorites and clarify when they are most appropriate. We will also simplify when it makes sense to turn to biological drops in the management of DED.

*Editor’s Note: Not all products discussed are available in the US.*

## DROPPING IN

Preservatives in multi-dose bottles are considered a necessary evil to contain bacterial replication and minimize contamination risk. However, they are counterproductive: an irritant is being introduced to an already compromised tear film and ocular surface. Preservative-free formulations are always superior but should be highly recommended for those using drops more than four times a day. Benzalkonium chloride and thimerosal formulations should be avoided at all costs.

Tear osmolarity can be used as a guideline for selecting AT viscosity. Moderate to severe DED often necessitates a thicker drop. Generally speaking, as viscosity increases the duration of effect of the drop increases—but so does the potential for blurred vision.

A relatively inexpensive and effective option for mild to moderate DED is *Systane Ultra Hydration (Alcon)*. It’s a moderately viscous drop that contains hyaluronate. Another ingredient, hydroxypropyl-guar (HP-Guar), interacts with the blinking motion to prolong on-eye contact time. HP-guar molecules bind preferentially to dried or compromised hydrophobic areas of the cornea, containing further

damage while epithelial cells regenerate. It forms a gel layer (acting as a mucomimetic), compensating for a compromised tear layer and reducing friction during blinks.<sup>1</sup>

Systane Ultra also comes in a single dose non-preserved option, which is substantially more expensive but highly recommended if using drops more than four times a day.

A top-shelf multi-dose preservative-free option for more advanced dry eye is *Hylo Dual Intense (Candorvision)*. It combines ectoine (a natural anti-allergy and anti-inflammatory agent) with a higher viscosity level (produced by a high concentration of heavier molecular

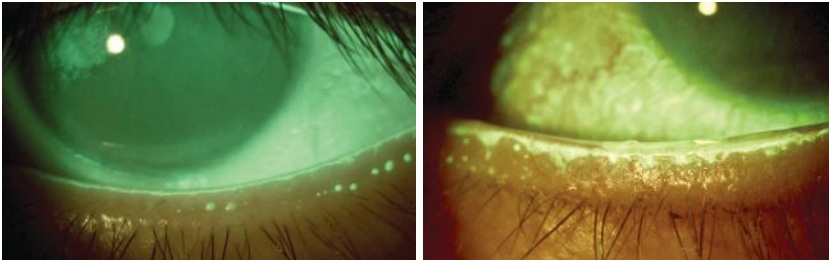
## ABOUT THE AUTHORS



Dr. Madan practices in Vancouver, is president of the British Columbia Doctors of Optometry and has pioneered a novel technique to produce PRP eye drops in her clinic. She frequently speaks on treatments for advanced dry eye disease. She has advisory positions for Lumenis, Labtician and Sun Pharmaceuticals.



Dr. Eltis, based in Toronto, has presented and published worldwide and has been sought as a medical-legal consultant. He is a Fellow of the American Academy of Optometry, a Diplomate of the American Board of Optometry and a member of the Optometric Glaucoma Society. He has advisory positions for CooperVision, Volk, Heine and Sun Pharma.



**Figs. 1A and B. Normal line of Marx highlighted by fluorescein stain (left). Irregular line of Marx displaced posteriorly (away from the bulbar conjunctiva) in chronic MGD.**

weight sodium hyaluronate) that does not blur vision. Ectoine has been found effective in DED and allergic conjunctivitis. It has even been shown to accelerate wound healing post-op.<sup>2</sup> The unique multi-dose pump does not allow air to penetrate the interior, keeping it safe for its six-month lifespan (once opened). When compared head-to-head with single-dose non-preserved options, this product's cost becomes more defensible.

**Thealoz Duo Gel (Labtician-Thea)**, a single unit preservative-free thicker gel, is an excellent bedtime option. It does not blur vision and is not oily. Trehalose (also found in Refresh Optive Mega 3) is an osmo-protectant designed to guard dried epithelial cells and stabilize their membranes. Simply put, trehalose protects against the destructive inflammatory cascade of DED. Sodium hyaluronate (as a glycosaminoglycan) enhances viscosity. Carbomer (a water-soluble polymeric resin) increases viscosity and maintains the hyaluronic acid and trehalose together in contact with the ocular surface for six hours without being sticky.<sup>3-5</sup> The single-unit dose does make it a more expensive option among the nighttime alternatives.

A unique product for MGD is preservative-free **Calmo spray (CandorVision)**. It is used with the eyes closed, which allows it to seep into the eye slowly, replicating meibomian gland secretions. It's also an excellent option for people who

hate putting drops into their eyes.

The product contains liposomes to replicate the oil-deficient layer in MGD sufferers and dexpanthenol (pro-vitamin B5), which moisturizes the eye and surrounding skin.

**Optase Hylo Night (Scope Health)** is a nighttime ointment that uses vitamin A to speed up epithelial healing.<sup>6</sup> It is preservative-free and good for mild to moderate dry eye. It is also phosphate free and good for six months once opened.

**Refresh Lacri-Lube ointment (Allergan)** is the go-to for very thick overnight coverage. It uses mineral oil as an ointment base that allows melting at body temperature and white petroleum as a lubricant.<sup>7</sup> If inserting the ointment in both eyes, patients need to be warned that it will blur them out for a sustained period. Ideally, they should already be in bed when inserting it, for safety.

The **Liposic (Bausch + Lomb)** line has been a reasonably priced option for decades. While MGD patients don't always respond to oil replenishment drops, this particular product has endured in both drop and

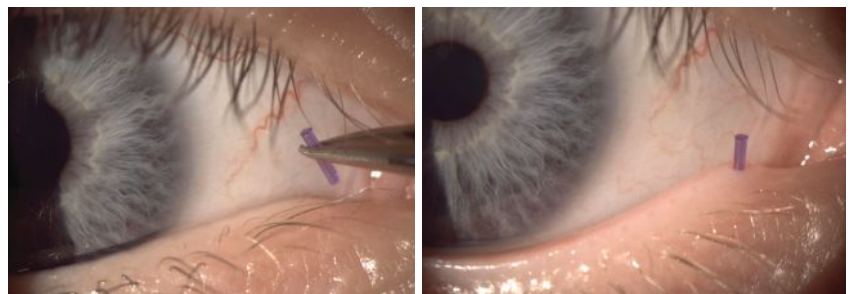
ointment form (for nighttime use). The drops contain carbomer, sorbitol, medium-chain triglycerides and cetrimide preservative. Liposic gel has sodium hydroxide, which closely mirrors tear pH, and attempts to replicate all three tear layers.

**Refresh Optive Mega-3 (Allergan)** is a single-dose preservative-free drop. As the name suggests, it contains omega-3 from flaxseed oil. Studies show that eye drops using emollients can increase lipid layer thickness for a short duration.<sup>8</sup> Omega-3 fatty acids are actually found in the normal tear film. Refresh Optive Mega-3 is formulated to minimize blur and does not require shaking. It is designed to replenish all three tear layers and is targeted towards MGD patients (like Systane complete and Retaine). Its lubricants include glycerin 1%, carboxymethylcellulose sodium 0.5% and polysorbate 80 (0.5%). These drops may be most helpful for patients with prolonged screen time, a lifestyle that decreases blinking and meibum secretion.<sup>8</sup>

There are many other excellent products on the market for DED. While there is no magic formula or perfect drop for every patient, a careful case history and an understanding (by both doctor and patient) that there will be some trial and error in finding the right products is key.

## WHEN TO PLUG?

Punctal occlusion to preserve tear volume was a more popular op-



**Fig. 2. Placing punctal plug in a lagophthalmos patient to increase tear volume.**

## FROM BASICS TO BIOLOGICS: SELECTING DROPS FOR EVERY DRY EYE PATIENT

tion when we thought DED was effectively an absence of tears. We now know inflammation is the root cause. Recent years have seen a reduction in punctal occlusion—the thought is that occlusion keeps inflammatory mediators in the eye.<sup>9</sup> However, the procedure should not be dismissed outright. It is still a key player in patients who have neurotrophic components, aqueous-deficient dry eye or non-resolving persistent epithelial defects (as in lagophthalmos patients). Increasing the tear volume can be extremely beneficial in these patients.<sup>10</sup>

Another benefit of punctal occlusion: it can increase the effectiveness of other medications used in the dry eye treatment, as it allows the drug to stay on the ocular surface longer. In one study, punctal plugs used with the cyclosporine group had longer symptom relief than either group treated separately.<sup>11</sup>

Before reaching for punctal plugs, though, manage ocular inflammation first with other methods. Punctal plugs are contraindicated when there are signs of active infection or allergies present (*Figures 1a and 1b*). Plugs are also not ideal in patients with blepharitis or meibomianitis, as they need management of their lid disease first.

Options range from dissolvable collagen inserts to more permanent silicone-type plugs. Temporary plugs can be used diagnostically to see if patients will benefit from longer plug use. Collagen plugs have a design advantage, too, as they lack the cap that is found in silicon plugs and can sometimes be irritating for patients (*Figure 2*).

Typically, plugs are placed in the lower puncta; however, all four can be plugged if needed. Punctal plugs may not have a significant impact when used alone in the treatment algorithm, but when combined with other treatment modalities, patients are likely to benefit. Current manufacturers include: *Odyssey, Katena, Lacrimedics* and others.

In the not so far future, we will be seeing punctal plug-based drug delivery systems for glaucoma, allergies and even dry eye. These will address compliance issues and are more convenient for patients. They also have the potential to reduce ocular surface and systemic side effects of drugs.

### BLOOD BIOLOGICS

For more severe dry eye sufferers, artificial lubricating drops are simply not enough. TFOS DEWS II reported that our natural tear film is a complex structure containing over 1,800 molecules that work together to not only form the most perfect lubricant, but the tear film also protects and nourishes the ocular surface. Our natural tears are epitheliotropic, which means they can support the proliferation, migration and differentiation of corneal and conjunctival cells.<sup>12</sup>

This is not something over-the-counter lubricating drops have been able to replicate.

When patients present with moderate to severe dry eyes with significant punctate keratitis, we can turn to blood biologics to help rescue and rehabilitate the ocular surface. The two common options are autologous serum eye drops (ASED) and platelet-rich plasma (PRP) eye drops.


Both have been successfully used in the treatment of moderate to severe DED; however, research suggests that PRP is superior in restoring the ocular surface.<sup>13</sup> This is because PRP contains platelets, which are considered the powerhouses for healing. Platelets are the first cells to arrive at the wound site; they adhere to damaged tissue and initiate a healing reaction that includes the release of a variety of cytokines and growth factors. Similar to the natural tear film, growth factors released by platelets have epitheliotropic properties and are responsible for cell growth, collagen production, cell adhesion and healing of corneal and conjunctival cells, thus improving signs and symptoms of DED.<sup>13,14</sup>

Platelets are eliminated in the production of ASED, decreasing its potency. ASEDs are often diluted before dispensing, which further reduces the growth factors (*Figure 3*).

Both ASED and PRP drops are particularly helpful in recalcitrant dry eye (*e.g.*, neuropathic and neurotrophic). PRP can help increase corneal nerve density lost in chronic DED.<sup>15</sup> It is beneficial in multiple conditions, including recurrent corneal erosions, persistent epithelial defects, post-LASIK dry eye and Sjögren's syndrome (*Figure 4*).<sup>13,14</sup>

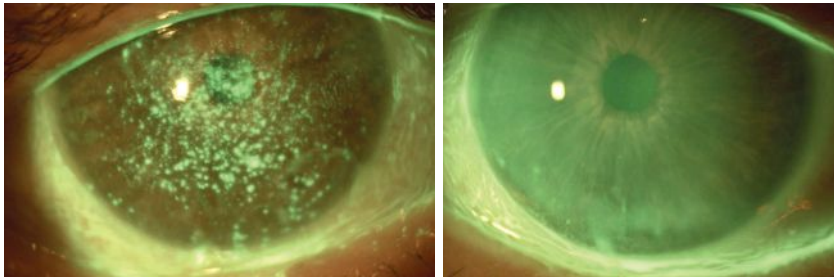
Contraindications to ASED and PRP drops are few but barriers to availability are many. Both require regular blood draw and processing of blood, which may not be feasible for everyone. Typical blood draw yields a three-month supply of ASED or PRP eye drops, which are often used four to six times per day. They also require refrigeration. Once improvement in ocular surface disease is noted, frequency can be tapered and patients can be maintained on other therapies.

Optometrists can produce blood biologics in their practice (subject to state law) or work with local com-



**Fig. 3. View of autologous serum on left and platelet rich plasma on the right.**





**Fig. 4. Resolution of persistent epithelial defects with PRP and lid hygiene for three months.**

pounding pharmacies. Vital Tears ([vitaltears.org](http://vitaltears.org)) is another option for ODs looking to access ASED.

### AMNIOTIC FLUID

If drawing the patient's blood is not an option, practitioners can also consider biological eye drops derived from donor human amniotic fluid or placenta. These are indicated for mild to severe DED and can be a good option for patients looking for lubricants from natural sources. One study found that topical application of amniotic membrane extract eye drops reduced pain and inflammation and promoted re-epithelialization in ocular chemical burns.<sup>16</sup>

Options here include *StimulEyes (M2 Biologics)* and *Regener-Eyes (Regener-Eyes)* eye drops. Both are preservative-free and contain cytokines, chemokines and growth factors to aid ocular surface healing.<sup>17</sup>

### GROW SOME NERVE

When neurotrophic keratitis (NK) is suspected, cenegermin eye drops may also be used. Cenegermin is a recombinant nerve growth factor (rhNGF), produced in *Escherichia coli*, can promote corneal healing in a neurotrophic cornea.<sup>18,19</sup> *Oxervate (cenegermin-bkbj 0.002%, Dompé)* is a sterile, preservative-free eye drop. It is available in seven multi-dose vials (1.0mL) intended to be used six times a day for eight weeks.

NGFs are known to regulate sensitivity in a normal cornea, which is important for epithelial healing.

When persistent corneal staining or non healing epithelial defects are present and corneal sensitivity is reduced, neurotrophic keratitis should be suspected. Although rare, when it does occur NK is challenging to manage, as patients can develop non-healing corneal ulcers and even perforation due to the cornea's inability to heal.<sup>20</sup>

In the current clinical studies, significant improvement in corneal healing was noted in the cenegermin treatment group vs. the placebo group.<sup>21,22</sup> However, whether there is improvement in corneal sensitivity in patients of the treatment groups is still debatable.<sup>18</sup> Interestingly, use of bandage contact lenses along with cenegermin drops improved corneal sensation in 79% of the eyes in a recent retrospective study.<sup>23</sup> Most common side effects of this therapy include hyperemia and eye pain, and it's important to note that patients can relapse when drops are discontinued, suggesting the need for ongoing treatment and additional therapies.<sup>18</sup>

Just like with artificial tears, biologics and advanced alternatives are not a silver bullet. Every patient is best served through an individualized treatment plan that matches their experience in the DED spectrum. As eyecare providers, we must be well-informed on all options available to make that proper connection between a patient condition and appropriate care. **CCCL**

- Ng A, Keech A, Jones L. Tear osmolarity changes after use of hydroxypropyl-guar-based lubricating eye drops. *Clin Ophthalmol.* 2018;12:695-700.
- Bilstein A, Heinrich A, Rybachuk A, Mösger R. Ectoine in the treatment of irritations and inflammations of the eye surface. *Biomed Res Int.* 2021;8885032.
- Märner K, Møller PM, Dillon M, Rask-Pedersen E. Viscous carbomer eye drops in patients with dry eyes. Efficacy and safety, a randomized, open, crossover, multicenter study. *Acta Ophthalmol Scand.* 1996;74(3):249-52.
- Sullivan LJ, McCurrach F, Lee S, et al. Efficacy and safety of 0.3% carbomer gel compared to placebo in patients with moderate-to-severe dry eye syndrome. *Ophthalmology.* 1997;104(9):1402-8.
- Wozniak PA, Schmidl D, Bata AM, et al. Effect of different lubricant eye gels on tear film thickness as measured with ultrahigh-resolution optical coherence tomography. *Acta Ophthalmol.* 2017;95(4):e307-13.
- Ubels JL, Edelhauser HF, Foley KM, et al. The efficacy of retinoic acid ointment for treatment of xerophthalmia and corneal epithelial wounds. *Curr Eye Res.* 1985;4(10):1049-57.
- Terrie YC. Relieving dry eye: what every patient needs to know. *Pharmacy Times.* May 12, 2016.
- Fogt JS, Fogt N, King-Smith PE, et al. Changes in tear lipid layer thickness and symptoms following the use of artificial tears with and without omega-3 fatty acids: a randomized, double-masked, crossover study. *Clin Ophthalmol.* 2019;13:2553-61.
- Behrens A, Doyle JJ, Stern L, et al. Dysfunctional tear syndrome study group. Dysfunctional tear syndrome: a Delphi approach to treatment recommendations. *Cornea.* 2006;25(8):900-7.
- Jones L, Downie LE, Korb D, et al. TFOS DEWS II management and therapy report. *Ocul Surf.* 2017;15(3):575-628.
- Roberts CW, Carniglia PE, Brazzo BG. Comparison of topical cyclosporine, punctal occlusion, and a combination for the treatment of dry eye. *Cornea.* 2007;26(7):805-9.
- Zhou L, Zhao SZ, Koh SK, et al. In-depth analysis of the human tear proteome. *J Proteomics.* 2012;75(13):3877-85.
- Allo JL, Rodriguez AE, Ferreira-Oliveira R, et al. Treatment of dry eye disease with autologous platelet-rich plasma: a prospective, interventional, non-randomized study. *Ophthalmol Ther.* 2017;6(2):285-93.
- Kim KM, Shin YT, Kim HK. Effect of autologous platelet-rich plasma on persistent corneal epithelial defect after infectious keratitis. *Jpn J Ophthalmol.* 2012;56(6):544-50.
- Fea AM, Aragno V, Testa V, et al. The effect of autologous platelet lysate eye drops: an in vivo confocal microscopy study. *Biomed Res Int.* 2016;2016:8406832.
- Liang L, Li W, Ling S, et al. Amniotic membrane extraction solution for ocular chemical burns. *Clin Exp Ophthalmol.* 2009;37(9):855-63.
- Murri MS, Moshirfar M, Birdsong OC, et al. Amniotic membrane extract and eye drops: a review of literature and clinical application. *Clinical Ophthalmol.* 2018;12:1105-12.
- Sheha H, Tighe S, Hashem O, Hayashida Y. Update on cenegermin eye drops in the treatment of neurotrophic keratitis. *Clin Ophthalmol.* 2019;13:1973-80.
- Versura P, Giannaccare G, Pellegrini M, et al. Neurotrophic keratitis: current challenges and future prospects. *Eye Brain.* 2018;10:37-45.
- Bonini S, Rama P, Olzi D, Lambiase A. Neurotrophic keratitis. *Eye (Lond).* 2003;17(8):989-995.
- Bonini S, Lambiase A, Rama P, et al. Phase II randomized, double-masked, vehicle-controlled trial of recombinant human nerve growth factor for neurotrophic keratitis. *Ophthalmology.* 2018;125(9):1332-43.
- Oxervate (cenegermin-bkbj) ophthalmic solution 0.002% (20mcg/mL) [US package insert]. Boston, MA: Dompé US.; 2018.
- Cheung AY, Shah AP, Pierson KL, et al. Use of cenegermin in the presence of bandage contact lenses. *Cornea.* 2022;41(1):78-82.

# Attacking *Acanthamoeba* Keratitis

How to spot and treat this rare but serious condition and reduce risk of vision loss.

**A** 24-year-old Asian female presented to our clinic with an ocular history of pain to the left eye that started one month prior. The patient has a history of orthokeratology (ortho-K) wear; no history of eye surgery and no other ocular history was conveyed, as well as no pertinent medical history. Her uncorrected acuity was 20/40 in the right eye.

Prior to our visit, the initial diagnosis was contact lens overuse, which then shifted to possible herpes simplex virus (HSV). The patient was put on ofloxacin QID, erythromycin, ketorolac QID and valacyclovir 1g three times a day. At this time, the patient called her ortho-K practitioner and was also prescribed a steroid eye drop.

At follow-up, the slit lamp exam showed a central ring infiltrate with discrete stromal opacities, centrally and peripherally, along with significant peripheral neovascularization. The patient was cultured for *Acanthamoeba*, had an HSV PCR and her contact lens was cultured for fungi, bacteria and *Acanthamoeba*, which came back positive (Figure 1). She reported using tap water to clean her lenses and was sent to our clinic for an *in vivo* confocal microscopy (IVCM) where cysts were found.

The patient was shifted to a regimen of Valtrex (valacyclovir, GlaxoSmithKline) 1000mg BID, ofloxacin and prednisolone (both QID), Impavido (miltefosine, Profounda), PHMB (polyhexamethylene biguanide, 0.02%) and 40mg of oral prednisone a day. As time progressed, an amniotic membrane was used routinely due to dense superficial punctate keratitis and

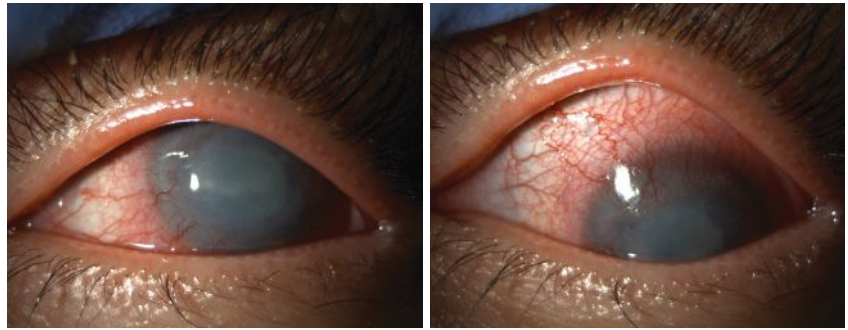


Fig. 1. *Acanthamoeba* and conjunctival injection shown in our patient.

stromal thinning. Brolene (propamidine) QID in the left eye, doxycycline 100mg daily, vitamin C 2g daily and serum tears were also added.

Unfortunately, she continued to worsen and developed an epithelial defect and a white cataract. Now, eight months later, she is still on chlorhexidine 0.02% QID, serum tears QID, vitamin C 100mg, doxycycline 100mg QID and prednisolone TID. She is aware she will ultimately need a penetrating keratoplasty, extracapsular extraction and an intraocular lens OS.

## DIAGNOSIS

*Acanthamoeba* keratitis (AK) is a rare but very serious infection that can lead to vision loss or blindness.<sup>1</sup> It is caused by a single-celled living organism—a tiny amoeba called *Acanthamoeba*—which is found in nature and can be in bodies of water, tap water, whirlpools, air conditioning units and soil.<sup>2</sup> In order for AK to grow, the organism has to make direct contact with the eye; a corneal infection will not occur from drinking or inhaling water that has the amoeba in it. Usually, a small scrape or microtrauma on the cornea acts as the vehicle for entry.<sup>3</sup>

Around 85% of all AK cases in the United States occur in contact lens wearers. Patients who do not store or handle their lenses properly, do not correctly disinfect their cases, swim or shower while wearing lenses are at higher risk.<sup>4</sup> Soft contact lens wearers are at an increased risk because *Acanthamoeba* adheres well to hydrophilic plastic, specifically silicone hydrogels.<sup>5</sup>

The diagnosis is very challenging and, unfortunately, the available treatment regimens are lengthy—as seen in our case—and not fully effective against all strains. The reason we do not have a better solution is that the pathogenesis of AK is still under study. The combination of common misdiagnosis in most cases and lack of consensus has led AK to remain significant; however, it is still very rare, with an estimated prevalence of 1/100,000 to 9/100,000.<sup>6</sup>

The first step is to always keep it in your differentials when dealing with a contact lens wearer or any case of trauma involving exposure to soil or contaminated water. Patients may experience extreme pain with photophobia, ring-like stromal infiltrate, epithelial defect and lid edema. AK is usually unilateral and starts



off as an epithelial disease that slowly progresses to stromal. If the diagnosis is delayed, the amoeba will have already penetrated further into the corneal stroma, which causes therapy to be difficult. At an early point in AK, one can expect to see diffuse superficial keratopathy, which is why it is often confused with herpes simplex keratitis. Later, multifocal infiltrates will be observed in the stroma, which is confused with fungal keratitis. The characteristic ring infiltrate is only seen in 50% of patients.<sup>6</sup>

In-office treatments and procedures that can be used to diagnose AK are plate culturing and IVCN. Culturing remains the gold standard for laboratory diagnosis; however, there are several PCR-based techniques that have increased sensitivity.

As previously mentioned, an IVCN was used around one month after this patient's initial presentation (Figure 2). *Acanthamoeba* cysts appear on this microscopy as hyper-reflective spherical structures that are well defined by a double wall.<sup>5</sup>

### THERAPEUTIC APPROACHES

There are two goals of therapy: (1) removal of the *Acanthamoeba* cyst and trophozoites and (2) resolution of the host inflammatory response.<sup>7</sup>

*Acanthamoeba* trophozoites are sensitive to a variety of available medications: antibiotics, antiseptics, antifungals and antiparasitics. Diamidines and biguanides are the most successful cysticidal anti-amoebics. They are usually prescribed in combination and for the first 48 hours, given hourly continuously



Fig. 2. IVCN showed *Acanthamoeba* cysts at the patient's follow-up exam.

before being reduced to hourly daytime, then four times a day for up to six months.<sup>7</sup>

Extracorneal manifestations can appear and the use of oral nonsteroidal anti-inflammatory medications, high-dose systemic steroids or other immunosuppressive drugs (e.g., cyclosporine) are often initiated and used for several months.<sup>7</sup>

Biguanides are the most effective drugs for this type of infection, including PHMB (polyhexamethylene biguanide 0.02-0.06%) and chlorhexidine 0.02%-0.2%. Our patient was started on PHMB, but had to be changed to chlorhexidine due to pain and intolerance.

Examples of diamidines include brolofen (propamidine isethionate, 0.1%), desomedine (hexamidine diisethionate, 0.1%), corneal transplantation, photorefractive excimer, crosslinking and steroids.

Steroids remain controversial in treatment of AK, as there is no clear consensus about their use. They are often recommended in cases with a persistent infection with inflammation; however, they are controversial because they do suppress the patients' immunological response. Studies have shown an association with topical steroid use and a diagnostic delay in AK manifestation, which was seen in our patient.<sup>5</sup>

Remember that your contact lens wearers will often present late because they are accustomed to having minor irritation due to the lenses. The most important factors associated with AK outcomes are disease severity at presentation and time to therapy initiation. A delay of three weeks is associated with worse prognosis; if you have any suspicion of AK, an attempt to get confirmation is necessary.<sup>8</sup>

This case ended up being complex, resulting in over 50 visits, with the patient seen by multiple specialists. She is still being seen today. **RCCL**

1. Page MA, Mathers WD. *Acanthamoeba* keratitis: a 12-year experience covering a wide spectrum of presentations, diagnoses and outcomes. *J Ophthalmol.* 2013;2013:670242.
2. Visvesvara GS, Moura H, Schuster FL. Pathogenic and opportunistic free-living amoebae: *Acanthamoeba* spp., *Balamuthia mandrillaris*, *Naegleria fowleri* and *Sappinia diploidea*. *FEMS Immunol Med Microbiol.* 2007;50(1):1-26.
3. He YG, McCulley JP, Alizadeh H, et al. A pig model of *Acanthamoeba* keratitis: transmission via contaminated contact lenses. *Invest Ophthalmol Vis Sci.* 1992;33(1):126-33.
4. Patel A, Hammersmith K. Contact lens-related microbial keratitis: recent outbreaks. *Curr Opin Ophthalmol.* 2008;19(4):302-6.
5. Villani E, Baudouin C, Efron N, et al. In vivo confocal microscopy of the ocular surface: from bench to bedside. *Curr Eye Res.* 2014;39(3):213-31.
6. Lorenzo-Morales J, Khan NA, Walochnik J. An update on *Acanthamoeba* keratitis: diagnosis, pathogenesis and treatment. *Parasite.* 2015;22:10.
7. Maycock NJ, Jayaswal R. Update on *Acanthamoeba* keratitis: diagnosis, treatment and outcomes. *Cornea.* 2016;35(5):713-20.
8. Dart JKG, Saw VPJ, Kilvington S. *Acanthamoeba* keratitis: diagnosis and treatment update 2009. *Am J Ophthalmol.* 2009;148:487-99.



## Flood Zone

Lacrimal duct obstruction leaves tears with no drainage mechanism, leading to epiphora.

**A**n 88-year-old female was referred by her glaucoma specialist for epiphora and sore eyelids. She reported that her vision is stable but she is experiencing excessive tearing and is constantly wiping her lids with a tissue. Her inner canthi have become sore and this has decreased the quality of her life, she explained. She uses latanoprost daily and has been recommended artificial tears and lid hygiene for dry eye.

Upon examination, she was found to have ptosis of both eyes, medial canthal fat prolapse and inferior medial lower lid ectropion with no apposition of the puncta to the

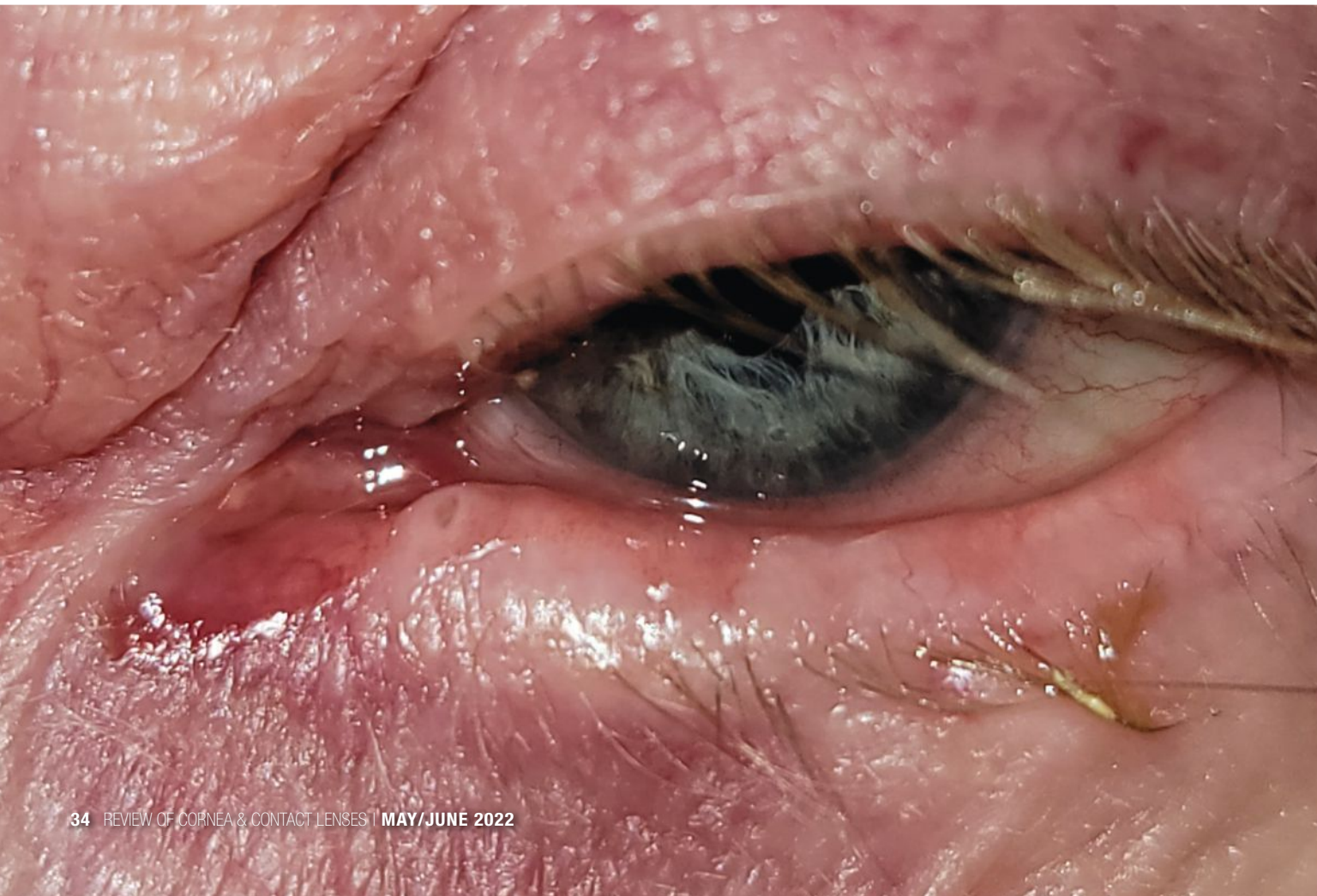
globe. Tears were pooling in the inner canthus, causing excoriation of the skin. Punctal probing showed bilateral inferior lacrimal duct obstruction. There was significant lid margin alteration with blunting and obliteration of the meibomian glands.

Surgical intervention was discussed with this patient, including ptosis repair and lateral tarsal strip to tighten the inferior lid and reposition the puncta. However, since the inferior puncta is blocked, she would also need to undergo lacrimal duct repair.

This patient was not interested in surgery and requested palliative care for her symptoms. Without any meibomian glands, traditional

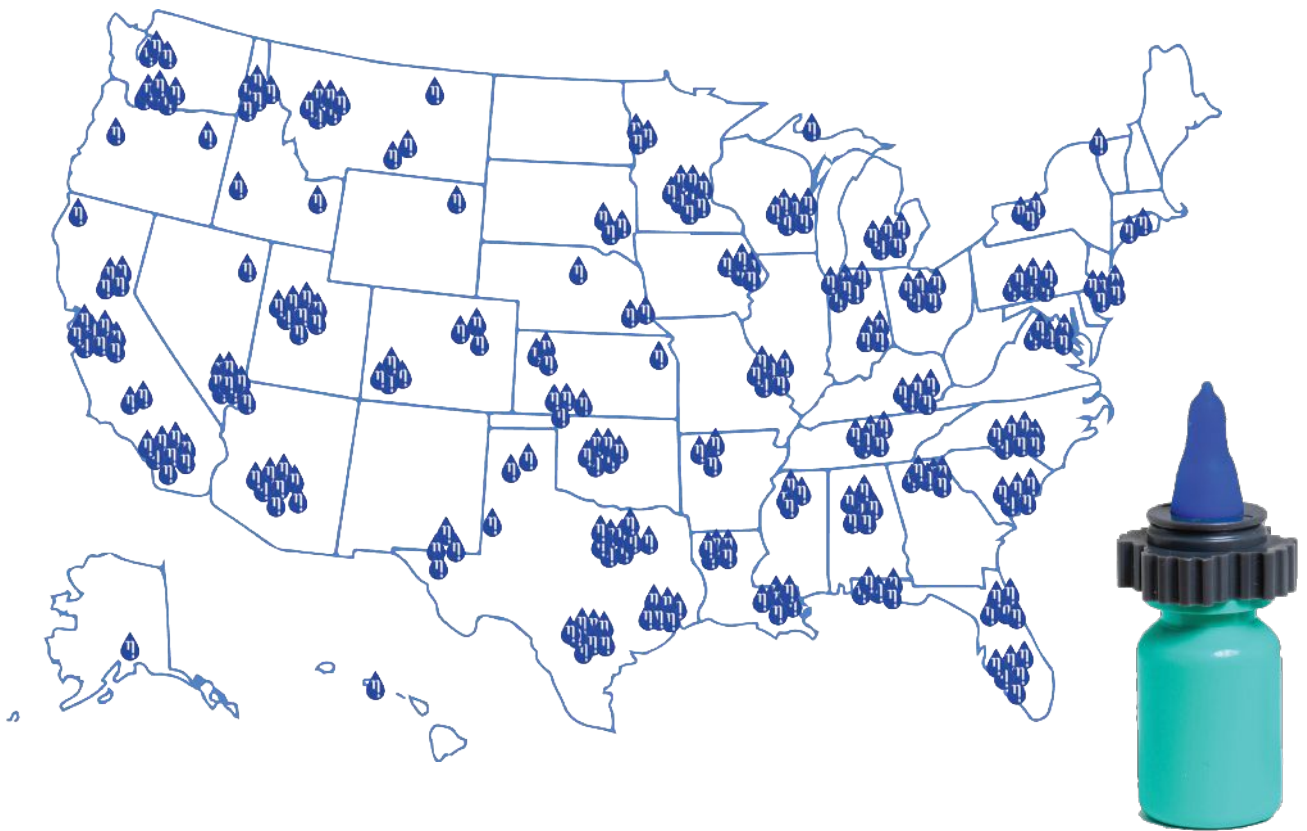meibomian care (*e.g.*, hot compresses) will be less than helpful. However, removing the bioload and the overspill of the latanoprost may reduce irritation. In cases of chronic epiphora with excoriation, barrier creams are quite effective in protecting the skin.

This patient was instructed to wipe the skin around the eyes with a moist towelette 10 minutes after instilling the latanoprost and then apply a scant amount of a barrier cream, such as zinc oxide or Vaseline, to the affected areas. Zinc oxide has antibacterial properties as well as UV barrier function and is non-toxic to the eye. **RCCL**



# NANO DROPPER

**Don't get let your clinic and patients get left behind.**



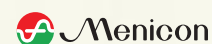Since our launch in June 2020, amidst a global pandemic, we have incorporated **hundreds of clinics** around the country into our partner clinic network. Each clinic has elevated the standard of care for their patients. **Are you ready to join in?**

**Use discount code RCCL10  
for 10% off your first order!**

The Nanodropper is the only FDA-listed, volume-reducing adaptor for eyedrop bottles designed to deliver precisely the amount of fluid the eye can absorb. Smaller drops reduce the waste and cost of in-clinic and Rx formulations while minimizing local and systemic side effects.

**[www.nanodropper.com](http://www.nanodropper.com) | [support@nanodropper.com](mailto:support@nanodropper.com) | (507) 405-5676**

**70<sup>th</sup>**  
anniversary  
1951-2021



# Miru 1day UpSide

silicone hydrogel contact lenses  
with **Smart Touch™** technology

A new generation of silicone hydrogel material balanced for health and comfort incorporating a unique combination of **high oxygen** and **ultra low modulus**.

## SMART TOUCH™

Miru 1day UpSide contact lenses are always the right way up and ready to wear, thanks to **Smart Touch™** technology.

**Multifocal now available**

Miru  
1day UpSide

Miru  
1day UpSide

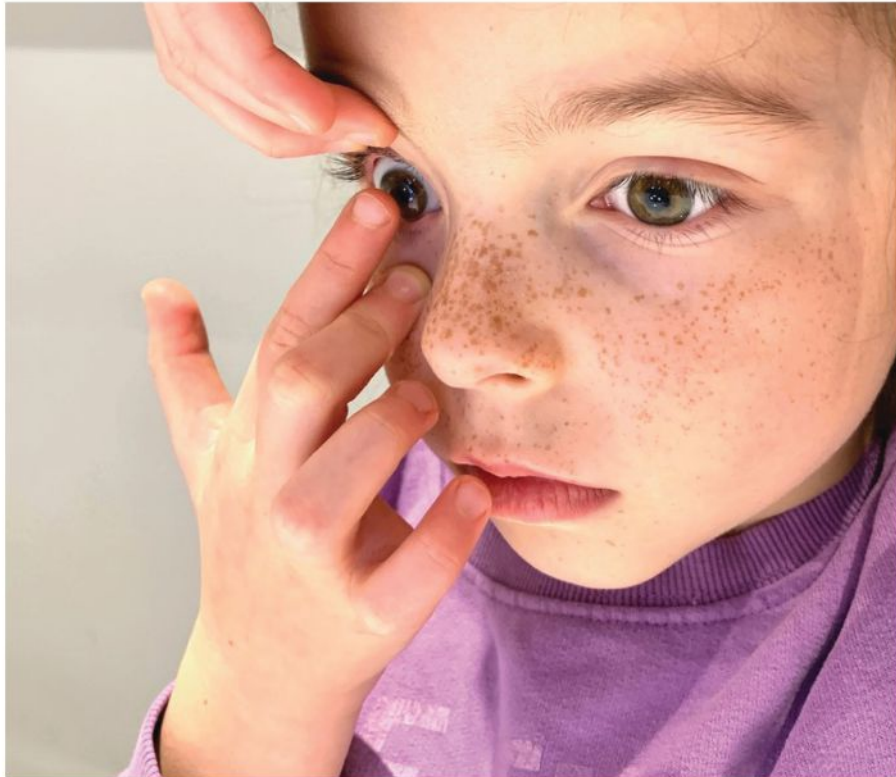
Find us on:    

[www.meniconamerica.com](http://www.meniconamerica.com)

# Click to access OrthoK THE COMPLETE GUIDE TO ORTHOKERATOLOGY SUCCESS IN MYOPIA CONTROL

## OrthoK

THE COMPLETE GUIDE TO ORTHOKERATOLOGY SUCCESS IN MYOPIA CONTROL



*This eResource is  
brought to you by*

**Review**  
MYOPIA MANAGEMENT