

RCCL[®]

REVIEW OF CORNEA & CONTACT LENSES

EARN 2 CE CREDITS

TRENDS IN INFECTIOUS KERATITIS


Here's what you need to know to better diagnose and treat this condition.

By William Skoog, OD, and
Lindsay A. Sicks, OD

Page 22

MiSight[®] 1 day is the ONE for myopia control*

MiSight[®] 1 day soft contact lenses are specifically designed for myopia control and are FDA approved* to slow the progression of myopia in children aged 8-12 at initiation of treatment.^{1†}



MiSight[®] 1 day
for daily wear



FDA-Approved*

How can myopia control with MiSight[®] 1 day benefit your practice?


Learn more at [CooperVision.com](https://www.CooperVision.com)

***Indications for use:** MiSight[®] 1 day (omafilcon A) soft (hydrophilic) contact lenses for daily wear are indicated for the correction of myopic ametropia and for slowing the progression of myopia in children with non-diseased eyes, who at the initiation of treatment are 8-12 years of age and have a refraction of -0.75 to -4.00 diopters (spherical equivalent) with ≤ 0.75 diopters of astigmatism. The lens is to be discarded after each removal.

[†]Compared to a single vision 1 day lens over a 3 year period.

Reference: 1. Chamberlain P, et al. A 3-year randomized clinical trial of MiSight[®] lenses for myopia control. *Optom Vis Sci.* 2019; 96(8): 556-67.





RCCL®

REVIEW OF CORNEA
& CONTACT LENSES

JANUARY/FEBRUARY 2022

EARN 2 CE CREDITS

TRENDS IN INFECTIOUS KERATITIS

*Here's what you need to know to better
diagnose and treat this condition.*

By William Skoog, OD, and
Lindsay A. Sicks, OD

Page 22

ALSO: Post-surgical Lens Fitting • Genetic Testing for KCN • Grow Your GP Practice • Corneal Transplant Complications

GET THERE IN TIME

When you see patients with signs of keratoconus, don't hesitate. Refer them for iLink[™] – the only FDA-approved cross-linking procedure that slows or halts disease progression and is eligible for commercial insurance coverage with over 95% of commercially covered lives.

Connect with an
iLink[™] expert today.
Visit iLinkExpert.com

INDICATIONS

Photrexa[®] Viscous (riboflavin 5'-phosphate in 20% dextran ophthalmic solution) and Photrexa[®] (riboflavin 5'-phosphate ophthalmic solution) are indicated for use with the KXL system in corneal collagen cross-linking for the treatment of progressive keratoconus and corneal ectasia following refractive surgery. Corneal collagen cross-linking should not be performed on pregnant women.

IMPORTANT SAFETY INFORMATION

Ulcerative keratitis can occur. Patients should be monitored for resolution of epithelial defects.

The most common ocular adverse reaction was corneal opacity (haze). Other ocular side effects include punctate keratitis, corneal striae, dry eye, corneal epithelium defect, eye pain, light sensitivity, reduced visual acuity, and blurred vision.

These are not all of the side effects of the corneal collagen cross-linking treatment. For more information, go to www.livingwithkeratoconus.com to obtain the FDA-approved product labeling.

You are encouraged to report all side effects to the FDA. Visit www.fda.gov/medwatch, or call 1-800-FDA-1088.

*Photrexa[®] Viscous and Photrexa[®] are manufactured for Avedro. The KXL[®] system is manufactured by Avedro. Avedro is a Glaukos company.

REFERENCE: 1. Photrexa [package insert]. Waltham, MA: Glaukos, Inc; 2016.

MA-02164A
PM-US-0427

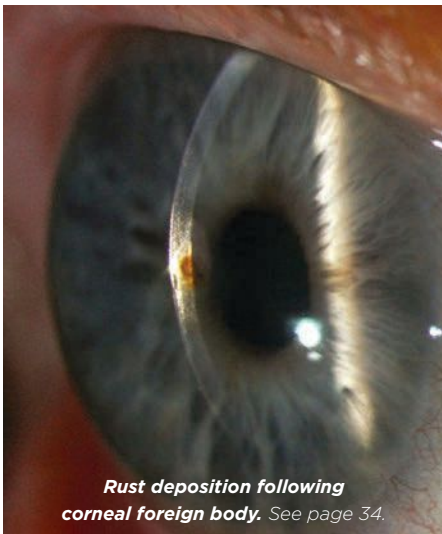
iLink[™] is a trademark of Glaukos Corporation. Photrexa[®], Photrexa[®] Viscous, and the KXL[®] system are registered trademarks of Avedro, a Glaukos company. All rights reserved. ©2022



GLAUKOS

contents

Review of Cornea & Contact Lenses | January/February 2022



Rust deposition following corneal foreign body. See page 34.

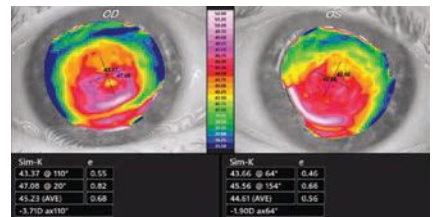
features

10

KCN Genetic Testing: Where does it fit in?

This new technology holds the potential to help identify some patients early, but experts caution it's just one piece of the diagnostic puzzle.

By Jane Cole, Contributing Editor



departments

4 News Review

Scarring, Astigmatism Mediate CXL Results Against Infection; Mask Taping Reduces Ocular Surface Issues

6 My Perspective

Circling Back on Recycling Contacts
By Joseph P. Shovlin, OD

8 The GP Expert

Building Your GP Practice
By Lindsay A. Sicks, OD

32 Corneal Consult

Deep Dive
*By Aaron Bronner, OD,
and Alison Bozung, OD*

34 The Big Picture

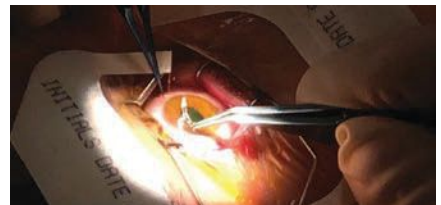
In the Line of Fire
By Christine W. Sindt, OD

16

Fitting the Keratoconic Eye Post-Surgery

We discuss how to carefully initiate contact lenses after various corneal procedures, including crosslinking.

By Melissa Barnett, OD, Barry Eiden, OD, and Louise Scalfani, OD

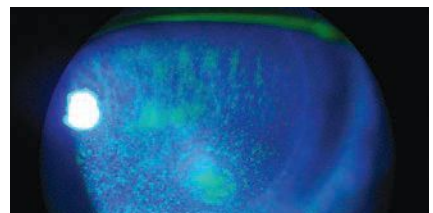


22

CE: Trends in Infectious Keratitis

Here's what you need to know to better diagnose and treat this condition.

**By William Skoog, OD,
and Lindsay A. Sicks, OD**



IN BRIEF

■ A recent study found **no significant difference in meibomian gland dropout percentage or gland visibility metrics after one year of scleral lens wear** in a study of 43 patients. However, researchers did conclude that their proposed algorithm, which involved infrared meibography of the upper eyelid and similar to the meibomian gland contrast measurement, showed merit with **moderate-acceptable repeatability of gland visibility metrics**.

García-Marqués JV, Macedo-De-Araújo RJ, Cerviño A, et al. Assessment of meibomian gland drop-out and visibility through a new quantitative method in scleral lens wearers: a one-year follow-up study. Cont Lens Anterior Eye. January 5, 2022. [Epub ahead of print].

■ A recent investigation found **multifocals and some single vision lenses may be useful in controlling myopia in young patients**. The research team suggested multifocal wear results in better myopia correction in the first 18 months compared with single vision CLs. On the other hand, both had better outcomes than spectacle lenses at 24 months. Also of note: **multifocals were most effective early in the diagnosis and before the condition intensified**.

Malinowski A, Mrugacz M, Stopa M, et al. A clinical study of the impact of soft contact lenses on the progression of myopia in young patients. Clin Ophthalmol. January 22, 2022. [Epub ahead of print].

■ A group of contact lens specialists argue that **replacing the term “rigid lens” with the more commercially palatable “gas permeable” label is confusing and inaccurate**. The authors propose using the general terms “rigid lens” and “rigid CL” when referring non-specifically to a hard lens, depending on the context. For a rigid lens that only bears on the cornea, any of the terms “corneal lens,” “rigid corneal lens,” “corneal CL” and “rigid corneal CL” could be used.

Efron N, Vincent S, Lindsay RG. It's time to call a spade a spade rigid contact lens nomenclature. Clin Exp Optom. January 5, 2022. [Epub ahead of print].

Scarring, Astigmatism Mediate CXL Results Against Infection

Crosslinking-assisted infection reduction, abbreviated as CLAIR, is a randomized, outcome-masked clinical trial that evaluated the benefit of adjuvant corneal crosslinking in moderate to severe bacterial keratitis. Studies have shown that photochemically-activated riboflavin may be effective against some ocular pathogens.^{1,2} In fact, because the photochemical reaction between UV light and riboflavin kills pathogens, crosslinking is safe to perform outside the operating room at the slit lamp.³ This approach isn't approved in the United States yet.

Crosslinking is currently being assessed for its possible use against infectious keratitis and as an adjunctive therapy in fungal keratitis.^{4,5} So far, it's proved less useful in cases of fungal keratitis. Researchers believe this may be because fungal infections tend to penetrate deeper into the cornea.⁴ In the CLAIR study, however, the researchers found “patients with filamentous fungal corneal ulcers who underwent both adjunctive crosslinking and topical antifungal treatment had worse visual acuity outcomes than those treated with antifungal alone.”⁵

A total of 111 patients in the CLAIR study with moderate vision loss from a smear-positive fungal ulcer were randomized to one of four treatment arms: topical natamycin 5%, topical natamycin 5% + CXL, topical amphotericin B 0.15% and topical amphotericin 0.15% + CXL.

The team reported that patients had a mean BSCVA of 0.82 logMAR (Snellen equivalent 20/132). They found that three-month infiltrate and/or scar size, depth and densitometry were significant predictors of

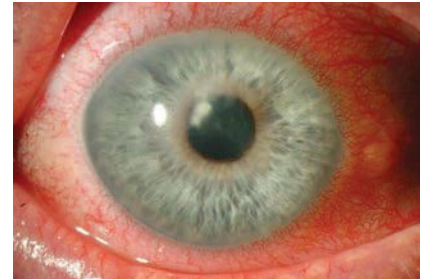


Photo: Christine W. Strick, OD

Astigmatism and scar size each mediated 23% of the effect of crosslinking on BSCVA.

three-month BSCVA. “Astigmatism mediated 23% of the effect of crosslinking on BSCVA, whereas scar size mediated 23%, scar depth 17% and densitometry 7%,” they reported.⁶

Together, these factors mediated 47% of the crosslinking effect on visual acuity in fungal keratitis cases. “During acute infectious keratitis, inflammatory cells invade the corneal stroma, disrupting the regular arrangement of collagen fibrils and causing an increase in corneal light scatter,” the researchers explained.

They concluded corneal scarring and astigmatism were mediators of worse visual acuity in patients with fungal keratitis who received CXL.

1. Martins SA, Combs JC, Noguera G, et al. Antimicrobial efficacy of riboflavin/UVA combination (365 nm) in vitro for bacterial and fungal isolates: a potential new treatment for infectious keratitis. Invest Ophthalmol Vis Sci. 2008;49(8):3402-8.

2. Wollensak G, Spoerl E, Reber F, Seiler T. Keratocyte cytotoxicity of riboflavin/UVA-treatment in vitro. Eye (Lond). 2004;18(7):718-22.

3. Hafezi F, Rizocho O, Torres-Netto EA, et al. Corneal cross-linking at the slit lamp. J Refract Surg. 2021;37(2):78-82.

4. Deshmukh R. Commentary: PACK-CXL in fungal keratitis. Indian J Ophthalmol. 2019;67(10):1701-2.

5. Prajna NV, Radhakrishnan N, Lalitha P, et al. Cross-linking-assisted infection reduction: a randomized clinical trial evaluating the effect of adjuvant cross-linking on outcomes in fungal keratitis. Ophthalmol. 2020;127:159-66.

6. Prajna NV, Radhakrishnan N, Lalitha P, et al. Mediators of the effect of corneal cross-linking on visual acuity for fungal ulcers: a prespecified secondary analysis from the cross-linking-assisted infection reduction trial. Cornea. 2022;00:1-5.

EDITORIAL STAFF

EDITOR-IN-CHIEF

Jack Persico jpersico@jobson.com

SENIOR EDITOR

Julie Shannon jshannon@jobson.com

SENIOR ASSOCIATE EDITOR

Catherine Manthorp cmanthorp@jobson.com

SENIOR ASSOCIATE EDITOR

Mark De Leon mdeleon@jobson.com

ASSOCIATE EDITOR

Leanne Spiegle lspiegle@jobson.com

CLINICAL EDITOR

Joseph P. Shovlin, OD jpsovlin@gmail.com

ASSOCIATE CLINICAL EDITOR

Christine W. Sindt, OD christine-sindt@uiowa.edu

SENIOR ART DIRECTOR

Jared Araujo jaraujo@jhihealth.com

AD PRODUCTION MANAGER

Farrah Aponte faponte@jobson.com

BUSINESS STAFF

PUBLISHER

Michael Hoster mhoster@jobson.com

SENIOR MANAGER, STRATEGIC ACCOUNTS

Michele Barrett mbarrett@jobson.com

REGIONAL SALES MANAGER

Jon Dardine jdardine@jobson.com

EXECUTIVE STAFF

CEO, INFORMATION SERVICES GROUP

Marc Ferrara mferrara@jhihealth.com

SENIOR VICE PRESIDENT, OPERATIONS

Jeff Levitz jlevitz@jhihealth.com

**SENIOR VICE PRESIDENT,
HUMAN RESOURCES**

Tammy Garcia tgarcia@jhihealth.com

**VICE PRESIDENT,
CREATIVE SERVICES & PRODUCTION**

Monica Tettamanzi mtettamanzi@jhihealth.com

VICE PRESIDENT, CIRCULATION

Jared Sonners jsonners@jhihealth.com

CORPORATE PRODUCTION MANAGER

John Caggiano jcaggiano@jhihealth.com

EDITORIAL REVIEW BOARD

James V. Aquavella, MD

Edward S. Bennett, OD

Aaron Bronner, OD

Brian Chou, OD

Kenneth Daniels, OD

S. Barry Eiden, OD

Desmond Fonn, Dip Optom, MOptom

Robert M. Grohe, OD

Susan Gromacki, OD

Patricia Keech, OD

Bruce Koffler, MD

Pete Kollbaum, OD, PhD

Jeffrey Charles Krohn, OD

Jerry Legerton, OD

Kelly Nichols, OD

Robert Ryan, OD

Jack Schaeffer, OD

Charles B. Slonim, MD

Kirk Smick, OD

Mary Jo Stiegemeier, OD

Loretta B. Szczołka, OD

Michael A. Ward, FCLSA

Barry M. Weiner, OD

Barry Weissman, OD

Mask Taping Reduces Ocular Surface Issues

Face coverings have become a daily staple during the COVID-19 pandemic, and in some cases, this health and safety measure has resulted in dry eye and other ocular surface issues in some individuals. A new study that investigated ways to remedy this trend found taping the edge of an N95 mask resulted in better ocular surface stability in terms of TBUT, lipid layer thickness, tear meniscus height, corneal staining score and tear osmolarity.

Additionally, nearly two-thirds of the study participants reported a decrease in DED-related symptoms that correlated well with changes in OS parameters.

The investigation included 50 eyes of 50 healthcare workers who regularly wore N95 masks (average age=27). The study team assessed pre-intervention, ocular surface parameters, subjective dry eye scores and visual acuity at the end of the participants' eight-hour shifts during which they wore an N95 face mask without taping its upper edge. On the following day, the upper edge of the N95 mask was taped to the healthcare workers' nasal bridges at the beginning of their shifts.

Ocular surface measures were significantly better after mask taping when analyzed by TBUT, tear lipid layer thickness, tear meniscus height, corneal staining score and tear osmolarity. On the other hand, the investigators observed no significant change in VA, Schirmer I or OSDI scores.

Considering symptom relief, 68% of individuals reported their ocular surface symptoms improved, and these findings appeared to correlate well with changes in noninvasive TBUT, tear meniscus height, tear lipid layer thickness and TBUT.

The primary mechanism behind the mask-associated dry eye was the mechanical desiccation of the ocular surface caused by inadvertent airflow, resulting from the reversal of the normal direction of exhaled air within the face mask, the researchers explained. The steady flow of warm exhaled air adversely affected the tear film homeostasis by causing increased tear evaporation.

Additionally, the outermost lipid layer plays a key role in maintaining tear film stability and preventing its evaporation and is directly affected by the exhaled air.

“A key finding in our study was an increase in tear film lipid layer thickness after taping the upper mask edge, with a corresponding increase in TBUT,” the authors wrote. “Treatment targeting the augmentation of the tear film lipid layer should be considered in mask-associated dry eye patients, as it may play a key role in altering ocular surface stability.”

Nair S, Kaur M, Sah R, et al. Impact of taping the upper mask edge on ocular surface stability and dry eye symptoms. *Am J Ophthalmol*. January 1, 2022. [Epub ahead of print].

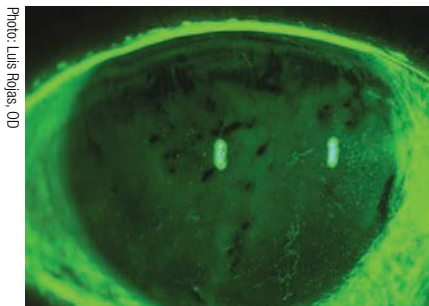


Photo: Luis Rojas, OD

Mask taping may reduce ocular surface issues during wear that occur in some individuals.



Circling Back on Recycling Contacts

Consider the efforts that can limit the environmental impact of lenses and their packaging.

Proper disposal of contact lenses, packaging and related care products has long been a subject of discussion.^{1,4} To some extent, it remains a personal decision whether or not to recommend and/or offer patients a recycling option. Does it really matter if lenses end up in the landfill or flushed down the toilet?

On one hand, it's about the environment, and most should be concerned about what we're doing to our environment even though the impact has been reported to be negligible.² On the other hand, is there significant waste or consequences to alternatives (flushing or disposing in the waste basket) to recycling lenses and packaging?

FLUSHED AWAY

Full-time daily disposable lens wear generates 27% more waste annually than full-time reusable lens wear.⁴ Contacts don't break down in septic tanks or sewer systems. Researchers from Arizona State University found that flushing lenses down the sink or toilet may result in them ending in wastewater treatment plants, which reduces them to microplastic fragments.³ On a national basis, the researchers reported, that would amount to 1.8 billion to 3.36 billion lenses being flushed every year. That translates into 20 to 23 metric tons of plastic trash winding up in our wastewater each year.³

"Flushing contact lenses is particularly concerning because their size and flexibility allow them to slip through filters meant to keep nonbiological waste out of wastewater treatment plants," the researchers noted.^{1,3,4}

OUT WITH THE TRASH

Mixing your lenses and packaging with "trash" is not a better option than flushing. Overall, an eco-friendly disposal of lenses is not as simple as tossing them into a recycling bin.¹ Even if you think you're recycling properly, most facilities typically can't properly handle contact lens and packaging processing due to their size. Unfortunately, they are often diverted to the landfill, which may take up to 500 years to decompose and potentially causing pollutants to leak into the soil and water.^{1,4}

CONSIDERATE SOLUTIONS

For the eye care providers who might appear to be less environmentally friendly by not recommending or providing a recycling program, citing data that shows that daily disposable lenses and packaging account for less than 0.5% of our daily "trash" might help you feel less guilty.²

For providers who have not considered recycling as an option, Bausch & Lomb teamed up with TerraCycle, a handler of hard-to-recycle waste to create the One by One Recycling Program. This program is designed to recycle contact lenses, blister packs and blister-pack foil. Once patients have collected their old contacts, blister packs and foil, they can either take the waste to a local eye doctor's office participating in the recycling program, or they can ship directly to TerraCycle by placing waste in a sealed cardboard box.¹

As of April 2019, the program had diverted more than 9.2 million used contacts, blister packs and foil from waterways, landfills and traditional recycling facilities. Altogether, those weighed nearly 28 tons.^{1,5}

The program accepts used contact lenses and other contact-lens recyclables from any manufacturer. Of note, TerraCycle has a partnership with Johnson & Johnson Vision in the United Kingdom and a partnership with CooperVision in Sweden.^{6,7}

I appreciate the various opinions on how much of a concern not recycling lenses and packaging poses to you, your patients and the environment. Your practice must weigh the pros and cons in order to decide whether to participate in such a program. But I say, why not? It's going at least have some lasting impact on the environment. Today, more than 5,500 optometry practices have enrolled in the One by One Recycling Program. To register and learn more about this program, visit www.bauschrecycles.com. I think I'm long overdue in presenting this program. **RCCL**

1. Egan J. Don't flush contact lenses. recycle them. www.allaboutvision.com/contact-lenses/recycle. August 2019. Accessed December 13, 2021.

2. Morgan SL, Morgan PB, Efron N. Environmental impact of three replacement modalities of soft contact lens wear. *Cont Lens Anterior Eye*. 2003;26(1):43-6.

3. Rolsky C, Kelkar VP, Halden RU. Nationwide mass inventory and degradation assessment of plastic contact lenses in US wastewater. *Environ Sci Technol*. 2020;54(19):12102-8.

4. Smith SL, Osborn GN, Silley A, et al. An investigation into disposal and recycling options for daily disposable and monthly replacement soft contact lens modalities. *Cont Lens Anterior Eye*. 2021;43(3):101435.

5. Bausch + Lomb One by One Recycling Problem. Terra Cycle. www.terracecycle.com/en-us/brigades/bauschrecycles. Accessed December 13, 2021.

6. Sustainability at Acuvue. a world worth seeing. Johnson & Johnson Vision. www.jnvisionpro.com/about/sustainability. Accessed December 13, 2021.

7. CooperVision launches soft contact lens recycling program for all brands in Sweden. CooperVision. cooper-vision.com/our-company/news-center/press-release/cooper-vision-launches-soft-contact-lens-recycling-program-all. August 26, 2019. Accessed December 13, 2021.

NEW
ENHANCED
COMFORT
NO REFIT REQUIRED

Redefine
the patient experience



**Introducing New
NaturalVue® (etafilcon A) Enhanced
Multifocal 1 Day™ contact lenses**

Acuity and comfort—together like never before

TripleTear® lubrication system, including hyaluronic acid, hydrates, lubricates, locks-in moisture and maintains a clean surface¹

Ultra-Tapered Edge designed for optimal fit and comfort

See what's possible at vvision.com

For information about the management of myopia in your practice and how NaturalVue® Multifocal can help, call 1-844-884-5367, ext.136, or email dbenoit@vvision.com

Reference: 1. Chang W-H, Liu P-Y, Lin M-h, et al. Applications of hyaluronic acid in ophthalmology and contact lenses. *Molecules*. 2021;26:2485

Building Your GP Practice

Combine the right tools with passion and persistence to create the ultimate GP and specialty lens practice.

There has been a lot of talk lately about how to build a specialty lens practice, as practitioners look to maximize their revenue and establish a niche. Fitting specialty lenses can be endlessly rewarding, with patients returning year after year because your talents help them live their best lives. So, what can you do to build GP and specialty lens fitting in your practice and, ultimately, change more lives this year?

FITTING SETS

The first step is to ensure you have the tools necessary to fit any patient who enters your practice. While spherical GP lenses are often ordered empirically these days, many specialty lenses still require a fitting set and diagnostic fitting process. Even our most advanced scleral profilometry technologies still work best in concert with a diagnostic fitting in office to

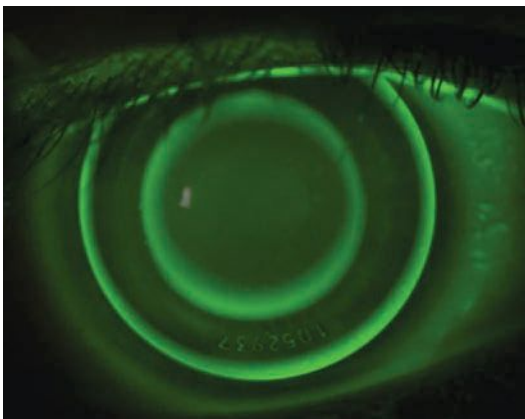

Fig. 1. A well-centered, empirically designed orthokeratology lens is evaluated on-eye at the dispensing visit. The sodium fluorescein dye is absent in the central treatment zone and midperipheral alignment curves.

determine the initial lens power. That's not to say you need every single fitting set under the sun; many laboratories will lend you a fitting set for a prescribed amount of time if you wish to fit a particular patient.

In general, the lens fitting sets I would consider essential include: a corneal keratoconic GP set, a corneal reverse geometry GP set, a scleral GP set (preferably with two different diameters and toric haptic options) and an irregular cornea hybrid lens fitting set. If you wish to order spherical GP, bitoric GP, regular cornea hybrid or orthokeratology (ortho-K) lenses, there is a very high success rate with empirical fitting; thus a lens fitting set is optional. I find the same is true for simultaneous GP multifocal lens designs.

There are empirical lens fitting options available for irregular cornea hybrids, but I highly recommend getting in touch with the laboratory's consultation team prior to attempting such a fit so you can obtain all necessary data at the patient's initial fitting visit.

It is useful to have a fitting set for a translating GP multifocal design, as you can determine

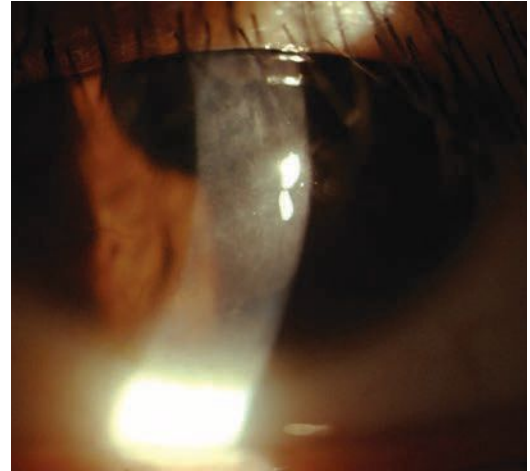

Fig. 2. This patient with keratoconus was referred by an outside optometrist for evaluation of a poor fitting hybrid lens. Note the corneal neovascularization induced inferiorly to the left of the light beam. She was eventually refit into a scleral lens design.

in-office how the initial lens fits and where the segment height is relative to the pupil center. However, the final power of the lens affects the overall weight, therefore impacting the final placement of the segment height, the diameter and the amount of prism needed for optimal lens movement and stability.¹ Some fitting sets will have varying lens powers to assist with this unique scenario.

PATIENT REFERRALS

The next step is to ensure you have patients to fit. Network with local practitioners to let them know you have a passion for GP lenses. You may be able to grow your ortho-K practice by meeting with local pediatricians or primary care providers, and you may also find success in growing your scleral lens practice by offering your services to

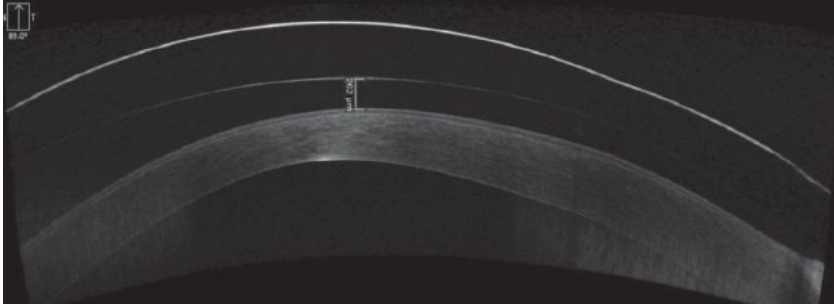


Fig. 3. This scleral fit was decentering inferiorly, as shown on an anterior segment OCT (the tear film reservoir depth is greater inferiorly, seen on the left side of the image). The decentration was resolved by reducing the central vault and steepening the scleral landing zone.

both corneal specialists and general ophthalmologists.

Once these specialty fits are complete, follow-up with the referring practitioner to thank them for their referral and share the results of your fitting success. This, along with word-of-mouth referrals from happy patients, can result in more patients entering your practice.

DIAGNOSTIC EQUIPMENT

It can be useful to invest in specialized diagnostic equipment to fit these lenses, though this is not always required (nor are you required to have the fanciest version of every item listed). For ortho-K, it is essential to have a corneal topographer because it tells you so much more about how the lens fits on the eye, at night, when the eye is closed. These findings don't always translate to what we see in the manifest refraction, over-refraction or a sodium fluorescein pattern assessment on the open eye.

If you are fitting specialty lenses on irregular corneas, it may be worth investing in corneal tomography so that you can image the

posterior corneal surface and have global pachymetry readings. If you intend to have a heavy scleral lens practice, profilometry and anterior segment optical coherence tomography are worthwhile considerations. There are instruments which combine several of these imaging options so you can ensure your investment will meet any current and future needs.

An imaging system may also be useful as you communicate your findings to GP lab consultants. I cannot tell you the number of emails I send to consultants (my apologies to all the lovely consultants out there I work with) with my written findings, but then I also say "see attached image" to help better communicate what my words may fail to convey. My photography and anterior segment OCT skills don't always communicate everything flawlessly, but there have been times that a consultant's assessment of an included image has helped optimize my lens fit for the better.


With all that said, there are also times when it's easier to communicate these findings and challenges

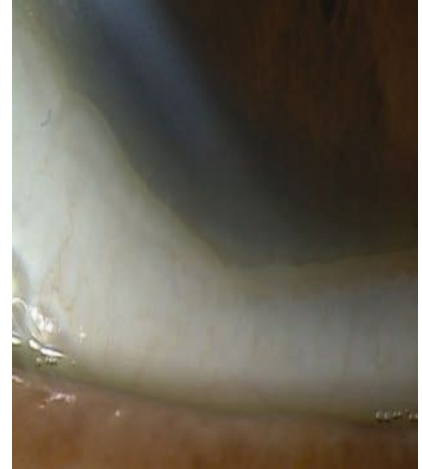

Fig. 4. Patient with scleral prolapse, which was resolved with the assistance of a laboratory consultant. This image was uploaded to the lab's web consultation tool, along with other fitting data, and they replied via email with suggested changes to the fit, which included reducing the lens diameter.

via phone; it may also be worth following up your email with a phone call in tough cases.

PASSION AND PERSISTENCE

Yes, these are qualities you can possess and not tangible tools to purchase and implement; however, passion and persistence are essential to your success when building a practice around GP and other specialty lenses. Your passion for these patients will carry you through even the toughest cases you encounter. Your persistence will give you the ability to succeed when the going gets tough. So, get going! 

1. Truform Optics LlevationsThin (Multifocal) Contact Lens Fitting Guide. www.tfoptics.com/presbyopic/documents/llevationsthinfittingguide.pdf. Accessed January 25, 2021.



KCN GENETIC TESTING: WHERE DOES IT FIT IN?

This new technology holds the potential to help identify some patients early, but experts caution it's just one piece of the diagnostic puzzle.

By Jane Cole, Contributing Editor

A clear-cut diagnosis of keratoconus (KCN) can be all a clinician needs to recommend corneal crosslinking (CXL) or rule out refractive procedures that may cause post-op issues in patients with corneal degenerations and dystrophies. However, not every diagnosis is obvious—there is often a gray area in which the individual doesn't exhibit clinical signs of the disease but may still harbor latent KCN.

These gray areas can sometimes place doctors in tricky situations, as early detection of ocular conditions is always the best approach to stop future vision loss.

Enter AvaGen (Avellino), the first commercially available test of its kind to help identify patients at risk for developing KCN and certain other corneal dystrophies. The DNA test generates a polygenic KCN risk score based on the analysis of 75 KCN-related genes and more than 2,000 gene variants, according to the company.¹ Since some ethnicities show a higher prevalence of this eye condition, the AvaGen test also factors this information into its results, the company says. The test is also purported to measure susceptibility of several corneal dys-

trophies, including epithelial basement membrane, granular, lattice, Reis-Bucklers, Schnyder and Theill-Behnke, Avellino states.¹

“Genetic testing for KCN provides one more data point for determining risk of disease development,” says Aaron Bronner, OD, of Boise, ID. “Unlike previous ways of screening for the disease, genetic testing provides a look not only at current risk status but also future risk. This can be both helpful and confounding as clinical decisions are made.”

KCN CLUES

On the screening front, KCN diagnostics have expanded and become even more refined in recent years.

For example, corneal tomography allows clinicians to evaluate the anterior and posterior cornea along with global pachymetry, says Melissa Barnett, OD, of UC Davis. Anterior segment optical coherence tomography (AS-OCT) can evaluate corneal epithelial thickness and wavefront aberrometry can be used to evaluate specific aberrations such as the third-, fourth- and fifth-order aberrations, especially vertical coma and trefoil. Also, corneal biomechanics can supply useful information to predict early KCN, she suggests.

“AS-OCT has certainly evolved to provide us much more information about the cornea in those at high risk or who actually have KCN, but their condition snuck by with traditional technologies,” adds Mile Brujic, OD, of Bowling Green, OH.

Currently the diagnosis of keratoectasia at a mild stage—“the sweet spot” for doing something about it—requires Scheimpflug imaging, Dr. Bronner says.

Beyond the traditional and enhanced diagnostic tools available, numerous studies have supported the premise that genetics play a role into whether an individual may develop KCN.

One recent investigation included genetic screening in a large cohort of Chinese and Greek patients with KCN, and its researchers suggested variants in the VSX1 and TGFBI genes might be responsible for the condition through autosomal-dominant inheritance patterns with variable expressivity.² The authors concluded that genetic screening is of great value in establishing a disease classification system of subclinical and early-stage KCN and for the preoperative screening of refractive surgery individuals to prevent postoperative corneal ectasia.²

Another relatively large KCN genome-wide association study used data from eye clinics in Australia, the United States and Northern Ireland. It reported the potential role of genes involved in apoptotic pathways and identified a genome-wide significant locus for KCN in the region of PNPLA2 on chromosome 11.³

Other research papers have found ethnicity plays a role in which populations may develop the disease.^{4,6} When comparing the risk of progression between East Asians, Europeans and Middle Eastern populations, one investigation found the latter group had the greatest risk, followed by Europeans and East Asians.⁴ Another recent investigation that looked at a US managed care network identified about 16,000 individuals with KCN. Its investigators found Black patients were 57% more inclined to develop KCN, followed by Latinos at 43%. Additionally, Asian Americans had 39% lower odds of developing KCN compared with Caucasians.⁷

POTENTIAL BENEFITS

KCN is a highly prevalent genetic disease, and early diagnosis and management is essential to preserve vision, says Dr. Barnett. “With early detection, we can recommend corneal stabilization with CXL to avoid corneal transplantation,” she says.

An early diagnosis can also improve the quality of life and independence for individuals with the condition, in addition to lessening the disease’s lifetime economic burden, Dr. Barnett explains. Genetic testing can provide reassurance and hope to individuals with KCN and their families, which will improve the vision-related quality of life over a person’s lifetime, according to her.

“The wonderful aspect of genetic testing is increasing awareness of KCN,” Dr. Barnett says. “KCN is a highly prevalent condition and should be ruled out on every single

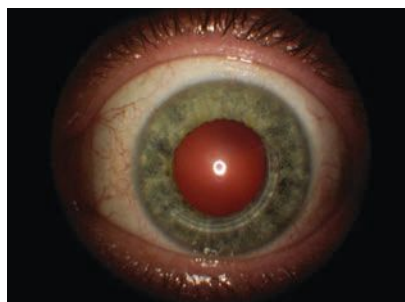


Photo: Brian Ohou, OD

Although genetic testing does not diagnose KCN, a positive risk profile could help recommend more frequent screenings or adjust treatment.

eye examination, just like dry eye disease and myopia.”

Dr. Bronner, who isn’t using the AvaGen test, believes this tool does have a role, although in its current form, a relatively narrow one.

The benefits he sees in genetic testing include enhanced vigilance in screening, which could allow the disease to be caught earlier—and subsequently halted with CXL—and reduced tolerance for otherwise borderline refractive surgery cases. “As with many diseases, the earlier you catch KCN, the better off the patient will be,” Dr. Bronner explains.

Although genetic testing does not diagnose the condition, a positive genetic risk profile can be used to recommend more frequent screenings with Scheimpflug imaging that can be used to diagnose the disease, at which point timely intervention can be offered, he adds.

Since KCN is known to have a genetic component, many patients who are diagnosed with the condition want to know if they can pass it onto their children or whether other family members could be at risk, says Stephanie Woo, OD, of Las Vegas.

Dr. Woo will recommend genetic testing if a patient is at high risk for KCN, with indicators such as large changes in refractive error, large amounts of cylinder and visual acuity less than 20/20 with correction. When she does perform genetic

testing, Dr. Woo will do it along with other diagnostic tests, such as topography, tomography and pachymetry.

“This helps us determine the genetic risk factor and develop an appropriate treatment plan for that specific patient,” Dr. Woo says.

Additionally, the test can be used on children. Since younger patients tend to progress more rapidly, it is important to examine and treat children of individuals with KCN, Dr. Barnett suggests. “A person’s genes don’t change over a lifetime,” she says. “Since genetic testing is easy to perform and isn’t painful, it is an option for adults and children alike.”

This example hit close to home for Dr. Brujic, since one of the first AvaGen tests he administered at his practice was on his young daughter.

“We were going to put her in orthokeratology (ortho-K), but she had suspiciously thin corneas. They looked normal and had a normal curvature and shape, but they were very thin to the point where I wanted to rule this out before we proceeded. We don’t have a family history of KCN, but it was such a bizarre clinical finding,” Dr. Brujic explains.

After running the test and receiving a zero-risk result, Dr. Brujic said he felt a higher sense of security putting his daughter on an ortho-K treatment regimen. “The last thing I’d want is to put her or another patient at risk by placing them in ortho-K lenses that could lead to quicker KCN progression,” he says.

ONE PIECE OF THE PUZZLE

It is important to use genetic testing as one piece of the clinical decision-making process, along with clinical tests, including corneal topography, corneal tomography, OCT, wavefront analysis, optical response analyzer, keratometry and visual acuity, Dr. Barnett says. Other considerations include age, ethnicity, allergies, asthma, atopy, sleep apnea,



KCN GENETIC TESTING: WHERE DOES IT FIT IN?

collagen vascular diseases, diabetes, mitral valve prolapse and Down syndrome, she adds.

Even if a practice doesn't have advanced technology, evaluating for risk factors such as eye rubbing, the quality of vision on refraction, fre-

quent changes in glasses or contact lens prescription, retinoscopy and mires on keratometry can be used, Dr. Barnett suggests.

Like most medical diagnoses, one test in isolation is not sufficient, echoes Dr. Woo. "Just because

someone is at high risk on their genetic test does not mean that they have KCN," she says. Other testing, such as topography, refraction and a slit lamp exam, will be needed.

This test shouldn't be used alone to recommend CXL, which requires

My Early Experience with Genetic Testing for KCN

Repeated results from one patient are oddly different.

By Brian Chou, OD

Genetic testing for keratoconus (KCN) is promoted as a new diagnostic tool. The opportunity is to move ahead of lagging disease indicators—like apical scarring, Vogt's striae and Fleischer's rings—to predictive heritable indicators of KCN. Having this information could help identify corneal crosslinking candidates and patients at greater risk for keratectasia after LASIK. I share my early clinical experience.

Genetics and KCN

KCN has a well-known genetic link. A 2012 review article found that 6% to 23.5% of patients with KCN have a family member with it.¹ Furthermore, studies have shown that relatives of KCN patients have a 15x to 67x higher risk of developing KCN.² Several genome-wide

association studies of KCN cases have confirmed previously identified genes and found several new susceptibility loci linked to KCN.³

External factors like eye rubbing and mechanical interaction of the cornea appear to combine with genetic predisposition to result in KCN.⁴ A case-control study of 33 KCN patients with highly asymmetric corneas and 64 controls found that vigorous eye rubbing and applying eye pressure during sleep were associated with the more afflicted eye.⁵

AvaGen by Avellino Labs

In February 2020, Avellino Labs introduced AvaGen, the first commercial genetic test to assess risk for KCN and detect the presence of certain corneal dystrophies. Due to the COVID-19 pandemic, Avellino Labs suspended producing and processing AvaGen tests until June 2021 when Avellino announced full nationwide availability of AvaGen.^{6,7}

AvaGen involves collecting four noninvasive inner cheek (buccal) swab samples from the patient. Results typically arrive in two to

four weeks. One outcome of AvaGen identifies the presence or absence of hereditary corneal dystrophies linked to the TGFBI gene: granular type 1 and type 2, epithelial basement membrane, lattice, Reis-Bücklers and Thiel-Behnke. These dystrophies are monogenic (*i.e.*, caused by a single genetic mutation), and AvaGen is designed to yield a yes/no result for these.

The KCN part of AvaGen is more complex because KCN is polygenic. Many genes encode for KCN, with environmental factors also having an influence. A polygenic risk score (PRS) devised by the company is returned on a scale of 0 to 100, where a PRS of 0 indicates no genetic risk. A higher AvaGen PRS is reported to indicate a greater genetic risk of developing KCN.

Avellino says that AvaGen examines over 2,000 variants across 75 genes for KCN using whole-exome DNA sequencing, a fast and cost-effective technique to selectively sequence an individual's DNA encoding for proteins or exons. Most genetic diseases are thought to show mutations in exons, so sequencing them can efficiently identify disease-causing mutations. All the exons in a genome make up an exome, which is understood to represent about 1% of a person's DNA.

The Test Subject

Patient JL, a 74-year-old Caucasian male with known KCN and a strong family history of KCN, (sister, half-brother, aunt) served as the subject. On 3/2/20, best-spectacle corrected visual acuity was 20/25 OD with +1.75 -5.50x095 and 20/20 OS with +1.25 -3.00x070. Corneas showed an absence of apical scarring, Vogt's striae and Fleischer rings. Tangential corneal topographies showed a globus-type cone (Figure 1).

First Submission

Buccal swab samples were collected on 4/24/20 and received by the lab on 4/27/20. The test requisition form was completed without disclosing the diagnosis of KCN and family history of KCN. The AvaGen report was generated on 8/11/21 with a PRS of 9, meaning the patient's risk for KCN was low (Figure 2). Genes with KCN-associated variants were ZEB1 and MYLK. The low risk score did not make sense to me, so I submitted a repeat sample.

Second Submission

Buccal swab samples were again collected from JL on 9/12/21 and received by the lab on 9/16/21. The test requisition form was submitted using an alias without disclosing a known diagnosis of KCN or the family history of KCN. The AvaGen report was generated on 9/26/21 with a risk score of 22, indicating the patient's risk for KCN was low (Figure 3). Genes with KCN-associated variants were MYLK, AGBLI and ZEB1. The different risk score and additional variant for the same patient was unexpected, so I submitted yet another repeat sample.

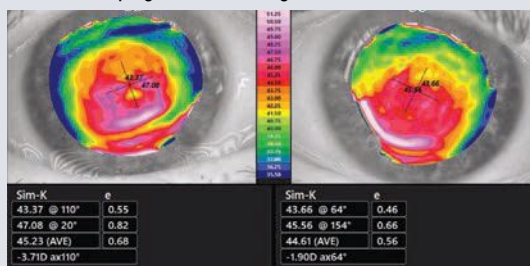


Fig. 1. Topographies showed a globus-type cone.

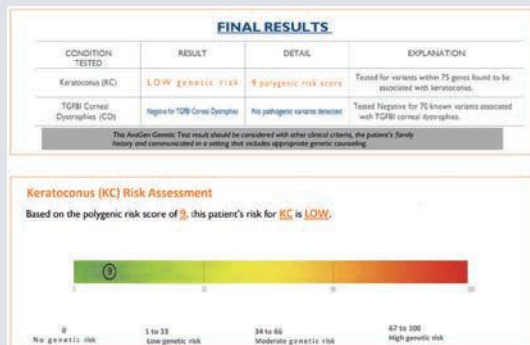

Fig. 2. The first test determined that the PRS was 9.

a diagnosis of progressive keratectasia, Dr. Bronner notes. With genetic profiling in diseases that aren't purely genetic, be careful in how you interpret and present the data to patients. Genetic testing alone won't determine the diagnosis

of KCN, but if a patient scores in the low-risk category, a practitioner may adjust their treatment plan, Dr. Woo adds.

For instance, if a child has a high amount of astigmatism, normal topography and low-risk results from

a genetic test, consider repeating their refraction, topography and slit lamp exam annually or every six months. If that same patient scores high on the genetic risk scale, consider seeing them more frequently to monitor for KCN, she suggests.

Third Submission

Buccal swab samples were again collected from JL on 10/10/21 and received by the lab on 10/15/21. The test requisition form was submitted under yet another alias, this time disclosing a known diagnosis of KCN but not disclosing the family history of KCN. The AvaGen report was generated on 11/10/21 with a PRS of 61 categorizing the patient's risk for KCN as moderate (Figure 4). Genes with KCN-associated variants were COL2A1, COL4A1, COL5A1, COL6A1 and LTBP2.

Same Patient DNA, Three Different Results

To recap, the PRS of the first submission came back as 9, the second submission came back as 22 and the last submission came back as 61. The first two submissions identified genes with KCN-associated variants as ZEB1 and MYLK, although the second submission also picked up AGBLI. The third submission did not detect ZEB1, MYLK or AGBLI, while finding five other genes with KCN-associated variants that were not detected in the first two submissions.

The inconsistency of the results is concerning. As the subject's DNA composition remained the same, some as-yet-unknown extrinsic factor contributed to the findings.

What effect could inaccurate or inconsistent genetic results have on patient health and safety? Some doctors are reportedly using AvaGen to tip the scales in deciding whether to perform corneal surgery. These are non-trivial decisions. What if a patient undergoes corneal crosslinking unnecessarily based on genetic test results that mistakenly suggest elevated risk for KCN? What if a 25-year-old myope gets a PRS of 9 (like the first submission), contributing to a surgeon's decision to perform LASIK, yet the patient subsequently develops keratectasia?

Perhaps my findings are an anomaly. I encourage other practitioners to share their experience.

While my primary concern is with the inconsistent results for samples submitted from the same patient, clinicians also need to know how different demographic and clinical data affect the PRS calculation for AvaGen. The specific details of the methods were not

available to AvaGen providers at the time that I inquired. However, I learned that Avellino is developing a white paper to shed light on this calculation.⁸

Eyecare professionals need to know the clinical validity and clinical utility of the AvaGen testing and the PRS algorithm. Clinical validity refers to how well the genetic variants being analyzed relate to the risk of developing KCN. Think of clinical validity as including sensitivity, specificity and predictive value.⁹ Presently, there is no federal oversight of the clinical validity of most genetic tests.¹⁰ Clinical utility refers to whether the test can help with diagnosis, treatment, management or prevention of KCN. Neither the FDA nor CMS has issued formal plans to regulate the clinical utility of genetic tests.¹⁰ Due to the relative newness of clinical genomics, oversight of clinical validity and clinical utility is evolving.

While precision medicine is welcome in KCN cases, the clinical validity and utility of testing like AvaGen needs greater characterization by independent clinicians and researchers, laboratories and other stakeholders. My reported findings are limited because they come from a single patient. They cannot necessarily be generalized. Yet the inconsistency of the AvaGen results also cannot be discounted. Their mere existence should give clinicians pause to consider if it is an isolated aberration or suggestive of a need for refinement in the test.

Dr. Chou practices at ReVision Optometry, a referral clinic for keratoconus and scleral lenses in San Diego. He reported the first US case of Intacs for keratoconus, wrote the chapter on keratoconus in Ocular Therapeutics Handbook, and is a past recipient of the National Keratoconus Foundation's Top Doctor award.

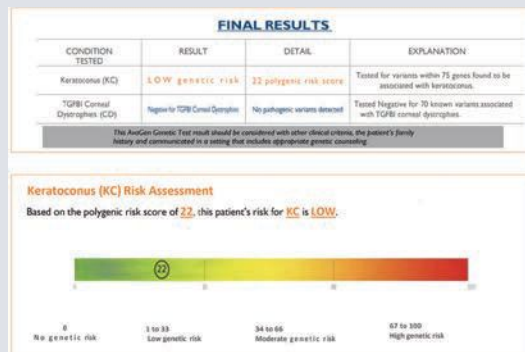


Fig. 3. The second test returned a PRS of 22.




Fig. 4. A third test measured PRS at 61.

1. Wheeler J, Hauser MA, Afshari NA, et al. The genetics of keratoconus: a review. *Reprod Syst Sex Disord*. 2012;Suppl 6:1.
2. Rabinowitz YS. The genetics of keratoconus. *Ophthalmol Clin North Am*. 2003;16(4):607-20;vii.
3. Bykhovskaya Y, Rabinowitz YS. *Exp Eye Res*. 2021;202:108398.
4. Rabinowitz YS, Galvis V, Tello A, et al. Genetics vs. chronic corneal mechanical trauma in the etiology of keratoconus. *Exp Eye Res*. 2021;202:108328.
5. Mazharian A, Panthier C, Courton R, et al. Incorrect sleeping position and eye rubbing in patients with unilateral or highly asymmetric keratoconus: a case-control study. *Graefes Arch Clin Exp Ophthalmol*. 2020;258(11):2431-9.
6. Business Wire. Avellino expands production of genetic test kits for coronavirus detection. AP News. apnews.com/bpress-release/business-wire/coronavirus-pandemic-science-business-health-public-health-0d4b-55988ba24271a23fe380fbba72a. March 19, 2020.
7. Avellino launches AvaGen nationwide as first genetic test to quantify keratoconus risk and presence of corneal dystrophies. Business Wire. www.businesswire.com/news/home/20210602005304/en/avellino-launches-avagen-nationwide-as-first-genetic-test-to-quantify-keratoconus-risk-and-presence-of-corneal-dystrophies. June 2, 2021.
8. Personal communication with Paul Dorsey, MS, senior genetic counselor of Avellino Labs.
9. Burke W. Genetic tests: clinical validity and clinical utility. *Curr Protoc Hum Genet*. 2014;81:9.151-8.
10. Regulation of genetic tests. National Human Genome Research Institute. www.genome.gov/about-genomics/policy-issues/regulation-of-genetic-tests.



KCN GENETIC TESTING: WHERE DOES IT FIT IN?

GRAY AREAS

Despite genetic testing's benefits, misperceptions of its role need to be considered, Dr. Bronner points out.

"I've heard people describe this test as being able to diagnose future KCN. This is incorrect," he says. "As with many diseases with a genetic risk, development of KCN is multifactorial, so even people with a 'high risk' genetic profile aren't guaranteed to develop the disease."

Another caveat: this can lead to unnecessary healthcare expenditures with frequent screening, and most insurance plans don't pay for truly diagnostic tests for KCN, barring an actual ICD-10 KCN code. So these screening costs are, in most cases, passed on to the patient.

The flip side of this scenario may also hold true. A patient with a first-degree family member with KCN who receives a "low/no risk" result may be saved screening expenses, Dr. Bronner explains.

"The final caution with this test

is how it might prevent otherwise good candidates for refractive surgery from proceeding with a desired refractive procedure," Dr. Bronner says. "If I were the doctor ordering this test, and it came back positive for genetic risk but the patient had no other risk factors for ectasia/KCN, that would shape my recommendations for LASIK/PRK."

With that said, in his 15-year career treating thousands of refractive surgery patients, Dr. Bronner had only one patient with no true ectasia risk factors on exam who later developed post-LASIK ectasia.

"Based on my experience alone, I feel this test has more potential to interfere with otherwise safe refractive surgery than it does to prevent unsafe surgery," he says. On the other hand, for somewhat borderline refractive candidates—especially in those with a family history of KCN—this test could be extremely valuable in shaping firm recommendations against surgery, he adds.

"As with all forms of genetic testing, you have to avoid painting the risk with too broad of strokes," Dr. Bronner says. "If you use this test, you have to avoid taking the information too far."

Yet another consideration is the technology's newness. The test's predictive value is likely to improve as sample sizes grow.

As with all new technologies, you may get very clear delineated answers in some cases, but you may have additional variables that obscure the clearest path forward in others, Dr. Brujic adds. For individuals in the middle, the test can provide another layer of complexity to the diagnostic algorithm.

For example, if a patient has normal corneas and other diagnostic tests have ruled out KCN but the parents have the condition, ordering the genetic test is clearly of value, Dr. Brujic says. However, if a test is ordered because a patient has certain suspicious corneal topog-

Q&A With Avellino

Here, Avellino representatives Yelena Bykhovskaya, principal scientist, and Joe Boyd, global head of sales and marketing, offer responses about their test's accuracy, benefits and the possible reasons why a clinician might receive varying results from the same patient.

What are the benefits of genetic testing for KCN for patients and practitioners?

Early diagnosis of keratoconus (KCN) is critical to successful medical management of the disease to preserve vision—a goal shared by both patients and practitioners.

Genetic testing, including AvaGen (Avellino), helps eyecare professionals (ECPs) uncover a potential risk for KCN even prior to a diagnosis suspected by preliminary indications revealed via slit lamp exam, keratometry, topography or tomography. Further, a genetic diagnosis of KCN informs patients and families of a risk profile, which allows for even earlier medical intervention to protect against vision loss.

AvaGen provides ECPs a tool to test patients and detect corneal conditions earlier, subsequently allowing treatment to begin sooner and

counter the course of the disease. For LASIK and other corneal surgical procedures, genetic testing provides surgeons with additional data points to consider for a patient's treatment plan by ruling patients in or out for surgery.

What is the accuracy rate of the test and what are the scores based on?

KCN is a polygenic disease. Avellino developed a proprietary algorithm to determine a risk score (a polygenic risk score, or PRS) based on the genetic testing of a large cohort of available KCN patients and controls collected by the company. The testing process includes sequencing a panel of genes to determine the number of risk and protective variants in the patient. These variants determine the patient's PRS that fall into a low, moderate or high risk.

The clinical sensitivity of AvaGen's PRS score for KCN is estimated to be 80% in the discovery cohort. Avellino is currently performing a clinical validation of sensitivity in an independently collected large cohort of KCN cases and controls. The clinical sensitivity and specificity of the test may continue to improve as the test numbers increase and as we include more risk genes for KCN in the gene panel.

As this is a new technology, are there any current limitations of the testing?

Polygenic disease, where several risk genes each contribute to the manifestation, is very different from the category of monogenic diseases, (e.g., corneal dystrophies and retinitis pigmentosa, which are inherited in a Mendelian pattern). Most physicians are quite familiar with monogenic diseases, where the presence of a pathogenic variant in the target gene leads to the disease. The clinical test reports for monogenic diseases are binary "yes or no" results. For polygenic diseases, a PRS is used to determine a patient's genetic risk profile.

The methodologies of polygenic risk are evolving and, while currently there are no clear standards in the field on how this statistical algorithm should be developed or reported, we continuously improve the AvaGen test scoring methods and robustness. In addition to following the latest improvements in PRS algorithm development, Avellino is increasing the size of the cohort of KCN patients (cases) and healthy individuals (controls) in collaboration with various eye clinics. We also look to the published data on genetic association studies in KCN to consider in future gene panels.

raphy readings or refractive error measurements, a moderate risk on genetic testing may increase suspicion but still doesn't clearly indicate KCN.

"With these types of early findings, we are looking for further genetic information to determine how closely we should be monitoring this individual or whether we can let this person go a bit longer without seeing them," he suggests.

If a patient has a family history of KCN with negative, healthy corneal findings and a low-risk genetic test result, would it be reasonable for the individual to undergo refractive surgery? "Assuming all other clinical findings support refractive surgery, the answer would be yes," Dr. Brujic says. "That would definitely make me feel more comfortable recommending refractive surgery."

Another area that requires a measured approach to the test is a patient's potential reaction to the results, adds Dr. Woo. A patient

who scores high on the genetic risk scale might become anxious or develop emotional issues related to the information, she explains.

FINAL THOUGHTS

Genetic testing for KCN may offer insight into a patient's future risk of developing the condition, yet doctors caution not to skip out on the tried-and-true screening tools for a true clinical assessment.

"Genetic testing is a supplemental test in screening for keratectasia. Scheimpflug corneal imaging does the heavy lifting and is the gold standard for diagnosing the conditions," Dr. Bronner says. "This modality's ability to detect subtle patterns in pachymetric profiles, topographies and especially elevation deviations make it extremely useful in the diagnosis of early keratectasias, and careful interpretation of this data will allow avoidance of refractive surgery for at-risk patients as well."

Adds Dr. Barnett: genetic testing helps identify patients who are at risk of KCN, but similar to many genetic tests, there are undiscovered genes that may contribute to the disease. "As new genes and variants are discovered, genetic testing for KCN will continue to evolve," she says. **hcccl**

1. Avellino Launches AvaGen Nationwide as First Genetic Test to Quantify Keratoconus Risk and Presence of Corneal Dystrophies www.businesswire.com/news/home/20210602005304/en/avellino-launches-avagen-nationwide-as-first-genetic-test-to-quantify-keratoconus-risk-and-presence-of-corneal-dystrophies. June 2, 2021
2. Chen S, Li XY, Jin JJ, et al. Genetic screening revealed latent keratoconus in asymptomatic individuals. *Front Cell Dev Biol*. 2021 May 31;9:650344
3. McComish BJ, Sahebajada S, Bykhovskaya Y, et al. Association of genetic variation with keratoconus. *JAMA Ophthalmol*. 2020 Feb 1;138(2):174-181.
4. Ferdi AC, et al. Keratoconus natural progression: A systematic review and meta-analysis of 11,529 eyes. *Ophthalmol*. 2019;126(7):935-45.
5. Abu-Amaro KK, Al-Muammar AM, Kondkar A. Genetics of keratoconus, where do we stand? *J Ophthalmol*. 2014; 2014: 641708.
6. Hardcastle AJ, Liskova P, Hysi PG. A multi-ethnic genome-wide association study implicates collagen matrix integrity and cell differentiation pathways in keratoconus. *Communications Biology* 4, 266 (2021).
7. Woodward MA, Blachley TS, Stein JD. The association between sociodemographic factors, common systemic diseases, and keratoconus: an analysis of a nationwide healthcare claims database. *Ophthalmology*. 2016;123(3):457-65.

As more data is gathered over time, will the test offer an even greater predictive value?

The human genome has approximately 22,000 genes, and there are thousands whose function is yet undiscovered, thus there is ample opportunity to continue to understand KCN.

The current test detects 75 genes; however, published KCN research indicates there may be many more that contribute to genetic risk for this disease. Future iterations of AvaGen may include these additional genes, increasing the test's predictive value and thus its clinical utility.

If a doctor submits more than one sample from the same patient and gets a different risk score, what could be the cause of this?

The AvaGen test was launched in June 2021, with a significant PRS algorithm update in October of the same year. Therefore, depending upon the date of submission, different scores from the same patient are possible.

The next generation sequencing methodology used in the AvaGen test has a greater than 92.7% run-to-run concordance. Therefore, multiple testing of the same person's DNA occasionally results in different calls for some DNA variants. However, since the PRS is based on

the combination of multiple variants, in these cases, it may shift a few points but generally will be within the same risk category (low, medium or high). Our laboratory testing results indicate that for a majority of clinical samples, identical PRS scores are calculated for multiple replicates of the same person's DNA sample.

It is important to understand that there is some fluidity with the risk scoring because it is not a single pathogenic mutation analysis, as in monogenic diseases. New knowledge and advancements in the field of polygenic diseases will lead to better risk assessments and understanding of the genes that contribute significantly to the risk.

Polygenic conditions are complex, and a PRS should always be used in conjunction with other diagnostic testing, a clinical eye examination, guidance from a qualified doctor and referral to a specialist as appropriate so the patient receives the best possible treatment course. Results should also be considered with other clinical criteria, the patient's family history and behavioral and environmental contributors. Results of the genetic testing should be communicated in a setting that includes available genetic counseling.

Do different demographic and clinical data affect the PRS calculation?

Yes. Historic lack of diversity in genomic studies led to limited applicability of the majority of PRS. However, our PRS was developed using a diverse ethnicity cohort.

In general, you want a genetic test to work in all ethnic groups. However, different genes or different risk variants may give rise to the same disease in different populations. Thus, when deriving the PRS system, it's best to have a good distribution of different ethnicities in the discovery cohort so differences in allele frequencies or different risk variants can be adjusted using statistical methodology.

In addition, polygenic disease is influenced by environmental and behavioral factors that can trigger activation and progression.

What's the clinical utility of AvaGen testing?

KCN is an underdiagnosed disease with sight-threatening consequences. Early detection through genetic testing leads to improved clinical outcomes through early intervention to slow progression. Importantly, a genetic finding of KCN in one patient can lead to even earlier clinical intervention in that patient's family.

FITTING THE KERATOCONIC EYE POST-SURGERY

We discuss how to carefully initiate contact lenses after various corneal procedures, including crosslinking.

By Melissa Barnett, OD, Barry Eiden, OD, and Louise Sclafani, OD

For those patients who have suffered vision loss from keratoconus, contact lenses usually provide optimal visual rehabilitation and remain our first-line therapy given their versatility and low risk, as discussed in Part 1 of this two-part article (published in the Nov/Dec 2021 issue). Many of the lens modalities discussed in Part 1—scleral, corneal, soft contact, specialty soft, piggyback and hybrid—are also viable options after keratoconus surgical procedures, as the cornea will likely still have some irregularities that impact vision and are not amenable

to spectacle correction. Some of these surgical procedures, such as corneal collagen crosslinking (CXL) and intrastromal corneal ring segments (ICRS), are intended to halt progression and reduce some of the ectasia, thereby making contact lens fitting easier.

When a keratoconus patient has become intolerant of contact lenses, has visually compromising scars or corneal perforation, a full or partial keratoplasty is recommended. In 2016, the Eye Bank Association of America reported that keratoconus was the most common indication for penetrating keratoplasty (PKP)

in the United States and 6,195 transplants are performed each year.¹ Fortunately, advancements in contact lens technology and the introduction of CXL have reduced the incidence of PKP over the years.

When to initiate contact lens therapy after a procedure depends on the type of procedure and the eyes' response to healing. When fitting, monitor the state of the corneal tissue. As these are more “fragile” corneas, it is important to use high oxygen permeable materials, schedule more frequent observation and emphasize compliance to reduce complications.

ABOUT THE AUTHORS



Dr. Barnett is a principal optometrist at the Univ. of California, Davis Eye Center. She is chair of the AOA's Contact Lens and Cornea Section, a fellow of the American Academy of Optometry, a diplomate of the American Board of Certification in Medical Optometry, a fellow and global ambassador of the BCLA and a board member of the GPLI and the International Society of Contact Lens Specialists.



Dr. Eiden is president and medical director of North Suburban Vision Consultants, president and founder of the International Keratoconus Academy of Eye Care Professionals and co-founder and president of EyeVis Eye and Vision Research Institute. He is a fellow of the American Academy of Optometry and the Scleral Lens Education Society.



Dr. Sclafani is vice president of professional affairs for SynergEyes and sees patients at SoLo Eyecare in Chicago and the Illinois College of Optometry. She is a fellow of the Scleral Lens Society and associate member of the International Society of Contact Lens Specialists.

Financial disclosures relevant to this article:

Dr. Barnett has consulting and/or lecturing relationships with ABB, Acculens, Bausch + Lomb, Contamac, CooperVision, EveryDay Contacts, Johnson & Johnson Vision Care, SynergEyes and Tangible Science.

Dr. Eiden has consulting, lecturing and/or financial interests with the following companies: Alcon, Avellino, Bausch + Lomb, CooperVision, Oculus, Special Eyes, SynergEyes and VTI.

Dr. Sclafani is vice president of professional affairs at SynergEyes.

In Part 2 of this two-part article, we'll discuss in detail these surgical interventions and post-procedure contact lens fitting, including the application of scleral lens fitting.

CORNEAL COLLAGEN CROSSLINKING

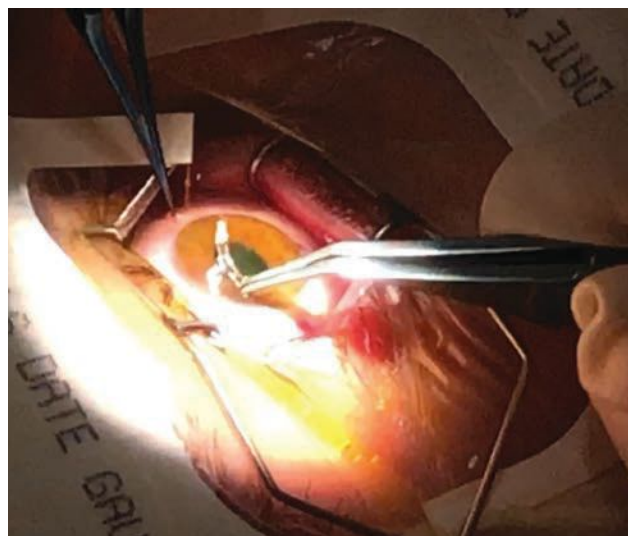
Improved technology and early diagnosis have led way for earlier surgical intervention so that patients do not have to succumb to corneal transplantation. In 2016, the FDA approved the Avedro KXL System and Photrexa for CXL. The procedure is intended to both strengthen and stabilize an ectatic cornea by applying riboflavin (vitamin B12) and controlled UV light. It is indicated for corneas over 400 μ m thick that have shown progression of keratoconus or post-surgical ectasia. The eye must be free of scars, herpetic infection, autoimmune disease and wound healing issues.

Some interesting studies came out of the recent pause in elective procedures due to the COVID-19 pandemic. A paper by Shah et al. in the UK demonstrated that in their study, all 46 subjects with progressive keratoconus worsened during the wait time to receive treatment.² Goh et al. showed a similar finding in New Zealand with 39.6% of 96 eyes further worsened.³

Early intervention with CXL is critical to achieve maximum benefit from the procedure, but the post-operative management is crucial. In the US, the 'epi-off' technique, which requires epithelial debridement prior to riboflavin application, is the only approved procedure. It also requires the use of a soft therapeutic bandage lens for seven to 10 days following surgery while the surface heals. However, the epithelium continues to strengthen and the stroma remodels for several months; therefore, this tissue must be respected.

The epithelium remains fragile for several months to a year with increased apoptosis and changes in thickness and density, which may alter visual acuity likely due to induced higher-order aberrations. The corneal nerve plexus is also altered, reducing sensitivity for up to a year, making it critical for the clinician to monitor carefully for ocular surface damage, even though the patient may be asymptomatic. Finally, stiffening and remodeling of the stroma leads to curvature changes for several months, so be aware that modifications may be needed to provide optimal vision and the healthiest outcome.^{4,7} This may necessitate the use of pre-procedure spectacle wear for five to six weeks to avoid any damage and allow for full recovery.

Many patients achieve better spectacle visual acuity after CXL, but most will still require a specialty contact lens design. Because diagnostic tools allow earlier diagnosis and the opportunity to halt progression with CXL, patients can benefit from more options for optical corrections, especially spectacles, soft lens designs and hybrid lenses, as their disease status may stay in the mild to moderate phase. Patients may be anxious to be fit or refit into contact lenses, but it's important to stress that rehabilitation may take time to get the safest and optimal fit and the fitting process may begin around one to two months following the procedure.



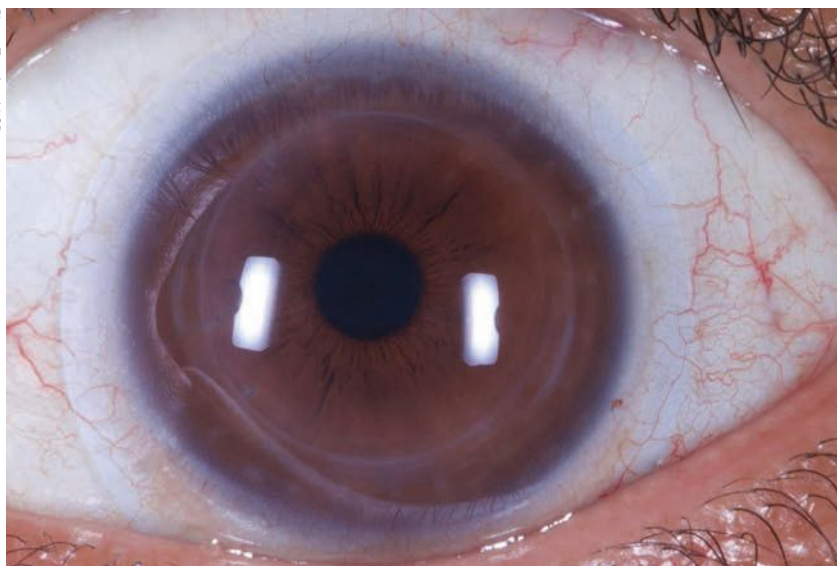
An ICRS is placed into an intrastromal channel immediately after undergoing CXL. Note the riboflavin-induced yellow hue of the cornea.

Higher Dk soft lenses may be fit, but careful observation for signs of hypoxia is important; also, lens stability is often challenging. Rigid corneal lenses are an option, but the fit may be delayed or require multiple modifications to avoid landing on the cornea during the postoperative months while it is in transition. It may be safer and require fewer re-fits if the prescriber monitors the topography until stability is achieved.

Hybrid lenses can be considered, as they should vault the corneal tissue approximately 100 μ m, which will maintain corneal integrity, and the newer designs emphasize landing on the sclera rather than GP portion; however, timing is still crucial. Many of these patients may present as scleral lens wearers, and their habitual design can be re-established much sooner—likely within a month, since the surface does not come into contact with the lens. During the first few months following the procedure, the cornea undergoes a series of changes that may necessitate modifying the scleral lens fit and power; therefore, proper patient education is essential.

Photo: John Galles, OD

Photo: Tom Arnold, OD



A scleral lens over an eye post-ICRS.

As discussed, much of our attention should be directed to the ocular surface and lens designs that touch the cornea should be avoided until the epithelium is healed. Some of these patients will be novice lens wearers and inadvertently self-inflict mild trauma to the surface; take heed of their need for additional training.

Between improvements in CXL as the technology matures and potentially better outcomes from ‘epi-on’ procedures (where the cornea remains intact) with supplemental oxygen, there is hope that contact lens management can be initiated sooner for this population, as the procedure will become more accepted and available.

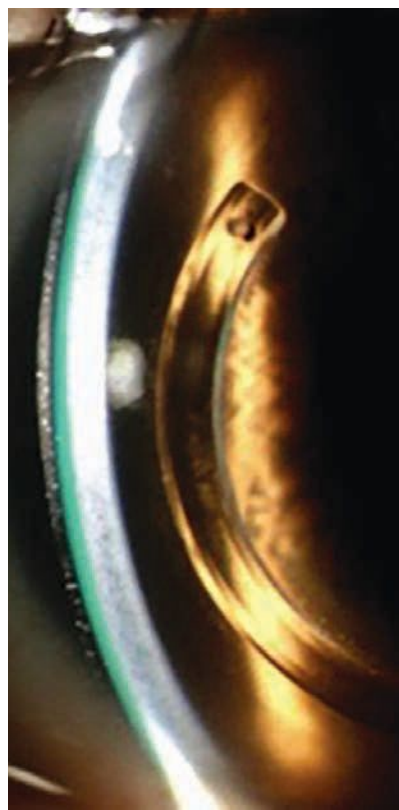
INTRACORNEAL RING SEGMENTS (ICRS)

These implants are used to flatten corneal curvature and reduce or create more “regular” astigmatism. Often, it is done in combination with CXL to help maintain the effect. There are many different approaches to this procedure with regard to the number of segments and location, and the outcomes

vary.⁸ Undercorrection, overcorrection or residual refractive error can be remedied with optical devices; however, more serious complications need to be monitored during the long-term post-op phase. Some of these include neovascularization toward the incision, migration of a segment toward the wound, extrusion of the segment, stromal deposits, epithelial ingrowth and flap wrinkling.

Many times, there is elevation at the ring site; it is important to respect the tissue overlying the inserts and not allow too much touch or pressure from a lens. The contact lens practitioner must monitor the ICRS position, as mechanical trauma can cause the implants to erode at the insertion site or migrate forward. We must also document inflammation and deposits, since we may be the only professional monitoring these findings during the postoperative phase. Complications from the ring and/or contact lens must be monitored, since the insertion site can serve as an entry point for bacteria and lead to serious microbial keratitis, necessitating explantation of the device.

Photo: Tom Arnold, OD



A scleral lens over an eye post-ICRS.

The goal of the procedure is for the topography to be “normalized” so that spectacles or soft toric lenses can correct these eyes if the astigmatism becomes more regular and shifted towards the central visual axis.⁹ Other patients will benefit from larger diameter corneal rigid lenses or hybrid lenses that have reverse geometry curves and can accommodate an oblate cornea. If a smaller diameter corneal GP is used, a tandem system with high Dk soft base can provide protection of the underlying ring. Undeniably, scleral lenses are an excellent option as they are easy to vault and protect the corneal tissue.^{10,11}

Do not create too much clearance on these oblate corneas, though, as this can lead to hypoxic stress. Many patients who have been offered and underwent ICRS procedures are given the expectation that

they will not require contact lenses. While it is true that spectacle vision is improved, most patients will still benefit most from the optics of a contact lens.¹²

KERATOPLASTY

Corneal transplantation procedures are typically reserved for advanced keratoconus or eyes that have suffered trauma, endothelial disease or scarring from infection. The recuperation process is much longer and complicated than the procedures listed above, as it requires the integration of donor tissue.

Postoperative astigmatism is very common; however, the sutures can be manipulated during various stages of the healing process to provide a more regular surface and ease the fitting process. The surgeon must determine proper diameter of the donor graft—usually 0.50mm larger than the recipient bed. It should be large enough to avoid the visual axis, yet small enough to avoid interaction with the limbal vessels so as not to promote rejection. Some surgeons may opt to go only 0.25mm larger so that, as the eye heals, the adhesion between host and donor causes stretching, leading to flattening that can increase hyperopia or decrease myopia, which may be a desired effect.

Typically, there are six to eight interrupted sutures placed during surgery to hold the tissue in place; these may be removed starting at three months after the procedure. An additional running or continuous suture at 45 or 90 degrees that encircles the cornea creates tension, promotes host-donor integration, can be altered early to change the tension and is typically removed after one year.

During the early phases, if an excessive amount of astigmatism is present, selective removal or loosening of the sutures can reduce it. A

tight suture can be found in the plus cylinder axis and one can decrease the chord and radius of curvature to reduce toricity. A loose suture can be found in the minus cylinder axis and one can increase the chord and radius of curvature to reduce toricity. This may also be the location of edema or wound gap and may be transient or more serious. These points are mentioned because the fitting of a contact lens following a PKP may be dependent on the topography of the cornea. If modifications can be made early on, the long-term success can be improved by co-managing these opportunities.

It is important to set expectations for patients prior to surgery. Based on the type of procedure (full penetrating, partial lamellar or eccentric tectonic), etiology and surgical techniques, the outcomes may vary. Some patients may achieve success in spectacles; others will require contact lenses to attain the best visual outcome. It is safe to fit lenses at about 12 months after the procedure; however, many patients

and surgeons desire earlier fitting (*e.g.*, at six months) and this can be done as long as the following criteria are met:

- the cornea displays intactness of the wound
- antibiotic treatment is complete
- steroid use is minimal
- refraction and topography are stable
- the patient is psychologically ready

The latter is included because many patients are reluctant to interfere with their “new eye.” Many of these patients will require a contact lens, as irregular astigmatism is common. Typically, these surfaces require some form of a rigid design, and it is very important to respect the corneal host-graft junction. Most often, these patients have worn some form of contact lenses prior to surgery, so adaptation is easy, but the ideal modality may differ from patient to patient.

Remember that the goal is to improve vision without doing any harm. Prior to the fit, make sure to

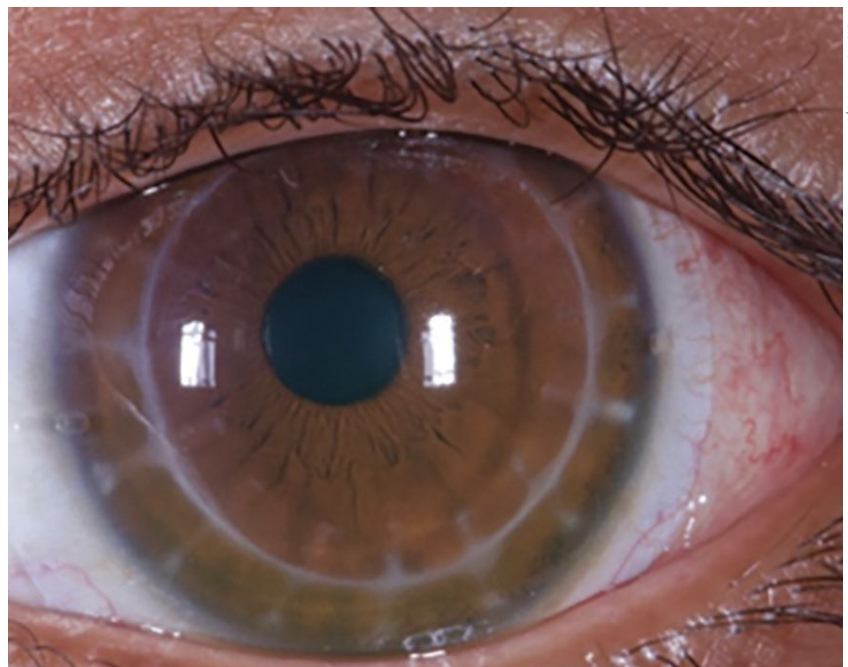


Photo: Tom Arnold, OD

A well-fit scleral lens over an eye that has undergone a corneal transplant.

document any remaining sutures, neovascularization, scars or erosions to rule out any contact lens-induced complications. Based on the healing, sutural technique and donor tissue, many graft topographies can result:

- a steep or proud graft is similar to a central keratoconus
- a tilted graft will result in local, eccentric ectasia
- a sunken graft may be more oblate in shape with a flat center and raised areas near the junction similar to a post-RK cornea

A rigid lens will center over the steepest part of the cornea, and since some of these eyes have irregular

pupils, larger optical zones are needed to improve centration and reduce flare. Some benefit from fitting inside the graft, while others will find it easier to land on the peripheral host cornea or on the sclera. Smaller corneal GPs are often a challenge; larger intra-limbal designs are preferred so that they can rest on the host tissue. Scleral lenses avoid all corneal interaction, and hybrid designs for post-surgical corneas are also an option.

In general, when fitting patients who have undergone corneal transplantation, we must monitor not only the superficial cornea and

respect the junction but also maintain the integrity of the endothelial layer to achieve optimal deturgescence. Pachymetry is essential, and endothelial cell counts can aid in determining continue viability of the graft tissue. It is also very helpful to monitor intraocular pressure, as many of these patients remain on steroids long-term. Although our focus is on the maintenance of the transplant, we must remember that it is attached to the rest of the eye and human body where many comorbidities exist, thereby optometrists are part of the transplant team for life.

Organizational Resources for Keratoconus

The complexity of keratoconus care need not be a deterrent to embracing this important aspect of optometry, particularly for ODs who have (or want) a thriving specialty lens practice. Numerous professional organizations are here to help.

- **The International Keratoconus Academy of Eye Care Professionals (IKA, www.keratoconusacademy.com)** promotes ongoing professional education and scientific development in the area of keratoconus and other forms of corneal ectatic disease. Its mission is to develop the knowledge base and awareness of the state of the art pertaining to the diagnosis and management of these conditions. The organization is oriented towards the eyecare professions. IKA accomplishes its mission by providing an array of educational initiatives, which include live events, web-based education, social media activities and publications in the professional literature. It is also dedicated to supporting ongoing clinical research. Membership is complimentary for eyecare professionals as well as for students and residents.

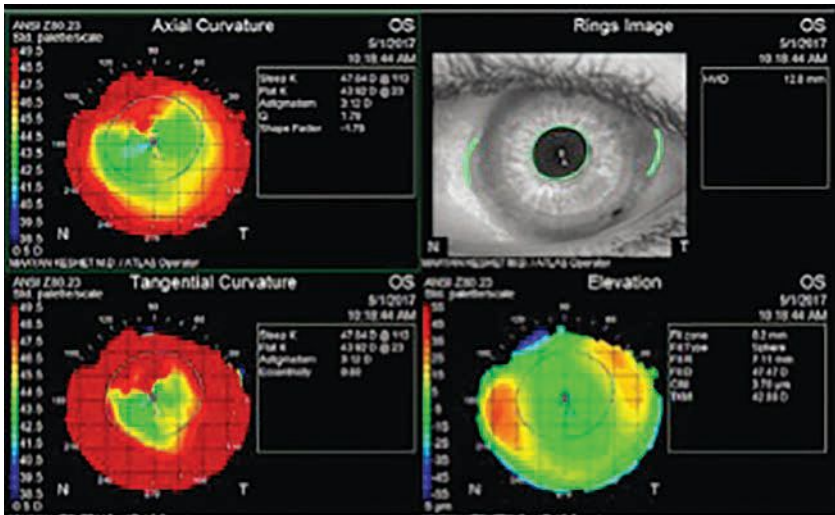
- **The National Keratoconus Foundation (NKCF, www.nkcf.org)** provides information, support and advocacy for patients who suffer from keratoconus as well as their family members. NKCF is an outreach program of Gavin Herbert Eye Institute at UC-Irvine. It is dedicated to increasing awareness and understanding of keratoconus and aims to provide resources to individuals with the disease.

- **The Scleral Lens Education Society (SLS, www.sclerallens.org)** aims to provide unbiased education to eyecare professionals regarding the science and art of prescribing scleral lenses. This is accomplished via live workshops and lectures as well as online webinars. Additionally, the organization supports education of the public relating to the indications, benefits and use of sclerals. Since the application of scleral lenses for keratoconus has grown tremendously over the past years, the SLS has taken on a significant role in the field of keratoconus education. Eyecare professionals can join the SLS and progress to fellowship status in the organization.

- **The American Academy of Optometry Cornea, Contact Lens and Refractive Technologies Section** is both the oldest and largest specialty section of the Academy. Its mission is to foster professional growth and advocate excellence in patient care through leadership, education and research. One can become a diplomate in this section by completing a rigorous process including peer-reviewed case reports, written and clinical testing, culminating in an oral interview to defend their knowledge and demonstrate a required level of expertise in various areas, including keratoconus. To date, there are 154 practitioners who have achieved this status worldwide. www.aaopt.org/membership/sections-sigs/fellows-sections.

- **The American Optometric Association Contact Lens & Cornea Section (CLCS)** is a nationally recognized segment of the American Optometric Association (AOA). Members of CLCS include eyecare professionals and optometry students who are dedicated to furthering their understanding in the field of contact lenses, cornea, diagnosis and treatment of anterior segment disease, refractive surgery and related technologies. The AOA CLCS council can be contacted at clcs@aoa.org.

- **The Gas Permeable Lens Institute (GPLI)** is dedicated to providing the eyecare community with unbiased education, practice-building materials and resources to realize the full benefits and advantages of GP and custom soft contact lenses. The GPLI provides a comprehensive schools program, including webinars and a three-day workshop program for cornea and contact lens residents. There are over 100 archived webinars from renowned speakers on topics such as myopia management, orthokeratology, scleral lenses, multifocal GPs, bitorics, keratoconus, spherical GPs, custom soft lenses and lens care. Other resources include a "Find a GP Specialist" database, several empirical lens design calculators, a comprehensive staff training module, a specialty contact lens coding and billing module, a case grand rounds troubleshooting book and a laboratory consultant FAQs module. Several resources are available for order online, including laminated cards on lens fitting and care as well as numerous consumer brochures on GP lenses.



Boh Summers, OD, and Mahayan E. Keshet, OD

Topography shows relative central flat and steep periphery (reverse geometry) in a post-PK cornea. This patient was fit into an oblate-shaped (steep skirt) hybrid lens.

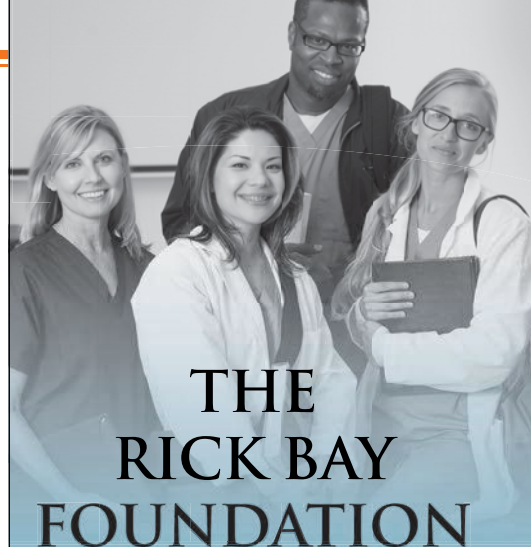
CONTACT LENSES AT THE CORE OF KCN

Keratoconus patients are fortunate to have many interventions available that can induce long-term changes that lessen the disease’s visual burden. Medical management of disease progression from the procedures discussed above has already shown to have a positive impact on the natural course of the disease. ICRS, topography- and tomography-guided PRK all aim to reduce disease severity via their impact on corneal shape and thus both uncorrected and best-corrected visual acuity.

Still, to this day, the mainstay of visual rehabilitation and improved function for those who have suffered vision loss from keratoconus is contact lenses. They are relied on early in the disease course when surgery isn’t yet advisable and complete “the last mile” even after successful procedures have taken place. Each case should be evaluated individually to come up with the most appropriate contact lens treatment. [RCLL](#)

1. Eye Bank Association of America 2016 Eye Banking Statistical Report. www.restore sight.org/wp-content/uploads/2017/04/2016_Statistical_Report-Final-040717.pdf. Accessed January 25, 2022.

2. Shah H, Pagano L, Vakharia A, et al. Impact of COVID-19 on keratoconus patients waiting for corneal crosslinking. *Eur J Ophthalmol*. 2021;31(6):3490-3.
3. Goh YW, Gokul A, Yadegarfar ME, et al. Prospective clinical study of keratoconus progression in patients awaiting corneal crosslinking. *Cornea*. 2020;39(10):1256-60.
4. Lombardo M, Serrao S, Rosati M, et al. Biomechanical changes in the human cornea after transepithelial corneal crosslinking using iontophoresis. *J Cataract Refract Surg*. 2014;40(10):1706-15.
5. Del Buey MA, Lanchares E, Cristóbal JÁ, et al. Immediate effect of ultraviolet-a collagen cross-linking therapy on the biomechanics and histology of the human cornea. *J Refract Surg*. 2015;31:70-1.
6. Li Z, Wang Y, Xu Y, et al. The evaluation of corneal fragility after UVA/riboflavin crosslinking. *Eye Contact Lens*. 2017;43(2):100-2.
7. Ozgurhan EB, Celik U, Bozkurt E, Demirok A. Evaluation of subbasal nerve morphology and corneal sensation after accelerated corneal collagen cross-linking treatment on keratoconus. *Curr Eye Res*. 2015;40(5):484-9.
8. Szczotka LB, Lindsay RG. Contact lens fitting following corneal graft surgery. *Clin Exp Optom*. 2003 Jul;86(4):244-9.
9. Moreira LB, Bardal RA, Crisogiovanni LR. Contact lenses fitting after intracorneal ring segments implantation in keratoconus. *Arq Bras Oftalmol*. 2013;76(4):215-7.
10. Park J, Gritz DC. Evolution in the use of intrastromal corneal ring segments for corneal ectasia. *Curr Opin Ophthalmol*. 2013;24(4):296-301.
11. Montalt JC, Porcar E, España-Gregori E, Peris-Martínez C. Visual quality with corneo-scleral contact lenses after intracorneal ring segment (ICRS) implantation for keratoconus management. *Contact Lens Anterior Eye*. 2019;42(1):111-6.
12. Szczotka-Flynn LB. Research review: How intracorneal rings affect lens fitting for keratoconus. *Contact Lens Spectrum*. May 1, 2010. Accessed January 30, 2022.



THE RICK BAY FOUNDATION

for Excellence in Eyecare Education

Support the Education of Future Healthcare & Eyecare Professionals

Scholarships are awarded to advance the education of students in both **Optometry** and **Ophthalmology**, and are chosen by their school based on qualities that embody Rick’s commitment to the profession, including integrity, compassion, partnership and dedication to the greater good.

ABOUT RICK

Rick Bay served as the publisher of *The Review Group* for more than 20 years.

To those who worked for him, he was a leader whose essence was based in a fierce and boundless loyalty. To those in the industry and the professions he served, he will be remembered for his unique array of skills and for his dedication to exceeding the expectations of his customers, making many of them fast friends.



INTERESTED IN BEING A PARTNER WITH US?

www.rickbayfoundation.org

(Contributions are tax-deductible in accordance with section 170 of the Internal Revenue Code.)



THE RICK BAY FOUNDATION
for Excellence in Eyecare Education

(The Rick Bay Foundation for Excellence in Eyecare Education is a nonprofit, tax-exempt organization under section 501(c)(3) of the Internal Revenue Code.)

Trends in Infectious Keratitis

Here's what you need to know to better diagnose and treat this condition.

By William Skoog, OD, and Lindsay A. Sicks, OD

Infectious corneal ulcers are a leading cause of blindness worldwide, affecting approximately six million people globally.^{1,2} Most of this burden falls on the developing world, complicated by lack of access to proper hygiene and health care.

When these infectious corneal ulcers—also known collectively as infectious keratitis (IK)—are left untreated, the resulting corneal opacity can result in blindness. In 2019, the World Health Organization proposed that member states recognize IK as a neglected tropical disease, along with trachoma and onchocerciasis.³ The designation was an effort to increase awareness of, and funding toward, ending this corneal disease and its associated preventable blindness.³

IK can be caused by a variety of pathogens, including bacteria, viruses, fungi and parasites. The condition is commonly associated with contact lens wear; however, it can also occur secondary to trauma, corneal surgery and ocular surface disease (OSD). In this article, we will review some of the pathogens responsible for IK, along with additional risk factors for development of and best practices for managing this potentially blinding condition.

BACTERIAL KERATITIS

Based on the difference in composition of the bacterial cell wall, bacteria can be categorized as either

gram-positive or gram-negative. Gram-positive bacteria do not have an outer membrane; rather, they contain a thick outer cell wall. Gram-negative bacteria have cell walls that consist of a thin middle layer with an outer membrane containing lipopolysaccharide.⁴ The difference in composition of the bacterial cell wall can determine, in part, how the bacteria will affect the host immune system. It is also important to have a general understanding of the characteristics of both gram-positive and gram-negative pathogens to choose the most appropriate medication for a patient's given disease.

Bacterial keratitis represents the most common type of IK globally, with polymicrobial infection accounting for up to 15% of all IK cases.² In North America, bacterial keratitis accounts for 86% to 92% of all IK cases.⁵ A recent study found that bacteria was the causative organism in 95.1% of all IK cases.⁶ Gram-positive organisms were more commonly isolated than gram-negative organisms. Coagulase-negative *Staphylococcus* (CoNS) species, such as *Staphylococcus epidermidis*, are the most common gram-positive bacteria (25.7%), while *Pseudomonas aeruginosa* is the most common gram-negative bacteria (23.4%). CoNS are ocular commensal organisms found in the normal flora of the skin, eyelid and conjunctiva, whereas *Pseudomonas aeruginosa* is most

commonly found in soil, water and vegetation.⁷

A closer look at the study's population revealed that *Pseudomonas aeruginosa* was the most common pathogen in bacterial keratitis patients who wore contact lenses (57.9%).⁶ This data is similar to other studies done around the world.⁸⁻¹¹ Researchers have also found similar results for the common causative organisms in bacterial keratitis occurring after corneal transplantation, with gram-positive bacteria (~40%) more commonly cultured than gram-negative (~20%) or fungal (~10%) species.¹²

FUNGAL KERATITIS

There are two broad categories of fungi—filamentous fungi and yeasts. The prevalence and epidemiological distribution of fungal keratitis are strongly associated with one's geographical location and, thus, vary widely throughout the world.¹³

ABOUT THE AUTHORS



Dr. Skoog is a cornea and contact lens and ocular disease resident at the Illinois College of Optometry (ICO).



Dr. Sicks is an associate professor at ICO and a clinical attending in the Cornea Center for Clinical Excellence at the Illinois Eye Institute. She lectures and conducts research on specialty contact lenses.

Overall, the worldwide incidence is 23.6 cases per 100,000 people, with the highest caseloads located in Asia and Africa.¹⁴ Filamentous fungi, such as *Fusarium* and *Aspergillus*, are the most common cause of fungal keratitis around the world and tend to be the predominant organisms in warmer, tropical climates.¹³ Yeasts, such as *Candida* species, tend to be found in more temperate climates, as well as in patients who are immunocompromised or have had chronic OSD or corneal surgery prior to infection.¹⁵

Though less common than bacterial keratitis, fungal keratitis can be more severe in nature. Corneal perforation is five- to six-times more likely to occur in fungal keratitis when compared with bacterial keratitis.¹⁶ In the developing world, fungal keratitis is strongly associated with ocular trauma from vegetable matter or other organic material. However, in the developed world, contact lens wear is the most common cause of fungal keratitis.¹³

ACANTHAMOEBA KERATITIS

A free-living parasite (amoeba, or single-celled organism) called *Acanthamoeba* is found in water and soil and is known to cause severe, sight-threatening infections.¹⁷ Most

cases of *Acanthamoeba* keratitis (AK) have been observed in contact lens wearers, with an estimated prevalence of one to 33 per million contact lens wearers per year.¹⁸ AK most commonly occurs due to poor contact lens hygiene, such as topping off solutions or storing lenses in tap water.¹⁹ Patients typically present with symptoms that are out of proportion with signs (*e.g.*, in extreme pain but with minimal corneal staining).

Targeted AK treatment is often delayed because the infection tends to be initially treated as a different type of keratitis (bacterial, fungal or viral). For example, in the early stages of infection, AK is often confused with herpes simplex viral keratitis if there is a dendritic pattern of epithelial staining. A more definitive diagnosis of AK can be made using *in vivo* confocal microscopy, though not every clinician has easy access to such an instrument.¹⁸

Acanthamoeba is especially adherent to the hydrophilic plastics used in contact lenses. For best outcomes, frequent replacement contact lens

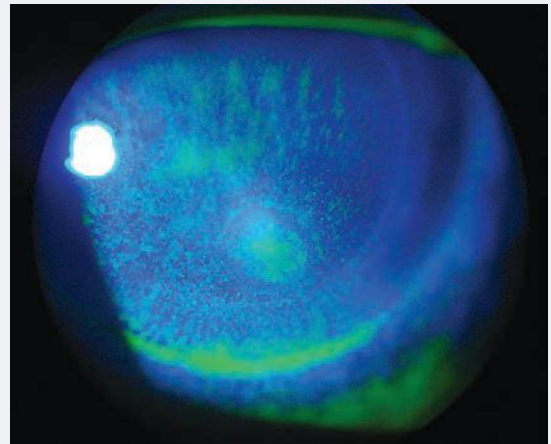


Fig. 1. Microbial keratitis post-DSEK.

wearers using multipurpose solution should clean their case with clean fingers (digital rubbing), rinse it with multipurpose contact lens solution, wipe it with a tissue and leave it to air dry face down on a tissue with the caps off.²⁰⁻²² The contact lenses should be rubbed, rinsed and stored using the recommended solution and following the manufacturer's labeled instructions. Lenses should be replaced at the prescribed interval, and cases should be replaced regularly (every one to three months minimum).²³

Patients using a hydrogen peroxide-based system with their soft contact lenses should rinse and store their lenses as directed by the

Release Date: February 15, 2022

Expiration Date: February 15, 2025

Estimated time to complete activity: two hours

Jointly provided by the Postgraduate Institute for Medicine (PIM) and Review Education Group.

Educational Objectives: After completing this activity, the participant should be better able to:

- Discuss the current trends in infectious keratitis.
- Recognize the risk factors associated with this condition.
- Diagnose and treat corneal infections.
- Review how contact lens advancements have impacted infection rates.

Target Audience: This activity is intended for optometrists engaged in managing patients with infectious keratitis.

Accreditation Statement: In support of improving patient care, this activity has been planned and implemented by PIM and the Review Education Group. PIM is jointly accredited by the Accreditation Council for Continuing Medical Education, the Accreditation Council for Pharmacy Education and the American Nurses Credentialing Center to provide CE for the healthcare team. PIM is accredited by COPE to provide CE to optometrists.



JOINTLY ACCREDITED PROVIDER™
INTERPROFESSIONAL CONTINUING EDUCATION

Reviewed by: Salus University, Elkins Park, PA



Faculty/Editorial Board: William Skoog, OD, and Lindsay A. Sicks, OD

Credit Statement: This course is COPE-approved for two hours of CE credit. Activity #123252 and course ID 76681-TD. Check with your local state licensing board to see if this counts toward your CE requirement for relicensure.

Disclosure Statements: PIM requires faculty, planners and others in control of educational content to disclose all their financial relationships with ineligible companies. All identified conflicts of interest are thoroughly vetted and mitigated according to PIM policy. PIM is committed to providing its learners with high-quality, accredited CE activities and related materials that promote improvements or quality in healthcare and not a specific proprietary business interest of an ineligible company.

Those involved reported the following relevant financial relationships with ineligible entities related to the educational content of this CE activity: **Authors**—Dr. Skoog has no financial interests to disclose. Dr. Sicks receives fees from Alcon. **Managers and Editorial Staff**—The PIM planners and managers have nothing to disclose. The Review Education Group planners, managers and editorial staff have nothing to disclose.

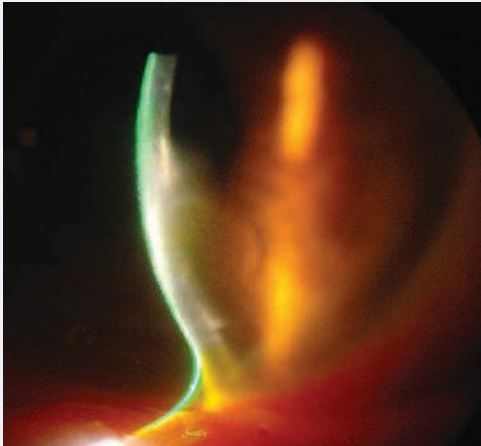


Fig. 2. Corneal thinning and opacity in the same patient as Figure 1.

solution manufacturer's labeled instructions and take care not to apply hydrogen peroxide solution directly to the eye. All contact lens wearers should avoid rinsing or washing their case with tap water as this behavior increases the rate of contamination with gram-negative bacteria and *Acanthamoeba* strains.^{24,25} Daily disposable lens wearers should replace their lenses daily and avoid any re-use or storage.

VIRAL KERATITIS

The most common viral ocular pathogens are herpes simplex virus (HSV) and varicella zoster virus (VZV). Other adenoviral pathogens, such as Epstein-Barr virus and cytomegalovirus, can also cause viral keratitis, though they are less commonly seen.²⁶ Approximately 50% of the US population is seropositive for HSV-1, and the annual incidence of all types of new ocular HSV infections is 11.8 per 100,000 people in the United States.^{27,28} Typically, HSV-1 predominates in ocular infections.

Primary ocular HSV-1 infections tend to occur in children or young adults and typically present as a conjunctivitis, which can also involve the eyelids (blepharoconjunctivitis), marked by inflammatory vesicles and ulcers, which can include dendritic

lesions on the corneal epithelium. More often, HSV-1 ocular infections occur in adults due to reactivation of the HSV which lays dormant in the trigeminal ganglion since the time of primary infection. Epithelial keratitis is the most common type of ocular HSV, comprising approximately 60% of cases.²⁸ Stromal keratitis accounts for 20% to 48% of ocular HSV cases and may also present with epithelial lesions.^{26,28} Less common are the endothelial subtypes of HSV ocular infection and resultant

cases of neurotrophic keratitis.^{28,29}

VZV, or shingles infection, occurs during or following infection with the virus. The disease affects specific and discrete regions of the body, known as dermatomes. Approximately 50% to 72% of patients who develop VZV have ocular involvement, which then becomes known as herpes zoster ophthalmicus.²⁶

RISK FACTORS TO CONSIDER

There are several common risk factors associated with IK, including contact lens wear, ocular trauma, OSD and a history of corneal surgery.

Contact lens wear. Despite changes in contact lens materials and uptake of more frequent replacement lenses, research has shown a relatively stable rate of microbial keratitis (MK) in contact lens wearers over the past 25 years, affecting roughly two to five per 10,000 of those who wear contact lenses on a regular basis.³⁰⁻³⁵

Research shows that a combination of blinking, tear flow and the regulatory elements of the corneal epithelium and the basal lamina in the healthy eye work together to form a formidable barrier and protect the vulnerable corneal stroma against microbial infection.

It should be noted, however, that superficial trauma is not necessary for *Pseudomonas aeruginosa* to cross the corneal epithelium during lens wear and cause infection. *Pseudomonas aeruginosa* is the most common cause of contact lens-related infection.³⁶ Silicone hydrogel lenses were developed, in part, to try and reduce infection rates in contact lens wearers. While the material innovation increased oxygen transmissibility to the cornea, uptake of silicone hydrogel lenses has not reduced rates of MK infection.³⁶

In developed countries, contact lens wear is the number one risk factor for IK, in part due to modifiable risk factors such as hygiene. Poor hygiene practices including poor cleaning methods, sleeping in lenses, showering in lenses, poor hand hygiene, failure to replace lenses on time, "topping off" contact lens cleaning solution and lack of cleaning/replacing contact lens cases can all lead to an increased risk of IK.^{32,37-39} Infection rates are higher with planned replacement contact lenses when compared with daily disposable contact lenses. One major benefit of daily disposable lenses is that no contact lens solutions, cleaning or cases are necessary, as the lenses are simply discarded at the end of each wearing day.

Studies have shown that patients who wear daily disposable lenses are more compliant with on-time replacement compared with those who use extended wear contact lenses.^{40,41} Approximately 88% of daily disposable lens wearers in the United States reported following the manufacturer's recommended replacement frequency, compared with 72% of monthly replacement lens wearers and 48% of two-week replacement lens wearers.⁴¹ Overwearing or sleeping in contact lenses increases one's risk of developing IK.^{30,32,37,39} Several studies have also identified poor con-

tact lens case hygiene as a major risk for the development of IK.^{32,37,38}

Various types of bacteria and fungi can be found on contact lenses and in cases, including *Fusarium*, *Candida*, *Pseudomonas* and CoNS.⁴²⁻⁴⁴ One study examined different microbes found on daily disposables compared with planned replacement lenses and noted that after a normal period of wear for a daily disposable lens, the only microbe on the contact lens was CoNS, which is part of the normal ocular microbiota of the skin, eyelids and conjunctiva.⁴³ The planned replacement lenses contained *Pseudomonas* species, CoNS and fungi (*Candida* and *Aspergillus*). *Pseudomonas* was the most commonly found bacteria on planned replacement lenses.

This finding is significant because CoNS has been shown to cause a milder form of keratitis, in contrast with *Pseudomonas* which can cause a more severe form of keratitis and progress quickly.⁴³ Additionally, silicone hydrogel lenses show greater adhesion to *Pseudomonas aeruginosa* and *Staphylococcus aureus* when compared with hydrogel lenses.⁴⁴

Both *Fusarium* and *Candida* species can form biofilms on contact lenses and cases, as well as case wells and caps. Approximately one-quarter of fungal keratitis cases are caused by contact lens wear, and the commonly isolated pathogen is *Fusarium* species. This rate accounts for the elevated incidence during times when ReNu with MoistureLoc (Bausch + Lomb) was commercially available.^{42,45} Topping off solution was implicated in the 2004 to 2006 *Fusarium* keratitis outbreak associated with ReNu with MoistureLoc contact lens solution.⁴² ReNu with MoistureLoc also demonstrated reduced efficacy after evaporation and instability at higher temperatures—two factors that could have contributed to the outbreak.⁴⁶

During this outbreak, the rate of risk and incidence of *Fusarium* infection was three- to six-times higher than in previous years.⁴⁵

Corneal trauma. It is challenging to estimate the overall incidence of IK due to corneal trauma. In some studies, the language “corneal blindness” or “corneal trauma requiring topical antibiotic prophylaxis” is used to describe IK caused by trauma. The burden of corneal blindness from IK secondary to ocular trauma disproportionately falls on developing countries, where up to 90% of cases occur.⁴⁷ The higher case numbers in developing countries could be due to the lack of access to, or availability of, prophylactic antibiotics.⁴⁸ One study in Nepal showed that 96% of patients who started prophylactic topical antibiotics did not end up developing IK following corneal trauma, highlighting the importance of prompt treatment to prevent vision loss.⁴⁹ In rural environments, IK cases are more commonly caused by trauma in association with contaminated water, vegetative matter such as soil and tree branches or wind-borne foreign bodies.⁴⁸ Any trauma caused by vegetative matter increases the risk of fungal keratitis.

Fungal keratitis is also more common in working-aged males with occupations involving farming and manual labor and has a higher prevalence in Asian and African countries with agricultural communities. These trends highlight the importance of protective eyewear in high-risk environments to prevent not only direct infection, but also any corneal trauma that carries with it an elevated risk of infection and subsequent complications.

Corneal surgery. Due to its complex and invasive nature, keratoplasty carries a risk of IK. In the United States, the

incidence of post-keratoplasty IK ranges from 0.02% to 4.1%.^{12,50} The majority of infections are caused by gram-positive organisms, the most common of which is *Staphylococcus aureus*.⁵¹ A single, large, retrospective study observed a higher incidence of MK following penetrating keratoplasty (PKP) than endothelial keratoplasty between 2007 and 2018 in the United States. This difference is attributed to long-term corticosteroid use, broken/loose sutures, recurrence of IK and OSD (including dry eye, neurotrophic keratitis and persistent epithelial defects). The study also noted that repeat grafts were more prone to infection than initial grafts.^{12,52} Other studies in the United Kingdom found similar results, with higher rates of IK following PKP compared with other corneal transplantation techniques.⁵¹ Over the past two decades, the incidence of post-keratoplasty bacterial keratitis has decreased; however, there has been a significant increase in post-keratoplasty fungal infection.^{53,54}

IK following keratoplasty poses a diagnostic and therapeutic challenge for clinicians. Infection in eyes post-keratoplasty can lead to graft rejection, graft failure and endophthalmitis. Patients are usually on long-term topical corticosteroids to prevent graft rejection. However,

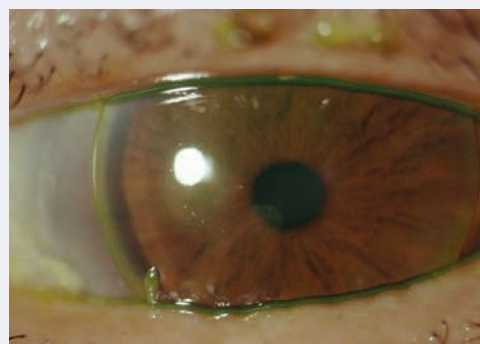

Fig. 3. Patient with history of presumed microbial keratitis from continuous wear of spherical GP lenses showing an anterior stromal scar near the pupil.



during the active phase of an infection, steroids can worsen the clinical picture, especially in fungal keratitis. Yeasts tend to be the causative organism of fungal keratitis following corneal surgery, and recent studies have found a higher incidence of *Candida* infection following endothelial keratoplasty, highlighting the importance of proper diagnosis and treatment protocols in these complex cases.⁵²

Keratorefractive surgeries, including laser *in situ* keratomileusis (LASIK), laser-assisted subepithelial keratectomy (LASEK) and photorefractive keratectomy (PRK), also carry a risk of IK. However, the incidence following refractive surgery is low at only about four per 10,000 eyes.⁵⁵ IK incidence after LASIK was higher when compared with LASEK and PRK, and the most commonly cultured organisms were *Staphylococcus* bacterial species.⁵⁵

OSD. This is a term that encompasses various forms of dry eye disease including keratoconjunctivitis sicca, Sjögren's syndrome, blepharitis, cicatrizing conjunctivitis, Stevens-Johnson syndrome, post-refractive surgery dry eye, neurotrophic keratopathy, exposure keratopathy, bullous keratopathy, limbal stem cell

deficiency and others.^{56,57} IK caused by OSD most commonly features gram-positive bacteria, such as CoNS, in culture results.⁵⁶ Dry eye disease, as defined by the Tear Film and Ocular Surface Society's Dry Eye Workshop II, features "a loss of tear film homeostasis with ocular symptoms, in which tear film instability and hyperosmolarity, ocular surface inflammation and damage and neurosensory abnormalities play etiological roles." This loss of tear film homeostasis can lead to breakdown of the corneal epithelium, which is a vital part of the cornea's defense mechanism.⁵⁸ Further breakdown in corneal defenses, such as that seen in chronic inflammation, poses a continuous risk of OSD-related IK.²

DIAGNOSIS OF IK

It is imperative that eyecare practitioners promptly recognize, diagnose and treat cases of IK. Patients will typically present with rapid-onset eye pain, conjunctival injection, photophobia and reduced visual acuity. The rate of symptom progression may depend on the virulence of the infectious agent. Clinical evaluation will typically reveal a corneal defect that stains with sodium fluorescein (NaFl) dye.

In cases of bacterial keratitis, one will usually see an infiltrate with an overlying epithelial defect. In HSV epithelial keratitis, there is often a typical dendritic corneal staining pattern—though sometimes the staining is non-specific in early stages. Some cases of IK have a more intense inflammatory response. For example, it is possible to see a marked anterior chamber reaction and associated

hypopyon with some bacterial and fungal infections.

Following the American Academy of Ophthalmology guidelines for obtaining cultures and smears, a specimen should be obtained for laboratory evaluation if a presenting corneal infiltrate is central, large (>2mm) or has multiple sites of corneal infiltration.⁵⁹ Additionally, a corneal culture should be obtained if there is significant stromal involvement or melting, the infection is chronic and unresponsive to broad-spectrum antibiotic therapy or there is any history of corneal surgery. Finally, if atypical clinical features are present suggestive of fungal, amoebic or mycobacterial keratitis (for example, a ring infiltrate or satellite lesion), an appropriate culture should be obtained. This culture may require special culture medium or plates, and a negative result does not necessarily rule out the suspected infectious agent.⁶⁰

The clinical presentation of fungal keratitis tends to have less of an early inflammatory response than bacterial keratitis, though later in its course, conjunctival injection is fairly common. There is typically acute eye pain upon presentation, the severity of which can be out of proportion compared with the level of corneal inflammation detected.¹⁴ Fungal keratitis can manifest as gray-white, nonsuppurative infiltrates with irregular, feathery margins. Superficial lesions may be elevated with a dry, rough texture. Satellite lesions may also be present.⁶⁰ Positive corneal cultures require several days or weeks for final identification, and sensitivity testing of any fungal isolate takes even longer, with questionable utility.⁶¹

AK can mimic HSV keratitis early in the disease process. Initially, the infection is localized to the epithelium and may present as diffuse epitheliopathy with coarse punctate

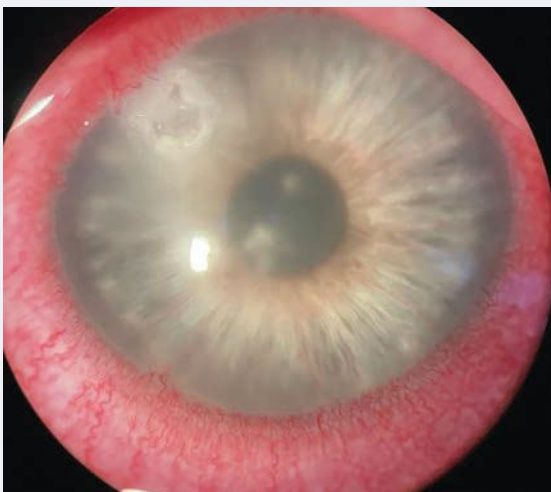

Fig. 4. This case of *Acanthamoeba* keratitis was confirmed by confocal microscopy.

features, subepithelial opacities or dendritic epithelial lesions. A ring infiltrate is present in about 50% of cases and is typically only seen in later stages of the disease. The patient classically presents with severe ocular pain that is out of proportion with the clinical signs. Features that favor a diagnosis of AK over HSV keratitis include the presence of epidemiologic risk factors, such as contact lens use or recent exposure to water (e.g., shower, hot tub or potentially contaminated freshwater). A good case history can help determine how likely the diagnosis is AK when the clinical picture is less clear.⁶⁰

HSV keratitis can present with an epithelial or stromal lesion. Epithelial lesions will have the appearance of a dendrite and stain centrally with NaFl. Any heaped epithelium will stain with rose bengal or lissamine green, and the dendritic pattern will feature terminal end bulbs. These epithelial dendrites can progress to geographic ulcers, especially if a topical steroid is used without prophylactic antivirals. VZV keratitis presents as a pseudodendrite, which appears “stuck on” instead of ulcerated. Pseudodendrite lesions do not stain with NaFl and feature more blunted ends compared with the end bulbs seen in HSV keratitis.⁶²

TREATMENT OPTIONS

The primary goal in treating IK is preserving the patient’s sight and corneal integrity. Any corneal perforation that develops can progress to endophthalmitis, so prompt identification and treatment are necessary. Generally, topical therapy should not be initiated until a corneal sample can be obtained for laboratory culture. Initial therapy usually consists of topical medications to combat the presumed infective agent, such as antibiotics, antifungals or antivirals. Adding a topical cycloplegic agent can reduce ocular discomfort and

prevent any sequelae from intraocular inflammation if present.⁶⁰

Initial treatment for bacterial keratitis consists of broad-spectrum topical antibiotics such as fluoroquinolones. Second-generation fluoroquinolones (ciprofloxacin, ofloxacin) have excellent gram-negative coverage and work well against *Pseudomonas*, but lack gram-positive activity. Newer, fourth-generation fluoroquinolones (moxifloxacin, gatifloxacin, besifloxacin) have similar gram-negative coverage, but feature improved gram-positive coverage. Combination therapy with separate antibiotics to obtain both gram-positive and gram-negative coverage is also acceptable. For more severe bacterial ulcers, consider culturing upon initial presentation in order to better target topical therapy and prevent antibiotic resistance.

Fortified antibiotics are another option in severe cases where one has access to a compounding pharmacy.⁶⁰

The initial recommended therapy for fungal keratitis includes topical natamycin 5% for filamentous fungi, particularly *Fusarium* species, or topical amphotericin B 0.15% for yeasts, such as *Candida* species.⁶³ For more severe infections, or in fungal keratitis with scleral or intracameral extension, systemic antifungal agents may be needed.⁶⁰

In cases of AK, early diagnosis is the single most important predictive factor for a positive outcome, as it is easier to treat trophozoites compared with cysts. Early in the diagnosis, epithelial debridement can be performed, followed by a three- to four-month course of topical therapy, the exact nature of which can vary. Topical therapies may include voriconazole, polyhexamethylene biguanide and chlorhexidine, among other antifungal agents, biguanides and antibiotics.

To prevent *Acanthamoeba* infection in contact lens wearers, avoiding

exposure to water is key since few multipurpose solution preservatives are effective against this parasite. Hydrogen peroxide or povidone iodine (PI)-based solutions are preferred for any patient who may expose their contact lenses to water, as these are the only solution categories effective against *Acanthamoeba*.⁶⁴ Unfortunately, PI solutions are not currently commercially available in the United States.

Primary ocular HSV infection is generally self-limiting; however, there are a few different approaches to treating HSV epithelial keratitis. Topical antiviral agents available in the United States are trifluridine 1% dosed nine times per day and ganciclovir 0.15% gel dosed initially at five times per day. Topical acyclovir ointment is currently only available abroad. While acyclovir ointment (Fera Pharmaceuticals) was FDA-approved in 2019 for acute herpetic keratitis, its commercial future is uncertain.⁶⁵

Topical antiviral therapy is generally discontinued after a maximum of 10 days of treatment due to the high level of ocular surface toxicity. Common oral antivirals, such as acyclovir, valacyclovir and famciclovir, may also be prescribed to speed up the resolution of signs and symptoms in epithelial keratitis as they are not corneo-toxic. Once HSV progresses to stromal involvement, topical corticosteroids are required in combination with oral antivirals. Initial treatment for stromal disease is topical prednisolone acetate 1% dosed every two hours, along with prophylactic oral antivirals.⁶²

Other potential treatment options for IK include corneal crosslinking (CXL), next-generation sequencing, novel antimicrobial agents (specifically to address drug resistance), photodynamic antimicrobial therapy and other adjuvant therapies that focus on modifying the immune

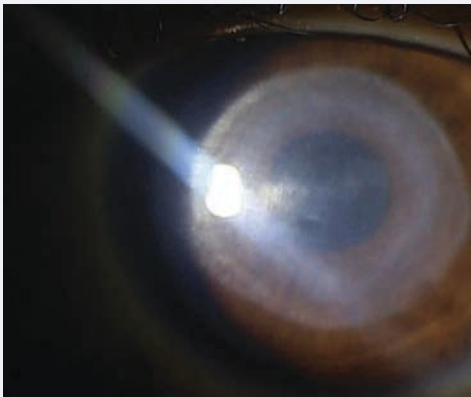


Fig. 5. Central corneal scarring remaining after presumed *Pseudomonas* ulcer from extended wear of soft contact lens.

response to treatment. CXL is a treatment typically reserved for keratoconus and corneal ectasia in which photochemically activated riboflavin promotes the formation of covalent bonds between corneal collagen strands. To date, there is little evidence to support CLX use to treat filamentous fungal keratitis; however, a stronger case can be made for its use in bacterial keratitis.⁶⁶

Rose bengal photodynamic antimicrobial therapy has also been shown to be beneficial in severe, progressive IK cases, including those of fungal etiology.^{67,68} Next-generation sequencing techniques can improve diagnostic accuracy (and therefore help target treatment), especially in culture-negative IK cases. The sequencing can currently identify a wider variety of organisms, including atypical or anaerobic bacteria that are challenging to culture, but its role in targeting treatment is less clear.⁶⁶

Further research in therapeutics may lead to novel antimicrobial agents which can be used to target various pathogens implicated in IK. Several case studies demonstrate the use of adjuvant therapies such as anti-collagenases, corticosteroids and systemic therapies, which can reduce corneal scarring and infection, thereby improving visual outcomes in IK.^{66,69,70}

CONCLUSIONS

There are many risk factors associated with IK, though contact lenses have remained a constant risk, especially in cases of bacterial keratitis. Eyecare providers should also understand and consider additional risk factors for the development of IK such as corneal trauma, corneal surgery and OSD.

Bacterial keratitis case numbers have remained constant over the past 25 years, despite innovations in contact lens materials and the shift toward

daily disposable lenses. With the advent of silicone hydrogel lenses in 1998, the eyecare industry was hopeful that the increased oxygen transmissibility would reduce the rate of MK, especially with extended wear. However, this change in material has had no appreciable impact on rates over time, which have held steady at two to five per 10,000 patients per year.³⁰⁻³⁵ Even with the rise in daily disposable contact lens use, which removes contact lens solutions and storage cases from the equation, the risk of severe infection is reduced but not completely eliminated.⁷¹

There is room for further improvement in reducing the incidence of IK, especially in contact lens wearers. Two potential innovations include the use of silver (or silver-salt) and cationic peptides. Silver iodide-infused galyfilcon A lenses performed similarly to normal galyfilcon A lenses, with no significant differences in comfort, acuity or ocular health.⁷² *In vitro* studies of silver-impregnated contact lens cases have also shown good efficacy against gram-negative bacteria. Contact lenses coated with melimine, a synthetic antimicrobial cationic peptide, show reduced bacterial adhesion with less gram-positive bacteria cultured from the eye.⁷¹

Keys to prevent IK include following best practices for safe contact

lens wear, proper hand hygiene and the use of appropriate eye protection during any activity that carries a risk of ocular trauma. Despite the availability of appropriate treatments for many of the types of IK that exist, clinical outcomes are often poor and can vary based on geography and the availability of therapies. A better prognosis is associated with early diagnosis, access to appropriate treatment and use of prophylaxis in cases of ocular trauma. [hcc](#)

The authors would like to thank Shivani Patel (ICO Class of 2022) for her assistance in obtaining Figure 4 from Dr. Anthony Verachtert, and Dr. Jennifer Harthan for her assistance in capturing Figure 5.

1. Flaxman SR, Bourne RRA, Resnikoff S, et al. Global causes of blindness and distance vision impairment 1990–2020: a systematic review and meta-analysis. *Lancet Glob Health*. 2017;5(12):e1221-34.
2. Ting DSJ, Ho CS, Deshmukh R, et al. Infectious keratitis: an update on epidemiology, causative microorganisms, risk factors, and antimicrobial resistance. *Eye*. 2021;35(4):1084-101.
3. Ung L, Acharya NR, Agarwal T, et al. Infectious corneal ulceration: a proposal for neglected tropical disease status. *Bull World Health Organ*. 2019;97(12):854-6.
4. Silhavy TJ, Kahne D, Walker S. The bacterial cell envelope. *Cold Spring Harb Perspect Biol*. 2010;2(5):a000414.
5. Tam ALC, Côté E, Saldanha M, et al. Bacterial keratitis in Toronto: a 16-year review of the microorganisms isolated and the resistance patterns observed. *Cornea*. 2017;36(12):1528-34.
6. Puig M, Weiss M, Salinas R, et al. Etiology and risk factors for infectious keratitis in South Texas. *J Ophthalmic Vis Res*. 2020;15(2):128-37.
7. Norina TJ, Raihan S, Bakiah S, et al. Microbial keratitis: aetiological diagnosis and clinical features in patients admitted to Hospital Universiti Sains Malaysia. *Singapore Med J*. 2008;49(1):67-71.
8. Tan SZ, Walkden A, Au L, et al. Twelve-year analysis of microbial keratitis trends at a UK tertiary hospital. *Eye*. 2017;31(8):1229-36.
9. Mun Y, Kim MK, Oh JY. Ten-year analysis of microbiological profile and antibiotic sensitivity for bacterial keratitis in Korea. *PLoS One*. 2019;14(3):e0213103.
10. Tavassoli S, Nayyar G, Darcy K, et al. An 11-year analysis of microbial keratitis in the South West of England using brain-heart infusion broth. *Eye*. 2019;33(10):1619-25.
11. Ting DSJ, Settle C, Morgan SJ, et al. A 10-year analysis of microbiological profiles of microbial keratitis: the North East England Study. *Eye*. 2018;32(8):1416-7.
12. Dohse N, Wibbelsman TD, Rapuano SB, et al. Microbial keratitis and clinical outcomes following penetrating and endothelial keratoplasty. *Acta Ophthalmol*. 2020;98(7):e895-900.
13. Ahmadikia K, Aghaei Gharehbolagh S, Fallah B, et al. Distribution, prevalence, and causative

- agents of fungal keratitis: a systematic review and meta-analysis (1990 to 2020). *Front Cell Infect Microbiol.* 2021;11:698780.
14. Brown L, Leck AK, Gichangi M, et al. The global incidence and diagnosis of fungal keratitis. *Lancet Infect Dis.* 2021;21(3):e49-57.
 15. Ritterband DC, Seedor JA, Shah MK, et al. Fungal keratitis at the new york eye and ear infirmary. *Cornea.* 2006;25(3):264-7.
 16. Keay LJ, Gower EW, Iovieno A, et al. Clinical and microbiological characteristics of fungal keratitis in the United States, 2001-2007: a multi-center study. *Ophthalmology.* 2011;118(5):920-6.
 17. Illingworth CD, Cook SD. Acanthamoeba keratitis. *Surv Ophthalmol.* 1998;42(6):493-508.
 18. Maycock NJR, Jayaswal R. Update on Acanthamoeba keratitis: diagnosis, treatment, and outcomes. *Cornea.* 2016;35(5):713-20.
 19. Brown AC, Ross J, Jones DB, et al. Risk factors for Acanthamoeba keratitis—a multistate case-control study, 2008-2011. *Eye Contact Lens.* 2018;44:S173.
 20. Wu YTY, Willcox M, Zhu H, et al. Contact lens hygiene compliance and lens case contamination: a review. *Cont Lens Anterior Eye.* 2015;38(5):307-16.
 21. Wu YT, Zhu H, Willcox M, et al. Removal of biofilm from contact lens storage cases. *Invest Ophthalmol Vis Sci.* 2010;51(12):6329-3.
 22. Wu YT, Zhu H, Willcox M, et al. Impact of air-drying lens cases in various locations and positions. *Optom Vis Sci.* 2010;87(7):465-8.
 23. Lorenzo-Morales J, Khan NA, Walochnik J. An update on Acanthamoeba keratitis: diagnosis, pathogenesis and treatment. *Parasite.* 2015;22:10.
 24. Mutoh T, Ishikawa I, Matsumoto Y, et al. A retrospective study of nine cases of Acanthamoeba keratitis. *Clin Ophthalmol.* 2010;4:1189-92.
 25. Tilia D, Lazon de la Jara P, Zhu H, et al. The effect of compliance on contact lens case contamination. *Optom Vis Sci.* 2014;91(3):262-71.
 26. Koganti R, Yadavalli T, Naqvi RA, et al. Pathobiology and treatment of viral keratitis. *Exp Eye Res.* 2021;205:108483.
 27. Young RC, Hodge DO, Liesegang TJ, et al. Incidence, recurrence, and outcomes of herpes simplex virus eye disease in Olmsted County, Minnesota, 1976-2007: the effect of oral antiviral prophylaxis. *Arch Ophthalmol.* 2010;128(9):1178-83.
 28. Lobo AM, Agelidis AM, Shukla D. Pathogenesis of herpes simplex keratitis: the host cell response and ocular surface sequelae to infection and inflammation. *Ocul Surf.* 2019;17(1):40-9.
 29. Holland EJ, Schwartz GS. Classification of herpes simplex virus keratitis. *Cornea.* 1999;18(2):144-54.
 30. Stapleton F, Keay L, Edwards K, et al. The incidence of contact lens-related microbial keratitis in Australia. *Ophthalmology.* 2008;115(10):1655-62.
 31. Morgan PB, Efron N, Brennan NA, et al. Risk factors for the development of corneal infiltrative events associated with contact lens wear. *Invest Ophthalmol Vis Sci.* 2005;46(9):3136-43.
 32. Stapleton F. Contact lens-related corneal infection in Australia. *Clin Exp Optom.* 2020;103(4):408-17.
 33. Poggio EC, Glynn RJ, Schein OD, et al. The incidence of ulcerative keratitis among users of daily-wear and extended-wear soft contact lenses. *N Engl J Med.* 1989;321(12):779-83.
 34. Schein OD, McNally JJ, Katz J, et al. The incidence of microbial keratitis among wearers of a 30-day silicone hydrogel extended-wear contact lens. *Ophthalmology.* 2005;112(12):2172-9.
 35. Cope JR, Collier SA, Schein OD, et al. Acanthamoeba keratitis among rigid gas permeable contact lens wearers in the United States, 2005 through 2011. *Ophthalmology.* 2016;123(7):1435-41.
 36. Fleiszig SMJ, Kroken AR, Nieto V, et al. Contact lens-related corneal infection: Intrinsic resistance and its compromise. *Prog Retin Eye Res.* 2020;76:100804.
 37. Stapleton F, Carnt N. Contact lens-related microbial keratitis: how have epidemiology and genetics helped us with pathogenesis and prophylaxis. *Eye.* 2012;26(2):185-93.
 38. Sauer A, Greth M, Letsch J, et al. Contact lenses and infectious keratitis: from a case-control study to a computation of the risk for wearers. *Cornea.* 2020;39(6):769-74.
 39. Stellwagen A, MacGregor C, Kung R, et al. Personal hygiene risk factors for contact lens-related microbial keratitis. *BMJ Open Ophthalmol.* 2020;5(1):e000476.
 40. Rueff EM, Wolfe J, Bailey MD. A study of contact lens compliance in a non-clinical setting. *Cont Lens Anterior Eye.* 2019;42(5):557-61.
 41. Dumbleton K, Woods C, Jones L, et al. Patient and practitioner compliance with silicone hydrogel and daily disposable lens replacement in the United States. *Eye Contact Lens.* 2009;35(4):164-71.
 42. Imamura Y, Chandra J, Mukherjee PK, et al. Fusarium and Candida albicans biofilms on soft contact lenses: model development, influence of lens type, and susceptibility to lens care solutions. *Antimicrob Agents Chemother.* 2008;52(1):171-82.
 43. Hall B, McCanna D, Jones L. Identification of coagulase-negative staphylococci in daily disposable contact lens wearers. *Lett Appl Microbiol.* 2014;59(3):313-9.
 44. Evans DJ, Fleiszig SMJ. Microbial keratitis: could contact lens material affect disease pathogenesis? *Eye Contact Lens.* 2013;39(1):73-8.
 45. Zhang S, Ahearn DG, Noble-Wang JA, et al. Growth and survival of Fusarium solani-F. oxysporum complex on stressed multipurpose contact lens care solution films on plastic surfaces in situ and in vitro. *Cornea.* 2006;25(10):1210-6.
 46. Bullock JD, Warwar RE, Elder BL, et al. Temperature instability of ReNu with MoistureLoc: a new theory to explain the worldwide Fusarium keratitis epidemic of 2004-2006. *Trans Am Ophthalmol Soc.* 2008;106:117-26.
 47. Whitcher JP, Srinivasan M, Upadhyay MP. Corneal blindness: a global perspective. *Bull World Health Organ.* 2001;79:214-21.
 48. Stapleton F. The epidemiology of infectious keratitis. *Ocul Surf.* 2021.
 49. Upadhyay MP, Karmacharya PC, Koirala S, et al. The Bhaktapur Eye Study: ocular trauma and antibiotic prophylaxis for the prevention of corneal ulceration in Nepal. *Br J Ophthalmol.* 2001;85(4):388-92.
 50. Edelstein SL, DeMatteo J, Stoeger CG, et al. Report of the Eye Bank Association of America Medical Review Subcommittee on Adverse Reactions Reported From 2007 to 2014. *Cornea.* 2016;35(7):917-26.
 51. Griffin B, Walkden A, Okonkwo A, et al. Microbial keratitis in corneal transplants: a 12-year analysis. *Clin Ophthalmol.* 2020;14:3591-7.
 52. Song A, Deshmukh R, Lin H, et al. Post-keratoplasty infectious keratitis: epidemiology, risk factors, management, and outcomes. *Front Med.* 2021;8:707242.
 53. Sung MS, Choi W, You IC, et al. Factors affecting treatment outcome of graft infection following penetrating keratoplasty. *Korean J Ophthalmol.* 2015;29(5):301-8.
 54. Lin IH, Chang YS, Tseng SH, et al. A comparative, retrospective, observational study of the clinical and microbiological profiles of post-penetrating keratoplasty keratitis. *Sci Rep.* 2016;6:32751.
 55. Afsharpaiman S, Zare M, Yasemi M, et al. The prevalence of infectious keratitis after keratorefractive surgery: a systematic review and meta-analysis study. *J Ophthalmol.* 2020;2020:6329321.
 56. Khoo P, Cabrera-Aguas M, Robaei D, et al. Microbial Keratitis and ocular surface disease: a 5-year study of the microbiology, risk factors and clinical outcomes in Sydney, Australia. *Curr Eye Res.* 2019;44(11):195-202.
 57. Schornack MM, Pyle J, Patel SV. Scleral lenses in the management of ocular surface disease. *Ophthalmology.* 2014;121(7):1398-405.
 58. Craig JP, Nichols KK, Akpek EK, et al. TFOS DEWS II Definition and Classification Report. *Ocul Surf.* 2017;15(3):276-83.
 59. Lin A, Rhee MK, Akpek EK, et al. American Academy of Ophthalmology preferred practice pattern cornea and external disease panel. *Ophthalmology.* 2019;126(1):P1-55.
 60. Feder RS, et al. 2020-2021 Basic and Clinical Science Course, Section 8: External Disease and Cornea, Chapter 12: Infectious Diseases of the Cornea and External Eye: Bacterial, Fungal, and Parasitic Infections. American Academy of Ophthalmology, San Francisco. Published online 2021:317-51.
 61. Tanure MA, Cohen EJ, Sudesh S, et al. Spectrum of fungal keratitis at Wills Eye Hospital, Philadelphia, Pennsylvania. *Cornea.* 2000;19(3):307-12.
 62. Feder RS, et al. 2020-2021 Basic and Clinical Science Course, Section 8: External Disease and Cornea, Chapter 11: Infectious Diseases of the Cornea and External Eye: Viral Infections. American Academy of Ophthalmology, San Francisco. Published online 2021:281-316.
 63. Sharma S, Das S, Viridi A, et al. Re-appraisal of topical 1% voriconazole and 5% natamycin in the treatment of fungal keratitis in a randomised trial. *Br J Ophthalmol.* 2015;99(9):1190-5.
 64. Bradley CS, Sicks LA, Pucker AD. Common ophthalmic preservatives in soft contact lens care products: benefits, complications, and a comparison to non-preserved solutions. *Clin Optom (Auckl).* 2021;13:271-85.
 65. Maulvi FA, Ranch KM, Desai AR, et al. Chapter 28 - Ophthalmic preparations. In: Adejare A, ed. *Remington (Twenty-Third Edition)*. Academic Press; 2021:565-75.
 66. Austin A, Lietman T, Rose-Nussbaumer J. Update on the management of infectious keratitis. *Ophthalmology.* 2017;124(11):1678-89.
 67. Naranjo A, Arboleda A, Martinez JD, et al. Rose bengal photodynamic antimicrobial therapy for patients with progressive infectious keratitis: a pilot clinical study. *Am J Ophthalmol.* 2019;208:387-96.
 68. Martinez JD, Naranjo A, Amescua G, et al. Human corneal changes after rose bengal photodynamic antimicrobial therapy for treatment of fungal keratitis. *Cornea.* 2018;37(10):e46-8.
 69. Srinivasan M, Mascarenhas J, Rajaraman R, et al. Corticosteroids for bacterial keratitis: the Steroids for Corneal Ulcers Trial (SCUT). *Arch Ophthalmol.* 2012;130(2):143-50.
 70. Sharma B, Soni D, Mohan RR, et al. Corticosteroids in the management of infectious keratitis: a concise review. *J Ocul Pharmacol Ther.* 2021;37(8):452-63.
 71. Szczotka-Flynn LB, Shovlin JP, Schnider CM, et al. American Academy of Optometry Microbial Keratitis Think Tank. *Optom Vis Sci.* 2021;98(3):182-98.
 72. Lakkis C, Anastasopoulos F, Slater J, et al. Clinical performance of silver salt-infused silicone hydrogel contact lenses over six months of daily wear. *Optom Vis Sci.* 2011;88.



CE TEST ~ JANUARY/FEBRUARY 2022

You can obtain CE credit by completing the test form and returning it with the \$35 fee to: Jobson Healthcare Information, Attn: CE Processing, 395 Hudson Street, 3rd Floor New York, NY 10014. To be eligible, return the card within three years of publication. You can also access the test form and submit your answers and payment via credit card at Review Education Group online, www.revieweducationgroup.com.

You must achieve a score of 70 or higher to receive credit. Allow four weeks for processing. For each course you pass, you earn two hours of credit. Check with your state licensing board to see if this approval counts toward your CE requirement for relicensure.

- 1. Which designation did the World Health Organization bestow on IK in order to raise awareness about the blinding nature of the disease?**
 - a. Neglected tropical disease.
 - b. Blinding corneal disease.
 - c. Preventable ocular surface condition.
 - d. Ocular disease of concern.
- 2. Which is the most common type of IK in the United States?**
 - a. Fungal keratitis.
 - b. AK.
 - c. MK.
 - d. Viral keratitis.
- 3. Which pathogen is the most common cause of IK related to OSD?**
 - a. *Pseudomonas aeruginosa*.
 - b. CoNS.
 - c. HSV.
 - d. *Candida albicans*.
- 4. Which is the most common cause of bacterial keratitis in contact lens wearers?**
 - a. *Pseudomonas aeruginosa*.
 - b. *Staphylococcus epidermidis*.
 - c. *Staphylococcus aureus*.
 - d. *Acanthamoeba*.
- 5. Which type of IK is five-times more likely to cause corneal perforation compared with MK?**
 - a. AK.
 - b. Viral keratitis.
 - c. Fungal keratitis.
 - d. Post-keratoplasty infectious keratitis.
- 6. Which pathogen is a common cause of fungal keratitis infection in the United States?**
 - a. *Candida albicans*.
 - b. *Acanthamoeba*.
 - c. *Pseudomonas aeruginosa*.
 - d. CoNS.
- 7. Which type of IK is associated with water and has an estimated prevalence of one to 33 per million contact lens wearers per year?**
 - a. AK.
 - b. Viral keratitis.
 - c. Fungal keratitis.
 - d. MK.
- 8. Which is the most common viral ocular pathogen?**
 - a. Herpes simplex.
 - b. Epstein Barr virus.
 - c. Varicella zoster.
 - d. Both a and c.
- 9. A corneal dendrite is typical of which type of IK?**
 - a. HSV.
 - b. Herpes zoster keratitis.
 - c. MK.
 - d. Fungal keratitis.
- 10. Which is the most common risk factor for IK in developed countries?**
 - a. Trauma.
 - b. Contact lens wear.
 - c. Prior corneal surgery.
 - d. OSD.
- 11. Which contact lens replacement schedule has the best replacement compliance?**
 - a. Daily disposable.
 - b. Bi-weekly replacement.
 - c. Monthly replacement.
 - d. Quarterly replacement.
- 12. Which microbe was the only one found on daily disposable contact lenses after a normal period of daily wear?**
 - a. *Pseudomonas aeruginosa*.
 - b. *Fusarium*.
 - c. *Candida*.
 - d. CoNS.
- 13. Which type of corneal surgery carries the highest risk of post-surgical infection?**
 - a. Cataract surgery.
 - b. LASIK.
 - c. PKP.
 - d. Endothelial keratoplasty.
- 14. Which IK can feature satellite lesions?**
 - a. AK.
 - b. Viral keratitis.
 - c. Fungal keratitis.
 - d. MK.
- 15. Which form of IK may benefit from epithelial debridement and is confirmed with confocal microscopy?**
 - a. AK.
 - b. Viral keratitis.
 - c. Post-keratoplasty infectious keratitis.
 - d. MK.
- 16. Which type of contact lens solution is most efficacious in preventing *Acanthamoeba* infection and is commercially available in the United States?**
 - a. Multipurpose solutions.
 - b. Hydrogen peroxide solutions.
 - c. PI solutions.
 - d. Saline solutions.
- 17. Which is not a potential future treatment option for IK?**
 - a. CXL.
 - b. Next-generation sequencing techniques.
 - c. Novel antimicrobial agents.
 - d. Keratorefractive surgery.
- 18. Which is not an appropriate treatment option for herpes simplex epithelial keratitis?**
 - a. Ganciclovir 0.15%.
 - b. Trifluridine 1%.
 - c. Oral acyclovir.
 - d. Oral doxycycline.
- 19. Despite technical innovations, rates of MK have remained constant at which rate over the past 25 years?**
 - a. Zero to one per 10,000 patients per year.
 - b. Two to five per 10,000 patients per year.
 - c. Four to seven per 10,000 patients per year.
 - d. Ten to 12 per 10,000 patients per year.
- 20. Which is not an additional risk factor for the development of IK?**
 - a. OSD.
 - b. Presbyopia.
 - c. PKP.
 - d. Corneal trauma.

Examination Answer Sheet

Trends In Infectious Keratitis

Valid for credit through February 15, 2025

Online: You can take this exam online at www.revieweducationgroup.com. Upon passing the exam, you can view the results immediately and download a real-time CE certificate. You can view your test history any time on the website.

Directions: Select one answer for each question in the exam and completely darken the appropriate circle. A minimum score of 70% is required to earn credit.

Mail to: Jobson Healthcare Information, LLC, Attn.: CE Processing, 395 Hudson Street, 3rd Floor New York, New York 10014.

Payment: Remit \$35 with this exam. Make check payable to Jobson Healthcare Information, LLC.

Credit: This course is COPE-approved for two hours of CE credit. Course ID 76681-TD.

Jointly provided by PIM and the Review Education Group.

Salus University has sponsored the review and approval of this activity.

Processing: There is a four-week processing time for this exam.

Answers to CE exam:

1. A B C D
2. A B C D
3. A B C D
4. A B C D
5. A B C D
6. A B C D
7. A B C D
8. A B C D
9. A B C D
10. A B C D
11. A B C D
12. A B C D
13. A B C D
14. A B C D
15. A B C D
16. A B C D
17. A B C D
18. A B C D
19. A B C D
20. A B C D

Post-activity evaluation questions:

Rate how well the activity supported your achievement of these learning objectives:

1=Poor, 2=Fair, 3=Neutral, 4=Good, 5=Excellent

21. Discuss the current trends in infectious keratitis. ① ② ③ ④ ⑤
22. Recognize the risk factors associated with this condition. ① ② ③ ④ ⑤
23. Diagnose and treat corneal infections. ① ② ③ ④ ⑤
24. Review how contact lens advancements have impacted infection rates. ① ② ③ ④ ⑤
25. Based upon your participation in this activity, do you intend to change your practice behavior? (choose only one)
 A I do plan to implement changes in my practice based on the information presented.
 B My current practice has been reinforced by the information presented.
 C I need more information before I will change my practice.
26. Thinking about how your participation in this activity will influence your patient care, how many of your patients are likely to benefit? (please use a number):
27. If you plan to change your practice behavior, what type of changes do you plan to implement? (check all that apply)
 a Apply latest guidelines b Change in pharmaceutical therapy c Choice of treatment/management approach
 d Change in current practice for referral e Change in non-pharmaceutical therapy f Change in differential diagnosis
 g Change in diagnostic testing h Other, please specify: _____
28. How confident are you that you will be able to make your intended changes?
 a Very confident b Somewhat confident c Unsure d Not confident
29. Which of the following do you anticipate will be the primary barrier to implementing these changes?
 a Formulary restrictions e Lack of interprofessional team support
 b Time constraints f Treatment related adverse events
 c System constraints g Patient adherence/compliance
 d Insurance/financial issues h Other, please specify: _____

30. Additional comments on this course: _____

Please retain a copy for your records. Please print clearly.

First Name

Last Name

E-Mail

The following is your: Home Address Business Address

Business Name

Address

City State

ZIP

Telephone # - -

Fax # - -

Rate the quality of the material provided:

1=Strongly disagree, 2=Somewhat disagree, 3=Neutral, 4=Somewhat agree, 5=Strongly agree

31. The content was evidence-based.

① ② ③ ④ ⑤

32. The content was balanced and free of bias.

① ② ③ ④ ⑤

33. The presentation was clear and effective.

① ② ③ ④ ⑤

By submitting this answer sheet, I certify that I have read the lesson in its entirety and completed the self-assessment exam personally based on the material presented. I have not obtained the answers to this exam by any fraudulent or improper means.

Signature _____ Date _____

Lesson 122419, RO-RCCL-0222

Deep Dive

Don't let suture-related complications sneak up on you after a corneal transplant.

A 68-year-old woman presented to the emergency department with a history of intermittent redness and pain in the left eye for one month.

She had a past ocular history of radial keratotomy (RK) in both eyes and a penetrating keratoplasty (PKP) eight months prior in the left eye, for which she was using prednisolone acetate 1% twice daily.

On examination, her vision pinholed to 20/80 in the right eye and 20/60 in the left eye. Intraocular pressure and dilated fundus examination were within normal limits in both eyes. The anterior segment exam of the right eye revealed RK scars and moderate endothelial guttae without stromal edema, and the left eye revealed RK scars on the host cornea and a PKP with no sutures remaining. The graft was grossly clear, but attention was drawn to the temporal graft, where a fluffy deep stromal infiltrate was appreciable below a prior suture site. There was an overlying pinpoint epithelial defect. The left eye's anterior chamber revealed 1+ cell and flare, but the conjunctiva was surprisingly quiet (*Figure 1*). Further imaging with anterior segment optical coherence tomography (OCT) revealed a hyperreflective density at 50% depth (*Figure 2*).

Upon review of the patient's medical records, there had been an eroded corneal suture temporally on the left eye one month

prior. The suture was removed at that time, but the patient noted her symptoms had since worsened.

MICROENVIRONMENT

PKPs change the corneal dynamics. First, the corneal innervation is significantly altered. During surgery, full-thickness trephination of the diseased cornea severs corneal nerves. Corneal innervation is integral for a number of processes, including protection of the ocular surface via blink reflexes, enabling wound healing by numerous trophic mechanisms and providing neural feedback to stimulate lacrimation.^{1,2}

Studies reveal that, following PKP, a peripheral graft's subbasal nerve complex may begin to reform in as little as two months, but central innervation may take one to two years before it is initially detectable.^{3,4} Even when detectable, significant alterations in the density and branching pattern of the subbasal nerve complex exist, and there remains some degree of decreased sensation in many cases.^{4,5}

Another alteration in the PKP microenvironment is local immuno-

suppression. Though the cornea may have relative immune privilege compared to other areas of the body due to lack of corneal neovascularization or lymphatics, corneal graft rejection still remains a real risk. It has been well-accepted that local or systemic immunosuppression greatly reduces the chance of graft rejection.^{6,7} In most cases this is successfully done with topical ophthalmic corticosteroids, but topical cyclosporine and tacrolimus, as well as oral immunosuppressives such as mycophenolate mofetil and cyclophosphamide, have been used successfully.⁸ Regardless of the drug, the result is a reduced host immune response against the donor tissue or exogenous infectious sources.

Finally, corneal sutures are always placed during full-thickness keratoplasties—typically first in four cardinal positions, then the graft is further stabilized by the use of a single running suture or multiple interrupted sutures. Sutures can remain in the graft indefinitely but are often removed for refractive optimization. While in place, they may break or loosen with time. Exposed sutures lead to a breakdown of the corneal epithelial barrier and can allow a pathway for external pathogens to make their way into the corneal stroma.

CORNEAL SUTURES AND ABSCESS FORMATION

In addition to assessing the overall status of the corneal transplant itself, clinicians should carefully evaluate any sutures. The best way to visualize a suture's integrity is to use topical sodium fluorescein (NaFl). A suture properly covered

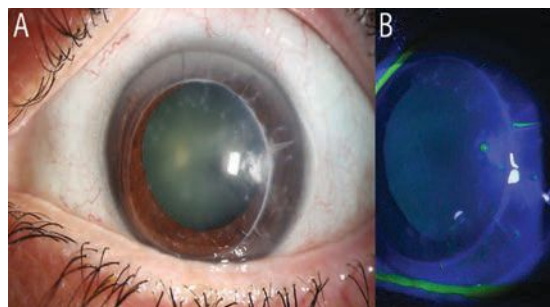



Fig. 1. (a) Minimal conjunctival injection (post phenylephrine/dilation). Notice the PKP graft with host RK scars. At 3 o'clock, there is a deep but irregular infiltrate. (b) Notice the lack of NaFl staining over the lesion, denoting only a pinpoint epithelial defect where the graft's suture passed.



by epithelium will not stain under blue light. A loose or eroded suture, on the other hand, will stain with NaFl. Though NaFl may pool over a suture mimicking epithelial erosion, it's helpful to draw up any excessive dye from the suture with a sterile cotton-tipped applicator or cellulose sponge spear for better evaluation. If the NaFl can be soaked up and there is no staining of the suture, the suture is not exposed and may be left in place. Any that are loose, broken or otherwise exposed, should be removed. Most physicians recommend using povidone-iodine solution prior to suture removal, then prophylactic topical antibiotics are dosed until the epithelial defect is closed.

The presence of corneal sutures, in addition to reduced corneal innervation and chronic local immunosuppression, combine to create a corneal microclimate that predisposes the post-keratoplasty eye to microbial keratitis.⁹ The rate of infectious keratitis (IK) among eyes that have undergone a PKP is high, anywhere from 1.76% to 11.9%.¹⁰ Suture tract abscesses, in particular, occur when a suture becomes exposed to the external environment and allows for microbial penetration deeper into the stromal tissue. These appear clinically as corneal infiltrates along any portion of the suture tract, usually with attendant anterior chamber inflammation and conjunctival injection.

There will often be a small epithelial defect, but the absence of one does not exclude the presence of an infection. Patients will likely complain of photophobia, foreign body sensation and decreased vision. Loose or eroded sutures, suture manipulation and suture abscess-

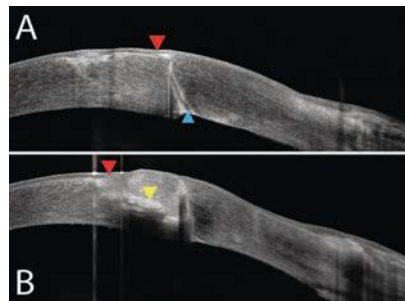


Fig. 2. (a) OCT of the graft-host junction superior to the infiltrate shows a fully intact epithelium (red) and a delineated graft-host barrier (blue). (b) OCT over the lesion demonstrates intact corneal epithelium (red) with a midstromal opacity/infiltrate (yellow).

es have all been implicated in the development of endophthalmitis, which generally carries a poor visual prognosis.¹¹

PATIENT OUTCOME

Due to the presence of a deep stromal infiltrate, a cornea specialist was called for evaluation. In most IK cases, a corneal culture is taken by scraping an ocular surface lesion with a surgical spatula/blade or sterile cotton alginate swab. Because of the depth of infection, a culture by suture pass was performed. The surgeon anesthetized the eye, then passed a curved needle with braided silk suture in through clear cornea adjacent to the infiltrate. Next, the needle and suture were directed anteriorly through the infiltrate. The suture material was plated on blood agar, chocolate agar, Sabouraud dextrose agar, Lowenstein-Jensen medium and agar agar, and sent to the microbiology laboratory.

Two days later, the culture grew a yeast, *Candida parapsilosis*. Fortified antibiotics originally dosed every hour were reduced to four times

daily and natamycin 5% was started every hour. At one week, the stromal infiltrate was thought to be worsening, so a superficial scrape was performed to allow for improved drug penetration. Given the potential of *Candida parapsilosis* to form biofilms, fortified topical voriconazole and oral fluconazole were added. The patient was evaluated weekly for two months before the infection was finally ameliorated. Fortunately, this post-keratoplasty eye had a good visual outcome.

Managing patients with corneal transplants can certainly have its ups and downs. It's important to be aware of the abnormal microclimate in these transplants and be vigilant in searching for signs of complications. Early recognition and removal of loose or broken sutures can prevent worse outcomes by reducing the risk of inflammation and infection. **RECL**

- Müller LJ, Marfurt CF, Kruse K, Tervo TMT. Corneal nerves: structure, contents and function. *Exp Eye Res.* 2003;76(5):21-42.
- Dartt DA. Dysfunctional neural regulation of lacrimal gland secretion and its role in the pathogenesis of dry eye syndromes. *Ocul Surf.* 2004;2(2):76-91.
- Richter A, Slowik C, Somodi C, et al. Corneal reinnervation following penetrating keratoplasty—correlation of esthesiometry and confocal microscopy. *Ger J Ophthalmol.* 1996;5(6):513-7.
- Darwish T, Brahma A, Efron N, O'Donnell C. Subbasal nerve regeneration after penetrating keratoplasty. *Cornea.* 2007;26(8):935-40.
- Stachs O, Zhivov A, Kraak R, et al. Structural-functional correlations of corneal innervation after LASIK and penetrating keratoplasty. *J Refract Surg.* 2010;26(3):159-67.
- Shimmura-Tomita M, Shimmura S, Satake Y, et al. Keratoplasty postoperative treatment update. *Cornea.* 2013;32 Suppl 1:S60-4.
- Abudou M, Wu T, Evans JR, Chen X. Immunosuppressants for the prophylaxis of corneal graft rejection after penetrating keratoplasty. *Cochrane Database Syst Rev.* 2015;(8):CD007603.
- Azevedo Magalhaes O, Shalaby Bardan A, Zarei-Ghanavati M, Liu C. Literature review and suggested protocol for prevention and treatment of corneal graft rejection. *Eye (Lond).* 2020;34(3):442-50.
- Leahy AB, Avery RL, Gottsch JD, et al. Suture abscesses after penetrating keratoplasty. *Cornea.* 1993;12(6):489-92.
- Vajpayee RB, Sharma N, Sinha R, et al. Infectious keratitis following keratoplasty. *Surv Ophthalmol.* 2007;52(1):1-12.
- Henry CR, Flynn HW Jr, Miller D, et al. Delayed-onset endophthalmitis associated with corneal suture infections. *J Ophthalmic Inflamm Infect.* 2013;3(1):51.



In the Line of Fire

Corneal foreign bodies can cause longstanding problems if not attended to quickly.

A 38-year-old male presented complaining of foreign body sensation OD. One day earlier, he had been working on some equipment when he thought something flew into his eye. He rinsed his eye with contact lens solution, and the sensation improved. However, he woke up the next morning with a gritty feeling and photophobia. His vision was slightly diminished at 20/20-2.

Examination showed a single central rust ring with an overlying epithelial defect. Corneal infiltrates circumscribed the rust ring. The wound was Seidel negative. The pupil was round and reactive, and the anterior chamber was quiet.

Most of the rust was removed using a golf club spud, taking care not to penetrate too deeply into the stroma. Cycloplegia and a bandage

lens improved comfort. The patient was put on moxifloxacin 0.5% QID and instructed to return the next day.

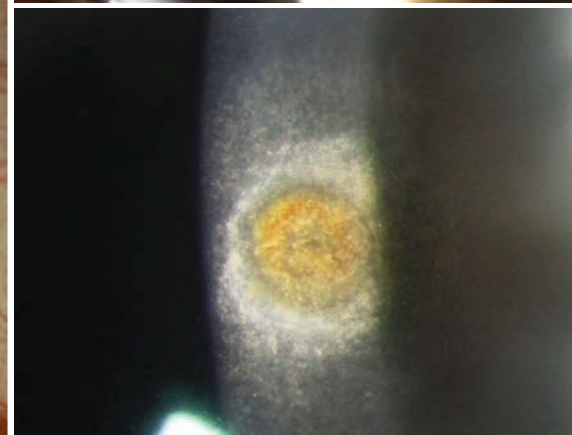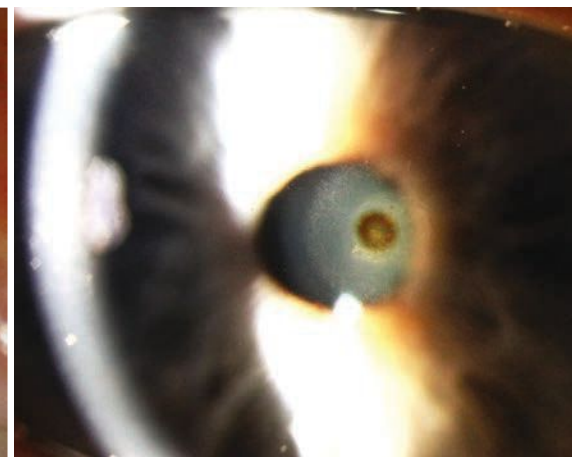
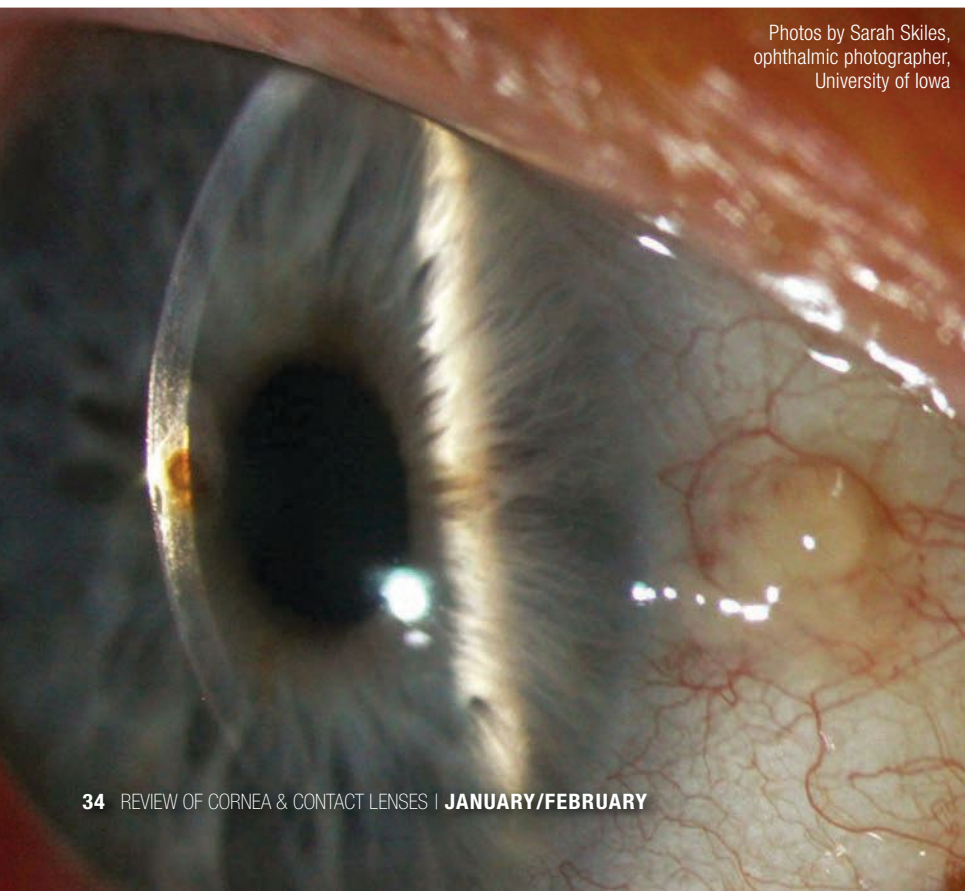Rust rings are created when an iron-containing foreign body lodges in the corneal surface and oxidizes from salt in the tears. Formation typically starts at the level of the superficial stroma within a few hours. White blood cells (WBCs) drawn to the damaged tissue secrete collagenase, which causes the adjacent collagen to soften and break down.

The presence of WBCs indicates an inflammatory response to tissue damage and not necessarily an infectious process. It is hypothesized that soluble iron complexes react with the softened collagen to create the classic bull's-eye rust ring. This progressive damage may be why it is often easier to remove a rust ring two to three days after the injury.

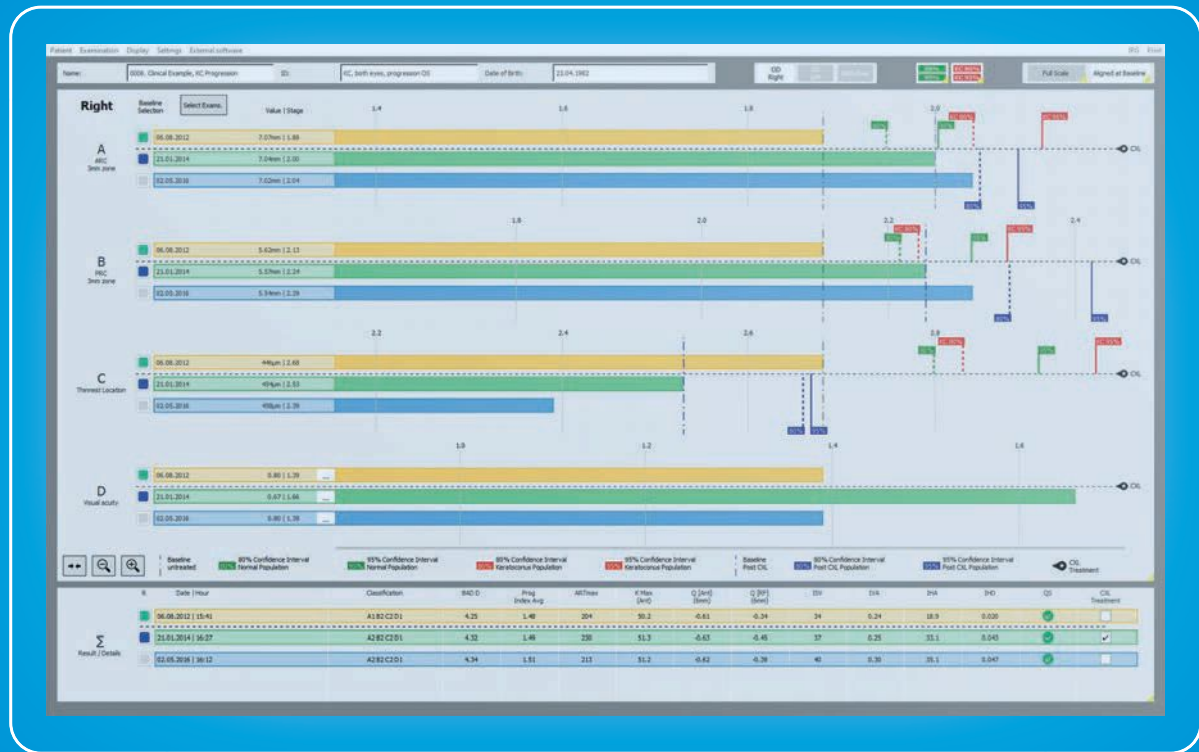
A small rust ring may be of no consequence and heal regardless of removal. However, it is standard of care to remove any remaining foreign material and as much of the rust as possible when there is visible necrosis. Rust may be removed with a cotton-tipped applicator, small-gauge needle, golf club spud, magnetic spud or Alger brush. Use caution to avoid drilling too deep or creating a bigger wound. If residual rust remains, it should be monitored and removed later if it is impeding the healing process.

Our patient returned the next day with a nearly closed epithelium, minimal residual rust and only mild foreign body sensation. Residual scarring was discussed with the patient, but his vision remained acceptable at 20/20-2. Safety goggles were advised to avoid future events. **RCCL**

Photos by Sarah Skiles,
ophthalmic photographer,
University of Iowa



Keratoconus Progression at a Glance!



Retrospective use



Free update



User-friendly

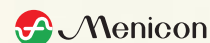

The Belin ABCD Progression Display now includes post-CXL data

The newly integrated post-CXL function and database allow for evaluation of the cornea after crosslinking, based on the full complement of parameters including posterior corneal surface and corneal thickness at its thinnest spot.

Monitor your keratoconus treatment with ease and improve your surgery outcomes!

70th
anniversary
1951-2021



Introducing,

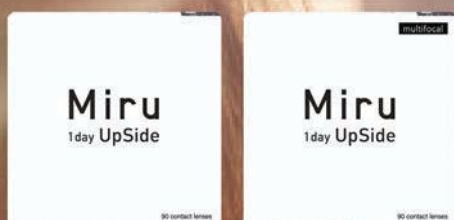Miru 1day UpSide

silicone hydrogel contact lenses
with **Smart Touch™** technology.

A new generation of silicone hydrogel material
balanced for health and comfort incorporating
a unique combination of **high oxygen** and **ultra
low modulus**.

SMART TOUCH™

Miru 1day UpSide contact lenses are always
the right way up and ready to wear, thanks to
Smart Touch™ technology.



Find us on:    

www.meniconamerica.com