

RCCL[®]

REVIEW OF CORNEA
& CONTACT LENSES

NOVEMBER/DECEMBER 2020

EARN 2 CE CREDITS:

HERPES SIMPLEX KERATITIS: MANAGING THE MASQUERADER

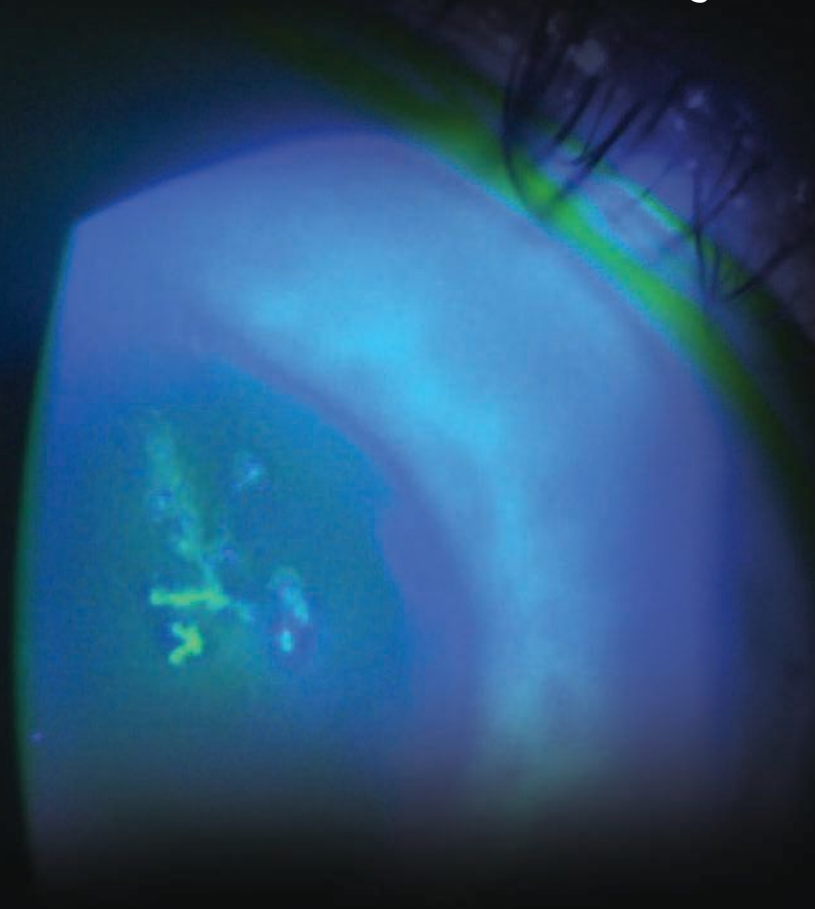
Page 24

ALSO:


A New Era of Keratoconus Care, *Page 12*

Specialty Contact Lenses for the Diseased Cornea, *Page 20*

Four Troubleshooting Pearls for Scleral Lens Success, *Page 32*



Simplify your Lens Fitting.



OCULUS Pentacam® for efficient specialty lens fitting

Bring efficiency to your specialty lens fitting! Order fewer lenses and decrease patient chair time while increasing the first fit success rate. The Pentacam® simplifies the fitting process by providing true elevation data independent of the tear film. Benefit further with direct links to advanced fitting and design software.

OCULUS Pentacam® – Your new trial lens fitting set!



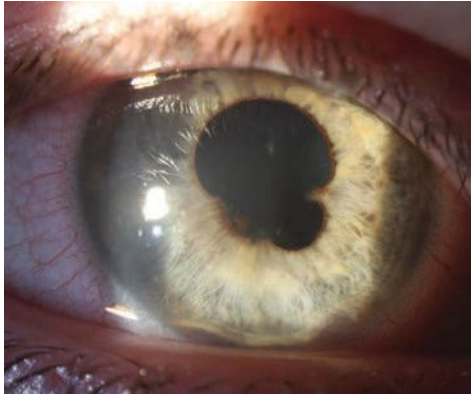
Scan here or visit
www.oculususa.com/lensfitting

Toll free 888-519-5375
ads@oculususa.com

 **125 YEARS**
OCULUS®

contents

Review of Cornea & Contact Lenses | November/December 2020



departments

4 News Review

Post-op patients and sclerals; late bedtime and myopia

6 My Perspective

The COVID Story So Far
By Joseph P. Shovlin, OD

8 The GP Experts

Go Deeper With Annual Evaluations
By Lindsay Sicks, OD, and Kyle Martin, OD

10 Fitting Challenges

Fit the Patient, Not the Diagnosis
By Cory Collier, OD

38 Corneal Consult

The Answer's in the Details
By Aaron Bronner, OD, and Alison Bozung, OD

40 Practice Progress

Corneal GPs are Here to Stay
By Courtney Melchione, OD, Mile Brujic, OD, and David Kading, OD

42 The Big Picture

Don't Burst Your Bubble
By Christine W. Sindt, OD

features

12

A New Era of Keratoconus Care

Learn how advances in diagnostics and treatment are turning the old paradigm on its head.

By John D. Gelles, OD, Peter S. Hersh, MD, and Steven A. Greenstein, MD



20

Specialty Contact Lenses for the Diseased Cornea

When fit successfully, these medical devices can be a life-changer for appropriate patients.

By Christopher Lopez, OD

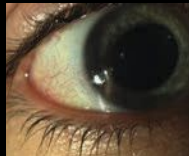

24

CE: Herpes Simplex Keratitis: Managing the Masquerader

This review can help you better identify, diagnose and treat this condition.

By Shannon Leon, OD



32

Four Troubleshooting Pearls for Scleral Lens Success

Early training can help scleral patients avoid lens wetting issues, midday fogging and other common problems that can lead to dropout.

By Andrew Pucker, OD, PhD



IN BRIEF

■ Researchers recently reported that six weeks of home-based, anaglyphic, contrast-balanced, dichoptic videogame play can improve amblyopic distance visual acuity (DVA) and stereo acuity significantly in mild amblyopia. They examined 23 individuals for six weeks and found that the difference in mean DVA between groups remained at 12 weeks follow-up but not at 24 weeks, but the improvement in stereo acuities still remained at 24 weeks.

Pang PCK, Lam CSY, Hess RF, et al. Effect of dichoptic video game treatment on mild amblyopia—a pilot study. *Acta Ophthalmologica*. September 30, 2020. [Epub ahead of print].

■ Changing the lens diameter or surface lubricity doesn't help new, healthy gas permeable (GP) wearers adapt better to lens wear. The investigators found neither the Hydra-PEG (Tangible Science) coating or larger diameters (from 9.6mm to 10.1mm or 10.6mm) improved comfort or bulbar redness during the 20-minute adaptation period. In both cohorts, comfort improved and bulbar redness reduced with time. Additionally, corneal staining, ease of insertion and ease of removal did not differ with GP coating or diameter.

Debarun D, Wolffsohn JS. Effect of large diameter and plasma coating on the initial adaptation of gas permeable contact lens fitting for neophytes. *Cont Lens Anterior Eye*. September 8, 2020. [Epub ahead of print].

■ Researchers have discovered significant differences in the microbiota of those with aqueous-deficient dry eye disease (DED), suggesting these microorganisms, or their absence, play a part in DED pathophysiology. The team studied conjunctival swab samples from patients with aqueous-deficient DED (18 with ocular graft-vs.-host disease, 21 without) and 28 controls. They isolated the bacterial DNA from the swabs and analyzed them with gene sequencing. They found those with DED not only had decreased microbiota diversity but also a different composition than controls. While *Pseudomonas* was a biomarker for controls, *Bacilli* was the biomarker for those with aqueous-deficient DED.

Andersson J, Vogt JK, Dalgaard MD, et al. Ocular surface microbiota in patients with aqueous tear-deficient dry eye. *Ocul Surf*. September 12, 2020. [Epub ahead of print].

How to Keep Post-op Patients in Their Sclerals

A recent study noted that 15% to 22% of patients with chronic graft-vs.-host disease (GVHD) who undergo cataract surgery rely on scleral lenses, and after surgery, they're expected to resume their scleral lens wear within about one week, regardless of visual outcome.

Currently, there's no reliable approach to achieving satisfactory vision: obtaining a manifest refraction before cataract surgery is difficult in this population because the ocular surface deteriorates dramatically upon removal of the scleral lens. Furthermore, many cataract surgeons select refractive targets assuming the patient will replace their scleral lenses postoperatively, but this is usually not the case. Replacing scleral lenses is financially burdensome and can cause unnecessary delays to vision recovery while waiting for a prescription change.

In the study, the authors proposed a novel approach to reverse-calculate the refractive aim in patients with well-fitted, properly over-refracted scleral lenses. They said this will maximize the immediate post-op refractive outcome without the need to replace the lens and cause undue financial stress and delays in vision recovery.

In this retrospective, single-surgeon study, the researchers determined the target refraction for the intraocular lens by considering the effective scleral lens system power. They calculated this by adding the known scleral lens spherical power to the difference between the scleral lens base curve and the average keratometry value.

Six eyes of three patients with

ocular GVHD who wore scleral lenses underwent cataract surgery with this refractive calculation. Postoperatively, all patients achieved corrected visual acuities of 20/30 or better while wearing their original scleral lenses at the follow-up visit one week later. All six eyes resumed full scleral lens use a week after cataract surgery, and no patients required scleral lens replacement.

The authors noted that all six eyes were moderately myopic or near emmetropic before cataract surgery. They said that targeting a refraction in this range is practical because it's compatible with necessary daily activities, such as the insertion and removal of scleral lenses. "If the preoperative refractive state is hyperopic or highly myopic, it could be beneficial to reestablish a more practical refractive outcome for best-uncorrected near and intermediate vision," they wrote.

This particular approach to reverse-calculating the target refraction relies heavily on the assumption that the scleral lenses are well-fitted and properly over-refracted. Additionally, the authors stressed the importance of performing biometry or autokeratometry efficiently and immediately after scleral lens removal.

"Such an approach also solves the dilemma of whether to fit scleral lenses in patients with visually significant cataracts requiring urgent ocular surface protection, knowing that they will likely need to be replaced after cataract surgery," the authors wrote.

1. Ma KK, Luo ZK. Novel method to determine target refraction in cataract surgery for patients dependent on therapeutic scleral lenses. *Eye Contact Lens*. October 1, 2020. [Epub ahead of print].

19 Campus Blvd., Suite 101
Newtown Square, PA 19073
Telephone (610) 492-1000
Fax (610) 492-1049

Editorial inquiries: (610) 492-1006
Advertising inquiries: (610) 492-1011
Email: rccl@jobson.com

EDITORIAL STAFF

EDITOR-IN-CHIEF

Jack Persico jpersico@jobson.com

MANAGING EDITOR

Rebecca Hepp rhepp@jobson.com

ASSOCIATE EDITOR

Catherine Manthorp cmantorh@jobson.com

ASSOCIATE EDITOR

Mark De Leon mdeleon@jobson.com

CLINICAL EDITOR

Joseph P. Shovlin, OD, jpshovlin@gmail.com

ASSOCIATE CLINICAL EDITOR

Christine W. Sindt, OD, christine-sindt@uiowa.edu

GRAPHIC DESIGNER

Jared Araujo jaraujo@jhihealth.com

AD PRODUCTION MANAGER

Farrah Aponte faponte@jobson.com

BUSINESS STAFF

EXECUTIVE DIRECTOR

James Henne jhenne@jobson.com

PUBLISHER

Michael Hoster mhoster@jobson.com

REGIONAL SALES MANAGER

Michele Barrett mbarrett@jobson.com

REGIONAL SALES MANAGER

Jon Dardine jdardine@jobson.com

EXECUTIVE STAFF

CEO, INFORMATION SERVICES GROUP

Marc Ferrara mferrara@jhihealth.com

SENIOR VICE PRESIDENT, OPERATIONS

Jeff Levitz jlevitz@jhihealth.com

**SENIOR VICE PRESIDENT,
HUMAN RESOURCES**

Tammy Garcia tgarcia@jhihealth.com

**VICE PRESIDENT,
CREATIVE SERVICES & PRODUCTION**

Monica Tettamanzi mtettamanzi@jhihealth.com

VICE PRESIDENT, CIRCULATION

Emelda Barea ebarea@jhihealth.com

CORPORATE PRODUCTION MANAGER

John Caggiano jcaggiano@jhihealth.com

EDITORIAL REVIEW BOARD

Mark B. Abelson, MD

James V. Aquavella, MD

Edward S. Bennett, OD

Aaron Bronner, OD

Brian Chou, OD

Kenneth Daniels, OD

S. Barry Eiden, OD

Desmond Fonn, Dip Optom, M Optom

Gary Gerber, OD

Robert M. Grohe, OD

Susan Gromacki, OD

Patricia Keech, OD

Bruce Koffler, MD

Pete Kollbaum, OD, PhD

Jeffrey Charles Krohn, OD

Kenneth A. Lebow, OD

Jerry Legerton, OD

Kelly Nichols, OD

Robert Ryan, OD

Jack Schaeffer, OD

Charles B. Slonim, MD

Kirk Smick, OD

Mary Jo Stiegemeier, OD

Loretta B. Szcotka, OD

Michael A. Ward, FCLSA

Barry M. Weiner, OD

Barry Weissman, OD



Late Bedtime Linked With Myopia

Although the underlying mechanisms remain unclear, researchers have highlighted the impact of sleep patterns on myopia onset and progression, noting that a later bedtime (9:30pm or after) is linked with increased risk of myopia and myopia progression. They believe the relationship may allude to a more complex dynamic between indoor environment, activities, circadian rhythm and myopia.

The Shanghai study followed 6,295 children (ages six to 10) for 24 months using an app-based questionnaire completed by parents and caregivers four times a year. They found that children who went to sleep after 9:30pm were 1.55-times more likely to be diagnosed with myopia at baseline and 1.44-times more likely to have myopia by the two-year follow-up, after adjusting for residency area, age, sex and time spent outdoors (Table 1). Those who had a later bedtime were also more likely to experience myopia progression. However, the researchers found no evidence supporting a relationship between sleep duration and myopia.

The team suggested that going to sleep later could be linked with more late-night, near-based activi-




Photo: Julie Tyler, OD, and Heidi Wagner, OD, MPH

Researchers suggest screen time could lead to a later bedtime in children.

ties and more exposure to artificial lighting conditions. A child is highly likely to spend more time reading on digital devices while inside in the evenings. The study noted that children who read more and spent more time on screens and less time outdoors were also more likely to go to bed later.

The researchers said they believe future studies on myopia should determine whether going to sleep late makes children more prone to myopigenic activities under poor lighting conditions when they are supposed to be sleeping or more susceptible to abnormal eye growth due to circadian disturbance. **RCCL**

Liu XN, Naduvilath TJ, Wang J, et al. Sleeping late is a risk factor for myopia development amongst school-aged children in China. *Sci Rep.* 2020;10(1):17194.

Table 1. Myopia Prevalence By Bedtime

	Baseline	24 Months
<8:30pm	3.7%	7.9%
8:30–8:59pm	5.8%	11.0%
9:00–9:29pm	6.7%	11.4%
9:30–9:59pm	7.7%	14.0%
≥10pm	8.7%	14.1%



The COVID Story So Far

Researchers are exploring the virus's ocular implications. Here's what we currently know.

Many questions surrounding COVID-19 remain unanswered. We're certainly encountering significant debates on SARS-CoV-2/COVID-19 experiences, especially as they relate to the likely potential for eye transmission and the actual rate of eye complications and their implications.

Gaps in knowledge remain, but let's separately review each of these issues and what we know so far. How we prepare now and successfully educate patients on these important questions will help determine how much of an impact a potential second wave might have.

EYE TRANSMISSION

The eye appears to be a vector for viral replication and possible downstream transmission from the ocular surface to the respiratory and gastrointestinal tract areas.^{1,2} However, little evidence suggests viral transmission occurs through the eye.³ Researchers have documented SARS-CoV-2 receptors in the eye, possibly explaining the viral tropism to the ocular tissue.²

Co-expression and protein interaction network analysis uncovered that the mitochondrial function-related genes in the cornea contribute to the dissection of SARS-CoV-2 susceptibility and potential therapeutic interventions.²

In a series of COVID-19 patients diagnosed via pharyngeal swab and broncho-alveolar lavage, all ocular tissues and fluid were free of RNA detection with quantitative reverse transcription PCR testing.² The researchers determined that late-stage COVID-19 patients might

not harbor an ocular reservoir of SARS2, thereby making it likely that transmitting SARS-CoV-2 via ocular tissues and fluids is low.¹ However, it's possible the viral load in real time PCR testing of human tears may remain below detection threshold levels.²

In addition, when any viral load is detected on the ocular surface, it might come directly from the sinuses.³ The eye's microbiome, along with natural defense mechanisms (e.g., lactoferrin and IgA and the blink mechanism), may keep the probability of SARS-CoV-2 binding to ACE2 receptors low, thereby protecting the eye from the coronavirus.^{1,4}

Obviously, if clinicians are seeing any patients positive for COVID-19 and are engaged in seeing any at-risk patients, special precautions should include eye protection (tight-fitting goggles), along with a suitable N95 mask since there remains the possibility of viral shedding and potential for transmission through the eye.

EYE COMPLICATIONS

Research has reported follicular and hemorrhagic conjunctivitis in patients with COVID-19.⁵ Conflicting information exists on the actual rate of COVID-related eye complications. Several reports show a low percentage of COVID-19 positive patients with conjunctivitis (probably less than 5%).⁵

Other reported complications associated with COVID-19 infection include episcleritis, corneal neuropathies, optic neuritis, uveitis, retinitis and exacerbations of dry eye.^{5,6} Again, whether the ocular surface

can serve as a reservoir for transmitting infection remains uncertain and is under debate.^{3,6}

Fortunately, we have learned a great deal about best practices for reducing risk, how to best detect COVID-19 infections and even how we might reduce morbidity/mortality once infection has occurred. But, when following the data collected to date, it's easy to see that there's still much we need to learn about this illness.

The debates will continue as we strive to thwart this dreaded disease. We will hopefully have an effective and safe vaccine soon, along with more effective treatment options and directives on how to treat this disease. In the meantime, continue to take every measure to protect your patients, staff and yourself.

We must remain vigilant not only in paying close attention to ocular manifestations related COVID-19 but also sorting out the other questions that remain. **rccl**

1. Bayyoud T, Iftner A, Iftner T, et al: Absence of severe acute respiratory syndrome-coronavirus-2 RNA in ocular tissues. *Am J Ophthalmol*. 2020;19:100805.

2. Guemes-Villahoz N, Burgos-Biasco B, Vidal-Villegas B, et al: Novel insights into the transmission of SARS-CoV-2 through the ocular surface and its detection in tears and conjunctival secretions: a review. *Adv Ther*. August 18, 2020. [Epub ahead of print].

3. Personal communication, Mark Willcox, PhD.

4. Yuan J, Dan F, Xue Z, et al: Co-expression of mitochondrial genes and ACE2 in cornea involved in COVID-19 infection. *bioRxiv*. July 24, 2020. [Epub ahead of print].

5. Cimberle M: Ophthalmologists need to stay vigilant for ocular manifestations of COVID-19. www.healio.com/news/ophthalmology/20200812/ophthalmologists-need-to-stay-vigilant-for-ocular-manifestations-of-covid19. August 18, 2020. Accessed October 5, 2020.

6. Jones L, Walsh K, Wilcox M, et al: The COVID-19 pandemic: important considerations for contact lens practitioners. *Cont Lens Anterior Eye*. 2020;43(3):196-203.

REVIEW OF OPTOMETRY

The OD's TOP CHOICE

Ranked #1 Eye Care
Publication In
FIVE
Critical Readership
Categories:



Total Readers



Most Read Publication/
Website Within the Last
Six Months



Quality Clinical Content
I Use in My Practice



Average Page Exposures



Websites Visited within
the Last Six Months

Source: Kantar Media Eyecare 2020 Study

Practitioners rely on RO
more than any other eye
care publication



**Review also is number one in readership
across the following categories:**

- Total Optometrists
- ODs in High-Volume Practices
- Solo Practitioners
- Annual Practice Revenue (\$500k+)
- ODs who Purchase Examination Equipment
- Write Prescriptions (11+ per week)
- Perform Refractions (51+ per week)
- Contact Lens Prescribers
- Years in Practice (1-15 and 15+)
- Among Key Opinion Leaders

***To our readers:* Thank you for
your loyalty, time and trust.
We'll keep working hard to earn
your support.**

Go Deeper With Annual Evaluations

There might be something going on beneath the patient's claim of feeling fine.

A recent patient visit reminded us of the myriad reasons we recommend annual eye examinations for contact lens wearers. A 53-year-old keratoconus patient wearing corneal gas permeable (GP) lenses had been wearing the same pair for the last decade with no interim examinations.

The present visit opened up a much-needed dialogue, and we were able to mutually agree that changes to her routine and lenses were necessary. In the decade since her last visit, advancements in contact lens designs and care have allowed us to better meet her needs.

ASK THE RIGHT QUESTIONS

Given that a good case history is key to any patient visit, asking the right questions to uncover unspoken issues that contact lens wearers will get us beyond “everything is fine” and to the real story.

This patient initially relayed that everything was great with her lenses, including her vision. She didn't feel she was having any problems other than a single emergency room visit for a red, irritated eye, where she received unknown eye drops for treatment. She said that issue cleared up shortly after the visit and has not recurred.

We asked her to elaborate on how she uses her eyes at home and work and about any specific potential symptoms she may have encountered. The patient then admitted to repeated episodes of eye irritation over the last few years. She also confirmed persistent daily

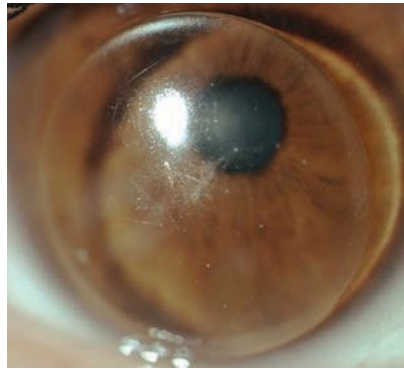


Fig. 1. GP lens with central scratches, deposits and makeup debris at the edges.

dryness that had been worsening over the past few months as she struggled with working from home and increasing use of digital devices. She then admitted to having difficulty seeing up close with her lenses, which had been worsening over time. Also, she described a “greasy film” that had appeared in her vision over the past couple months. She then admitted non-compliance with the use of her current GP multipurpose solution and only occasionally rubbed her lenses in the morning before application.

We performed a slit lamp examination, which uncovered the underlying cause of this patient's episodes of eye irritation. Her habitual lenses had numerous front surface scratches and deposits. The lenses were caked with debris at the edges (*Figure 1*). Her cornea had nasal and temporal (3 o'clock and 9 o'clock) staining. There was also peripheral corneal neovascularization with mild opacification consistent with previous episodes of vascularized limbal keratitis (VLK) present on each cornea (*Figure 2*).¹

Her conjunctiva had a moderate papillary response with mild injection on the upper and lower lids. She also wore heavy makeup and presented with mascara, eyeliner and powder on each eyelid. She was not always compliant with nightly removal of her makeup.

We were able to perform a targeted dry eye workup, uncover the underlying causes of her dry eye and treat accordingly. We reviewed the importance of removing her GP lenses for cleaning nightly as well as complete removal of eye makeup nightly.

PREVENT COMPLICATIONS

Each time we see a patient, we gain an opportunity to review critical parts of lens wear and care. Since this patient hadn't been to our office in a decade, she developed some bad habits that we felt could stand correcting. Given the age of her habitual lens, it was in definite need of replacement. Contact lens deposits can occur secondary to protein or lipid buildup and begin to occur within minutes of lens wear.²

Proper lens cleaning, including a rubbing step, is vital to reducing the bacterial bioburden on a contact lens. This patient was using Boston Simplus (Bausch + Lomb) solution, so we reviewed the best practices, including using fresh solution each night, soaking overnight (or at least for four hours) and rinsing for approximately five seconds with a steady stream of solution before lens application.³

We also reviewed proper hand-washing and case cleaning protocols (discard used solution, rub and



rinse lenses with fresh solution, wipe with a tissue, let air dry face-down and avoid using tap water).⁴

Contact lenses may come into contact with cosmetics during the application and removal process or when makeup is applied while lenses are on. Additionally, research has shown that cosmetics are released from the lids and lashes and into the tear film. One study showed migration of product applied directly to the inner eyelash line migrates onto the ocular surface in as little as five minutes.⁵

Adherence to proper hygiene practices with cosmetics can be just as important as hygienic contact lens use. Makeup should be replaced at appropriate intervals (mascara every three to six months, liquid and gel eyeliner every six to eight months and eyeliner pencils and powder annually).⁶ Additionally, if a patient develops symptoms of an eye infection, it is best to remove contact lenses, discontinue makeup wear and replace products after the infection clears.

As clinicians, we also need to do our part to prevent contact lens-related complications when patients are in the office. After years of overwear of a GP lens, this patient required careful slit lamp evaluation with fluorescein staining to check for corneal compromise and evaluate lens fit, upper lid eversion to check for papillary conjunctivitis and corneal topography to monitor disease progression. Corneal warpage can be difficult to detect on anterior topography in corneal GP lens wearers with keratoconus, as both conditions exhibit steepening on anterior topography.

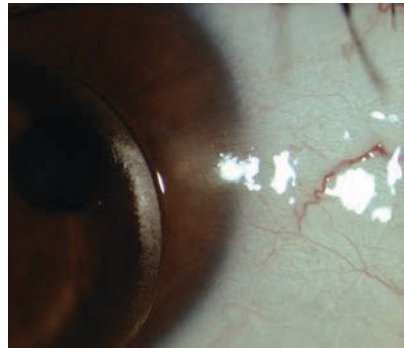


Fig. 2. Scarring and neovascularization in the limbal region from VLK is visible.

Each patient visit is also a chance to review signs and symptoms of contact lens-related complications. Since our patient had sought care at an emergency room for a previous red eye, and, because we noted signs of previous inflammation, we reminded her we are happy to triage any future red eye concerns.

One easily accessible resource on best practices for all types of contact lens wear and the prevention of complications is a printable handout from the Association of Optometric Contact Lens Educators called “Healthy Gas Permeable Contact Lens Habits” (available at aocle.org/index.php/healthy-gp-cl-habits). We give a copy to new and returning patients as a reminder of the items reviewed during their visit.

DISCUSS NEW TECHNOLOGY

This visit also allowed us to introduce the patient to some of the technology our practice has acquired over the last decade—including corneal tomography, tear osmolarity and scleral mapping. GP lenses certainly have their place in management of both the normal

and irregular cornea; however, when we verified the difficulties this patient was having, they centered around reduced vision, dry eye symptoms and irritation. We discussed a GP multifocal with an optimized fit and edge profile as an option but ultimately decided on a scleral multifocal with Tangible Hydra-PEG (Tangible Science) to avoid desiccation and microtrauma at the limbus and to attempt to reduce the dry eye symptoms.

We recommended she start using lubricating eye drops regularly in each eye as well as a preservative-free, hydrogen-peroxide-based care system for her new lenses.

Ultimately, this patient was excited at the prospect of improved comfort and having her near vision restored. Her visit was a nice reminder that contact lens patients do require annual evaluations, regardless of whether they say they are doing fine or not. Very often, further questioning and an in-office evaluation of the anterior segment reveals problems we have the capability to solve with new (or old) technology. **RCLE**

1. Grohe RM, Lebow KA. Vascularized Limbal Keratitis. *Int Contact Lens Clin.* 1989;16(7):197-209.

2. Zhao Z, Naduvilath T, Flanagan JL, et al. Contact lens deposits, adverse responses and clinical ocular surface parameters. *Optom Vis Sci.* 2010;87(9):669-74.

3. Boston Simplus Multi Action Solution [package insert]. Bausch + Lomb; 2019.

4. Wu YT, Zhu H, Willcox M, Stapleton F. The effectiveness of various cleaning regimens and current guidelines in contact lens case biofilm removal. *Invest Ophthalmol Vis Sci.* 2011;52(8):5287-92.

5. Goto T, Zheng X, Gibbon L, Ohashi Y. Cosmetic product migration onto the ocular surface: exacerbation of migration after eyedrop instillation. *Cornea.* 2010;29(4):400-3.

6. How long does makeup last? L'Oréal Paris USA. www.lorealparisusa.com/beauty-magazine/makeup/makeup-looks/does-makeup-expire.aspx. Accessed October 2, 2020.

Fit the Patient, Not the Diagnosis

Carefully consider each contact lens wearer's needs to ensure the right fit.

Considering a patient's contact lens options based solely on their diagnosis is easy. While this may result in acceptable fits for a reasonable percentage of patients, each patient deserves individualized care despite what might be a common condition. This is especially evident with irregular cornea patients, where one size does not fit all. This case looks at a rarely used lens option in keratoconus fitting, a bitoric corneal gas permeable, and illustrates why this specific design presented the best contact lens option for this particular patient.

THE CASE

A 54-year-old Hispanic male was referred for a contact lens evaluation by his corneal specialist. The patient was diagnosed with keratoconus in his mid-teens and was first prescribed polymethyl methacrylate contact lenses and, later, gas permeable contact lenses. He struggled with decreased wear time and discomfort in the left eye while wearing his gas permeable contact lenses, which had worsened over the past several years to the point where he discontinued lens wear about two months prior to the appointment.

A manifest refraction of -6.50-3.75x015D OD and -6.50-4.25x170D OS yielded distance visual acuities of 20/30-2 OD and 20/20-2 OS. Corneal findings consistent with mild keratoconus demonstrated a Fleischer ring, apical thinning and Vogt's striae in both eyes. Fortunately, no corneal scarring was present in either eye.

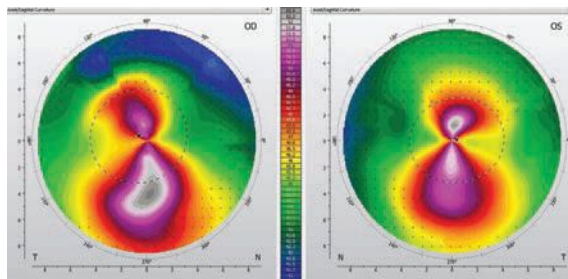


Fig. 1. Note the relatively symmetrical, with-the-rule astigmatic pattern in the left eye.

Topography displayed an asymmetric with-the-rule appearance with more asymmetry and axis variance in the right eye than the left. Centrally, the left eye was fairly regular (*Figure 1*). Elevation maps displayed a fairly common inferior depression below the cone of the right eye. The left eye, however, displayed a relatively symmetrical elevation map with comparable superior and inferior depression (*Figure 2*).

I discussed contact lens options with the patient with a particular emphasis on corneal gas permeable, hybrid, scleral and custom soft lenses. The patient was reluctant to consider options beside corneal gas permeable lenses, as he felt he would have difficulty adjusting to the change.

DIAGNOSTIC FITTING

I trialed a gas permeable keratoconus design with a moderate-sized diameter on each eye. In the right eye, a diagnostic lens of -3.00D, base curve radius of 6.96mm and overall diameter of 9.50mm helped achieve a

central three-point-touch pattern. I observed excess inferior edge lift and ordered a lens with inferior tuck, or quadrant-specific inferior steepening, to lessen inferior edge lift and aid centration. An over-refraction of -4.50D provided 20/20 vision in the right eye.

In the left eye, I had difficulty identifying a lens with an acceptable fluorescein pattern and centration. I observed an evident with-the-rule fluorescein pattern (i.e., bearing along the horizontal meridian, clearance along the vertical meridian), as well as excess movement with blink and inferior decentration. While steepening the base curve improved alignment in the horizontal meridian, it created excess clearance along the vertical meridian. Based on the fluorescein pattern observed with the spherical lens and the relative symmetry observed in both the topography and elevation maps, a toric back-surface lens was preferable.

I used diagnostic fitting information to determine the right lens parameters and ordered the left lens empirically. The right lens had a power of -7.25D, base curve radius of 6.96mm, overall diam-

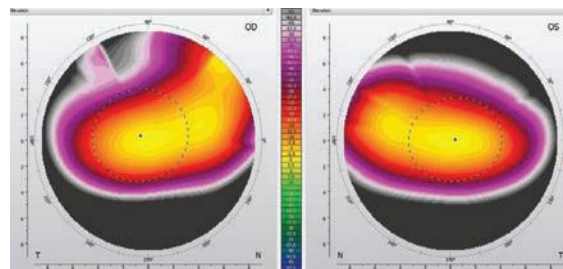


Fig. 2. Symmetrically superior and inferior depression is evident in the left eye.



eter of 9.50mm, standard edge lift and two steps of inferior edge tuck. The left lens had a power of -5.75/-8.50D, base curve radius of 44.25/47.75mm, overall diameter of 9.50mm and axial edge lift of 0.12mm.

DISPENSING

With the ordered lenses, distance visual acuities were 20/20 OD, OS and OU. Slit-lamp evaluation of the right lens displayed a central three-point-touch pattern and average/uniform edge lift. The inferior edge lift had improved as a result of the inferior tuck. The left eye's lens was centered and displayed a three-point-touch pattern with a feathered touch centrally that increased to paracentral clearance and returned to a mid-peripheral touch pattern (*Figure 3*). I deemed the edge lift inadequate, so I reordered it with an increase in axial edge lift from 0.12mm to 0.16mm. The new fit was satisfactory, and both lenses were dispensed.

FOLLOW-UP

The patient returned one week later wearing his contact lenses. He

reported improving comfort with a gradual return to lens wear. He also noted excellent vision and equal comfort between the right and left eyes. Distance visual acuities were 20/20 OD, OS and OU. The corneal surface was intact and tolerating lens wear adequately.

At the six-month follow-up, the patient had increased lens wear from 12 to 16 hours each day with excellent vision and equal comfort in both eyes. The corneal surface remained intact, and topography showed stable results in each eye.

DISCUSSION

Several options exist when fitting patients with keratoconus, including corneal gas permeable, hybrid, scleral and custom soft lenses. Within the family of corneal gas permeable lenses, clinicians can achieve successful fitting relationships in a wide range of diameters, depending on the size and location of the cone. Smaller and more central cones may benefit from smaller-diameter lenses, while lower or larger cones may see improved fits with larger-diameter or intralimbal designs.¹

Due to the anterior surface

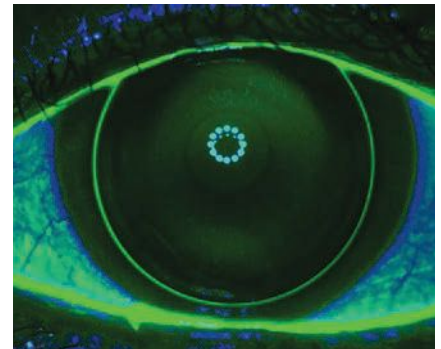


Fig. 3. This bitoric lens has a central three-point-touch fluorescein pattern.

irregularity typically present in keratoconus, bitoric lenses are rarely applicable. For a bitoric to be considered, a high degree of inferior/superior symmetry must be present. In addition, a bitoric lens performs best when the principal meridians of the eye are located 90° apart.

To help you visualize these two criteria, imagine a figure eight. Comparing the size and shape of the top and bottom of the pattern helps to reveal its symmetry. If the principal meridians are not 90° apart, the pattern will be skewed so the top and bottom of the figure eight don't stack directly on top of each other (*Figure 4*).

For the patient in this case, each eye dictated its own lens design. The more asymmetric right eye was able to achieve a fit in a moderate-diameter, keratoconus-specific corneal lens. Due to the toric yet symmetrical nature of the left cornea, a back-surface toric lens was necessary to improve centration and the central fitting relationship. By considering the individual characteristics of each eye, clinicians can create clear and comfortable contact lenses. **RCCL**

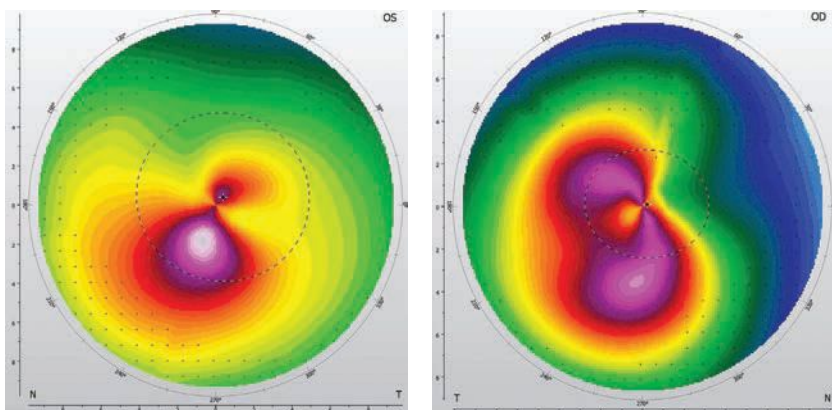


Fig. 4. Superior-inferior asymmetry (left) and principal meridian variance.

1. Bennett ES, Henry VA. *Clinical Manual of Contact Lenses*. Wolters Kluwer; 2020.

A NEW ERA of Keratoconus Care

Learn how advances in diagnostics and treatment
are turning the old paradigm on its head.

By John D. Gelles, OD, Peter S. Hersh, MD, and Steven A. Greenstein, MD

The modern management of keratoconus can best be characterized by four directives: (1) diagnose early, (2) monitor often, (3) stop progression and (4) improve vision. Significant advances are changing the way we approach each of these four aspects of care. Here, we review many innovations impacting the clinical approach to keratoconus, including advanced diagnostics with corneal topography, optical coherence tomography (OCT) and wavefront aberrometry. New approaches to therapy include corneal collagen crosslinking (CXL) and specialty contact lenses, to name a few.

DIAGNOSE AND MONITOR

Our ability to diagnose and monitor keratoconus has improved tremendously in recent decades. The traditional Amsler-Krumeich keratoconus classification system, established in 1946, is based on a combination of pachymetry, slit lamp findings, central keratometry and refraction.¹ However, today's diagnostic workup includes far more than those four metrics of the 1940s. No currently agreed upon classification system

has been established to account for the rapid evolution in device technology, but the traditional Amsler-Krumeich classification system is long due for an update.

Here at the Cornea and Laser Eye Institute (CLEI), we analyzed approximately 1,200 eyes with keratoconus to understand baseline characteristics and explore findings that may suggest the need for further testing. The preliminary analysis suggests the Amsler-Krumeich exaggerates the level of myopia and, because it uses central keratometry, misses the true severity of the disease. The data indicates these patients are in need of further testing to rule out keratoconus.

The advent of corneal topography provided new metrics for reviewing cornea curvature and symmetry.² We now rely on several topographic metrics to diagnose keratoconus. Some of the earliest suggested are:^{3,4}

- Keratometry values greater than 47.0D.
- Axis skew between the steepest superior and inferior semi-meridians of greater than 20° with greater than 1.5D of corneal astigmatism.

ABOUT THE AUTHORS



Dr. Gelles is the director of the specialty contact lens division at the Cornea and Laser Eye Institute (CLEI)-Hersh Vision Group and the CLEI Center for Keratoconus in Teaneck, NJ. He is also a clinical assistant professor in the Department of Ophthalmology at Rutgers New Jersey Medical School in Newark, NJ.

Disclosures: Glaukos, BostonSight, Bausch + Lomb, Gas Permeable Lens Institute, International Keratoconus Academy, Scleral Lens Education Society, Synergeyes, Visionary Optics.



Dr. Hersh is the director of the CLEI-Hersh Vision Group and CLEI Center for Keratoconus. He is also a clinical professor in the Department of Ophthalmology at Rutgers New Jersey Medical School and a visiting research collaborator in the Department of Aerospace and Mechanical Engineering at Princeton University in Princeton, NJ.

Disclosures: Glaukos.



Dr. Greenstein is a cornea and refractive surgeon at the CLEI-Hersh Vision Group and CLEI Center for Keratoconus. He is also a clinical assistant professor in the Department of Ophthalmology at Rutgers New Jersey Medical School.

Disclosures: none.

- Inferior to superior (I-S) keratometry value differences greater than 1.4D on an axial curvature map.

These individual metrics then led to the development of multifactor metrics that can provide higher levels of diagnostic specificity and sensitivity.⁵⁻⁸

Corneal tomography added information about global corneal pachymetry and anterior and posterior corneal elevation. Diagnostic metrics derived from tomography include: thinnest pachymetry less than 500µm, anterior elevation greater than 10µm to 15µm and posterior elevation greater than 15µm to 20µm.⁹⁻¹¹

In addition, an impressive array of device-specific multifactor algorithms are available for early detection, monitoring and classification, all of which are highly sensitive and specific for diagnosing keratoconus and monitoring for progression.^{7,12-16}

Clinicians can now analyze individual corneal layers with ultra high-resolution ultrasound and OCT. Epithelial remodeling in keratoconus, thinning of the epithelium over the cone and epithelial thickening around the base have all been well documented and have diagnostic value.¹⁷⁻¹⁹

One study suggests maximum and minimum epithelial thickness greater than 16.3µm and pattern standard deviations of greater than 0.057 are highly specific and sensitive for early keratoconus detection.²⁰ When comparing normal corneas with forme fruste keratoconus corneas, researchers found significant epithelial thickness differences despite having no differences in corneal topography.²¹ This thinning also affects Bowman's layer. Other researchers used an enhanced OCT algorithm to visu-

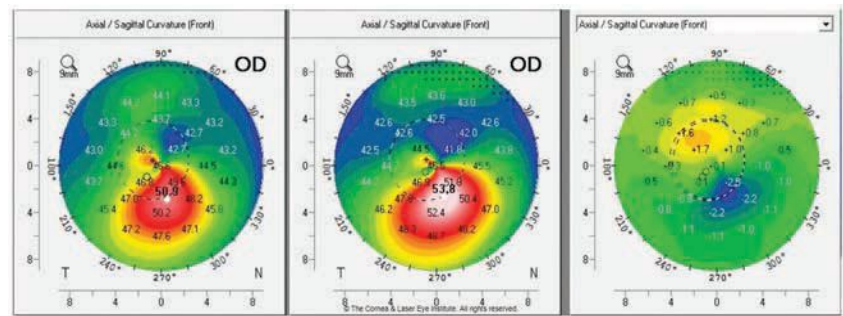


Fig. 1a. These axial curvature topography maps display differences (right) in pre-op curvature (center) to one-year post-op curvature (left). This cornea shows flattening of the corneal apex, consistent with the dioptric change reported in the literature one year after standard CXL.

alize Bowman's layer and found statistically significant inferior thinning compared with a normal cornea.²² These same changes in Bowman's layer thickness are found in global pachymetry measurements.²³

The missing link has always been in measuring corneal biomechanics, another area of diagnostic innovation. Infrared sensor-based, waveform-derived biomechanical data can differentiate normal from grossly abnormal. Outside of the United States, highly sensitive and specific data has been derived from Scheimpflug-based biomechanical data and has become common practice for evaluating corneal biomechanics.^{24,25} This technology

captures ultra high-speed video of the corneal deformation under applanation and analyzes the amplitudes and temporal qualities.

Two new tools, OCT elastography and Brillouin, have mostly been used in laboratory and research settings, although both are currently under development for clinical applications. Research with OCT elastography shows the depth-related strength of cornea tissue; in normal corneas, anterior strength is higher than the posterior. By contrast, keratoconus corneas have a loss of anterior biomechanical strength.²⁶

Waveform-derived biomechanical metrics in their current forms give global corneal biomechanics and

are not completely location specific; therefore, a weakness in a specific point of the cornea cannot be pinpointed; however, it can with elastography and Brillouin microscopy. This has become particularly important now that research shows CXL can increase anterior corneal strength.²⁷

Brillouin derives focal metrics throughout the cornea by analyzing photonic shifts and can be targeted to any focal point in the corneal tissue. Researchers have found that the weakness of the corneal tissue in keratoconus is focal to the cone location, while the

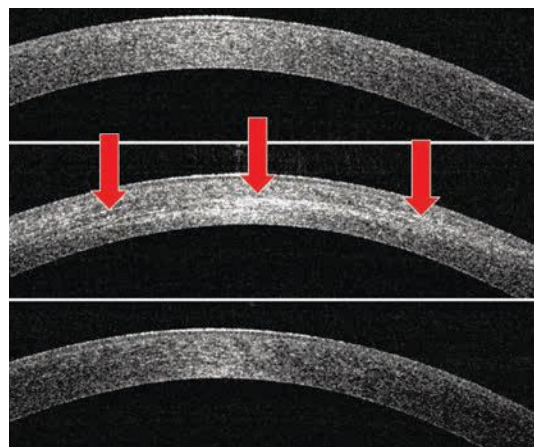


Fig. 1b. Corneal OCT shows the development of corneal haze from the pre-op (top) to one month post-op (middle). Note the presence of the demarcation line (red arrows), then resolution of corneal haze from the one-month post-op to the 12-month post-op (bottom).

On the Rise or Better Identified?

The diagnostic evolution in keratoconus may have led, in part, to the increased prevalence of keratoconus reported over the past several years. The commonly quoted prevalence, approximately 1:2,000, came from a 1998 review and has been challenged by more recent studies.¹ Now, research suggests an approximate prevalence of keratoconus of 1:725 worldwide.² More specific population studies suggest a prevalence of 1:375 in the Netherlands, 1:191 in New Zealand adolescents, 1:45 in a sub-analysis of the New Zealand Maori population and 1:84 in Australia, the last of which was based on Scheimpflug tomography.³⁻⁵

1. Rabinowitz YS. Keratoconus. *Surv Ophthalmol.* 1998;42:297-319.

2. Hashemi H, Heydarian S, Hooshmand E, et al. The prevalence and risk factors for keratoconus: a systematic review and meta-analysis. *Cornea.* 2020;39:263-70.

3. Godefrooij DA, de Wit GA, Uiterwaal CS, et al. Age-specific incidence and prevalence of keratoconus: a nationwide registration study. *Am J Ophthalmol.* 2017;175:169-72.

4. Papali'i-Curtin AT, Cox R, Ma T, et al. Keratoconus prevalence among high school students in New Zealand. *Cornea.* 2019;38:1382-9.

5. Chan E, Chong EW, Lingham G, et al. Prevalence of keratoconus based on Scheimpflug imaging: The Raine Study. *Ophthalmology.* 2020;S0161-6420(20):30838-1.

rest of the cornea displays properties like those of a normal cornea.²⁸⁻³⁰

However, with measurement of such small shifts, patient movement can affect Brillouin results.

Wavefront aberrometry is another helpful tool when evaluating for keratoconus. The type and extent of higher-order aberrations can be used as a proxy to detect early optical changes in keratoconus. Studies show a significant difference between normal, suspect and keratoconic corneas in total, 3rd, 4th and 5th orders of aberrations, and total, coma (vertical coma, specifically) and trefoil have the most statistically significant differences.^{31,32}

In combined topographer and aberrometer devices, the ray trace-derived corneal aberrometry can be compared with the total ocular aberration to determine the source,

whether it's the corneal surface or an internal aberration. One study noted that the combination of topography and aberrometry was more than 95% sensitive and specific.³³

Others found the specific combination of I-S value from topography and vertical coma from aberrometry was highly statistically significant.³⁴

Although combination metrics can help clinicians better detect and monitor keratoconus, many devices are unable to communicate with or combine data from other devices. New devices available outside the United States are able to combine the data derived from Scheimpflug tomography with Scheimpflug biomechanics to review risk factors and provide an ectasia risk score.³⁵

Using the power of artificial intelligence, researchers developed an algorithm capable of diagnosing and classifying keratoconus with high sensitivity and specificity, without being device- or manufacturer-specific—meaning it could be applied to any device.³⁶ Researchers have also used a convolutional neural network to analyze tomography and found 100% sensitivity and specificity for classification of keratoconus.³⁷

Genetic testing for keratoconus in a clinically impactful capacity, while in its infancy, is an exciting possibility. Researchers found an association with chromosome 5 and the lysyl oxidase (LOX) gene that is responsible for the production of lysyl oxidase, which initiates the natural crosslinking of the corneal collagens.³⁸⁻⁴⁰ Studies show decreased levels of LOX in keratoconus corneas compared with the normal cornea.⁴¹

Recently, investigators discovered a genome-wide significant loci that met statistical significance required by genetic standards, located on

chromosome 11 in the region of PNPLA2.⁴² More data will emerge as the commercially available genetic test becomes more widely used, and researchers may find more associations. In the future, this could lead to targeted genetic treatment.

STOP PROGRESSION

CXL, mediated by riboflavin and ultraviolet (UV) light illumination, has been standard of care in Europe to slow the progression of keratoconus since researchers documented its efficacy in 2003.⁴³

In the United States, experience with the procedure began in 2008 with Phase III clinical trials using the standard protocol (central 9mm of epithelium removed followed by a 30-minute riboflavin soak and 30-minute illumination of 365nm UV wavelength at 3mW/cm² for a total energy of 5.4J/cm²). The treatment was effective in slowing the progression of keratoconus, resulting in the 2016 FDA-approval of the KXL UV illumination device (Glaukos) and two riboflavin formulations (Photrexa and Photrexa viscous, Glaukos).^{28,44}

Many manuscripts have been published by CLEI describing the clinical time course and efficacy of the standard CXL treatment.^{29,30,45-51} The important observations in the treatment group focused on visual acuity, maximum keratometry and transient corneal haze with a demarcation line.^{29,45,46} We found that these metrics are initially worse at the one-month post-op and improve, on average, to better than baseline over the first year (*Figures 1a and 1b*). These studies also show an excellent safety profile (only one severe adverse event), an improvement in subjective patient-reported vision and no significant change (i.e., damage or loss of cell density) to the endothelial cells.^{44,47}

Many variations to the procedure

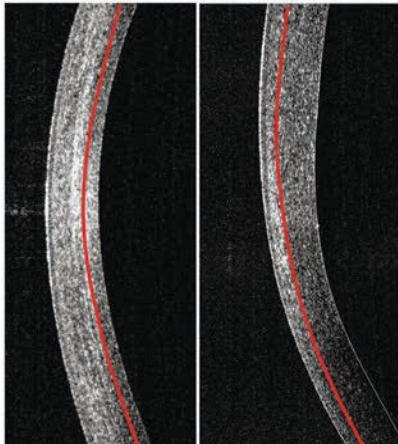


Fig. 2. Comparison of corneal haze and demarcation line depth at the one-month follow-up. The standard CXL procedure (left) produces a more profound haze with a deeper demarcation line depth than the epi-on CXL procedure (right).

are continuously under development, and researchers are exploring innovations within each of three necessary components of crosslinking: riboflavin, UV light and oxygen. For instance, we recently published a study looking at different osmolarities to keep corneal thickness more consistent throughout the procedure. Our hypotonic riboflavin study showed no difference in efficacy when comparing the standard protocol with dextran-containing riboflavin but did show the ability to maintain a thicker stroma during UV illumination.⁵²

One technique of interest is transepithelial, or epi-on, CXL. The current US literature shows a less robust effect compared with the standard CXL procedure.^{53,54} Our center's data shows less corneal flattening after the procedure and less haze formation with a shallower demarcation line (Figure 2).⁵⁴⁻⁵⁶ Still, the procedure doesn't seem to create the temporary worsening of outcome metrics at the one-month mark. This may be due to an intact epithelium, which does not undergo epithelial remodeling, or simply because it is a less effective treatment.

Various riboflavin formulations have been studied internationally, and most include additives to the riboflavin, such as benzalkonium chloride, to create faster and more complete penetration through intact epithelium.^{52,54} Others have changed riboflavin concentrations and additives to change the osmolarity.

The riboflavin delivery method is under investigation as well, and researchers are working on ways to soak the cornea by a fluid retention ring well or plectet, methods to speed up the saturation process (e.g., with iontophoresis) and ways to keep the epithelium anchored but disrupted, such as epithelium disruptor instruments or femto laser microchannels, for easier penetration.^{57,58}

One recently developed delivery system increases riboflavin retention time on the corneal surface, shortening time to full corneal saturation, and another uses a scleral lens filled with riboflavin that has an internal illumination system to complete the CXL procedure.^{59,60} CLEI is currently analyzing a method of scleral lens-based riboflavin delivery compared with traditionally applied drops.

As for UV illumination, most innovations focus on accelerating the procedure by increasing the power and reducing the illumination duration. While these accelerated treatments maintain the overall energy dose of 5.4J/cm², they produce shallower stromal demarcation lines and seem to be less effective in some studies.^{61,62}

Pulsing the UV illumination remains under investigation and allows for more oxygen to regenerate, which is a vital and rate-limiting component in the production of crosslinks.⁶³

Another modification is the delivery of a topography guided CXL treatment with multi-energy focal UV illumination. This approach more focally treats the weaker cone region of the cornea by customizing the position, zone and energy applied, thus creating focally deep demarcation lines and greater corneal curvature flattening.⁶⁴

In the United States, an ongoing Phase III epi-on CXL clinical trial combines several of these new approaches. The procedure uses riboflavin formulated to penetrate intact the epithelium, a pulsed and accelerated application of UV light and oxygen supplementation provided by specialized goggles. Though formal data is not yet available, researchers reported a prominent corneal curvature change, more oxygen availability to the cornea and increased tissue strength *ex-vivo*.⁶⁵

Treatment with CXL can be difficult with thin corneas; thus, researchers are exploring techniques to make the procedure possible for these patients. The use of a non UV-blocking contact lens soaked in riboflavin and corneal tissue lenticule on-lays to create artificial thickness are two possibilities.^{66,67} Customized time and fluence is another variation that uses the demarcation lines to

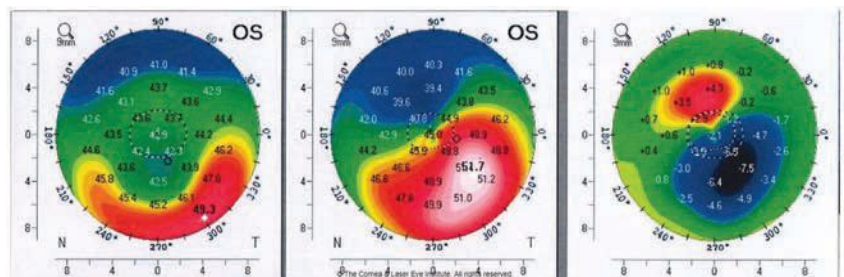


Fig 3. These axial curvature topography maps show the differences (right) in pre-op curvature (center) to six months post-op TGPRK (left) curvature.

A NEW ERA OF KERATOCONUS CARE

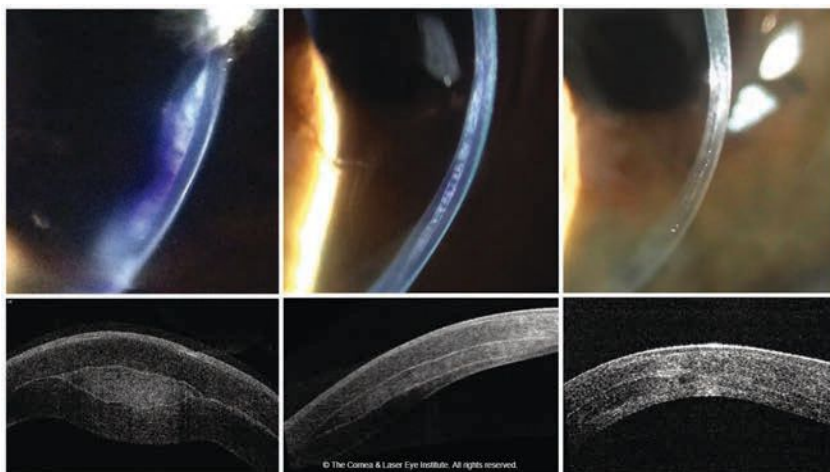


Fig. 4. These images show the optic section and corneal OCT of post-op allograft corneal tissue implantation for keratoconus, immediately post-op (left), one month post-op (middle) and 18 months post-op (right).

create a time-related model whereby less time will result in a shallower treatment for thinner corneas.^{68,69}

Still others have used rose bengal and green light illumination to induce crosslinking, known as RGX. This treatment results in a very shallow demarcation line and a small increase in anterior corneal strength based on Brillouin.^{55,70}

Even newer CXL treatments, such as dual photon femtosecond laser, forgo photosensitizers altogether. Femtosecond lasers that use a sub-cavitation level of energy crosslink tissue rather than cleave it.⁷¹ The benefits could include improved precision and reduced treatment duration.

Another non-photosensitizing treatment option is the use of topical LOX supplementation. In a Phase I/II-a study, investigators found approximately 1.00D of flattening in the treatment group, while the control group progressed by approximately 0.46D.⁷²

IMPROVE VISION

The opportunity to strengthen the cornea with CXL has opened new avenues of surgical keratoconus management. In addition to traditional corneal transplant, such as

penetrating keratoplasty or deep anterior lamellar keratoplasty, subtractive and additive procedures are showing promise, as are custom scleral contact lenses.

Subtractive procedures. Excimer and femtosecond laser technology modifies corneal shape by subtracting or removing corneal tissue. During the evolution of these lasers and procedures, anatomical and optical data derived from topography and aberrometry helped to create custom ablation profiles to optimize refractive results in normal corneas.

Many of these same technologies can be applied to the keratoconic cornea to re-sculpt corneal curvature, with the goal of improving symmetry and total aberrations and creating partial refractive correction.

Guided ablations, whether topographically or wavefront-guided, have been pioneered outside of the United States where more customizable ablations have been available for some time. Research shows improvements in curvature and visual acuity with wavefront-guided ablations combined with CXL, and even ten-year data shows stability of keratometry and visual acuity after concurrent CXL with topography guided ablations.^{73,74}

In the United States, patients treated with CXL first and then topography guided photorefractive keratectomy (PRK) several months later experienced improved topography measures and visual acuity.⁷⁵

In our center, we found transepithelial topography-guided PRK (TGPRK) is capable of improving uncorrected visual acuity by approximately four lines and one to two lines of best-corrected spectacle visual acuity (Figure 3).

Additionally, this can be used in patients after intracorneal ring segments (ICRS) to improve outcomes and enhance visual acuity postoperatively. Furthermore, a sequential treatment with TGPRK first, for the purpose of improving corneal symmetry, can allow for improved outcomes with intraocular and implantable collamer lens-based procedures by allowing for improved biometry measurement and decreased corneal aberrations postoperatively.

Additive procedures. Recently, randomized prospective trials out of our center and abroad show ICRS procedures can be safely performed concurrently with CXL and that single segments seem best.⁷⁶ However, the corneal biocompatibility of PMMA placed at 70% to 80% depth in the cornea can occasionally present a problem. We found a 2.5% rate of ICRS explantation due to medical complications.⁷⁷ Thus, allograft and even xenograft corneal tissue inlays may be the future materials of choice.⁷⁸⁻⁸¹

Since 2016, CLEI has had an open clinical trial for implantation of e-beam sterilized allogeneic stroma, which is shaped on the femtosecond and excimer lasers and implanted into the cornea via femto laser pocket or channel. This work has shown large changes in corneal curvature (flattening of up to approximately 20.0D) and excellent biocompatibility (Figure 4).



“ I didn't realize
STARS
were little dots that twinkled ”

—Misty L, *RPE65* gene therapy recipient

**WE'RE SEEING
AMAZING RESULTS.
AND SO ARE THEY.**

At the Foundation Fighting Blindness our mission is everybody's vision. Our work shines a light on the darkness of inherited retinal diseases (IRDs).

We're the world's leading organization searching for treatments and cures. We need your help to fuel the discovery of innovations that will illuminate the future for so many. We have robust disease information, a national network of local chapters and support groups, local educational events, and our My Retina Tracker® Registry to help keep your patients connected with clinical and research advancements.

Help accelerate our mission
by donating at ECPs4Cures.org.

**FOUNDATION
FIGHTING
BLINDNESS**

FightingBlindness.org

A NEW ERA OF KERATOCONUS CARE

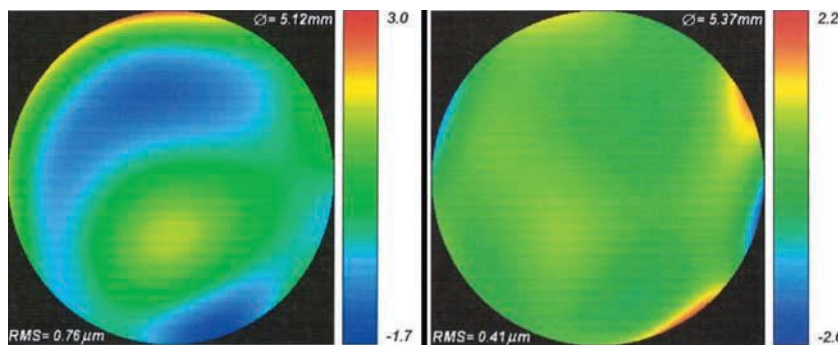


Fig 5. These are the total higher-order aberration maps of an eye of a patient with severe keratoconus while wearing a scleral lens. The map of total aberrations while wearing the final scleral lens corrected with spherical optics and a plano over-refraction (left) is compared with the final customized higher-order aberration correcting optics (right). A 46% reduction of total higher-order root mean square values was observed, translating to one to two lines of visual acuity improvement.

Contact lenses. These innovations, especially scleral lenses, have progressed by leaps and bounds. Profilmometry devices, capable of measuring the ocular surface up to 22mm in coverage, are providing a deeper understanding of the contour of the scleral surface, with one study suggesting the scleral contour is mostly asymmetric.⁸²

These same devices are now enabling freeform lenses. At CLEI, we analyzed approximately 560 eyes fit with scleral lenses and found that it took fewer lenses to achieve a final fit with impression-based lenses compared with profilmometry/scan-based lenses and diagnostically fit lenses. Though this is prepublication data, it shows the trend that technology can improve the fitting process.

Research shows sclerals with optimized optical profiles can improve high and low contrast visual acuity with the addition of front surface eccentricity.⁸³ Higher-order aberration correction on scleral lenses has been studied as well. The literature shows a 43% reduction in higher-order root mean square values with wave-front-guided optics for patients with ectasia.⁸⁴ Others found these values decreased from 1.17 μ m to 0.37 μ m, a 68% reduction, and a mean of 1.9 lines of visual improvement.⁸⁵

This approach to scleral lens design is starting to make its way into clinical practice and is showing promise at our center (Figure 5).

Advances in diagnostic imaging and therapy have already changed the keratoconus care paradigm for the better with earlier diagnosis and more effective treatment. As newer innovations move from the lab to the clinic, they will further improve our understanding of the disease process and help us better care for these patients. Until then, today's technologies give practitioners the tools they need to diagnose early, monitor often, stop progression, and improve vision. RCCL

1. Amsler M. Classic keratocone and crude keratocone; Unitary arguments. *Ophthalmologica*. 1946;111:96-101.
2. Klyce SD. Computer-assisted corneal topography. High-resolution graphic presentation and analysis of keratometry. *Invest Ophthalmol Vis Sci*. 1984;25:1426-35.
3. Wilson SE, Lin DT, Klyce SD. Corneal topography of keratoconus. *Cornea*. 1991;10:2-8.
4. Rabinowitz YS. Videokeratographic indices to aid in screening for keratoconus. *J Refract Surg*. 1995;11:371-9.
5. Rabinowitz YS, Rasheed K. KISA% index: a quantitative videokeratography algorithm embodying minimal topographic criteria for diagnosing keratoconus. *J Cataract Refract Surg*. 1999;25:1327-35.
6. Maeda N, Klyce SD, Smolek MK, Thompson HW. Automated keratoconus screening with corneal topography analysis. *Invest Ophthalmol Vis Sci*. 1994;35:2749-57.
7. Zhang X, Munir SZ, Sami Karim SA, Munir WM. A review of imaging modalities for detecting early keratoconus. *Eye (Lond)*. July 16, 2020. [Epub ahead of print].

8. McMahon TT, Szczołka-Flynn L, Barr JT, et al. A new method for grading the severity of keratoconus: the Keratoconus Severity Score (KSS). *Cornea*. 2006;25:794-800.
9. Martinez-Abad A, Pinero DP. New perspectives on the detection and progression of keratoconus. *J Cataract Refract Surg*. 2017;43:1213-27.
10. Uçakhan Ö, Cetinkor V, Özkan M, Kanpolat A. Evaluation of Scheimpflug imaging parameters in subclinical keratoconus, keratoconus, and normal eyes. *J Cataract Refract Surg*. 2011;37:1116-24.
11. Miháltz K, Kovács I, Takács A, Nagy ZZ. Evaluation of keratometric, pachymetric, and elevation parameters of keratoconic corneas with pentacam. *Cornea*. 2009;28:976-80.
12. Duncan JK, Belin MW, Borgstrom M. Assessing progression of keratoconus: novel tomographic determinants. *Eye Vis (Lond)*. 2016;3:6.
13. Belin MW, Duncan JK. [Keratoconus: The ABCD grading system]. *Klin Monbl Augenheilkd*. 2016;233:701-7.
14. Moshirfar M, Motlagh MN, Murri MS, et al. Galilei corneal tomography for screening of refractive surgery candidates: a review of the literature, Part II. *Med Hypothesis Discov Innov Ophthalmol*. 2019;8:204-18.
15. Motlagh MN, Moshirfar M, Murri MS, et al. Pentacam(R) corneal tomography for screening of refractive surgery candidates: a review of the literature, Part I. *Med Hypothesis Discov Innov Ophthalmol*. 2019;8:177-203.
16. Shetty R, Rao H, Khamar P, et al. Keratoconus screening indices and their diagnostic ability to distinguish normal from ectatic corneas. *Am J Ophthalmol*. 2017;181:140-8.
17. Reinstein DZ, Archer TJ, Gobbe M. Corneal epithelial thickness profile in the diagnosis of keratoconus. *J Refract Surg*. 2009;25:604-10.
18. Reinstein DZ, Gobbe M, Archer TJ, et al. Epithelial, stromal, and total corneal thickness in keratoconus: three-dimensional display with artemis very-high frequency digital ultrasound. *J Refract Surg*. 2010;26:259-71.
19. Silverman RH, Urs R, RoyChoudhury A, et al. Combined tomography and epithelial thickness mapping for diagnosis of keratoconus. *Eur J Ophthalmol*. 2017;27:129-34.
20. Li Y, Chamberlain W, Tan O, et al. Subclinical keratoconus detection by pattern analysis of corneal and epithelial thickness maps with optical coherence tomography. *J Cataract Refract Surg*. 2016;42:284-95.
21. Temstet C, Sandali O, Bouheraoua N, et al. Corneal epithelial thickness mapping using Fourier-domain optical coherence tomography for detection of form fruste keratoconus. *J Cataract Refract Surg*. 2015;41:812-20.
22. Abou Shousha M, Perez VL, Fraga Santini Canto AP, et al. The use of Bowman's layer vertical topographic thickness map in the diagnosis of keratoconus. *Ophthalmology*. 2014;121:988-93.
23. Pircher N, Beer F, Holzer S, et al. Large field of view corneal epithelium and Bowman's layer thickness maps in keratoconic and healthy eyes. *Am J Ophthalmol*. 2020;209:168-77.
24. Steinberg J, Frings A, Mousli A, et al. New Scheimpflug dynamic in vivo curve analyses to characterize biomechanical changes of the cornea after cross-linking for progressive keratoconus. *J Refract Surg*. 2016;32:34-9.
25. Vinciguerra R, Romano V, Arbabi EM, et al. In vivo early corneal biomechanical changes after corneal cross-linking in patients with progressive keratoconus. *J Refract Surg*. 2017;33:840-6.
26. Vinciguerra R, Romano V, Arbabi EM, et al. In vivo early corneal biomechanical changes after corneal cross-linking in patients with progressive keratoconus. *J Refract Surg*. 2017;33:840-6.

27. Blackburn BJ, Gu S, Ford MR, et al. Non-invasive assessment of corneal crosslinking with phase-decorrelation optical coherence tomography. *Invest Ophthalmol Vis Sci.* 2019;60:41-51.
28. Hersh PS, Stulting RD, Muller D, et al. U.S. multicenter clinical trial of corneal collagen crosslinking for treatment of corneal ectasia after refractive surgery. *Ophthalmology.* 2017;124:1475-84.
29. Greenstein SA, Fry KL, Bhatt J, Hersh PS. Natural history of corneal haze after collagen crosslinking for keratoconus and corneal ectasia: Scheimpflug and biomicroscopic analysis. *J Cataract Refract Surg.* 2010;36:2105-14.
30. Greenstein SA, Fry KL, Hersh PS. Corneal topography indices after corneal collagen crosslinking for keratoconus and corneal ectasia: one-year results. *J Cataract Refract Surg.* 2011;37:1282-90.
31. Lim L, Wei RH, Chan WK, Tan DT. Evaluation of higher order ocular aberrations in patients with keratoconus. *J Refract Surg.* 2007;23:825-8.
32. Kosaki R, Maeda N, Bessho K, et al. Magnitude and orientation of Zernike terms in patients with keratoconus. *Invest Ophthalmol Vis Sci.* 2007;48:3062-8.
33. Saad A, Gatinel D. Combining placido and corneal wavefront data for the detection of forme fruste keratoconus. *J Refract Surg.* 2016;32:510-6.
34. Jafri B, Li X, Yang H, Rabinowitz YS. Higher order wavefront aberrations and topography in early and suspected keratoconus. *J Refract Surg.* 2007;23:774-81.
35. Ferreira-Mendes J, Lopes BT, Faria-Correia F, et al. Enhanced ectasia detection using corneal tomography and biomechanics. *Am J Ophthalmol.* 2019;197:7-16.
36. Jimenez-Garcia M, Ni Dhubghaill S, Koppen C, et al. Baseline findings in the Retrospective Digital Computer Analysis of Keratoconus Evolution (REDCAKE) Project. *Cornea.* June 10, 2020. [Epub ahead of print].
37. Zéboulon P, Debellemanière G, Bouvet M, Gatinel D. Corneal topography raw data classification using a convolutional neural network. *Am J Ophthalmol.* 2020;219:33-9.
38. Tang YG, Rabinowitz YS, Taylor KD, et al. Genomewide linkage scan in a multigeneration Caucasian pedigree identifies a novel locus for keratoconus on chromosome 5q14.3-q21.1. *Genet Med.* 2005;7:397-405.
39. Bisceglia L, De Bonis P, Pizzicoli C, et al. Linkage analysis in keratoconus: replication of locus 5q21.2 and identification of other suggestive Loci. *Invest Ophthalmol Vis Sci.* 2009;50:1081-6.
40. Bykhovskaya Y, Li X, Epifantseva I, et al. Variation in the lysyl oxidase (LOX) gene is associated with keratoconus in family-based and case-control studies. *Invest Ophthalmol Vis Sci.* 2012;53:4152-7.
41. Dudakova L, Liskova P, Trojek T, et al. Changes in lysyl oxidase (LOX) distribution and its decreased activity in keratoconus corneas. *Exp Eye Res.* 2012;104:74-81.
42. McComish BJ, Sahebjada S, Bykhovskaya Y, et al. Association of genetic variation with keratoconus. *JAMA Ophthalmol.* 2020;138:174-81.
43. Wollensak G, Spoerl E, Seiler T. Riboflavin/ultraviolet-a-induced collagen crosslinking for the treatment of keratoconus. *Am J Ophthalmol.* 2003;135:620-7.
44. Hersh PS, Stulting RD, Muller D, et al. United States multicenter clinical trial of corneal collagen crosslinking for keratoconus treatment. *Ophthalmology.* 2017;124:1259-70.
45. Greenstein SA, Shah VP, Fry KL, Hersh PS. Corneal thickness changes after corneal collagen crosslinking for keratoconus and corneal ectasia: one-year results. *J Cataract Refract Surg.* 2011;37:691-700.
46. Hersh PS, Greenstein SA, Fry KL. Corneal collagen crosslinking for keratoconus and corneal ectasia: One-year results. *J Cataract Refract Surg.* 2011;37:149-60.
47. Brooks NO, Greenstein S, Fry K, Hersh PS. Patient subjective visual function after corneal collagen crosslinking for keratoconus and corneal ectasia. *J Cataract Refract Surg.* 2012;38:615-9.
48. Greenstein SA, Fry KL, Hersh MJ, Hersh PS. Higher-order aberrations after corneal collagen crosslinking for keratoconus and corneal ectasia. *J Cataract Refract Surg.* 2012;38:292-302.
49. Greenstein SA, Fry KL, Hersh PS. In vivo biomechanical changes after corneal collagen cross-linking for keratoconus and corneal ectasia: 1-year analysis of a randomized, controlled, clinical trial. *Cornea.* 2012;31:21-5.
50. Greenstein SA, Fry KL, Hersh PS. Effect of topographic cone location on outcomes of corneal collagen cross-linking for keratoconus and corneal ectasia. *J Refract Surg.* 2012;28:397-405.
51. Greenstein SA, Hersh PS. Characteristics influencing outcomes of corneal collagen crosslinking for keratoconus and ectasia: implications for patient selection. *J Cataract Refract Surg.* 2013;39:1133-40.
52. Rosenblatt E, Hersh PS. Intraoperative corneal thickness change and clinical outcomes after corneal collagen crosslinking: Standard crosslinking versus hypotonic riboflavin. *J Cataract Refract Surg.* 2016;42:596-605.
53. Stulting RD, Trattler WB, Woolfson JM, Rubinfeld RS. Corneal crosslinking without epithelial removal. *J Cataract Refract Surg.* 2018;44:1363-70.
54. Hersh PS, Lai MJ, Gelles JD, Lesniak SP. Transepithelial corneal crosslinking for keratoconus. *J Cataract Refract Surg.* 2018;44:313-22.
55. Lesniak SP, Hersh PS. Transepithelial corneal collagen crosslinking for keratoconus: six-month results. *J Cataract Refract Surg.* 2014;40:1971-9.
56. M JL, Greenstein SA, Gelles JD, Hersh PS. Corneal haze after transepithelial collagen cross-linking for keratoconus: a Scheimpflug densitometry analysis. *Cornea.* 2020;39:1117-21.
57. Cherfan D, Verter EE, Melki S, et al. Collagen cross-linking using rose bengal and green light to increase corneal stiffness. *Invest Ophthalmol Vis Sci.* 2013;54:3426-33.
58. Bradford S, Mikula E, Xie Y, et al. Enhanced transepithelial riboflavin delivery using femtosecond laser-machined epithelial microchannels. *Transl Vis Sci Technol.* 2020;9:1.
59. Godin M, Hansen M, Reeves S, Hardten D. Use of the keratoflow device in epithelium on corneal collagen crosslinking. *ASCRS* 2019.
60. Batlle L, Rivera CD. Trans-epithelial (epithelium-on) corneal collagen crosslinking using a novel ultraviolet light-emitting contact lens device. 2020. *ASCRS* 2020.
61. Wen D, Li Q, Song B, et al. Comparison of standard versus accelerated corneal collagen cross-linking for keratoconus: a meta-analysis. *Invest Ophthalmol Vis Sci.* 2018;59:3920-31.
62. Spadea L, Di Genova L, Tonti E. Corneal stromal demarcation line after 4 protocols of corneal crosslinking in keratoconus determined with anterior segment optical coherence tomography. *J Cataract Refract Surg.* 2018;44:596-602.
63. Mazzotta C, Traversi C, Paradiso AL, et al. Pulsed light accelerated crosslinking versus continuous light accelerated crosslinking: one-year results. *J Ophthalmol.* 2014;2014:604731.
64. Mazzotta C, Moramarco A, Traversi C, et al. accelerated corneal collagen cross-linking using topography-guided uv-a energy emission: preliminary clinical and morphological outcomes. *J Ophthalmol.* 2016;2016:2031031.
65. Hill J, Liu C, Deardorff P, et al. Optimization of oxygen dynamics, UV-A delivery, and drug formulation for accelerated epi-on corneal crosslinking. *Curr Eye Res.* 2020;45:450-8.
66. Jacob S, Kumar DA, Agarwal A. Reply: To PMID 24972403. *J Refract Surg.* 2014;30:728-9.
67. Cagini C, Riccitelli F, Messina M, et al. Epi-off-lenticule-on corneal collagen cross-linking in thin keratoconic corneas. *Int Ophthalmol.* August 13, 2020. [Epub ahead of print].
68. Caruso C, Epstein RL, Ostacolo C, et al. Customized corneal cross-linking-a mathematical model. *Cornea.* 2017;36:600-4.
69. Hafezi F, Gilardoni F, Kling S, et al. Results of a prospective study using individualized fluence corneal-cross-linking in ultra-thin corneas: the sub400 protocol. *ESCRS* 2020.
70. Germann JA, Martinez-Enriquez E, Martinez-Garcia MC, et al. Corneal collagen ordering after in vivo rose bengal and riboflavin cross-linking. *Invest Ophthalmol Vis Sci.* 2020;61:28.
71. Guo Y, Wang C, Celi N, Vukelic S. Femtosecond laser collagen cross-linking without traditional photosensitizers. *SPIE* 2015.
72. Molokhia S, Muddana SK, Hauritz H, et al. IVMED 80 eye drops for treatment of keratoconus in patients -Phase 1/2a. *Invest Ophthalmol Vis Sci.* 2020;61:2587.
73. Gore DM, Leucci MT, Anand V, et al. Combined wavefront-guided transepithelial photorefractive keratectomy and corneal crosslinking for visual rehabilitation in moderate keratoconus. *J Cataract Refract Surg.* 2018;44:571-80.
74. Kanellopoulos AJ. Ten-year outcomes of progressive keratoconus management with the Athens Protocol (topography-guided partial-refraction PRK combined with CXL). *J Refract Surg.* 2019;35:478-83.
75. Nattis AS, Rosenberg ED, Donnenfeld ED. One-year visual and astigmatic outcomes of keratoconus patients following sequential crosslinking and topography-guided surface ablation: the TOPOLINK study. *J Cataract Refract Surg.* 2020;46:507-16.
76. Hersh PS, Issa R, Greenstein SA. Corneal crosslinking and intracorneal ring segments for keratoconus: A randomized study of concurrent versus sequential surgery. *J Cataract Refract Surg.* 2019;45:830-9.
77. Nguyen N, Gelles JD, Greenstein SA, Hersh PS. Incidence and associations of intracorneal ring segment explantation. *J Cataract Refract Surg.* 2019;45:153-8.
78. Jacob S, Patel SR, Agarwal A, et al. Corneal allogenic intrastromal ring segments (CAIRS) combined with corneal cross-linking for keratoconus. *J Refract Surg.* 2018;34:296-303.
79. van Dijk K, Parker JS, Baydoun L, et al. Bowman layer transplantation: 5-year results. *Graefes Arch Clin Exp Ophthalmol.* 2018;256:1151-8.
80. Jin H, He M, Liu H, et al. Small-incision femtosecond laser-assisted intracorneal concave lenticule implantation in patients with keratoconus. *Cornea.* 2019;38:446-53.
81. Kanellopoulos AJ, Vingopoulos F. Combining porcine xenograft intra-corneal ring segments and CXL: a novel technique. *Clin Ophthalmol.* 2019;13:2521-5.
82. DeNaeyer GSD, Michaud L, Morrison S, et al. Correlation of corneal and scleral topography in cases with ectasias and normal corneas. *J Cont Lens Res Sci.* 2019;3:e10-e20.
83. Hussoin T, Le HG, Carrasquillo KG, et al. The effect of optic asphericity on visual rehabilitation of corneal ectasia with a prosthetic device. *Eye Contact Lens.* 2012;38:300-5.
84. Hastings GD, Applegate RA, Nguyen LC, et al. Comparison of wavefront-guided and best conventional scleral lenses after habituation in eyes with corneal ectasia. *Optom Vis Sci.* 2019;96:238-47.
85. Sabesan R, Johns L, Tomashevskaya O, et al. Wavefront-guided scleral lens prosthetic device for keratoconus. *Optom Vis Sci.* 2013;90:314-23.

Specialty Contact Lenses for the **DISEASED CORNEA**

When fit successfully, these medical devices can be a life-changer for appropriate patients.

By Christopher Lopez, OD

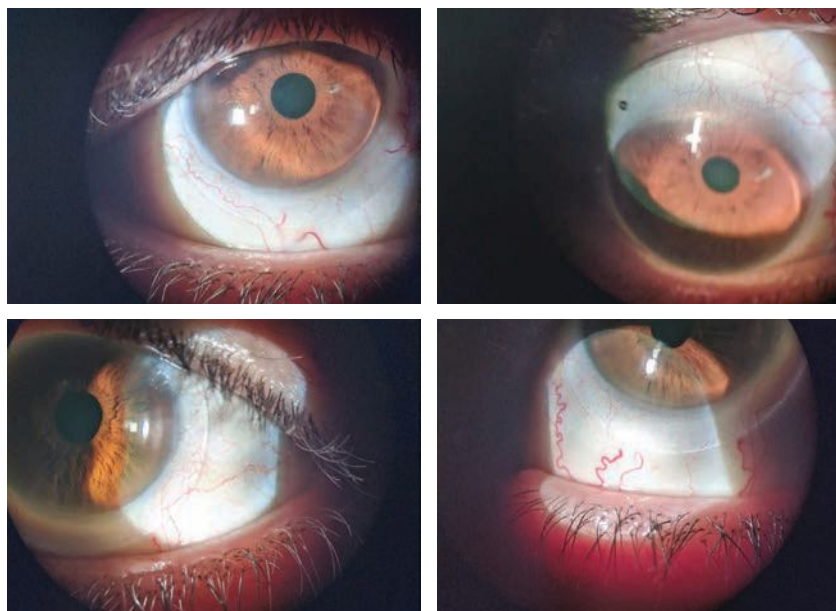
Specialty contact lenses have taken optometry by storm. Although optometrists have been fitting these medical devices for decades, booms in technology, education and training have encouraged more clinicians to use them to enhance the vision, health and well-being of patients.

Each specialty contact lens modality—including rigid gas permeable (GP), hybrid, piggyback and scleral contact lenses—has its own pros and cons and can be applied to a broad array of conditions.¹ For example, GPs can improve visual outcomes in children who suffer from ocular trauma and the quality of life for people with keratoconus.²⁻⁴ Scleral lenses can aid patients with ocular surface disease, combat corneal neovascularization and help treat persistent corneal epithelial defects.⁵⁻⁷

These corneal disease cases and their fitting considerations demonstrate how scleral lenses and GPs can improve patients' livelihoods.

CASE 1: POST-REFRACTIVE SURGERY ECTASIA

A 69-year-old Caucasian female presented for a scleral lens evaluation. She underwent a scleral lens fitting in both eyes four years prior and



The patient in case 1 was fit with scleral lenses (OD on top).

had not been to an eye doctor since. With her lenses in place, she reported discomfort, worsening vision in both eyes and pain upon lens removal.

Ocular history was significant for LASIK and post-refractive surgery ectasia in both eyes. Scleral lenses were initially fit to improve the poor vision that had resulted from the loss of corneal integrity, which is commonly associated with corneal thinning, steepening, a decrease in visual acuity and induced irregular astigmatism.⁸

The patient's best-corrected distance visual acuities (BCDVs) with scleral lenses were 20/30-2 OD and 20/30- OS. A scleral lens evaluation after two hours of wear revealed no central corneal clearance

ABOUT THE AUTHOR



Dr. Lopez graduated summa cum laude from the University of Houston College of Optometry. He practices in Wisconsin with a focus on ocular pathology and specialty contact lenses.

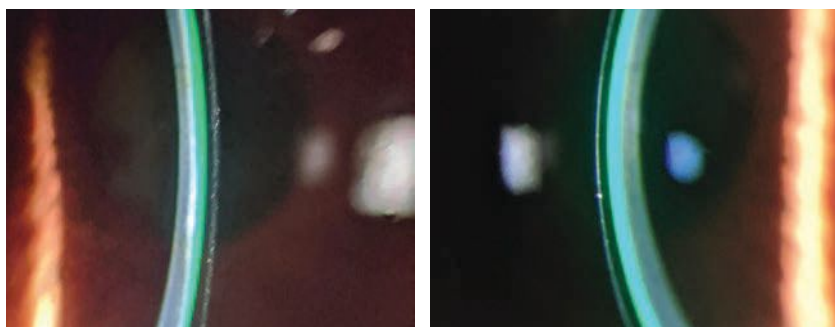
and significant 360° compression of the bulbar conjunctiva in both eyes. Compression of the bulbar conjunctiva can cause a number of problems, such as irritability, and was likely the culprit of the patient's discomfort and pain after removing the lenses.⁹ A significant conjunctival compression ring was evident after removing the lenses.

After a short washout period, a diagnostic scleral lens fit was performed in both eyes. Diagnostic lenses with a small sagittal depth (sag) were selected to mimic the shape of the patient's oblate corneas. The fit was acceptable with the exception of inadequate limbal clearance. After the appropriate adjustments to the lens parameters were made, new scleral lenses were ordered (*Table 1*).

The patient reported improved vision and comfort with the well-fitting lenses at the dispensing visit and was later able to wear them throughout the day without issue. BCDVAs improved to 20/25+ OD and 20/20 OS. The scleral lenses were finalized, and the patient has been wearing them successfully ever since.

Takeaway #1. Because LASIK results in a flat cornea (even though steepening occurs with post-refractive surgery ectasia), be sure to fit these patients in a lens with a flatter base curve or a smaller sag to match their oblate corneal shape.

Takeaway #2. Extra limbal clearance can improve areas of insufficient clearance. If a larger limbal clearance is not an option with one scleral design, another may be needed to help achieve appropriate clearance over the limbus.



The first case's patient's scleral lens fit displayed adequate central clearance (OD on the left).

CASE 2: KERATOCONUS

A 34-year-old Caucasian male presented for a comprehensive exam and reported that he was overdue for a scleral lens evaluation. He was fit with sclerals three years earlier but had discontinued wear due to his unhappiness with the visual outcome. The patient expressed a desire to get back into scleral lenses to maximize his vision. A slit lamp examination and corneal topography revealed stage II keratoconus in both eyes.

Using diagnostic lenses, the overall fit appeared satisfactory with only minor modifications. The patient reported comfort but disappointment in the 20/25 vision achieved in each eye with a spherical over-refraction. A spherocylindrical over-refraction (SCOR) assessed for residual astigmatism that results from internal refractive components of the eye, mainly the crystalline lens, the posterior cornea or both.¹⁰ Corneal topography scans with the lenses in place ruled out flexure as a cause of residual astigmatism. The SCOR revealed -0.75D of residual astigmatism in each eye, the addition of which improved the BCDVA to 20/20+ in each eye.

The acceptable levels of visual acuity and refractive residual astigmatism (both are subjective measurements) guided the decision to order the first trial pair of scleral lenses without astigmatic correction.

Upon dispensing the scleral lenses, the fit and comfort were excellent, but the patient still reported dissatisfaction with the visual results. Repeat SCOR showed that -0.75D of residual astigmatism remained in each eye. Lens stability and rotation was confirmed, and new lenses were ordered with the addition of astigmatic correction in a front-surface toric design (*Table 2*). The patient was pleased with the vision improvement gained from the second trial pair, which yielded 20/15-2 in each eye. The overall fit and comfort were satisfactory.

At follow-up, central clearance was low, measuring 75µm in each eye after 10 hours of wear time. While no universally accepted value for central clearance exists, most scleral lens practitioners prefer a range of 100µm to 200µm. One study reported an optimum central clearance range of 50µm to 200µm after settling.¹¹ A number of

Table 1. Case 1 Lens Parameters

	Brand	Overall Diameter (mm)	Base Curve (mm)	Power (DS)	Center Thickness (mm)	Material	Peripheral Curve	Additional Modifications
OD	Blanchard Onefit	14.90	7.40	-16.12	0.28	Boston XO	Sphere	XLC, Plasma tx
OS	Blanchard Onefit	14.90	7.30	-11.37	0.28	Boston XO	Sphere	XLC, Plasma tx

SPECIALTY CONTACT LENSES FOR THE DISEASED CORNEA



The patient in case 2 was also fit with scleral lenses, which displayed low central clearance (OD at left).

Table 2. Case 2 Lens Parameters

	Brand	Overall Diameter (mm)	Base Curve (mm)	Power (DS)	Center Thickness (mm)	Material	Peripheral Curve	Additional Modifications
OD	Blanchard Onefit	14.90	8.00	-2.25-0.75x125	0.23	Optimum Extra	Sphere	XLC, Plasma tx
OS	Blanchard Onefit	14.90	8.00	-3.25-0.75x050	0.23	Optimum Extra	Sphere	XLC, Plasma tx

experienced specialty contact lens fitters believe some central bearing with scleral lenses may even be well tolerated compared with GPs.¹²

Central clearance aside, the rest of the scleral lens fit looked great, the comfort was excellent and no ocular surface complications (e.g., microcystic edema, limbal staining) were present after lens removal. The lenses were dispensed, and the patient has been successfully wearing them ever since.

Takeaway #1. Perform a SCOR when suspicions of residual astigmatism arise. However, it may be worth forgoing astigmatic correction in scleral lenses until the patient returns for a follow-up, at which time a SCOR can be repeated to determine if astigmatic correction is the same and reasonable to add.

Takeaway #2. Work within your comfort level. Different doctors may have different reactions to the low central clearance described in this case. In these instances, sometimes the thought that the enemy of good is better comes to mind.

CASE 3: PENETRATING KERATOPLASTY

A 51-year-old Caucasian male was referred for a contact lens examination. He had worn GPs for years but noticed a steady decline in vision and

reported longstanding lens awareness. His most recent pair of GPs was two years old. His ocular history was significant for a successful penetrating keratoplasty (PKP) in the right eye and stage III keratoconus in the left eye.

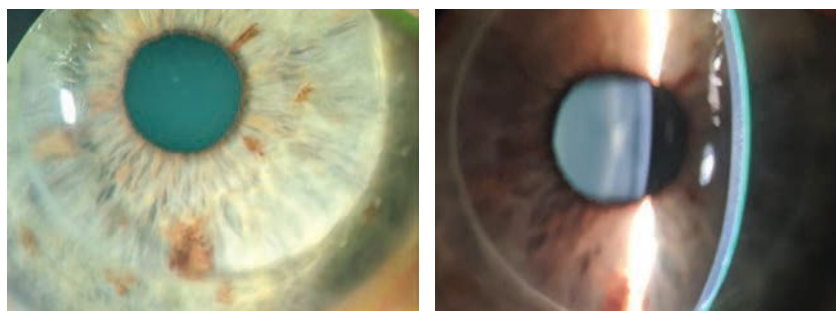
BCDVA with the GPs was 20/30-2 OD and 20/30- OS. Evaluation revealed a flat fit with excessive inferior edge lift in the right eye and a steep fit in the left eye. Excess edge lift is a common cause of lens awareness, discomfort or both.

The patient was successfully refit with GPs that had a post-graft design in the right eye and a keratoconic design in the left eye. Because the initial right trial lens demonstrated excessive inferior edge lift, asymmetric corneal technology (ACT) was added to improve edge lift. Different grade levels for ACT exist depending on the required lift change.

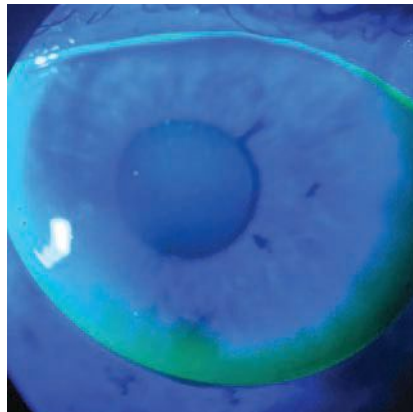
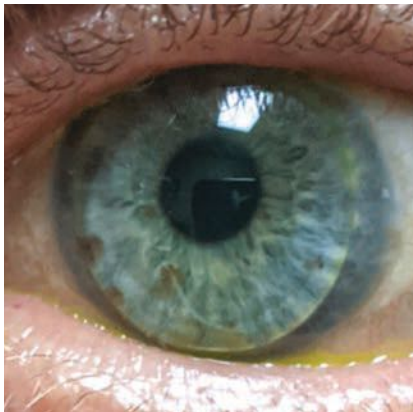
With the newly designed GPs, the patient experienced improved distance vision and a noticeable increase in comfort, which was likely attributable to an improved inferior edge lift design via an ACT grade two modification. Slight inferior edge lift remained with the right lens, but further enhancement was deferred, as there were no stability or comfort issues.

The patient did, however, report difficulty completing near tasks. He worked as a handyman and found his growing dependence on reading glasses inconvenient. Multifocal GPs were discussed as an option to improve the patient's functionality, and he decided to move forward with a multifocal GP fitting.

The patient was fit in the same GP lenses as above with the addition of an aspheric front surface design to incorporate a near add. Trial lenses



The patient in case 3 had a PKP in his right eye (left). An optic section highlights the graft-host junction of the PKP.



The patient in case 3 had keratoconus in his left eye and slight, but acceptable, inferior edge lift remains after ACT adjustment in the right eye.

were ordered to integrate over-refraction adjustments for both lenses (Table 3).

At the dispensing visit, the patient's distance and near vision were checked binocularly, as is customary with multifocal contacts. A BCDVA of 20/25+2 was achieved with a near visual acuity of 20/25+. The new GPs demonstrated a significant improvement in near vision.

At follow-up, the patient reported enhanced functionality at work and less reliance on reading glasses.

Takeaway #1. Become familiar with contact lens designs. In this case, a specific change was made using ACT to improve excess inferior edge lift, resulting in improved patient comfort and lens stability.

Takeaway #2. Specialty lens practitioners are eager to achieve optimal results. When paired with a motivated patient, success is achievable. The complexity of this case may have been daunting, but tackling the challenge improved the patient's quality of life.

DISCUSSION

Advancements in scleral lens education, training and marketing have pushed this modality to the forefront of the specialty contact lens market. Many optometrists now consider these lenses the first-line option for maximizing health and vision.

As optometrists become more comfortable with scleral lens fitting, they should not forget the benefits of GPs. In many instances, GPs may be the best specialty contact lens option for irregular eyes.

Remember that this subcategory of optometric care does not revolve entirely around simply fitting contact lenses. Rather, we are using medical devices to treat and manage complex ocular surface conditions. It is easy to get lost in the wonders of specialty contact lenses and forget that the patients who benefit from them will likely need ongoing medical care, a role optometrists should feel comfortable embracing.

While laboratory consultants can be a tremendous resource, every practitioner should develop enough familiarity and knowledge about lens designs to troubleshoot issues themselves. Tapping into the brain of lens consultants can be extraordinarily useful, but it is no substitute for understanding how to fit your own patients.

The specialty contact lens market is continually expanding. These medical devices provide a unique opportunity to improve the vision, comfort and health of patients. As advancements progress, so do future applications. The possibilities leave a lot to be excited about. **RCCL**

1. Andrzejewski T, Gelles J. Irregular corneas meet their match with GP lenses. *RCCL*. 2020;157(3):22-5.
2. Elseht RM, Nagy KA. Rigid gas permeable contact lens as a vision-sparing tool in children after traumatic corneal laceration. *J Pediatr Ophthalmol Strabismus*. 2018;55(3):178-81.
3. Pradhan ZS, Mittal R, Jacob P. Rigid gas-permeable contact lenses for visual rehabilitation of traumatized eyes in children. *Cornea*. 2014;33(5):486-9.
4. Wu Y, Tan Q, Zhang W, et al. Rigid gas-permeable contact lens related life quality in keratoconic patients with different grades of severity. *Clin Exp Optom*. 2015;98(2):150-4.
5. Schornack M, Nau C, Nau A, et al. Visual and physiological outcomes of scleral lens wear. *Cont Lens Ant Eye*. 2019;42(1):3-8.
6. Yin J, Jacobs DS. Long-term outcome of using Prosthetic Replacement of Ocular Surface Ecosystem (PROSE) as a drug delivery system for bevacizumab in the treatment of corneal neovascularization. *Ocul Surf*. 2019;17(1):134-41.
7. He X, Kendall D, Quinones VLP, et al. Case series: overnight wear of scleral lens for persistent epithelial defects. *Optom Vis Sci*. 2018;95(1):70-5.
8. Wolle MA, Randleman JB, Woodward MA. Complications of refractive surgery: ectasia after refractive surgery. *Int Ophthalmol Clin*. 2016;56(2):129-41.
9. Denaeyer GW, Michaud L. Scleral Lens Troubleshooting. *Cont Lens Spect*. August 1, 2017.
10. Ensley R, Miller H. The toric toolbox: don't forget GPs. *RCCL*. 2016;153(8):8-9.
11. GP Lens Institute - Scleral Lens Education Society. Scleral lens troubleshooting FAQs. www.gpli.info/pdf/GPLISLSTSGuide1017.pdf. Accessed September 17, 2020.
12. Van der Worp E. A Guide to Scleral Lens Fitting. 2nd ed., Pacific University College of Optometry, 2015.

Table 3. Case 3 Lens Parameters

	Brand	Overall Diameter (mm)	Base Curve (mm)	Power (DS)	Material	Additional Modifications	Multifocal Modifications
OD	Blanchard RSS	10.00	6.75	-8.00	Boston XO	Act 2, Plasma tx	Reclaim +2.25 add, 3.00mm optic zone
OS	Blanchard RSS	9.50	7.14/7.46	-1.50	Boston XO	Plasma tx	Reclaim +2.25 add, 3.00mm optic zone

Herpes Simplex Keratitis: MANAGING THE MASQUERADER

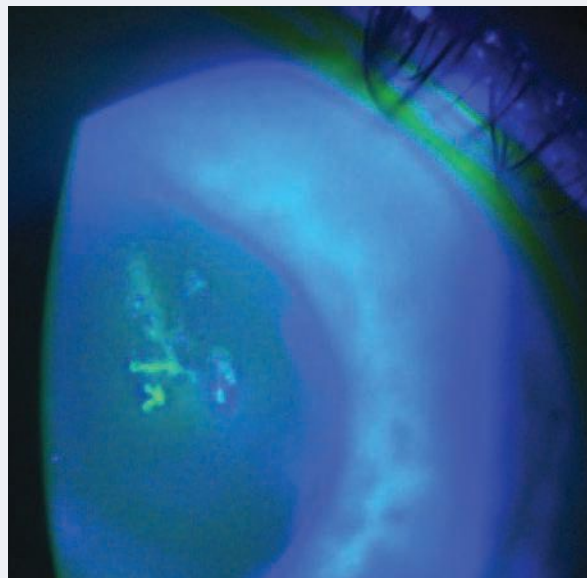
This review can help you better identify, diagnose and treat this condition.

By Shannon Leon, OD

Herpes simplex viral keratitis (HSVK) is a condition that can frustrate both clinicians and patients alike. It has often been recognized as a ‘clinical masquerader’ due to its occasionally mystifying and varying presentation. These variations can result in delayed diagnosis, which impacts the patient’s time and comfort as well as their overall visual outcomes. Eye care professionals must be able to recognize and treat HSVK efficiently to not only shorten the course of the disease but also reduce permanent corneal scarring and poor visual prognosis.

HSV PATHOLOGY

The herpes simplex virus is a double-stranded DNA virus that spreads via direct contact with the mucous membranes of the host.^{1,2} It is part of the *Herpesviridae* family, which includes three main players: herpes simplex virus type 1 (HSV-1), herpes simplex virus type 2 (HSV-2) and herpes varicella zoster virus (HZV).¹ Additional members include the Epstein Barr virus and cytomegalovirus. The challenge of managing HSV ocular infections has risen to prominence



HSV epithelial keratitis is characterized by a dendrite lesion with terminal bulbs.

Photo: Lisa Martin, MD

then progresses to either cause an immune-mediated inflammatory response, which clinicians call stromal keratitis, or the virus will travel in a retrograde manner along the trigeminal ganglion via the corneal nerves to wait for future reactivation.^{1,3}

A DETAILED HISTORY

Unfortunately, HSVK can have many clinical presentations and, therefore, should always be on your list of differentials when diagnosing and treating anterior segment disease.

When diagnosing a corneal

condition, the best place to start is with a thorough history. The majority of HSVK is secondary to viral recurrence, which is often associated with stress, ultraviolet light exposure, corneal trauma or immunosuppression.¹ Therefore, one of the most important questions you can ask your patient is whether they have had a similar

not only because of its often-devastating corneal effects but also because of the significant seroprevalence of these viruses within the population. As a result, HSV infections of the eye are the leading cause of infectious corneal blindness in developed countries.² HSV-1, specifically, is heavily associated with ocular infections and can be difficult to manage due to its reoccurring nature. After initial infection, HSV can move to corneal epithelial cells where it will often continue to replicate and spread from cell to cell.³ This replication results in what we often recognize as the hallmark dendritic corneal lesion.³ The virus

When diagnosing a corneal condition, the best place to start is with a thorough history. The majority of HSVK is secondary to viral recurrence, which is often associated with stress, ultraviolet light exposure, corneal trauma or immunosuppression.¹ Therefore, one of the most important questions you can ask your patient is whether they have had a similar

ABOUT THE AUTHOR



Dr. Leon practices at the South Texas Eye Institute in San Antonio. She is a graduate of the Rosenberg School of Optometry where she completed both her optometry degree and her residency in Primary Care.

episode in the past. Still, many episodes of HSV are asymptomatic, and the lack of a clear previous history doesn't rule out the condition.

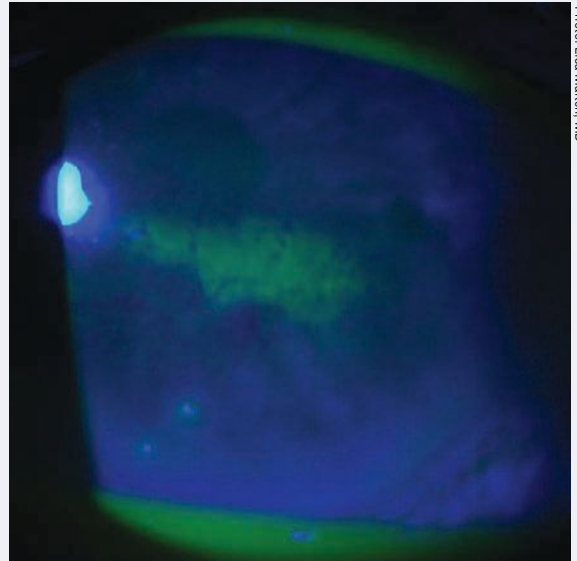
It is vital to document recent ocular surgeries, current and previous contact lens wear, a history of corneal abrasions or recurrent corneal erosions and any changes in recent systemic health. Furthermore, always note any recent episodes of fever, new or recurrent cold or nasal sores and any recent use of systemic and/or topical corticosteroids. Steroids in particular, without the use of an antiviral, can result in HSVK recurrence due to lowered immune system activity that allows for an increase in viral replication.

Symptoms of HSVK can vary from person to person and may depend on the degree and type of corneal involvement. Patients will often present with pain, foreign-body sensation, light sensitivity, watering, redness and blurred vision.^{2,4} In addition, HSVK is most commonly recognized as unilateral and should therefore be considered as a differential in any unilateral red eye or keratitis, regardless of pain. Bilateral HSVK is rare and is more likely to occur in children and patients who have experienced recent immunosuppression.⁵

RECOGNIZE AND PRIORITIZE

At the beginning of the clinical exam, always evaluate the patient's ocular adnexa while they are sitting in the exam chair even before they are behind a slit lamp biomicroscope. Evaluation of the ocular adnexa can reveal signs related to other conditions that present with similar symptoms as HSVK. For example, HZV will often produce vesicles of the forehead, scalp and face that respect the vertical midline.⁴

Corneal sensitivity testing and a thorough slit lamp exam, which includes evaluation of the cornea and corneal staining, are key components in the diagnosis and management of HSVK. Corneal staining is a technique that uses fluorescein, lissamine green or rose Bengal stain to improve visualization of epithelial defects and virus-laden cells on the cornea. The hallmark sign of HSVK is a dendritic lesion with terminal bulbs. The main body of the lesion will stain with fluorescein while the



Geographic ulcers can be more difficult to distinguish from other differentials. They are categorized by coalesced staining and dendriform characteristics along their edge margin.

terminal bulbs will stain with rose Bengal or lissamine green.^{4,6} This can be helpful especially in distinguishing HSVK from conditions such as HZV that produce pseudodendrites that result in negative staining and no terminal bulbs.

Occasionally, the corneal lesions will be coalesced in appearance, making them slightly more difficult to diagnose. These more amoeba-appearing lesions are called geographic ulcers. However, even with their less distinguished appearance, these ulcers still usually have dendriform characteristics

Release Date: November 15, 2020
Expiration Date: November 15, 2023
Estimated time to complete activity: 2 hours

Jointly provided by Postgraduate Institute for Medicine (PIM) and Review Education Group.

Educational Objectives: After completing this activity, the participant should be better able to:

- Provide a timely diagnosis and initiate the right therapy for patients with herpes simplex keratitis.
- Review the examination and testing steps for herpes simplex keratitis.
- Recognize what signs and symptoms can reveal herpes simplex keratitis as the cause.
- Treat herpes simplex keratitis properly.
- Discuss the long-term prognosis and how clinicians can monitor for recurrence.

Target Audience: This activity is intended for optometrists engaged in the care of patients with herpes simplex keratitis.

Accreditation Statement: In support of improving patient care, this



JOINTLY ACCREDITED PROVIDER™
 INTERPROFESSIONAL CONTINUING EDUCATION

activity has been planned and implemented by the Postgraduate Institute for Medicine and Review Education Group. Postgraduate Institute for Medicine is jointly accredited by the Accreditation Council for Continuing Medical Education, the Accreditation Council for Pharmacy Education, and the American Nurses Credentialing Center, to provide continuing education for the healthcare team. Postgraduate Institute for Medicine is accredited by COPE to provide continuing education to optometrists.

Faculty/Editorial Board: Shannon Leon, OD, the South Texas Eye Institute.

Credit Statement: This course is COPE approved for 2 hours of CE credit. Course ID is **70082-SD**. Check with your local state licensing board to see if this counts toward your CE requirement for relicensure.

Disclosure Statements:

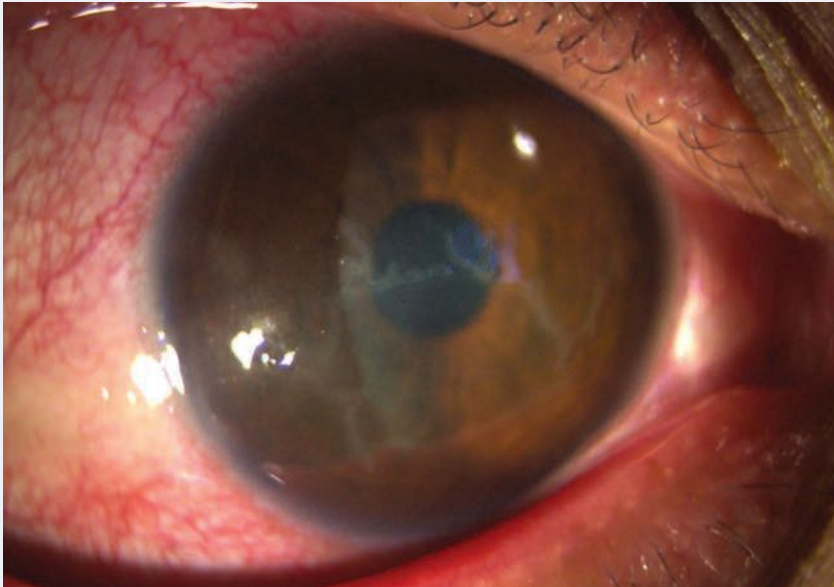
Dr. Leon has nothing to disclose.

Managers and Editorial Staff: The PIM planners and managers have nothing to disclose. The Review Education Group planners, managers and editorial staff have nothing to disclose.



HERPES SIMPLEX KERATITIS: MANAGING THE MASQUERADER

Photo: Lisa Martin, MD



Dendrites that stem from HSV epithelial keratitis can come in all shapes and sizes, ranging from small to those that encompass a large surface area of the cornea.

along their edge margin which can be visualized through corneal staining.⁶

Although HSVK most commonly presents as an epithelial disease, recurrent infections can become both stromal and endothelial in nature.⁴ Distinguishing between the types of presentations is important as this can help determine which type and dosing of treatment should be administered. Unlike epithelial HSVK, stromal disease commonly presents with an eccentric lesion, stromal edema and anterior chamber reaction.⁴ This can result in stromal keratitis with or without epithelial ulceration, which can be determined through dye staining at the slit lamp biomicroscope. Alternatively, endothelial disease presents with endothelial inflammation, elevated intraocular pressure (IOP), keratic precipitates and disc-shaped corneal edema (i.e., disciform keratitis).⁵

Once corneal staining has been completed, it is important to check corneal sensitivity. Decreased corneal sensitivity can be a sequelae of HSVK, which results from dam-

age to the corneal nerves and is especially common in patients with recurrent disease.⁴ This attribute of HSVK can be easily evaluated both behind the slit-lamp and in the exam chair by using a cotton whip to evaluate blink reflex. Reduced blink reflex is a sign that corneal sensitivity is decreased and can help to rule out other differentials often marked by increased corneal sensitivity such as corneal abrasions, recurrent corneal erosions and microbial keratitis.

Clinical examination through slit lamp biomicroscopy combined with a thorough history is usually sufficient in diagnosing HSV keratitis.² This typically makes laboratory testing and diagnostic testing unnecessary. However, diagnostic testing is available when the presentation is atypical and the clinical examination does not reveal easily diagnosed HSV ulcers and lesions.

Culturing is considered the standard in laboratory diagnosis of HSVK.⁵ Unfortunately, this is usually only useful when the disease is epithelial in nature since the virus

typically cannot be cultured in cases of stromal or endothelial disease.⁵ Culturing generally results in outcomes that have high specificity but low sensitivity and long turnaround times.⁵ In addition, a virology laboratory is usually necessary to process the viral cultures, which can result in decreased availability to clinicians and increased diagnostic times.⁵

The other two most common diagnostic tests for identifying HSVK are direct fluorescent antibody (DFA) and polymerase chain reaction (PCR). DFA allows for detection of HSV antigens while PCR detects viral DNA.⁵ Although both methods are highly sensitive and specific, they are limited by their need for trained technicians, expensive equipment and low availability.⁵

UNDERSTANDING THE DIFFERENTIALS

One of the most difficult aspects of diagnosing, treating and managing patients with HSVK is the wide variety of presentations that can manifest. The list of differentials for HSV keratitis can vary based on whether the course of the disease is epithelial, stromal or endothelial in nature.

Epithelial differentials include conditions that cause dendritic and/or geographic-like lesions such as HZV keratitis, *Acanthamoeba* keratitis (AK), bacterial keratitis, recurrent corneal erosions, exposure keratopathy and tyrosinemia keratitis. AK in particular can cause a dendritic epithelial pattern that can be mistaken for HSVK.⁷ However, a clinician can garner distinguishing features by evaluating corneal staining (AK has no terminal bulbs) and patient history (AK is commonly contact-lens associated).⁷ Alternatively, conditions such as HZV keratitis

and tyrosinemia keratitis produce pseudodendritic lesions that can be better defined by their staining pattern and corneal appearance.

For stromal and endothelial keratitis, the differential diagnosis list includes conditions that can cause interstitial keratitis as well as keratouveitis. This includes diseases such as syphilis, Cogan's syndrome, Epstein-Barr virus, microbial keratitis, neurotrophic keratopathy, Posner-Schlossman syndrome and cytomegalovirus endothelial keratitis, among others.⁵

Many times, these conditions may be harder to separate, especially in cases where there is no epithelial ulceration. In some cases, laterality can help distinguish differentials, as is the case with Cogan's syndrome and syphilis. In situations where the condition does not respond to treatment, additional laboratory testing may be necessary to rule out differentials.

Due to its prevalence and potentially devastating corneal outcomes, clinicians must consider HSVK as a possible diagnosis in any case of epithelial, stromal or endothelial keratitis.

TREATMENT APPROACHES

Understanding the differences and ways in which HSVK can affect the ocular surface is important when approaching the treatment of each patient. Guidelines exist for the care and management of patients with HSVK; however, the types of medications and their dosages depend on the specific disease process. This means that clinical treatment will vary based on whether the HSVK is epithelial, stromal or endothelial.

Treatment of HSVK is divided into three main components: topical antiviral, oral antiviral and topical corticosteroids. There are currently three topical antivirals

Table 1. Recommended Dosing for HSV Epithelial Keratitis^{3,5,8}

Name	Administration Route	Recommended Dosage
Viroptic	Topical	1ggtt nine times a day for seven days then decreased to five times a day for seven days once ulcer is healed
Zirgan	Topical	1ggtt five times a day until ulcer is healed and then TID for seven additional days
Zovirax	Oral	400mg five times a day for seven to 10 days
Valtrex	Oral	500mg TID PO for seven to 10 days
Famvir	Oral	250mg TID PO for seven to 10 days

approved by the Food and Drug Administration (FDA) for the treatment of HSV keratitis. The two most common are Viroptic (trifluridine 1%, Pfizer) and Zirgan (ganciclovir 0.15%, Bausch + Lomb). The third, Avaclyr (acyclovir ophthalmic ointment 3%, Fera) was approved by the FDA in April 2019, but commercial launch appears to still be pending based on the company's website.

In addition to the topical variations, oral antivirals are widely and commonly used off label to treat HSV keratitis.⁵ The three most common agents are Zovirax (acy-

clovir, GlaxoSmithKline), Valtrex (valacyclovir, GlaxoSmithKline) and Famvir (famciclovir, Novartis). Choosing between topical or oral antivirals as well as whether or not an adjunct topical corticosteroid is necessary depends on which portion of the ocular surface is affected and the type of patient you are treating.

Herpes simplex epithelial keratitis. The most common form of HSVK disease, HSV epithelial keratitis is characterized by the hallmark dendritic lesion or geographic ulcer without stromal or endothelial involvement.

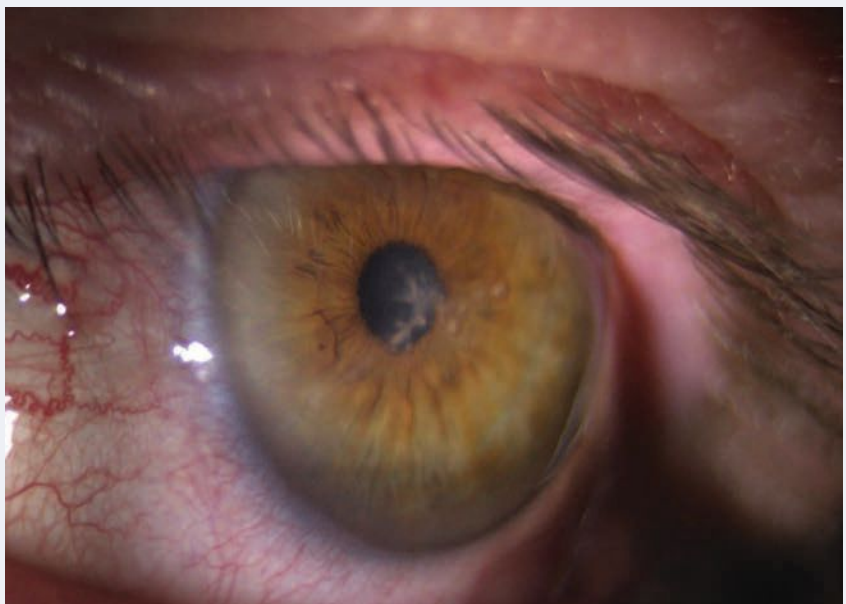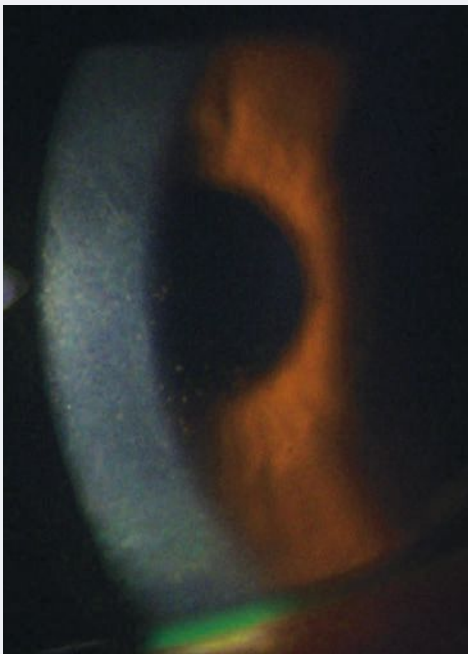


Photo: Lisa Maenen, MD

Dendritic lesions that occur centrally can be visually detrimental. Even with treatment these ulcers may cause permanent vision loss due to scarring.



Photos: Lisa Martin, MD



HSV endothelial keratitis is unique because it can occur with or without prior HSVK clinical manifestation.

Research suggests combining both oral antiviral and topical therapy is not necessary in the treatment of epithelial HSVK. The Herpetic Eye Disease Study (HEDS) I noted no benefit from adjunct therapy in the average HSVK patient, so maintaining one course of treatment is ideal from both a time and cost perspective.⁸

Oral antivirals are the treatment of choice when managing HSV epithelial keratitis. They are typically more affordable for patients and have a more adaptable dosing schedule. The three most common oral antiviral agents, acyclovir, valacyclovir and famciclovir, are all dosed at different intervals. Acyclovir is dosed 400mg five times daily for seven to 10 days, valacyclovir is dosed 500mg three times daily for seven to 10 days and famciclovir is dosed 250mg three times daily for seven to 10 days. Valacyclovir, specifically, is a great option since it is generally well tolerated and has a reduced dosing schedule. There is also some

evidence that it may have superior ocular penetration (Table 1).⁸

Topical antiviral usage and dosage vary based on availability, timing during the course of the condition and affordability. Topical antivirals are often reserved for patients who cannot use oral antivirals due to systemic health or other limitations.

Viroptic is typically dosed at one drop in the affected eye nine times daily for seven days and then decreased to five times daily for seven days if the ulcer is healed, whereas Zirgan is dosed at one drop into the affected eye five times daily until the ulcer is healed and then three times daily for an additional seven days.^{3,5,8}

Both medications have their own advantages and disadvantages.^{3,5,8} Viroptic is generally more affordable, but is considered toxic to the ocular surface at prolonged exposure and therefore must be limited to just 21 days of use.⁵ Zirgan is better for children as well as patients who require prolonged treatment but is often considered a more expensive therapy.⁵

Choosing between an oral and topical antiviral will likely depend on the patient. Oral antivirals should be used cautiously in patients with known kidney or liver disease due to metabolism of the active drug. When choosing oral antivirals always alert patients to possible side effects, and whenever in doubt discuss with the patient's primary care physician before prescribing.

HSV stromal keratitis (with and without ulceration). Unlike HSV epithelial keratitis, HSV stromal keratitis is considered an immune-mediated response resulting in inflammation of the

ocular tissue. It is thought to be secondary to the viral particles from the initial epithelial infection that persist in latent or active states in the corneal stroma.³ When HSV stromal keratitis presents without ulceration, this means that necrosis of the stromal tissue has not yet occurred and ulceration of the stromal bed is not present.^{5,8,9}

Rarely, instead of signaling an inflammatory response, the cells progress to necrosis of the tissue, which can then result in thinning of the corneal tissue and increased risk of corneal perforation.^{5,8,9} This is known as HSV stromal keratitis with ulceration. Fortunately, HSV stromal keratitis without ulceration is the more common presentation of the two forms.

Treatment of stromal keratitis is directed at controlling both the viral and inflammatory response. This is achieved via the combination of an oral antiviral and a topical corticosteroid.³ Combination therapy should be applied for at least 10 weeks, and the balance and taper regimen can be adjusted based on the corneal appearance.⁵ This ultimately means that the taper period of the steroid may be longer depending on how the patient responds to therapy.

For patients with stromal keratitis, oral antivirals are recommended over topical due to their safety profile (i.e., length of use) and superior corneal penetration.⁵ Throughout therapy, as long as a patient is on a topical corticosteroid they must also be on an antiviral agent.

HSV endothelial keratitis. This condition is a cell-mediated immune reaction to corneal endothelial tissue that results in persistent corneal edema and inflammation.⁵ Endothelial keratitis is unique compared with other forms of HSVK because it can occur independent

of epithelial or stromal keratitis.⁵ In fact, in up to half of reported cases of HSV endothelial keratitis the patient has no prior history of HSV epithelial keratitis.

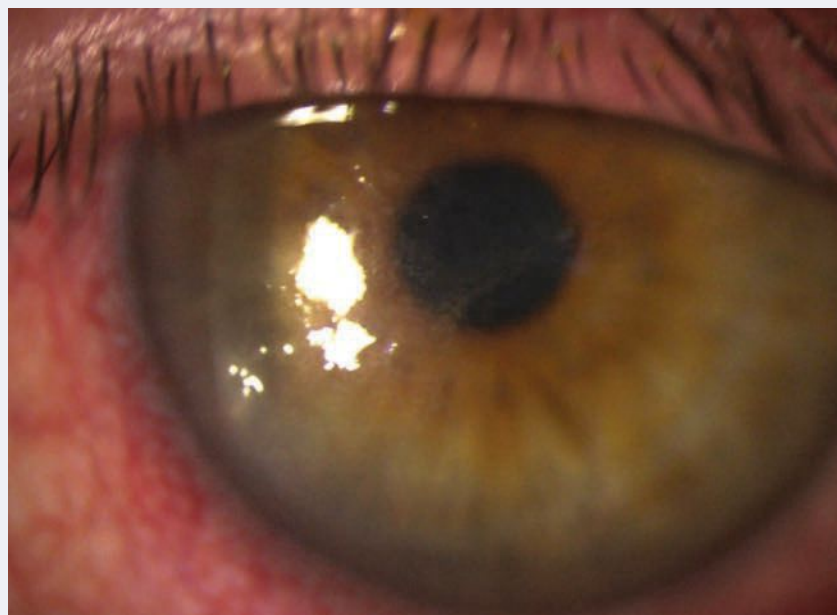
A combination of oral antiviral and topical corticosteroid are considered the mainstay of treatment for this condition.⁵ Unlike stromal keratitis, endothelial keratitis responds more rapidly to treatment, resulting in shortened therapy time and disease course.⁵ As with all forms of HSVK, management and taper is dependent on the patient's response to medication and may vary among individuals.

PROGNOSIS AND PROPHYLAXIS

For patients who suffer from recurrent disease or are at increased risk of recurrence, prophylaxis can help decrease the incidence of stromal scarring, vascularization and minimize poor visual outcomes. The HEDS II study found that the prophylactic use of an oral antiviral could reduce reactivation by 45% compared with the placebo group.⁸ Therefore, prophylactic dosing of oral antiviral agents is indicated in patients with higher risk of reactivation.

The recommended dosing varies between antivirals but includes acyclovir 400mg twice daily for at least one year, valacyclovir 500mg once daily for at least one year or famciclovir 250mg twice daily for at least one year.⁵ Prophylactic dosing does not have to end after one year, especially if the patient has a prolonged increased risk of reactivation; but at least one year of dosing is recommended.

In many cases, clinician vigilance and early recognition of HSVK can help prevent many of the devastating corneal outcomes. However, sometimes due to the severity of the disease or other prognostic



Photos: Lisa Marten, MD

HSV stromal keratitis is considered an immune-mediated response resulting in inflammation of the ocular tissue. It is characterized by inflammation of the stromal bed.

factors (i.e., lack of symptoms in smoldering disease, which can delay treatment), corneal scarring and poor visual prognosis cannot be avoided. In these cases, it is important to manage outcomes and educate patients on visual expectations. This may require eventual application of an amniotic membrane to improve corneal scarring, fitting of specialty lenses to reduce visual distortion or referral to a corneal specialist for further surgical intervention.

THE BOTTOM LINE

HSV keratitis undoubtedly can be difficult to recognize, treat and manage. With its propensity for high seroprevalence in the population along with its ability to masquerade as other corneal diseases, it is important for clinicians to recognize the signs and symptoms of this condition quickly. By having a thorough understanding of the disease process, its clinical presentation and the necessary treatment, we can further reduce poor visual prognoses and be better advocates

for our patients. Ultimately, in any corneal or ocular surface condition that presents to your clinic, always be on the lookout for red flags and HSV hallmarks. **RECL**

The author would like to thank Lisa Marten, MD, of South Texas Eye Institute, for the images.

1. Farooq AV, Shukla D. Herpes simplex epithelial and stromal keratitis: an epidemiologic update. *Surv Ophthalmol.* 2012;57(5):448-62.

2. Azher T, Yin XT, Tajfirouz D, et al. Herpes simplex keratitis: challenges in diagnosis and clinical management. *Clin Ophthalmol.* 2017;11:185-91.

3. Lobo AM, Agelidis AM, Shukla D. Pathogenesis of herpes simplex keratitis: The host cell response and ocular surface sequelae to infection and inflammation. *Ocul Surf.* 2019;17(1):40-9.

4. Ahmad B, Patel BC. Herpes simplex keratitis. StatPearls [Internet]. Treasure Island, FL: StatPearls Publishing; 2020.

5. White ML, Chodosh J. Herpes simplex virus keratitis: a treatment guideline-2014. American Academy of Ophthalmology Clinical Guidelines. www.aao.org/clinical-statement/herpes-simplex-virus-keratitis-treatment-guideline. Accessed October 6, 2020.

6. Weiner G. Demystifying the ocular herpes simplex virus. *American Academy of Ophthalmology.* 2013. www.aao.org/eyenet/article/demystifying-ocular-herpes-simplex-virus. Accessed October 6, 2020.

7. Acanthamoeba keratitis often mistaken for herpes simplex. *Rev Optom.* 2007;144(8).

8. Austin A, Lietman T, Rose-Nussbaumer J. Update on the management of infectious keratitis. *Ophthalmology.* 2017;124(11):1678-89.

9. American Academy of Ophthalmology. Herpes Simplex Keratitis - Europe. 2013. www.aao.org/topic-detail/herpes-simplex-keratitis--europe. Accessed October 6, 2020.



HERPES SIMPLEX KERATITIS: MANAGING THE MASQUERADER

CE TEST - NOVEMBER/DECEMBER 2020

You can obtain continuing education credit through the Optometric Study Center.

Complete the test form and return it with the \$35 fee to: Jobson Healthcare Information, LLC, Attn.: CE Processing, 395 Hudson Street, 3rd Floor New York, New York 10014. To be eligible, please return the card within three years of publication. You can also access the test form and submit your answers and payment via credit card at Review Education Group online, www.revieweducationgroup.com. You must achieve a score of 70 or higher to receive credit. Allow four weeks for processing. For each Optometric Study Center course you pass, you earn 2 hours of credit from Pennsylvania College of Optometry.

Please check with your state licensing board to see if this approval counts toward your CE requirement for relicensure.

- The herpes simplex virus is a _____ virus that spreads via direct contact with mucous membranes of the host.
 - Single-stranded RNA.
 - Single-stranded DNA.
 - Double-stranded DNA.
 - Double-stranded RNA.
- The majority of HSVK cases are secondary to viral reoccurrence often associated with:
 - Stress.
 - UV exposure.
 - Corneal trauma.
 - All of the above.
- Which of the following is considered a corneal sign characteristic of HSV epithelial keratitis?
 - Pseudodendritic lesion with negative corneal staining.
 - Dendritic lesion with terminal bulbs.
 - Stromal ring-shaped infiltrate.
 - Dry ulcer with feathery borders and satellite lesions.
- If you are unable to diagnose HSVK with clinical examination and history, what is considered the standard in laboratory test for this condition?
 - Polymerase chain reaction.
 - Direct fluorescent antibody test.
 - Enzyme-linked immunosorbent assay.
 - Corneal culture.
- Which of the following should be considered as a differential when diagnosing HSVK?
 - Acanthamoeba keratitis.
 - Herpes zoster virus.
 - Tyrosinemia keratitis.
 - All of the above.
- Which of the following agents are FDA-approved for the treatment of HSVK?
 - Viroptic and Zirgan.
 - Zovirax and Valtrex.
 - Zovirax and Famvir.
 - Valtrex and Famvir.
- What is considered the recommended therapy for patients with herpes simplex stromal or endothelial keratitis?
 - Topical antiviral only.
 - Oral antiviral and topical corticosteroid.
 - Oral antiviral only.
 - Topical antiviral and oral antiviral.
- What is the correct recommended dosing for Zirgan in the treatment of HSV epithelial keratitis, 1gtt in the affected eye:
 - Five times a day until the ulcer is healed and then TID for an additional seven days.
 - Nine times a day for seven days and then five times daily for seven days if the ulcer is healed.
 - TID until the ulcer is healed.
 - Nine times a day until the ulcer is healed, but no more than 21 days.
- What is the recommended therapy for patients with HSV epithelial keratitis?
 - Oral antiviral only.
 - Topical antiviral only.
 - Oral antiviral and topical corticosteroid.
 - Both a and b.
- What is the correct recommended oral antiviral dosing of acyclovir in the treatment of HSVK?
 - 400mg TID for seven to 10 days.
 - 400mg BID for seven to 10 days.
 - 400mg five times daily for seven to 10 days.
 - 500mg five times daily for seven to 10 days.
- Prophylactic use of oral antivirals is recommended in patients with a history of HSVK reoccurrence for at least _____.
 - One year.
 - Six months.
 - Three months.
 - One month.
- Herpes simplex virus is considered a part of the Herpesviridae family, which includes:
 - Herpes simplex virus Type I.
 - Herpes simplex virus Type II.
 - Herpes varicella zoster virus.
 - All of the above.
- When evaluating the corneal appearance in a patient with suspected HSVK, which type of stain should be used to evaluate for terminal bulbs?
 - Rose Bengal.
 - Fluorescein.
 - Lissamine green.
 - Both a and c.
- When testing corneal sensitivity in patients, what is considered a hallmark result associated with HSVK?
 - Significant increase in corneal sensitivity.
 - Decreased corneal sensitivity.
 - No effect on corneal sensitivity.
 - Slight increase in corneal sensitivity.
- HSVK has a propensity to reoccur, which stems from its ability to travel in a retrograde manner along the _____ ganglion via the corneal nerves.
 - Ciliary.
 - Pterygopalatine.
 - Trigeminal.
 - Submandibular.
- What class of medications can result in recurrence of HSVK by lowering the immune system activity and allowing for an increase in viral replication?
 - Corticosteroids.
 - Antihistamines.
 - Non-steroidal anti-inflammatory.
 - None of the above.
- What type of HSVK is due to an immune-mediated response where cells progress to necrosis of the tissue, which can result in increased risk of corneal perforation?
 - HSV epithelial keratitis.
 - HSV stromal keratitis without ulceration.
 - HSV stromal keratitis with ulceration.
 - HSV endothelial keratitis.
- In treatment of stromal keratitis, how long should combination antiviral and corticosteroid therapy be administered?
 - Four weeks.
 - Six weeks.
 - Eight weeks.
 - 10 weeks.
- Prior to administering oral antiviral therapy, it is extremely important to ask about the patient's status in regard to _____.
 - Cholesterol control.
 - Liver disease.
 - Kidney disease.
 - Both b and c.
- Which of the available antivirals has greater bioavailability to allow for less frequent dosing?
 - Valtrex.
 - Avaclyr.
 - Zovirax.
 - None of the above.

Examination Answer Sheet

Herpes Simplex Keratitis: Managing the Masquerader

Valid for credit through November 15, 2023

Online: This exam can be taken online at revieweducationgroup.com. Upon passing the exam, you can view your results immediately and download a real-time CE certificate. You can also view your test history at any time from the website.

Directions: Select one answer for each question in the exam and completely darken the appropriate circle. A minimum score of 70% is required to earn credit.

Mail to: Jobson Healthcare Information, LLC, Attn.: CE Processing, 395 Hudson Street, 3rd Floor New York, New York 10014

Payment: Remit \$35 with this exam. Make check payable to Jobson Healthcare Information, LLC.

Credit: This course is COPE approved for 2 hours of CE credit. Course ID is 70082-SD.

Jointly provided by Postgraduate Institute for Medicine and Review Education Group.

Salus University has sponsored the review and approval of this activity.

Processing: There is a four-week processing time for this exam.

Answers to CE exam:

1. A B C D
2. A B C D
3. A B C D
4. A B C D
5. A B C D
6. A B C D
7. A B C D
8. A B C D
9. A B C D
10. A B C D
11. A B C D
12. A B C D
13. A B C D
14. A B C D
15. A B C D
16. A B C D
17. A B C D
18. A B C D
19. A B C D
20. A B C D

Post-activity evaluation questions:

Rate how well the activity supported your achievement of these learning objectives:

1=Poor, 2=Fair, 3=Neutral, 4=Good, 5=Excellent

21. Provide a timely diagnosis and initiate the right therapy for patients with herpes simplex keratitis. ① ② ③ ④ ⑤
22. Review the examination and testing steps for herpes simplex keratitis. ① ② ③ ④ ⑤
23. Recognize what signs and symptoms can reveal herpes simplex keratitis as the cause. ① ② ③ ④ ⑤
24. Treat herpes simplex keratitis properly. ① ② ③ ④ ⑤
25. Discuss the long-term prognosis and how clinicians can monitor for recurrence. ① ② ③ ④ ⑤
26. Based upon your participation in this activity, do you intend to change your practice behavior?

(choose only one of the following options)

- A I do plan to implement changes in my practice based on the information presented.
- B My current practice has been reinforced by the information presented.
- C I need more information before I will change my practice.

27. Thinking about how your participation in this activity will influence your patient care, how many of your patients are likely to benefit? (please use a number):

28. If you plan to change your practice behavior, what type of changes do you plan to implement? (check all that apply)

- a Apply latest guidelines b Change in pharmaceutical therapy c Choice of treatment/management approach
- d Change in current practice for referral e Change in non-pharmaceutical therapy f Change in differential diagnosis g Change in diagnostic testing h Other, please specify: _____

29. How confident are you that you will be able to make your intended changes?

- a Very confident b Somewhat confident c Unsure d Not confident

Please retain a copy for your records. Please print clearly.

First Name

Last Name

E-Mail

The following is your: Home Address Business Address

Business Name

Address

City State

ZIP

Telephone # - -

Fax #

OE Tracker Number

By submitting this answer sheet, I certify that I have read the lesson in its entirety and completed the self-assessment exam personally based on the material presented. I have not obtained the answers to this exam by any fraudulent or improper means.

Signature _____ Date _____

Lesson 120434

RO-RCCL-1120

30. Which of the following do you anticipate will be the primary barrier to implementing these changes?

- a Formulary restrictions
- b Time constraints
- c System constraints
- d Insurance/financial issues
- e Lack of interprofessional team support
- f Treatment related adverse events
- g Patient adherence/compliance
- h Other, please specify: _____

31. Additional comments on this course:

Rate the quality of the material provided:

1=Strongly disagree, 2=Somewhat disagree, 3=Neutral, 4=Somewhat agree, 5=Strongly agree

32. The content was evidence-based.

- ① ② ③ ④ ⑤

33. The content was balanced and free of bias.

- ① ② ③ ④ ⑤

34. The presentation was clear and effective.

- ① ② ③ ④ ⑤

Four Troubleshooting Pearls For Scleral Lens Success

Early training can help scleral patients avoid lens wetting issues, midday fogging and other common problems that can lead to dropout.

By Andrew Pucker, OD, PhD

While the world and the way we practice have changed since COVID-19, our patients' vision needs still persist. Many individuals require ophthalmic devices to correct their refractive errors, and some rely on advanced ophthalmic products, such as scleral lenses, that can provide better visual outcomes and greatly improve a patient's quality of life.

Sclerals hold the title as the first contact lens modality to enter the market. The lens was developed in 1887, and early designs were used to manage ocular surface disease.

Despite sclerals' evolution through the decades, this modality didn't become popular until the early 2000s due to problems mainly centered on technology. Older generations were impermeable to oxygen, designs were limited and little attention was given to this technology in the optometric curriculum, which made scleral lenses either unsafe or challenging to fit.^{1,2}

Today's sclerals have come a long way. Modern designs are gas permeable, highly customizable and are now commonly fit in nearly

every mode of practice.¹ Despite the advancements in this specialty lens category, clinicians still need to closely monitor a number of issues to ensure their patients have a safe and comfortable wearing experience.

1. TRAIN EARLY AND OFTEN TO CURB CONTACT LENS DROPOUTS

For new scleral lens wearers, the early adaptation period can be challenging. One recent study found 27.4% of neophyte scleral lens wearers dropped out of their lenses within the first year mainly because of lens handling issues.³ In contrast, new soft contact lens wearers most frequently drop out of lenses due to poor vision.^{4,5} The difference between the two groups is likely due to sclerals' unique designs. Scleral lenses typically have a larger diameter and are made of rigid materials. These attributes, combined with the lenses' large size, often require the aid of devices, such as DMV inserters, for application.⁶

Despite these early challenges, clinicians can help their new scleral wearers adapt by closely monitor-

ing them during the initial fitting period.⁶ Additionally, scleral lens training can help ensure patients will become successful wearers.

While scleral lens application may be easy for some, it can pose challenges for others, especially in individuals with dexterity limitations (e.g., motor issues secondary to a stroke or Parkinson's disease).⁷

One common problem associated with scleral lens application is application bubbles, especially when patients are first learning how to apply the lenses (*Figure 1*).⁷ While very small bubbles may not be cause for concern, larger bubbles can result in visual disturbance or ocular discomfort in the event the bubbles get trapped in the lens fluid reservoir. If a bubble begins to form after lens application, a peripheral lens adjustment (e.g., steeper peripheral edge, quadrant-

ABOUT THE AUTHOR



Dr. Pucker is an assistant professor at the University of Alabama at Birmingham.

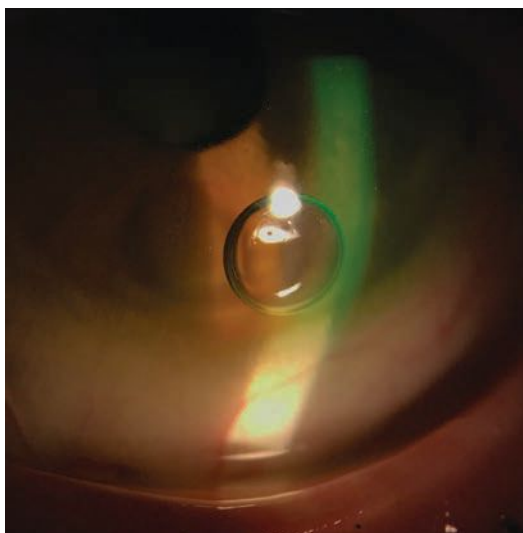


Fig. 1. One common problem associated with scleral lens application is application bubbles.

specific lens, freeform lens) is likely needed to better align the lens edge with the sclera. A smaller lens may be needed to avoid the surface toricity associated with the peripheral sclera. Applying a non-preserved artificial tear to the lens bowl prior to lens application can also help avoid bubbles that form throughout the day.

2. PREACH PROPER LENS CARE FROM THE GET-GO

For inexperienced scleral wearers, improper lens care can also pose problems, including corneal toxicity caused by products such as hydrogen peroxide-based solutions.^{8,9} Therefore, clinicians should regularly educate patients on how to correctly use their care regimens.⁹ Commonly prescribed care systems for sclerals include Clear Care (Alcon), Boston Simplus Multi-Action Solution (Bausch + Lomb), Boston Advance (Bausch + Lomb), Advanced Comfort Formula System (Bausch +Lomb) and Tangible Clean Multipurpose Solution (Tangible Science).

Poor lens wetting is a problem for both new and veteran wearers.¹⁰ The Scleral Lens Assessment

by Patients and Practitioners (SLAPP) study group found poor lens wetting was one of the main issues practitioners noticed in their scleral lens patients.¹⁰ When poor lens wetting occurs, practitioners should instruct the patients to remove, clean and then reapply their lenses.¹⁰

Clinicians can also tackle this problem by recommending a Tangible Hydra-PEG (Tangible Science) lens coating.¹¹ Hydra-PEG consists

of a 90% water polyethylene glycol-based polymer mixture that permanently encapsulates the lens and helps with wettability issues.

If a patient is wearing a lens coated with Hydra-PEG, practitioners should advise them to only use care products approved for this specific technology since rinsing them in water or using non-approved brands may prematurely remove the coating.¹¹ In addition to improving wettability, Hydra-PEG may also reduce deposits on the scleral lens (Figures 2 and 3).¹¹

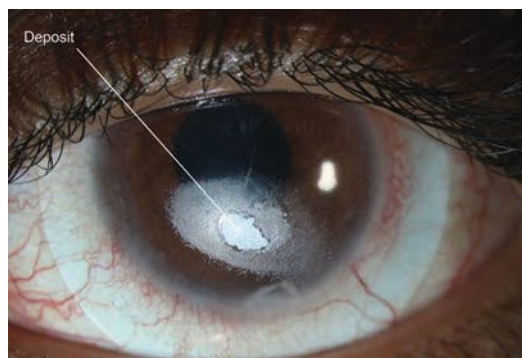
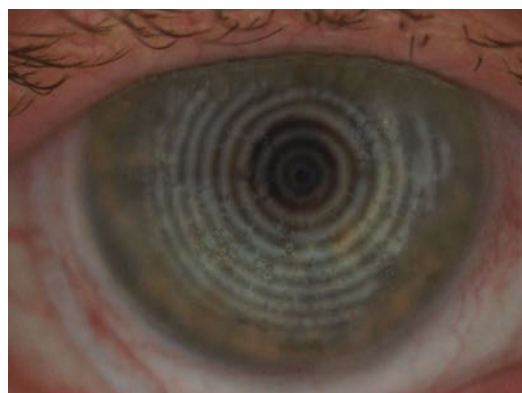
If lens deposits are a problem, the clinician should also investigate their origin, and if they are found to be due to foreign matter, such as makeup or improper cleaning, the patient should be reeducated to ensure proper lens handling.¹² Handwashing may also help avoid the introduction of unwanted deposits.

After a scleral lens has been fit and finalized, keep in mind the lens will likely accumulate damage over time, such as scratches or warpage, which may result in a slight fit or vision change (Figure 4). In these instances, it may be best to replicate the last lens before attempting to make lens adjustments, especially if the lenses are more than a year old.

3. KEEP MIDDAY FOGGING AT BAY

It's estimated that up to one-third of scleral lens patients experience midday fogging (Figures 5 and 6).¹³ This phenomenon results from either a lens that is fit too loosely or too tightly in the periphery, which may cause poor peripheral alignment with the sclera/episclera.^{14,15}

A loose lens may subsequently result in too much tear exchange, which may trap debris or biomolecules between the cornea and



Figs. 2 and 3. Deposits (distorted spots) might appear on a compromised scleral lens surface.

FOUR TROUBLESHOOTING PEARLS FOR SCLERAL LENS SUCCESS

lens. This may lead to a buildup of material within the tear reservoir and cause the lens to fog.

A tight peripheral lens may also trap debris or biomolecules between the cornea and lens, preventing the material from washing off the ocular surface. While the exact nature of these biomolecules is still not fully understood, some evidence suggests this material may be comprised of proteins or lipids.¹³

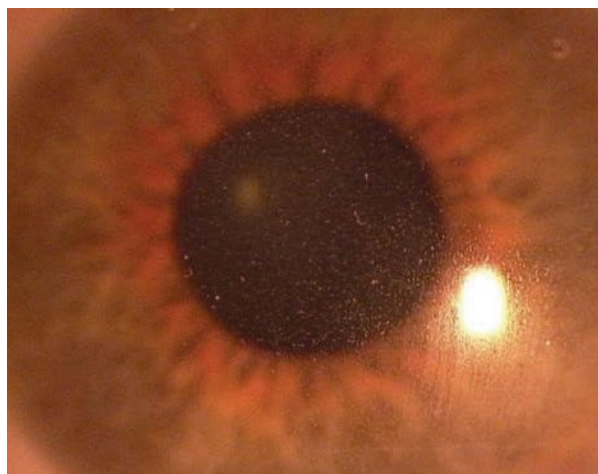
Alternatively, a scleral lens may induce a mild hypoxia situation that results in mild corneal swelling.^{16,17} Although modern materials are highly gas permeable, hypoxia may occur because tears are an oxygen barrier.^{16,17} Therefore, the greater the clearance between the cornea and the lens (thicker tear reservoir), the less oxygen will reach the cornea. This situation may subsequently result in a mild hypoxic situation that could cause white blood cells to infiltrate into the tear reservoir, which may also be a source of fogging.¹⁸ One study found that for every 50 μ m increase in tear reservoir thickness, there was a 1.72x increase in scleral lens fogging.¹⁸

With these issues in mind, especially when dealing with compromised corneas (e.g., post-surgical, Fuch's endothelial dystrophy),

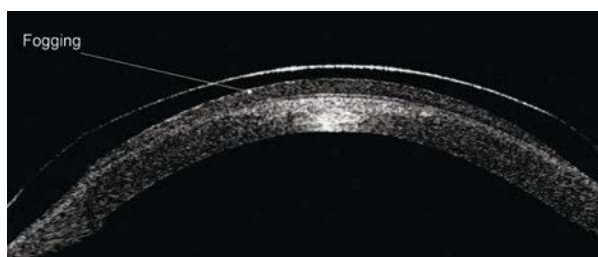
practitioners should try to fit the lens as close to the cornea as possible while still avoiding corneal touch (\sim 200 μ m after settling). Clinicians should also consider a quadrant-specific or fully customizable scleral lens periphery to allow for the best fit and to avoid seal-off or excessive tear exchange.^{10,19}

In addition to these options, the SLAPP study group reported the top treatment for scleral lens fogging was to simply have patients remove, clean and reapply their lenses.¹⁰

By using these options, patients could avoid other complications commonly associated with cornea hypoxia, such as corneal neovascularization (growth of blood vessels from the limbal region into the cornea) and corneal edema (Figures 7 and 8).



Photos: Maria Walker, OD



Figs. 5 and 6. Midday fogging results from either a lens that is fit too loosely or too tightly in the periphery.

4. POORLY FIT LENSES LEAD TO OCULAR TROUBLE

Other issues that may stem from a poorly fit scleral lens include conjunctival prolapse, conjunctival redness and ocular discomfort.

Conjunctival prolapse is a condition wherein a small or large region of the conjunctiva is pulled within the lens chamber.¹³ While the Scleral Lenses in Current Ophthalmic Practice Evaluation (SCOPE) study group found that some contact lens practitioners were comfortable with less than 30° of conjunctival prolapse, few practitioners in the investigation said they were comfortable with more than 30 degrees of prolapse.²⁰

If conjunctival prolapse occurs, it may likely deprive the limbus of oxygen, which could result in limbal stem cell death and, subsequently, a decreased ability to regenerate the cornea.

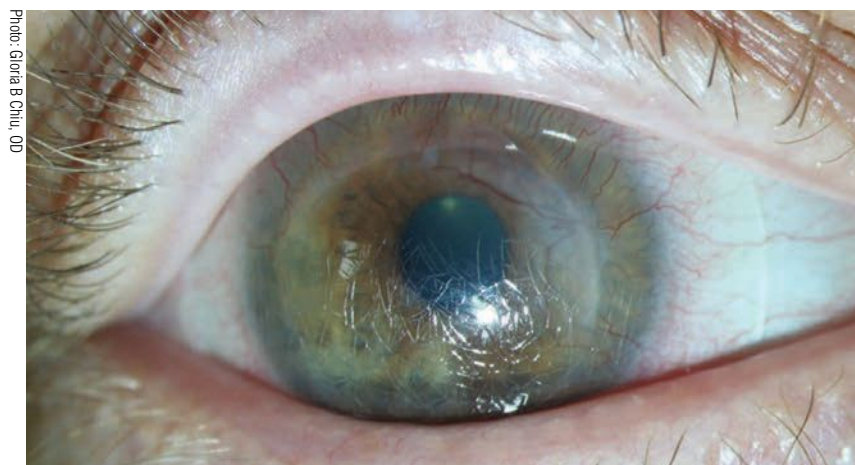


Photo: Gloria B Chiu, OD

Fig. 4. Over time, a scleral lens might get severely scratched and damaged.

While one may think that enlarging the scleral lens chamber would resolve this issue, larger chambers may actually make the condition worse due to greater suction.¹³ When you encounter conjunctival prolapse, make the lens chamber smaller. Quadrant-specific lens changes may likewise alleviate prolapse. Also, while a small amount of conjunctival prolapse is acceptable to some practitioners, try to at least mitigate prolapse for the listed reasons.²⁰

Conjunctival redness is a primary sign of ocular inflammation, and when noted in an otherwise normal scleral lens wearer, it suggests the lens periphery may be too tight in the red region (*Figure 9*).²¹⁻²⁶ This redness may occur near the limbus, which suggests that the lens periphery may be too flat, or near the lens edge, which suggests that the lens periphery may be too steep. This scenario can be likened to the toe (peripheral edge) and heel (limbal region) of a shoe.

This issue may first present as conjunctival blanching (blood vessel seal-off from the lens being too tight). The SLAPP study group found that optimizing the periph-

eral lens edge was the best treatment for ocular redness.¹⁰ Ocular discomfort is often a frequent complaint when poor peripheral edge fit occurs.

An alternative form of ocular redness, giant papillary conjunctivitis (GPC), has been reported to occur in 0.16% of scleral lens patients.⁸ While GPC is uncommon in scleral lens wearers, ODs should treat it similarly to an occurrence in a soft contact lens wearer, and should also address any underlying allergy issues.²⁷ An effort should be made to remove potential allergens by cleaning the lenses with a product such as an enzymatic protein remover. GPC may also stem from mechanical issues, though this may be less of an issue with scleral lenses due to limited lens movement.

Other, more serious complications associated with scleral lens use are corneal infiltrates and microbial keratitis.⁸

A corneal infiltrate is the accumulation of white blood cells within the cornea. They may or may not be related to an ocular infection.²⁸

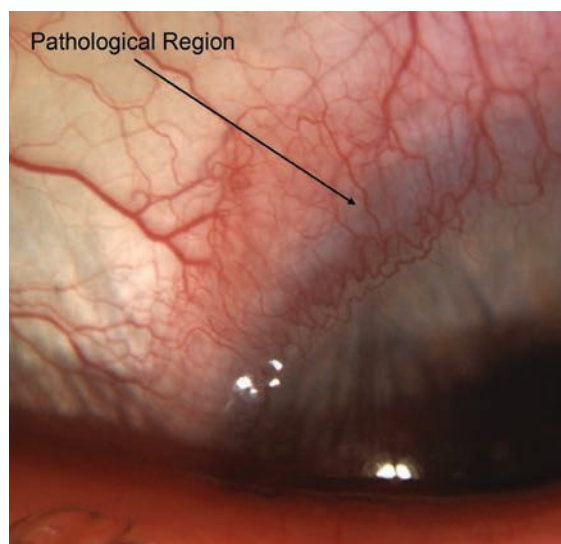
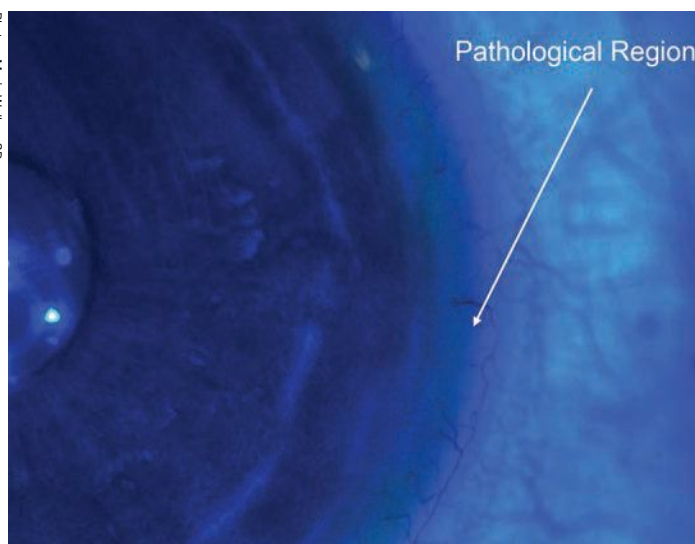
Microbial keratitis happens when the cornea is infected with a

microbe, such as bacteria, fungus or protozoa (e.g., *Acanthamoeba*), and it is by far the most serious complication since it can result in permanent vision loss or even the need for a corneal transplant once the condition has resolved.²⁸ Since many scleral lens wearers already have compromised corneas, they may be at a higher risk of developing these two conditions.

While the frequency of corneal infiltrates and microbial keratitis has been estimated to be 0.17% and 0.08%, respectively, well-controlled prospective studies are still needed to fully understand the frequency of these complications.⁸ If corneal infection or inflammation does arise, suspect poor lens compliance.²⁹ If a corneal complication does occur, lens wear should be ceased until the condition is under control, and these patients should be treated with antibiotic or antibiotic/steroid topical drops.

When they are able to return to lens wear, these patients should be re-educated about how to properly wear their scleral lenses to help avoid any potential reoccurrences. Remind patients that all their care products,

Photos: Maria Walker, OD



Figs. 7 and 8. If neovascularization and corneal edema secondary to limbal touch, as seen here, occurs, a lens change would be needed.

FOUR TROUBLESHOOTING PEARLS FOR SCLERAL LENS SUCCESS

including application devices and cases, are potential sources of contamination, and, because of this, these products should be regularly cleaned and replaced.^{30,31} One way to help ensure this is to provide your patients with a care bag that includes a set of application/removal devices since some patients have trouble finding replacement products.

Scleral lenses have become a mainstay for most practices. These specialty lenses are quickly becoming the standard of care for patients with complex refractive errors and for others who need long-term bandage contact lenses for extreme drying conditions, such as Sjögren's or Stevens-Johnson syndromes.¹ While the literature suggests scleral lenses are safe, especially when patients are correctly caring for them, a number of issues can still arise, so practitioners should regularly monitor their patients to help ensure they are successful and healthy wearers. **RCCL**

1. Nau CB, Harthan J, Shorter E, et al. Demographic characteristics and prescribing patterns of scleral lens fitters: The SCOPE Study. *Eye Contact Lens*. 2018;44 Suppl 1:S265-72.
2. van der Worp E, Barnett M, Johns L. Scleral lenses: history & future. *Cont Lens Anterior Eye* 2018;41:243-4.
3. Macedo-de-Araujo RJ, van der Worp E, Gonzalez-Mejome JM. A one-year prospective study on scleral lens wear success. *Cont Lens Anterior Eye*. 2020;40.
4. Sulley A, Young G, Hunt C. Factors in the success of new contact lens wearers. *Cont Lens Anterior Eye*. 2017;40:15-24.
5. Sulley A, Young G, Hunt C, et al. Retention rates in new contact lens wearers. *Eye Contact Lens*. 2018;44 Suppl 1:S273-82.
6. Pucker AD, Tichenor AA. A review of contact lens dropout. *Clin Optim*. 2020;12:85-94.
7. Bickle KM, Jones-Jordan LA, Kuhn J, et al. Initial scleral contact lens wearing experience. Poster presented at Global Specialty Lens Symposium 2019.
8. Schornack M, Harthan J, Barr JT, et al. Complications of scleral lens wear. *ARVO* 2016. Abstract A0147.
9. Food and Drug Administration. Hydrogen Peroxide Solution. www.fda.gov/medical-devices/contact-lenses/hydrogen-peroxide-solution. 2018. Accessed August 30, 2020.
10. Pucker AD, Bickle KM, Jones-Jordan LA, et al. Assessment of a practitioner's perception of scleral contact lens complications. *Cont Lens Anterior Eye*. 2019;42:15-9.
11. Tangible Hydra-PEG. Tangible Science. tangiblescience.com/tangible-hydra-peg-toolkit. 2018. Accessed August 30, 2020.
12. Pucker AD, Nichols JJ. Impact of a rinse step on protein removal from silicone hydrogel contact lenses. *Optom Vis Sci*. 2009;86(8):943-7.
13. Walker MK, Bergmanson JP, Miller WL, et al. Complications and fitting challenges associated with scleral contact lenses: a review. *Cont Lens Anterior Eye*. 2016;39:88-96.
14. McKinney A, Miller WL, Leach N, et al. The cause of midday visual fogging in scleral gas permeable lens wearers. *Invest Ophthalmol Vis Sci*. 2013;54:5483.
15. Skidmore KV, Walker MK, Marsack JD, et al. A measure of tear inflow in habitual scleral lens wearers with and without midday fogging. *Cont Lens Anterior Eye*. 2019;42:36-42.
16. Michaud L, van der Worp E, Brazeau D, et al. Predicting estimates of oxygen transmissibility for scleral lenses. *Cont Lens Anterior Eye*. 2012;35:266-71.
17. Kim YH, Tan B, Lin MC, Radke CJ. Central corneal edema with scleral lens wear. *Curr Eye Res*. 2018;43:1305-15.
18. Postnikoff CK, Pucker AD, Laurent J, et al. Identification of leukocytes associated with midday fogging in the post-lens tear film of scleral contact lens wearers. *Invest Ophthalmol Vis Sci*. 2019;60:226-33.
19. Consejo A, Llorens-Quintana C, Bartuzel MM, et al. Rotation asymmetry of the human sclera. *Acta Ophthalmol*. 2019;97:e266-70.
20. Harthan J, Shorter E, Nau C, et al. Scleral lens fitting and assessment strategies. *Cont Lens Anterior Eye*. 2019;42:9-14.
21. Wolffsohn JS, Arita R, Chalmers R, et al. TFOS DEWS II diagnostic methodology report. *Ocul Surf*. 2017;15:539-74.
22. Wu S, Hong J, Tian L, et al. Assessment of bulbar redness with a newly developed keratograph. *Optom Vis Sci*. 2015;92:892-9.
23. Papas EB. Key factors in the subjective and objective assessment of conjunctival erythema. *Invest Ophthalmol Vis Sci*. 2000;41:687-91.
24. Fieguth P, Simpson T. Automated measurement of bulbar redness. *Invest Ophthalmol Vis Sci*. 2002;43:340-7.
25. Amparo F, Wang H, Emami-Naeini P, et al. The ocular redness index: a novel automated method for measuring ocular injection. *Invest Ophthalmol Vis Sci*. 2013;54:4821-6.
26. Peterson RC, Wolffsohn JS. Sensitivity and reliability of objective image analysis compared to subjective grading of bulbar hyperaemia. *Br J Ophthalmol*. 2007;91:1464-6.
27. Donshik PC, Ehlers WH, Ballow M. Giant papillary conjunctivitis. *Immunol Allergy Clin North Am*. 2008;28:83-103.
28. Ehlers JP, Shah CP. *The Wills Eye Manual: Office and Emergency Room Diagnosis and Treatment of Eye Disease*. 5th ed. Philadelphia: Lippincott Williams & Wilkins; 2008.
29. Zimmerman AB, Marks A. Microbial keratitis secondary to unintended poor compliance with scleral gas-permeable contact lenses. *Eye Contact Lens*. 2014;40:e1-4.
30. Logan AK, Perrigin J. Microbial growth after cleaning scleral DMV devices. Poster presented at Global Specialty Lens Symposium 2017.
31. Wu Y, Carnt N, Willcox M, Stapleton F. Contact lens and lens storage case cleaning instructions: whose advice should we follow? *Eye Contact Lens*. 2010;36:68-72.

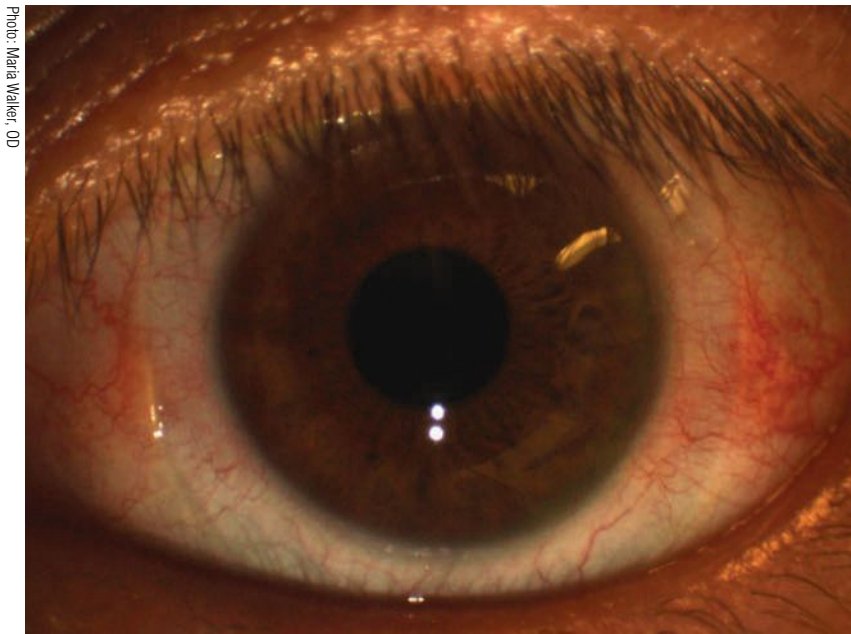


Fig. 9. Conjunctival redness (3 o'clock and 9 o'clock regions) after scleral lens removal might be due to a lens that is too tight in the periphery.

Photo: Maria Walker, OD

RETINAUPDATE2020

DECEMBER 4–5, 2020

 VIRTUAL EVENT

CHAIR



Mohammad Rafieetary, OD, FAAO

Consultative Optometric
Physician
Charles Retina Institute
Germantown, TN

TOPIC AREAS INCLUDE

- Diabetic Retinopathy
- Macular Disease
- AMD
- Peripheral Retina

REGISTRATION

Super early rate: \$149
Rate increases November 21: \$199

CO-CHAIR



Steven Ferrucci, OD, FAAO

Chief, Optometry Section
Sepulveda VA Medical Center
Sepulveda, CA

ORS MISSION STATEMENT

The mission of the Optometric Retina Society (ORS) is to promote the advancement of vitreoretinal knowledge for clinicians, ophthalmic educators, residents, and students. The ORS is dedicated to posterior segment disease prevention, diagnosis, management and co-management.

* Earn up to 8 LIVE COPE Credits and 4 Enduring Online Credits

To register visit:

www.ReviewEdu.com/ORSRetUpdate2020

e-mail: ReviewMeetings@MedscapeLIVE.com



*Approval pending

Partially supported by an unrestricted educational grant from Maculogix.

Review Education Group partners with Salus University for those ODs who are licensed in states that require university credit.



Administered by

REVIEW
EDUCATION GROUP

The Answer's in the Details

Comprehensively reviewing cases of uveitis will lead you to an accurate diagnosis.

A 17-year-old male was referred for a uveitis evaluation. He'd been seen by his primary OD about four weeks ago, at which time he noted redness and reduced vision. He was diagnosed with iritis and placed on prednisolone acetate 1% QID OU. The patient's symptoms had subsided to the point where he no longer needed the steroid. After approximately one week, however, his symptoms returned, so he was sent in for evaluation.

EXAMINATION

On exam, the patient's vision was 20/25 OD and 20/20 OS. His pupils were misshapen and minimally reactive. His extraocular muscles were normal, and his confrontation fields were full-to-finger counting. His intraocular pressures were 19mm Hg OD and 23mm Hg OS.

Slit lamp evaluation showed 1+ to 2+ conjunctival injection OU, 2+ fine keratic precipitates with few larger confluences OU and 3+ cell and mild flare in the anterior chamber OU. The patient's irides had remarkable anterior and posterior synechiae.

Dilated exam showed normal posterior segments, with the exception of some spillover cells in the anterior vitreous.

The patient denied problems with lower back or knee-based pain. He had no unusual skin lesions and didn't think he reacted abnormally to skin injuries or scratches. He had no history of oral or genital ulcerations and denied difficulty or pain with urination. He had no respiratory issues and denied fevers or night sweats. Other than the bout of strep

throat he had developed approximately two months earlier and the short course of oral antibiotics that followed, he was a healthy young man undergoing an episode of iritis.

MANAGEMENT

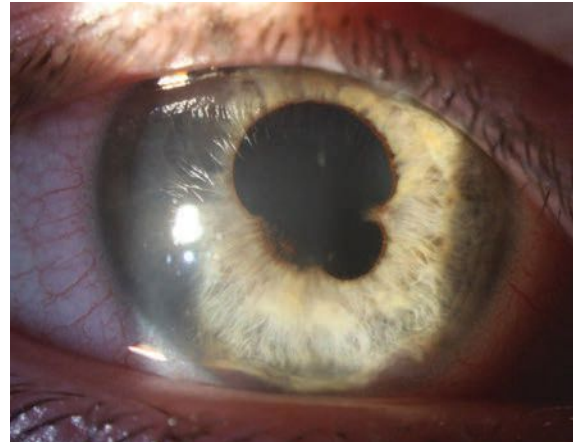
Treating our patient's ocular pathology was relatively straightforward. We find that our profession is often reluctant to initiate an effective dose of anti-inflammatory therapy and too eager to initiate a taper. The goal of initial therapy is to get inflammation under total control, and in an eye with intense inflammation, this almost always requires Durezol (difluprednate, Novartis). Maintain the effective dose for about a week before making any attempts at a slow taper.

We tend to treat most acute anterior uveitis (AAU) cases as though they are HLA-B27-linked, and we know that the average duration of a flare-up of this type is six to eight weeks. Thus, this is my targeted treatment duration.¹

In this instance, we began the patient on Durezol every hour OU and gradually tapered him off over a six-week interval. We maintained him on cycloplegics over the first two weeks of therapy but eliminated these as inflammation came under better control.

DISCUSSION

Much of the optometric education on uveitis suggests treating initial




Broad and extensive posterior synechia are present in the right eye at presentation. Substantial anterior synechia are also apparent at 5 o'clock and 7 o'clock.

episodes and considering systemic testing should the disease recur. However, systemic testing should be conducted as soon as suspicion of an underlying pathology arises.

In this patient's case, there were clear indicators that his uveitis was caused by systemic pathology, despite his negative review of systems. The indicator was something so mundane that it was hiding in plain sight—his specific classification of uveitis.

It is easy to consider this a case of anterior uveitis or iritis, but only diagnosing to this degree leaves a lot of fruit on the vine when it comes to your differential. We've all heard that most cases of uveitis are idiopathic. This mindset can give a false sense of security, especially when the patient isn't volunteering any additional systemic clues. It is important to be specific when classifying uveitis episodes to reveal any diagnostic clues.

First and foremost, our patient's case of anterior uveitis should be classified based on its course



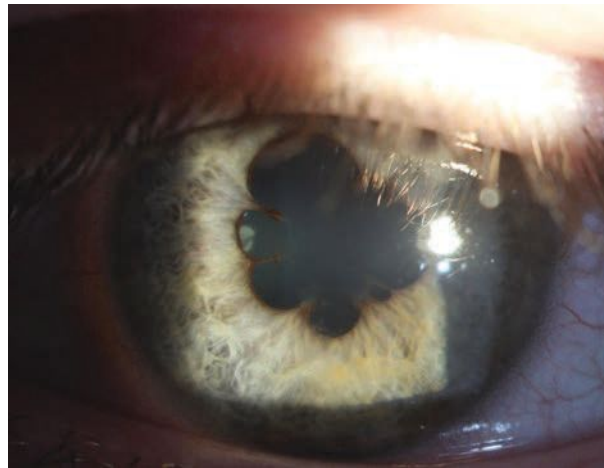
of approximately four weeks, which makes it an acute episode, or AAU. Suddenly, our differential opens up.

It's been estimated that up to 50% of AAU cases in Caucasians are HLA-B27-linked.¹ Going a step further lends even more weight to the clinical suspicion of an underlying process. This case is a bilateral AAU, which is extremely unusual.

According to one study, bilateral, simultaneous-onset AAU accounted for only 1% of uveitis patients over a 20-year period.² Of the 1%, idiopathic disease accounted for about 30% of cases; the rest had an underlying source.²

While HLA-B27 is the chief source of unilateral AAU, it is distinctly less common in bilateral disease, accounting for only about 9% of patients.² Post-infectious, usually following a bout of strep throat, and drug-induced uveitis were by far the most common causes.² HLA-B27-linked disease and tubulointerstitial nephritis and uveitis (TINU) were less common but still occurred.² TINU was a particularly interesting differential in this case, as the patient was young. A separate review found that while TINU only accounted for 1.7% of uveitis patients overall, it accounted for 32% of those who had bilateral AAU and were under the age of 20.³ Another small series found TINU in 60% of children with bilateral AAU.⁴

Uveitis in the setting of acute tubular/renal dysfunction has been



In the left eye, 360° of marked posterior synechiae can be seen at presentation.

infrequently reported since the mid-1970s. The mechanism, like many systemic inflammatory processes, is somewhat murky. The disease has been linked to previous infections, autoimmunity and, most commonly, drugs (primarily antibiotics and oral non-steroidal agents, though approximately half of cases have no risk factor).⁵

In most cases of TINU, uveitis follows the renal disease, but approximately 20% of the time, it may precede systemic pathology, sometimes by as much as a year.⁵ While recurrence of uveitis is common, long-term visual prognosis is good. Kidney disease tends to resolve completely with treatment, and renal function remains good.⁵

Given the patient's disease, age and health history, we ordered HLA-B27, urine beta-2 microglobulin, urinalysis and antistreptolysin O titer testing. Of these, only beta-2 microglobulin was positive, yielding 1,997mg/dL compared with the normal range of 0mg/dL to 300mg/dL. This test is a good marker in

identifying renal dysfunction, even with normal renal function results, and correlates with TINU in patients with uveitis that matches the profile of bilateral AAU. The test is so sensitive that the authors of one review theorize that with the correct patient and uveitis profile, it may be able to altogether replace renal biopsy, the historic standard for disease confirmation.⁴

Given the likelihood of this underlying disease, the patient's uveitis was treated in our office, but he was referred to pediatric nephrology for further evaluation.

This case illustrates the diagnostic utility of fully classifying uveitis. Failing to understand that bilateral AAU is an unusual class and is often associated with systemic pathology may prompt an OD to opt out of further workup if a patient's review of systems is negative. Recognizing the uniqueness of this case, we pivoted to an appropriate differential, ordered a reasonable series of blood work and got the patient to a subspecialist to monitor kidney function for the best outcome. **BCCL**

1. Mapstone R, Woodrow HC. HL-A 27 and acute anterior uveitis. *Br J Ophthalmol.* 1975;59(5):270-5.

2. Birnbaum AD, Jiang Y, Vasaiwala R, et al. Bilateral simultaneous-onset nongranulomatous acute anterior uveitis. *Arch Ophthalmol.* 2012;130(11):1389-94.

3. Mackensen F, Smith JR, Rosenbaum JT. Enhanced recognition, treatment, and prognosis of tubulointerstitial nephritis and uveitis syndrome. *Ophthalmology.* 2007;114(5):995-9.

4. Mackensen F, David F, Grulich-Henn J, et al. Urinary beta-2 microglobulin levels reveal a high incidence of tubulointerstitial nephritis and uveitis syndrome (TINU) in children with sudden onset, bilateral, anterior uveitis. *Invest Ophthalmol Vis Sci.* 2007;48:3901.

5. Mandeville JT, Levinson RD, Holland GN. The tubulointerstitial nephritis and uveitis syndrome. *Surv Ophthalmol.* 2001;46(3):195-208.

Corneal GPs are Here to Stay

This modality has much to offer both practitioners and patients—just don't forget these key tips at the onset.

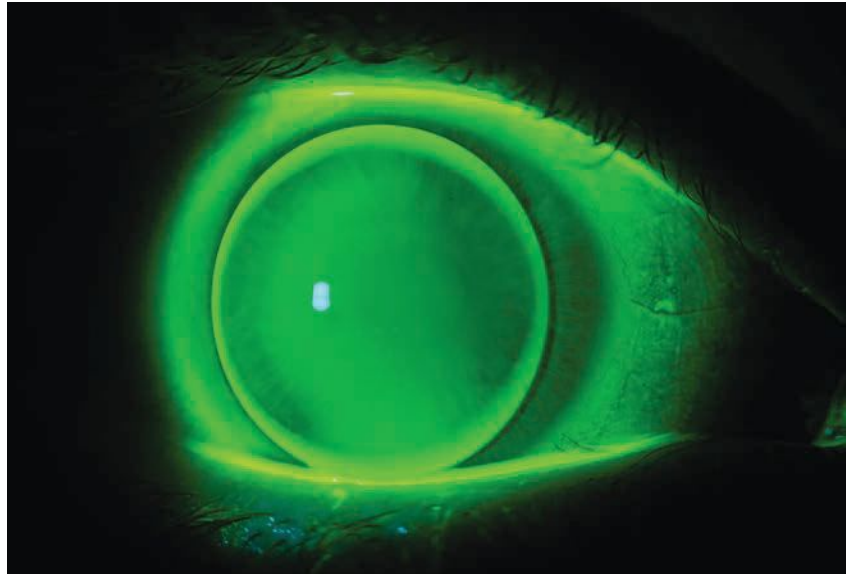
There are many reasons to promote corneal gas permeable (GP) lenses as a modality in your specialty contact lens practice. For patients with regular corneas, soft lenses have become increasingly popular as parameters expand and toric designs improve. The optics of a corneal GP lens are likely going to beat out the best soft contact lens designs available in the case of significant astigmatism, however.

For patients with irregular corneas, scleral lenses have become a practitioner favorite due to their smooth transition and adaptation period and high rate of success when it comes to vision and comfort. Unfortunately, fitting all corneal irregularities with a scleral lens is hard to justify. This is where corneal GPs come in. This modality is associated with fewer health risks and is less complicated than scleral lenses.

One of the barriers to entry in fitting a corneal GP is the work involved in getting a first-time wearer adapted to the lenses. There are several simple steps to include in your fitting process to make the transition easier on you and your patients.

POST-REFRACTIVE SURGERY

Educating. Before you fit corneal GPs, consider how to prepare your patients. There is an association between the type of language practitioners use to introduce patients to GP lenses and the dropout rate. Using terms like “pain” or “discomfort” greatly



Successful GP fits rely on an effective mix of patient education, lens design choices and savvy assessment of the patient's physical and psychological needs.

increased the chances that a patient would not continue with the lenses. Terminology like “lens awareness” and “lid adaptation” was met with more favorable outcomes.

Expressing enthusiasm when presenting GPs as an option also increases the likelihood of patient success with the modality. Offer stories of patients who were happy with their corneal GP lenses to set the stage for new patients to have a similar experience.

Ordering. We recommend ordering corneal GP lenses empirically so that the first lens your patient experiences will be one that was designed specifically for them. Take advantage of online calculators, do your own calculations or employ the assistance of laboratory consultants when you conduct

a diagnostic fitting. Compared with trial lenses, a set of lenses personalized for your patient will offer better comfort and optimized optics—the biggest motivators for adapting to a corneal GP.

We recently dispensed empirically ordered lenses for a first-time GP wearer who exclaimed that they were “a miracle.” Patients who have a positive first experience with corneal GPs will be more motivated to commit to the adaptation process and will, in turn, see better results.

Coating. We've also found success ordering corneal GP lenses with Hydra-PEG coating (Tangible Science) for first-time wearers. We order the coating if the lenses are not wetting well, there are deposits present or comfort is less than satisfactory. This coating makes



OPHTHALMIC

Product Guide

the lenses slicker and reduces friction in the eye as the eyelids make contact with the lens.

For first-time lens wearers, assume comfort will be an issue during the adaptation process. Preemptively offering Hydra-PEG offers a smoother initial awareness period.

Introducing. We suggest instilling a topical anesthetic before applying GP lenses. Doing so dramatically improves a patient's first interaction with the lenses by offering a more gradual introduction to a new modality.

As you evaluate the fit and vision of the lenses, the anesthetic begins to wear off. This way, the patient will become more aware of the lenses on their eyes over time for a more comfortable initial experience. Patients will be much more likely to continue with the modality if they're not thrown into it unprepared.

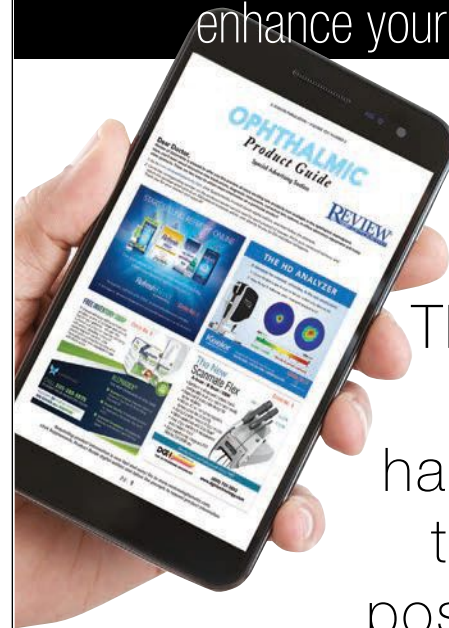Scheduling. Talk with your patient about gradually easing into a more consistent daily wear schedule. There is a physiological adaptation factor that contributes to the comfort of a GP lens. For most patients, lens awareness does not go away after one day of lens wear. Encourage the patient to wear the lenses for an hour the first day, a few more the next and so on. Let the patient know that over the first week or two, their eyes will adapt to feel of the lenses and they will be able to wear them for longer periods of time.

If a patient expects to be able to follow a normal lens wear schedule the day after their dispensing visit, they may give up on GPs when they instead find themselves struggling with discomfort.

Corneal GPs have been around for decades and have held a steady percentage of the contact lens market for the last several years, even in the face of increasingly successful soft lenses. This modality addresses corneal irregularity, offers pristine multifocal optics and improves comfort in ocular surface disease, to name a few benefits. Keep the tips we provided in mind and you'll be on your way to successfully fitting corneal GPs in no time. **RECL**

Dr. Melchione completed a residency in cornea and contact lenses this year and will be practicing in Blacksburg, VA.

Innovative products to
enhance your practice



The future
is in your
hands. One
tap, many
possibilities.

Experience the digital edition on
your handheld device. Use your
smart device to scan the code
below or visit:

www.reviewofoptometry.com/publications/archive

Download a QR scanner app. Launch app and hold your
mobile device over the code to view
<https://www.reviewofoptometry.com/publications/archive>



REVIEW[®]
OF OPTOMETRY



Don't Burst Your Bubble

Conjunctival lymphangiectasis may be cosmetically troubling to patients but these benign lesions should be left undisturbed.

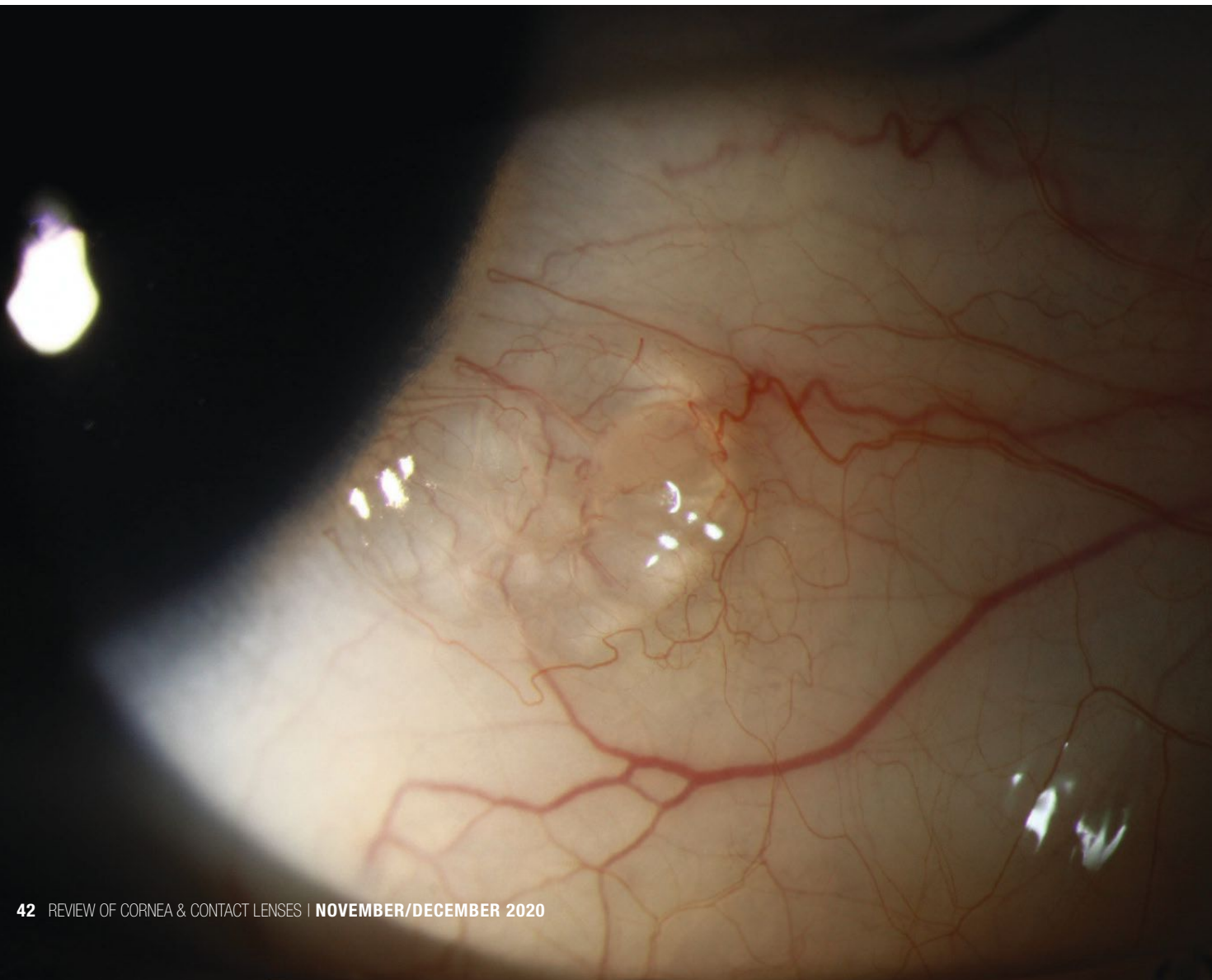
A 17-year-old female presented for a contact lens and ocular health exam. She said she had noticed a “bubble” on her eye. It was not painful but she stated she has been “trying to pop it.” She reported no change in her vision and her slit lamp exam was otherwise unremarkable. She was diagnosed with conjunctival lymphangiectasis and was told to stop trying to remove it, as it is a normal part of her eye.

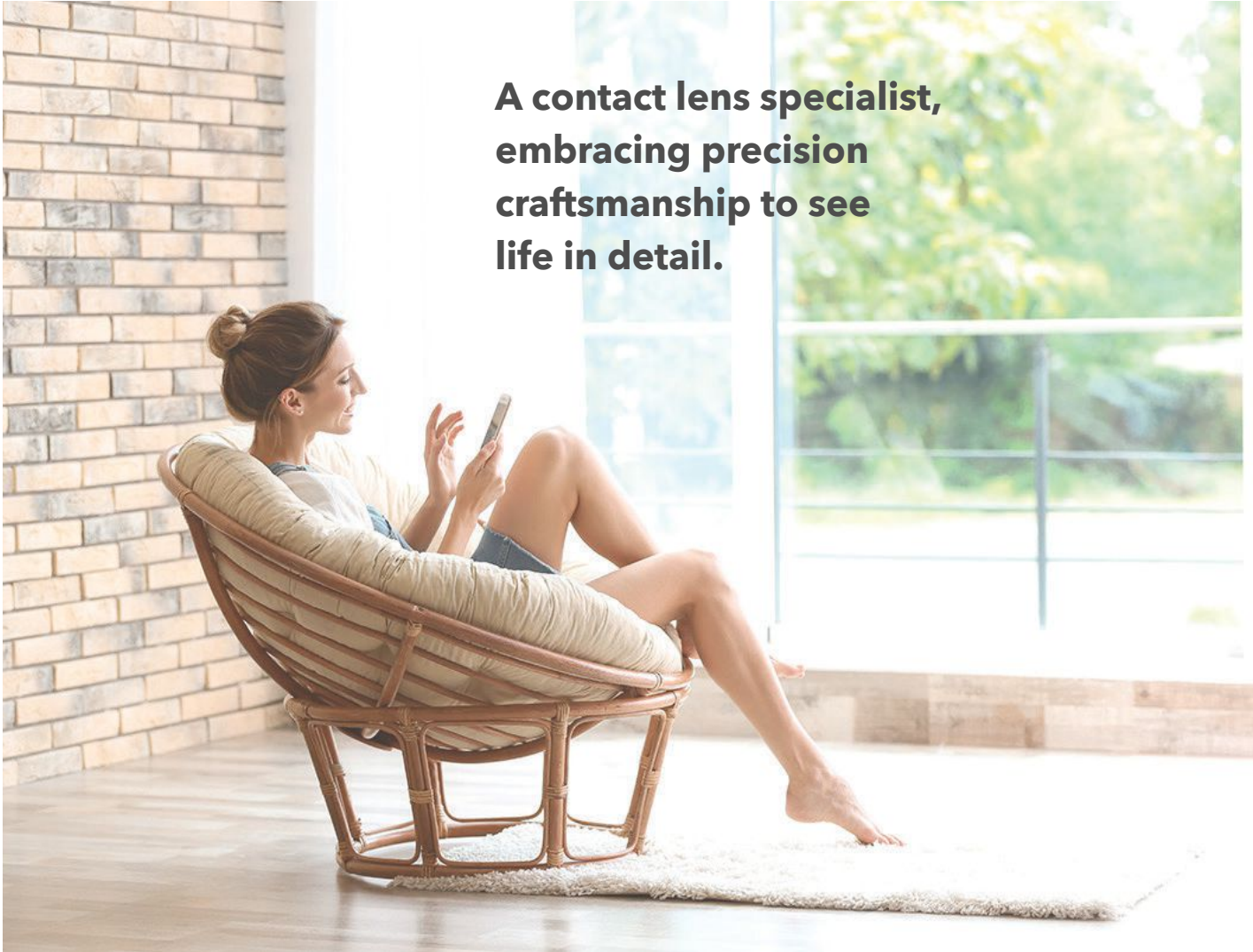Conjunctival lymphangiectasis is a condition wherein subconjunctival fluid accumulates from dilated conjunctival lymphatic channels. It can be seen most readily on the bulbar conjunctiva.¹ The bubble will often have a cystic appearance and may be clear or yellow. Elevated lymphatic channels are separated by translucent septate walls.

The etiology is unknown, but the condition is presumed to involve obstructed lymphatic channels.

There is one report in the literature that defines conjunctival lymphangiectasis as an under-recognized ocular sign in the presence of Fabry's disease.¹ Although conjunctival lymphangiectasis is considered benign, clinicians should remain vigilant for signs of bilateral corneal verticillata in order to rule out Fabry's. [RCCU](#)

1. Sivley MD, Wallace EL, Warnock DG, Benjamin WJ. Conjunctival lymphangiectasia associated with classic Fabry disease. *Br J Ophthalmol.* 2018 Jan;102(1):54-58.





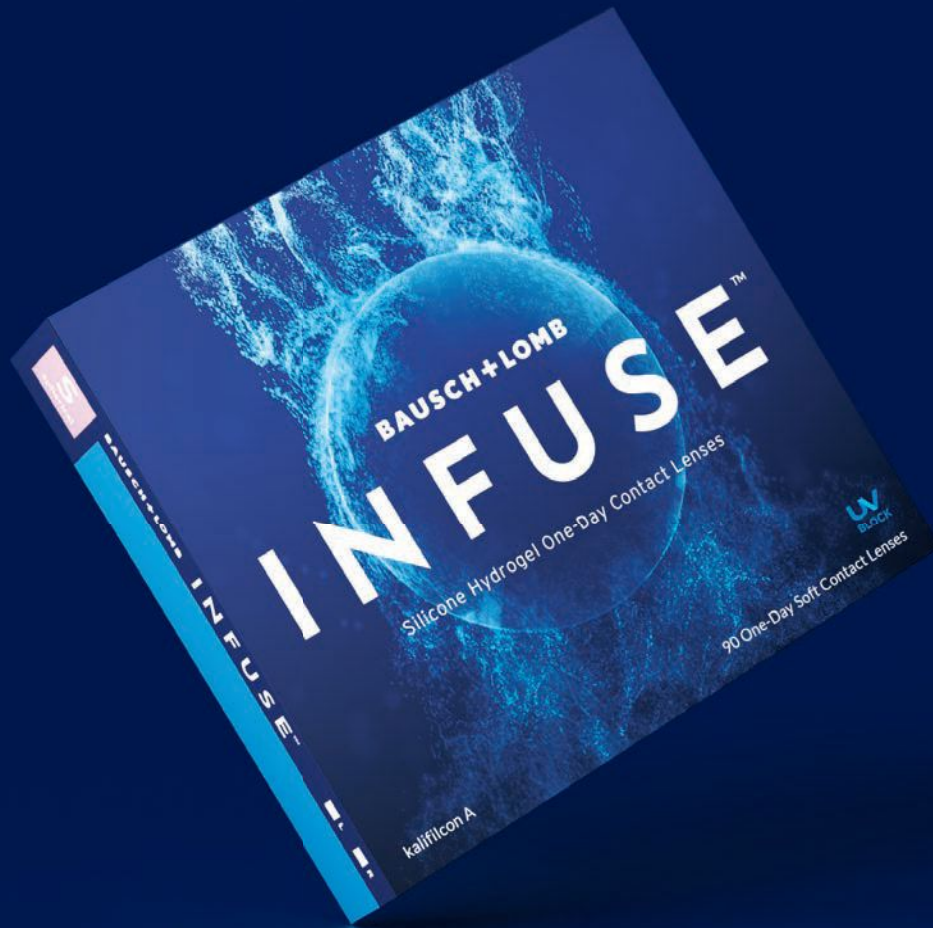**A contact lens specialist,
embracing precision
craftsmanship to see
life in detail.**



**Menicon is a contact lens
manufacturer born in Japan.**

For over 60 years, Menicon has been a pioneer in contact lens innovation, delivering groundbreaking contact lenses and lens care solutions across the globe.

To learn more, visit: www.meniconamerica.com



INFUSED FOR BALANCE

The only silicone hydrogel daily disposable with a next-generation material infused with ProBalance Technology™ to help maintain ocular surface homeostasis¹



Next-Generation
Material



Ocular Surface
Homeostasis



ProBalance
Technology™

Find balance at [BauschINFUSE.com](https://www.BauschINFUSE.com)

REFERENCE: 1. Data on file. Bausch & Lomb Incorporated. Rochester, NY.

®/™ are trademarks of Bausch & Lomb Incorporated or its affiliates.
©2020 Bausch & Lomb Incorporated or its affiliates. INF.0084.USA.20

BAUSCH+LOMB

See better. Live better.