

RCCL®

REVIEW OF CORNEA & CONTACT LENSES

CONTACT LENS

BAUSCH + LOMB ULTRA® MULTIFOCAL FOR ASTIGMATISM

WHY MAKE 32 MILLION* PATIENTS WAIT?

The time for same-day multifocal toric fitting is now. Unlike other brands, **Bausch + Lomb ULTRA® Multifocal for Astigmatism** is available in office to save time and reduce follow-ups. Prescribe the only multifocal toric lens with **same-day convenience**.

*Estimated number of astigmatic presbyopes in the US.



®/™ are trademarks of Bausch & Lomb Incorporated or its affiliates.

©2020 Bausch & Lomb Incorporated or its affiliates. UMT.0128.USA.20

RCCL[®]


REVIEW OF CORNEA & CONTACT LENSES

CONTACT LENS PROBLEM SOLVING

Here's how to work through the puzzles posed by dry eyes, abnormal lids, tricky topographies, lens deposits and more.

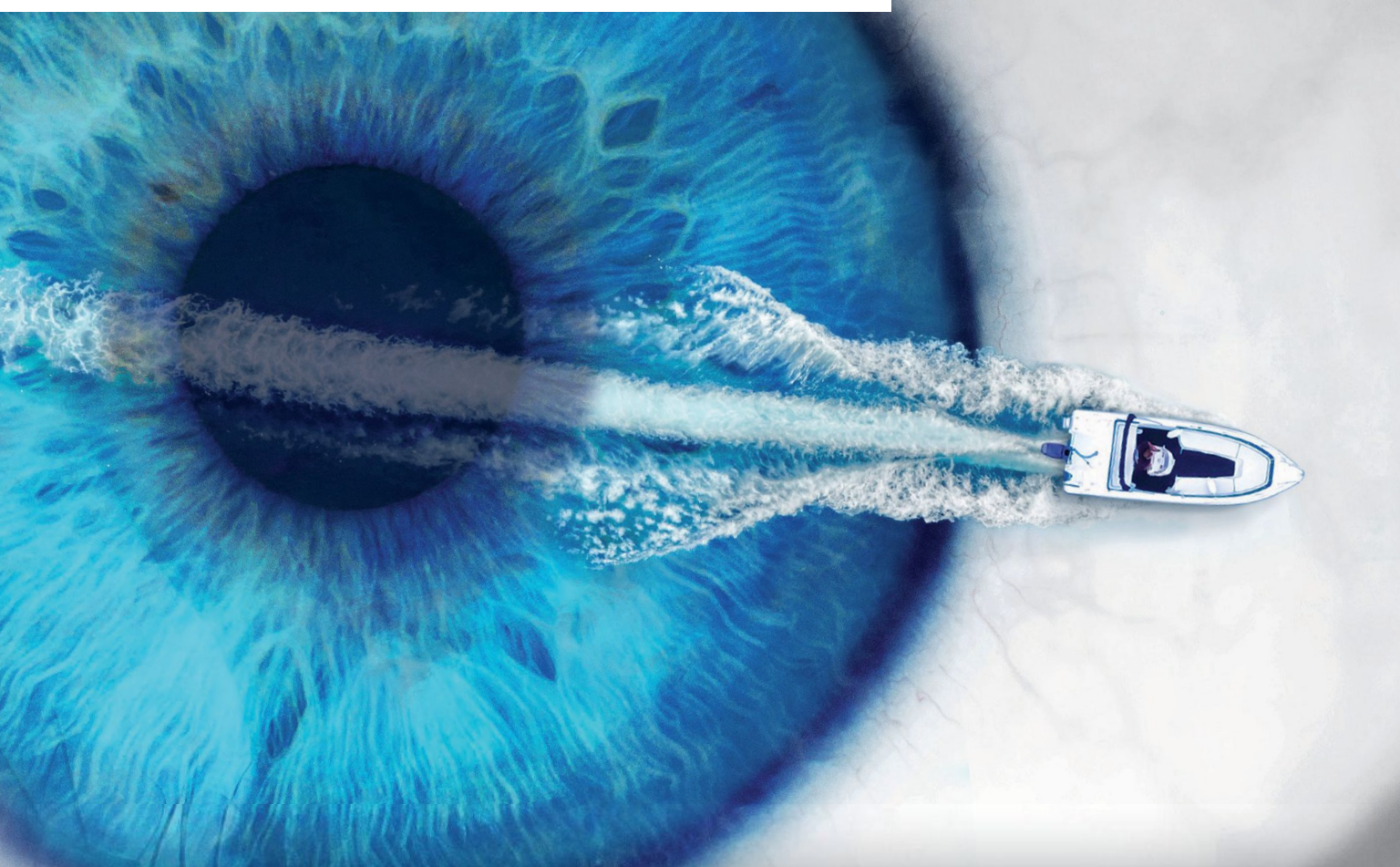
- Fixing Ocular Surface Impediments to GP Lens Wear, p. 8
- Lids and Lenses: Three Snags to Success, p. 14
- Five Conjunctival Findings to Look Out For in Contact Lens Wearers, p. 18
- Irregular Corneas Meet Their Match With GP Lenses, p. 22
- Soft or Scleral Lenses for Dry Eye Patients?, p. 26
- The How and Why of Contact Lens Deposits, p. 30 —EARN 2 CE CREDITS
- Embrace the Oddball Cases and Thrive, p. 40

ALSO: CONTACT LENS WEAR AND COVID-19 • TRIAL LENS SAFETY • DEMODEX • SCLERITIS



NEW Cornea Scleral Profile Scan for Pentacam®

Beyond the Cornea!



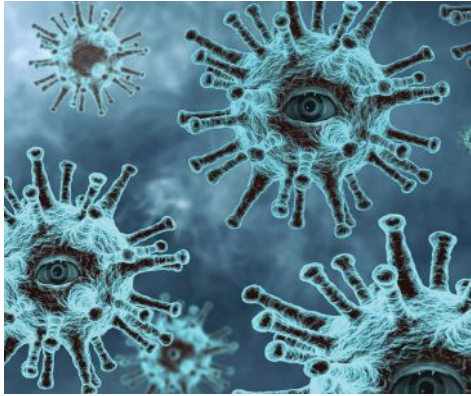
Pentacam® CSP Report – a new level of accuracy

Measure beyond past boundaries when fitting scleral lenses. The new CSP Report creates 250 images within the measuring process. The tear film independent measurement with automatic release allows coverage up to 18 mm with the same fixing point.

Visit www.pentacam.com to learn more

contents

Review of Cornea & Contact Lenses | May/June 2020



departments

- 4 News Review**
COVID-19 exposure; epi-on CXL and corneal haze
- 6 My Perspective**
Time to Rethink Trial Lens Safety?
By Joseph P. Shovlin, OD
- 8 The GP Experts**
Fixing Ocular Surface Impediments
By Lindsay Sicks, OD
- 38 Fitting Challenges**
When Lashes, Not Lenses, are the Problem
By Vivian P. Shibayama, OD
- 40 Practice Progress**
Embrace the Oddballs
By Mile Brujic, OD, and David Kading, OD
- 42 The Big Picture**
Vessels Sound the Alarm
By Christine W. Sindt, OD

features

11

Four Reasons Contact Lens Wear Isn't a Problem With COVID-19

Despite conflicting reports, patients are just as safe as ever, as long as they adhere to proper wear and care instructions.

By Daddi Fadel, DOptom

14

Lids and Lenses: Three Snags to Fitting Success

Surgical and anatomical considerations could throw a wrench in your contact lens fitting process. Here's what to keep in mind.

By Steven Turpin, OD, and Leonid Skorin Jr., OD, DO, MS

18

Five Conjunctival Findings to Look Out For in Contact Lens Wearers

Learn the basics so you can better manage these conditions in your patients.

By Paymaun Asnaashari, OD

22

Irregular Corneas Meet Their Match with GP Lenses

These other modalities can provide solutions and improve vision in these unique cases.

By Tiffany Andrzejewski, OD, and John Gelles, OD

26

Soft or Scleral Lenses For Dry Eye Patients?

Determine the best option that treats your patient's symptoms and expectations.

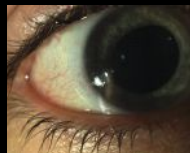By David Sweeney, OD

30

CE: The How and Why of Contact Lens Deposits

Optometrists need a comprehensive understanding of this complication to help patients avoid it.

By Heidi Wagner, OD, MPH



IN BRIEF

■ For low to intermediate levels of myopia—with or without regular astigmatism—**macular OCT imaging didn't improve with the placement of a soft or gas permeable contact lens.** They found no added benefit in removing a spherical soft lens in habitual wearers prior to scanning. Their study also found no correlation between sphere power and the change in image quality in any of the three groups, nor were differences observed between OCT-derived macular thickness measurements from scans with and without a contact lens.

Aviram T, Beeri I, Berkow D, et al. The effect of contact lens wear on retinal spectral domain optical coherence tomography. *Clin Exp Optom.* March 30, 2020. [Epub ahead of print].

■ Researchers suggest the prevalence of patient-reported scleral lens midday fogging is similar to previously reported rates. An electronic survey distributed to scleral lens practitioners asked them to describe their most recent established scleral lens patient. As far as risk factors go, the study notes that **no specific lens design or care product is associated with midday fogging.** Of the 248 survey respondents, 25.8% had patients who self-reported midday fogging. Patients who reported midday fogging more commonly reported redness or irritation associated with scleral lens wear.

Schorneck MM, Fogt J, Harthan J, et al. Factors associated with patient-reported midday fogging in established scleral lens wearers. *Cont Lens Ant Eye.* March 20, 2020. [Epub ahead of print].

■ **For keratoconus patients, contact lens fit, wearing comfort and cost may be more important than lens performance** even in the most advanced designs. A study measured spatial vision, stereoacuity and optical quality in 28 KCN patients and 10 controls in spectacle lenses, gas permeable, Kerasoft, Rose K2 and scleral rigid GP lenses. **All outcomes deteriorated with keratoconus severity and improved with lens wear relative to spectacles.** The improvement was smaller for Kerasoft lenses and higher but comparable for the other three designs across all disease severities. Visual function and optical quality outcomes never reached control levels for any correction modality, the investigators said.

Kumar P, Bandela PK, Bharadwaj SR. Do visual performance and optical quality vary across different contact lens correction modalities in keratoconus? *Cont Lens Ant Eye.* March 29, 2020. [Epub ahead of print].

Keeping Patient COVID-19 Exposure Low

Two studies have provided several considerations to take into account to limit exposure to COVID-19.

CONTACT LENS RISKS

While no current findings support concerns that healthy contact lens wearers are at a higher risk of contracting COVID-19, these patients should be aware of certain factors to remain safe in their lenses.¹

First, switching to spectacle wear may actually pose a greater risk of exposure, as intermittent use increases face touching, and plastic surfaces serve as virus transmitters.

Second, with how often we touch our faces, proper hygiene becomes even more crucial. This includes washing hands with soap and water for at least 20 seconds after encountering anything that may not have been disinfected, using hand sanitizer containing at least 60% alcohol if soap and water are not readily available and avoiding touching mucous membranes with unwashed hands. Contact lens wearers should be well-versed in hand-washing, especially before inserting and removing lenses.

Third, the report adds that no contact lens material is more likely to enhance or reduce the risk of COVID-19, but following the recommended replacement schedule is more important than ever. It notes that daily disposable contact lenses substantially diminish the risk of inflammatory complications and should be disposed of each evening. Monthly and two-week lenses should be disinfected regularly and according to manufacturer instructions. Contact lens use should be

discontinued if a patient falls sick or receives a positive diagnosis.

As the situation evolves, so too does new guidance. Now more than ever, clinicians must look to patient communication and compliance for the best chance at success.¹

OCULAR SURFACE SAFE

Researchers recently found that inpatients and hospital workers could be exposed to COVID-19 through the eyes; however, the incidence of COVID-19 transmission through the ocular surface is extremely low overall. To lower the risk of exposure, the researchers support the push for all health care professionals to wear protective goggles.²

This cross-sectional study evaluated 102 patients with a positive COVID-19 diagnosis. The 48 males and 54 females were an average of 57.63 years old.

The team discovered that 72 of the total patients identified were confirmed to have COVID-19 by laboratory diagnosis. Of this smaller cohort, they noted that only two patients (2.78%) had conjunctivitis. They added that only one of the two patients had COVID-19 RNA fragments in their ocular discharge.

“The inefficient diagnostic method and the sampling time lag may contribute to the lower positive rate of conjunctival swab samples of COVID-19,” the study authors concluded in their paper.²

1. Jones L, Walsh K, Willcox M, et al. The COVID-19 pandemic: important considerations for contact lens practitioners. *Cont Lens Ant Eye.* April 3, 2020. [Epub ahead of print].

2. Zhang X, Chen X, Chen L, et al. The evidence of SARS-CoV-2 infection on ocular surface. *Ocul Surf.* April 11, 2020. [Epub ahead of print].

19 Campus Blvd., Suite 101
Newtown Square, PA 19073
Telephone (610) 492-1000
Fax (610) 492-1049

Editorial inquiries: (610) 492-1006
Advertising inquiries: (610) 492-1011
Email: rccl@jobson.com

EDITORIAL STAFF

EDITOR-IN-CHIEF

Jack Persico jpersico@jobson.com

MANAGING EDITOR

Rebecca Hepp rhepp@jobson.com

ASSOCIATE EDITOR

Catherine Manthorp cmantorp@jobson.com

ASSOCIATE EDITOR

Mark De Leon mdeleon@jobson.com

CLINICAL EDITOR

Joseph P. Shovlin, OD, jpshovlin@gmail.com

ASSOCIATE CLINICAL EDITOR

Christine W. Sindt, OD, christine-sindt@uiowa.edu

EXECUTIVE EDITOR

Arthur B. Epstein, OD, artepstein@artepstein.com

CONSULTING EDITOR

Milton M. Hom, OD, eyemage@mminternet.com

GRAPHIC DESIGNER

Jared Araujo jaraujo@jhihealth.com

AD PRODUCTION MANAGER

Farrah Aponte faponte@jobson.com

BUSINESS STAFF

PUBLISHER

James Henne jhenne@jobson.com

REGIONAL SALES MANAGER

Michele Barrett mbarrett@jobson.com

REGIONAL SALES MANAGER

Michael Hoster mhoster@jobson.com

EXECUTIVE STAFF

CEO, INFORMATION SERVICES GROUP

Marc Ferrara mferrara@jhihealth.com

SENIOR VICE PRESIDENT, OPERATIONS

Jeff Levitz jlevitz@jhihealth.com

**SENIOR VICE PRESIDENT,
HUMAN RESOURCES**

Tammy Garcia tgarcia@jhihealth.com

**VICE PRESIDENT,
CREATIVE SERVICES & PRODUCTION**

Monica Tettamanzi mtettamanzi@jhihealth.com

VICE PRESIDENT, CIRCULATION

Emelda Barea ebarea@jhihealth.com

CORPORATE PRODUCTION MANAGER

John Caggiano jcaggiano@jhihealth.com

EDITORIAL REVIEW BOARD

Mark B. Abelson, MD
James V. Aquavella, MD
Edward S. Bennett, OD
Aaron Bronner, OD
Brian Chou, OD
Kenneth Daniels, OD
S. Barry Eiden, OD
Desmond Fonn, Dip Optom, M Optom
Gary Gerber, OD
Robert M. Grohe, OD
Susan Gromacki, OD
Patricia Keech, OD
Bruce Koffler, MD
Pete Kollbaum, OD, PhD
Jeffrey Charles Krohn, OD
Kenneth A. Lebow, OD
Jerry Legerton, OD
Kelly Nichols, OD
Robert Ryan, OD
Jack Schaeffer, OD
Charles B. Slonim, MD
Kirk Smick, OD
Mary Jo Stiegemeier, OD
Loretta B. Szcotka, OD
Michael A. Ward, FCLSA
Barry M. Weiner, OD
Barry Weissman, OD



Post-CXL Haze Resolves By One Year After Treatment

Keratoconus (KCN) patients who undergo transepithelial, or “epi-on,” corneal collagen crosslinking (CXL) may have haze issues in the months following treatment, but this should resolve within a year of the procedure, a study in *Cornea* reports.

The researchers found that after epi-on CXL, corneal haze increased slightly at one month, plateaued between months one and three and returned to baseline between three and 12 months.

“Transepithelial CXL appears to be effective in decreasing maximum keratotomy and uncorrected vision in KC but perhaps less robust than standard CXL,” researcher Peter S. Hersh, MD, says. “Corneal haze associated with CXL is substantially less using the transepithelial technique. How this relates to procedure efficacy remains unclear.”

The team enrolled 59 eyes of KCN patients who underwent epi-on CXL and then were randomized into two groups. Group one re-

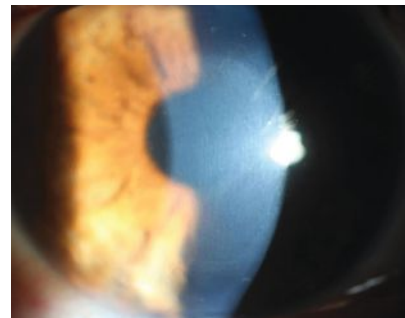


Photo: Clark Chang, OD, and Aaron Bronner, OD

Corneal haze post-CXL improves between three and 12 months.

ceived riboflavin 0.1% every minute and group two received treatment every two minutes during ultraviolet exposure. Scheimpflug densitometry was measured pre-op and at one, three, six and 12 months. The researchers also correlated densitometry measurements with visual acuity (VA), pachymetry and topography results.

Baseline pre-op corneal densitometry was 20.45 ± 2.79 , which increased at one month (22.58 ± 3.79). While no significant change was observed between months one and three (22.64 ± 3.83), a significant improvement was noted after month six and 12 (21.59 ± 3.39 and 20.80 ± 3.27 , respectively).

No difference was found between preoperative densitometry measurements and those taken at one year.

The study also found that corneal densitometry readings at three months and one year didn't appear to correlate with uncorrected distance VA, corrected distance VA or maximum keratometry one year after CXL. **RCCL**

CXL PROTOCOLS TESTED

Researchers from New Zealand recently compared the corneal densitometry changes after three styles of accelerated CXL: transepithelial pulsed (t-ACXL), epithelium-off continuous (c-ACXL) and epithelium-off pulsed (p-ACXL). They found that c-ACXL induced more corneal haze than either p-ACXL or t-ACXL in the early post-op period, but these differences resolved in approximately six months.

Kocabeyoglu S, Colak D, Mocan M, et al. Sensory adaptation to silicone hydrogel contact lens wear is not associated with alterations in the corneal subbasal nerve plexus. *Cornea*. 2019;38(9):1142-6.

Nanji A, Redd T, Chamberlain W, et al. Application of corneal optical coherence tomography angiography for assessment of vessel depth in corneal neovascularization. *Cornea*. December 20, 2019. [Epub ahead of print].



Time to Rethink Trial Lens Safety?

When handling the same contacts with multiple patients, remember these in-office tips.

Eye care providers have struggled with, and often debated, the best practices for caring for multi-patient, reusable trial contact lenses. Disposable lenses are available in many parameters, obviating the need for reusable trial lenses in many cases. Nevertheless, we're still called upon to care for trial lenses with the resurgence of scleral lens use. Using these lenses has forced us to take another look at in-office, multi-patient guidelines, especially in light of the COVID-19 pandemic.

HYGIENIC STANDARDS

An excellent summary of in-office handling of reusable trial lens suggestions is available using the standards from the International Organization for Standardization (ISO).¹ In addition, the contact lens groups of the American Academy of Optometry and the American Optometric Association have updated guidelines for in-office disinfection of trial lenses.²

For those who haven't already digested the main elements of the 2018 ISO guidelines, these pertinent key points might help you and your staff ensure minimal transmission risk of any infection to your patients, especially since office staff hygiene can be a significant factor in disease transmission.³

The ISO 19979 provides guidance to manufacturers for the development of information provided to eye care practitioners for the hygienic management of trial hydrogel, composite and rigid gas permeable contact lenses intended for multi-patient use.^{1,3} These documents are updated every five years. Within the

guidelines, contact lenses are categorized by material and design, listed as rigid, soft or hybrid lenses.

Remember, our patients potentially are exposed to a wide variety of pathogens when subjected to reusable trial lenses in our office. The wide range of pathogens could include both gram-positive and gram-negative bacteria, fungi (mold and yeast), protozoa and several different viruses, whose survivability depends on lens material and variations in polymer differences.³

A vigorous rub and rinse of any lens surface will easily remove a good portion of any microbial contamination, along with most deposits, particulate and debris.³ Train staff and reinforce this important first step. Keep in mind that several disinfection methods depend on lens type and material. Remember, while the recommended steps do not sterilize, following them does more than simply sanitize lenses.

In order to ensure safety, employ a broad-spectrum disinfectant. Chemical disinfecting solutions have not been tested for HTLV-III/LAV efficacy, so oxidative systems seem to win the day.¹ A three-hour, non-neutralizing soak in 3% hydrogen peroxide seems to be the most effective eradicator of pathogens and is recommended for all lenses. Soft and hybrid lenses should then be placed in a neutralizing case with fresh 3% hydrogen peroxide for a minimum of six hours, rinsed and then stored in a multi-purpose disinfecting solution and disinfected case.

SYSTEMS IN CHECK

It's key for eye care providers and staff to keep these things in mind:

(1) Ensure consistent handwashing with soap and water for at least 20 seconds and dry with clean paper towels for technicians, providers and patients.

(2) Carefully inspect each lens after cleaning with a vigorous rub and rinse.

(3) Always use approved rinses with sterile solution after disinfecting trial lenses.

(4) Avoid tap or well water exposure after disinfecting.

(5) Use clean, new cases for storage.

(6) Color-code bottles with stickers depending on in-office expiration.

(7) Repeat the disinfection cycle every three to six months even without use; if bottles are opened and not reused, repeat disinfection steps every month.

Be mindful to record the dates and number of clinic uses for every trial lens. Consult each manufacturer on their disposal recommendations after so many uses.

A special thank you to the many individuals who have worked tirelessly on the updated guidelines. Kudos to our eye care groups who have collaborated in such a collegial fashion. **RECL**

1. ISO. Ophthalmic optics—contact lenses—Hygienic management of multi-patient use trial contact lenses. www.iso.org/standard/67859.html. March 2018. Accessed April 6, 2020.

2. AAO, AOA. In-office disinfection of multi-patient use diagnostic contact lenses. files.constantcontact.com/fd2dfe10101/b82a6f1b-8373-42f9-9a25-72ff50af9d64.pdf. March 17, 2020. Accessed April 6, 2020.

3. The AOA Health Policy Institute. Disinfection of multi-patient contact lenses in the clinical setting. www.aoa.org/documents/HPI/HPI_Report_Disinfection_of_Multipatient_CLs_in_the_Clinical_Setting_2018.pdf. October 2018. Accessed April 6, 2020.



SAVE THE DATE

OCTOBER 7-10, 2020

MUSIC CITY CONVENTION CENTER

Over **400** hours
of CE offered.

24 CE hours dedicated
to contact lenses.

CONTACT LENS LECTURE & SYMPOSIA SCHEDULE

Wednesday, October 7, 2020

The Science and Art of Presbyopic Contact Lens Fitting

Thomas G. Quinn, Edward Bennett

Scleral Topographers: Making Better Scleral Lenses

Jason G. Jedlicka

An Overview to Geriatric Contact Lens Fitting

JulieAnne M. Roper

Thursday, October 8, 2020

Burning Hot Topics in Myopia Control Contact Lenses

Kate L. Gifford, Paul Gifford

Rapid Fire: Scleral Contact Lenses for Treatment of Pediatric Eye Diseases

Elaine Chen, Nurit A. Wilkins, Abigail Harsch, Colton Heinrich

Pediatric Aphakic Contact Lenses

Nidhi Rana

Visual Discomfort and Contact Lens Wear

Erin M. Rueff

Rapid Fire: Scleral Lenses for Everything but Keratoconus

Julie DeKinder, Jonathan Chen, Matthew K. Lee, Jessica Tu

Friday, October 9, 2020

Section on CCLRT Symposium: Myopia Management: "The Evidence is in...Now Let's Make this Happen!"

Louise A. Sclafani, Susan A. Resnick, Jeffrey J. Walline

Presbyopia: The Correction Conundrum

Douglas P. Benoit

Scleral Lens Fitting Challenges

Gregory W. DeNaeyer

Do No Harm - When and When Not to Fit Scleral Lenses

Alan Kwok, Gloria B. Chiu

Current Trends in Colored Therapeutic and Prosthetic Contact Lenses

Marsha M. Malooley, Melanie J. Frogozo

Improving Contact Lens Care and Compliance

Andrew D. Pucker

Saturday, October 10, 2020

Best Keratoconus Contact Lenses, Explained

Langis Michaud, Clark Y. Chang, Daniel Brazeau

Myopia Control Orthok Lenses for Kids

Randy Kojima, Patrick J. Caroline

Managing Mild to Advanced Keratoconus with Corneal GP Lenses

Dawn Y. Lam, Annie Chang

Implementing Myopia Control with Standard and Specialty Lenses

Andrew D. Pucker, Katherine Bickle

Scleral Lens Risks: Fact or Fiction?


Jason G. Jedlicka, Gee Stephanie

Topography and Contemporary Corneal GP Lens Fitting

Matthew Lampa, Mari Fujimoto, Patrick J. Caroline



AMERICAN ACADEMY
of OPTOMETRY



REGISTRATION OPENS ON MAY 12, 2020. LEARN MORE AT WWW.ACADEMYMEETING.ORG.

Fixing Ocular Surface Impediments

Corneal staining and lens non-wetting are common complications that refitting and proper hygiene education can help resolve.

When fitting any type of gas permeable (GP) contact lens, issues with dryness and non-wetting can arise. They can often occur if a patient has a poor-quality tear film, improper lid hygiene or lens handling or demonstrates non-compliance with the prescribed care regimen. Lens fit and care system changes along with periodic lens replacement can help address these concerns.

CASE ONE

A 23-year-old Hispanic male with keratoconus presented for a contact lens evaluation wearing ill-fitting, three-year-old GP corneal lenses. He noted occasional dryness with his lenses but found relief with occasional use of artificial tears.

We diagnostically fit and ordered a new pair of aspheric corneal lenses with the addition of a toric peripheral curve system. Toric peripheries are indicated when topography suggests the steeper inferior cornea is inferiorly displaced and causes the lower edge of the lens to lift up and irritate the lower eyelid.¹ The patient achieved 20/20 vision OU, but, a few weeks later, he again complained of increased dryness and discomfort OU during the latter half of his daily wear time. The patient did admit he was not rubbing the lenses with the multipurpose GP lens cleaning solution for the recommended length of time at night.

After adding sodium fluorescein, we noted moderate staining on the temporal side of each cornea, closer to the limbus. This type of staining

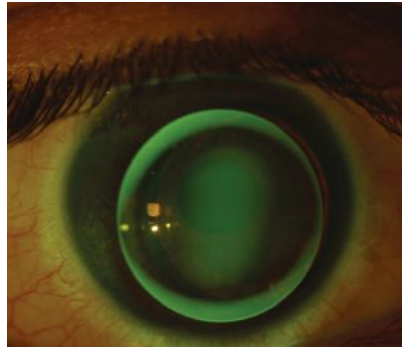


Fig. 1. Temporal corneal staining present at follow-up on a keratoconic corneal GP lens.

can occur in keratoconic patients who may have dry eye associated with atopic disease and meibomian gland dysfunction. Other causes of 3 o'clock and 9 o'clock staining are a thick edge profile or a high axial edge clearance.¹ We observed minimal edge clearance in the horizontal meridian of the lens, as opposed to high clearance (*Figure 1*).

We reordered the lens with a flatter edge and an increased toricity (1.3mm) in the periphery to improve comfort. We also initiated aggressive lubrication at nighttime, recommended warm compresses and proper lid hygiene and then reviewed proper rubbing with the multipurpose GP solution. Upon follow-up of the re-designed lens, the staining resolved and symptoms improved. The patient successfully wore the lenses for the following 18 months.

If 3 o'clock and 9 o'clock staining are present, increase the lens's overall diameter. This will cover more of the cornea, reduce exposure and improve comfort. Ensure appropriate edge thickness, edge clearance and movement. Address any tear

film abnormalities with tear supplementation and blinking exercises.²

CASE TWO

A 40-year-old African American male presented for his annual evaluation wearing a piggyback system for keratoconus OU. He complained of fogginess and reduced vision in the right eye that had been getting worse over the past six months. Vision in the left eye was stable, and the patient had recently purchased a replacement GP lens for that eye after breaking it when cleaning it a month ago. The blur OD was constant through all 16 hours of daily wear. He did not adhere to the recommended rubbing steps in either regimen due to fear of lens breakage. There was some apical scarring OS, limiting best-corrected vision. The tear break-up time was normal at 15 seconds per eye.

The patient's entering acuity was 20/50 OD and 20/300 OS. There was independent movement of both the soft lens and GP lens on each blink. The entering OD GP lens was showing extensive surface deposits (*Figure 2*). Factors that cause deposits include lens replacement frequency, hand contamination and tear film properties of the patient.³ The most common tear-derived lens deposits are proteins and lipids, which in-office cleaning can remove.³

Laboratory-grade cleaning solution in-office cleaned the GP lenses, leading to visual acuities 20/30 OD and 20/125 OS. Despite the improvement, we still recommended that a new GP lens be ordered for the right eye.

We reviewed with the patient

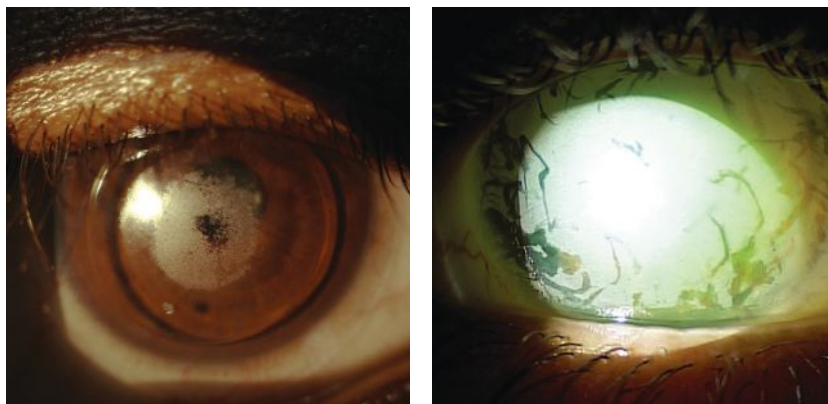


Fig. 2 and 3. Piggyback system with large central area of non-wetting on the GP lens (left). Extensive front surface non-wetting on a 16.0mm scleral lens (right).

proper lens care and hygiene, including how to properly rub the GP and soft lens to clean each appropriately without excessive force. The patient switched to a hydrogen peroxide-based care system. By using two cases, he could use the same solution for each of the four lenses, reduce confusion and increase adherence to our recommendations.

While GP lenses have a negligible water content and high modulus of elasticity that contribute to their long life expectancy, replace them periodically to ensure optimal wettability, comfort and vision.^{1,4,5}

CASE THREE

A 30-year-old Asian male presented one year overdue for an annual evaluation of his spherical scleral lenses. He was experiencing blurry vision OU at distance and near and had recently broken his habitual two-year-old scleral OD. He had a history of bilateral keratoconus and was s/p deep anterior lamellar keratoplasty OD, and s/p corneal crosslinking OS with a complicated

toric intraocular lens (IOL) implant OS. The ocular surface showed extensive tear film debris, reduced tear break-up time of three seconds and punctate conjunctival staining OU.

We had the patient apply the lens in-office for evaluation and found his entering acuity with the lens in place was 20/70 OS. The patient had been able to achieve 20/20 OS the year before with this spherical lens, which was unusual at the time, considering we expect to employ a front toric scleral design for full correction in a patient with a toric IOL. No over-refraction improved the acuity in this case, presumably due to the severe non-wetting. (Figure 3).

Tear film debris and poor lid hygiene, as well as lack of adherence to the prescribed cleaning regimen, were all contributing factors. We prescribed Clear Care (Alcon) nightly and advised the patient to fill the lens with preservative-free 0.9% NaCl inhalation saline for insertion. Instead, he used Boston Advance (Bausch + Lomb) cleaning

solution with no conditioner and did not heed our recommendation of monthly Progent (Menicon) use.

This non-wetting did not improve, even after use of in-office laboratory cleaner. We recommended the patient continue with his habitual spectacles until receiving his new pair of sclerals. A less oxygen permeable material could improve the wettability, and adding a surface coating might improve the lens's surface properties.

When investigating signs of dryness in the setting of any type of GP lens wear, it is crucial to determine the root cause of the problem. There can be ocular surface- and lens-related causes for any associated symptoms. In the case of untreated or undertreated dry eye disease, consider changing to a preservative-free care system or adding lubricating drops, gels or ointments. More aggressive management of any associated ocular surface disease is a boon to continued, comfortable lens wear. Don't forget about the lens surface either, as any areas of non-wetting can cause reduced vision and discomfort and warrant immediate lens cleaning or replacement. **CCCL**

1. Sorbara, L. Correction of keratoconus with GP lenses. Centre for Contact Lens Research, University of Waterloo. 2010.
2. Bennett ES, Weissman BA, ed. Clinical Contact Lens Practice. 4th Ed. Philadelphia, PA: Lippincott, Williams & Wilkins; 2005.
3. Efron N. Contact Lens Complications. 4th Ed. Philadelphia, PA: Elsevier; 2019.
4. Efron N. Contact Lens Practice e-Book. Elsevier Health Sciences. 2016.
5. Jones L, Woods CA, Efron N. Life expectancy of rigid gas permeable and high water content contact lenses. CLAO J. 1996;22(4):258-61.



I was only seeing light flashes early on, but light

FLASHES

when you've not seen anything for
so many years—it was wonderful

—Keith H, retinal prosthesis recipient

**WE'RE SEEING
AMAZING RESULTS.
AND SO ARE THEY.**

At the Foundation Fighting Blindness our mission is everybody's vision. Our work shines a light on the darkness of inherited retinal diseases (IRDs).

We're the world's leading organization searching for treatments and cures. We need your help to fuel the discovery of innovations that will illuminate the future for so many. We have robust disease information, a national network of local chapters and support groups, local educational events, and our My Retina Tracker® Registry to help keep your patients connected with clinical and research advancements.

Help accelerate our mission
by donating at ECPs4Cures.org.

**FOUNDATION
FIGHTING
BLINDNESS**

FightingBlindness.org



4 REASONS

CONTACT LENS WEAR ISN'T A PROBLEM WITH COVID-19

Despite conflicting reports, patients are just as safe as ever, as long as they adhere to proper wear and care instructions. By Daddi Fadel, DOptom

Author's Note: COVID-19 From the Frontlines

Until the United States took the lead on March 26, 2020, Italy—where I live—had the highest rate of confirmed cases. At the time of this writing (April 1), we are on the 25th day of lockdown, staying home.

Our country seems to be moving through the seven stages of grief. After the denial phase, which unfortunately lasted too long, costing thousands of human lives, we are now through the pain and guilt phase. We have looked for the guilty party to blame for this disaster of human lives, personal finances and the world economy. We have even passed through the bargaining phase—that period of singing and dancing on the balconies to ward off the virus, or at least its psychological implications.

We are currently working on the second half of that phase, anger, and perhaps are moving into depression. At this moment, unfortunately, some people have run out of money and no longer have enough to eat, so they either attack the supermarkets or shop and sneak out without paying. These violent and impulsive behaviors ignore social distancing and could potentially worsen the spread of the virus. Our healthcare system is already at risk of collapse.

Fortunately, the depression phase is still limited to a few desperate people, but the rumors of an extended lockdown, do not promise positive psychological reactions and impact.

From a professional point of view, optometrists are considered an essential service, and we remain open. Some practices are open during a narrow time slot (only two to three hours in the morning), while others are available only for emergencies.

As in other countries, we find ourselves inundated with misinformation and fake news. Here, I am personally trying to provide credible and evidence-based information and sources from which professionals and patients may benefit.

A popular Italian saying goes, “there’s no two without three,” which, in the US, translates to “bad things come in threes.” After the severe acute respiratory syndrome coronavirus (SARS-CoV) and the Middle East respiratory syndrome coronavirus (MERS-CoV), the third novel iteration, SARS-CoV-2, could not miss. The fatal consequences of the first two should have, but didn’t, serve to alarm the population about the risks of the coronavirus.

SARS-CoV-2, commonly known as COVID-19, is a significant global health emergency with substantial psychosocial and business implications. As of April 14, 2020, there are 2,001,267 confirmed cases globally and 130,487 deaths.¹ Generally, patients infected with COVID-19 have the first symptom of fever and then may develop a respiratory disorder, cough and fatigue that can quickly progress into pneumonia.² Other signs such as conjunctivitis have been observed on occasion.³

Researchers have identified several different potential transmission routes, including respiratory droplets and close contact, and have hypothesized others, such as contact with the ocular surface.⁴ Studies show the virus can be transmitted through the mucus

ABOUT THE AUTHORS



Dr. Fadel is a contact lens designer and a specialist in contact lenses for irregular cornea, myopia control and orthokeratology. She studied optometry at Istituto Superiore di Scienze Optometriche (ISSO) in Rome. She runs an optometric practice specializing in contact lenses in Italy where she designs and fits special customized contact lenses. She is a well-known international speaker and author in the area of specialty contact lenses.

4 REASONS CONTACT LENS WEAR ISN'T A PROBLEM WITH COVID-19

membranes, including the tears and conjunctiva.⁵⁻¹⁰ Even with this recent research, controversies exist surrounding the transmission of COVID-19 through the contact lens (CL). Myriad editorials and articles have addressed this topic, ranging from reputable information to speculative and even incredible reporting.

These four scenarios refute the concept that CLs should be avoided during the COVID-19 pandemic:

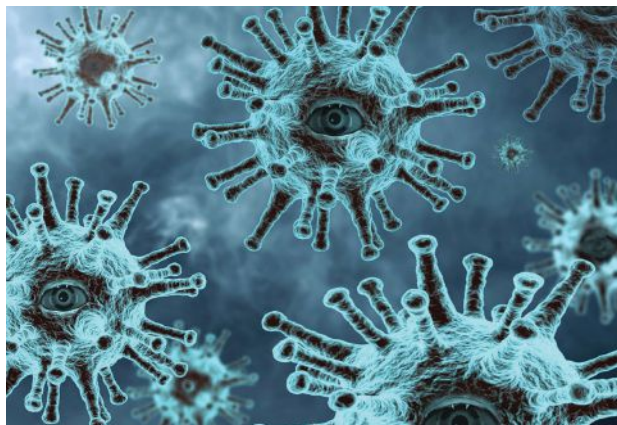
1. *Let's assume that the virus reaches the eyes by adhering to the surface of the CL and then migrating to the ocular mucous membrane, infecting the individual.* Perhaps the virus even penetrates the contact lens material, not just adhering to the surface. This adherence can happen either with airborne contact or from contaminated fingers during insertion or removal.

Even if this proves to be true with further study, patients are not necessarily at an increased risk of exposure due to CL wear. If the virus reaches the lens, it also reaches the exposed parts of the eye, providing direct contact with the ocular mucous membrane, still infecting the individual. The virus infects the patient in both cases, whether they are wearing CLs or not. Even if the virus is embedded within the lens material, the infected droplets in contact with the exposed mucous membrane will penetrate the organism faster compared with the droplets absorbed by the lens material, as the latter must first be released by the material before infecting the organism.

Various studies investigating the potential transmission route of human coronaviruses through the eye found the virus in the conjunctival sac of infected patients, yet they did not note viral transmission via the conjunctival route.^{5,7,8} However, more studies are needed to better understand if the eye may be an alternative transmission route of COVID-19 specifically. Still, even if the virus is transmitted through eyes, the virus will infect the subjects through the ocular mucous membrane, whether they wear CLs or not.

2. *Some think spectacles provide some sort of protection from viruses.* In this case, clinicians should consider the international experts and the World Health Organization irresponsible for not recommending spectacle wear, whether eyeglasses or sunglasses. In this scenario, manufacturers of spectacles should recommend them to the entire world population. In addition, clinicians should recommend CL wearers wear sunglasses to protect themselves for viral spread.

However, spectacles do not represent adequate protection.¹⁰ In fact, they may represent a potential source of contagion, probably more than CLs. Spectacles may be made of metal and plastic, while contact lenses are



hydrogel or a mixture of hydrogel and silicone. Research shows that COVID-19 can survive on metal and plastic surfaces for up to nine days but only up to five days on silicone rubber.¹¹ Additionally, patients apply CLs with washed hands, while people wearing spectacles tend to touch their spectacles frequently during the day—especially presbyopes—with unwashed hands, transferring the virus from fingers to face.

3. *Some believe that even appropriate hand washing does not eliminate all the microbes and viruses from hands, suggesting CL wearers remain at risk even with proper hygiene.* If this is true, studies demonstrate that ethanol is excellent in inactivating human coronavirus.¹¹ Clinicians can suggest patients use disposable gloves, ethanol or alcohol wipes to disinfect their fingers before lens handling as an extra precaution.¹²

4. *Realistically, patients won't stop wearing their lenses.* Instead of banning CL wear, clinicians should use this as an opportunity to educate patients on:

- Proper handwashing.
- Adequate disinfection of CLs every evening (ethanol, hydrogen peroxide and sodium hypochlorite all inactivate human coronaviruses).¹¹
- Compliance with case hygiene and care solutions.
- Proper spectacle disinfection often during the day.

We want to protect the eyes, but contact lenses and spectacles are not the issue. Patients, whether or not they wear CLs, should instead use compliant masks, remembering to disinfect them often and correctly.

Suggesting patients limit their CL wear to emergencies only and to wear spectacles instead makes no sense. Various CL experts have provided their own evidence-based statements on CL wear safety.¹³⁻¹⁶

Another essential and sensible factor to consider during this pandemic is the psychological impact. COVID-19 has significant psychosocial implications, and

Earn up to
18-29 CE
Credits*

A Medscape **LIVE!** CONFERENCE

NEW TECHNOLOGIES
& TREATMENTS IN
2020
EYE CARE

REVIEW
EDUCATION GROUP

2020 MEETINGS

OCTOBER 30-NOVEMBER 1

AUSTIN, TEXAS

Omni Barton Creek

Program Chair: Paul Karpecki, OD, FAO

REGISTER:

www.ReviewEdu.com/Austin2020

NOVEMBER 5-8

PHILADELPHIA, PENNSYLVANIA

Joint meeting with OCCRS**

Philadelphia Marriott Downtown

Review Program Chair:

Paul Karpecki, OD, FAO

OCCRS Program Chair:

Tracy Schroeder Swartz, OD, MS, FAO

REGISTER:

www.ReviewEdu.com/Philadelphia2020

DECEMBER 11-13

ORLANDO, FLORIDA

Disney's Yacht & Beach Club

Program Chair: Paul Karpecki, OD, FAO

REGISTER:

www.ReviewEdu.com/Orlando2020

CLs have shown to improve patients' quality of life compared with spectacles correction, not only by correcting refractive errors but also by providing better appearance and fewer physical limitations.^{17,18} This last factor should not be underestimated.

Ongoing research on this topic is needed to truly understand the role of CLs with COVID-19. While the literature is emerging, clinicians should be practical in their recommendations with conservative precautions for patients. Practitioners must keep up-to-date on the evidence-based recommendations in this fast-changing pandemic situation and refer to credible sources such as academic institutions and global organizations' regulatory and government sources.

Hopefully, by the time this editorial makes it to print, Italy will have made the upward turn toward reconstruction, acceptance and hope. Together, we can all work through this pandemic to keep our families and patients as safe as possible. **BCCL**

1. World Health Organization. Coronavirus disease (COVID-2019) situation reports. www.who.int/emergencies/diseases/novel-coronavirus-2019/situation-reports. Accessed March 27, 2020.
2. Huang C, Wang Y, Li X, et al. Clinical features of patients infected with 2019 novel coronavirus in Wuhan, China. *Lancet*. 2020;395:497-506.
3. Rothe C, Schunk M, Sothmann P, et al. Transmission of 2019-nCoV Infection from an 205 Asymptomatic Contact in Germany. *N Engl J Med*. 2020;382(10):970-71.
4. Brankston G, Gitterman L, Hirji Z, et al. Transmission of influenza A in human beings. *Lancet Infect Dis*. 2007;7:257e265.
5. Xia J, Tong J, Liu M, et al. Evaluation of coronavirus in tears and conjunctival secretions of patients with SARS-CoV-2 infection. *J Med Virol*. February 26, 2020. [Epub ahead of print].
6. Lu CW, Liu XF, Jia ZF. 2019nCoV transmission through the ocular surface must not be ignored. *Lancet*. 2020;395:e39.
7. Zhou YY, Zeng YY, Tong YQ, et al. Ophthalmologic evidence against the interpersonal transmission of 2019 novel coronavirus through conjunctiva. 2020.
8. Seah I, Agrawal R. Can the coronavirus disease 2019 (COVID-19) affect the eyes? A review of coronaviruses and ocular implications in humans and animals. *Ocul Immunol Inflamm*. 2020;16:1-5.
9. Dai X. Peking University Hospital Wang Guangfa disclosed treatment status on Wei-bo and suspected infection without wearing goggles. *Beijing News*. January 22, 2020.
10. Centers for Disease Control and Prevention. Interim infection prevention and control recommendations for patients with suspected or con-firmed coronavirus disease 2019 (COVID-19) in healthcare settings. www.cdc.gov/coronavirus/2019-ncov/infection-control/control-recommendations.html#minimize. Accessed March 30, 2020.
11. World Health Organization. Coronavirus disease (COVID-19) advice for the public. www.who.int/emergencies/diseases/novel-coronavirus-2019/advice-for-public. Accessed March 30, 2020.
12. Fonn D, Jones L. Hand hygiene is linked to microbial keratitis and corneal inflammatory events. *Cont Lens Ant Eye*. 2019;42:132-35.
13. Walsh K. COVID-19 and contact lens wear: what do eye care practitioners and patients need to know? *Contact lens Update*. March 16, 2020.
14. Centre for Ocular Research & Education. Top contact lens experts dispel misinformation regarding coronavirus / COVID-19 protections for contact lens wearers. <https://core.uwaterloo.ca/news/top-contact-lens-experts-dispel-misinformation-regarding-coronavirus-covid-19-protections-for-contact-lens-wearers>. Accessed March 30, 2020.
15. Centre for Ocular Research & Education. Contact lens update special edition: COVID-19 and contact lens wear. <https://core.uwaterloo.ca/news/contact-lens-update-special-edition-covid-19-and-contact-lens-wear>. Accessed March 30, 2020.
16. British Contact Lens Association. Contact lens wear and coronavirus (COVID-19) guidance. www.bcla.org.uk/Public/Public/Consumer/Contact-Lens-Wear-and-Coronavirus-guidance.aspx. Accessed March 30, 2020.
17. Fadel D, Walsh K. Covid-19, [when the use of lenses is safe]. www.b2eyes.com/news/covid-19-quando-%E2%80%99uso-delle-lenti-%C3%A8-sicuro. Accessed March 30, 2020.
18. Queirós A, Villa-Collar C, Gutiérrez AR, et al. Quality of life of myopic subjects with different methods of visual correction using the NEI RQL-42 questionnaire. *Eye Cont Lens*. 2012;38(2):116-21.

For the latest information visit:

www.ReviewEdu.com/Events
e-mail: ReviewMeetings@MedscapeLIVE.com
call: 866-658-1772

Administered by:

REVIEW
EDUCATION GROUP

OCCRS
OPTOMETRIC, CORNEAL, CATARACT
AND REFRACTIVE SOCIETY

SALUS
UNIVERSITY
Pennsylvania College of Optometry

COPE

**17th Annual Education
Symposium
Joint Meeting with NT&T
in Eye Care

*Approval pending

Review Education Group partners with Salus University for those ODs who are licensed in states that require university credit. See www.reviewedu.com/events for any meeting schedule changes or updates.

LIDS AND LENSES:

Three Snags to Fitting Success

Surgical and anatomical complications could throw a wrench in your contact lens fitting process. Here's what to keep in mind.

By Steven Turpin, OD, and Leonid Skorin Jr., OD, DO, MS

When fitting contact lenses, the status of the ocular surface is our primary focus. The cornea, conjunctiva and sclera support the lens and are the major contributors to the fit. But, by focusing solely on these structures, we often fail to acknowledge the equally important role the eyelids play. The interaction between the eyelids and a contact lens can significantly contribute to contact lens success. This article reviews complications that may arise from surgical alterations to the lids, including lid closure and lesion removal, and investigates how anatomical variations, such as lid tension, can influence the lens fit.

EYES WIDE SHUT

One of the most difficult eyelid issues to overcome when fitting contact lenses is a partial tarsorrhaphy, or surgical closure of the eyelids, which is primarily indicated to prevent exposure of the ocular surface. The etiology of the exposure may include non-resolving Bell's palsy, acoustic neuroma causing seventh cranial nerve paresis, exophthalmos or neurotrophic disease.¹

The surgical technique depends on how long the lids should be closed. For temporary tarsorrhaphy,

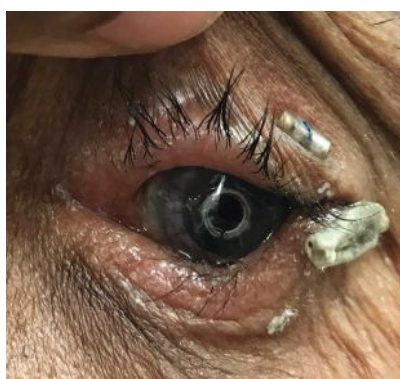

Photo: Pratik Patel, OD

Fig. 1. Note the narrowing of palpebral fissure vertically and horizontally in this partial temporary tarsorrhaphy.

phies, the lids can be partially or completely closed. Non-absorbable sutures create “drawstrings” that can be tightened or loosened to control the size of the interpalpebral fissure.

Fully opening the lids is crucial for examining the entire ocular surface at follow-up and ensuring proper healing. As ocular surface healing takes place, the degree of lid closure can be optimized for visual quality, patient comfort and ocular health. The ability to control fissure size makes this technique more popular than permanent closure.

In the case of permanent closure, usually only the lateral-most portion of the lids is approximated. During surgery, the surgeon separates the

anterior lamella (skin side of the lids) from the posterior lamella (conjunctival side) with a #11 or #15 blade. Next, they remove the epithelium from the lid margin. Separating the anterior and posterior portions of the lid and removing the lid margin tissue allow the upper and lower portions of the anterior and posterior lamella to heal. The posterior lamella of the upper and lower lid is then connected using absorbable sutures, and the anterior lamella of the upper and lower lid is connected using non-absorbable sutures. Patients are still able to see, but the interpalpebral fissure is narrower vertically and horizontally to protect a portion of the ocular surface from exposure (*Figure 1*).¹

ABOUT THE AUTHORS



Dr. Turpin is an optometrist at North Cascade Eye Associates in northwest Washington. He is building a specialty contact lens clinic within the larger practice. He is the founder of Practically Abstract, a website and newsletter dedicated to reviewing contact lens and dry eye research.



Dr. Skorin is a consultant in the Department of Surgery, Community Division of Ophthalmology at the Mayo Clinic Health System in Albert Lea, MN.

Drawbacks of tarsorrhaphy include poor functionality and aesthetics. In addition, the procedure may not provide adequate corneal coverage or allow segmental deterioration over time. Examination of the cornea is usually difficult, and the patient's vision and visual field are restricted.²

Despite partial surgical closure of the lids, some patients may still need protection from ocular surface exposure. In these cases, a bandage soft contact lens is often indicated. While a scleral lens may be an effective treatment option, the large diameter of the lens makes placement on the eye difficult. In most cases, it is easiest to start with standard-sized bandage soft lenses, which range from 13.8mm to 14.0mm in diameter. Standard lenses may prove to be too large but are often readily available in most clinical settings.

Trial and error informs the provider on what adjustments are necessary or if a custom lens is required. Diameters of custom soft lenses usually range anywhere from 11.0mm to 22.0mm to fit the various needs of patients. Regardless of base curve and diameter, the lens may need to be partially folded to “tuck” one edge under the upper lid and then position the inferior edge under the lower lid. Patients who are unable to place the lens themselves should return every three to four weeks for lens replacement.

A BUMPY ROAD

As eyecare providers, we are no strangers to lid lesions. Patients with lesions often present with concerns about their aesthetics and to determine if they pose any health

risk. Fortunately, approximately 80% of lesions are benign and do not require excision.³ However, even if a lesion is benign and possesses no threat of malignancy, its location may eventually damage the ocular surface and potentially complicate contact lens wear.

A lesion or tumor can form in any of the four layers of the eyelid (skin and subcutaneous tissue, striated muscle, tarsus or conjunctiva), but nearly all lesions are cutaneous in origin and can be categorized as epithelial or melanocytic.

Lesions primarily affect the outermost layer of the lid, meaning they interact with the ocular surface if located along the upper or lower lid margins. The irregular mass disrupts normal function, and the lid no longer acts as a “squeegee” to move tears on the ocular surface. Poor distribution of the tear film and damage to the corneal epithelium can occur and may eventually lead to surface scarring and reduced vision.

While contact lens wear can help protect the ocular surface, it may cause other problems. If the lesion is made up of keratinized epithelial cells (not smooth palpebral tissue), it may snag on the lens. Although it seems contradictory, sometimes this can be beneficial (e.g., an upper lid lesion may help keep a gas permeable lens attached). More often, the lesion causes the lens to move erratically and pop out. As the patient blinks, the margins of the lesion slide under the lens edge and the lens falls out (*Figure 2*). We have seen this happen with every single modality of lens, including sclerals. The simplest solution, from a lens fitting standpoint, is to increase the lens diameter to prevent the lid margin from crossing over the upper or lower edge of the lens.

However, it is often more effective to address the problem at its

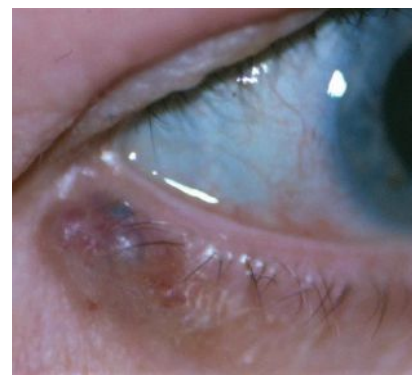


Fig. 2. A pigmented basal cell carcinoma margin lesion is noticeable on this eyelid.

source—the lesion. If the lesion is removed, the regularity of the lid margin can be restored.

Whether a lesion is benign or malignant is crucial to determining how it is removed. For lid margin lesions, a shave excision is often preferred to prevent lid margin notching that can occur with other excision techniques.^{4,5}

To perform a shave excision, an anesthetic is injected under the lesion. The skin is then stabilized or stretched using the non-dominant hand, and, using the dominant hand, the lesion is separated from the underlying tissue with a #11 blade, curette or fine wire electro-surgical loop. This is done horizontally with the eyelid margin serving as a guide. The technique maintains the integrity of the underlying tissue and prevents excessive scarring. After removal, the tissue should be sent to pathology to confirm whether it is benign or malignant. The patient should use antibiotic ointment following the procedure to prevent infection.

For known malignant lesions, excision that allows for an additional 3.0mm to 4.0mm margin ensures that all of the malignant tissue is removed. Part or all of the lid margin may need to be removed in some cases. Bandage contact lenses—either soft or scleral—can be applied



To see a video of a shave excision, visit www.reviewofoptometry.com or scan the QR code.

after the procedure to protect the ocular surface. While smaller custom bandage lenses are needed to accommodate the narrower lid fissure created by a tarsorrhaphy, larger lenses (>16.0mm) are required in the case of a lid lesion to protect the more peripheral conjunctival tissue. When a significant amount of the eyelid is removed, tissue grafts can help restore lid integrity over time. Until then, regular monitoring of ocular surface health is essential.

DOWN AND OUT

It is well known that soft contact lenses tend to decenter down and out. We often attribute lens decentration to the height differences of the sclera. Usually, the nasal sclera is higher than the temporal sclera. This difference may occur as a result of the medial rectus being inserted closer to the limbus than the lateral rectus. Similarly, the inferior sclera tends to be lower than the superior sclera. While scleral height most certainly plays a significant role in lens decentration, it could be that the lids—specifically the upper lid—contribute as well.

Researchers have not reached a consensus on the role of superior lid tension in soft contact lens wear. There are a number of competing theories suggesting it plays very different roles in the fitting process. One theory proposes that the closer the upper lid is to the globe, the greater the resistance the lens encounters when trying to move superiorly.⁶ As a result, those with greater superior lid tension have more inferior lens decentration. The theory also suggests that, on average, younger patients have more inferior soft lens decentration. Recent evidence seems to support this, as the phenomenon that superior lid tension decreases with age is well documented.⁷ One study revealed that various soft lens designs tended

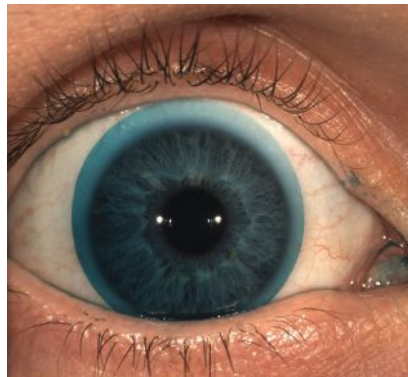

Fig. 3. Note superior lens decentration when the upper lid is manually elevated and the lower lid is in normal position.

to decenter more in the pre-presbyopic population.⁸ Another found that soft lenses tended to decenter superiorly when the upper eyelid was held up, which the researchers noted could be explained by the lower lid pushing the lens up, but it did not mention the decrease in resistance from the upper lid when it was held as a possible explanation.⁹ To our knowledge, no studies specifically compare upper lid tension and soft contact lens decentration (Figure 3).

Regardless of the exact mechanism causing soft lenses to decenter, the result is the same. The optical center of the contact lens settles inferiorly and temporally to our line of sight. For patients who wear soft spherical lenses or even most toric lenses, this mismatch between optical center and line of sight is inconsequential. The optic zone of the lens is large enough to provide a high quality image.

However, for those who wear multifocal contact lenses for myopia or presbyopia, decentration can have a big impact on visual quality. Many believe this is a primary factor in the relatively high failure rate of soft multifocal contact lenses. Fortunately, more custom soft lens manufacturers are offering decentered optic options for their lens

designs. Most recommend ordering a lens in the power, base curve and diameter you desire, fitting the lens to measure the amount of lens decentration and then re-ordering the decentered optic lens. Keep in mind that, if lid tension does play a role, the amount of decentration will change over time as a patient's lid laxity increases with age and will have to be managed accordingly.

The role the eyelids play in contact lens management is often ignored or overlooked. However, in certain circumstances, the lids can have a major impact not only when fitting gas permeable lenses but also when fitting soft or scleral lenses. Whether the lids are too narrow, wide, loose, tight or bumpy, having a few tricks up your sleeve that you can turn to will help improve your success rate. Additionally, don't be afraid to make a referral for surgery if restoration of normal lid structure makes the fitting process easier. Generally, the less the lids and lens interact, the better. **RCCL**

1. Rajak S, Rajak J, Selva D. Performing a tarsorrhaphy. *Community Eye Health* 2015;28(89):10-1.
2. Seiff SR, Choo PH, Carter SR. Facial nerve paralysis. In: Mauriello JA, eds. *Unfavorable Results of Eyelid and Lacrimal Surgery: Prevention and Management*. Boston: Butterworth Heinemann; 2000: 227-41.
3. Yu SS, Zhao Y, Zhao H, et al. A retrospective study of 2228 cases with eyelid tumors. *Int J Ophthalmol*. 2018;11(11):1835-41.
4. Sundar G, Manjandavida FP. Excision of eyelid tumors: principles and techniques. In: Chaugule SS, Honavar SG, Finger PT, eds. *Surgical Ophthalmic Oncology: A Collaborative Open Access Reference*. Vol Cham: Springer International Publishing; 2019: 15-32.
5. Skopin L, Goemann L. Lumps and bumps be gone. *Rev Optom*. 2018;155(2):104-5.
6. Cui L, Li M, Shen M, et al. Characterization of soft contact lens fitting using ultra-long scan depth optical coherence tomography. *J Ophthalmol*. 2017;2017:5763172.
7. Yamaguchi M, Shiraishi A. Relationship between eyelid pressure and ocular surface disorders in patients with healthy and dry eyes. *Invest Ophthalmol Vis Sci*. 2018;59(14):DES56-63.
8. Fedtke C, Ehrmann K, Thomas V, et al. Association between multifocal soft contact lens decentration and visual performance. *Clin Optom (Auckl)*. 2016;8:57-69.
9. El-Nimri NW, Walline JJ. Centration and decentration of contact lenses during peripheral gaze. *Optom Vis Sci*. 2017;94(11):1029-35.

Earn up to
19 CE
Credits*

A Medscape **LIVE!** CONFERENCE

NEW TECHNOLOGIES
& TREATMENTS IN
2020 EYE CARE

REVIEW
EDUCATION GROUP

Austin, Texas

October 30 - November 1, 2020
at the Omni Barton Creek

Review's New Technologies & Treatments in Eye Care proudly presents Austin 2020!
Join us for three days of education detailing the latest ideas and innovations in eye care.

Register before September 4 for Early Bird discount.



PROGRAM CHAIR
Paul M. Karpecki, OD, FAAO

LOCATION:

Omni Barton Creek
8212 Barton Club Drive
Austin, TX 78735
(512) 329-4000

REGISTRATION COST:

Early Bird Special: \$420
Full Conference after September 4: \$495

See event website for daily fees.

A limited number of rooms have been reserved at the group rate of \$275/night + tax and fees.
Call the hotel directly at the number above and identify yourself as a participant of "Review's New Tech" for group rate.

THREE WAYS TO REGISTER:
www.ReviewEdu.com/Austin2020

Call: 866-658-1772 or E-mail: ReviewMeetings@MedscapeLIVE.com

Administered by:

REVIEW
EDUCATION GROUP

COPE

*Approval pending

SALUS
UNIVERSITY

Pennsylvania College of Optometry

Partially supported by an unrestricted
educational grant from:

Novartis

Review Education Group partners with Salus University for those ODs who are licensed in states that require university credit.

5

CONJUNCTIVAL FINDINGS TO LOOK OUT FOR IN CONTACT LENS WEARERS

Learn the basics so you can better manage these conditions in your patients. By Paymaun Asnaashari, OD

The conjunctiva—the thin, translucent membrane that lines the inside of the eyelids (palpebral conjunctiva) and covers the sclera (bulbar conjunctiva)—is thinnest along the eyelid margin and thickest in the fornices. It is composed of two layers: a stratified, non-keratinized epithelial layer consisting mostly of goblet cells and a submucosa layer containing mostly antimicrobial and inflammatory response cells, such as macrophages and mast cells.¹ Its main functions include protecting the soft tissues of the eyelid and orbit, allowing extensive movement of the eye without damaging soft tissue, serving as a source of antimicrobial and other immunological agents and producing the mucin layer of the tear film.

Soft contact lens wear causes the conjunctiva to respond in various ways. The association between conjunctival changes and symptomatology is important to consider, as it can play a role in the outcome of a fitting. However, it is not always entirely clear whether these physiological changes are the underlying cause of contact lens discomfort. This article describes several conjunctival findings that are important to consider in soft contact lens wearers.

1 *Giant Papillary Conjunctivitis (GPC)*

This is a non-infectious inflammatory response of the superior tarsal palpebral conjunctiva due to mechanical irritation from chronic eyelid movement over a foreign object. Most commonly, GPC is associated with contact lens wear; however, similar reactions have been noted with exposed ocular sutures, filtering blebs, ocular prosthesis, scleral buckles and elevated corneal scars.²

Pathophysiology. GPC results in papillary changes in the palpebral conjunctiva as part of an immunoglobulin E-mediated hypersensitivity reaction to the presence of a foreign object.² Eyelid movement can stimulate the resulting inflammatory response, especially as people blink tens of thousands of times per day.³ With age, this rate increases even more.³ The papillary inflammation causes papillae to grow in size as GPC advances. Large papillae (greater than 0.3mm in diameter) on the tarsal conjunctiva are a classic sign of the disease.⁴

The polymer of a contact lens can also influence GPC development. The type of polymer can impact the amount of deposits that form on the surface of a lens. For example,

polymers that have higher water content and ionic properties attract larger amounts of protein deposits compared with lenses with lower water content.^{5,6} The push toward increased oxygen permeability with silicone hydrogel contact lenses unfortunately makes the lenses more susceptible to protein deposits. In addition, the higher modulus of silicone hydrogel lenses makes them stiffer, which can cause even more mechanical trauma.⁷

Management. Since the pathophysiology of GPC involves immune and mechanical components, treating both is important. GPC is manageable with nontherapeutic or therapeutic methods. Nontherapeutic methods that can effectively prevent and treat GPC include discontinuing lens wear temporarily or permanently, changing to a daily disposable—or at least a more frequent replacement cycle to accommodate lens parameters that

ABOUT THE AUTHOR



Dr. Asnaashari graduated from the UC Berkeley School of Optometry in 2018 and is a therapeutic and glaucoma-certified optometrist in Sacramento, CA. One of his areas of expertise is specialty contact lenses.

aren't offered in a daily disposable option—or gas permeable lens, switching to a preservative-free disinfectant solution and using cold compresses or lubricating eye drops. Taking into account contact lens edge thickness and design are other strategies to prevent recurrence.

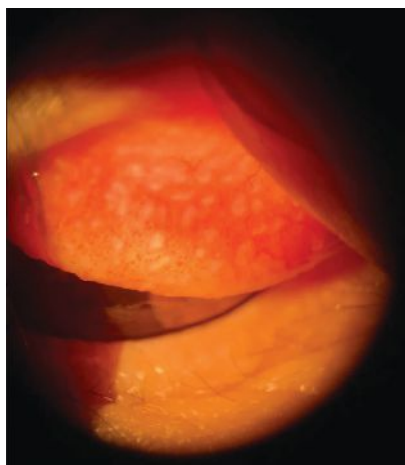
One therapeutic option that can be helpful in treating the inflammation associated with GPC is topical steroids. Although steroids can provide prompt symptom relief, they can cause potential complications, such as healing impairment and infection risk, and side effects, including cataracts, glaucoma and increased intraocular pressure.

Another option is antihistamines or mast cell stabilizers. Although GPC is not primarily a mast cell-mediated reaction, these alternatives may allow us to get ahead of the disease before it progresses.

Proactively trying to understand GPC could ultimately help prevent it and promote a healthy interaction between the conjunctiva and the ocular surface.

2 Pyogenic Granuloma (PG) These benign vascular proliferations can occur on the skin and mucous membranes, including the conjunctiva.⁸ They appear as small or large and smooth or lobulated vascular nodules that can grow rapidly. Symptoms include irritation, foreign body sensation and bleeding.⁸ PGs can occur in all age groups and appear to affect both men and women equally.

Pathophysiology. PGs are presumed to represent an abnormal reaction to healing, most commonly occurring in sites of injury that involve chronic chalazia or surgery.⁹ However, the true etiology remains unknown. Histological slides reveal a mixture of inflammatory cells, blood vessels and connective tissue.⁹ Inflammatory cells include lympho-



Temporarily discontinuing lens wear can help manage GPC.

cytes, plasma cells and scattered neutrophils. Newly exhibited blood vessels are immature.

Vascular proliferation occurs in three stages: cellular phase, capillary or vascular phase and involutionary phase.⁸ Early lesions contain numerous capillaries and venules with prominent endothelial cells arrayed radially toward the epithelial surface. Mature lesions exhibit a fibromyxoid stroma that separates the lesion into lobules. A major driver in the pathogenesis of PG appears to be a mutation within the endothelial cells.⁸

Management. A first-line therapeutic treatment for PG is ophthalmic drops. Since the pathophysiology of PG is inflammatory, treatment with topical corticosteroids is effective in controlling and reducing the size of the lesion. For those who do not respond to topical agents, surgical excision or cryotherapy is advised.

3 Conjunctivochalasis This is defined as a loose, redundant conjunctiva. As we age, our body's tissues, including the ocular surface, lose their elasticity. A common sign the ocular surface is experiencing this is chalasis. Often located in the inferior-temporal con-

junctiva, chalasis tends to increase in incidence and magnitude with age.^{10,11} Many symptoms associated with chalasis are similar to those of dry eye disease and could include eye pain, blurred vision, epiphora, discomfort and dryness.¹²

Pathophysiology. While the true cause of chalasis is not yet known, it is hypothesized that the etiology is multifactorial.¹³ It may result from local trauma, age-related connective tissue degradation, inflammation or delayed tear clearance.^{13,14} The dominant theory was derived from the thought that chalasis is the result of an age-related degradation of conjunctival elastic fibers from repeated mechanical insult of the eyelids on the conjunctiva.¹⁵ This may escalate with contact lens use, seeing how contact lens wearers, especially gas permeable users, are more likely to have conjunctivochalasis.¹⁶ This risk increases with years of wear, as mechanical insult causes the elastic fibers to degrade over time and creates redundant tissue.^{15,16}

The mechanical trauma is also thought to activate an inflammatory cascade that breaks down the conjunctival connective tissue, which may lead to chalasis.¹⁷ Another study proposed the idea that chronic inflammation from decreased tear clearance allows inflammatory or degradation mediators to build up on the ocular surface and break down the conjunctival fibers over time, creating redundant tissue.¹⁸ It showed that stress on the ocular surface from ultraviolet radiation, oxidative stress, dry eyes and mechanical trauma could lead to an increased production of inflammatory molecules.¹⁸

The increase in inflammatory molecules due to insult can activate matrix metalloproteinases (MMPs).^{18,19} The decreased tear clearance encourages MMPs to remain on the ocular surface for even

FIVE CONJUNCTIVAL FINDINGS TO LOOK OUT FOR IN CONTACT LENS WEARERS

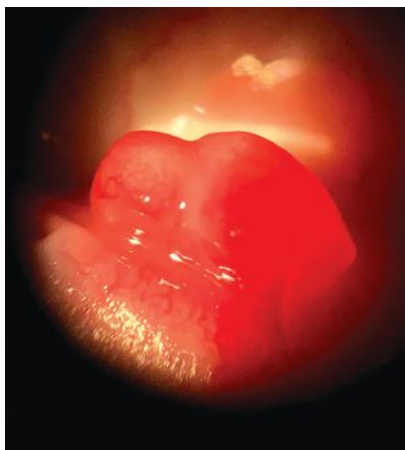
longer, allowing for compounding conjunctival damage that leads to more redundant tissue. This creates a continuous cycle of worse tear flow, more redundant tissue and possible punctum blockage to keep more toxic tears on the conjunctiva for longer periods of time.

Management. Treatment of chalasis varies depending on the severity of each case. Generally, no treatment is needed for asymptomatic patients. Topical pharmaceutical intervention can help address inflammation and stabilize the tear film in symptomatic patients. Soft corticosteroids can target inflammation but may require extended periods of use. In addition, antihistamines and mast cell stabilizers can assist in managing any concurrent allergic-like conjunctivitis. Lubricants, such as artificial tears and gels, can help stabilize the tear film. If discomfort continues to persist despite maximum therapy, consider conjunctivoplasty.

4 Lid Wiper Epitheliopathy (LWE)

This refers to an epithelial disturbance of the marginal conjunctiva of the upper and lower eyelids. It is an epitheliopathy of the squamous epithelium of the conjunctiva. The lid wiper region is the portion of the marginal conjunctiva of the upper and lower eyelid that spreads the tear film over the ocular surface.²⁰ It is located in the area of the eyelid that rubs against the ocular surface, posterior to the line of Marx (the mucocutaneous junction between the palpebral conjunctiva and the eyelid positioned posterior to the meibomian glands).

Pathophysiology. LWE is thought to be the result of increased mechanical friction between the lid wiper region and the ocular surface that leads to epithelial compromise and inflammation.²¹ This increase in



A pyogenic granuloma can appear small or large and smooth or lobular.

friction could be due to inadequate lubrication, contact lens wear or environmental factors. You can observe the disturbance to the conjunctival epithelium of the lid wiper region through vital staining of the upper and lower lid margins.

LWE is more prevalent in contact lens wearers and has been observed in both gas permeable and soft lens users.²² One study found LWE in over 80% of contact lens participants.²³ It can be seen in both symptomatic and asymptomatic patients.²⁰ Histological studies demonstrated that the goblet cells in the lid wiper epithelium produce gel-forming mucins, which create a thin mucin-water gel that lubricates the surfaces of the lid wiper region and the ocular surface.²⁴ The thin gel protects the lid wiper region from damage by facilitating low friction during blinking. Contact lenses can separate the thin gel, causing inadequate lubrication.

A study found that the microvascular response of the lid wiper region was significantly correlated with contact lens discomfort, suggesting that friction could be related to both the hyperemic response and lid wiper staining.²⁵ Another team of researchers observed an upregulation of Langerhans cells (LCs) in

the lid wiper region during contact lens discomfort, indicating that LWE may have an inflammatory component.²⁶ LCs act as antigens within the squamous epithelium of the epidermis and help lymphocytes recognize and react to an immune response.²⁷

Management. Adequately lubricating the ocular surface is essential to minimize friction and manage LWE. Rewetting drops containing carboxymethylcellulose and hyaluronic acid can improve comfort and LWE staining.²⁸ Metastable lipid emulsion drops are also effective in diminishing the severity of LWE and any associated symptoms.²⁹ Other options include using punctal plugs, applying ointment at night and decreasing the modulus of the contact lens.

5 Chalazion

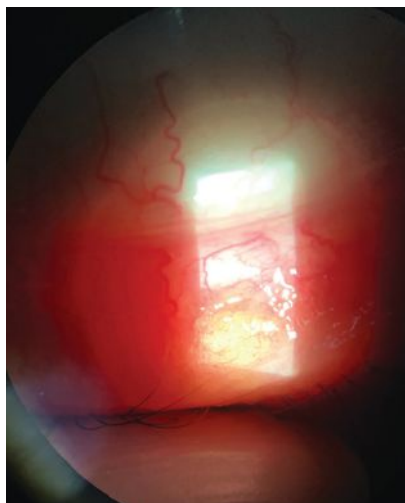
This benign inflammatory condition of the eyelid starts as a tender swelling of the upper or lower eyelid. While styes are caused by an infected hair follicle along the lid margin, chalazia are the result of blockage and inflammation of the oil-secreting glands of the eyelid.³⁰ They are common, but their exact incidence is unknown.³⁰ They occur more commonly in adulthood and affect males and females equally. Patients with underlying conditions, such as rosacea, seborrheic dermatitis and blepharitis, are more prone to multiple and recurrent chalazia.³⁰

Pathophysiology. Blockages in the eyelid glands that secrete oil create lipid inspissation in the meibomian gland that can lead to the rupture and release of lipids into the surrounding tissues.³¹ This results in a granulomatous inflammatory reaction. A study looking into the cytopathology of chalazia revealed that this condition may involve two patterns of granulomatous inflammation.³² A chalazion may either be

a mixed-cell or a suppurating granuloma.³² These two patterns of granulomatous inflammation reflect the spectrum of changes in the course of the condition. The inflammatory response from lipid inspissation can create a continuous cycle that causes the chalazion to enlarge and break through the tarsal plate.

Management. It is common practice to treat chalazia conservatively. Employ noninvasive methods, such as lid scrubs and hot compresses with or without a digital massage. The majority of chalazia clear up within one month of these conservative measures.³⁰ Although antibiotics are generally not indicated for chalazia, consider a short course of systemic therapy for lesions with associated blepharitis. Doxycycline is the drug of choice because of its dual antimicrobial and anti-inflammatory properties, but azithromycin can be effective as well.³³ In patients who don't respond to conservative therapy, intralesional steroid injection has long been an effective option because the inflammatory cells comprising chalazia are sensitive to steroids. Alternatively, surgical incision and drainage may be necessary.

Most of the focus remains on the cornea and ocular surface when it comes to contact lenses; however, it is important not to overlook the conjunctiva. Contact lenses interact with both the bulbar and palpebral conjunctival regions and, thus, they can have adverse effects on a contact lens wearer. There are multiple conjunctival considerations to take into account with contact lens wear. Contact lens users can present with conditions that are multifactorial, so understanding conjunctival comorbidities is of extreme importance. Now that we have a better understanding of



Treat chalazia conservatively by employing noninvasive methods. They should resolve within a month.

these conditions, we can use our knowledge in clinical practice to more effectively diagnose and treat them in our patients. [BCCU](#)

1. Remington LA, Goodwin D. *Clinical Anatomy and Physiological of the Visual System*, 3rd Ed. Boston: Butterworth-Heinemann; 1988.
2. Barnett M. Rethinking GPC: a new look at an old problem. *Rev Cornea Cont Lens*. 2015;152(2):10-3.
3. Sforza C, Rango M, Galante D, et al. Spontaneous blinking in healthy persons: an optoelectronic study of eyelid motion. *Ophthalmic Physiol Opt*. 2008;28(4):345-53.
4. Allansmith MR, Korb DR, Greiner JV, et al. Giant papillary conjunctivitis in contact lens wearers. *Am J Ophthalmol*. 1977;83(5):697-708.
5. Fowler SA, Korb DR, Allansmith MR. Deposits on soft contact lenses of various water contents. *CLAO J*. 1985;11(2):124-7.
6. Minno GE, Eckel L, Groeminger S, et al. Quantitative analysis of protein deposits on hydrophilic soft contact lenses: I. Comparison to visual methods of analysis. II. Deposit variation among FDA lens materials groups. *Optom Vis Sci*. 1991;68(11):865-72.
7. Kim E, Saha M, Ehrmann K. Mechanical properties of contact lens materials. *Eye Contact Lens*. 2018;44(Suppl 2):S148-56.
8. Efron N. *Contact Lens Complications*, 4th Ed. Philadelphia: Elsevier; 2019.
9. Norn MS. Fluorescein vital staining of the cornea and conjunctiva. *Acta Ophthalmol (Copenh)*. 1964;42:1038-45.
10. Gumus K, Pflugfelder SC. Increasing prevalence and severity of conjunctivochalasis with aging detected by anterior segment optical coherence tomography. *Am J Ophthalmol*. 2013;155(2):238-42.
11. Balci O. Clinical characteristics of patients with conjunctivochalasis. *Clin Ophthalmol*. 2014;8:1655-60.
12. Bert BB. How to manage conjunctivochalasis. *Rev Ophthalmol*. September 12, 2017. [Epub ahead of print].

13. Lozano AFI, Larrazabal LI, Nallasamy N, et al. Conjunctivochalasis. *American Academy of Ophthalmology*. eyewiki.aao.org/conjunctivochalasis. October 13, 2019. Accessed March 26, 2020.
14. Meller D, Tseng SC. Conjunctivochalasis: literature review and possible pathophysiology. *Surv Ophthalmol*. 1998;43(3):225-32.
15. Watanabe A, Yokoi N, Kinoshita S, et al. Clinicopathologic study of conjunctivochalasis. *Cornea*. 2004;23(3):294-8.
16. Mimura T, Usui T, Yamamoto H, et al. Conjunctivochalasis and contact lenses. *Am J Ophthalmol*. 2009;148(1):20-5.e1.
17. Huang Y, Sheha H, Tseng S. Conjunctivochalasis interferes with tear flow from fornix to tear meniscus. *Ophthalmology*. 2013;120(8):1681-7.
18. Meller D, Li DQ, Tseng SC. Regulation of collagenase, stromelysin, and gelatinase B in human conjunctival and conjunctivochalasis fibroblasts by interleukin-1beta and tumor necrosis factor-alpha. *Invest Ophthalmol Vis Sci*. 2000;41(10):2922-9.
19. Erdogan-Poyraz C, Mocan MC, Bozkurt B, et al. Elevated tear interleukin-6 and interleukin-8 levels in patients with conjunctivochalasis. *Cornea*. 2009;28(2):189-93.
20. Srinivasan S. Lids, friction and contact lens wear. *Rev Cornea Cont Lens*. 2016;153(7):20-2.
21. Efron N, Brennan NA, Morgan PB, et al. Lid wiper epitheliopathy. *Prog Retin Eye Res*. 2016;53:140-74.
22. Shiraiishi A, Yamaguchi M, Ohashi Y. Prevalence of upper- and lower-lid-wiper epitheliopathy in contact lens wearers and non-wearers. *Eye Cont Lens*. 2014;40(4):220-4.
23. Schulze MM, Srinivasan S, Hickson-Curran SB, et al. Lid wiper epitheliopathy in soft contact lens wearers. *Optom Vis Sci*. 2016;93(8):943-54.
24. Knop N, Korb DR, Blackie CA, et al. The lid wiper contains goblet cells and goblet cell crypts for ocular surface lubrication during the blink. *Cornea*. 2012;31(6):668-79.
25. Deng Z, Wang J, Jiang H, et al. Lid wiper microvascular responses as an indicator of contact lens discomfort. *Am J Ophthalmol*. 2016;170:197-205.
26. Alzahrani Y, Colorado L, Pritchard N, et al. Inflammatory cell upregulation of the lid wiper in contact lens dry eye. *Optom Vis Sci*. 2016;93(8):917-24.
27. Jaitley S, Saraswathi TR. Pathophysiology of Langerhans cells. *J Oral Maxillofac Pathol*. 2012;16(2):239-44.
28. Nichols JJ, Lievens CW, Bloomenstein MR, et al. Dual-polymer drops, contact lens comfort, and lid wiper epitheliopathy. *Optom Vis Sci*. 2016;93(8):979-86.
29. Herman JP, Korb DR, Greiner JV, et al. Treatment of lid wiper epitheliopathy with a metastable lipid emulsion or a corticosteroid. *Invest Ophthalmol Vis Sci*. 2005;46(13).
30. Jordan GA, Beier K. Chalazion. [StatPearls. www.ncbi.nlm.nih.gov/books/NBK499889/](http://www.ncbi.nlm.nih.gov/books/NBK499889/). February 11, 2020. Accessed March 26, 2020.
31. Gilchrist H, Lee G. Management of chalazia in general practice. *Aust Fam Physician*. 2009;38(5):311-4.
32. Dhaliwal U, Arora VK, Singh N, et al. Cytopathology of chalazia. *Diagn Cytopathol*. 2004;31(2):118-22.
33. *The Wills Eye Manual: Office and Emergency Room Diagnosis and Treatment of Eye Disease*, 7th Ed. Philadelphia: Wolters Kluwer; 2017.

IRREGULAR CORNEAS MEET THEIR MATCH WITH GP LENSES

This modality can provide solutions and improve vision in these unique cases.

By Tiffany Andrzejewski, OD, and John Gelles, OD

Irregular astigmatism can arise from a multitude of causes, and a variety of different lens designs can help manage it. Nonetheless, most practitioners consider gas permeable (GP) lenses the standard of care for rehabilitating vision due to irregular astigmatism. A GP-type lens, whether it be corneal GPs, hybrids or sclerals, works well to mask corneal irregularities and diminish higher-order aberrations.

One study reports that GP lenses provide superior visual performance and a greater reduction in third-order aberrations compared with soft toric contact lenses in keratoconus patients.¹ GP lenses reduce corneal aberrations induced by irregular astigmatism by masking the irregular corneal surface with the regular refractive surface of the rigid GP lenses and a liquid tear lens.^{2,3}

A GP contact lens is indicated in the presence of irregular astigmatism and when a manifest refraction does not yield acceptable visual acuity with no other ocular pathology present. Since irregular corneas are unique, there is no one lens type that will work for all. Thus, clinicians need to be proficient at fitting different specialty lens modalities to improve the likelihood of success. The three keys to contact lens success are:

1. Maintaining corneal and anterior segment health
2. Maximizing comfort
3. Improving vision

Topography is essential to understanding corneal shape. It includes knowing the profile (prolate or oblate), symmetry, location, area and magnitude of curvature and elevation. To start, evaluate anterior segment health to collect baseline measurements and rule out complicating factors. An attempt at manifest refraction is also necessary. All this data will help determine an appropriate lens design and fitting method (diagnostic vs. empirical). Let's see which options can best benefit your patients.

CORNEAL GPs

These lenses were the mainstay for irregular cornea management for decades, but developments with scleral and hybrid lens designs have demoted corneal designs to a secondary status. A recent survey indicated that 36% of practitioners fit corneal (including intralimbal) GP lenses on the majority of their keratoconus patients, second to scleral lenses at 39%.⁴

Fitting a corneal GP on a cornea with very mild irregularity or form fruste keratoconus is similar to fitting a normal cornea for refractive

error. However, this task becomes increasingly difficult with increases in irregularity.

When fitting corneal GP designs, avoid heavy apical bearing. A mild touch that provides divided support and doesn't result in corneal staining is appropriate. At the conclusion of the eight-year CLEK study, 31% of patients who wore flat-fitting lenses with apical touch developed corneal scarring, whereas only 9% of steep fits with apical clearance developed scarring.⁵ Along with lens discomfort, flatter fits were associated with an increased likelihood of penetrating keratoplasty.⁶ Therefore, avoiding apical bearing is crucial to avoid

ABOUT THE AUTHORS



Dr. Andrzejewski works at Chicago Cornea Consultants with special areas of interest in the management of cornea- and contact lens-related issues. She is an adjunct clinical faculty member of the Illinois College of Optometry.



Dr. Gelles is the director of the specialty contact lens division at the Cornea and Laser Eye Institute (CLEI) and the CLEI Center for Keratoconus in Teaneck, NJ.

corneal complications and improve peripheral lens alignment.

Depending on the lens design, the diameter and curve widths can be variable or fixed. Small overall diameter (OAD) and back optic zone diameter (BOZD) lenses are best suited for relatively well-centered ectasias or irregularities (*Figure 1*).⁷ As irregularities such as decentered ectasias and mild pellucid marginal degeneration become steeper and more peripheral, they require an increasingly larger OAD and BOZD.

There are many ways you can choose your first diagnostic lens, but, as designs vary, it is typically best to follow the fitting guide.

When in doubt, choosing a diagnostic lens with a base curve (BC) close to average keratometry value can be a good place to start. Let the lens settle so the fluorescein can dissipate for a few minutes and then evaluate the fluorescein pattern.

If apical clearance or bearing is present, modify the base curve in 0.50D to 1.00D steps until feather touch is achieved.⁷ A “three-point touch” pattern or minimal apical clearance is the goal. With three-point touch, there is light bearing in the periphery nasally and temporally (two points) and at the apex of the irregularity (third point) and definite peripheral clearance. With both smaller-diameter and intralimbal designs, you can customize the peripheral curves with toric or quadrant-specific curves to improve edge alignment and centration. Generally, an oblate cornea can be effectively fit with a reverse geometry curve.

When to choose this lens. Many irregular cornea patients are already habitual GP lens wearers. If they have acceptable vision, are well-adapted and maintain corneal health, continue. Corneal GPs work well for mild to moderate corneal irregularity and when there is less than 350µm of corneal elevation

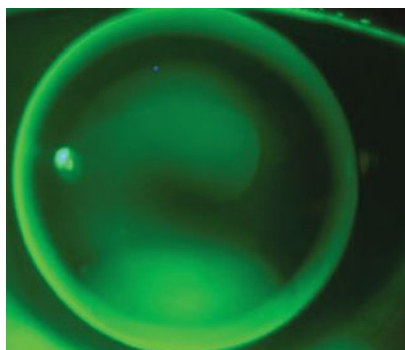


Fig. 1. The “three-point touch” pattern of a small (9.2mm) OAD lens for a patient with keratoconus.

difference along the greatest meridian of change.⁸ This is a good option for challenging scleral obstacles to fit around, such as filtering blebs.

PIGGYBACK SYSTEMS

Patients who desire the optics of a corneal GP with the comfort and protection of a soft lens underneath can consider this modality, which is often overlooked. Only around 2% of keratoconus patients use it, yet it can be a real problem-solver.⁹

There are two main fitting approaches for this modality. The first is to fit the corneal GP and then use a low-powered, low modulus, hyper-Dk soft lens underneath, which will minimally affect the fitting relationship and the power of the system. The second option is to fit the soft contact lens to artificially change the contour of the cornea to aid in the fitting process. Topography over the soft lens maps the new contour, and guides how to fit the GP lens on top.

Corneal GP lenses will tend to center on the steepest area of the cornea, therefore a moderate- to plus-powered (approximately +6.00D) soft lens with a thicker center can be beneficial in patients who have decentered irregularities or who have oblate corneas to bulk up the center to aid in GP lens centration (*Figure 2*).¹⁰ A mild minus soft lens (approximately -3.00D)

may be more appropriate in the case of keratoconus, as it has an artificial flattening effect and will allow use of a flatter and lower power GP lens.¹¹ The power effect from the soft lens will be much less than you would expect by just adding the powers of the two lenses together—the result will be 21% of the labeled soft lens power.¹²

The patient’s comfort and tolerability of the lenses largely determines a successful piggyback fit. The soft lens and GP should move independently of one another, and the GP periphery should align nicely with the soft lens to avoid both adherence and excessive edge lift.

If a standard disposable soft lens does not achieve an adequate fitting relationship, a custom soft lens may be necessary. This will allow for a custom diameter base curve and power to aid the piggyback system. When using custom soft lenses with a recessed cavity in the center, the recess should be larger and deeper than the diameter and thickness of the GP lens, which will facilitate some movement while keeping the lid interaction minimal and stable.

When to choose this lens. Choose this option when a corneal GP fits well and is the correct lens option, but awareness or difficulty adapting is preventing success. This can also improve the centration of the GP, protect a focal elevation, such as an apical nodule or scar, or prevent epithelial disruption from an otherwise well-fitting corneal GP.

HYBRIDS

These lenses have a GP center hyper-bonded to a soft skirt. In the United States, there is only one manufacturer (SynergEyes) that offers multiple designs and geometries to accommodate a variety of corneal shapes, while the OAD and GP diameter is fixed. The GP portion of the lens uses variable base curves or

IRREGULAR CORNEAS MEET THEIR MATCH WITH GP LENSES

sagittal depths to align with or vault the cornea, while the soft skirt has three to four different base curve radii that help facilitate movement, centration and tear exchange. The newer generation designs are available in higher oxygen-permeable materials for both lens portions and are designed specifically for vaulting the irregular cornea. This may reduce complications with neovascularization found in designs with low Dk materials.

An appropriately fitting hybrid lens will exhibit approximately 100 μ m clearance at insertion, as the lens may settle 30 μ m to 60 μ m after several hours of wear. The central GP portion should clear the cornea, with light touch on the mid-peripheral cornea at the GP-soft lens junction (the inner-landing zone) and land evenly on the soft skirt without fluting or impingement. The soft skirt (the outer-landing zone) bears 80% of the weight of the lens system, making it more comfortable than corneal GPs.^{13,14} There should be movement upon blink initially, but movement after a few hours of wear may not be seen although there is tear exchange.

When to choose this lens. Hybrids serve as a great first-line option for mild to moderate central corneal irregularities or ectasias as well as for patients experiencing discomfort or centration problems with corneal GPs. It's a logical transition for previous soft lens wearers who need a GP lens for improved vision, patients with a suboptimal experience with piggyback systems or those with complications from scleral lens wear, particularly lens reservoir fogging. Patients with significantly decentered irregularities, intracorneal rings, poor corneal rigidity (i.e., radial keratotomy), cornea transplants or those with significant ocular surface disease are less ideal candidates for hybrid lenses.

SCLERALS

Scleral lenses are large diameter GP lenses that rest on the sclera, tucking under the lids and vaulting the cornea. This creates a tear reservoir behind the lens bathing the cornea in preservative-free saline, improving vision when other modalities were unsuccessful. These lenses are available with an abundance of modifications depending on the laboratory and their design.

Overall, diameters can be variable or fixed, and you can adjust their vault by changing their base curves or sagittal depths. Some designs compensate for changes to individual curves, allowing for a single parameter change to occur without affecting the rest of the fit. Many come in various geometries (oblate and prolate) with variable haptic designs (toric and quad-specific) to enhance

scleral alignment and complete customization of the lens optics (sphere, front toric, multifocal). Some designs also incorporate additional customizations of notches, peripheral lifts, channels or microvaults to account for scleral obstructions.

There are three primary objectives in fitting a scleral lens—the lens must vault the cornea, clear the limbus and align with the sclera. A range of 100 μ m to 300 μ m of apical clearance and about 50 μ m over the limbus after settling is deemed acceptable. These lenses are primarily fit diagnostically.

When to choose this lens. This is the go-to for moderate to severe irregularities where there is significant asymmetry of the inferior and superior cornea. Sclerals are a good second-line option when patients fail with other lens modalities and are beneficial for patients with ocular surface disease and those suffering from contact intolerance due to dry eye.

SCAN/IMPRESSION-BASED SCLERALS

The availability of free-form, elevation-specific scleral designs allow practitioners to achieve an optimal fit on the most irregular and challenging cases.

An impression-based scleral prosthetic is developed in a process similar to those used in orthodontics. The impression is 3D-scanned, a model is generated, a points file is developed and the device is manufactured. A scan-based scleral uses a profilometer, similar to a wide field topographer.

This technology will drive empirical fitting of scleral lenses, such as the EyePrintPro, as well as further customization options. This is the ultimate in scleral technology and offers an option for those who have failed with traditional sclerals or for whom traditional sclerals are not an

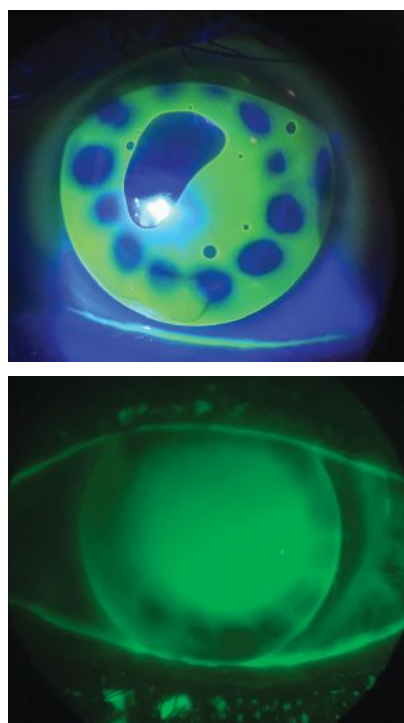


Fig. 2. Intralimbal GP on sunken corneal transplant. The steep central BC causes a central bubble, but midperiphery is aligned on the graft/host junction (top). The same GP piggybacked with a +7.00D silicone hydrogel soft lens (bottom).

Table 1. Pros and Cons of Each Lens Type

Corneal GP	Piggyback	Hybrid	Scleral	Scan/Impression-based Sclerals
(+) Healthy cornea physiology	(+) Avoids need for more complex/expensive lens design	(+) Improves comfort compared with GPs; vaults the central cornea	(+) Great comfort—better than GPs and hybrids; stable optics	(+) Great comfort even when commercial sclerals fail
(+) Lower cost to manufacture	(+) Soft lens cushions and protects the cornea; aids in stability/centration of the GP	(+) Convenience of a one lens system	(+) Complete customization of parameters	(+) Precise first-lens fit; less revisions/chair time
(+) Ease of handling	(+) Eliminates discomfort from debris	(+) Soft skirt improves centration and stability; eliminates discomfort from debris	(+) Ability to vault over any corneal irregularity	(+) Can be used for the most complex ocular geometries (prism, HOA correction); can incorporate complex optics
(-) Patient comfort	(-) Care of two different lenses	(-) Limited customization of parameters	(-) Multiple office visits/revisions required for proper fit	(-) Cost
(-) Discomfort from debris under lens	(-) Dk/t of the “system”	(-) Nuanced fitting, evaluating and troubleshooting; possibly more chair time at the initial fitting	(-) Requires a great deal of practitioner experience	(-) Not covered by many insurances
(-) Potential to scar the cornea	(-) Mass-manufactured soft lenses have limited parameters	(-) Older generation designs have a higher risk for neovascularization	(-) Difficult handling due to the filling solution and increased size	(-) Limited patient access

option. Currently, impression- and scan-based sclerals are limited to those practitioners who are certified and have the necessary devices.

When to choose this lens. If you have this option at your disposal, use it when a patient presents after being unsuccessful other commercially available scleral lenses. It can help patients who need a scleral lens but have significant time and/or travel constraints and cannot make the required multiple office visits sometimes necessary for the fitting of commercial scleral lenses.

This modality can benefit first-time scleral fits that have significant corneal irregularities, especially peripheral ectasias where decentering the optic zone can be key to achieving a successful fit, conjunctival abnormalities (such as pingueculae, pterygia and/or filtering blebs) and/or asymmetric scleral contours. It is a great first-line option for patients who have especially complex anterior segment pathologies and

are in immediate need of a perfect-fitting lens for ocular protection (i.e., Stevens-Johnson syndrome, persistent epithelial defect and other severe ocular surface disease). Lastly, it can be a last line of contact lens therapy before considering surgical intervention.

GP lenses are vital to vision rehabilitation for our irregular cornea patients. We are fortunate to have many options to offer them (Table 1). Being skilled in fitting different lens modalities will help clinicians make the best choices and meet the visual needs of these challenging but rewarding patients. **RCCL**

1. Jinabhai A, Radhakrishnan H, Tromans C, O'Donnell C. Visual performance and optical quality with soft lenses in keratoconus patients. *Ophthalmic Physiol Opt.* 2012;32(2):100-16.
2. Griffiths M, Zahner K, Collins M, Carney L. Masking of irregular corneal topography with contact lenses. *CLAO J.* 1998;24(2):76-81.
3. Kosaki R, Maeda N, Bessho K, et al. Magnitude and orientation of Zernike terms in patients with keratoconus. *Invest Ophthalmol Vis Sci.* 2007;48(7):3062-8.
4. Bennett ES. GP annual report 2019. *Contact Lens Spectrum*, 2019; 34(10):22-7.

5. Zadnik K, Barr JT, Steger-May K, et al. Comparison of flat and steep rigid contact lens fitting methods in keratoconus. *Optom Vis Sci.* 2005;82(12):1014-21.
6. Gordon MO, Steger-May K, Szczotka-Flynn L, et al. Baseline factors predictive of incident penetrating keratoplasty in keratoconus. *Am J Ophthalmol.* 2006;142(12):923-30.
7. Bennett ES, Barr JT, Szczotka-Flynn L. Keratoconus. In Bennett ES, Henry VA, eds., *Clinical Manual of Contact Lenses* (4th ed.). Philadelphia, Lippincott Williams & Wilkins; 2014:518-77.
8. Zheng F, Caroline P, Kojima R, et al. Corneal elevation differences and the initial selection of corneal and scleral contact lenses. Poster presented at the Global Specialty Lens Symposium. Las Vegas, January 2015.
9. Zadnik K, Barr JT, Edrington TB, et al. Baseline findings in the Collaborative Longitudinal Evaluation of Keratoconus (CLEK) Study. *Invest Ophthalmol Vis Sci.* 1998;39(13):2537-46.
10. Bennett ES, Grohe RM, Anderson BW, et al. Piggyback applications in modern contact lens practice. *Contact Lens Spectrum.* 2007; 22(12):17.
11. Romero-Jiménez M, Santodomingo-Rubido J, González-Méjome JM, et al. Which soft lens power is better for piggyback in keratoconus? Part II. *Cont Lens Anterior Eye.* 2015;38(1):48-53.
12. Michaud L, Brazeau D, Corbeil ME, et al. Contribution of soft lenses of various powers to the optics of a piggy-back system on regular corneas. *Cont Lens Anterior Eye.* 2013;36(6):318-23.
13. Sclafani L, Alvis C. Utilizing technology instead of time to successfully fit the irregular cornea with hybrid lenses. Presented at the 2020 Global Specialty Lens Symposium. Las Vegas, NV. January 2020.
14. Nau AC. A comparison of synergeyes versus traditional rigid gas permeable lens designs for patients with irregular corneas. *Eye Contact Lens.* 2008;34(4):198-20.

SOFT OR SCLERAL LENSES FOR DRY EYE PATIENTS?

Determine the best option that treats your patient's symptoms and expectations.

By David Sweeney, OD

Often, patients believe they are not candidates for contact lenses because of their chronic dry eyes. Lens-induced dry eye can cause associated symptoms to appear or even worsen, while pathologic causes of dry eye include more common etiologies such as evaporative meibomian gland dysfunction (MGD).^{1,2} Aqueous deficiency is another less common cause of dry eye due to lacrimal gland dysfunction associated with systemic diseases, such as Sjögren's syndrome or chronic graft-vs.-host disease (GVHD).

In addition to ocular surface and tear quality concerns, other factors contribute to the complexity of fitting contact lenses, such as patient's refractive error, corneal or conjunctival irregularities and poor blink function. Perhaps they have tried contact lenses in the past and were not successful due to comfort, vision or handling. However, much has changed with contact lens materials and design over the last 10 years in regards to access, comfort and variety.

Dry eye patients who are not great candidates for refractive surgery should consider the appropriate contact lens as an alternative.³ Improving the ocular surface and tear film prior to contact lens fitting is the key to success.

TREATMENT AND PREP

Start dry eye treatment as early as you can in the fitting process, and take the time to assess the severity of the patient's condition. If you provide them the optimal dry eye treatment while stressing the importance of compliance, you will be giving them the tools they need to achieve the highest level of contact lens wear success and adherence.

Determining the root cause of dry eye will help make the contact fitting process successful. Review the patient's symptoms with the Ocular Surface Disease Index (OSDI) questionnaire and medical history and note any inflammatory conditions, such as rheumatoid arthritis,

thyroid disease and allergies, as well as the medications they use that may contribute to dry eye, such as anti-anxiety/antidepressant medications, anti-hypertensives and oral antihistamines. Consider all the different behavioral and environmental factors that could exacerbate their dry eyes. Ask them how much of their day is spent looking at their computer. Then, thoroughly assess their ocular surface and tear film with numerous tests, including Oculus Keratograph 5M imaging. After thoroughly assessing and determining the patient's dry eye severity, prescribe treatments to manage the condition and prepare the eye for contact lens success.

Lastly, determine the patient's visual demands. We want to provide them the best possible vision, ease of handling, comfort and relief of dry eye symptoms.

SOFT LENS BENEFITS

This lens type may be the preferred choice for patients with mild dry eye or patients who are consistent with their dry eye treatment. These lenses are made of flexible materials that drape over elevations or depressions in the conjunctiva, often making them easier to fit. One key measurement for fitting contact lenses is corneal diameter. For example, with smaller corneas, select smaller diameter soft lenses and flatter base curves to improve edge alignment and tear flow under the lens for improved comfort.⁴ Soft lens handling may be easier for patients with previous soft lens experience. Unfortunately, some may still need instruction on better techniques.

ABOUT THE AUTHOR



Dr. Sweeney practices at Vision Source Insight in Atlanta and is a member of both the Georgia Optometric Association and American Optometric Association (AOA). He is a member of the AOA's Cornea and Contact Lens and Low Vision sections.

Daily disposable lenses provide fresh, clean and convenient lenses. In my practice, I have found this option better for people with allergies. Also, storage solutions used with reusable lenses may result in toxicity.⁵⁻⁷

Soft lenses are available in new breathable silicone hydrogel materials with high-water gel-like surface treatments (Precision1 and Dailies Total1, Alcon) for enhanced comfort and increased wearing time. Fortunately, new daily disposable lenses are available to correct higher prescriptions, astigmatism as well as presbyopia with multifocal designs.

Consider trying soft lenses first if you note irregular conjunctival anatomy on the slit lamp exam. Also consider lenses such as Acuvue Transitions (Johnson & Johnson) for patients who are light sensitive due to retinal or macular dystrophy or albinism.

SCLERAL BENEFITS

Scleral lenses made of rigid, gas permeable (GP) materials provide crisper vision to patients with irregular corneas due to keratoconus or other corneal diseases, or due to corneal trauma or refractive surgery such as radial keratotomy, photorefractive keratectomy, LASIK or cataract surgery.⁸⁻¹¹

Still, fitting scleral lenses often requires additional follow up to fine tune the fit and monitor lens settling. Another deterrent to this modality is the higher cost attributed to doctor training, equipment and multiple scleral lens trial sets and replacement costs.

In my practice, patients with moderate to severe dry eye often find scleral lens often more comfortable than soft lenses for the following reasons:

- The thick 0.25mm tear layer across the back surface of the contact lens and over the cornea provides constant lubrication. Only use preservative-free saline in the bowl of the lens before application. Consider preservative-free Nutrifill (Contamac) saline solution or even autologous serum in the bowl of lens for severe dry eye patients.

- Breathable high-oxygen transmissible materials such as Boston XO2 (Bausch + Lomb) and Optimum Infinite (Contamac) provide superior corneal health by allowing more oxygen to reach the cornea.

- New Hydra-PEG (Tangible Science) surface treatments improve wettability and reduce protein deposition.¹² Patients notice significant improvement in dryness, lens comfort and vision.

Scleral lenses should be large enough to not touch the cornea. However, selecting a

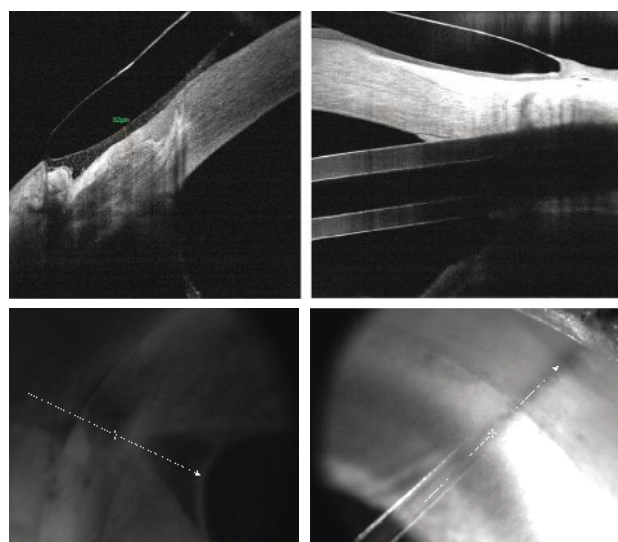


Fig. 1. A depression in this patient's conjunctiva, due the removal of a tube shunt, allowed debris to be sucked under the loose scleral lens edge, clouding vision.

scleral lens diameter that is too large may complicate the fit as the conjunctival anatomy gets more irregular further from the limbus.¹³⁻¹⁵ Alignment with the conjunctiva can be perfected with use of toric peripheral curves, custom vaults over pingueculas and custom depressions if there is a valley following surgery (*Figures 1 and 2*).

OCT imaging can guide where edge alignment needs to be enhanced to avoid tear debris getting sucked under a loose edge. Tear layer debris under the lens will blur vision after just a few hours of wear. Corneal topography over the scleral lens can be helpful to assess multifocal add location and to determine the need to decenter the reading add for better distance and near vision (*Figure 3*).

A well-aligned scleral lens will be more difficult for the patient to remove. However, if they rotate the lens 90 degrees with their finger to misalign the lens with the sclera, the lens is easily removed with a lens remover.

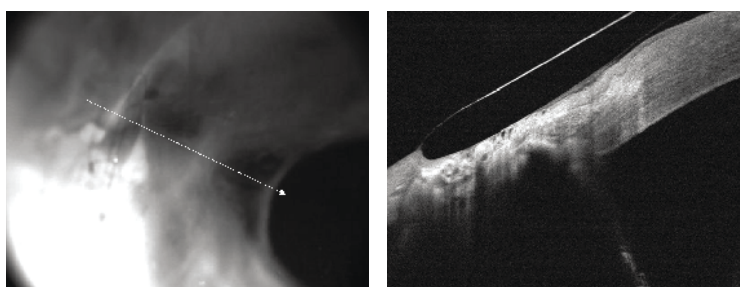


Fig. 2. The patient in Figure 1 was refit with a scleral lens with a lower edge to better align with the conjunctival depression. The patient reported better vision throughout the day.

SOFT OR SCLERAL LENSES FOR DRY EYE PATIENTS?

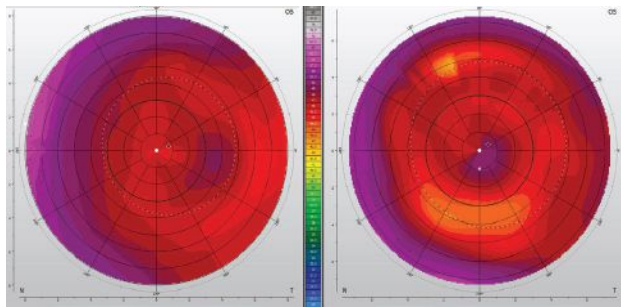


Fig. 3. This presbyopic dry eye patient placed their scleral multifocal lens with a decentered add on the eye upside down (left). After rotating the lens 180 degrees, the reading add was positioned correctly (right).

Patients with Sjögren's or GVHD will do best with well-fitted scleral lenses because of their ability to relieve their disabling dryness by bathing the ocular surface with a tear reservoir between their compromised ocular surface and back surface of the scleral lens.¹⁶⁻¹⁸ Scleral lenses provide a smooth ocular surface over irregular or diseased corneas, resulting in best possible vision and greatly improving quality of life.

CASE 1

A 36-year-old Caucasian male presented to the office requesting a scleral lens fit. He complained of dry eye, discomfort and severe light sensitivity, which made him unable to function at work and play with his three young children. He was diagnosed with GVHD after an allogeneic stem cell transplant to treat his leukemia diagnosed three years ago.

Ocular history was remarkable for LASIK surgery to correct his -3.00D myopia in each eye. He used autologous serum eye drops Q2H to QID OU and Pred Forte (prednisolone acetate ophthalmic suspension 1%, Allergan) 1% eye drops BID OU. He had discontinued Restasis (cyclosporine A 0.05%, Allergan) and Xiidra (lifitegrast 5%, Novartis) due to increased burning with use. To improve his ocular surface and prepare it for scleral lens wear, we prescribed erythromycin antibiotic ointment two to three times a day. His Pred Forte was changed to Lotemax SM (loteprednol etabonate 0.38%, Bausch + Lomb) TID, as it has less risk of intraocular pressure spikes and cataract development.

During the course of the scleral lens fitting we addressed severe meibomian gland obstruction, inflammation, eyelid biofilm formation and tear film instability to help repair the cornea and conjunctiva.

We selected Jupiter scleral lenses with initial trial lens diameter of 16.6mm with spherical peripheral curves. To improve comfort and prevent tear debris due to edge lift in the vertical meridian (Figure 4), we ordered

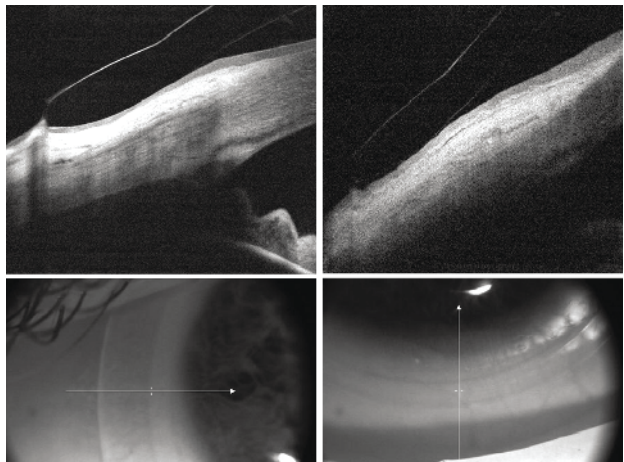


Fig. 4. To correct edge lift in the vertical meridian in this trial fit spherical scleral lens, we ordered toric peripheral curves flatter along the horizontal and steeper along the vertical meridians.

toric peripheral curves that provided better alignment.

The final lens noticeably improved the patient's comfort and protected his cornea. He noted better visual quality, as the scleral lens provided a smooth surface over his compromised cornea. Scleral lenses helped relieve his severe dry eye, and his drop frequency eventually reduced and light sensitivity improved. He could function better at work and have fun with his children.

CASE 2

An 84-year-old Caucasian female was referred by her optometrist for scleral lens fitting to treat her advanced keratoconus and discomfort with corneal GP lenses. She reported spending only 30 minutes per day on her computer. Her ocular history was positive for cataract extraction with peripheral-curve IOL implantation and nodules were removed from her left cornea. She had contact lens-induced dry eye resulting in her corneal GP lenses becoming less tolerable over the years. Her manifest refraction was +3.75 - 1.00 x 125 20/50 OD and +6.50 - 1.50 x 180 20/30 OS with +1.50 add OU. Autorefractor K's were 54.00/56.75 @48 OD and 58.50/62.50 @98 OS. Her corneal diameter was 11.90mm, she was OD dominant and pupil size was 3mm OU. Oculus K5M revealed mild MGD and keratoconus, worse in OD (Figure 5).

We initially tried improving the GP fit with custom corneal topography-based lenses, but comfort did not improve significantly. She was successful for the first couple of weeks using scleral lenses, with good 20/30 vision in each eye. But on two occasions in the first month, she had difficulty removing the lens. Unfortunately, she lived about three hours from the

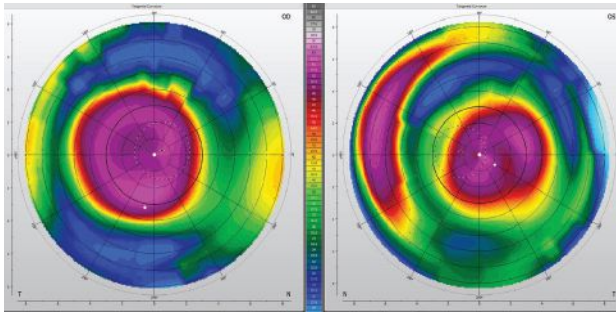


Fig. 5. Corneal topography of advanced keratoconus OU successfully fit with Kerasoft IC Toric lenses.

office, which worried her enough to strongly request a different solution.

To improve her success with contact lenses, we recommended: warm compresses and lid massage for her moderate MGD, triglyceride form of omega-3s for inflammation, 0.01% hypochlorous acid lid hygiene spray for her eyelid biofilm and artificial tears for tear film instability.

We then offered her Kerasoft IC Toric (Bausch + Lomb) soft lenses that are designed to correct keratoconus and other irregular corneas.¹⁹ Single lenses were ordered and then second lens dispensed with final prescription and vision: 8.0 base curve, 14.50 +5.50-1.25 x 138 20/25 OD and 7.80 base curve, 14.50 +7.25 - 1.75 x 176 20/40 OS with standard peripheral curves. She was delighted with her vision, all-day lens comfort and handling (*Figure 6*). With her small pupils, she only needed +1.50D readers for fine print.

Her toric silicone-hydrogel contact lenses provided conservative dry eye therapy, and she found lens wear to be comfortable all day. The high plus power she needed resulted in a thicker lens that corrected her irregular astigmatism and maintained excellent vision despite her irregular cornea from keratoconus.

Contact lenses can improve quality of life at work, home and play for many dry eye patients. They are happy seeing well with more comfortable eyes while free of glasses during the day. You can improve your patient's contact lens success by reducing symptoms of dry eyes with timely diagnosis and appropriate treatment. Determining whether soft or scleral lenses will better address the patient's problems due to dry eye will help provide your patients the vision and comfort they need and improve their quality of life. [ncc](#)

1. Molina K, Graham AD, Yeh T. et al. Not all dry eye in contact lens wear is contact lens-induced. *Eye Contact Lens*. September 10, 2019. [Epub ahead of print].

2. Lemp MA, Crews LA, Bron AJ, et al. Distribution of aqueous-deficient and evaporative dry eye in a clinic-based patient cohort: a retrospective study. *Cornea*. 2012;31(5):472-8.

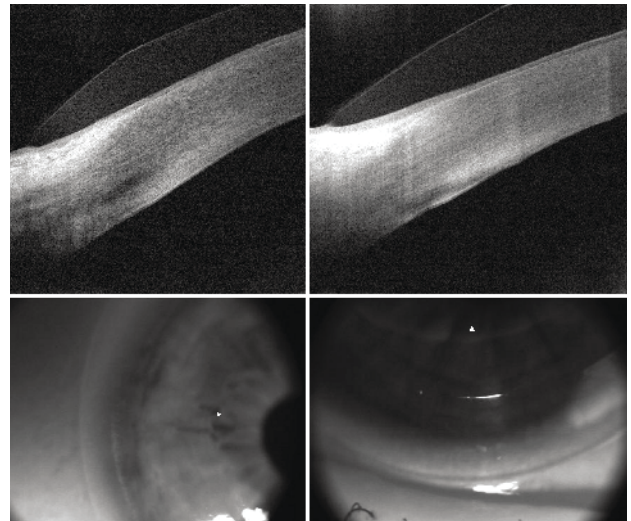


Fig. 6. This toric lens has a thicker edge profile for improved lens stability, while the edge is parallel to the conjunctiva for good comfort.

3. Chuck RS, Jacobs DS, Lee JK, et al. Refractive errors & refractive surgery Preferred Practice Pattern. *Ophthalmology*. 2018;125(1):P1-P104.
4. Caroline PJ, André MP. The effect of corneal diameter on soft lens fitting, part 1. *Cont Lens Spectrum*. 2002;17(4):56.
5. Stapleton F, Naduvilath T, Keay L, et al. Risk factors and causative organisms in microbial keratitis in daily disposable contact lens wear. *PLoS One*. 2017;12(8):e0181343.
6. Wu YT, Teng YJ, Nicholas M, et al. Impact of lens case hygiene guidelines on contact lens case contamination. *Optom Vis Sci*. 2011;88(10):e1180-1187.
7. Wu Y, Carnt N, Willcox M, Stapleton F. Contact lens and lens storage case cleaning instructions: whose advice should we follow? *Eye & Cont Lens*. 2010;36(2):68-72.
8. Alipour F, Kheirkhah A, Jabarvand Behrouz M. Use of mini scleral contact lenses in moderate to severe dry eye. *Cont Lens Anterior Eye*. 2012;35(6):272-6.
9. Walker MK, Bergmanson JP, Miller WL, et al. Complications and fitting challenges associated with scleral contact lenses: a review. *Cont Lens and Ant Eye*. 2015;39:88-96.
10. Visser E-S, Visser R, van Lier H, Otten H. Modern scleral lenses part II: patient satisfaction. *Eye Contact Lens*. 2007;33:21-5.
11. Romero-Rangel T, Stavrou P, Cotter J, et al. Gas permeable scleral contact lens therapy in ocular surface disease. *Am J Ophthalmol*. 2000;130:25-32.
12. Mickles C, Harthan J, Barnett M. A surgical treatment solution for scleral lens wearers with dry eye. Presentation at the Global Specialty Lens Symposium. Las Vegas. January 2019.
13. van der Worp E, Graf T, Caroline PJ. Exploring beyond the corneal borders. *Cont Lens Spectrum*. 2010;25(6):26-32.
14. Ritzmann M, Morrison S, Caroline P, et al. Scleral shape and asymmetry as measured by OCT in 78 normal eyes. Poster presented at the Global Specialty Lens Symposium, Las Vegas, January 2016.
15. van der Worp E. A Guide to Scleral Lens Fitting, Version 2.0. Forest Grove, OR: Pacific University; 2015. Available: commons.pacificu.edu/mono/10/. Accessed April 21, 2020.
16. Jacobs DS, Rosenthal P. Boston scleral lens prosthetic device for treatment of severe dry eye in chronic graft-versus-host disease. *Cornea*. 2007;26(10):1195-9.
17. Schornack MM, Baratz KH, Patel SV, Maguire LJ. Jupiter scleral lenses in the management of chronic graft versus host disease. *Eye Cont Lens*. 2008;34(6):302-5.
18. Alipour F, Kheirkhah A, Jabarvand Behrouz M. Use of mini scleral contact lenses in moderate to severe dry eye. *Cont Lens Anterior Eye*. 2012;35(6):272-6.
19. Kumar P, Bandela PK, Bharadwaj SR. Do visual performance and optical quality vary across different contact lens correction modalities in keratoconus? *Cont Lens Anterior Eye*. March 29, 2020. [Epub ahead of print].

The How and Why of Contact Lens Deposits

Optometrists need a comprehensive understanding of this complication to help patients avoid it. By Heidi Wagner, OD, MPH

In this era of disposability, many eye care providers are less concerned about contact lens deposits. In 2019, daily disposable soft contact lenses (SCLs) accounted for 35% of international lens prescribing and 44% of lenses prescribed in the United States.¹ As the market share of conventional and planned replacement SCLs shrinks, lens deposits may be less prevalent and less severe; still, lens deposition remains a factor, especially with the expanded use of specialty contact lenses.

Specialty SCLs, gas permeable (GPs) lenses and hybrids play an important role in the United States market of 45 million contact lens wearers.² Specialty SCLs and hybrids are typically replaced far less frequently than daily disposables—often at quarterly or six-month intervals. In contrast to SCLs, GPs are often replaced “reactively” (i.e., when the patient requires a change in lens power or experiences reduced comfort, degraded vision or lens loss or damage) rather than on a planned schedule.

Contact lens deposits significantly impact the patient’s lens wearing experience and ocular health. Lens spoilage can potentially reduce lens surface wettability and adversely impact patient comfort, wearing time and quality of vision. Further, lens deposits can result in contact lens-related ocular pathology, including papillary conjunctivitis,

punctate keratitis, corneal inflammatory events and even microbial keratitis.^{3,4} This article reviews how to identify various types of lens deposits, describes the impact of lens material choices on comfort and vision and delineates how lens care options and surface treatments impact deposition.

UNDERLYING MECHANISMS

A general understanding of the underlying mechanisms of lens deposits and an awareness of strategies to reduce them remain integral to contemporary contact lens practice. Lens depositing is influenced by many factors, including patient compliance, individual tear chemistry and environment. Individual tear chemistry is evidenced by lipid composition, protein profile, mucin and electrolyte analysis—characteristics that manifest in the wearer response.⁵ Understanding these interactions can help the eye care provider optimize lens performance and minimize adverse events.

IDENTIFYING DEPOSITS

Lens deposition begins within minutes of wear.⁶ While surface deposits may be minimized by increasing the frequency of lens replacement, variation exists among individual patients with regards to tear chemistry and compliance with the lens care regimen.⁷ Practitioners must be vigilant in identifying lens deposits

with all types of lens materials and replacement regimens.

Contact lens deposits are best identified through observation of the lens on the eye with biomicroscopy under varying illumination and magnification. A lens loupe is a practical alternative, particularly if the lens is damaged and could potentially harm the eye.

Lens deposits can be distinguished by color, structure and location. Identification of the predominant deposit can guide the practitioner in management decisions. There are a number of common types of deposits practitioners should be aware of.

Proteins and lipids. These are long-recognized lens deposits in contact lens practice.^{8,9} Protein deposits occur as lysozyme binds to the lens surface and undergoes structural changes that impair its function. These changes, termed protein denaturation, are influenced by numerous factors such as the lens substrate, pH and temperature.⁶ Protein deposits are characterized by an opaque film on the lens that becomes more obvious over time. In contrast, lipid deposition is characterized by a shiny, lubricious ap-

ABOUT THE AUTHOR



Dr. Wagner is a professor of clinical optometry and director of extern programs at Ohio State University.

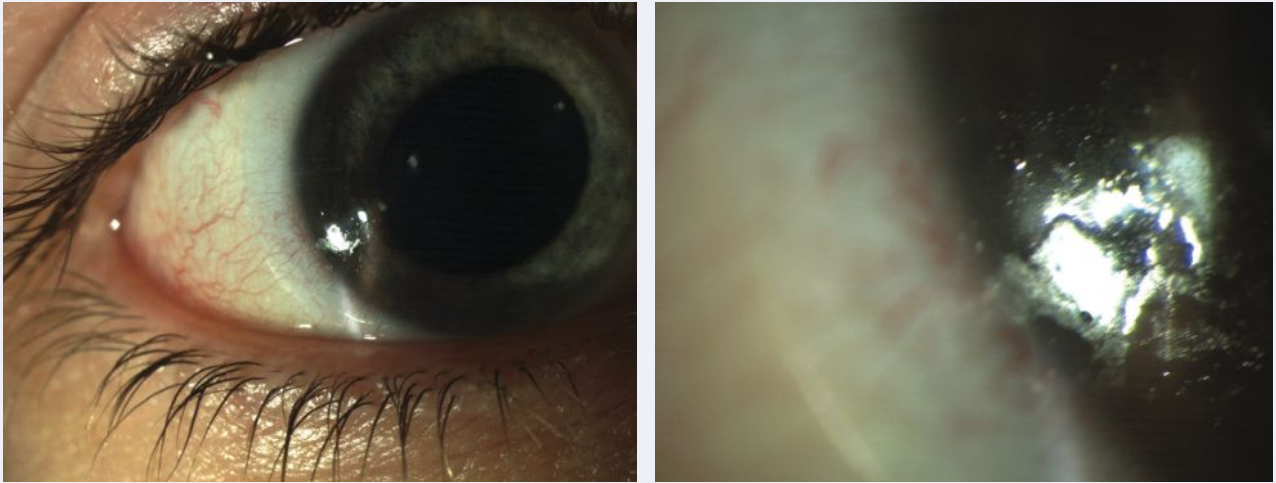


Fig. 1. Patients can present with both protein and lipid deposits. These common lens deposits are shown here at (left) low and (right) high magnification.

pearance. Both are present in SCLs and GPs. Protein and lipid deposits can be observed in combination in an individual patient (*Figure 1*).

Lens calculi. Sometimes referred to as “jelly bumps,” these deposits are distinct, localized elevations on the anterior surface of the SCL. Lens calculi are composed of calcium, lipid and mucoprotein inherent in the tear film (*Figure 2*).¹⁰ Their formation is attributed to depletion of the aqueous tear layer that results in a hydrophobic zone that, in turn, promotes deposition.¹¹ If significant in number and size, they can degrade comfort and vision.

While frequently observed in the era of conventional SCL lens wear, they are relatively uncommon in lenses that are replaced monthly

or more frequently. Thus, if practitioners observe lens calculi in patients wearing lenses with shorter replacement cycles, wearers may be “stretching” their replacement cycles. As the deposit is embedded within the matrix of the lens, replacement is necessary.

This type of deposit is more commonly observed in high-water, ionic (group IV), hydrogel lens materials.¹¹ The practitioner can address this problem by refitting the patient into a different lens material, though simply reinforcing the lens replacement schedule or refitting into daily disposable contact lenses may address the problem.

Fungal deposits. Given the prediction of fungus for lens materials of a higher water content, this type

of deposit, which is often characterized by a filamentary appearance, is more commonly observed in soft or hybrid lenses.¹²

Fungal deposits may be associated with poor disinfection regimens. This can occur when patients use saline instead of a multipurpose disinfection solution or when part-time wearers or multiple pair (e.g., colored lenses) wearers store lenses in solution for extended periods of time. Additionally, patients who disinfect lenses with hydrogen peroxide systems may be unaware that the neutralized disinfection solution is saline and that the solution must be replaced every seven days if the lenses are not worn.¹³ Therefore, it is important to prescribe a lens care system that is appropriate for

Release Date: May 15, 2020

Expiration Date: May 15, 2023

Estimated time to complete activity: 2 hours

Jointly provided by Postgraduate Institute for Medicine (PIM) and Review Education Group.

Educational Objectives: After completing this activity, the participant should be better able to:

- Discuss the underlying mechanisms of contact lens deposits.
- Identify contact lens deposits in their patients.
- Recommend changes to reduce deposits in their contact lens wearers.
- Factor in lens material choices to improve comfort and vision.
- Describe how lens care options and surface treatments impact deposition.

Target Audience: This activity is intended for optometrists engaged in the care of patients with contact lens deposits.

Accreditation Statement: In support of improving patient care, this



activity has been planned and implemented by the Postgraduate Institute for Medicine and Review Education Group. Postgraduate Institute for Medicine is jointly accredited by the Accreditation Council for Continuing Medical Education, the Accreditation Council for Pharmacy Education, and the American Nurses Credentialing Center, to provide continuing education for the healthcare team. Postgraduate Institute for Medicine is accredited by COPE to provide continuing education to optometrists.

Faculty/Editorial Board: Heidi Wagner, OD, MPH, Ohio State University

Credit Statement: This course is COPE approved for 2 hours of CE credit. Course ID is **67922-CL**. Check with your local state licensing board to see if this counts toward your CE requirement for relicensure.

Disclosure Statements:

Dr. Wagner has contracted research with Alcon and has received honoraria from Wink Productions.

Managers and Editorial Staff: The PIM planners and managers have nothing to disclose. The Review Education Group planners, managers and editorial staff have nothing to disclose.



THE HOW AND WHY OF CONTACT LENS DEPOSITS

the patient's wearing schedule and ensure that the patient understands how to use it.

Iron deposits. Characteristically round and brown-to-orange in color, such deposition may be a consequence of incorporating tap water into the lens care regimen, despite published evidence of the association of *Acanthamoeba* with water exposure.¹⁴ In a survey of more than 1,000 SCL wearers, 31% reported rinsing their SCLs with tap water on at least one occasion, and 10% reported always or fairly often rinsing their lenses with tap water.¹⁵ Of the wearers who reported rinsing their lenses with tap water, 41% reported also storing their lenses in tap water.¹⁵

Upon identifying iron deposits, eye care providers should emphasize that no amount of water exposure is acceptable. This message may be reinforced by promotional materials, such as the “no water” stickers distributed by the Cornea, Contact Lenses and Refractive Technologies Diplomate Section of the American Academy of Optometry (Figure 3).

Mucin balls. These deposits are round, semitransparent spheres ranging in size between 40 μ m and 120 μ m. While mucin balls have been observed in a variety of lens materials, they are more frequently associated with silicone hydrogels (SiHy). Research suggests that their formation is based on a mechanical interaction between the cornea and high modulus SiHy materials.¹⁶

Mucin balls do not appear to impact vision or comfort and, therefore, can easily be differentiated from other types of lens deposits. They are more likely observed in first-generation SiHy products that are characterized by “stiffer” (high modulus) lens materials.

Environmental debris. Make-up, such as mascara and eyeliner, is a common source of lens deposits.

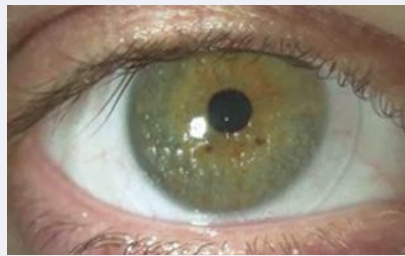

Fig. 2. This patient presented with distinct, localized elevations on the anterior surface of the lens—lens calculi.

While eye make-up may be easily identified by color and texture, identifying the source of other contaminants degrading the lens surface may prove to be more elusive.¹⁷

Lotions transferred from fingertips and aerosol hairspray can also bind to the lens. These types of deposits can be eliminated by proper hand washing before lens handling and applying make-up after lens insertion (Figure 4).

Other potential sources of environmental lens deposits include organic debris such as leaf litter and inorganic contaminants such as a metallic foreign body. If you suspect a metallic foreign object, always perform a more extensive eye examination, given the possibility of an intraocular foreign body.

Lipid, protein and exogenous contaminants are likely to deposit on both GP and SCL lens materials. Unique to GP lenses, however, is poor wetting exhibited in newly dispensed lenses. This is somewhat less common as water-soluble products currently used in the manufacturing process have largely eliminated the oily residue (i.e., “pitch”) that was previously part of the manufacturing process.

This problem can generally be solved by plasma cleaning or soaking lenses in an appropriate conditioning solution prior to dispensing. Lens cleaners can also be used with appropriate materials, as discussed below.

On occasion, topical and systemic medications have been associated with lens discoloration in SCLs. For example, rifampin, a drug used to treat tuberculosis, can cause an orange discoloration of contact lenses.¹⁸ A similar phenomenon has been reported with sulfasalazine, which is used to manage inflammatory bowel disease.¹⁹ Lens discoloration, ranging from pink to brown, has also been observed with some topical medications, such as the epinephrine ophthalmic drops used in the past to treat glaucoma.

While these conditions are not observed in every day clinical practice, the practitioner should be aware of the potential of oral and topical medications to influence the tear ocular environment.²⁰

Lysozyme deposits. Notably, lysozyme deposition may provide beneficial effects during contact lens wear, as lysozyme exhibits antibacterial and anti-inflammatory properties.⁶ Research also shows that lactoferrin in the tears has the potential to work in concert with lysozyme to inhibit gram-positive and gram-negative bacteria.⁶ However, further study is needed to better understand these interactions.

Lens materials influence the deposition of tear-derived products that, in turn, influences lens comfort.²¹ Some investigators have also challenged the belief that lens deposition negatively impacts comfort, noting that lysozyme has, on occasion, been associated with increased comfort in HEMA-based lens materials. This was attributed to the fact that lysozyme retains a higher degree of activity when deposited on traditional hydrogel lens materials compared with silicone hydrogels.²² They propose the development of lens materials that can selectively bind “good” deposits and inhibit “bad” deposits.²³

LENS MATERIAL

The FDA classifies hydrogel contact lenses as ionic (groups III and IV) and nonionic (groups I and II). Groups II and IV exhibit a higher water content ($\geq 50\%$ water) than groups I and III. SiHy, in general, are characterized by lower water content but higher oxygen permeability.⁶

The rate of protein deposition is significantly related to the lens material. Polymethyl methacrylate (PMMA) and SiHy lens materials deposit less lysozyme than hydrogels, and lysozyme is particularly prevalent in high-water, ionic lens (group IV) materials.²⁴ The external environment and lens handling further expose the lenses to contaminants.

SCLs provide an ideal medium to attract lens deposits, given the hydrophilic surface. Hydrogel lenses contain methacrylic acid to increase water content and oxygen permeability.²⁵ Consequently, HEMA-based lens materials exhibit a predisposition toward protein deposition, as the negatively charged methacrylic acid binds to positively charged proteins, including lysozyme.²⁶ Thus, refitting patients wearing SCLs from high-water, ionic lens (group IV) materials to low-water, non-ionic lens (group I) materials may reduce protein deposits. SiHy lenses, while highly oxygen permeable, are potentially hydrophobic in nature. They may exhibit reduced wettability and a greater tendency towards lipid deposition compared with their HEMA-based counterparts.²⁷

Rigid lens materials exhibit a parallel story. All but obsolete, PMMA contact lenses were deposit resistant but impervious to oxygen. GP lenses are permeable to oxygen in varying degrees based on the polymer components. Silicone was added to the lens material to create silicone acrylate (SA) lens materials.

This resulted in an increased oxygen permeability but more protein deposition.

Fluorine was then added to maintain oxygen permeability and improve wettability of the current generation of fluorosilicone acrylate (FSA) lens materials. Earlier generation SA lenses tended to deposit proteins while newer FSA lenses tend to deposit lipids.²⁸

Given these various material characteristics, clinicians should customize the lens material to the individual patient. For example, a hyper-Dk lens material may be desirable for overnight wear in orthokeratology while a moderate-Dk lens material may be ideal for a patient who tends to deposit lipids.

In addition, the provider can further tailor the lens care regimen to the needs of the lens wearer. For example, a heavy lipid depositor who also requires a high-Dk lens material could benefit from a more rigorous lens care system as described below.

LENS WEAR AND CARE

Proper contact lens wear and care practices are essential for all contact lens modalities, and they should be tailored to the particular lens

modality and patient. In a recent survey administered by the Centers for Disease Control and Prevention, six of seven contact lens wearers acknowledged at least one behavior that places them at risk for a contact lens-related adverse event.² Eye care providers play an important role in educating all contact lens wearers at the initial fitting as well as reinforcing best practices at every follow-up visit.

Clinicians should provide specific guidance based on the unique needs of the patient, including the lens material, replacement schedule, contact lens care, tear chemistry and history of compliance.

SCLs. Appropriate lens care goes a long way in maintaining a clean lens surface. Chemical disinfection systems (commonly designated as multipurpose solution [MPS]) combine cleaning, rinsing and disinfection. While MPS is integral to lens care, it is useful to remember that its success is based on its ability to deliver key components of the lens care regimen: cleaning, rinsing, disinfecting and storage.

Cleaning removes loosely adhered deposits, as does lubrication. Rinsing removes the debris and avoids the introduction of addition-

Other Considerations

Further consideration for giant papillary conjunctivitis (GPC) is warranted, given its association with lens deposits. GPC is most commonly associated with SCLs but can be associated with GPs, as well as sutures following surgery.³ While the condition was initially described as a "reaction" to soft contact lenses, the term was later redefined by researchers who postulated that the syndrome was immunologic in origin with deposits on the lenses serving as an antigen (type IV immune response).³⁵ A mechanical component has also been suggested, although there is no consensus on this issue.³⁶

GPC is characterized by papillae on the tarsal conjunctiva. In mild cases, patients may have symptoms of lens awareness. In severe cases of GPC, patients may experience excessive lens movement, substantial lens depositing and lens intolerance. Contact lens-induced GPC can be managed by increasing lens replacement frequency, decreasing lens wearing time or changing lens materials. Concurrent pharmacological management, such as mast-cell inhibitors/antihistamine combination drugs and topical steroids, can be added.



THE HOW AND WHY OF CONTACT LENS DEPOSITS

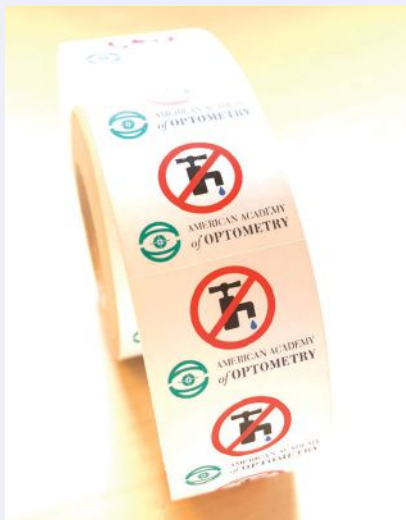

Fig. 3. These “no water” stickers, distributed by the American Academy of Optometry, can help reinforce to patients that no amount of water exposure is acceptable.

al external contaminants. Proper disinfection and storage limits microbial intrusion. It is important that patients remember that all lens care components—including the lens case, when applicable—are part of the lens care system.

In studies where the FDA required the manufacturers to inoculate the

lenses with one million organisms to study the efficacy of a lens care system, the inclusion of a cleaning step removed one log unit of microorganisms from the lens. If the cleaner was rinsed from the lens, two additional log units of microorganisms were further eliminated.¹⁷

This work reinforces the need for digital cleaning, even with MPS. The FDA further discouraged the promotion of “no rub” lens care systems after the voluntary removal of two lens care products from the marketplace following their association with *Fusarium* and *Acanthamoeba*.²⁹⁻³¹ Further studies have supported digital rubbing and rinsing to minimize deposits and limit bacterial contamination in reusable soft and GP lenses.^{32,33}

A separate surfactant or enzymatic cleaner is rarely indicated for two-week or monthly replacement SCLs, although these products may be added to the care regimen for “heavy depositors.” Surfactant cleaners remove loosely adhered lens debris, unbound protein and microbial contamination. As these

cleaners are less accessible than in the past, patients may require additional direction regarding where to purchase them.

Hydrogen peroxide systems are a particularly effective preservative-free disinfection option. Contemporary systems contain a surfactant and, in one system, a wetting agent. However, anecdotal reports suggest lens residue may be associated with solutions that contain a proprietary wetting agent. This can be resolved by switching to another hydrogen peroxide product without the wetting agent.

Practitioners should be cognizant of current MPS systems, make an initial prescribing decision and modify as needed. They should also be alerted to potential patient pitfalls, such as “topping off” (which can reduce disinfection efficacy), purchasing alternate products and not completing the cleaning regimen as directed. It should also be noted that SCL wearers who have an ample supply of lenses are more likely to replace their lenses at recommended intervals.³⁴

GPs. One-bottle care systems for cleaning, rinsing, disinfection and storage are also available for GP lenses. As with MPS SCL solutions, digital cleaning can enhance the efficacy of the process. For example, Unique pH (Menicon) and Boston Simplus (Bausch + Lomb) provide one-bottle convenience. Two-bottle systems, such as Boston Original and Advance (Bausch + Lomb), incorporate a separate abrasive cleaner that enhances the cleaning regimen. Boston Original was designed for lower-Dk SA lenses, which tend to deposit proteins, while Boston Advance was developed for higher-Dk FSA lens materials that deposit lipids.

Clinicians can also manage lens deposits by being judicious in the addition of Hydra-PEG (Tangible

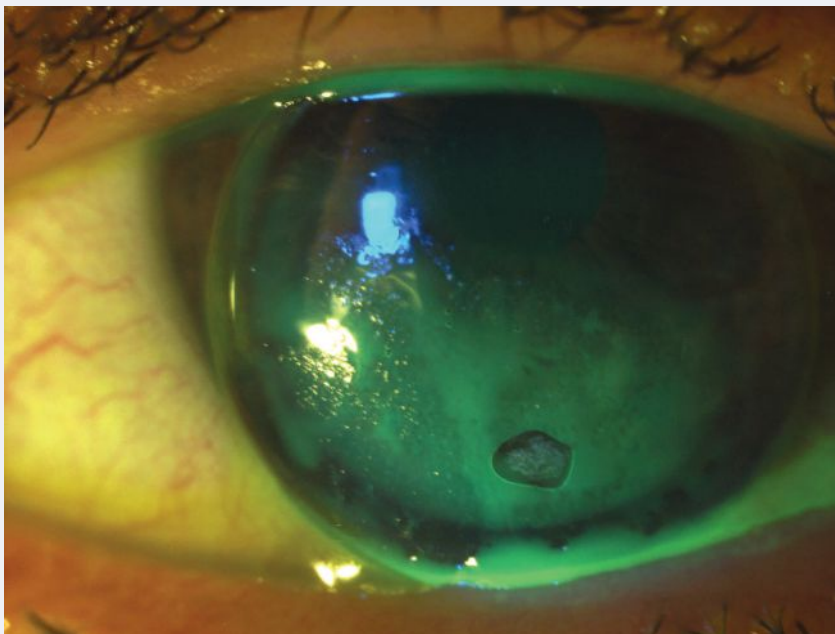


Fig. 4. In this case, lip balm was inadvertently transferred to the lens, resulting in poor GP lens wetting.

Science) and surface treatments. Hydra-PEG is a biocompatible polymer that may be applied to GP or hybrid lenses as part of the manufacturing process. As described by the manufacturer, the coating promotes a lubricious lens surface that is designed to inhibit lens deposits and fogging. Tangible Clean (Tangible Science) is an MPS solution designed for Hydra-PEG coated lenses. It can also be used for uncoated lenses.

Abrasive cleaners are contraindicated in plasma-treated lenses, hyper-Dk lens materials and with Hydra-PEG. Non-abrasive cleaners that contain alcohol are particularly effective with lipid removal and are compatible with hyper-Dk lens materials; however, no consensus exists regarding their use with plasma-treated lenses, and they are contraindicated with Hydra-PEG.

Given that tap water is contraindicated with all contact lenses, low viscosity solutions such as saline or MPS should be employed to rinse the cleaner from the lens. As this inadvertently introduces a third step, one-step hydrogen peroxide systems provide a practical alternative whereby the disinfection solution also contains a surfactant cleaner and the solution neutralizes to saline.

Anecdotally, patients who successively use MPS systems with corneal GPs may require a more rigorous system with scleral lenses, presumably because corneal lenses exhibit more tear exchange. Heavy depositors may also benefit from periodic cleaners such as enzymatic cleaners that remove protein or Progent (Menicon), which exhibits both cleaning and disinfection properties. Progent may be used as frequently as every two weeks for heavy depositors and can be used in office. Patients who experience difficulty digitally cleaning their lenses

because of the lens geometry (e.g., lenses for keratoconus with steep base curves) may also benefit from incorporating periodic cleaners.

Contact lens deposits are a well-known clinical challenge. This challenge can lead to reduced comfort and vision and negatively impact ocular health. Often, changing the contact lens or care regimen is not enough to ward off deposits. Many factors impact a patient's chances of experiencing this complication, including the lens material, surface treatments, wear schedules, care regimens and the patient's individual tear fluid composition. **rccl**

- Morgan PB. International contact lens prescribing in 2019. *Contact Lens Spectrum*. 2020;35(1):26-32.
- Cope JR, Collier SA, Nethercut H, et al. Risk behaviors for contact lens-related eye infections among adults and adolescents—United States, 2016. *MMWR Morb Mortal Wkly Rep*. 2017;66:841-5.
- Allansmith MR, Korb DR, Greiner JV, et al. Giant papillary conjunctivitis in contact lens wearers. *Am J Ophthalmol*. 1977;83(5):697-708.
- Aswad MI, John T, Barza M, et al. Bacterial adherence to extended wear soft contact lenses. *Ophthalmology*. 1990;97(3):296-302.
- Mann A, Tighe B. Contact lens interactions with the tear film. *Exp Eye Res*. 2013;117(12):88-98.
- Omali NB, Subbaraman LN, Coles-Brennan C, et al. Biological and clinical implications of lysozyme deposition on soft contact lenses. *Optom Vis Sci*. 2015;92(7):750-7.
- Ilhan B, Irkec M, Orhan M, et al. Surface deposits on frequent replacement and conventional daily wear soft contact lenses: a scanning electron microscopic study. *Clao J*. 1998;24(4):232-5.
- Lin ST, Mandell RB, Leahy CD, et al. Protein accumulation on disposable extended wear lenses. *CLAO J*. 1991;17(1):44-50.
- Jones L, Evans K, Sariri R, et al. Lipid and protein deposition of N-vinyl pyrrolidone-contacting group II and group IV frequent replacement contact lenses. *CLAO J*. 1997;23(2):122-6.
- Begley CG, Waggoner PJ. An analysis of nodular deposits on soft contact lenses. *J Am Optom Assoc*. 1991;62(3):208-14.
- Hart DE, Tidsale RR, Sack RA. Origin and composition of lipid deposits on soft contact lenses. *Ophthalmology*. 1986;93(4):495-503.
- Chen J, Fraser T, Fisher D, et al. Characteristics of fungal growth in soft contact lenses. *Int Contact Lens Clin*. 2000;26(4):84-91.
- Kilvington S, Lam A, Nikolic M, et al. Resistance and growth of *Fusarium* species in contact lens disinfectant solutions. *Optom Vis Sci*. 2013;90(5):430-8.
- Radford CF, Minassian DC, Dart JK. Acanthamoeba keratitis in England and Wales: incidence, outcome, and risk factors. *Br J Ophthalmol*. 2002;86(5):536-42.
- Zimmerman AB, Richdale K, Mitchell GL, et al. Water exposure is a common risk behavior among

soft and gas-permeable contact lens wearers. *Cornea*. 2017;36(8):995-1001.

- Tan J, Keay L, Jalbert I, et al. Mucin balls with wear of conventional and silicone hydrogel contact lenses. *Optom Vis Sci*. 2003;80(4):291-7.
- Weisbarth R, Henderson B. Hydrogel Lens Care Regimens and Patient Education. In: Bennett ES, Weissman BA, eds. *Clinical Contact Lens Practice*. Philadelphia, PA: Lippincott Williams & Wilkins; 2005.
- Lyons RW. Orange contact lenses from rifampin. *N Engl J Med*. 1979;300(7):372-3.
- Kreznoski JZ. Topical medications. *Int Ophthalmol Clin*. 1981;21(2):173-6.
- Miller D, Brooks SM, Mobilia E. Adrenochrome staining of soft contact lenses. *Ann Ophthalmol*. 1976;8(1):65-67.
- Jones L, Brennan NA, Gonzalez-Mejome J, et al. The TFOS international workshop on contact lens discomfort: report of the contact lens materials, design, and care subcommittee. *Invest Ophthalmol Vis Sci*. 2013;54(1):TFOS37-70.
- Subbaraman LN, Glasier MA, Varikooty J, et al. Protein deposition and clinical symptoms in daily wear of etafilcon lenses. *Optom Vis Sci*. 2012;89:1450-9.
- Subbaraman LN. Is contact lens deposition good or bad? *Contact Lens Update*. 2016. <https://contactlensupdate.com/2016/06/25/is-contact-lens-deposition-good-or-bad>.
- Subbaraman LN, Glasier MA, Senchyna M, et al. Kinetics of in vitro lysozyme deposition on silicone hydrogel, PMMA, and FDA groups I, II, and IV contact lens materials. *Curr Eye Res*. 2006;31(10):787-96.
- Tighe B. Rigid lens materials. In: Efron N, ed. *Contact Lens Practice*. Oxford, United Kingdom: Butterworth-Heinemann; 2010.
- Jones L, Mann A, Evans K, et al. An in vivo comparison of the kinetics of protein and lipid deposition on group II and group IV frequent-replacement contact lenses. *Optom Vis Sci*. 2000;77(10):503-10.
- Nicolson PC, Vogt J. Soft contact lens polymers: an evolution. *Biomaterials*. 2001;22(24):3273-83.
- Bennett ES, Henry VA, eds. *Clinical Manual of Contact Lenses*. 4th ed. Philadelphia: Lippincott Williams & Wilkins; 2013.
- Centers for Disease Control and Prevention. Update: Fusarium keratitis—United States, 2005-2006. *MMWR Morb Mortal Wkly Rep*. 2006;55(20):563-4.
- Joslin CE, Tu EY, Shoff ME, et al. The association of contact lens solution use and Acanthamoeba keratitis. *Am J Ophthalmol*. 2007;144(2):169-80.
- Food and Drug Administration. FDA Letter to Firms with Marketing Clearance for No-rub Multipurpose Contact Lens Solutions. 2019. www.fda.gov/medical-devices/contact-lenses/fda-letter-firms-marketing-clearance-no-rub-multipurpose-contact-lens-solutions.
- Cho P, Poon HY, Chen CC, et al. To rub or not to rub? - effective rigid contact lens cleaning. *Ophthalmic Physiol Opt*. 2020;40(1):17-23.
- Cho P, Cheng SY, Chan WY, et al. Soft contact lens cleaning: rub or no-rub? *Ophthalmic Physiol Opt*. 2009;29(1):49-57.
- Schneider C. The 'Pantry Load' Effect - Can it help drive more compliant contact lens replacement? *Optom Vis Sci*. 2012;89:E-abstract 120652.
- Spring TF. Reaction to hydrophilic lenses. *Med J Aust*. 1974;1(12):449-50.
- Donshik PC, Ehlers WH, Ballow M. Giant papillary conjunctivitis. *Immunol Allergy Clin North Am*. 2008;28(1):83-103, vi.



THE HOW AND WHY OF CONTACT LENS DEPOSITS

CE TEST - MAY/JUNE 2020

You can obtain continuing education credit through the Optometric Study Center.

Complete the test form and return it with the \$35 fee to: Jobson Healthcare Information, LLC, Attn.: CE Processing, 395 Hudson Street, 3rd Floor New York, New York 10014. To be eligible, please return the card within three years of publication. You can also access the test form and submit your answers and payment via credit card at Review Education Group online, www.revieweducationgroup.com. You must achieve a score of 70 or higher to receive credit. Allow four weeks for processing. For each Optometric Study Center course you pass, you earn 2 hours of credit from Pennsylvania College of Optometry.

Please check with your state licensing board to see if this approval counts toward your CE requirement for relicensure.

- Silicone hydrogel contact lenses tend to deposit ____ while hydrogel contact lenses tend to deposit ____.**
 - Protein; lipid.
 - Lipid; protein.
 - Fungus; bacteria.
 - Bacteria; fungus.
- Enzymatic contact lens cleaners remove:**
 - Protein.
 - Lipid.
 - Bacteria.
 - Fungus.
- Contact lens deposits may begin to form in:**
 - Minutes.
 - Hours.
 - Days.
 - Weeks.
- In studies where the FDA required the manufacturers to inoculate the lenses with one million organisms to study the efficacy of a lens care system, how many microorganisms were removed with the inclusion of a cleaning and rinsing step?**
 - 1,000.
 - 10,000.
 - One log unit.
 - Three log units.
- Which of the following are attributes of a surfactant cleaner?**
 - Removal of loosely adhered lens debris, unbound protein and microbial contamination.
 - Elimination of bound protein.
 - Lubrication of the lens.
 - Lens disinfection.
- Iron deposition in soft contact lenses is associated with:**
 - Improper contact lens disinfection practices.
 - Poor hygiene.
 - Water exposure.
 - Silicone hydrogel lens materials.
- High-water content, ionic, HEMA-based lens materials are associated with what type of deposition?**
 - Protein.
 - Lipid.
 - Cholesterol.
 - Iron.
- Which of the following is exhibited by lysozyme?**
 - Antibacterial properties.
 - Anti-inflammatory properties.
 - Antibacterial and anti-inflammatory properties.
 - None of the above.
- Silicone is characterized by which of the following properties?**
 - Hydrophilicity.
 - Hydrophobicity.
 - Low oxygen permeability, relative to HEMA-based lens materials.
 - Low modulus.
- In a recent survey of more than 1,000 soft contact lens wearers, what proportion reported always or fairly often rinsing their lenses with tap water?**
 - ~ 1%.
 - ~ 5%.
 - ~ 10%.
 - ~ 30%.
- “Topping off” _____ :**
 - Reduces disinfection efficacy.
 - Increases disinfection efficacy.
 - Reduces lens wettability.
 - Increases lens wettability.
- Alcohol in lens care products is known for all of the following, except:**
 - Antimicrobial activity.
 - Moisture-enhancing properties.
 - Lipid removal.
 - All of the above.
- Abrasive cleaners are contraindicated in which type of contact lens?**
 - Low-Dk materials.
 - Silicone acrylate materials.
 - Fluorosilicone acrylate materials.
 - Lenses treated with Hydra-PEG.
- Contact lens discoloration is associated with:**
 - Systemic medications but not topical medications.
 - Topical medications but not systemic medications.
 - Topical and systemic medications.
 - No medications.
- Hydrogen peroxide disinfection systems are characterized by all of the following, except:**
 - Preservative-free system.
 - Well-documented disinfection capabilities.
 - Efficacy as a lens lubricant.
 - Appropriate use with gas permeable and soft contact lenses.
- High-Dk fluorosilicone acrylate contact lenses are more likely to deposit ____ than low-Dk silicone acrylate contact lenses.**
 - Lipid.
 - Protein.
 - Sodium.
 - Potassium.
- Mucin balls are associated with which type of contact lens?**
 - Low-modulus silicone hydrogels.
 - High-modulus silicone hydrogels.
 - Low-modulus hydrogels.
 - High-modulus hydrogels.
- The FDA classifies a high-water, ionic hydrogel contact lens material as:**
 - Group I.
 - Group II.
 - Group III.
 - Group IV.
- In a recent survey administered by the Centers for Disease Control and Prevention, what proportion of lens wearers acknowledged at least one behavior that places them at risk for a contact lens-related adverse event?**
 - One out of seven.
 - Two out of seven.
 - Four out of seven.
 - Six out of seven.
- Which of the following describes distinct, localized elevations on the anterior surface of the soft contact lens that are composed of calcium, lipid and mucoprotein?**
 - Fungus.
 - Lens calculi.
 - Lysozyme.
 - Acanthamoeba.

Examination Answer Sheet

The How and Why of Contact Lens Deposits

Valid for credit through May 15, 2023

Online: You can take this exam online at www.revieweducationgroup.com. Upon passing the exam, you can view the results immediately and download a real-time CE certificate. You can view your test history any time on the website.

Directions: Select one answer for each question in the exam and completely darken the appropriate circle. A minimum score of 70% is required to earn credit.

Mail to: Jobson Healthcare Information, LLC, Attn.: CE Processing, 395 Hudson Street, 3rd Floor New York, New York 10014

Payment: Remit \$35 with this exam. Make check payable to Jobson Healthcare Information, LLC.

Credit: This course is COPE approved for 2 hours of CE credit. Course ID is **67922-CL**.

Jointly provided by Postgraduate Institute for Medicine and Review Education Group.

Salus University has sponsored the review and approval of this activity.

Processing: There is a four-week processing time for this exam.

Answers to CE exam:

1. A B C D
2. A B C D
3. A B C D
4. A B C D
5. A B C D
6. A B C D
7. A B C D
8. A B C D
9. A B C D
10. A B C D
11. A B C D
12. A B C D
13. A B C D
14. A B C D
15. A B C D
16. A B C D
17. A B C D
18. A B C D
19. A B C D
20. A B C D

Post-activity evaluation questions:

Rate how well the activity supported your achievement of these learning objectives:

1=Poor, 2=Fair, 3=Neutral, 4=Good, 5=Excellent

21. Discuss the underlying mechanisms of contact lens deposits. ① ② ③ ④ ⑤
22. Identify contact lens deposits in their patients. ① ② ③ ④ ⑤
23. Recommend changes to reduce deposits in their contact lens wearers. ① ② ③ ④ ⑤
24. Factor in lens material choices to improve comfort and vision. ① ② ③ ④ ⑤
25. Describe how lens care options and surface treatments impact deposition. ① ② ③ ④ ⑤
26. Based upon your participation in this activity, do you intend to change your practice behavior?
(choose only one of the following options)
27. Thinking about how your participation in this activity will influence your patient care, how many of your patients are likely to benefit? (please use a number):

28. If you plan to change your practice behavior, what type of changes do you plan to implement? (check all that apply)

- a Apply latest guidelines b Change in pharmaceutical therapy c Choice of treatment/management approach
 d Change in current practice for referral e Change in non-pharmaceutical therapy
 f Change in differential diagnosis g Change in diagnostic testing h Other, please specify: _____

29. How confident are you that you will be able to make your intended changes?

- a Very confident b Somewhat confident c Unsure d Not confident

Please retain a copy for your records. Please print clearly.

First Name

Last Name

E-Mail

The following is your: Home Address Business Address

Business Name

Address

City State

ZIP

Telephone # - -

Fax # - -

By submitting this answer sheet, I certify that I have read the lesson in its entirety and completed the self-assessment exam personally based on the material presented. I have not obtained the answers to this exam by any fraudulent or improper means.

Signature _____ Date _____

Lesson 119563 | RO-RCCL-0520

30. Which of the following do you anticipate will be the primary barrier to implementing these changes?

- a Formulary restrictions
 b Time constraints
 c System constraints
 d Insurance/financial issues
 e Lack of interprofessional team support
 f Treatment related adverse events
 g Patient adherence/compliance
 h Other, please specify: _____

31. Additional comments on this course:

Rate the quality of the material provided:
1=Strongly disagree, 2=Somewhat disagree,
3=Neutral, 4=Somewhat agree, 5=Strongly agree

32. The content was evidence-based. ① ② ③ ④ ⑤
33. The content was balanced and free of bias. ① ② ③ ④ ⑤
34. The presentation was clear and effective. ① ② ③ ④ ⑤

When Lashes, Not Lenses, are the Problem

Demodex is common in patients with rosacea and can really throw a wrench in contact lens wear.

D*emodex* is a common yet often overlooked condition among our patients. Even though signs and symptoms may not be obvious under a slit lamp, they are sure to cause discomfort. This makes it even more imperative that we catch and treat these tiny mites as early as possible. The following case example will give you a good idea of how to go about this.

THE CASE

A 23-year-old female patient presented with complaints of contact lens intolerance for the past two years. The itching and discomfort she experiences worsen when she wears contact lenses, despite only using them for sport. She has tried many different contact lens brands and modalities but has found no success. Further exacerbating her symptoms is eye makeup, which she has stopped wearing altogether to avoid ocular irritation. She was diagnosed with dry eye, but warm compresses and artificial tears have not improved her signs and symptoms. She was also told she is not a good candidate for LASIK surgery due to her reduced corneal thickness and unique lens prescription.

The patient's presenting visual acuity was 20/20 OU with her spectacles, which had a prescription of -8.00D OD and -9.00D OS. She wore Acuvue Oasys 1-Day HydraLuxe lenses with a base curve of 8.50mm and a prescription of -7.00D OD and -8.00D OS. She was receiving topical treatment for facial

rosacea, which was mild and under control. Her ocular history was not significant, but she did report that she had taken oral doxycycline in the past.

Her pupils were reactive to light, with no relative afferent pupillary defects in either eye, and extraocular movements were full OU. Slit lamp examination revealed clear corneas OU, a clear palpebral conjunctiva with no papillae OU and a deep and quiet anterior chamber OU.

Examination of the lid margin revealed telangiectasia OU and cylindrical collarettes with lashes that pouted at the base (*Figure 1*). The patient's meibomian glands expressed clear oil. Her non-contact tear breakup time was five seconds OD and four seconds OS, keratometry readings were 45.00/46.00@045 OD and 44.00/44.50@150 OS and intraocular pressures were 10mm Hg OD and 11mm Hg OS. Undilated posterior segment evaluation revealed a normal fundus OU.

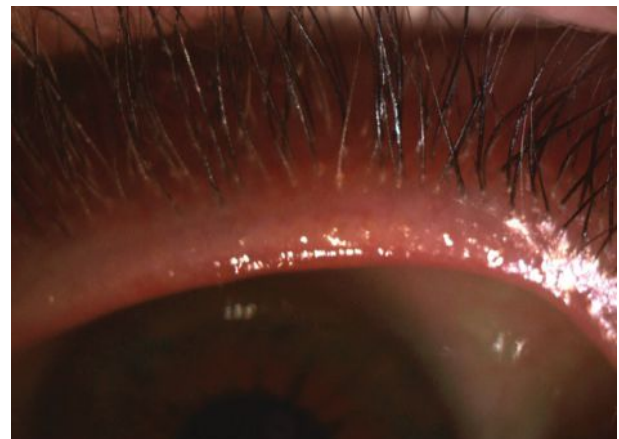
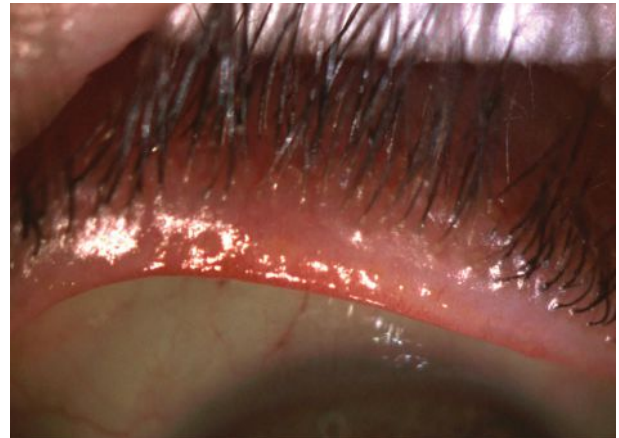


Fig. 1. Lid margin examination revealed lashes that pouted at the base (OD on the top).

THE VERDICT

The patient's soft contact lenses fit well and centered with good movement. While the lid margin initially appeared relatively clear and clean, the lashes pouted at the base. That, along with the fact that the patient had a history of facial rosacea, made me suspicious of possible *Demodex* burrowed in her lash follicles.

I temporarily suspended contact lens wear and put the patient on a regimen that would treat her ocular rosacea and



Demodex—twice daily Oust *Demodex* cleanser (OcuSoft) and Avenova spray (NovaBay). I asked her to avoid common triggers of rosacea, including sun, dairy, alcohol and caffeine, and to continue application of warm compresses daily for 10 minutes with a plug-in eye mask. I advised her to discontinue makeup use indefinitely. If she made the decision to wear it, I recommended she purchase products with clean ingredients and no irritants and ensure complete removal after each use.

FOLLOW-UPS

The patient came back one week later stating her itching had slightly improved but was still present. Upon examining the anterior segment, I found clear and clean lashes, but the lash base was still pouted (*Figure 2*). I performed in-office BlephEx on both eyelids with tea tree oil and asked the patient to continue lid cleansing with the same regimen.

She returned after another week had passed with improved symptoms. Slit lamp examination revealed clear lids and lashes. I gave her permission to resume contact lens wear and asked her to follow up in a week.

The patient was now able to wear her lenses for eight hours at a time, which was a significant improvement from her previous experience. I suggested she increase lubrication with preservative-free artificial tears, and we discussed scleral lenses and more aggressive treatment of her rosacea, such as oral antibiotics

or intense pulsed light therapy, if her condition worsened. The patient was happy with her current situation, and the fit was finalized.

DISCUSSION

Demodex is a common condition in patients who also have rosacea.¹ The skin inflammation associated with rosacea makes these patients more prone to blepharitis, the bacteria of which *Demodex* like to feed on. Even when the blepharitis seems to be under control, the mites can embed in the lash follicle and cause discomfort.

Rosacea is more common in women and light-skinned patients but can be underdiagnosed in those who have darker skin. Patients with rosacea are typically more sensitive to facial products since the blood vessels lay close to the top layer of skin.² They should avoid food triggers and use hypoallergenic products and sunscreen to protect them from ultraviolet light.³

Tea tree oil lid washes are a form of preventative therapy

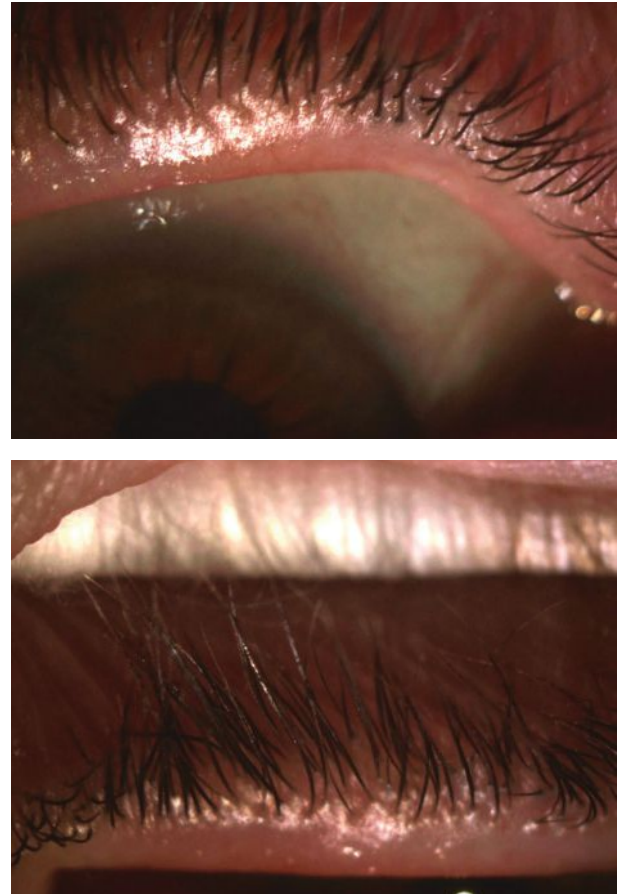


Fig. 2. After discontinuing contact lens wear for a week, the patient's lashes were still pouted (OD on the top).

for patients with rosacea. Inform patients that long-term treatment is usually required to control the effects of rosacea—a chronic condition that requires daily maintenance to manage its symptoms. **BCCL**

1. Gonzalez-Hinojosa D, Jaime-Villalonga A, Aguilar-Montest G, et al. Demodex and rosacea: is there a relationship? *Indian J Ophthalmol.* 2018;66(1):36-8.
2. Knox C. Rosacea: a review of a common disorder. *The Internet Journal of Academic Physician Assistants.* 2006;4(2).
3. National Rosacea Society. www.rosacea.org. Accessed April 10, 2020.

Embrace the Oddballs

Better serving your more difficult cases will prove to be highly beneficial.



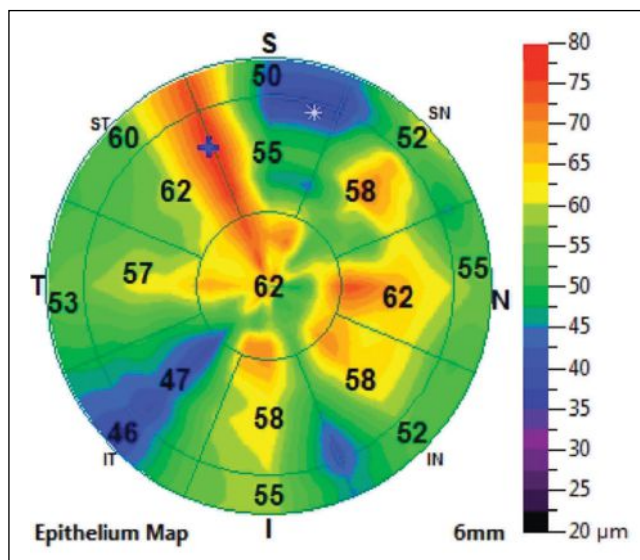
ftentimes, your most loyal patients are

those who believe that you would go above and beyond to meet their visual needs appropriately while still allowing them to wear contact lenses. In turn, they're more than willing to refer others to you without a second thought or any type of incentive.

We can take patient satisfaction a step further when handling particularly challenging cases that require specialty care and advanced knowledge. Here, we discuss several examples of oddball ocular surface issues among contact lens wearers and how to appropriately address them to optimize the patient experience.

POST-REFRACTIVE SURGERY

These corneas typically have a lower sagittal depth than normal because the central cornea is thinned and flattened during the refractive procedure, whether it be photorefractive keratectomy, laser-assisted *in situ* keratomileusis or laser-assisted epithelial keratomileusis. Although radial keratotomy doesn't thin the cornea, it does alter its architecture. As such, if suboptimal refractive results occur with any refractive procedure, resulting in an irregular corneal surface, it becomes very difficult to fit these



Irregular thickness secondary to a corneal injury can cause an irregular surface.

patients with standard soft contact lenses. These lenses often vault over the surgically altered cornea, leading to vision that is clear shortly after blinking but becomes blurrier as the eye remains open.

Post-refractive surgery patients require contact lenses with a lower sagittal depth to mitigate the vaulting. This is difficult to achieve with standard soft contact lenses, but other options are available for these types of corneas. Reverse-geometry gas permeable (GP) lenses provide a flat central curve that transitions to a steeper peripheral curve joined by a reverse curve. Hybrid and scleral lenses can also optimize vision for these surgically altered corneas. When fitting scleral lenses, be cognizant of the need to establish appropriate clearances over post-refractive corneas, as these patients tend to have excessive central corneal clearance.

PROGRESSIVE KERATOCONUS

This clinical condition can range in severity. Early on, mild corneal thinning causes a protrusion of the cornea in the area of thinning. As the condition progresses, further thinning and steepening of the cornea occur, increasing the sagittal depth of the cornea and creating irregular astigmatism. Keratoconic eyes have a hard time succeeding with standard soft contact lenses.

Earlier on in the condition, the irregular astigmatism may be correctable with a standard soft toric contact lens. However, as the condition progresses, you can prescribe specialty soft contact lenses, such as KeraSoft (UltraVision) and Novakone (Bausch + Lomb). GP and standard hybrid lenses are also options. As corneal steepening begins to take place, it's likely that you'll need to turn to specialty hybrid lenses, including UltraHealth (SynergEyes), and scleral lenses to correct for the irregular cornea. Discuss corneal crosslinking with progressive keratoconus patients when necessary.

IRREGULAR OR SCARRED CORNEA

Injuries and infections can cause permanent architectural changes to the cornea that may affect the cornea's shape and



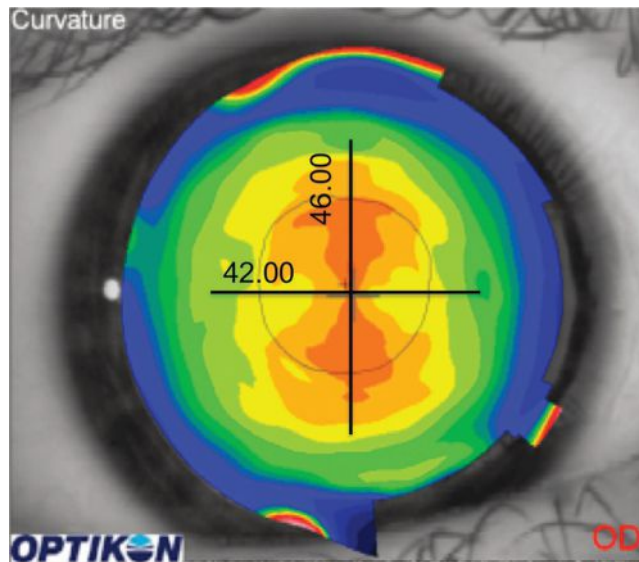
clarity. They can also permanently alter the corneal epithelial thickness, creating additional abnormalities to the ocular surface. Depending on the level of irregularity present, a high-modulus silicone hydrogel lens may mask these abnormalities. GP, hybrid and scleral lenses are also all options.

HIGH ASTIGMATISM

Moderate corneal astigmatism can be adequately corrected with soft toric lenses.

The technology, contemporary design and wide range of disposable options provide a reliable, predictable fit. As corneal astigmatism increases and becomes the main refractive error causing visual disturbance, however, it becomes increasingly difficult to correct with soft toric lenses. Smaller rotations of soft toric lenses create greater changes with higher amounts of astigmatism, oftentimes compromising it. This is where GP designs come into play and provide superior vision.

A tear lens is created between the posterior surface of a GP lens and the cornea to correct the corneal astigmatism. If the astigmatism is centrally located, high amounts may be correctable with a standard spherical lens. If the corneal astigmatism extends closer to the limbus, the lens is at greater risk of flexure, which ultimately compromises the



Centrally located astigmatism can often be fit with a spherical GP lens.

patient's vision by correcting less of the corneal astigmatism. By fitting the cornea with a back-toric GP lens, the lens toricity is designed to match the corneal toricity, mitigating lens flexure and optimizing vision.

Of course, don't forget about the option of scleral contact lenses, which are typically made at a thickness of between 300µm to 400µm centrally to provide a surface that resists flexure. This creates a predictable tear lens for patients with regular astigmatism. Those patients whose corneal astigmatism is similar to their refractive astigmatism tend to see very well with scleral lenses. Keep in mind that regular astigmatism can extend onto the sclera as well, so make sure to appropriately align the landing zone of the lens with the scleral shape by designing the lens with the appropriate toricity.

IRREGULAR SCLERAL SHAPE

A decade ago, discussion about the importance of the shape of the sclera was just starting to emerge. We used to be limited to scleral lenses with a spherical landing zone that caused unintended consequences, such as discomfort, more lens awareness in certain regions where the lens lifted away from the sclera, impingement in areas where the landing zone was steeper than the scleral profile and post-lens tear clouding

throughout the day.

It is critical to understand the relationship between the landing zone of the lens and the often irregular scleral shape. There are technologies that guide clinicians in measuring the scleral profile and producing the appropriate landing zone on the lens. Many scleral lens diagnostic sets now come with a standard toric landing zone. This provides the practitioner with the added advantage of an adequate starting point that may require only minor modifications to optimize the landing zone.

Oddball ocular surfaces present unique challenges to clinicians as they work to restore appropriate vision. Keep these examples and fitting strategies in mind when managing tricky cases. Your patients and your practice are sure to benefit. [RCLL](#)



Vessels Sound the Alarm

These painful eyes need steroids—and immunosuppressives when they fall short.

A 51-year-old white female presented after a week of right eye tenderness, especially upon eye movement. The nasal quadrant appeared hyperemic and slightly edematous and did not fully blanch with 2.5% phenylephrine. Her intraocular exam was unremarkable. She was diagnosed with mild scleritis and conservatively started on 800mg ibuprofen and topical 1% prednisolone acetate four times a day.

Scleritis is an inflammatory process that involves dilation of the superficial and deep episcleral vessels, resulting in a bluish-red hue and the sclera becoming edematous and painful. The patient may complain of tearing, blurred vision and photophobia.

Scleritis is classified in several

ways: anterior or posterior, nodular or diffuse, necrotizing or non-necrotizing, and infectious or non-infectious.

Anterior, non-necrotizing, non-infectious scleritis is the most common form. In the nodular version, there is visible elevation with engorged scleral vessels. Vision is rarely affected, unless there is concurrent involvement of the cornea or uveal tract. Infection is responsible for about 5% to 10% of cases of anterior scleritis and is typically associated with trauma (89%) or surgery.^{1,2} Visual prognosis is guarded with infectious scleritis.

Systemic diseases associated with scleritis include rheumatoid arthritis (89% of scleritis), systemic lupus erythematosus, inflammatory bowel disease, sarcoidosis, polyarteritis

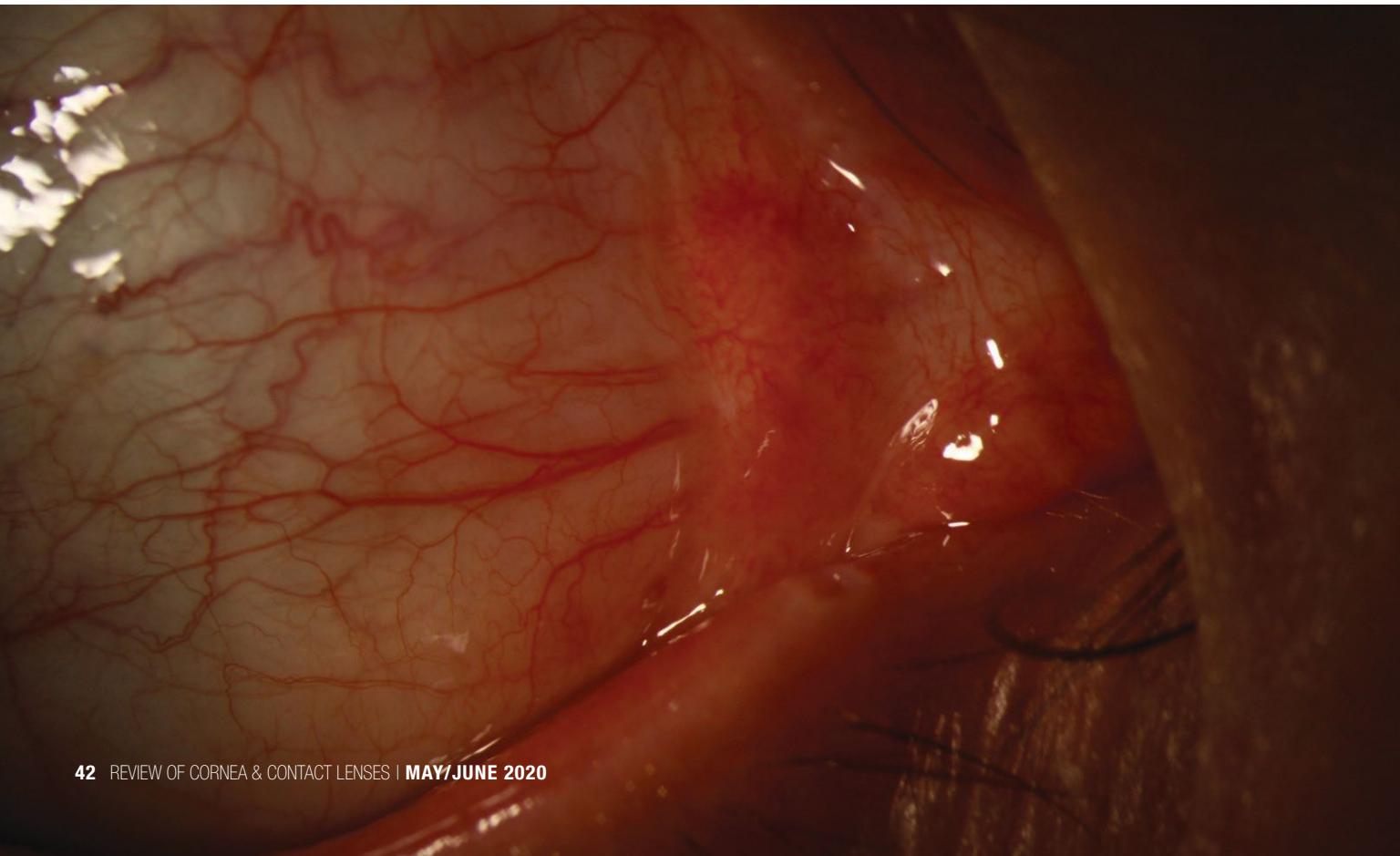
nodosa, the seronegative spondyloarthropathies and multiple forms of systemic vasculitis.³

The first-line therapy for non-infectious scleritis is oral NSAIDs and prednisone. Topical steroids are useful when there is coexisting intraocular inflammation or mild disease but typically fail if used without systemic medications. Steroid-sparing immunosuppressives, such as methotrexate, are started if the patient cannot be successfully tapered below 10mg of prednisone without symptoms or clinical signs of active scleritis. **RCCL**

1. Guerrero-Wooley RL, Peacock JE Jr. Infectious scleritis: what the ID clinician should know. *Open Forum Infect Dis.* 2018;5(6):ofy140.

2. Hodson KL, Galor A, Karp CL, et al. Epidemiology and visual outcomes in patients with infectious scleritis. *Cornea.* 2013;32(4):466-72.

3. Akpek EK, Thorne JE, Qazi FA, et al. Evaluation of patients with scleritis for systemic disease. *Ophthalmology.* 2004;111(3):501-6.





“ I didn't realize
STARS
were little dots that twinkled ”

—Misty L, *RPE65* gene therapy recipient

**WE'RE SEEING
AMAZING RESULTS.
AND SO ARE THEY.**

At the Foundation Fighting Blindness our mission is everybody's vision. Our work shines a light on the darkness of inherited retinal diseases (IRDs).

We're the world's leading organization searching for treatments and cures. We need your help to fuel the discovery of innovations that will illuminate the future for so many. We have robust disease information, a national network of local chapters and support groups, local educational events, and our My Retina Tracker® Registry to help keep your patients connected with clinical and research advancements.

Help accelerate our mission
by donating at ECPs4Cures.org.

**FOUNDATION
FIGHTING
BLINDNESS**

FightingBlindness.org

Earn up to
18-29 CE
Credits*

A Medscape **LIVE!** CONFERENCE

NEW TECHNOLOGIES
& TREATMENTS IN
2020 EYE CARE
REVIEW
EDUCATION GROUP



Join us for our
2020 MEETINGS



» **NEW DATE**

OCTOBER 30-NOVEMBER 1 - AUSTIN, TX

Omni Barton Creek

Program Chair: Paul M. Karpecki, OD, FAAO

REGISTER ONLINE: www.ReviewEdu.com/Austin2020



» **NEW DATE**

NOVEMBER 5-8 - PHILADELPHIA, PA

Philadelphia Marriott Downtown

Joint Meeting with OCCRS**

Review Program Chair: Paul M. Karpecki, OD, FAAO

OCCRS Program Chair: Tracy Schroeder Swartz, OD, MS, FAAO

REGISTER ONLINE: www.ReviewEdu.com/Philadelphia2020



» **NEW DATE**

DECEMBER 11-13 - ORLANDO, FL

Disney's Yacht & Beach Club

Program Chair: Paul M. Karpecki, OD, FAAO

REGISTER ONLINE: www.ReviewEdu.com/Orlando2020

For the latest information visit:

www.ReviewEdu.com/Events

e-mail: ReviewMeetings@MedscapeLIVE.com or call: 866-658-1772

Administered by:

REVIEW
EDUCATION GROUP



*Approval pending



SALUS UNIVERSITY
Pennsylvania College of Optometry



**17th Annual Education Symposium
Joint Meeting with NT&T in Eye Care

Review Education Group partners with Salus University for those ODs who are licensed in states that require university credit.
See www.reviewedu.com/events for any meeting schedule changes or updates.