

RCCL®

REVIEW OF CORNEA & CONTACT LENSES

PRESBYOPIA ISSUE

HOW TO GET AHEAD OF PRESBYOPIA, P. 14

MULTIFOCAL OPTICS EXPLORED, P. 18

BAUSCH + LOMB ULTRA® MULTIFOCAL FOR ASTIGMATISM

THEIR SUCCESS IS YOUR SUCCESS.

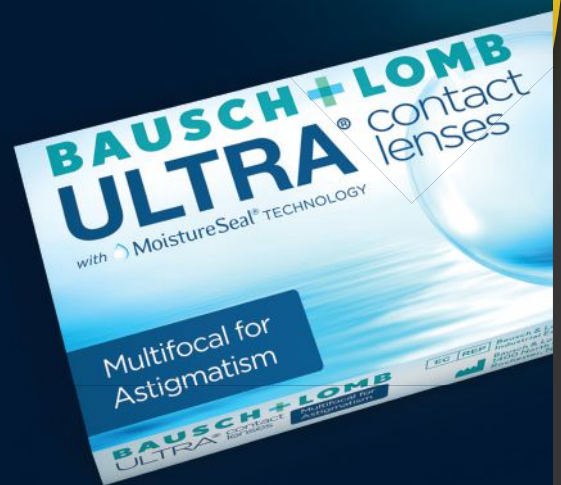The vision correction patients prefer is also the lens that's giving patients a more favorable impression of you.^{1,2}

87%

of patients prefer it over their previous contacts, readers, or eyeglasses.¹

91%

of patients had a more favorable impression of their eye care professional.²



Fit the lens that's fit for success.

REFERENCES: 1. Results of an online survey 435 patients who completed an evaluation program for Bausch + Lomb ULTRA® Multifocal for Astigmatism contact lenses. Survey results include 391 patients who indicated that they had a preference. 2. Results of an online survey 435 patients who completed an evaluation program for Bausch + Lomb ULTRA® Multifocal for Astigmatism contact lenses. Survey results include patients who strongly agreed, agreed, or slightly agreed (on a 6-point agreement scale) with a margin of error of +/- 2.7%.

®/™ are trademarks of Bausch & Lomb Incorporated or its affiliates. ©2020 Bausch & Lomb Incorporated or its affiliates. UMT.0043.USA.20

BAUSCH + LOMB
See better. Live better.



RCCL[®]

REVIEW OF CORNEA
& CONTACT LENSES

MARCH/APRIL 2020

PRESBYOPIA ISSUE

HOW TO GET AHEAD OF PRESBYOPIA, P. 14

MULTIFOCAL OPTICS EXPLORED, P. 18

Make
the Most of
MULTIFOCALS

*Inside: Expert advice on
optics, options, fitting
protocols and ideal
patients.*

WHEN PRESBYOPIA AND ASTIGMATISM COLLIDE, P. 24

PRESBYOPIA SURGERY: CURRENT & FUTURE TREATMENTS, P. 28

ALSO: REAL-WORLD LENS CARE PROBLEMS • PEDIATRIC GP FITTING • NEOPLASIA • EPITHELIAL INGROWTH

Biofinity® toric multifocal

AVAILABLE SPRING 2020



93% success rate
on initial fitting¹



Over 200,00 unique
prescription options²

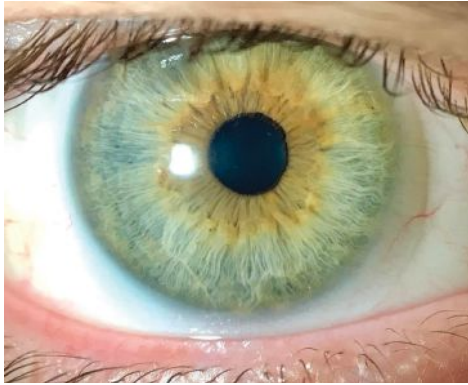
FROM SPHERE TO SPECIALTY
Only Biofinity®

 CooperVision®

1. CVI Data on file 2018. Non-dispensing, subject masked, randomized, bilateral, cross-over short-term clinical evaluation. 27 astigmatic, presbyopic soft CL wearers at 2 sites (UK & US) fitted using CVI fit guide.
2. CVI data on file 2019. Based on total number of prescription option combinations manufactured (for sphere, cylinder, axis and add – including D & N combinations). ©2020 CooperVision. 8947 01/20

contents

Review of Cornea & Contact Lenses | March/April 2020



departments

- 4 News Review**
OCT and keratic precipitates, NSAIDs, serum eye drops and LSCD, lasers and Fuchs'
- 8 My Perspective**
Coronavirus: Ready for the Questions
By Joseph P. Shovlin, OD
- 10 Practice Progress**
Presbyopia: Knowing is Half the Battle
By Mile Brujic, OD, and David Kading, OD
- 12 Fitting Challenges**
Little Eyes, Big Solutions
By Vivian P. Shibayama, OD, and Cory Collier, OD
- 38 The GP Experts**
Managing Presbyopia With Sclerals
By Lindsay Sicks, OD, and Thanhhan Andy Nguyen, OD
- 40 Corneal Consult**
When a Red Eye Prompts a Red Alert
By Aaron Bronner, OD, and Alison Bozung, OD
- 42 The Big Picture**
Early Adopter, Chronic Sufferer
By Christine W. Sindt, OD

features

14

How to Get Ahead of Presbyopia

Intervening earlier on is key in successfully working through this inevitable condition.

By Erin Rueff, OD, PhD

18

Multifocal Optics Explored

Recent research may give insight on how to better implement these lenses for presbyopic patients.

By Mark De Leon, Associate Editor

24

When Presbyopia and Astigmatism Collide

A multitude of contact lens options exist for the independent correction of astigmatism and presbyopia. Let's discuss the options when these occur simultaneously.

By Robert Ensley, OD, and Jessica Jose, OD

28

Presbyopia Treatment: Current and Future Options

Make sure you're in the know about long-term solutions for the condition.

By Larry Baitch, OD, PhD

34

5 Real-world Contact Lens Care Problems

Poor lens care and handling practices can lead to infections, drop-outs and even vision loss. Here's how you can help patients avoid them.

By Jane Cole, Contributing Editor

IN BRIEF

■ Researchers recently reported that **LASIK and photorefractive keratectomy are safe and effective in breastfeeding women**. After evaluating 237 eyes of 168 women who were breastfeeding during either procedure or stopped breastfeeding at least three months beforehand, the team found no significant intraoperative or postoperative complications. No significant differences were found between the groups in visual acuity, postoperative spherical equivalent, efficacy index, predictability, safety index or retreatment. They noted that no infants experienced adverse effects.

Alonso-Santander N, Ortega-Usoabiaga J, Beltrán-Sanz J, et al. Laser in situ keratomileusis and surface ablation in breastfeeding patients. *Cornea*. January 30, 2020. [Epub ahead of print].

■ A systematic review found **no evidence of statistically significant differences in IOP or safety between benzalkonium chloride (BAK)-preserved eye drops, preservative-free and alternatively preserved prostaglandin analog and beta-blockers**. IOP was 0.15mm Hg lower in the BAK group than in the other groups, but this difference was not statistically significant or clinically relevant. Meta-analyses also revealed no differences with regard to conjunctival hyperemia, ocular hyperemia, total ocular adverse events or tear break-up time. The review noted that tolerability of eye drops with or without preservatives was generally reported as good.

Hedengran A, Steensberg AT, Virgili G, et al. Efficacy and safety evaluation of benzalkonium chloride preserved eye-drops compared with alternatively preserved and preservative-free eye-drops in the treatment of glaucoma: a systematic review and meta-analysis. *Br J Ophthalmol*. February 12, 2020. [Epub ahead of print].

■ A study conducted in Shanghai has established that **accelerated transepithelial corneal crosslinking (ATE-CXL) can be safe and effective for up to 36 months** for pediatric patients with progressive keratoconus. The researchers examined 53 eyes of 41 pediatric patients with progressive patients who received ATE-CXL. After 36 months, corrected distance visual acuity (CDVA) improved from $0.32 \pm 0.28 \log \text{MAR}$ to $0.26 \pm 0.25 \log \text{MAR}$. The study found corneal pachymetry, central thickness and epithelial thicknesses remained stable throughout the three-year follow-up period.

Tian M, Jian W, Zhang X, et al. Three-year follow-up of accelerated transepithelial corneal cross-linking for progressive pediatric keratoconus. *Br J Ophthalmol*. February 12, 2020. [Epub ahead of print].

Keratic Precipitates Trouble for OCT

Researchers in Scotland recently looked at the potential diagnostic role of anterior segment OCT (AS-OCT) and realized clinicians should not use it to differentiate infective infiltrates from inflammatory keratic precipitates for patients presenting with postoperative inflammation.

Still, AS-OCT may be a good diagnostic and monitoring tool to assess response to treatment in cases where anterior segment inflammation of uncertain etiology is present, they noted. If AS-OCT only identifies endothelial deposits, clinicians should still suspect interface infection. The researchers could differentiate endothelial pigment deposits from keratic precipitates with smaller, poorly defined, hyporeflective deposits.

The case-based review included six patients with inflammatory keratic precipitates, one patient with infective interface keratitis following Descemet membrane endothelial keratoplasty and one patient with endothelial pigment. AS-OCT images in acute and active inflammation generally demonstrated hyperreflective keratic precipitant variants compared with other conditions with moderate or longstanding inflammation. The presence of hyperreflective precipitates on AS-OCT may help clinicians decide whether there may be active inflammation in the anterior chamber that requires treatment.

In the patient with infective interface keratitis, keratic precipitates were evident on the endothelial surface but no changes were identified at the graft-host interface. When patients first present with uveitis and keratic precipitates one week following surgery, AS-OCT did not demonstrate any morphological differences between the precipitates compared with the other non-infectious cases in this series. Therefore, the researchers noted that there were no significant differences between infective and inflammatory precipitates to help distinguish between the two.

The researchers noted that it could be possible that the presence of hyperreflective keratic precipitates on AS-OCT could be more suggestive of newly deposited precipitates and active inflammation as well as keratic precipitates of herpetic origin. This may be helpful if corneal edema or opacity otherwise prevents visualization of cells in the anterior chamber.

Shipton C, Hind J, Biagi J, Lyall D. Anterior segment optical coherence tomographic characterisation of keratic precipitates. *Cont Lens Anterior Eye*. January 13, 2020. [Epub ahead of print].

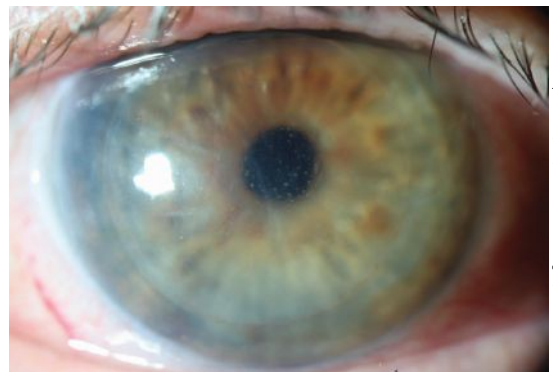

Photo: Christopher Kuc, OD, and Richard Manning, OD

New data suggest AS-OCT might not be a good option to image this patient's keratic precipitates due to DSAEK rejection.

The Role of NSAIDs Clarified

Two studies now clarify the benefits of topical non-steroidal anti-inflammatory drugs (NSAIDs) for patients undergoing an ocular procedure.

PRE-INJECTION: A PLUS

Patients heading in for an intravitreal injection may cope with the post-procedure pain better after administration of a pre-emptive topical NSAID, a new study suggests. Researchers found that administering NSAIDs pre-procedure—specifically, topical nepafenac—was associated with the greatest improvement in pain.¹

The study evaluated 598 eyes from nine randomized controlled trials that treated patients with a topical NSAID and analyzed post-procedure pain. The team assessed pain on the zero- to 10-point Visual Analog Scale and categorized the data into post-procedure time points of less than one hour, six hours and more than 24 hours.¹

The investigators observed a

low-to-medium risk of bias across the included trials. The mean pain score was significantly lower following topical NSAID administration relative to controls at every time point, adding that administering NSAIDs before vs. after intravitreal injection, as well as topical nepafenac relative to ketorolac or diclofenac, had a greater effect.

“Given the lack of diversity of studies and associated sample size, our findings should be regarded as hypothesis-generating,” the study authors concluded.

POST-OP: NOT SO MUCH

Following cataract surgery, patients are often prescribed a cocktail of eye drops to help them recover. These can include antibiotics, NSAIDs and steroids. But new research is showing that, in most cases, NSAID drops don't really do much for the patient. According to a study out of the Helsinki University Hospital in Finland, combining steroids and NSAIDs gets the same results as steroids alone and, in a head-to-

head match-up, steroids alone have a lower rate of posterior capsule opacification than NSAIDs alone.²

The researchers took a retrospective look at 13,368 uncomplicated cataract cases who presented to the hospital between 2014 and 2018. Some were treated with steroids alone (28.9% of cases), while others were treated with NSAIDs alone (62.2%) and 8.9% were treated with a combination of both. Treatment with steroids resulted in significantly lower Nd:YAG capsulotomy rates compared with NSAIDs alone, the research shows. Additionally, the combination therapy method showed no added benefits over steroids alone.²

The patients had a mean age of 73.2±9.7 years and 61.7% were female. Their mean follow-up time was 22.8±15.7 months.²

1. Popovic MM, Muni RH, Nichani P, et al. Topical non-steroidal anti-inflammatory drugs for pain from intravitreal injections: a meta-analysis. *Ophthalmology*. February 13, 2020. [Epub ahead of print].

2. Hecht I, Karesvuo P, Achiron A, et al. Anti-inflammatory medication after cataract surgery and posterior capsular opacification. *A, J Ophthalmol*. February 14, 2020. [Epub ahead of print].

Serum Eye Drops Heal CL-induced LSCD

Autologous serum eye drops may be able to reverse severe contact-lens induced limbal stem cell deficiency (LSCD) and prevent the need for surgery, especially when the condition is treated early and aggressively, a team of Taiwan researchers suggest.

Their study enrolled 20 eyes of 14 patients with severe CL-induced LSCD. All eyes underwent the serum eye drop treatment for at least two weeks with a follow-up of approximately two months.

Aggressive treatment with the serum eye drops was successful in all eyes, with signs and symptoms of LSCD stabilizing within two weeks. Complete resolution occurred in 30% at the two-week mark, in 45% at four weeks and in 25% after eight weeks.

“There is a high prevalence of severe CL-induced LSCD among symptomatic patients that sought help because of painful eye and blurred vision in our case series,” the researchers wrote in their paper. “Therefore, it is essential that pa-

tients wearing CLs, particularly soft CLs, receive annual examinations with a high degree of suspicion for the condition.”

The investigators emphasized the importance of early identification and suggested an aggressive treatment of analogous serum eye drops for CL-induced ocular surface diseases in an attempt to reverse the limbal damage and prevent the need for further surgical intervention.

Yeah SI, Chu TW, Cheng HC, et al. The use of autologous serum to reverse severe contact lens-induced limbal stem cell deficiency. *Cornea*. January 24, 2020. [Epub ahead of print].

Laser: A Graft-less Fuchs' Treatment?

For patients with Fuchs' endothelial corneal dystrophy (FECD), an endothelial graft is often the best treatment path. While surgery is often successful, researchers are still on the hunt for a better solution.

Now, excimer laser ablation shows promise as an experimental approach to remove diseased tissue from the Descemet membranes of FECD patients, which could allow corneal

endothelial cells to migrate more easily to the wounded area and help in the healing process, a new study in *Acta Ophthalmologica* suggests.

In the investigation, Descemet membranes of FECD patients and the corneal endothelium of normal human corneas were ablated *ex vivo* using an excimer laser. The samples were then kept in a cell culture medium supplemented with 10µm of the rho-kinase inhibitor ripasudil.

The research team used light and electron scanning microscopy to discover that guttae and corneal endothelium could be ablated with the laser without total damage to the Descemet membrane or stroma, and nearly complete endothelial wound



Photo: Michal Leach, OD

Patients such as this one with classic endothelial changes due to FECD may one day have laser ablation as a treatment option.

closure was accomplished after 26 to 38 days in the treated corneas.

The study noted that imaging also showed a layer of flat endothelial cells after the procedure, and cellular markers of neurotransmitter activity could only be observed on the inner side of the Descemet membrane.

While the study pointed to the potential of excimer laser ablations as a graft-less FECD treatment option, they cited several methodological problems that need to be resolved in clinical trials, in addition to *in vivo* research.

The laser option could pose some advantages, including the avoidance of a corneal graft in combination with the creation of a wound that does not present bare stroma, a favorable stromal healing response and faster cell migration over an intact basement membrane. **RCCL**

Kassumeh S, Studnitz A, Priglinger SG, et al. Ex vivo excimer laser ablation of cornea guttata and ROCK inhibitor-aided endothelial recolonization of ablated central cornea. *Acta Ophthalmol.* February 3, 2020. [Epub ahead of print].

Advertiser Index

CooperVisionCover 2

Oculus Cover 4

Visioneering TechnologiesCover 3

VSP 22-23

19 Campus Blvd., Suite 101
Newtown Square, PA 19073
Telephone (610) 492-1000
Fax (610) 492-1049
Editorial inquiries: (610) 492-1006
Advertising inquiries: (610) 492-1011
Email: rccl@jobson.com

EDITORIAL STAFF

- EDITOR-IN-CHIEF**
Jack Persico jpersico@jobson.com
- MANAGING EDITOR**
Rebecca Hepp rhepp@jobson.com
- ASSOCIATE EDITOR**
Catherine Manthorp cmanthorp@jobson.com
- ASSOCIATE EDITOR**
Mark De Leon mdeleon@jobson.com
- CLINICAL EDITOR**
Joseph P. Shovlin, OD, jpshovlin@gmail.com
- ASSOCIATE CLINICAL EDITOR**
Christine W. Sindt, OD, christine-sindt@uiowa.edu
- EXECUTIVE EDITOR**
Arthur B. Epstein, OD, artepstein@artepstein.com
- CONSULTING EDITOR**
Milton M. Hom, OD, eyemage@mminternet.com
- ASSOCIATE ART DIRECTOR**
Jared Araujo jaraujo@jhihealth.com
- AD PRODUCTION MANAGER**
Farrah Aponte faponte@jobson.com

BUSINESS STAFF

- PUBLISHER**
James Henne jhenne@jobson.com
- REGIONAL SALES MANAGER**
Michele Barrett mbarrett@jobson.com
- REGIONAL SALES MANAGER**
Michael Hoster mhoster@jobson.com

EXECUTIVE STAFF

- CEO, INFORMATION SERVICES GROUP**
Marc Ferrara mferrara@jhihealth.com
- SENIOR VICE PRESIDENT, OPERATIONS**
Jeff Levitz jlevitz@jhihealth.com
- SENIOR VICE PRESIDENT, HUMAN RESOURCES**
Tammy Garcia tgarcia@jhihealth.com
- VICE PRESIDENT, CREATIVE SERVICES & PRODUCTION**
Monica Tettamanzi mtettamanzi@jhihealth.com
- VICE PRESIDENT, CIRCULATION**
Emelda Barea ebarea@jhihealth.com
- CORPORATE PRODUCTION MANAGER**
John Caggiano jcaggiano@jhihealth.com

EDITORIAL REVIEW BOARD

- Mark B. Abelson, MD
- James V. Aquavella, MD
- Edward S. Bennett, OD
- Aaron Bronner, OD
- Brian Chou, OD
- Kenneth Daniels, OD
- S. Barry Eiden, OD
- Desmond Fonn, Dip Optom, M Optom
- Gary Gerber, OD
- Robert M. Grohe, OD
- Susan Gromacki, OD
- Patricia Keech, OD
- Bruce Koffler, MD
- Pete Kollbaum, OD, PhD
- Jeffrey Charles Krohn, OD
- Kenneth A. Lebow, OD
- Jerry Legerton, OD
- Kelly Nichols, OD
- Robert Ryan, OD
- Jack Schaeffer, OD
- Charles B. Slonim, MD
- Kirk Smick, OD
- Mary Jo Stiegemeier, OD
- Loretta B. Szczotka, OD
- Michael A. Ward, FCLSA
- Barry M. Weiner, OD
- Barry Weissman, OD



Earn up to
29 CE
Credits*

A Medscape **LIVE!** CONFERENCE

New Technologies & Treatments in Eye Care & OCCRS:

AUSTIN, TX

April 16-19, 2020

A unique joint meeting combines *Review's* New Technologies & Treatments in Eye Care and the Optometric Cornea, Cataract, and Refractive Society (OCCRS) to provide up to 29* COPE CE credits in one weekend.

PROGRAM CHAIRS:



Paul M. Karpecki, OD, FAAO
Review Program Chair



Tracy Schroeder Swartz, OD, MS, FAAO
OCCRS President, Program Chair

LOCATION:

Omni Barton Creek
8212 Barton Club Drive
Austin, TX 78735
(512) 329-4000

Discounted room rate: \$275/night + taxes & fees.
Some resort fees may apply for additional amenities.

THREE WAYS TO REGISTER:

Online: www.ReviewEducationGroup.com/Austin2020

Call: 866-658-1772 or E-mail: ReviewMeetings@MedscapeLIVE.com

Opportunities to register for one or both meetings.

See website for detailed fees.



Review Education Group partners with Salus University for those ODs who are licensed in states that require university credit. See event website for complete details.



Coronavirus: Ready for the Questions

Following these preparative measures will help minimize risk and keep patients at ease.

Similar to the MERS (Mers-CoV) and SARS (Sars-CoV) insurgence and hysteria experienced in the past, the newest version of the coronavirus, COVID-19, has unfolded rapidly, receiving much attention. With all this attention, are you ready to respond to questions and, more importantly, do you know what do to with a patient who presents with signs and symptoms of this disease?

THE FACTS

The coronaviruses, novel pathogens, are a frequent cause of the common cold and other respiratory infections including pneumonia.^{1,2} Health officials in China reported this outbreak in Wuhan in December 2019. Apparently the coronaviruses are found in different species of animals and can evolve to infect and spread among humans.¹ As this is published, the Centers for Disease Control and Prevention (CDC) has so far confirmed 423 cases detected in the United States.² More, of course, are sure to be on the way as the virus spreads. Because of the uptick in the infected numbers in China, authorities there have imposed an unprecedented lockdown on travel, affecting more than a dozen cities in China (a combined population of at least 50 million).¹

Though there are many cases already reported, a lot of the infections are not as severe as influenza.³ The recovery period only generally lasts for just a few days, but the young, elderly and those who have a compromised immune state are the most vulnerable. They can surface in as few as two days and up to two weeks after exposure.¹⁻³

Symptoms range from fever, cough and shortness of breath to diarrhea and vomiting.^{2,4}

A recent alert from the American Academy of Ophthalmology suggests the virus can cause conjunctivitis and may be transmitted by aerosol contact to the ocular surface.⁴ The coronavirus spreads via respiratory droplets. Patients may be infectious to others prior to experiencing their own symptoms, although asymptomatic transmission has not been confirmed.⁴

You might just be the first provider to evaluate an infected person with a co-morbid conjunctivitis and respiratory infection.⁴ Review infection control practices for patients under investigation and obtain adequate travel or other exposure history including travel dates and cities visited in the past 14 days.⁵ Check your inventory for any needed office items such as masks, gloves, gowns, goggles and disinfectant.

SAFETY MEASURES

It's key for healthcare providers to immediately notify their state or local health department if they suspect COVID-19 infection. Public health officials can then decide whether patients should be admitted to airborne isolation or monitored at home with appropriate precautions.⁵

In the absence of a viable vaccine, the CDC recommends these tips to minimize exposure and risk to the virus.¹⁻⁴

- Avoid touching your eyes, nose and mouth with unwashed hands.
- Keep a distance from those who are sick, especially those who recently traveled internationally—to China in particular.

- Stay home when sick.
- Clean and disinfect exposed surfaces.

This infection can have implications for the cornea, and the Global Alliance of Eye Bank Associations (GAEBA) has consolidated responses related to ocular tissue donation for transplants and lamellar surgery. They advise precautionary measures. "Exclude or defer potential donors for ocular tissue who resided or traveled to mainland China (regardless of symptoms) or to other geographical areas designated as areas of active transmission by the CDC," the GAEBA says.⁶

Continue to monitor your state and local health department alerts for any viral activity in your area, be prepared for questions your patients might ask regarding the coronavirus. **nccl**

1. Greenhaigh T. What you should know about the coronavirus outbreak. Pulmonary Advisor. www.pulmonologyadvisor.com/home/topics/lung-infection/what-you-should-know-about-the-coronavirus-outbreak. January 30, 2020. Accessed February 6, 2020.

2. Centers for Diseases Control and Prevention. 2019 novel coronavirus: information for healthcare professionals. www.cdc.gov/coronavirus/2019-ncov/hcp/index.html. Accessed March 9, 2020.

3. Palus S. How worried should you be about the new coronavirus? (Update: still not time to panic). Slate. slate.com/technology/2020/01/coronavirus-outbreak-china-sars-worry-level.html. January 24, 2020. Accessed February 6, 2020.

4. American Academy of Ophthalmology. Alert: important coronavirus context for ophthalmologists. www.aao.org/headline/alert-important-coronavirus-context. January 28, 2020. Accessed February 19, 2020.

5. Pavia AT. Novel coronavirus (2019-nCoV): frequently asked questions for clinicians. Medscape Infectious Diseases. www.medscape.com/viewarticle/924555. January 30, 2020. Accessed February 6, 2020.

6. Global Alliance of Eye Bank Associations. Alert: coronavirus (COVID-2019) and ocular tissue donation. www.gaeba.org/2020/alert-coronavirus-2019-ncov-and-ocular-tissue-donation. February 3, 2020. Accessed February 19, 2020.

Earn up to
19 CE
Credits*

NEW TECHNOLOGIES
& TREATMENTS IN
2020
EYE CARE
REVIEW
EDUCATION GROUP

San Diego

May 29-31, 2020 - Manchester Grand Hyatt

A Medscape **LIVE!** CONFERENCE

EARN UP TO 19* CE CREDITS!

Join *Review's* New Technologies & Treatments in Eye Care in San Diego for three days of education detailing the latest ideas and innovations in eye care.

WHEN:

Friday, May 29, 2020 - Sunday, May 31, 2020

WHERE:

Manchester Grand Hyatt

1 Market Place, San Diego CA 92101

Discounted room rate: \$269/night† + tax and resort fee.

REGISTRATION COST: \$495 EARLY BIRD SPECIAL: \$420

TO REGISTER: www.ReviewEducationGroup.com/SanDiego2020

Call: 866-658-1772 or E-mail: ReviewMeetings@MedscapeLIVE.com

PROGRAM CHAIR:



Paul M. Karpecki, OD, FAAO

Director of Cornea,
Kentucky Eye Institute

Director of OSD,
Gaddie Eye Centers

**Register by April 6, 2020
for Early Bird Pricing**

REGISTER: WWW.REVIEWEDUCATIONGROUP.COM/SANDIEGO2020

Administered by:

REVIEW
EDUCATION GROUP

COSE

*Approval pending

SALUS
UNIVERSITY
Pennsylvania College of Optometry

Review Education Group partners with Salus University for those ODs who are licensed in states that require university credit. †Rooms limited. See website for additional details.

Presbyopia: Knowing is Half the Battle

Many of these patients require some type of refractive correction but aren't even aware of their contact lens options.

Presbyopia is a near-certainty for anyone who lives to reach the age at which the eye's natural accommodative ability begins to fail. By the time patients are 50 years old, nearly 100% require some type of refractive correction. There is no other condition we manage where the same holds true. Yet only a small percentage of these patients wear contact lenses. We have the opportunity to step in and satisfy this unmet need.

Ophthalmic lens and contact lens technologies present solutions for these patients. Unfortunately, many aren't aware that there are contact lens options available, as they may not have been given the chance to try them. In the near future, there will also be pharmaceutical options to treat the symptoms of presbyopia. It is critical that we help our patients understand all of their options so that we can improve their outcomes and our standard of care.

DAILY DISPOSABLES

Historically, daily disposable lenses have been somewhat limited in their parameter availability, making it difficult for some patients to successfully wear them. This should not overshadow their advantages, especially as there has been an expansion in power ranges. These lenses are worn and disposed of on a daily basis, so there is no interaction with cleaning and disinfecting solutions, and patients are guaranteed a clean, fresh lens wearing experience each

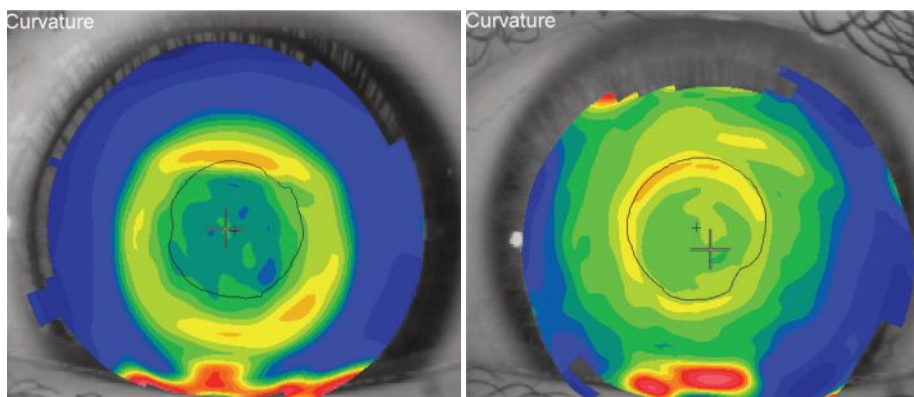


Fig. 1. Topography of a successful orthokeratology patient's cornea (left). Topography over the surface of a distance-centered multifocal contact lens (right).

day. Daily disposables are an ideal option for patients who stand to benefit from contact lenses and prefer part-time wear.

One complaint patients may have about daily disposable lenses is the amount of waste they produce. Fortunately, TerraCycle offers a program for patients to recycle lenses and packaging, and manufacturers like Bausch + Lomb have taken the initiative to encourage recycling.

SPECIALTY LENSES

There are currently no daily disposable options available to presbyopic patients who have astigmatic refractive error. Those interested in daily disposables are often limited to best-corrected distance vision in contact lenses and a combination of reading glasses and contact lenses to see at near. Monovision could help reduce the dependency for near glasses over contact lenses.

We have had access to specialty soft contact lens designs for decades. These lenses give patients with multifocal requirements who also need astigmatic refractive correction the

opportunity to wear contact lenses. The inherent challenge with these lenses is that they are custom made and come with a wait time for initial access and orders and reorders in the case of modifications.

Presbyopic lenses with astigmatic correction have experienced advances in recent years. There is now a monthly disposable silicone hydrogel lens Ultra Multifocal for Astigmatism (Bausch + Lomb) with toric and multifocal correction. The lens is made of samfilcon A and is 46% water. This lens is unique in that it is available in a diagnostic set to help you avoid much of the wait time in the ordering process.

OTHER OPTIONS

As a profession, optometry has become increasingly aware of line of sight and how it may affect a patient's visual performance in soft multifocal designs. This can be seen through the advancements the field has made. We now have a contemporary soft multifocal design and a scleral lens design we can customize to offset the optics nasally to corre-



spond with a patient's line of sight.

Gas permeable (GP) lenses are a viable option for presbyopes, even though they often are thought of as a secondary option for patients who may experience initial lens awareness. GPs provide optical clarity and are intuitively designed to provide distance vision correction in the center of the lens while progressing to the near powers toward more peripheral portions. Translation of the lens in downgaze allows patients to acquire more near power.

Hybrid lenses provide opportunities for presbyopes as well. These lenses have a GP center that is surrounded by a soft lens skirt. This makes initial lens awareness subtler, similarly to soft lenses, and offers comparable optical quality properties to standard GP lenses.

Although much of the conversation surrounding orthokeratology over the last several years has revolved around managing myopia, we certainly can't overlook our presbyopic patients as potential candidates who are looking for alternatives to glasses or traditional contact lenses. As such, myopic presbyopes are a logical group to consider with this lens technology. Because of the reverse curve in the lens design, the cornea has a prominent steep curve around the pupil. We could look at orthokeratology as having a similar effect as distance-centered, near periphery soft multifocal lenses (*Figure 1*). As presbyopia progresses, the appropriate next step would seem to be inducing monovision with the lens by under-correcting the level of myopia in the non-dominant eye.

Hyperopic-correcting ortho-K lenses are also now available. As

opposed to placing pressure on the central portion of the cornea, they put pressure on more peripheral portions of the cornea, steepening the central cornea and inducing myopic refractive correction. When done over the non-dominant eye, it can have a monovision effect, promoting better near vision.^{1,2}

PHARMACEUTICAL TREATMENTS

There are several pharmaceutical options on the horizon. It is critical that contact lens practitioners understand how to use these new technologies to supplement the contemporary contact lens practice.

In early presbyopes, this may replace the need for multifocal contact lenses, allowing patients to continue with single vision lenses while using drops. Depending on the efficacy of the drop, it may negate the need for multifocal technologies for more advanced presbyopes as well. Some may still need presbyopic refractive correction in addition to pharmaceutical assistance, although to a lower degree than what would be expected. This could be achieved with lower add-powered multifocals, which are beneficial because there is less of a discrepancy between the distance and near optics within the lens, maximizing the chances of a patient's success.

There are several presbyopic drops currently under development to be aware of. EV06 1.5% (UNR844-Cl) by Novartis is a lipoic acid choline ester that breaks disulfide bonds, which are thought to harden the lens over time.^{3,4} By disrupting these bonds, the lens becomes more elastic and regains

some functionality. PRX-100 by Presbyopia Therapies, CSF-1 by Orasis Pharmaceuticals and AGN-199201 and AGN-190584 by Allergan are miotic treatments that create a pinhole effect to allow for a greater depth of focus.⁵⁻⁸

Leveraging these technologies to enhance contact lens success will improve the presbyopic experience by giving patients more freedom from spectacle wear.

With current contact lens technologies and the promise of future therapies, we should have no problem helping presbyopic patients achieve clear vision and a comfortable lifestyle and fulfilling a need that has been neglected. **aca**

1. Williams BT. Orthokeratology for hyperopia and presbyopia. Contact Lens Spectrum. www.clspectrum.com/issues/2016/august-2016/orthokeratology-for-hyperopia-and-presbyopia. August 1, 2016. Accessed February 7, 2020.
2. Gifford P, Swarbrick HA. Refractive changes from hyperopic orthokeratology monovision in presbyopes. *Optom Vis Sci*. 2013;90(4):306-13.
3. Pending presbyopia treatments edge closer to disrupting the marketplace. Healio. www.healio.com/ophthalmology/cornea-external-disease/news/print/ocular-surgery-news/%7Ba40b0eb9-cddf-4908-b9bb-9911bef60bf1%7D/pending-presbyopia-treatments-edge-closer-to-disrupting-the-marketplace. March 25, 2019. Accessed February 7, 2020.
4. A study of safety and efficacy of UNR844 chloride (UNR844-Cl) eye drops in subjects with presbyopia. ClinicalTrials.gov. clinicaltrials.gov/ct2/show/NCT03809611. January 18, 2019. Accessed February 7, 2020.
5. Evaluation of the efficacy and safety of PRX-100 in the treatment of early to moderate presbyopia. ClinicalTrials.gov. clinicaltrials.gov/ct2/show/NCT02554396. September 18, 2015. Accessed February 7, 2020.
6. Safety, tolerability and efficacy of PresbiDrops (CSF-1) in presbyopia subjects. ClinicalTrials.gov. clinicaltrials.gov/ct2/show/NCT02965664. November 17, 2016. Accessed February 7, 2020.
7. Orasis Pharmaceuticals. www.orasis-pharma.com/. Accessed February 7, 2020.
8. A safety, efficacy and pharmacokinetic study of AGN-199201 and AGN-190584 in patients with presbyopia. ClinicalTrials.gov. clinicaltrials.gov/ct2/show/NCT02780115. May 23, 2016. Accessed February 7, 2020.

Little Eyes, Big Solutions

Pediatric specialty contact lenses make a world of difference in this younger patient population.

While specialty contact lenses in the infant and toddler populations present unique challenges to even the most adept fitters, they also offer incredible, life-changing potential. The value of mastering fitting techniques in these patients is indisputable. This case focuses on an infant with corneal scarring and traumatic aphakia, and provides rationale and fitting advice for pediatric specialty lens use.

THE CASE

A 13-month-old female was referred for a contact lens fitting by her cornea specialist. She had sustained a penetrating corneal injury in the right eye approximately three months earlier, resulting in central perforation and a traumatic cataract. At presentation, she was aphakic and had an elevated, 4.00mm linear scar extending across the central cornea from superior nasal to inferior temporal.

Retinoscopy resulted in +13.00D OD and +1.00D OS. The right eye displayed a high degree of scissoring and an overall dim reflex. The patient was resistant to occlusion of the left eye and became visibly agitated, started crying and was no longer cooperative with patching. Horizontal visible iris diameter (HVID) was 11.00mm.

The patient's parents quickly understood the visual benefits of contact lenses vs. spectacles for their infant daughter; however, they were concerned about the insertion and removal process and questioned her ability to adapt to lens wear. We explained that the younger the child, the easier the process and the faster the adaptation. As children move

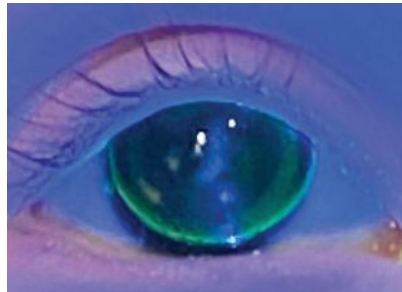


Fig. 1. Note the lack of NaFL centrally in this flat-fitting diagnostic lens.

out of infancy and into toddler age, contact lens fitting, parent-toddler interaction and contact lens adaptation usually become increasingly more difficult. At times, this may result in the inability to fit contact lenses until much later in adolescence. With this reassurance, the parents elected to proceed with a fitting.

DIAGNOSTIC FITTING

Due to the presence of both aphakia and corneal irregularity, a gas permeable (GP) lens was selected. As there were no reliable keratometry values to guide base curve selection, a diagnostic lens was prescribed based on diameter and estimated reasonable starting base curve radius (BCR). It was assumed that the central cornea was relatively steep from the retinoscopy value of +13.00D, lower than the +18.00D to +40.00D range typically expected in an infant with aphakia.¹ It was therefore assumed the patient had a steep central cornea offsetting, to some degree, the highly hyperopic correction anticipated in pediatric aphakia.


The diagnostic lens selected was +20.00D/6.92mm BCR/10.00mm overall diameter (OAD). A hand-held blue light was used to grossly assess the fit. This diagnostic lens

decentered superior and temporal, and displayed a lack of sodium fluorescein (NaFL) centrally (*Figure 1*). This lens was promptly removed and replaced with a steeper one. The parameters of the second lens were +18.50D/6.72mm BCR/10.00mm OAD. The lens was centered on the cornea and displayed a moderate density, green central NaFL pattern consistent with clearance of the central cornea without bubbles. Relative alignment was observed mid-peripherally with a thin line of NaFL at the edge signifying inadequate edge lift. Over-retinoscopy yielded -3.50D. The red reflex was noted as more regular with the GP lens in place.

As is typical in infant aphakia, a 2.50D to 3.00D myopic endpoint was designed to optimize the patient's visual development.² The periphery of the lens was flattened to increase edge lift. The following lens of Menicon Z material was ordered: +15.00D/6.72mm BCR/10.00mm OAD with an axial edge lift flattened from the standard 0.12mm to 0.16mm. In addition, plano polycarbonate over-spectacles were prescribed for full-time wear.

DISPENSING

The patient returned for a dispensing visit one week later. The lens was centrally located with mild central clearance without bubbles, mid-peripheral alignment and improved edge lift with a visible band approximately 1.00mm in width. Approximately 0.50mm to 1.00mm of lens movement was visible with blink and normal eye movement. Over-retinoscopy was approximated at -3.00D, consistent with the desired myopic endpoint. The parents were



instructed on proper lens care and trained on insertion and removal until they demonstrated proficiency. The lens was dispensed for daytime wear and permitted napping.

FOLLOW-UP

The patient returned one week later with her contact lens in place. The parents noted no dislocations with about 12 hours of daily wear. The patient was, for the first time since her injury, cooperative with patching. While patched, she was able to pick up and play with toys within arm's reach. Lens tolerance had increased rapidly over the first two to three days. At this point, the patient demonstrated no eye-rubbing, redness or excess tearing with the lens in place following a five- to 10-minute period of active distraction by her parents. The lens fit and ocular health were unchanged from the dispensing. Continued success and adaptation were noted at her subsequent follow-up one month later.

DISCUSSION

Three primary options exist for correcting ametropia in infants with contact lenses: corneal GP lenses, silicone elastomer lenses and custom soft lenses. While each lens option is feasible in infant management, GPs tend to be the preferred choice. Benefits include ease of handling, nearly unlimited physical and visual customization and a relatively low infection risk.³ In addition, for children with corneal scarring, these lenses provide optimal vision correction by masking anterior corneal irregularity.

We can explain the rationale behind our fitting patterns with the lifestyle, vision requirements and

anatomy of an infant. These patients are highly active, requiring a lens that provides excellent stability. Larger corneal lenses typically offer this through improved centration and decreased movement. These patients also nap daily. Using materials that allow adequate oxygen flow while napping is essential to minimize lens insertion and removal during the day.

Vision correction depends on the indication for lens wear. If the patient is phakic, full distance correction with an equalized stimulus for accommodation is the goal. If the patient is bilaterally or unilaterally aphakic, a 3.00D myopic refractive endpoint should be the target. This will place the child's far point near 33.00cm, allowing the child to develop vision and visual motor skills within their typical viewing and playing range. Polycarbonate over-spectacles are advised.

Infant eyes typically have steeper corneas and smaller HVIDs compared with adults.⁴ As a result, GPs with a relatively steep BCR are common in this patient population. Consistent with the fitting strategy used in the Infant Aphakia Treatment Study, I target the central curvature at approximately 1.00D to 1.50D steeper than the keratometry value, commonly siding on the smaller end of this spectrum due to my preference for larger corneal lenses.⁵

As keratometry is often not feasible or reliable in this age group, a bracketed fitting strategy is recommended. This entails using GPs to estimate the corneal curvature by identifying a BCR that displays touch over the central cornea and the next closest BCR that displays clearance. It can then be assumed that the corneal cur-

vature lies between the two points.

In this patient, a lens with a BCR of 6.92mm/48.75D displayed touch and a lens with a BCR of 6.72mm/50.25D displayed clearance. It can therefore be assumed the corneal curvature was between 48.75D and 50.25D. We ended up ordering the 50.25D BCR lens, as it displayed adequate centration and clearance and had no bubble formation.

Continuing with this example, if the 50.25D lens displayed excess clearance with bubble formation, the fitter would know to order a lens with a BCR with less than 50.25D but more than 48.75D. As noted previously, corneal lenses with a large diameter are commonly preferred due to their stability and centration. "Larger" in this situation is a relative term, as the diameter relies on the HVID. A reasonable starting point is 1.50mm to 1.00mm smaller than the HVID, commonly resulting in diameters ranging from 9.50mm to 11.00mm.

The importance of providing a clear image for visual development at a young age is inarguable. While there are several options for vision correction in infants and toddlers, none rival the versatility of corneal GP lenses. With nearly unlimited parameters and an excellent safety profile, this modality is the standard in pediatric contact lens fitting. **RCCL**

1. McQuaid K, Young TL. Rigid gas permeable contact lens changes in the aphakic infant. *CLAO J*. 1998;24(1):36-40.

2. Moore BD. Optometric management of congenital cataracts. *J Am Optom Assoc*. 1994;65(10):719-24.

3. Keay L, Edwards K, Naduvilath T, et al. Factors affecting the morbidity of contact lens-related microbial keratitis: a population study. *Invest Ophthalmol Vis Sci*. 2006;47(10):4302-8.

4. Borish IM. *Clinical Refraction*. 3rd ed. Chicago, IL: Professional Press; 1975: 61-74.

5. Lambert SR, Buckley EG, Drews-Botsch C, et al. The infant aphakia treatment study: design and clinical measures at enrollment. *Arch Ophthalmol*. 2010;128(1):21-7.

How to Get Ahead of PRESBYOPIA

Intervening earlier on is key in successfully working through this inevitable condition.

By Erin Rueff, OD, PhD

Presbyopia can seemingly happen overnight. One day, your 40-something patient can read the text on their phone screen, and the next, their arm is suddenly not long enough. In reality, presbyopia is a process that progresses as we move through adulthood. Contact lens wearers may experience subtle, early presbyopic symptoms before they reach their mid-40s, including eyestrain, fatigue with near work and headaches. Initiating presbyopic contact lens correction efforts earlier on can ease adaptation and prevent unnecessary contact lens dropout.

INITIATE MANAGEMENT

The discussion about presbyopic contact lens options typically starts when patients complain of near blur. It is important to remember, however, that near blur is not the only symptom associated with presbyopia, and it may not be the first symptom to present. Blurry near vision may not occur for most patients until their mid-40s, but symptoms associated with declining accommodative amplitude can begin as early as age 30. Be proactive and address presbyopic symptoms before complete near blur occurs.

Accommodative amplitude re-

mains relatively stable throughout childhood and into our mid-20s, when it starts to rapidly decline.¹ Between the ages of 30 and 40, accommodative amplitude can decrease by up to 3.00D.¹ This means that we lose almost half of our accommodative amplitude before even reaching an age many associate with presbyopia onset.

While patients approaching presbyopia may be able to visualize clear images, they may not be able to do so comfortably, especially after a long day of near or computer work. Symptoms associated with accommodative fatigue and insufficiency can contribute to symptoms of asthenopia and discomfort.² Myopic patients who wear glasses may be able to alleviate some of this accommodative fatigue by removing their glasses when doing near work. When corrected with contact lenses, however, these myopes cannot escape their waning accommodation and may mistakenly assume discomfort associated with accommodative fatigue is related to their contact lenses.

Recognize that presbyopic accommodative decline happens before a patient experiences sustained near blur. You can uncover other signs by asking those in their 30s and early 40s about


specific symptoms of discomfort resulting from near and computer work. “Discomfort” can describe symptoms that stem from different etiologies. While symptoms of discomfort such as dryness, itchiness and burning can be caused by an ocular surface or fit issue, symptoms such as eyestrain, headaches and blurry/variable vision are likely associated with discomfort related to presbyopic accommodative fatigue and insufficiency.^{2,3}

PERFORM REFRACTION

The first step to ensuring your emerging presbyope is optimally corrected in their contact lenses is to confirm that their lenses reflect your refraction, which you’ve confirmed is accurate. To do this, focus on accurate myopic and full astigmatic correction.

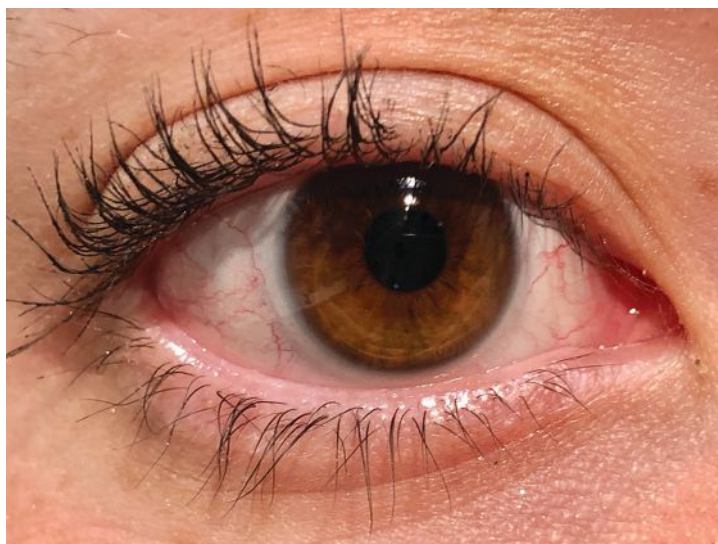As our accommodative amplitude is robust from childhood

ABOUT THE AUTHOR



Dr. Rueff is an assistant professor and the chief of the cornea and contact lens service at the Southern California College of Optometry at Marshall B. Ketchum University. She graduated from the Ohio State University College of Optometry where she completed a fellowship in cornea and contact lenses and PhD in vision science. She is a fellow of the American Academy of Optometry.

until early adulthood, myopic patients who prefer “smaller, darker” distance vision (i.e., overcorrected myopia) can overcome the increased accommodative demand that “over-minusing” causes. As these patients enter their 30s, that extra accommodative demand, however, can exacerbate symptoms related to their natural decline in accommodation.



Recommend multifocal contact lenses early for easier adaptation.

Make sure the manifest refraction doesn't include any myopic power that these patients do not actually need to achieve acceptable distance vision. Also ensure you have appropriately vertexed the manifest refraction on which you are basing your contact lens power. Accounting and correcting for even small amounts (0.25D to 0.50D) of myopic overcorrection can alleviate discomfort associated with near work.

With glasses, we almost always prescribe exactly what we find in our phoropter. Rarely do we round up to the major meridian or totally disregard cylinder power. Unfortunately, with contact lenses, we commonly ignore small amounts of astigmatism if the patient is “fine” in a spherical lens. About half of all contact lens wearers have at least 0.75D of astigmatism, but we only prescribe toric contact lenses for about 25%.⁴

Uncorrected astigmatism can contribute to overall and visual discomfort.³ Studies have shown that, even in cases of low astigmatism, visual acuity and performance in low light/glare conditions improve with toric contact lens

correction compared with spherical correction.^{5,6} Patients tend to prefer having their astigmatism maximally corrected when wearing contact lenses, and full toric correction may alleviate symptoms associated with eyestrain and discomfort at near.⁷

Failing to correct astigmatism to the best of your ability could cause visual strain and result in a patient removing their contact lenses and relying on their spectacles that fully correct for astigmatism. Before even initiating presbyopic contact lens correction, ensure the patient's distance prescription, including spherical and astigmatic elements, is optimally corrected with their contact lenses. This alone may eliminate symptoms associated with declining accommodation for the next year or so or, at the very least, will optimally position you to choose how to proceed with presbyopic contact lens correction.

INTRODUCE MULTIFOCALS

When a patient consistently complains of early presbyopic symptoms, including difficulty concentrating, tiredness while reading and consistent headaches and

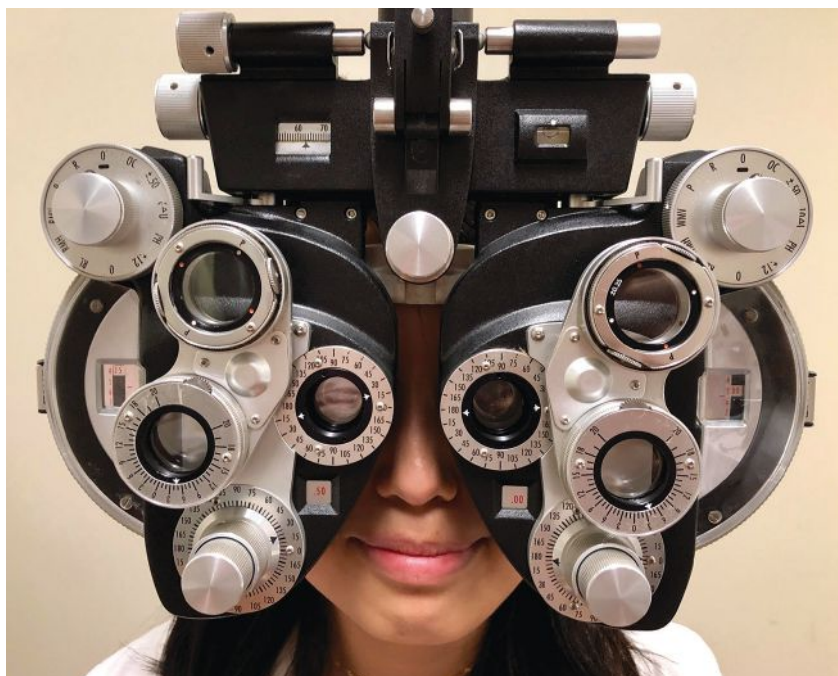
eyestrain, it's time to introduce a multifocal contact lens. Especially earlier on, a multifocal contact lens is the best option to alleviate symptoms of presbyopia while maintaining binocular vision at all distances.

Multifocal contact lenses are sometimes associated with a bad reputation and are consequently woefully under-prescribed in presbyopic contact lens wearers.⁸ The

simultaneous, aspheric optics used in today's modern multifocals sometimes compromise near, intermediate and/or distance vision. Patients may also experience glare in low light situations when pupil size increases. Prescribers assume these are deal breakers and tend to shy away from considering multifocals, suggesting an over-the-counter reading spectacle or turning to monovision contact lens correction.

Contact lens wearers, however, typically prefer multifocal contact lens correction to other presbyopic contact lens options when given the chance to try them. Compared with monovision, multifocal contact lenses consistently provide superior overall visual experiences and have similar acuities at all distances in high contrast conditions and superior stereoacuity.⁹⁻¹¹ Even though objective low contrast visual acuity is sometimes better with monovision, patients usually lean toward the vision and overall wearing experience multifocal contact lenses offer.^{9,11} When your patient begins having presbyopic symptoms, it's worth taking a look at multifocals.

HOW TO GET AHEAD OF PRESBYOPIA



Contact lens parameters must line up with your refraction for optimal correction.

SET EXPECTATIONS

Before beginning the multifocal fitting process, make sure your patient is educated, optimistic and confident so that compliance isn't an issue down the road. Successful multifocal contact lens fittings are achieved during patient education. If you take a few extra minutes during the initial fitting to explain why you are introducing a new contact lens, what the patient can expect during the adaptation period and how they will benefit from the change, your success rate will dramatically increase. It's also worth mentioning the consequences of improper wear and care practices in this stage.

Especially in early and emerging presbyopes, explaining presbyopia can be difficult. This age group may not know what presbyopia is or that they will inevitably experience it. Be concise when introducing the condition to patients who may have no prior knowledge or understanding of it and explaining

that as we get older, our eyes are unable to focus up close as effectively because we spend so much of our time looking at a screen and reading.

It also helps to use clear language when describing how vision correction lenses work, especially as the optics of these lenses are complex. Combining your description of the lenses with what patients can expect may be an effective way to do this. Note that because these lenses focus images from multiple distances on your eye at the same time with your brain deciding what image to pay attention to based on what you are looking at, it may take a few days to figure out how to find the sweet spot in your vision.

Patients benefit from reassurance that any preliminary issues they may experience are normal and will gradually subside with your help or with time. Displaying confidence in the lenses and communicating openly about them before

a patient experiences multifocal lenses for what could be the first time will make them more willing to work through any frustrations they have until they reach a more successful outcome.

OPTIMIZE THE FIT

In recent years, the parameters and modalities of soft multifocal contact lenses have expanded significantly. An increase in daily disposable options and myopic and hyperopic spherical powers and the emergence of soft toric multifocals means that there are solutions available for the majority of presbyopic patients. When possible, start with a daily disposable. The frequent replacement schedule associated with these lenses allows for the most consistent and comfortable experience. When a daily disposable is not an option, find another lens with an appropriate replacement schedule, and prescribe a solution that works best with that lens material.

Regardless of what lens you choose, make sure to follow the manufacturer's fitting guide for initial lens selection and troubleshooting. While suggestions included in these guides often seem like common sense, some recommended adjustments and starting points that have proven to be successful through extensive research may not be intuitive to you. Save yourself chair time and frustration by implementing these guides in your practice. Most fitting guides suggest initial lens powers based on add power. If your emerging presbyope does not require an add yet but is experiencing symptoms of accommodative fatigue, select a lens with the minimum add power the manufacturer advises.

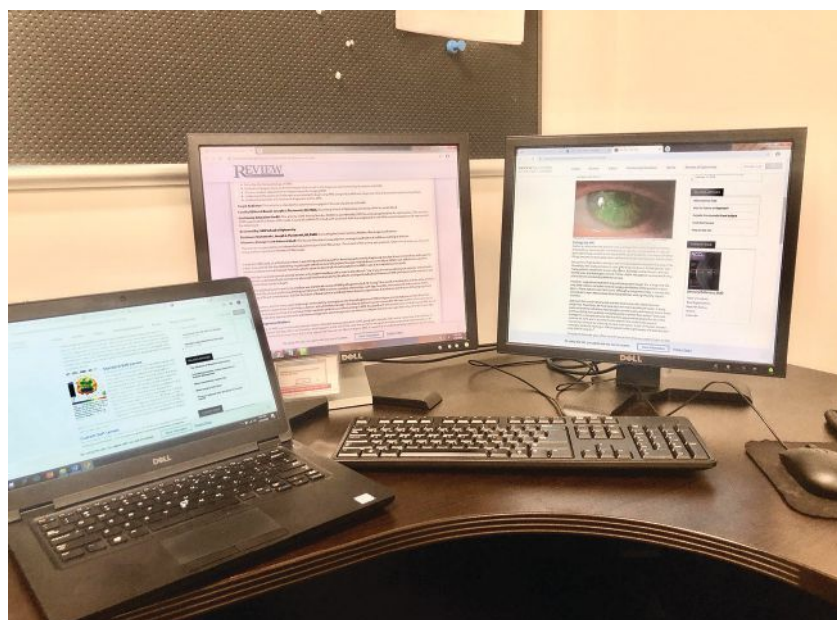
Assessing vision with a multifocal contact lens is different than taking entering acuities at the

beginning of your exam, especially on the first day. It is common for vision to improve with adaptation, so don't be discouraged if your patient can't see their best-corrected line right after you insert the multifocal. Make sure they know what to expect too; their first impression is important. Assess what they can see with the new lenses, and don't make what they cannot see the focus of the conversation. Remember, you want the patient to leave your office optimistic about the wearing experience they are about to embark on.

Evaluate vision binocularly and with normal room illumination. At distance, start with large, isolated lines, and go down in size as long as the patient is able to easily read each visual target. If you have good refractive data and began with the lenses suggested by the fitting guide, you should not need to make many, if any, changes on the initial fitting day.

The impressive moment with a multifocal comes when a presbyope is able to read small print without reading aids. You will not get this opportunity with an emerging presbyope who can still read small print clearly. Because you are introducing a new optical system, these patients may actually report that their vision feels different at all distances initially. In these instances, remind the patient that the purpose of the lenses is to alleviate symptoms of focusing fatigue. After the patient adapts to the lenses and wears them for a full day of work, reading or computer use, they will be able to fully appreciate them.

Once the patient is ready to leave your office on the first day, make sure they understand the importance of communicating any negative experiences they have after the initial adaption period, as



Use different resources to educate your patients and make sure you're always on the same page.

these can be addressed at follow up visits. This is when you can lean on the corresponding fitting guide for solutions to near and/or distance vision issues. If comfort isn't desirable and/or satisfaction cannot be reached after one or two lens swaps, consider switching brands.

Managing early presbyopic symptoms by keeping patients informed and prescribing multifocal contact lenses will prevent premature, unnecessary contact lens dropout. Transitioning presbyopes when the discrepancy between distance and near powers is the least problematic also helps ensure your patient experiences minimal negative symptoms and their visual system more easily adapts to future changes as you introduce greater add powers. Multifocal contact lenses are a great solution for patients who are entering a stage in their life when things are starting to become blurrier and they need an option to correct this unwanted change. **RCCL**

1. Anderson HA, Hentz G, Glasser A, et al. Minus lens-stimulated accommodative amplitude decreases sigmoidally with age: a study of objectively measured accommodative amplitudes from age 3. *Invest Ophthalmol Vis Sci.* 2008;49:2919-26.
2. Reindel W, Zhang L, Chinn J, et al. Evaluation of binocular function among pre- and early-presbyopes with asthenopia. *Clin Optom (Auckl).* 2018;10:1-8.
3. Sheedy JE, Hayes JN, Engle J. Is all asthenopia the same? *Optom Vis Sci.* 2003;80(11):732-9.
4. Morgan PB, Efron N, Woods CA. An international survey of toric contact lens prescribing. *Eye Contact Lens.* 2013;39(2):132-7.
5. Black AA, Wood JM, Colorado LH, et al. The impact of uncorrected astigmatism on night driving performance. *Ophthalmic Physiol Opt.* 2019;39(5):350-7.
6. Richdale K, Berntsen DA, Mack CJ, et al. Visual acuity with spherical and toric soft contact lenses in low- to moderate-astigmatic eyes. *Optom Vis Sci.* 2007;84(10):969-75.
7. Cox SM, Berntsen DA, Bickle KM, et al. Efficacy of toric contact lenses in fitting and patient-reported outcomes in contact lens wearers. *Eye Contact Lens.* 2018;44 Suppl 1:S296-9.
8. Morgan PB, Efron N, Woods CA. An international survey of contact lens prescribing for presbyopia. *Clin Exp Optom.* 2011;94(1):87-92.
9. Richdale K, Mitchell GL, Zadnik K. Comparison of multifocal and monovision soft contact lens corrections in patients with low-astigmatic presbyopia. *Optom Vis Sci.* 2006;83(5):266-73.
10. Situ P, Du Toit R, Fonn D, et al. Successful monovision contact lens wearers refitted with bifocal contact lenses. *Eye Contact Lens.* 2003;29(3):181-4.
11. Woods J, Woods CA, Fonn D. Early symptomatic presbyopes—what correction modality works best? *Eye Contact Lens.* 2009;35(5):221-6.

Multifocal Optics Explored

Recent research may give insight on how to better implement these lenses for presbyopic patients.

By Mark De Leon, Associate Editor

Patients with presbyopia who wish to wear contact lenses require a lens with more complex goals than a standard spherical lens—namely, to expand the depth of focus or allow the presbyope to see at more than one viewing distance—all with the highest image quality possible. Optics are a crucial aspect of a multifocal contact lens, as they inform how the lens is designed and impact patients differently depending on their anatomical conditions and visual scenarios.

Several recent studies highlight the ongoing development in multifocal contact lens research that may interest today's practitioners.

PUPIL SIZE

The changes that occur to the pupil as patients age can have lasting implications on their ability to focus at near, something multifocal lenses have to take into account. Pupil size generally decreases over the age of 50, and the retention of near vision pupil miosis in older eyes can further reduce pupil size for near-viewing conditions where

defocus is more likely.¹ The smaller pupils in older eyes effectively correct for the increased aberrations found in these eyes.¹ However, the decrease in photopic and mesopic pupil diameters in 65-year-old eyes fails to sufficiently expand the depth of field for observers, who typically require some optical correction to read at near.¹

Unfortunately, the same multifocal contact lens optics that help a patient address their decreasing pupil size can also cause other complications. In a recent study published in *Contact Lens & Anterior Eye*, researchers show that multifocal contact lenses can increase light distortion effects under low light conditions. In addition, the study found the size and shape of the pupil correlates with the size and shape of the distortion.²

The investigators looked at 14 eyes of seven contact lens patients. The light distortion index (LDI) was generally higher with multifocal lenses, varying from 3.7% with single vision lenses to 6.1% with the multifocal center-distance designs and the 5.0mm pupil. Patients with

larger pupils weighed in with even higher LDI values when wearing multifocal lenses, shifting from 4.5% (in 3.0mm pupils) to 6.1% (in 5.0mm pupils). The elliptical-shaped pupil produced the largest discrepancy in the distortion size between the vertical and horizontal directions. The team didn't note any difference between the center-distance and center-near designs.

Optical aberrations play a significant role in light disturbances, which are magnified with increasing pupil size. Thus, multifocal lenses with high amounts of spherical aberration (or distance defocus)—i.e., progressives with higher add powers—are more likely to generate significant light disturbances under low light conditions.

The authors concluded that, although no statistically significant differences were detected, multifocal contact lens wearers will find themselves in everyday situations that might compromise their visual performance due to greater light distortion effects, especially with larger pupils. A significant percentage of light distortion effects would be

produced by the presence of out-of-focus images given by a multifocal lens, rather than other optical phenomena.²

PINHOLE OPTICS

The need for multiple optical powers in one lens is often avoidable by employing pinhole optics, which will alleviate presbyopia symptoms through enhancing the depth of focus.¹ Many factors affect the selection of pinhole pupil size, but clinicians must strike a balance when improving defocused near vision without compromising focused distance vision.¹ Three parameters are key: pupil axial location, pupil size and whether to employ a fixed pupil or one that varies with light level.¹

As pupil size decreases, the role of diffraction blur in degrading image quality is amplified, but the impact of higher-order aberrations (HOAs) is reduced, which produces a peak image quality in a focused eye for pupil diameters between 2.0mm and 3.0mm.¹ At low photopic and mesopic light levels, reducing retinal illuminance lowers contrast sensitivity due to photon noise effects, and the combined effects of diffraction and reduction in retinal illuminance can significantly impair distance vision when pupil diameters are decreased below 2.5mm.¹

A study based in Seoul, South Korea, evaluated the efficacy and safety of a novel presbyopia-correcting pinhole soft contact lens. The Eyelike Pinhole II (Koryo Eyetech) includes an additional light-transmitting ring in the lens' mid-periphery. The researchers found that the lens improved distance-corrected near visual acuity (VA). The binocular-corrected distance VA was not affected by the pinhole contact lens.³

This prospective clinical study

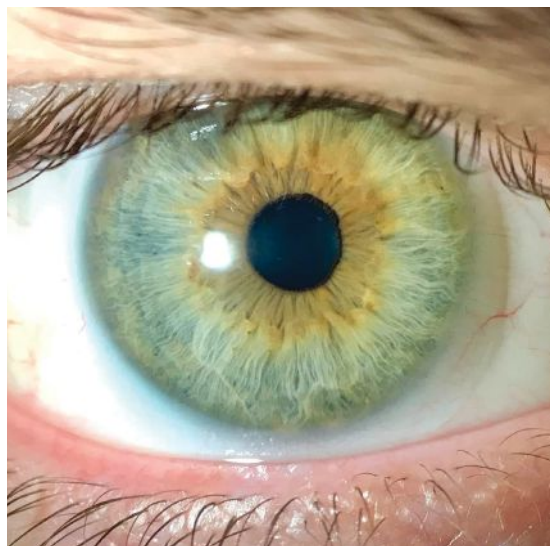


Photo: Alex Nikon, OD, MS and Erin Ruffel, OD, PhD

Making sense of multifocal optics can help you better fit presbyopes with the right lens.

enrolled 29 patients with presbyopia who wore the Eyelike Pinhole II for more than three hours per day for one week. The mean distance-corrected near VA of the treated eye and the mean binocular distance-corrected near VA improved after pinhole contact lens wear from $-5.00D$ to $-1.00D$. Although the mean corrected distance VA of the treated eye deteriorated, there was no significant change in the mean binocular corrected distance VA.

The researchers believe their findings suggest that the pinhole lens can allow the wearer to perform daily tasks such as reading books or newspapers, texting on mobile phones and working on the computer in a more convenient manner. VA values before lens wear did not significantly exceed those after lens wear in any case, which indicated that the lens didn't seem to worsen the vision quality.

The majority of participants were satisfied with the overall outcome, and 66% recommended the lens to others. Although the scores for visual symptoms and discomfort were lower than the work performance scores, the

overall satisfaction level was not affected. Participants were willing to tolerate slight discomfort if they could perform their tasks effectively.³

DESIGN AND ABERRATIONS

Radially symmetric or concentric multifocal lenses are the most common designs. The concentric multifocal design is rotationally insensitive and includes two or more powers contained in geometrically separate zones located at different distances from the lens center.¹ Designs that incorporate two powers

in alternating annular zones often also include significant regions of the lens in which there is a gradual power change with increasing radial distance.¹

When the outer zone of a two-zone concentric design is defocused, the defocused point-spread-function will be an annulus. In this case, the resulting annular halo will increase in size as the pupil dilates and be most visible when the stimulus contrast is highest, as it is when viewing lights at night—a common source of visual disturbance clinically reported with multifocal optics.¹

In addition to reducing the size of these haloes by reducing the add power (with either low add multifocal lenses or extended depth-of-focus lenses), an alternative strategy proposed is reducing the size of the defocused halo by coupling positive defocus with negative spherical aberration (including negative spherical aberration in the add zone) and vice versa. This produces a smaller but higher contrast halo.

Nevertheless, the naturally occurring changes in the refractive state across the pupil will add to (or subtract from) any multifocality pro-

MULTIFOCAL OPTICS EXPLORED

vided by a contact lens.¹ Therefore, the significant positive spherical aberration exhibited by older eyes and the corneas of pseudophakes may augment any center-distance multifocal that also contributes more positive power with increasing radial distance from the lens center, or positive spherical aberration.

Importantly, ocular spherical aberration may help or hinder the multifocal optics, depending on the type of design being fit and may likely contribute to the variable patient responses common during multifocal contact lens fits.¹ In the case of center-near designs that inherently contain negative spherical aberration, for example, ocular positive spherical aberration will subtract from the add power provided by the multifocal lens.¹

Achieving the desired level of multifocality in the corrected eye requires larger radially varying power changes in the correcting lens of a center-near design compared with a center-distance design. Although it could be simple to add the extra power needed for the center-near designs, high levels of spherical aberration in a contact lens will introduce more coma as the lens decenters.¹ Peak and overall image quality are ultimately affected more by lens decentration in the center-near design because of the higher levels of lens spherical aberration required to achieve multifocality.¹

POWER DYNAMICS

A study conducted by researchers at the Brien Holden Vision Institute assessed the effect of spherical aberration as a function of power by evaluating the optical power profiles of all the most commonly prescribed multifocal contact lenses across a wide range of prescription powers. The researchers found that power profiles can vary widely between the different lens types;

however, they also observed certain similarities between some of the center-near designs.⁴

“For the more recently released lens types, there seems to be a trend emerging to reduce the add amplitude, include negative spherical aberration, keep the power profiles consistent across the power range and offer lenses in at least three add powers and a daily disposable wearing mode,” the researchers wrote in their paper.⁴

The study measured power profiles of 38 types of multifocal contact lenses—in powers of +6.00D, +3.00D, +1.00D, -1.00D, -3.00D and -6.00D (three lenses each). The study identified three basic types of power profiles: center-near, center-distance, and concentric-zone ring-type designs. For most of the lens types, the relative plus with respect to prescription power was lower than the corresponding spectacle add. For some lens types, however, the measured power profiles were shifted by up to 1.00D across the power range relative to their labeled power.

In most lenses, the measured add amplitude was substantially lower than what would be required to provide the full reading compared with the corresponding recommended spectacle add power. Most of the lenses were designed with noticeable amounts of spherical aberration. The researchers noted that the sign and magnitude of spherical aberration can be either power-dependent or consistent across the power range.⁴

“When the first bi- and multifocal soft contact lenses appeared on the market, the lenses were labeled with their distance and add power,” the researchers noted. “In recent years, most of the newly released lenses only use descriptors like low, medium and high add power and make reference to the equivalent spectacle

Up the Power, Up the Success

Fitting multifocal contact lenses can be a time-consuming process, often requiring the trial of several different lens parameters before landing on a good fit for each patient. Knowing this is likely a barrier to the implementation of multifocal contact lenses in practice, researchers tried a modified fitting guide that added +0.25D binocularly to the spherical equivalent distance prescription. Preliminary results suggest the small change could have a big impact.^{1,2}

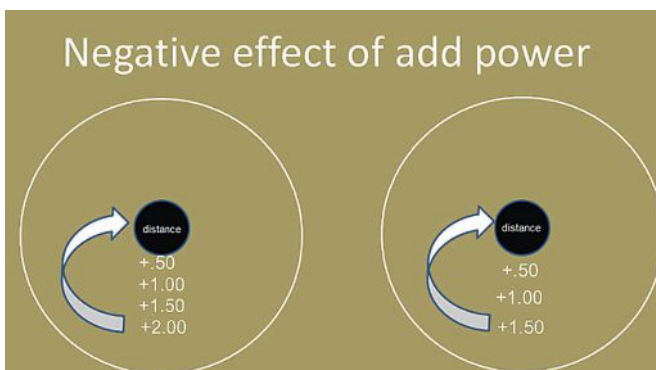
The researchers fit 183 presbyopic patients using either the traditional or modified fitting guides. The lenses all shared the same common optical design with either lotrafilcon B, nelfilcon A or delefilcon A materials. All participants were current soft contact lens wearers needing presbyopia correction.²

The team found practitioners needed to trial 1.2 ± 0.5 lenses when using the modified fitting guide, compared with 1.4 ± 0.5 lenses with the traditional fitting guide, which met the study's predetermined criteria for superiority. On the first fitting visit, 82.8% of presbyopic patients required only one multifocal lens to find the right fit using the modified guide, while 65.1% were fit with one lens using the traditional guide. By the second visit, 98% of patients were fit using one or two trial pairs of lenses when the practitioners used the modified fitting guide.²

In addition, more clinicians preferred the modified guide, with 63.6% of participating clinicians giving the modified version the highest ranking for ease of use—only 33.3% did so for the traditional fitting guide.

1. Kunnen C, Nixon L, Merchea M. Subjective functional quality of vision and ease of fit rating of three multifocal contact lenses with similar optical design using two different fitting guides. *Cont Lens Ant Eye*. 2019;42(6, Supp 1):e31.

2. Merchea M, Evans D, Kannarr S, et al. Assessing a modified fitting approach for improved multifocal contact lens fitting. *Cont Lens Ant Eye*. 2019;42(5):540-45.



Achieving the desired level of multifocality requires larger, radially varying power changes in the correcting lens of a center-near design compared with a center-distance design.

add power in the fitting guide.^{3,4}

Although some of the reasons for dissatisfaction with multifocal soft lenses are generally age-related discomfort and handling issues, unwarranted visual compromise does not make them an attractive option for the potential presbyopic lens wearer. Power profiles give

profiles to discriminate lens designs and to correlate design features with visual performance.⁴

A key understanding of the strengths and limitations of multifocal contact lens optics and how they might be applied in clinical practices is critical.

insight into the distribution and magnitude of relative plus with respect to the prescription power in multifocal contact lenses. Practitioners can use such

Making sense of the optics—and changing up their design as new ideas come out—can help you better fit presbyopes with the right lens. In clinical practice, doctors must provide the best image quality or vision correction possible. With this in mind, multifocal contact lenses can provide patients good vision at all distances and, theoretically, optimal image quality with the right design. **RCCL**

1. Kollbaum PS, Bradley A. Multifocal contact lenses can provide patients good vision at all distances. *Clin Exp Optom.* 2020;103(1):21-30.
2. Monsalvez-Romin D, Gonzalez-Mejome J, Esteve-Taboada J, et al. Light distortion of soft multifocal contact lenses with different pupil size and shape. *Cont Lens Ant Eye.* December 4, 2019. [Epub ahead of print].
3. Jun I, Cho JS, Kang MG, et al. Clinical outcomes of a novel presbyopia-correcting soft contact lens with a small aperture. *Cont Lens Ant Eye.* December 24, 2019. [Epub ahead of print].
4. Kim E, Bakaraju RC, Ehrmann K. Power profiles of commercial multifocal soft contact lenses. *Optom Vis Sci.* 2017;94(2):183-96.



Earn up to 18-29 CE Credits*

Join us for our 2020 MEETINGS



APRIL 16-19, 2020 - AUSTIN, TX**

Joint Meeting with OCCRS
Omni Barton Creek
Review Program Chair: Paul M. Karpecki, OD, FAAO
OCCRS Program Chair: Tracy Schroeder Swartz, OD, MS, FAAO
» www.ReviewEducationGroup.com/Austin2020

JUNE 5-7, 2020 - ORLANDO, FL

The Convention Center
at Disney's Yacht & Beach Club Resorts
Program Chair: Paul M. Karpecki, OD, FAAO
» www.ReviewEducationGroup.com/Orlando2020

MAY 29-31, 2020 - SAN DIEGO, CA

Manchester Grand Hyatt
Program Chair: Paul M. Karpecki, OD, FAAO
» www.ReviewEducationGroup.com/SanDiego2020

NOVEMBER 6-8, 2020 - PHILADELPHIA, PA

Philadelphia Marriott Downtown
Program Chair: Paul M. Karpecki, OD, FAAO
» www.ReviewEducationGroup.com/Philadelphia2020

Medscape **LIVE!** CONFERENCES

For the latest information visit:
www.ReviewEducationGroup.com/Events
e-mail: ReviewMeetings@MedscapeLIVE.com or call: 866-658-1772



**17th Annual Education Symposium
Joint Meeting with NT&T in Eye Care

Review Education Group partners with Salus University for those ODs who are licensed in states that require university credit. See www.revieweducationgroup.com/events for any meeting schedule changes or updates.

It's amazing how something so small
can make such a big impact.



SMALL?
PERHAPS.

SIGNIFICANT?
ABSOLUTELY.

HIGH OXYGEN TRANSMITTANCE

EXCEPTIONAL COMFORT

EXCELLENT VISION

RESERVED FOR VSP NETWORK DOCTORS

UNITY BIOSYNC WITH HYDRAMIST RATED...*

9^{OUT}
OF **10**
FOR OVERALL
VISION

9^{OUT}
OF **10**
FOR INITIAL
COMFORT

8^{OUT}
OF **10**
FOR OVERALL
COMFORT

*Based on results of multi-center randomized clinical trial conducted by an independent research consultant.

unity WITH HYDRAMIST™
biosync®

ONE-DAY SILICONE HYDROGEL SPHERICAL CONTACT LENSES

Visit unitybiosync.com for more information or to order your fit kit today.

WHEN PRESBYOPIA & ASTIGMATISM COLLIDE

A multitude of contact lens options exist for the independent correction of astigmatism and presbyopia. Let's discuss the options when these occur simultaneously.

By Robert Ensley, OD, and Jessica Jose, OD

The loss of accommodation can be frustrating, especially for today's busy and somewhat demanding presbyope. Digital devices combined with active lifestyles can simultaneously increase demands on near vision while also making wearing spectacles seem burdensome. Meeting the needs of our presbyopic patients, especially those with astigmatism, may sound challenging; however, there is a growing number of contact lens options at our fingertips.

According to the 2018 US Census Bureau, approximately 119 million people, or nearly 40% of the population are between the age of 40 and 69.¹ Patients in this age range may have the inability to keep up with the demands on their accommodative system. One approach to provide functional near vision is with the use of contact lenses. In fact, many patients entering their presbyopic years currently wear contact lenses or have previous experience. For these patients, maintaining independence from the use of spectacles is often a priority. Additionally, at least one study suggests that spectacle wearing presbyopes would prefer contact lens use, if using them would achieve good vision and comfort.²

Despite the interest in contact lens wear, there are challenges for the presbyopic patient. Physiological changes to the tear film and ocular surface can contribute to contact lens discomfort, which is commonly cited as the main reason for dropout.^{3,4} However, poor vision is equally responsible for discontinuation among presbyopic patients.⁵ One perceived barrier to optimal vision in contact lenses is the presence of astigmatism.

Nearly 50% of contact lens patients have astigmatism of 0.75D or greater in at least one eye, yet only 30% of contact lenses are prescribed for astigmatism.^{6,7} This discrepancy is concerning, considering the decrease in acuity and symptoms of eyestrain that occurs from not correcting astigmatism as low as 0.75D.^{8,9} Accordingly, as astigmats become presbyopic, their astigmatism can play a crucial role in the ability to achieve the desired range of vision.

MULTIPLE CHOICES

Early contact lenses made from polymethyl methacrylate evolved to higher oxygen-permeable gas permeable (GP) lenses, which have remained a mainstay in the correction of astigmatism. GP lenses rest on the

cornea and use the smooth refracting surface of the lens in combination with the post-lens tear layer to neutralize corneal astigmatism and provide crisp, stable optics. Before the rise of contemporary GP multifocals, presbyopic patients resorted to using reading glasses over their spherical, distance-only contact lenses or using monovision contact lenses.

Monovision. This option provides near vision by reducing minus power or adding plus power, typically over the non-dominant eye. Although effective, especially for early presbyopes, there are drawbacks to this set-up. As the power difference between eyes increases, it can become more difficult to suppress blur, affecting

ABOUT THE AUTHORS



Dr. Ensley practices at Gaddie Eye Centers in Louisville, KY. He is a Fellow of the American Academy of Optometry and the Scleral Lens Education Society.



Dr. Jose is an assistant professor at Midwestern University-Chicago College of Optometry in Downers Grove, IL. She is a Fellow of the American Academy of Optometry and the Scleral Lens Education Society.

binocularity and depth perception. Monovision has also been shown to reduce both contrast sensitivity and acuity.¹⁰ Despite these issues, monovision is still commonplace, with reduced chair time commonly cited as a reason for prescribing.¹¹ However, when comparing monovision with multifocal contact lenses, studies consistently show patients preferring multifocals.^{12,13}

Multifocal lenses. GP multifocals can be split into two categories, segmented and aspheric multifocals. Segmented or translating multifocals are similar to lined bifocals in that distance and near optics are separated into distinct segments. In primary gaze, the distance segment is in front of the pupil and visual axis, allowing for uninterrupted distance clarity. The reading segment is positioned at the pupil margin with the inferior lens edge resting on the lower eyelid. On down gaze, the reading segment translates upwards to move the near optics into the necessary position.

Aspheric multifocals have both distance and near zones, but the optics for both distance and near are presented in front of the pupil simultaneously. Near add power is created by a change in curvature on either the anterior or posterior curvature of the lens. These changes can create a smooth transition between working distances, but the brain must still adapt to the simultaneous vision optics.

Moving established GP wearers to multifocal designs is an easy transition, but having GP neophytes adapt to the initial comfort is a hurdle. If comfort is an obstacle, hybrid lenses provide GP optics with comfort similar to a soft lens. The smooth junction between the GP center and the soft skirt reduces lid interaction, while the skirt maintains centration and keeps the optics stable. Hybrid multifocals are available with aspheric optics in both center-near

Multifocal Lens Options		
Lens Type	Advantages	Disadvantages
Soft toric multifocal	<ul style="list-style-type: none"> Initial comfort Available in stock and custom designs Planned replacement schedule 	<ul style="list-style-type: none"> Toric stability critical to success Possible greater cost Limited lens materials
Gas permeable multifocal	<ul style="list-style-type: none"> Superior optics to soft multifocals Unlimited range of refractive correction Available in segmented or aspheric multifocal designs 	<ul style="list-style-type: none"> Adaptation to comfort Potential for dislodgement or lost lenses
Hybrid multifocal	<ul style="list-style-type: none"> GP optics with comfort closer to soft lenses Center-distance and center-near designs 	<ul style="list-style-type: none"> Strict replacement schedule Lens handling possibly tough for a novice
Scleral multifocal	<ul style="list-style-type: none"> GP lens optics Initial comfort 	<ul style="list-style-type: none"> No lens translation Higher expertise required to fit Cost

and center-distance designs. The center-near design has a set 3.0mm zone size with three different add powers, while the center-distance design has a flexible zone size with variable add powers up to 5.00D.

Although the popularity of GP multifocals has remained relatively stagnant, one growing market is scleral multifocals.¹⁴ Scleral lenses are large diameter GP lenses that vault the cornea and align with the sclera, providing stable optics and great comfort when fit properly. Their primary indication is for the irregular cornea, but their popularity has led to an increase in normal cornea applications, including multifocals, using smaller diameter (<15.5mm) scleral lenses.

Because there is no translation, many scleral lenses use center-near aspheric designs to provide near optics, though there are a few designs capable of center-distance optics. Additionally, at least one scleral multifocal design (Zenlens, Bausch + Lomb) is currently capable of decentering their optics to align with the true visual axis, rather than with the geometric center of the lens.

The optics of a GP lens is widely recognized as superior to their soft lens counterparts; however, soft toric

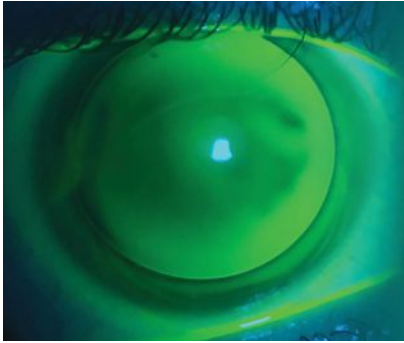
lenses are significantly more popular. Contemporary soft toric lenses use superior lathing technology to create highly reproducible lenses in both disposable and custom modalities. Disposable soft toric lenses can correct up to 2.75D of astigmatism with around the clock axis in 10-degree increments. Although there has been one monthly replacement toric multifocal available for more than a decade (Proclear Toric Multifocal, Cooper Vision), prescribing soft toric multifocal lenses never gained much traction. The recent launch of Bausch + Lomb's Ultra Multifocal for Astigmatism in June 2019 has brought soft toric multifocals back to the forefront.

If parameter availability is an issue, custom lens laboratories such as SpecialEyes or Art Optical are capable of customizing all parameters of the lens from the fit of the lens to the power of the astigmatism and the add power. Additionally, these custom lenses have the capability to adjust zone sizes and decenter the optics to help optimize vision.

ASTIGMATISM MATTERS

Perhaps the most important factor in selecting a contact lens for a patient is their refractive error.

WHEN PRESBYOPIA & ASTIGMATISM COLLIDE



Astigmatism up to 2.50D can be addressed easily in both soft toric and GP lens modalities.

For astigmats, correcting the astigmatism is the first priority. The total refractive astigmatism of the eye combines the power from both the cornea and the crystalline lens. If the amount of refractive astigmatism is equal to the corneal astigmatism, the astigmatism is derived primarily from the cornea. Both soft and GP lenses can correct corneal astigmatism effectively.

If the refractive astigmatism is different than the amount of corneal astigmatism, the residual astigmatism originates internally, or from the lens. When lenticular astigmatism is 0.50D or greater, soft toric lenses or toric GP lenses are ideal. Toric GPs require lathing the astigmatic power into the front surface of the lens, which also requires rotational stability, much like a soft toric lens.

The majority of astigmatic patients have regular astigmatism, in which the meridional power is 90 degrees apart. Regular astigmatism can be further classified into with-the-rule (WTR), against-the-rule (ATR) or oblique astigmatism. WTR astigmatism happens when the vertical meridian is steeper, resulting in more power needed, while the flatter meridian is along the horizontal axis. When fitting GP lenses, they will tend to move along the steeper meridian, which makes a WTR cornea a more natural fit due to

vertical blink forces. ATR corneal astigmatism will have a steeper horizontal meridian, which may result in lateral decentration of a corneal GP lens. If there is concern about the centration of a corneal GP lens, particularly with ATR or oblique corneal astigmatism, then soft toric lenses, hybrids or scleral lenses may be a better choice.

Also consider astigmatic power when selecting lenses. Astigmatism up to 2.50D can be fit easily in both soft toric and GP lens modalities. Correcting higher levels of astigmatism can be more complex. When choosing a soft toric, consider custom design lenses, given their ability to correct higher cylinder powers with a refined axis in one-degree increments. If the lens is not perfectly centered or rotationally stable, manipulate custom lenses to change base curve, diameter and prism-ballast amount to improve the lens fit.

A highly toric cornea can also cause decentration or poor alignment with a corneal GP lens. In these situations, adding back-surface toricity will improve the lens fit, but the lens may no longer have rotationally stable optics. Another option is scleral lenses, which vault the toric cornea while neutralizing astigmatism.

AN ADD FOR THE NEAR

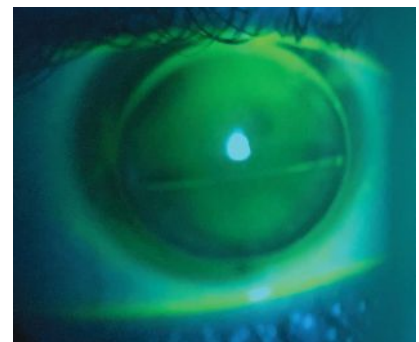
With as many contact lens options as we have in our tool bag, incorporating the near power for each patient requires careful consideration of two main factors.

Previous experience. Satisfied contact lens wearers may not require a significant deviation from their current contact lenses. GP lens, hybrid and scleral lens wearers can typically have multifocal optics incorporated into their current designs without the need for refit. Soft toric lens wearers may require a discussion about changing lens materials or modality since there are fewer soft lens options

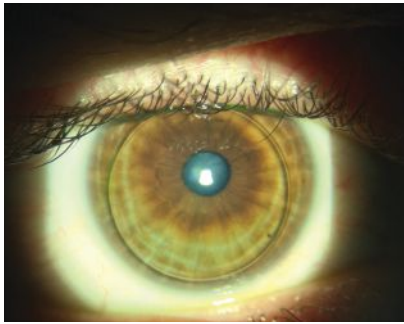
than can incorporate both astigmatic and presbyopic correction simultaneously. While most patients are open to switching lens brand and material to accommodate their changing visual needs, there are some who are a bit more hesitant. For example, daily disposable toric lens wearers may be the most difficult, and these wearers may be relegated to readers or monovision if they aren't willing or able to budge from the daily disposable route. Thorough education is key when determining the best options for your patients.

Visual demands and expectations. Learning the patient's demands and expectations for their vision is critical to understand their motivation level and to recommend a contact lens. Patients with higher demands and a higher sensitivity to blur would likely do better with a GP lens modality due to the crisper optics and stability.

The desire for a full range of vision will make a multifocal lens of any modality a great choice. However, simultaneous vision designs may involve some manipulation of the range of vision. Knowing if the patient prefers a stronger distance or near range is useful in designing the lens parameters. Conversely, some patients cannot tolerate any compromise in their range of vision. These patients will not be good multifocal candidates, despite the available



Segmented or translating multifocals are similar to lined bifocals in that distance and near optics are separated into distinct segments.



Moving established GP wearers to multifocal designs can be an easy transition.

technology. Presenting the potential lens options, using patient-focused terminology and including them in the lens selection process can keep them involved in the fitting process. Thorough education and setting expectations is also critical to the patient's contact lens success.

For contact lens neophytes, there is one additional factor to consider other than meeting vision demands. Initial adaptation to contact lens wear, including application and removal, can be a barrier to new wearers of any age. During preliminary testing, if a patient shows high sensitivity to approaching objects near the ocular surface, a soft lens might provide an easier adaptation to initial comfort. Patients with small apertures, deep set orbits or large fingers may also have more difficulty with application and removal and may do better with a smaller diameter corneal GP lens.

REFINING THE FIT

Providing that initial wow factor is the best way to start off on the right foot. Multifocals can be fit both empirically and diagnostically. Although diagnostic fitting sets are available for custom soft toric multifocals, you can order corneal GP multifocals and now hybrid multifocals empirically. This method can save chair time by producing an initial lens based off data provided to the laboratory.

If refinements are necessary, these changes are often minor since empirically designed lenses can be quite accurate.

Scleral multifocals are best fit diagnostically because haptic alignment and lens centration are imperative. Lens power can also vary based on lens vault and variable tear layer. Although it is time consuming, fit scleral multifocals in two phases—first perfect the lens fit and then add the multifocal optics.

Once lenses are dispensed, evaluate progress after one to three weeks, as it allows for adequate adaptation to both fit and vision. If troubleshooting is required, evaluate lens fit and visual performance.

For lenses of all modalities and design, centration is critical to the success of the multifocal optics.

If distance and near optics aren't presented properly, then vision will be poor at one or both working distances. If soft toric multifocals have been fit, confirm rotational stability. A rotationally unstable lens is useless and must be corrected first.

Visual performance is best evaluated binocularly at both distance and near; however, monocular assessment can be useful if the patient feels off-balance. When distance vision is the concern, modify distance power, reduce add power or change zone sizes. Conversely, if near vision needs improvement, push plus power in the distance prescription, increase add power or change zone size. If small refinements are needed, it is good practice to adjust only one variable at a time.

Many viable contact lens options are available for your patients with presbyopia and astigmatism. Communicating with them and making them aware of the solutions at their disposal can help reach or exceed their expectations. **rccl**

Clinical Pearls

- Check vision binocularly at both distance and near.
- Perform the over-refraction in free space with loose lenses.
- Use real-world examples to assess near vision (i.e., a computer screen, phone or tablet).
- Avoid making changes too early—adaptation time is key.
- Follow the fitting guide when available. Lab consultants are another great resource.
- Don't be afraid to change designs if your first doesn't work.

1. United States Census Bureau. Age and sex composition in the United States: 2018. www.census.gov/data/tables/2018/demo/age-and-sex/2018-age-sex-composition.html. Last revised July 11, 2019. Accessed February 5, 2020.
2. Rueff EM, Bailey MD. Presbyopic and non-presbyopic contact lens opinions and vision correction preferences. *Cont Lens Anterior Eye*. 2017;40(5):323-8.
3. Dumbleton K, Woods CA, Jones LW, Fonn D. The impact of contemporary contact lenses on contact lens discontinuation. *Eye Contact Lens*. 2013;39:92-98.
4. Richdale K, Sinnott LT, Skadahl E, Nichols JJ. Frequency of and factors associated with contact lens dissatisfaction and discontinuation. *Cornea*. 2007;26:168-74.
5. Rueff EM, Varghese RJ, Brack TM, et al. A survey of presbyopic contact lens wearers in a university setting. *Optom Vis Sci*. 2016;93:848-54.
6. Young G, Sulley A, Hunt C. Prevalence of astigmatism in relation to soft contact lens fitting. *Eye Contact Lens*. 2011;37:20-5.
7. Efron N, Nichols JJ, Woods CA, Morgan PB. Trends in US contact lens prescribing 2002 to 2014. *Optom Vis Sci*. 2015;92:758-67.
8. Richdale K, Berntsen DA, Mack CJ, et al. Visual acuity with spherical and toric soft contact lenses in low- to moderate-astigmatic eyes. *Optom Vis Sci*. 2007;84:969-75.
9. Berntsen DA, Cox SM, Bickle KM, et al. A randomized trial to evaluate the effect of toric versus spherical contact lenses on vision and eyestrain. *Eye Contact Lens*. 2019;45(1):28-33.
10. Wolffsohn JS, Davies LN. Presbyopia: effectiveness of correction strategies. *Prog Retin Eye Res*. 2019;68:124-43.
11. Bennett ES. Contact lens correction of presbyopia. *Clin Exp Optom*. 2008;91:265-78.
12. Richdale K, Mitchell GL, Zadnik K. Comparison of multifocal and monovision soft contact lens corrections in patients with low astigmatic presbyopia. *Optom Vis Sci*. 2006;83:266-73.
13. Woods J, Woods C, Fonn D. Visual performance of a multifocal contact lens versus monovision in established presbyopes. *Optom Vis Sci*. 2015;92(2):175-182.
14. Nichols JJ, Fisher D. Contact lenses 2018. *CL Spectrum*. 2019;34:18-23.

PRESBYOPIA TREATMENT:

Make sure you're in the know about long-term solutions for the condition.

By Larry Baitch, OD, PhD

CURRENT & FUTURE OPTIONS

Presbyopia is the only ocular condition with a prevalence of 100% in patients older than 50.¹ While not all presbyopes require correction, due to congenital monovision, it's important to realize that accommodation declines steadily with age for everyone.

To many, presbyopia may seem like it's just another annoyance that comes with aging. Uncorrected presbyopia, however, can result in severe visual impairment and deprive someone of a satisfactory quality of life and opportunities requiring working near vision. The global burden of uncorrected presbyopia in terms of productivity loss is estimated to be just over \$11 billion annually.²

Luckily, the condition is correctable. Those who are motivated to shed their spectacles can pursue contact lenses. Some go a step further and seek complete visual independence, and many surgical options are available. This article discusses current and future therapies available to the presbyopic population beyond spectacles and contact lenses.

SURGICAL THERAPIES

Device companies have come up with three basic surgical strategies for providing permanent, or at least long-term, correction of near vision loss in presbyopes: (1) making changes

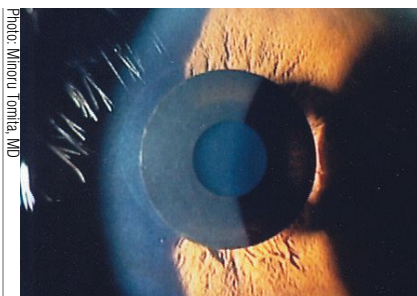


Fig. 1. The Kamra is designed to increase depth of focus.

directly within the optical pathway, (2) altering the underlying architecture and function of the accommodative mechanism outside the optical pathway and (3) inducing changes within the lens itself.

Kamra (AcuFocus). Launched in 2015, this is the only FDA-approved synthetic corneal presbyopic implant.³ It consists of a 6.0µm-thick laser-fenestrated disc of polyvinylidene fluoride that is 3.8mm in diameter with a 1.6mm central aperture.³ The device is positioned over the pupillary axis inside a femtosecond laser-created pocket at a corneal depth of 40% to achieve near monovision.³ The Kamra's small aperture extends the eye's depth of focus (DOF), providing uncorrected near visual acuity (UCNVA) of about 20/32 and distance of about 20/25 (*Figure 1*).³ A refractive error of -0.75D is optimal for maximal near and distance coverage via DOF.

PEARL. Soosan Jacob, MD, and her team based in India introduced the presbyopic allogenic refractive lenticule (PEARL) procedure to help avoid the pitfalls of corneal melt, implant fibrosis, opacification and haze associated with synthetic corneal implants (*Figure 2*).⁴

A serologically tested donor lenticule harvested from the small-incision lenticule extraction (SMILE) surgery of a -2.00D to 2.50D patient is trephined to form a 1.0mm stromal disc that is implanted over the center of the pupil in a 120.0µm-deep femtosecond laser-created pocket.⁴ Once the cornea heals, the lenticule is invisible to the naked eye and results in a hyperprolate central cornea, creating the multifocal optic necessary for excellent near and far vision.⁴ The allograft is completely permeable to oxygen and corneal nutrients.⁴

VisAbility micro-insert (Refocus Group). This was conceived on the theory that presbyopia is primarily due to decreasing space between the lens equator and the ciliary muscle as the diameter increases with age.⁵ It consists of four 5.0mm-long

ABOUT THE AUTHOR



Dr. Baitch is a professor and associate dean for research at the MCPHS University School of Optometry in Worcester, MA. He researches new ophthalmic diagnostic and therapeutic devices and pharmaceutical therapies.

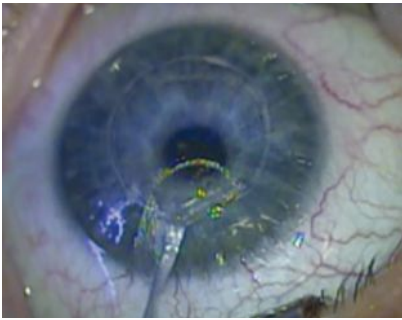


Fig. 2. A donor lenticule harvested from a SMILE refractive patient is ready for trephining into a 1.0mm-diameter intrastromal implant.

polymethyl methacrylate segments implanted 4.0mm from the limbus between the extraocular muscles in the four quadrants of the eye (Figure 3).⁵

As a scleral treatment peripheral to the cornea, VisAbility completely avoids the eye's optical pathway.⁵ Rather than offering a monovision treatment for presbyopia, it aims to provide natural, binocular vision without adverse effects on distance vision.⁵ FDA trial data revealed a 90% patient satisfaction rate with most patients reaching a UCNVA of 20/32 by three months after surgery.⁵

Disadvantages include extended postoperative conjunctival injection due to the conjunctival resection necessary to create the scleral tunnel and implant the micro inserts, prolonged optimal near visual acuity attainment until weeks or months after surgery and significant perioperative pain.⁵ The device is currently awaiting pre-market approval from the FDA.⁵

LaserAce (Ace Vision Group). This is a less invasive, less surgical binocular treatment that does not alter the optics of the lens or cornea.⁶ It is based on the belief that scleral rigidity is the primary culprit in presbyopia.⁶ In a young eye, the sclera is more elastic and gives slightly with accommodative traction from the ciliary muscles. In an aging eye, the sclera is more rigid and resists movement associated with accommodation.

The procedure involves a series of scleral laser perforations using the company's VisioLite Er-YAG laser.⁶ Four 5.0mm² ablation matrices are applied in a diamond-shaped configuration to the four quadrants 4.0mm peripherally to the limbus.⁶ Each matrix of laser perforations overlies five key anatomical constituents of the accommodative mechanism, affording more elasticity to the sclera.⁶ As biomechanical efficiency increases, it translates to the lens during accommodation.⁶ The procedure has not yet entered into FDA investigational device exemption clinical trials.⁶

OcuFit (Sooft Italia). This stimulates the ciliary muscle to increase its potency so that it can overcome the higher resistance of the system associated with aging.⁷ It avoids altering the optics of the eye and aims to restore dynamic accommodation.⁷

The device consists of a 20.0mm scleral lens with four electrodes positioned 3.5mm from the limbus at the four quadrants.⁷ Electricity, which causes the ciliary muscle to spasm, is pulsed for two seconds with a rest time of six seconds for eight minutes.⁷ Four treatments are performed at two-week intervals.⁷ More extensive studies are needed to consider electrostimulation a contender for presbyopia treatment.

CORNEAL PROCEDURES

Aside from monovision correction, there have been a number of attempts at presbyopia correction through multifocal corneal laser refractive procedures. PresbyLASIK describes a procedure that reshapes the cornea using standard laser refractive methods but alters the corneal laser ablation profile. This involves either making the peripheral cornea hyperprolate to create a central distance zone and a peripheral near zone or making the central cornea hyperprolate for a central near zone and a peripheral distance zone (Figure 4).

Both techniques can be performed using LASIK or PRK.

Supracor (Bausch + Lomb). This creates a variable-focus corneal profile with a 12.0µm elevation in the central 3.0mm, and provides a near addition power of approximately 2.00D.⁸ Peripheral to the central near portion is an aspheric annular zone, which provides intermediate and distance vision.⁸ It is best performed on hyperopic patients.⁸

Supracor outcomes vary depending on the technique's magnitude and whether it is performed in tandem with a refractive procedure, as a singular presbyopic treatment or binocularly.⁸ While patients have generally been satisfied with their resulting near vision, distance vision disturbances have limited the procedure's acceptance.⁸

Intracor (Bausch + Lomb). This employs a femtosecond laser to ablate concentric circles deep in the corneal stroma, inducing collagen shrinkage and causing a hyperprolate central near zone.⁹ Studies have demonstrated significant near vision improvement, but reductions in distance vision do occur and have precluded robust application.⁹ No clinical trials are currently in progress in the United States.⁹

PHARMA TREATMENTS

The medication realm may be home to the most encouraging class of treatment for presbyopic near vision

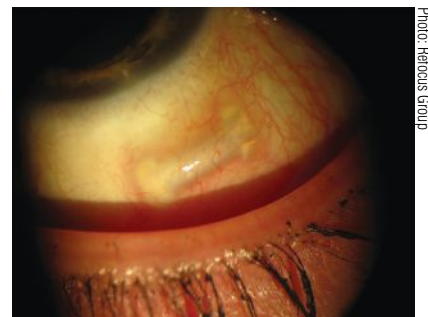


Fig. 3. The VisAbility offers natural, binocular vision without affecting the eye's optical pathway.

PRESBYOPIA TREATMENT: CURRENT & FUTURE OPTIONS

loss. The aim in this case is threefold: soften the age-stiffened crystalline lens matrix to allow for recovery of natural dynamic accommodation with the ciliary body, produce miosis of the pupil to allow for expansion of optical DOF, and increase corneal tissue pliability to allow for rigid contact lens molding of the cornea and a multifocal shape profile.

Dioptin. This topical eye drop (UNR844, Novartis) is a lipoic acid-based, topically instilled prodrug that penetrates into the lens.¹⁰ A prospective double-blind FDA Phase I/II trial reported no serious adverse results and comparable comfort in participants and controls.¹⁰ After the 90-day dosing period, Dioptin-dosed subjects had achieved a distance-corrected near visual acuity (DCNVA) of 20/22 and controls, 20/40.¹⁰ The near acuity improvement persisted through the 301-day follow-up.¹⁰

TVT. Yolia Health's True Vision Treatment (TVT) is a seven-day combo therapy involving an eye drop to make the cornea more malleable and a cornea-shaping contact lens designed for eight hours of wear.¹¹ The company claims the molding effect lasts more than seven months.¹¹ The twofold nature of this treatment has complicated the FDA trial process.¹¹ However, results have been encouraging, with reports of binocular UCNVA improving from 20/80 to 20/40.¹¹ Distance acuity was not adversely affected, but it is unknown whether aberrations typical of multifocals caused visual disturbances.¹¹

Liquid Vision. These eye drops (PRX-100, Presbyopia Therapies) encourage pupil miosis to improve both near and far visual acuity via DOF expansion.¹² In younger presbyopes, the myopic shift of the crystalline lens associated with the ciliary spasm can result in reduction of distance visual acuity. This drop is meant to solve these problems with its preparation of aceclidine.¹²

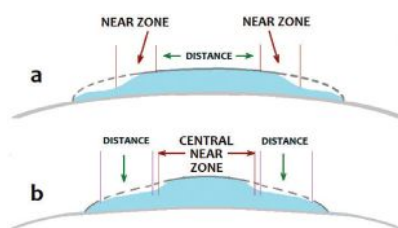


Fig. 4. There are two configurations of PresbyLASIK: a near peripheral corneal annular zone with a distance central zone (a) and a near central corneal zone with a peripheral annular distance zone (b).

The FDA Phase IIb study found that miosis took place about 30 minutes after eye drop instillation, with 47.2% of eyes gaining at least three lines of DCNVA and 91.7% gaining at least two.¹² The drug's effect lasted as long as seven hours, and there was no discomfort or adverse effect on distance visual acuity.¹² The medication will enter FDA Phase III clinical trials in the first half of 2020.¹²

PresbiDrops. This drop (CSF-1, Orasis) combines a parasympathomimetic with an NSAID in an oil-based vehicle to preclude discomfort due to ciliary spasm and minimize the risk of uveitis.¹³ The Phase IIb clinical trial met the three-line improvement criteria for DCNVA and achieved good comfort with no significant adverse effect on distance vision.¹³ The company claims that the drug has a fast onset of action and its effects are long-lasting and is now recruiting for FDA Phase III clinical trials.¹³

Oxymetazoline. This drug (AGN-199201, Allergan) is a vasoconstriction decongestant, a direct-acting alpha-1 adrenergic agonist and alpha-2a adrenergic partial agonist, traditionally used to treat sinus congestion and conjunctival hyperemia.¹⁴ In the Phase II trial, about 70% of subjects had at least a two-line improvement in UCNVA.¹⁴ Allergan is currently recruiting for Phase III trials for two preparations (AGN-190584 and AGN-199201), individually and in combination with each other.¹⁴

Many investigators are in the process of testing drugs and combination therapies to improve near vision, nearly all of which involve pupillary miosis. Most are not in the FDA pipeline yet, but all have achieved similar outcomes in terms of time to onset and duration of effect.^{15,16} International examples include FOV Tears produced by Luis Felipe Vejerano, MD, Método Benozzi by Jorge Benozzi, MD, and PresbiPlus by Roberto Pinelli, MD.^{15,16}

LENS REPLACEMENT

Intraocular lenses (IOLs) are not considered a treatment for presbyopia *per se*, but many ophthalmologists who lens replacement surgery on patients without cataracts by substituting the healthy crystalline lens with an IOL to correct the refractive error while providing near vision, intermediate vision or both. This surgery is also referred to as clear lens replacement or refractive lens exchange (RLE). Three types of IOL configurations can be employed in RLE:

Monofocal monovision.

Monofocal IOLs (spherical or spherocylindrical) are geared toward patients who have had success with contact lens monovision. However, monofocal IOLs have a minimal DOF, so it must be decided prior to surgery whether intermediate or near vision is more important to the patient based on their working distance demands.

EDOF, trifocal IOLs. Extended DOF (EDOF) and trifocal IOLs are a new generation of IOLs that provide clearer vision at all working distances. Sometimes promoted as presbyopia-correcting IOLs, these lenses can be used in a modified monovision configuration or they can be binocularly employed. For the most part, they have largely replaced multifocals as the ultimate choice for continuous vision at a full range of distances.

FDA-approved in 2016, the Tecnis

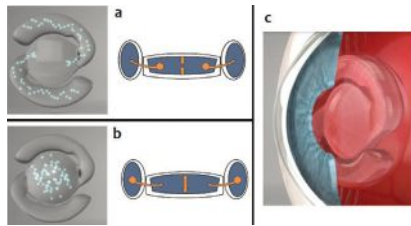


Fig. 5. In the un-accommodated state (a), a minute amount of fluid streams from the central optic into the peripheral balloon haptics of the lens, and the distance power of the optic is obtained. Upon accommodation and radial contraction of the lens capsule by the ciliary body (b), the fluid streams into the central optic, increasing its plus power for near vision provided by the FluidVision AIOL (c).

Symphony EDOF IOL (Johnson & Johnson) has a lens surface that carries achromatic diffractive grating elements called echelettes, which extend DOF and concurrently correct chromatic dispersion.¹⁷ Rather than prismatically splitting light to produce a second near focal point like multifocals, echelettes offer a more continuous range of visual working distances.¹⁷ Reduced chromatic dispersion results in higher contrast sensitivity, reduction of glare and halos and higher visual quality.¹⁷ Near vision can be compromised, so patients may occasionally need assistance from near spectacles for close targets.¹⁷

The Acrysof IQ PanOptix trifocal IOL (Alcon), which received FDA approval in August 2019, has a trifocal diffractive surface.¹⁸ Its three dioptric powers are targeted for 40.0cm, 60.0cm and infinity, and it is available with astigmatic correction.¹⁸

Other EDOF and trifocal IOLs in development that have found success internationally are the AT Lisa trifocal IOL (Carl Zeiss Meditec), the Alsafit trifocal VF lens (Alsanza), the FineVision Triumf trifocal EDOF lens (PhysIOL) and the Mini Well Ready EDOF lens (SiFi Medtech).^{19,20} The Mini Well Ready is unique in that it

has wavefront-guided progressive optics without diffractive lens zones, a peripheral monofocal distance optic, a middle distance optic with oppositely-signed spherical aberration and a central distance zone.²⁰ This combination precludes halos and provides a continuous range of vision.²⁰

Accommodating IOLs. The race is on for a lens that will fit into the capsular bag and re-establish normal dynamic accommodation. This is what accommodating IOLs (AIOLs) aim to do.

The only AIOLs approved so far in the US are the Crystalens AO and HD (Bausch + Lomb).^{21,22} The Crystalens has articulating haptics that are supposed to bend on accommodative effort and translate the optic forward.^{21,22} Research, however, has demonstrated that it does not accommodate as earlier stated; rather than the 1.50D to 1.90D theorized by a 1.0mm displacement of the optic with accommodation, forward translation of the optic has been measured at roughly 0.4mm and has even been observed to tilt backward, creating aberrations that would account for a near increase in DOF.^{21,22}

There are many AIOLs not yet approved in the United States that show true optical change with accommodative effort.

The FluidVision AIOL (Alcon) is promoted as the first true shape-changing, fluid-driven AIOL.²³ The lens has three main components: (1) a flexible central optic reservoir, (2) flexible pontoon-like haptics that also serve as reservoirs and (3) about 30µL of fluid (Figure 5).²³ Its method of action is based on the principle of ciliary compression; accommodative effort causes the ciliary body to compress the haptics, which causes fluid to stream out to the central optic.²³ As the central optic fills, the plus power of the lens increases, focusing the IOL for near.²³ Theoretically, graded action from the ciliary body

should be able to provide a continuous range of focus for the patient.²³

A study reported good visual acuity at every distance, with mean distance vision at 20/20, intermediate vision at 20/20 to 20/25 and near vision at 20/20 to 20/27.²³ Accommodation was measured at a mean of 2.00D, and accommodative amplitudes as high as 5.00D were achieved with accommodative effort.²³ Alcon named the newest version the NextGen 20/20 and is currently undergoing an international multicenter clinical trial.²³

Certain AIOL designs depend on the compressive action of the ciliary muscle to produce axial movement of the IOL optic, which has proved problematic.²⁴ In addition, IOLs positioned inside the capsular bag have been subject to capsular fibrosis, shrinkage and stenosis of the haptics, compounding the loss of IOL functionality over time.²⁴

The Lumina AIOL (AkkoLens) went in a different direction, using an opposing pair of optics called Alvarez lenses—freeform progressive lenses that vary the dioptric power through the pair when the lens elements move transversely to each other at a 90° angle to the pupillary axis (Figure 6).²⁵ When the ciliary body compresses the AIOL haptics with near accommodative effort, elements of the lens transverse one another with the net optical combination increasing the plus power of the lens.²⁵ For distance vision, the ciliary body relaxes and decompresses the haptics, allowing the lens elements to realign.²⁵

Rather than being located in the bag and subjected to fibrosis, the Lumina AIOL is positioned at the sulcus plane where the ciliary body muscle contacts the opposing elements of the lens, moving them transversely and engendering the accommodative myopic shift.²⁵ Breaking up the capsule can overcome restriction by capsular bag fibrosis.²⁵

PRESBYOPIA TREATMENT: CURRENT & FUTURE OPTIONS

While a study found a positive accommodative response to a stimulus—up to 4.50D—in the Lumina AIOL compared with an absent response in a monofocal IOL, there are issues with accommodative response variability from patient to patient.²⁵

The Juvene AIOL (LensGen) uses a two-part system that can be inserted into a smaller incision and assembled in the eye: a peripheral carrier that fills the capsular bag and a central fluid-filled optic that deforms to become more prolate as the carrier is compressed by the ciliary body. The device is simple and relatively clear of higher-order aberrations.²⁶

Data from clinical trials in Mexico and the Dominican Republic indicate that patients can maintain 2.50D of accommodation and achieve up to 3.00D.²⁷ Another study reported that about 50% of Juvene-implanted patients can achieve a DCNVA of 20/32 and 70%, 20/40.²⁷

IOLs that employ electro-optics and contain artificial intelligence software sense pupil constriction due to accommodation—distinct from the pattern and speed of constriction due to light reaction. Electro-optical IOLs may be incorporated into the long-term outlook on IOL technologies, but far simpler solutions exist that do not require nearly as much hardware or software.

In the near future, it is likely that a pharmaceutical solution will be the first big wave of treatment, and, in that case, a combination approach would be the most effective. Years from now, these drops may be available over-the-counter on shelves in pharmacies next to dollar readers. Presbyopic surgical methods are also always developing, further encouraging the rise of combination therapies. Patients over 60 will undergo RLE more often as procedures and AIOL technologies improve and receive FDA clearance. Despite the emer-

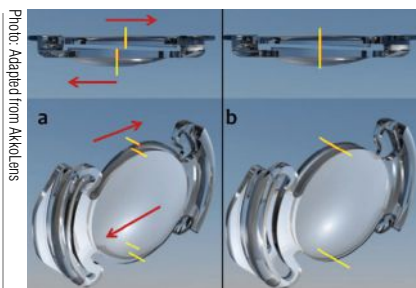


Fig. 6. As the ciliary body of the Lumina AIOL compresses the lens haptics (a), the lenses translate in apposition to each other, increasing plus power. With relaxation of the ciliary body (b), the lenses line up with the appropriate distance power.

gence and probable dominance of AIOLs, it is unlikely that multifocal and EDOF IOLs will go away, as the quality of vision from these lenses continues to improve with each generation.

Just as the exact cause of presbyopia is not entirely known, neither is the ideal treatment for the condition—one that reverses the presbyopic process and restores natural accommodation with the native crystalline lens. We can only hope that when one does emerge, it is affordable and accessible to the millions of people who experience the handicap of near vision loss around the world. **rccl**

- Duane A. Studies in monocular and binocular accommodation with their clinical applications. *Am J Ophthalmol.* 1922;5(11):865-77.
- Markets Insider. Myopia & presbyopia treatment market size worth \$28 billion by 2026: Grand View Research, Inc. [markets.businessinsider.com/news/stocks/myopia-presbyopia-treatment-market-size-worth-28-billion-by-2026-grand-view-research-inc-1028570106](https://www.markets.businessinsider.com/news/stocks/myopia-presbyopia-treatment-market-size-worth-28-billion-by-2026-grand-view-research-inc-1028570106). October 2, 2019. Accessed February 25, 2020.
- Vukich JA, Durrie DS, Pepose JS, et al. Evaluation of the small-aperture intracorneal inlay: three-year results from the cohort of the U.S. Food and Drug Administration clinical trial. *J Cataract Refract Surg.* 2018;44(5):541-56.
- Jacob S, Kumar DA, Agarwal A, et al. Preliminary evidence of successful near vision enhancement with a new technique: PrEsbyopic Allogenic Refractive Lenticule (PEARL) corneal inlay using a SMILE lenticule. *J Refract Surg.* 2017;33(4):224-9.
- Baitch L, Schanzlin D, Iskander D. One-year post-operative wavefront and refractive map changes following scleral implant surgery. Presented at the 15th International Congress on Wavefront & Presbyopic Refractive Correction; 2014; Dana Point, California.
- Hipsley A, Hall, B, Rocha KM. Long-term visual outcomes of laser anterior ciliary excision. *Am J Ophthalmol Case Rep.* 2018;10:38-47.
- Gualdi L, Gualdi F, Rusciano D, et al. Ciliary muscle electrostimulation to restore accommodation in patients with early presbyopia: preliminary results. *J Refract Surg.* 2017;33(9):578-83.
- Ryan A, O'Keefe M. Corneal approach to hyperopic presbyopia treatment: six-month outcomes of a new multifocal excimer laser in situ keratomileusis procedure. *J Cataract Refract Surg.* 2013;39(8):1226-33.
- Thomas BC, Fitting A, Khoramnia R, et al. Long-term outcomes of intrastromal femtosecond laser presbyopia correction: 3-year results. *Br J Ophthalmol.* 2016;100(11):1536-41.
- Stein JM, Robertson, SM, Evans DG, et al. An observational follow-up study assessing the long-term effects of bilaterally dosed topical lipico acid choline ester eye drops for the treatment of presbyopia. *Inv Ophthalmol Vis Sci.* 2017;58(8):330.
- Plenilunia Salud Mujer. Presenting a non-surgical procedure for presbyopia, which represents an option for patients with tired eyesight. plenilunia.com/noticias-2/presentan-procedimiento-no-quirurgico-para-presbicia-representa-opcion-para-pacientes-con-vista-cansada/55306/. July 5, 2018. Accessed February 25, 2020.
- Lipner M. EyeWorld. A unique drop. www.eyeworld.org/article-a-unique-drop. October 2014. Accessed February 25, 2020.
- ClinicalTrials.gov. Safety, tolerability, and efficacy of PresbiDrops (CSF-1), a topical ophthalmic drug for presbyopia. clinicaltrials.gov/ct2/show/NCT02745223. April 20, 2016. Accessed February 25, 2020.
- ClinicalTrials.gov. A Phase 3 efficacy study of AGN-190584 in participants with presbyopia. clinicaltrials.gov/ct2/show/study/NCT03804268?term=Allergan%2C+agn-190584&draw=2&rank=2. January 15, 2019. Accessed February 25, 2020.
- Vargas V, Vejarano F, Alió JL. Near vision improvement with the use of a new topical compound for presbyopia correction: a prospective, consecutive interventional non-comparative clinical study. *Ophthalmol Ther.* 2019;8(1):31-9.
- Healio. Clinicians anticipate treating presbyopia with eye drops. www.healio.com/optometry/optics/news/print/primary-care-optometry-news/%7B47b-f090e-50e5-4c49-aa96-d49d9843d2e1%7D/clicians-anticipate-treating-presbyopia-with-eye-drops?page=7. August 2017. Accessed February 25, 2020.
- Cochener B, Boutillier G, Lamard M, et al. A comparative evaluation of a new generation of diffractive trifocal and extended depth of focus intraocular lenses. *J Refract Surg.* 2018;34(8):507-14.
- Lawless M, Hodge C, Reich J, et al. Visual and refractive outcomes following implantation of a new trifocal intraocular lens. *Eye Vis (Lond).* 2017;4:10.
- Esteve-Taboada JJ, Domínguez-Vicent A, Del Águila-Carrasco AJ, et al. Effect of large apertures on the optical quality of three multifocal lenses. *J Refract Surg.* 2015;31(10):666-76.
- Savini G, Schiano-Lomoriello D, Balducci N, et al. Visual performance of a new extended depth-of-focus intraocular lens compared to a distance-dominant diffractive multifocal intraocular lens. *J Refract Surg.* 2018;34(4):228-35.
- Marcos S, Ortiz S, Pérez-Merino P, et al. Three-dimensional evaluation of accommodating intraocular lens shift and alignment in vivo. *Ophthalmology.* 2014;121(1):45-55.
- Pérez-Merino P, Birkenfeld J, Dorransoro C, et al. Aberrometry in patients implanted with accommodative intraocular lenses. *Am J Ophthalmol.* 2014;157(5):1077-89.
- DeBoer CM, Lee JK, Wheelan BP, et al. Biomimetic accommodating intraocular lens using a valved deformable liquid balloon. *IEEE Trans Biomed Eng.* 2016;63(6):1129-35.
- Alió JL, Ben-Nun J. Study of the force dynamics at the capsular interface related to ciliary body stimulation in a primate model. *J Refract Surg.* 2015;31(2):124-8.
- Alió JL, Simonov A, Plaza-Puche AB, et al. Visual outcomes and accommodative response of the Lumina accommodative intraocular lens. *Am J Ophthalmol.* 2016;164:37-48.
- Devgan U, Kohnen T, Donnerfeld E, et al. Dual-optic curvature-changing modular-design presbyopic IOL. Presented at the 37th Congress of the European Society for Cataract and Refractive Surgery; 2019; Paris, France.
- Pepose JS, Burke J, Qazi M. Accommodating intraocular lenses. *Asia Pac J Ophthalmol (Phila).* 2017;6(4):350-7.

Earn up to
18 CE
Credits*

NEW TECHNOLOGIES
& TREATMENTS IN
2020 EYE CARE
REVIEW
EDUCATION GROUP

Orlando, Florida

June 5-7, 2020

The Convention Center
at Disney's Yacht and Beach Club Resorts
1700 Epcot Resorts Blvd.
Lake Buena Vista, FL 32830



A Medscape **LIVE!** CONFERENCE

Review's New Technologies & Treatments in Eye Care proudly presents Orlando 2020!
Join us for three days of education detailing the latest ideas and innovations in eye care.

Earn up to 18* CE Credits

TQ/CEE will be approved for optometrists licensed in Florida or other states requiring
"Transcript Quality" courses for re-licensure.

PROGRAM CHAIR:



Paul M. Karpecki, OD, FFAO

Clinical Director
Advanced Ocular Surface Disease
Kentucky Eye Institute, Lexington, KY

Clinician OSD Clinic
Gaddie Eye Centers, Louisville, KY

Early Bird Registration Cost: \$495

Early Bird fees end on April 10, 2020. See website for daily fees.

THREE WAYS TO REGISTER:

Online: www.ReviewEducationGroup.com/Orlando2020
Call: 866-658-1772 or E-mail: ReviewMeetings@MedscapeLIVE.com

Administered by:
REVIEW
EDUCATION GROUP

COSE
*Approval pending

SALUS
UNIVERSITY
Pennsylvania College of Optometry

5 REAL-WORLD CONTACT LENS CARE PROBLEMS

Poor lens care and handling practices can lead to infections, drop-outs and even vision loss. Here's how you can help patients avoid them.

By Jane Cole, Contributing Editor

You know the scenarios. A patient recently fit with a monthly soft contact lens (CL) is sitting in your chair, complaining of constant redness. And then there's the veteran two-week wearer who made an urgent appointment due to severe ocular pain, photophobia and discharge, which you suspect could be microbial keratitis. While myriad reasons exist for these symptoms, poor CL care is likely at the top of your list of differentials.

Most of the 45 million contact lens wearers in the United States practice at least some behaviors that put them at risk for serious eye infections, according to a recent report from the CDC.¹ One third of lens wearers who responded to the study's survey recalled never hearing any lens care recommendations from their eye doctor, even though most clinicians reported sharing recommendations always or most of the time.¹ So, despite the educational efforts going on in the exam rooms, the importance of lens care isn't always getting through.

While daily disposable CLs have ushered in a healthier alternative with a care-free routine and reported better compliance, some wearers may still extend their wearing

cycles or even sleep in their lenses on occasion, upping their risk of infection.² Those in monthly and two-week regimens are prone to ocular discomfort, infections or even vision loss if they skimp on proper lens care, storage and disinfection.

"Some of the most common problems happen because patients are trying to save time or money," says Teresa Narayan, OD, who practices at MedStar Georgetown University Hospital Department of Ophthalmology in Washington DC, and is also an assistant professor at Georgetown University School of Medicine.

Improper contact lens care can lead to complications such as giant papillary conjunctivitis, corneal neovascularization, corneal edema and microbial keratitis, to name a few. "Some of these are more serious than others and many can be treated, but there is a chance of potential permanent vision decrease. I always make sure to educate patients on the risks of

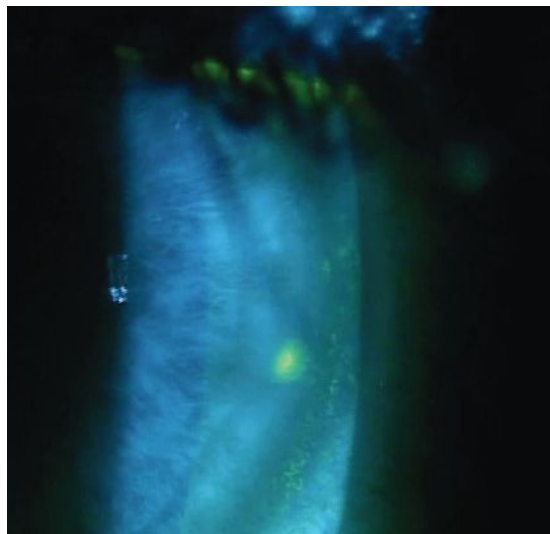


Photo: Mike Bujeic, OD

Patients who ignore proper lens care and handling may find themselves battling a contact lens peripheral ulcer.

contact lens wear and then emphasize that the risks are minimized with proper contact lens care," Dr. Narayan says.

Here, your colleagues share their five biggest contact lens-related problems and some pearls on how to counter them.

PROBLEM #1: HYGIENE HORROR STORIES

Washing your hands may seem simple enough, but poor hygiene is a common problem in CL wearers that can lead to issues such as

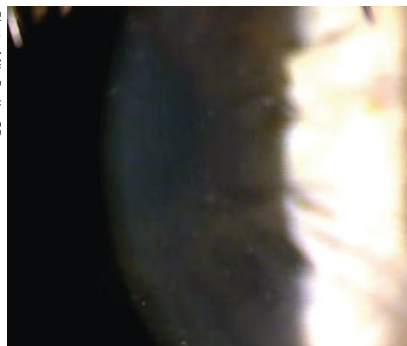
microbial keratitis and corneal inflammatory events.^{3,4}

Microbes that can cause infections are auto-inoculated from a person's fingers, so daily disposable, two-week and monthly wearers need to make sure they are washing their hands prior to lens insertion and removal, says Mile Brujic, OD, who practices at Premier Vision Group in Bowling Green, OH.

"A lack of hand washing is far and away the most common problem I see," adds Andrew Fischer, OD, of Professional Eyecare Associates in Jasper, IN. "We have sinks in every room, and for a majority of my contact lens patients, I find that I have to remind them to wash their hands before removing the lenses. If they aren't washing in the office, you can bet they aren't washing at home."

To counter this, at every visit—whether the patient is a new wearer or has been in lenses for 20 years—Dr. Fischer does a quick review of key hygiene tips, including the importance of washing hands, replacing cases, not sleeping in lenses not designed to be slept in and avoiding contact with water. Dr. Fischer also gives patients a "Contact Lens Do's and Don'ts" handout after the contact lens evaluation as a helpful reminder (Table 1).

Photo: Mile Brujic, OD



These non-infectious infiltrates are a tell-tale sign that the patient needs to be re-educated on proper lens care.

Table 1. Contact Lens Do's and Don'ts

DO:

- Wash hands before touching lenses.
- Replace lens cases at least monthly.
- When cleaning reusable lenses, rub and rinse with multipurpose solution.
- Replace lenses on schedule.
- Call the office ASAP if experiencing pain, redness, or change in vision.
- Scleral and sleep shape wearers: sterilize insertion and removal tools regularly with alcohol wipes and air dry.
- Return for annual contact lens evaluations and eye exams.

DON'T:

- Sleep in lenses (unless specifically instructed by your doctor).
- Use any type of water on the lenses—use only approved contact lens solutions.
- Refresh/top off solution in cases; instead, empty out and fill with fresh solution daily.
- Wear lenses while swimming or in a hot tub.

**PROBLEM #2:
CREEPY LENS CASES**

At Cascadia Eye in the Seattle, WA, area, Steven Turpin, OD, finds that infrequent case replacement is the issue he sees the most. During application and removal training, the patient is usually focused on getting the lenses on and off, and they forget about case replacement, he says. "People often come into the office with their lenses in a case that looks like its been dropped in the mud before they walked in. There was even a patient that came in with his lenses in a case used in the old thermal disinfection units from the '80s," Dr. Turpin says. "That's one reason we generally recommend peroxide products as our primary lens care system. Once the neutralizing disc wears out, patients have to change their case."

A recent study in *Contact Lens & Anterior Eye* found storage cases and mobile phones of 63 contact lens-wearing university students were highly contaminated with pathogenic bacteria.⁵ The investigation found the highest level of contamination was detected in CL storage cases where 18 (52%) bacterial isolates were detected.⁵ Another study of 2,267 patients that looked at contact lenses and infectious keratitis reported the most important risk factors in the non-daily disposable lens groups were lens cleaning

solutions and the failure to renew lens cases.² Other researchers found 47% of patients said they never replaced their lens cases or only did so if their doctor gave them a new one during their annual visit.⁶

At Dr. Brujic's practice, he has all CL patients bring in both their lens cases and solutions during the exam. "I'm still shocked at some of the conditions these patients place medical devices in. The lenses sit all day long on the patients' eyes, and at night, they store them in these horrific cases." When Dr. Brujic sees this, he throws the case in the garbage. "I tell the patient, 'you won't be using that case anymore, and make sure you clean or replace it every three months.'"

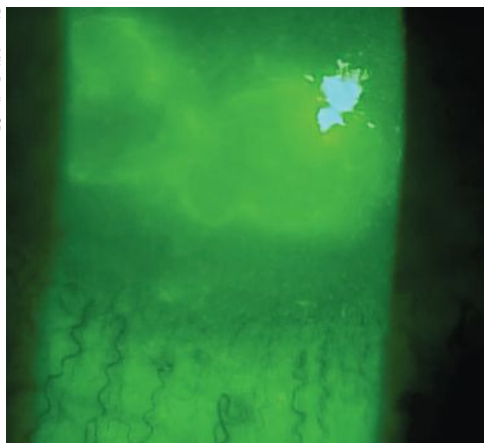
**PROBLEM #3: TERRIFYING
TALES OF SOLUTIONS**

Contact lens solutions are another real-world issue, and this is heightened if patients opt for generic products not recommended by their doctor.

CL solution sensitivity can be problematic for some patients, and it's hard to pinpoint and treat the problem if the person is switching between solutions, especially with some of the generic ones, Dr. Narayan says. The biggest danger is saline solution and patients confusing it with a multipurpose solution, she adds.

FIVE REAL-WORLD CONTACT LENS CARE PROBLEMS

Photo: Mike Brujic, OD



Infectious ulcers such as this one are a possible complication for patients who don't replace their contact lens cases in a timely manner.

"I've seen patients with cases of preventable microbial keratitis because they were using a plain saline that they thought was a cleaning/disinfection solution. If appropriate, I try to recommend two brands of specific contact lens solutions that would work for them and their lenses. I specify two because that way if the store doesn't have one, or if it's too expensive, they can get the other option rather than a generic or use saline or water," she says.

Generic or "cheap" solutions aren't inherently problematic, but issues can certainly arise, Dr. Turpin adds. If a patient is solely concerned with cost, they will often pick up the first bottle that says it can be used with contacts, which is often just saline solution. "This is always why we ask for specific brands of solution so we can confirm they are using something that keeps the nasty bugs away," Dr. Turpin says.

With generics, problems usually crop up suddenly because these brands will often alter formulation without changing any of the labeling, he adds. "A patient may be using a generic successfully for a number of years and suddenly have a reaction to it. For this reason,

I recommend name brand multipurpose solutions to ensure product consistency," Dr. Turpin says.

The most common issue Dr. Fischer encounters with generic multipurpose solutions is solution toxicity resulting in fine, diffuse punctate keratitis. "In the same brand of generic solution, additives and preservatives can change from one month to another, so if a patient has a sensitivity to one of the ingredients, it is impossible to always avoid it."

For patients who are symptomatic and have signs of an allergic reaction, Dr. Turpin will suggest trying a different solution or switching to a daily disposable lens. "We tend to pitch dailies initially because it removes a variable. We don't have to guess at which solution to try next. We just get rid of solutions all together. That said, if patients are resistant to move into a daily modality, we always recommend a peroxide solution first if they are currently using a multipurpose."

If a patient is using peroxide, and Dr. Turpin suspects it is causing a problem—high plus or minus patients may not have full neutralization of the peroxide due to lens thickness and experience stinging from the remaining peroxide—he recommends sticking to a name brand multipurpose solution.

Dr. Narayan routinely recommends hydrogen peroxide solutions, which she says are a great alternative, especially if someone has a history of solution sensitivity. Those with allergies and dry eye can really benefit, she adds. The system also seems to help deep clean lenses for those with a history of contact lens build-up and deposits. For peroxide solutions, it's important to educate patients on the appropriate length

of soak time, never rinsing with the solution directly and replacing the case as recommended, she says. "I haven't experienced any patient having a complication with a peroxide solution if the usage instructions are followed properly."

However, Crystal Brimer, OD, owner of Focus Eye Care and creator of The Dry Eye Institute in Wilmington, NC, still sees patients who've used peroxide-based cleansers directly on the eye or before lens insertion, which has the potential to cause significant corneal toxicity and keratitis. "We see both corneal staining and infiltrates that may or may not be induced partly from CL solution. I immediately ask what they're using and change it in those cases, and more so switch them to daily disposables and avoid the cleaning regimen altogether," she says.

Another solution issue: patients will often "hoard" supplies, even after the expiration date, Dr. Brujic says. Since he asks his CL patients to bring in their solutions during the evaluation, if he sees any expired bottles, he'll throw them away. "I tell the patient why I am throwing it away and explain why I make a specific suggestion for a solution. Sometimes, it's as simple as saying, 'The contact lenses you're wearing are the highest level of lenses available and this solution works best with them.'"

PROBLEM #4: THE NON-RUBBERS

For patients in reusable lens modalities, few rub their lenses prior to placing them in their case for overnight storage, Dr. Fischer says.

One study found compliance rates in patients who used CL disinfection systems that require rinsing and rubbing were 45% and 69%, respectively, despite the resultant increased risk of biofilms and pathogens,

which can cause contact lens-related dry eye.⁷

Lens deposits from non-rubbing are another issue Dr. Turpin sees in patients who are non-compliant in their lens care. “It is not necessarily a solution issue itself, just a simple misunderstanding in the handling process. Once we remind patients that mechanically rubbing lenses is the best defense, the problem usually resolves quickly,” he says.

To correct handling issues, Dr. Turpin observes patients’ insertion and removal routines in-office, “without trying to be obvious or overbearing for patients to give us a true representation of how they handle their lenses.” He then makes notes of issues and reviews any useful improvements casually at the end of the visit to avoid any sense of accusation or disapproval, he says. “More often than not, compliance is improved at their next visit,” Dr. Turpin says.

PROBLEM #5: THE TOPPING-OFFERS & OTHER SUSPECTS

Many age-old problems are still around, Dr. Brimer says. “But perhaps we hear less about them because the percentage of daily disposable wearers has increased.” Patients still store their lenses without any rubbing or cleaning, and many top off their solution instead of changing it, or don’t even bother to top off. Added to that, some still extend the wearing cycle beyond the indications for their lens modality, she explains.

Some of these bad habits have actually increased over the years as contact lens technology and materials have improved, Dr. Narayan says. Many lenses are quite comfortable, so patients think they don’t need to clean them, it’s okay to stretch the replacement or even sleep in the lenses as long as they still feel fine, she adds.

Prevention always circles back to patient education, for old and new wearers alike. “Don’t assume that a patient is taking proper care of their lenses just because they have been wearing contact lenses for years.

Those patients can have some of the worst habits, especially if nothing bad has happened to them. I always make sure to emphasize that nothing bad has happened yet and that they need to practice appropriate contact lens care if they want to continue a lifetime of healthy eyes and good vision,” Dr. Narayan says.

Another tactic Dr. Brujic uses is to remind patients that the subtle symptoms they are complaining about may be due to their non-compliant habits.

“One of the worst things a patient can do is replace their lenses when they feel like they need to be replaced, because at that point, there are often chronic issues occurring that are getting to the point of feeling different to the patient, and that’s a problem because it may be difficult to revert many of those changes,” Dr. Brujic says.

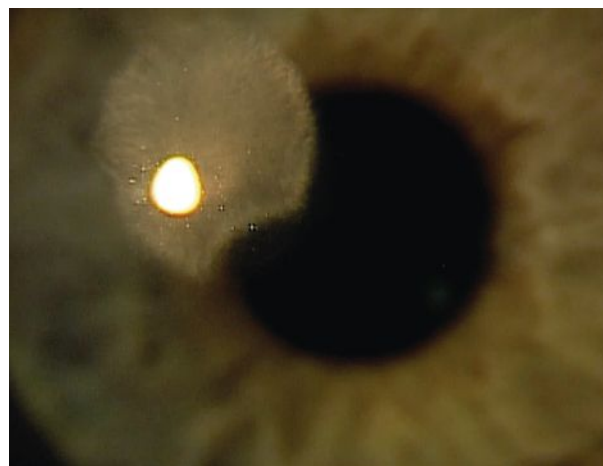
During an exam, if Dr. Brujic notices any signs that indicate contact lens abuse, he’ll take a picture of the findings with anterior segment photography and show it to the patient.

“This seems to hit home with most patients, and they generally will start curbing some of their poor hygiene habits.”

In addition to making sure new and existing contact lens patients are following proper care procedures, clinicians shouldn’t overlook those who have avoid-

ed lenses because of the perceived hassle or danger, Dr. Narayan suggests. “Now more than ever, contact lenses are a great option for a majority of patients,” she says. “With new technology and a widened range of parameters, especially in daily lenses, patients should be aware that with proper care, risks are minimized and they can enjoy healthy contact lens wear for years to come.” [hcccl](#)

1. Healthy contact lens behaviors communicated by eye care providers and recalled by patients—United States, 2018. *MMWR Morb Mortal Wkly Rep.* 2019;68(32):693-97.
2. Sauer A, Greth M, Letsch J, et al. Contact lenses and infectious keratitis: from a case-control study to a computation of the risk for wearers. *Cornea.* January 27, 2020. [Epub ahead of print].
3. Fonn D, Jones L. Hand hygiene is linked to microbial keratitis and corneal inflammatory events. *Cont Lens Anterior Eye.* 2019;42(2):132-35.
4. Carnt N, Hoffman JJ, Verma S, et al. *Acanthamoeba* keratitis: confirmation of the UK outbreak and a prospective case-control study identifying contributing risk factors. *Br J Ophthalmol.* 2018;102(12):1621-28.
5. Waleed AM, Lua’i AI, Wisam S, Sana J. Antimicrobial susceptibility of bacterial isolates from the conjunctiva, storage cases and mobile phones of university students using contact lenses. *Cont Lens Anterior Eye.* November 10, 2019. [Epub ahead of print].
6. Robertson DM, Cavanagh HD. Non-compliance with contact lens wear and care practices: a comparative analysis. *Optom Vis Sci.* 2011;88(12):1402-8.
7. Ramamoorthy P, Nichols JJ. Compliance factors associated with contact lens-related dry eye. *Eye Contact Lens.* 2014;40(1):17-22.



While many CL-related complications can be treated, some could lead to lasting visual effects, such as this stromal scar from a previous ulcer.

Photo: Mile Brujic, OD

Managing Presbyopia With Sclerals

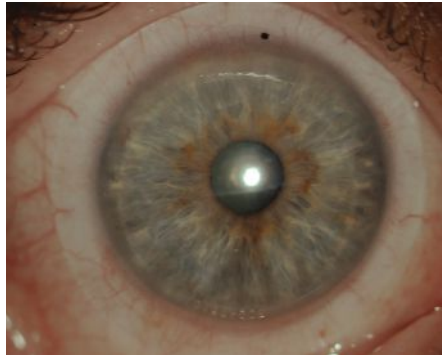
With this patient population, it is vital to manage expectations.

Gone are the days of reading glasses as your first, last and only option for presbyopia. Whether your scleral lens patient has a regular or irregular cornea, you can present the option of multifocal optics more confidently than ever before. Laboratories are offering simultaneous multifocal optics in their scleral designs, and the ability to customize them contributes to their success. Today, you can change add power or zone size and decenter the optics in the lens. A methodical approach to patient education and fitting can improve your success when offering these lenses to patients.

MANAGE EXPECTATIONS

With multifocal lenses, the visual outcome can hinge on a patient's expectations of what is considered successful completion of the fit. A patient's visual demands are going to largely determine their definition of success. Before you offer a multifocal to your scleral lens patient, a detailed case history will allow you to determine their near vision demands, daily tasks and work environment. Also, gauge their potential for dissatisfaction with less than perfect vision based on their personality and lens wear history.

For regular cornea patients who demand the highest quality vision, consider whether a translating gas permeable (GP) lens may be an option instead of a scleral lens. Simultaneous vision optics are really the only option with scleral and hybrid lenses because the lenses do not



This multifocal scleral was ordered after the single vision lens was fit successfully and best distance acuity achieved.

move or translate on-eye.¹ While this effect can contribute to stability, the optics must be centered properly over the visual axis for success. In irregular cornea patients who have reduced distance acuity, wearing glasses over their contact lenses may provide the best near vision.

The cost of a multifocal scleral may also be a deciding factor for some patients. Educate them that the cost may be similar to a daily disposable soft multifocal lens. For patients who are not willing to make the investment, you can consider a monovision or modified monovision scleral lens option or a monthly/biweekly multifocal soft contact lens. Demonstrating the monovision experience in-office can be useful for these patients. Keep in mind that patients may still need to supplement with reading glasses, so discuss this possibility upfront to reduce disappointment later.

Manufacturers recommend achieving a satisfactory fit (central clearance, limbal vault, edge alignment, patient vision and comfort) with a single-vision product and

having successful follow-up prior to adding multifocal optics. This can take up to four or more visits, depending on the cornea, the complexity of the fit and the experience of the fitter.² The addition of multifocal optics to the lens design may add another visit or two to achieve success.

SPECIAL FEATURES

When fitting multifocal sclerals, focus on two features:

Decentered optics. Large-diameter scleral lenses often decenter and can present a challenge to the practitioner. Lenses with excessive central vault also tend to decenter.³

One study showed that it is more common for a lens to decenter than to properly center.⁴ The lens tends to follow the contours of the sclera, positioning in the opposite direction of the patient's line of sight. Adding simultaneous vision optics in a decentered lens can cause issues with distance acuity, near acuity or both. Studies suggest visual improvement when soft lens optics are decentered (and over the line of sight), and that improvement is the impetus for decentered optics in scleral designs.^{5,6} Some fitting sets include lens markings that help determine the appropriate angle and offset amount for the near zone, while other sets use a standard design you can modify.

Variable zones. Consider whether changes to the near zone size can improve your results with multifocal lenses. Most designs on the market today have a center-near zone. Assess the patient's pupil size, as a smaller pupil may experience

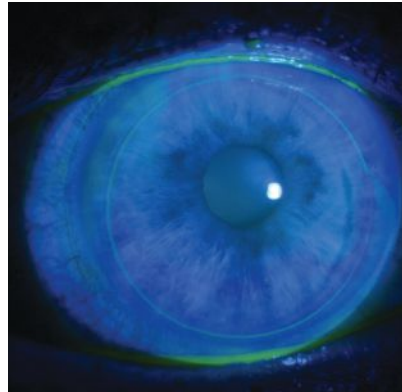


difficulties in bright light since more of the near zone is being viewed through the pupil. A larger pupil may have difficulty using the near zone at all if the pupil does not constrict enough or the light is dim. The multiple zones of scleral lens power require the proper alignment to deliver light to the retina and provide good near, intermediate and distance vision simultaneously. Having a variable near zone option allows for more flexibility to reach the patient's visual goals if the acuity is at a suboptimal level despite proper lens centration.

CASE ONE

A 67-year-old Caucasian male presented with complaints of discomfort and blur at near with his habitual multifocal hybrid lenses. As a longstanding patient, we were aware of his Type A personality and particular visual demands. We spent extensive time detailing realistic expectations with multifocal lenses, including a range of refit options—modifying the current hybrid lens design, switching to a GP design or attempting a scleral multifocal design. The patient insisted on trying the multifocal scleral. So, he was fit in a Zen RC (Bausch + Lomb) initially with the later addition of multifocal optics (Zen Multifocal) after the single vision lens was fit successfully and best distance acuity achieved.

We reduced the add and included a smaller near zone to the design of the Zen RC for the dominant eye. The axis was shifted OU to account for lens rotation, and the final lens allowed the patient to achieve 20/20



Markings on some scleral lens fitting sets can assist you in evaluating lens zones and centration.

vision OU at near. Adding Hydra-PEG (Tangible Science) to each lens ensured optimal comfort, given the entering complaint of discomfort with his habitual hybrid lenses.

CASE TWO

A 47-year-old Caucasian female presented complaining of blur, haloes and photophobia OS related to corneal scarring secondary to herpes zoster viral infection. She had been wearing multifocal soft lenses for the last three years with a best-corrected visual acuity of 20/20 OD, 20/30 OS and J3 OU at near. The patient was refit into a Zen Multifocal OS while continuing wear of the soft multifocal lens OD. Upon dispense of her new lens OS, vision was 20/20 OD, 20/25 OS and J2 OU at near. She was satisfied with her overall vision improvement at both distance and near but still wished to have sharper distance vision OS.

In cases of a distance vision complaint, the laboratory recommends removal of the near zone decen-

tration option. Theoretically, this should sharpen the distance vision without a substantial loss in near acuity, as the near optics are no longer in the patient's visual axis. With this small adjustment incorporated, the patient was thrilled with both her distance and near vision.

There are several different ways to approach troubleshooting when a distance or near complaint exists with a multifocal scleral lens. Much of your decision-making will depend on the lens design and the fitting guide. A quick call to the laboratory consultation department can also point you in the right direction. We find it especially useful in tough cases to consider lens designs that have special features such as decentered optics and/or custom near zone sizes. Your presbyopic patients often have the disposable income to invest in these technologies, and they will surely appreciate your dedication to their visual needs. [RCCU](#)

1. van der Worp E, Bornman D, Ferreira DL, et al. Modern scleral contact lenses: a review. *Cont Lens Anterior Eye*. 2014;37(4):240-50.
2. Macedo-de-Araújo RJ, van der Worp E, & González-Méijome JM. Practitioner learning curve in fitting scleral lenses in irregular and regular corneas using a fitting trial. *BioMed Res Int*. 2019;2019;1-11.
3. van der Worp E. A Guide to Scleral Lens Fitting, Version 2.0. Forest Grove, OR: Pacific University; 2015. Available: commons.pacificu.edu/mono/10/. Accessed February 5, 2020.
4. Ramdass S, Rosen C, Norman C, Buckingham R. Clinical analysis of scleral lenses on regular corneas. Presentation at: Global Specialty Lens Symposium. Las Vegas, NV. January 2016.
5. Brujic M. The importance of optical placement in multifocal lenses. Presentation at: Global Specialty Lens Symposium. Las Vegas, NV. January 2015.
6. Zheng F, Caroline P, Lampa M, et al. Visual effects of centered and decentered multifocal optics. Poster presented at the Global Specialty Lens Symposium, January 2016, Las Vegas.

When a Red Eye Prompts a Red Alert

Be on the lookout for neoplastic ocular surface lesions and know proper management techniques if you run into one.

A 52-year-old black male was referred by his pulmonary transplant team for persistent redness that had plagued his left eye for nearly two months. The patient was asymptomatic for pain, discharge, itching and vision loss.

Ocular history was significant for remote trauma of the right eye nearly 10 years prior, which had resulted in globe rupture and subsequent enucleation. He presented for his annual exams initially but was lost to follow-up for five years. Medical history was significant for pulmonary fibrosis that led to a double lung transplant four years ago. He was taking chronic tacrolimus and low-dose prednisone.

On examination, the right lids and visible conjunctiva appeared normal, and the prosthetic was in a good position. The patient refused prosthesis removal to view the remainder of the conjunctiva and ensure no orbital implant exposure.

In the left eye, vision was 20/20 and intraocular pressure was 17mm Hg. Pupillary function and extraocular motilities were normal. The posterior segment was also unremarkable. On slit lamp exam, there were scattered, thickened leukoplakic lesions over the nasal and inferior bulbar conjunctiva with attendant moderate injection. Near the limbus, the lesions became more gelatinous in appearance and involved nearly six clock hours, from 6:00 to 12:00. There were flat, opalescent lesions peripherally with fimbriated extension onto the cornea, which stained positively with rose bengal.

The concern for ocular surface squamous neoplasia (OSSN) prompted further questioning. The patient

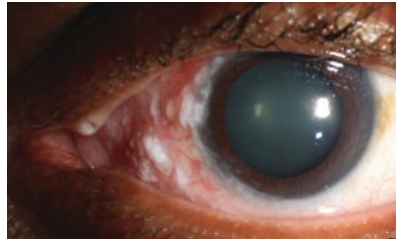


Fig. 1. Slit lamp photo of the ocular surface lesion involving the nasal conjunctiva and limbus.

was immunosuppressed but also reported a history of significant UV exposure after living in southern Florida his entire life. He denied any history of skin cancer, human immunodeficiency virus or cutaneous human papillomavirus.¹

Imaging helps determine lesion progression or therapeutic response in cases of suspected neoplasm. Slit lamp photography and ultra-high-res OCT (UHR-OCT) shed light on baseline findings, including a diffusely thickened and hyper-reflective epithelium with an abrupt transition zone consistent with OSSN (*Figures 1, 2 and 3*).

The patient was referred to an anterior segment surgeon who specializes in ocular surface tumors. He was prescribed 5-fluorouracil (5-FU) QID for one week and advised to then take three weeks off treatment. It was expected that he would need eight one-month cycles of treatment. Unfortunately, at his six-week follow up, he had not yet obtained the topical chemotherapeutic agent and his lesion had progressed (*Figure 4*).

OCULAR SURFACE LESIONS

Ocular surface lesions can vary widely in presentation and morphology. When evaluating any conjunctival or corneal lesion, our list of potential di-

agnoses should remain broad initially. Common lesions include pinguecula, pterygium, nevus, papilloma and pyogenic granuloma. When we begin to suspect neoplastic cells, we should become familiar with OSSN.

OSSN lesions are associated with a thickened epithelium near the limbus and may possess certain qualities, such as “feeder” vessels, local injection and overlying keratinization. Compared to conjunctival intraepithelial neoplasia (CIN), the term OSSN may be more favorable clinically due to our inability to assess the lesion’s depth and define it by its extension without an invasive biopsy. For example, if a neoplasia is contained within the epithelium and has not penetrated the basement membrane, it is termed CIN. Full-thickness epithelial involvement with significant cellular atypia on histopathology but an intact basement membrane is considered squamous carcinoma *in situ*. If the basement membrane is not intact and there is invasion of underlying tissue, it is considered invasive squamous cell carcinoma.

DIAGNOSIS

Differentiation of lesions may include the use of clinically available dyes,

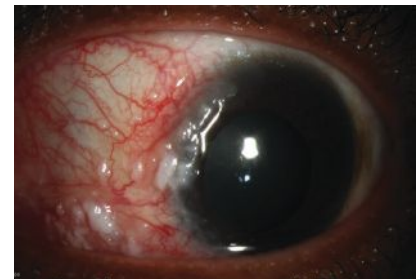



Fig. 2. Gelatinous and leukoplakic features of the lesion, with attendant vascular engorgement.



such as rose bengal, methylene blue and toluidine blue. Each dye will stain devitalized or degenerated epithelial cells, which are commonly seen in epithelial neoplasms. The dye uptake is not specific to neoplasms, however, and may be seen in some benign lesions or severe dry eye syndrome.²

In recent years, UHR-OCT has garnered attention as a noninvasive, *in vivo* imaging technique for ocular surface neoplasms. It is a specially designed anterior segment OCT instrument with a resolution of 3µm that can reveal abnormal characteristics. In cases of OSSN, UHR-OCT shows a thickened, highly hyper-reflective epithelium (>120µm) that abruptly transitions to a normal epithelium.^{3,4}

Pterygia imaging demonstrates a normal to mildly thickened epithelium with moderate hyper-reflectivity and a hyper-reflective fibrillary layer under the conjunctival or corneal epithelium. An amelanotic melanoma is associated with a normal to slightly thick epithelium over a significantly hyper-reflective subepithelial lesion with posterior shadowing.^{5,6} Though UHR-OCT is not adapted for mainstream use, there are commercially available instruments with resolutions of 5µm to 7µm that may provide diagnostic data to help differentiate lesions.⁵

Surgical excision and histopatho-

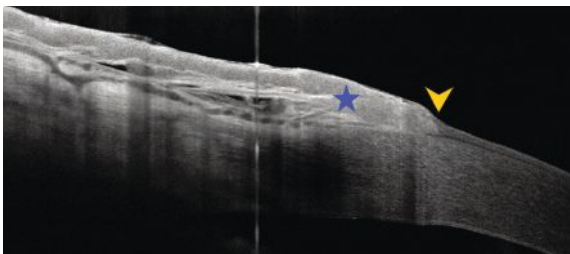


Fig. 3. UHR-OCT captured the thickened, hyper-reflective epithelium (star) and the abrupt reflectivity change (arrow), both of which are consistent with OSSN.

logic evaluation remain useful in the diagnosis of suspicious lesions. Biopsies carry inherent risks of bleeding, scarring, incomplete excision, recurrence, further seeding of neoplastic cells, limbal stem cell deficiency and inadequate sampling in cases of incisional biopsy. Excisional biopsy of a suspected neoplastic lesion uses a “no-touch” technique, in which conjunctival lesions are completely excised with 3mm to 4mm margins and cryotherapy is applied to the edges of excision.⁷ Absolute alcohol is often applied, and an amniotic membrane may also be used.

TREATMENT

OSSN treatment has vastly changed over the last 15 to 20 years. While excisional biopsy is still used for ocular surface tumors, topical chemotherapy has increased in popularity due to its less invasive nature, reduced complication rate and ability to treat the entire surface, including areas of subclinical disease that could lead to recurrence. The three most commonly used topical agents are interferon alpha-2b (IFN), 5-FU and mitomycin C (MMC).^{5,8} Each is efficacious, but there are no randomized controlled trials to compare them directly.

MMC has the highest reported complication rates of epitheliopathy, redness, keratitis, limbal stem cell deficiency and punctal stenosis. Punctal plugs must be used with MMC. While 5-FU’s side effects are similar to MMC, they’re also less profound. IFN is often the treatment of choice due to its improved

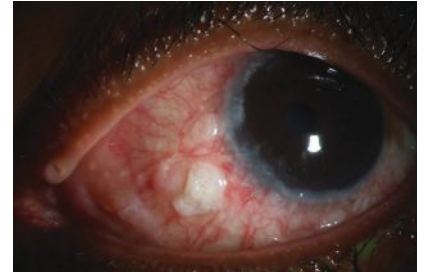


Fig. 4. Ten weeks later, the lesion had slightly progressed, as the patient had not obtained his medication.

tolerability and low side effect profile but is often the most costly of the three medications.

In our patient, the clinical suspicion for OSSN was supported by UHR-OCT. This “optical biopsy” can aid in both initial diagnosis and continued management of ocular surface lesions. We hope that our patient responds positively to topical therapy and will follow him on a regular basis with repeat UHR-OCT imaging to monitor for improvement. **RCCL**

1. Carreira H, Coutinho F, Carrilho C, et al. HIV and HPV infections and ocular surface squamous neoplasia: systematic review and meta-analysis. *Br J Cancer*. 2013;109(7):1981-8.
2. Nanji AA, Mercado C, Galor A, et al. Updates in ocular surface tumor diagnostics. *Int Ophthalmol Clin*. 2017;57(3):47-62.
3. Sepulveda R, Pe'er J, Midena E, et al. Topical chemotherapy for ocular surface squamous neoplasia: current status. *Br J Ophthalmol*. 2010;94(5):532-5.
4. Nanji AA, Sayyad FE, Karp CL. Topical chemotherapy for ocular surface squamous neoplasia. *Curr Opin Ophthalmol*. 2013;24(4):336-42.
5. Nanji AA, Sayyad FE, Galor A, et al. High-resolution optical coherence tomography as an adjunctive tool in the diagnosis of corneal and conjunctival pathology. *Ocul Surf*. 2015;13(3):226-35.
6. Shields JA, Shields CL, De Potter P. Surgical management of conjunctival tumors: the 1994 Lynn B. McMahan lecture. *Arch Ophthalmol*. 1997;115(6):808-15.
7. Shousha MA, Karp CL, Canto AP, et al. Diagnosis of ocular surface lesions using ultra-high-resolution optical coherence tomography. *Ophthalmology*. 2013;120(5):883-91.
8. Kieval JZ, Karp CL, Abou Shousha M, et al. Ultra-high resolution optical coherence tomography for differentiation of ocular surface squamous neoplasia and pterygia. *Ophthalmology*. 2012;119(3):481-6.



Early Adopter, Chronic Sufferer

A 1990s LASIK patient's troubled course continues nearly 30 years later.

A 53-year-old female with a history of bilateral myopic LASIK, performed in 1992, was referred with epithelial ingrowth OU. She previously underwent enhancement procedures in each eye (radial keratotomy OS, astigmatic keratotomy OU) and had a flap lift for epi ingrowth OD 10 years prior. She complained of decreased vision (OD>OS) but denied pain, discomfort or irritation.

Post-LASIK epithelial ingrowth is a rare complication characterized by the ingrowth of corneal epithelium at the interface between the flap and stromal bed. It has been reported in up to 3.9% of patients after initial surgery but up to 20% if the flap is lifted for retreatment.¹ While most cases are self-limited, surgical treatment is required in 0.92% to 3.2%

of patients when cells extend into the visual axis and reduce vision, induce astigmatism and/or cause keratolysis or foreign-body sensation.¹

Risk factors include type of refractive correction (hyperopic>myopic), surgical instrumentation (microkeratome>femtosecond), retreatment, location of flap hinge, corneal epithelial injury, flap dislocation, type 1 diabetes, epithelial basement membrane dystrophy and possibly increasing age.¹

Ingrowth is staged into four categories. Stage 1 is non-progressive; one to two cells within 2mm of the flap edge with a well-delineated white line on the advancing edge. Stage 2 has thicker cell growth with no demarcation line; the leading edge of the flap is rolled or grey with no melt. Stage 3 has thick ingrowth with geographic

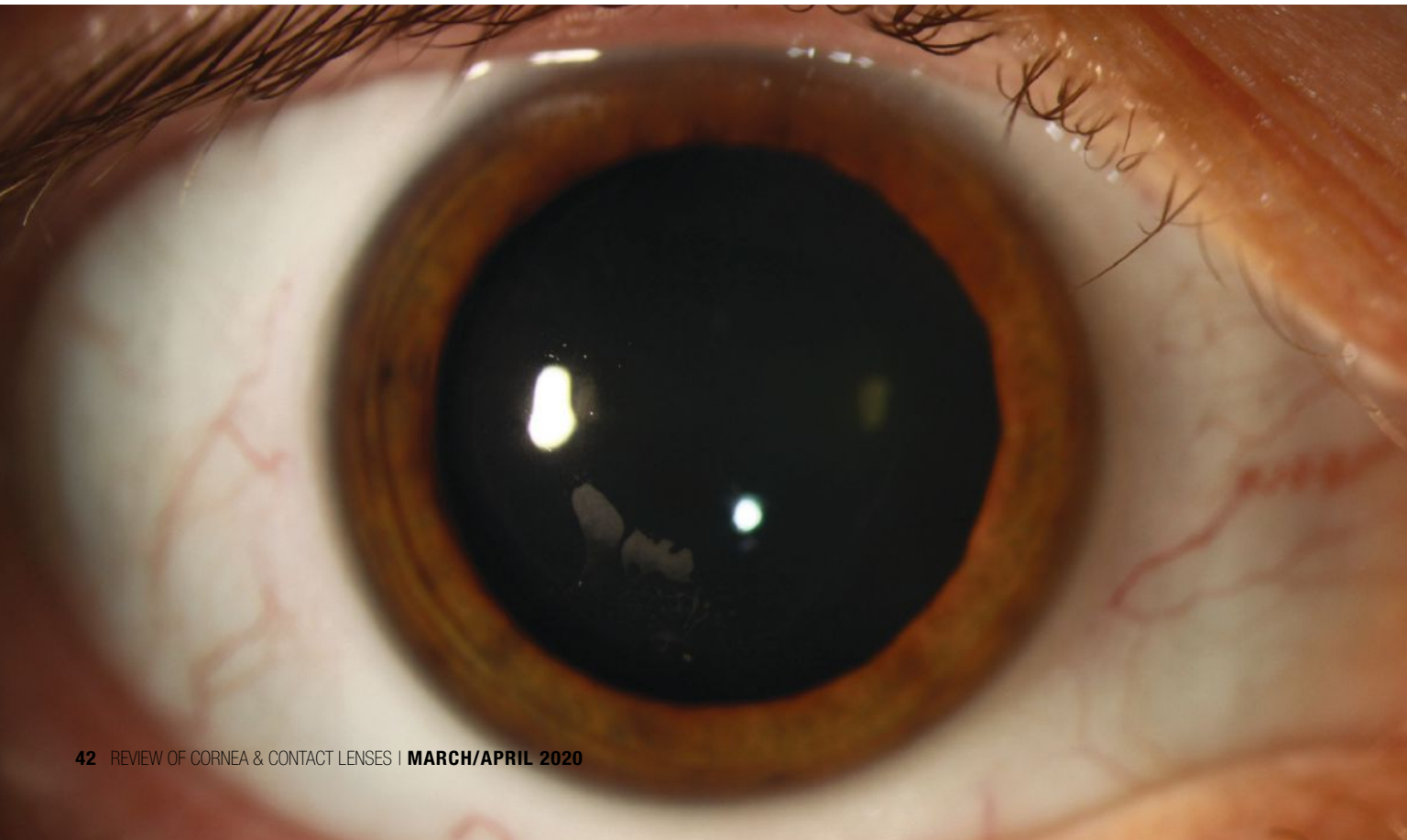areas of necrotic cells more than 2mm from the flap edge, with no demarcation line; the flap is rolled with a thickened, whitish-grey appearance. Stage 4 shows aggressive growth and strands of epithelial cells near the visual axis. As there is concern for flap melt, it requires urgent treatment.²

The most common intervention is mechanical debridement of the flap-stromal interface. Amniotic membrane graft may be used in cases associated with flap injury or melting.

Our patient was diagnosed with Stage 1 epithelial ingrowth and surgical treatment was deferred. She was referred for contact lens fitting to help with her blurred vision. **RCCL**


1. Ting DSJ, Srinivasan S, Danjoux JP. Epithelial ingrowth following LASIK: prevalence, risk factors, management and visual outcomes. *BMJ Ophthalmol.* 2018 Mar 29;3(1).

2. Yesilirmak N, Chhadva P, Cabot F, et al. Post-LASIK epithelial ingrowth: treatment, recurrence and long-term results. *Cornea.* 2018;37(12):517-21.



Redefine

what's possible



Take your
patients and practice
further with VTI innovation

For those who've experienced it, you know NaturalVue® Multifocal contact lenses redefine vision for presbyopes. This year, we're going beyond our flagship Neurofocus Optics® to unveil new optical designs, comfort technologies and more.

See what's possible at vtivision.com

NEW Cornea Scleral Profile Scan for Pentacam®

Beyond the Cornea!



The new Pentacam® CSP Report measures,
where others are just estimating

Measure beyond past boundaries when fitting scleral lenses. The new CSP Report creates 250 images within the measuring process. The tear film independent measurement with automatic release allows coverage up to 18 mm with the same fixing point.

Visit our booth #MS4539 during Vision Expo East.

Toll free 888-519-5375     Follow us!
ads@oculususa.com www.pentacam.com

 **125 YEARS**
OCULUS®