


RCCL[®]

REVIEW OF CORNEA
& CONTACT LENSES

SEPTEMBER/OCTOBER 2019

SUCCEED AT FITTING SCLERALS



- **Handle Sclerals with Care**, PAGE 8
- **Choosing a Scleral Fitting Set**, PAGE 10
- **Getting Started with Scleral Lenses**, PAGE 12
- **Navigating the Scleral Lens Maze**, PAGE 16
- **Consider Sclerals for Dry Eye**, PAGE 22
- **Multifocal Optics Expand the Reach of Scleral Lenses**, PAGE 26
- **Fitting Sclerals Around Ocular Surface Obstacles**, PAGE 38
- **Success Starts With Communication**, PAGE 40

ALSO: USING SPECULAR MICROSCOPY • LISCH CORNEAL DYSTROPHY • IRIS MELANOMA

brighten each day.
prescribe a high-oxygen lens
with a low-oxygen price.



clariti® 1 day

Give your patients a fresh perspective with clariti® 1 day, a full family of breathable, affordable silicone hydrogel lenses. [prescribecleariti.com](https://www.prescribecleariti.com)

contents

Review of Cornea & Contact Lenses | September/October 2019



departments

- 4 News Review**
CXL protocols; accommodative lag; inflammation and CLs; *Demodex*
- 8 My Perspective**
Handle Sclerals With Care
By Joseph P. Shovlin, OD
- 10 The GP Experts**
Dead Set on Sclerals
By Robert Ensley, OD, and Heidi Miller, OD
- 36 Corneal Consult**
Keep An Eye Out
By Aaron Bronner, OD
- 38 Fitting Challenges**
The Work-around
By Cory Collier, OD
- 40 Practice Progress**
Success Starts With Communication
By Mile Brujic, OD, and Jason R. Miller, OD, MBA
- 42 The Big Picture**
A Dark Diagnosis
By Christine W. Sindt, OD

features

12

Getting Started with Scleral Lenses

Adding innovative technologies and services to your practice can seem daunting, but it doesn't have to be.

By Jeffrey Sterling, OD

16

Navigating the Scleral Lens Maze

Here's how to avoid these common mistakes and complications and work through them when they occur.

By Emily Korszen, OD

22

Consider Sclerals For Dry Eye

This treatment option may require more care but provides patients with relief.

By Whitney Hauser, OD

26

Multifocal Optics Expand the Reach of Scleral Lenses

This modality gives presbyopic patients the break they've been looking for. Follow this guide for the best results.

By John Gelles, OD, Melissa Barnett, OD, and Jason Jedlicka, OD

30

CE: What Specular Microscopy Reveals About Your Patients



Visualizing the corneal endothelium aids in the diagnosis and management of myriad diseases.

By Daniel Epshtein, OD

IN BRIEF

■ Small-incision lenticule extraction (SMILE) either held its own or resulted in better outcomes compared with other corneal refractive surgeries. Canadian researchers reviewed 22 investigations conducted from 2005 to 2019 that compared SMILE and other refractive surgeries on adult myopia patients.

Corneal biomechanical strength was preserved significantly better after SMILE than femtosecond laser-assisted *in situ* keratomileusis (FS-LASIK) and LASIK, but was comparable to femtosecond lenticule extraction (FLEX) and the photorefractive keratectomy (PRK)/laser-assisted subepithelial keratectomy (LASEK) group.

Guo H, Hosseini-Moghaddam SM, Hodge W. Corneal biomechanical properties after SMILE versus FLEX, LASIK, LASEK, or PRK: a systematic review and meta-analysis. *BMC Ophthalmol*. 2019;19(1):167.

■ The **mean central corneal thickness (CCT) and endothelial cell density (ECD) values in obstructive sleep apnea (OSA) patients were lower** than those of control eyes in a recent study. To determine the corneal parameters in patients with OSA, the study evaluated the relationship between the severity of OSA, minimum peripheral capillary oxygen saturation and corneal morphological characteristics in 74 eyes of patients with OSA and 40 control eyes. The researchers found a significant negative correlation between CCT and ECD and a weak positive correlation for minimum peripheral capillary oxygen saturation.

Bojarun A, Vieversyte Z, Jaruseviciene R, et al. Effect of obstructive sleep apnea on corneal morphological characteristics. *Cornea*. July 23, 2019. [Epub ahead of print].

■ Most **patients who choose to wear cosmetic colored contact lenses** do just fine, but one small design detail may be surprisingly important: the location of the pigments. Researchers explained **if the pigment was located at the top or bottom surface of the lens, pigment particles had direct contact with the conjunctiva or cornea**, but designs with the pigment enclosed in the lens matrix eliminate exposure to the ocular surface. **Surface pigments may create a rough lens surface, which can also increase microbial adherence.** Investigators found the majority of the cosmetic contact lenses analyzed contained the bulk of the pigment within 0.4µm of the surface or on the surface itself.

Korde V, McDow K, Rollins D, et al. Identifying pigment enclosure in cosmetic contact lenses. *Eye Contact Lens*. July 15, 2019. [Epub ahead of print].

New CXL Protocols Reviewed

Today, researchers are analyzing a variety of new corneal crosslinking (CXL) protocols with the hopes of reducing complications and improving outcomes. These two studies reveal their potential effectiveness.

PACK-CXL AND KERATITIS

Researchers in the United Kingdom performed a systematic review to examine the efficacy and safety of photoactivated chromophore for infectious keratitis corneal crosslinking (PACK-CXL) based on the current literature. Their findings demonstrated that adjuvant PACK-CXL could expedite the resolution of infectious keratitis with bacterial etiologies, and potentially fungal keratitis, by reducing the time to complete healing and the size of the infiltrate.¹

The review included 46 eligible studies (including four randomized clinical trials) with a total of 435 patients. The majority of the studies focused on either bacterial or fungal keratitis or a combination of both, with only one clinical trial including *Acanthamoeba* keratitis (three participants).

The researchers found that PACK-CXL shortened the time to complete corneal healing by seven days compared with standard antibiotic treatment alone. Also, infiltrates resolved quicker at seven days (-5.49mm²) and at 14 to 30 days (-5.27mm²).

Nevertheless, the use of PACK-CXL in *Acanthamoeba* keratitis remains elusive, with contradicting evidence from *in vitro* and clinical studies, whereas PACK-CXL is contraindicated outright in cases of viral keratitis. Researchers concluded that standardized reporting of outcome measures will enable better applicability of the evidence and allow

for easier comparison of the results across different studies.¹

CUSTOM TREATMENT

A new rapid epi-on CXL method, custom fast CXL, shows promise for treating keratoconus patients, producing a significant, rapid and lasting cone progression stoppage, astigmatism reduction and visual acuity improvement.²

This technique involves significantly less ultraviolet A radiation beam fluence, total energy and exposure time. It features no epithelial disruption, 15 minutes of corneal presoaking with a riboflavin-vitamin E TPGS solution and a 370nm ultraviolet A radiation beam centered on the most highly curved corneal region.

The study enrolled 81 patients whose refraction, spectacle-corrected distance visual acuity, Kmax and corneal hysteresis were monitored for seven years after treatment. Researchers found the average refractive cylinder magnitude was reduced by 26.1% at one month postoperatively and by 44.2% at seven years.

The investigators also reported best spectacle-corrected distance visual acuity improved post-op from one month up to 84 months.

Kmax did not increase in 98.8% of patients at seven years postoperatively, with average corneal apex flattening at one month and seven years (-2.79±1.70D and 4.00±2.40D, respectively).²

1. Ting DSJ, Henein C, Said DG, Dua HS. Photoactivated chromophore for infectious keratitis-corneal cross-linking (PACK-CXL): a systematic review and meta-analysis. *Ocul Surf*. August 8, 2019. [Epub ahead of print].

2. Caruso C, Epstein RL, Troiano P, et al. Topography and pachymetry guided, rapid epi-on corneal crosslinking for keratoconus: 7-year study results. *Cornea*. July 24, 2019. [Epub ahead of print].

11 Campus Blvd., Suite 100
Newtown Square, PA 19073
Telephone (610) 492-1000
Fax (610) 492-1049

Editorial inquiries: (610) 492-1006
Advertising inquiries: (610) 492-1011
Email: rccl@jobson.com

EDITORIAL STAFF

EDITOR-IN-CHIEF

Jack Persico jpersico@jobson.com

MANAGING EDITOR

Rebecca Hepp rhepp@jobson.com

ASSOCIATE EDITOR

Catherine Manthorp cmanthorp@jobson.com

ASSOCIATE EDITOR

Mark De Leon mdeleon@jobson.com

CLINICAL EDITOR

Joseph P. Shovlin, OD, jpshovlin@gmail.com

ASSOCIATE CLINICAL EDITOR

Christine W. Sindt, OD, christine-sindt@uiowa.edu

EXECUTIVE EDITOR

Arthur B. Epstein, OD, artepstein@artepstein.com

CONSULTING EDITOR

Milton M. Horn, OD, eyemage@mminternet.com

GRAPHIC DESIGNER

Ashley Schmouder aschmouder@jobson.com

AD PRODUCTION MANAGER

Scott Tobin stobin@jhihealth.com

BUSINESS STAFF

PUBLISHER

James Henne jhenne@jobson.com

REGIONAL SALES MANAGER

Michele Barrett mbarrett@jobson.com

REGIONAL SALES MANAGER

Michael Hoster mhoster@jobson.com

VICE PRESIDENT, OPERATIONS

Casey Foster cfoster@jobson.com

EXECUTIVE STAFF

CEO, INFORMATION SERVICES GROUP

Marc Ferrara mferrara@jhihealth.com

SENIOR VICE PRESIDENT, OPERATIONS

Jeff Levitz jlevitz@jhihealth.com

SENIOR VICE PRESIDENT,

HUMAN RESOURCES

Tammy Garcia tgarcia@jhihealth.com

VICE PRESIDENT,

CREATIVE SERVICES & PRODUCTION

Monica Tettamanzi mtettamanzi@jhihealth.com

VICE PRESIDENT, CIRCULATION

Emelda Barea ebarea@jhihealth.com

CORPORATE PRODUCTION MANAGER

John Caggiano jcaggiano@jhihealth.com

EDITORIAL REVIEW BOARD

Mark B. Abelson, MD

James V. Aquavella, MD

Edward S. Bennett, OD

Aaron Bronner, OD

Brian Chou, OD

Kenneth Daniels, OD

S. Barry Eiden, OD

Desmond Fonn, Dip Optom, M Optom

Gary Gerber, OD

Robert M. Grohe, OD

Susan Gromacki, OD

Patricia Keech, OD

Bruce Koffler, MD

Pete Kollbaum, OD, PhD

Jeffrey Charles Krohn, OD

Kenneth A. Lebow, OD

Jerry Legerton, OD

Kelly Nichols, OD

Robert Ryan, OD

Jack Schaeffer, OD

Charles B. Slonim, MD

Kirk Smick, OD

Mary Jo Stiegemeier, OD

Loretta B. Szczołka, OD

Michael A. Ward, FCLSA

Barry M. Weiner, OD

Barry Weissman, OD



Soft Lenses and Near Vision

Two recent studies explore contact lenses' role in accommodative lag and how they could resolve it:

VISUAL FATIGUE

Because soft contact lenses may affect a patient's accommodative function, researchers recently explored this association and found a larger accommodative lag, approximately 1D, and more fluctuations with soft contact lenses. High accommodative lag (more than 0.75D) and accommodative variability with near work are both linked to visual fatigue and, possibly, myopia.¹

The team recorded dynamic accommodative response during 30-second intervals at five different distances in 21 patients with a mean refractive error of -0.79 ± 1.39 D who wore soft contact lenses or spectacles on two different days. They conducted a second identical intervention to assess inter-session and inter-method repeatability.

They obtained larger lags of accommodation and a higher variability of accommodation at near distances with the use of soft contact lenses compared with spectacles. In fact, study participants wearing spectacles showed lags of accommodation less than 0.75D—the threshold for clinical relevance—for all five viewing distances.

Accommodative variability has a close association with visual fatigue and myopia, and clinicians should note soft contact lenses can induce more variability during near tasks than spectacles, the researchers wrote in the study.¹

LOW-ADDS HELP YOUTH

The ocular and visual symptoms associated with accommodative and

binocular vision stress have become a major problem as a result of digital eyestrain, especially in young individuals. Researchers recently discovered that using low-add soft contact lenses reduced accommodation response time, without sacrificing distance vision, in young, non-presbyopic patients.

This study included 16 participants who were evaluated with a daily disposable low-add bifocal lens. The design used a center-distance optical zone and a peripheral zone with an add power of +0.50D to support near vision.

The team measured refractive state and accommodation using an open-field autorefractor with three target vergences: -0.20D, -2.50D and -4.00D. They also assessed binocular visual acuity at high (100%) and low (40%, 20%) contrasts and reading ability.

They found that accommodative response with low-add lenses was significantly smaller than that with monofocal contact lenses at 40cm (2.50D of stimulus) and 25cm (4.00D of stimulus). The 20% contrast visual acuity at distance was significantly better with low-add lenses and second-time monofocal contact lenses compared with first-time monofocal contact lenses.²

1. Jiménez R, Redondo B, Davies LN, et al. Effects of optical correction method on the magnitude and variability of accommodative response: a test-retest study. *Optom Vis Sci.* 2019;96(8):568-78.

2. Koh S, Inoue R, Sato S, et al. Quantification of accommodative response and visual performance in non-presbyopes wearing low-add contact lenses. *Cont Lens Ant Eye.* July 19, 2019. [Epub ahead of print].

Advertiser Index

Alcon	9
Bausch + Lomb	Cover 3
CooperVision	Cover 2
Menicon	Cover 4
Oculus	19
Visioneering Technologies	7

Inflammation Risk High in Early CL Wear

A recent study investigated the association between levels of matrix metalloproteinase-9 (MMP-9), a common marker of inflammation in tears, and changes to the meibomian glands accompanying soft contact lens (CL) wear. The researchers found that the early years of CL wear are associated with increased expression of MMP-9, possibly indicating low-level inflammation during this phase of wear.

The researchers collected flush tears from three cohorts: (1) CL wearers who had worn lenses on a daily basis for different durations (short: 2 ± 1 years, moderate: 5 ± 1 years and long: 10 ± 2 years); (2) a group of previous CL wearers who had ceased wear for at least six months; and (3) healthy non-wear-

ers as a control group. From the 100 participants, the study calculated the concentration ratio of MMP-9 to its inhibitor, tissue inhibitor of metalloproteinase-1 (TIMP-1).

MMP-9 concentrations and the MMP-9:TIMP-1 ratio were significantly different between groups, while the concentration of TIMP-1 did not vary statistically between study groups. A post-hoc analysis revealed that only CL wearers with a short experience had MMP-9 concentrations that were significantly high compared with non-wearers. When comparing MMP-9:TIMP-1 ratios, the team found it was also only significantly greater in CL wearers with a short experience (about a six-fold increase) compared with non-wear-

ers, CL wearers with moderate experience and previous wearers.


The concentration of MMP-9 falling to a level that is no longer significant in the following years of CL wear compared with non-wearers suggests that some adaptation may take place. The researchers note that although the disturbance to the MMP-9 levels was not enough to cause significant changes morphologically, it is unclear what effects these have downstream. They believe that further research will reveal whether the factors together may play role in the inflammatory cascade seen in meibomian gland dysfunction.

Alghamdi W, Markoulli M, Papas E. The relationship between tear film MMP-9 and meibomian gland changes during soft contact lens wear. *Cont Lens Anterior Eye*. August 6, 2019. [Epub ahead of print].

Demodex Can Complicate Dry Eye Tests

At first test, a *Demodex* infestation could look an awful lot like dry eye. Both patients will have reduced Schirmer test scores and elevated ocular surface disease index (OSDI) rates, according to newly published research in the journal *Eye & Contact Lenses*. The presence of the lash mites is associated with the same Schirmer test and OSDI scores, as well as average age values, as patients with newly diagnosed dry eye disease.

The investigators looked at 168 eyes of 84 dry eye patients—all with Schirmer test scores less than 5mm/min wetting—between ages 40 and 68, and performed three diagnostic examinations: OSDI,



Demodex infestation and dry eye share reduced OSDI and Schirmer scores.

Schirmer test and a microscopic eyelash evaluation.

To evaluate for *Demodex*, the clinicians extracted two eyelashes from the inferior eyelids of each eye, and the sample was immediately brought to the microbiology laboratory on the slides by pouring two drops of saline.


For those whose lash evaluations exposed a *Demodex* infestation, the average Schirmer test score was 2.1mm/min, the OSDI questionnaire score was 61.82 and the mean age was approximately 55. For the patients without a *Demodex* infestation, the average Schirmer test score was 6.6mm/min, OSDI was 40.96 and the mean age was approximately 49.

Determining *Demodex* infestation as a factor in dry eye disease with multifactorial etiopathogenesis can assist in the early treatment and prevention of the progression of dry eye symptoms, the study concluded. [RCLL](#)

Ayyildiz T, Sezgin FM. The effect of ocular *Demodex* colonization on Schirmer test and OSDI scores in newly diagnosed dry eye patients. *Eye Contact Lens*. August 6, 2019. [Epub ahead of print].

Redefining vision by fusing science, art and technology designed to achieve revolutionary solutions for presbyopia, myopia and astigmatism.

NaturalVue[®] (etafilcon A) Multifocal 1 Day Contact Lenses



- Innovative Neurofocus Optics[®] Technology inspired by advanced camera optics
- One Universal Extended Depth of Focus center-distance design
- Fit like a Single Vision Sphere

See Naturally[®]

Call us today at **1-844-VTI-LENS**
(1-844-884-5367, ext. 116)
or visit **vtivision.com**



Handle Sclerals With Care

Their expanded and accelerated use may raise some concerns yet to be identified.

This issue is teeming with valuable information that may aid you in fitting scleral lenses: step-by-step approaches in the initial fitting of these lenses, avoiding mistakes and complications related to lens wear and multifocal design options.

By all measures, the recent surge in scleral lens use is nothing short of phenomenal. This uptick is easily attributed to the many advantages scleral designs offer and the new materials used for irregular corneas and severe ocular surface disease indications. In addition, success can also be attributed to practitioner education programs offered throughout the world—increasing the number of providers comfortable using these lenses.

The advantages of using scleral lenses are numerous compared with both smaller GP corneal lenses and even soft lens modalities, and include excellent lens centration, exceptional acuity and relatively good comfort. For the most part, there are only a few downsides to these lenses that primarily relate to insertion and removal difficulties, as well as a few nuisance complications such as lens fogging and reduced oxygen flux. Even the most dreaded complication attributed to contact lens wear, microbial keratitis, seems to be rare and is only cited in a few isolated case reports.

A significant concern raised with the surge in scleral lens use is the lack of long-term surveillance on safety data. Even though scleral lenses date back to the early history of contact lenses, their use throughout the past 50 years has been quite

limited until recently. So, what are the long-term complications, and will there be any yet-to-be-identified complications with expanded use? Unfortunately, we lack large registries to help answer these important questions with confidence and assure us that there will not be any unexpected findings.

LOW-RISK COMPLICATIONS

In the Scleral Lenses in Current Ophthalmic Practice (SCOPE) study, the Mayo Clinic Survey Research Center surveyed a large group of practitioners treating more than 80,000 patients to look at key information including complications found in scleral lens wearers.¹

The most commonly reported complications (462 patients) were the result of inserting or removing scleral lenses incorrectly. An additional 148 patients developed an eye problem because they used eye-care products that were not recommended by their doctors. The study noted corneal edema or swelling in 385 patients, corneal neovascularization in 238 patients and corneal infections in 70 patients while wearing scleral lenses. Also, two patients experienced graft rejection while wearing scleral lenses.¹

Overall, the study reported few complications associated with scleral lens wear, even though these lenses tend to be prescribed for individuals who have some form of ocular pathology.¹

Serious complications directly attributed to scleral lens wear appear to be exceedingly rare, and other non-sight threatening complications appear also to be relatively rare. Nevertheless, patients who

wear scleral lenses should continue to follow their eyecare provider's recommendations for lens care products and advice for inserting and removing their lenses, which seem to account for most of the complications reported to date.¹

Although the use of scleral lenses is increasing, an ever-important question remains: Should we be moving so quickly to embrace fitting these lenses on regular corneas, rather than just on irregular corneal surfaces or patients with severe ocular surface disease? We'd all like to use these lenses, especially with the introduction of new multifocal designs that makes these lenses another viable option for presbyopia. Only additional follow-up over time will elucidate any new complications related solely to scleral lens fits and fully determine the true prevalence of complications found in its wearers.

In the meantime, proceed with some heedfulness. Scleral lenses remain an important part of any comprehensive contact lens practice, and I suspect that, with time, we will continue to find these lenses to be both reasonably safe and effective.

Until the jury returns a final verdict, continue to screen properly—especially for good endothelial function—and weigh all the options carefully. As with any medical device, ongoing surveillance is wise to continue ensuring both efficacy and safety. **RCL**

1. Harthan J, Nau CB, Barr J, et al. Scleral lens prescription and management practices: The SCOPE Study. *Eye Contact Lens*. 2018;44 (Suppl 1):S228-32.

MY FIRST CHOICE FOR CONTACT LENS CARE: CLEAR CARE® PLUS



Jessica Crooker, OD

Owner, Scituate Harbor Vision Source
Scituate, MA

Dr. Crooker was compensated by Alcon for her participation in this advertorial.

As an OD, my priority is to deliver excellent outcomes for my patients. As a practice owner, I also want to take advantage of every opportunity to improve and grow my business. In my experience, helping more patients become happy contact lens wearers is a big part of practice success. My patients who wear contact lenses typically generate more revenue for the practice, on a per-patient basis, than my glasses-only wearers! This is for a

I make CLEAR CARE® PLUS my first-line lens care recommendation for monthly and weekly replacement contact lens wearers because I want them all to enjoy an outstanding lens-wearing experience^{3,6} right from the start. CLEAR CARE® PLUS, which features Alcon's unique HydraGlyde® Moisture Matrix, provides the excellent disinfection efficacy^{3,4} and exceptional comfort^{5,6} that patients need to get the most out of their lenses. This is combined with ease of use⁵ that truly simplifies the lens care routine. For patients, my message is simple: "CLEAR CARE® PLUS is easy to use,⁵ and it keeps your lenses clean and feeling like new³⁻⁶ so you can enjoy them!"

In addition to making CLEAR CARE® PLUS my first-line lens care recommendation for patients just starting out with contact lenses, I also encourage multi-purpose solution (MPS) users to switch to CLEAR CARE®

Making your lenses feel like new is easy. Just add
BUBBLES.

- WASH RINSE AND DRY YOUR HANDS**
EVERY TIME YOU HANDLE YOUR LENSES
- PLACE LENSES IN BASKETS AND RINSE FOR 5 SECONDS WITH SOLUTION**
NO RUBBING REQUIRED
- FILL THE LENS CASE TO THE LINE WITH THE SOLUTION**
- PLACE THE LENS HOLDER IN THE CASE AND TIGHTEN THE LID**
TIP: Never shake the case or store it on its side.
- SOAK FOR AT LEAST 6 HOURS TO NEUTRALIZE**
WARNING! You MUST wait a full 6 hours for the solution to neutralize. If you don't, you may hurt your eyes.
- ALWAYS STORE THE LID UPSIDE DOWN TO AVOID CONTAMINATION**
Remember to pour out your used solution.

variety of reasons, including their tendency to return for more frequent regular exams and to make additional eyewear purchases.¹ Prescribing the right contact lenses for individuals' vision and lifestyle needs is an essential part of meeting both patient and practice goals, but so is recommending lens care that is efficacious, user-friendly, and promotes comfortable lens wear.²

One recent morning, I saw two patients with different vision care histories, but the same enthusiasm for wearing contact lenses. The first patient was a graduate student in his early twenties, who, after a few years of wearing glasses, was excited about the lifestyle and appearance benefits of contact lenses. The second was a professional in her mid-thirties needing vision correction for the first time, but who had no appetite for wearing glasses. Both patients' daily lives were best suited for a monthly replacement lens, and for both patients, my lens care recommendation was simple: CLEAR CARE® PLUS.

PLUS. In short, I want to give all of my reusable contact lens wearers the chance to use CLEAR CARE® PLUS, not only because it helps them love their lenses,⁵ but also because I have seen how it improves my patients' lens care compliance.^{7,8} This is a big deal for practitioners—less time talking about compliance means more time dedicated to meeting patients' evolving vision care needs.

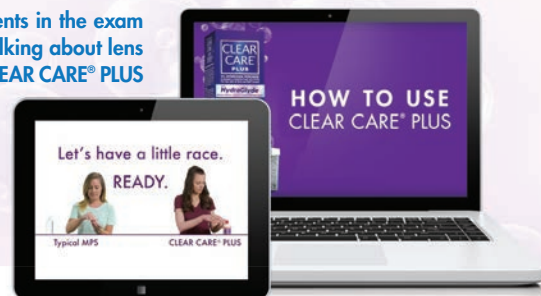In a survey of habitual MPS users who tried CLEAR CARE® PLUS for 21 days, 9 out of 10 participants agreed that they were happy with their eye care practitioner for recommending CLEAR CARE® PLUS.⁵ Patient and practice outcomes go hand-in-hand, and my experience is that more happy contact lens wearers means more referrals, more visits for eye exams, and practice growth. Making CLEAR CARE® PLUS your first-line lens care recommendation is another opportunity to set your practice apart—and to help reusable lens wearers love their lenses!

PRACTICE TIP

Ease of Use and How-To Videos in hand, office staff can reinforce my discussions with patients and help set them up for successful contact lens wear with CLEAR CARE® PLUS.

View the "How easy is it to use CLEAR CARE® PLUS?" video at <https://youtu.be/Xhok8710E7Q>

View the "CLEAR CARE® PLUS Solution & How It Works" video at https://youtu.be/mJMGPDZ_kn0



References 1. Aggregate de-identified GLIMPSE® data. Alcon data on file, 2018. 2. Lowe P. Educate patients about hydrogen peroxide solutions, reduce dropouts. *Rev Optom Bus.* November 14, 2013. 3. Gabriel MM, Bartell J, Walters R, et al. Biocidal efficacy of a new hydrogen peroxide contact lens care system against bacteria, fungi, and Acanthamoeba species. *Optom Vis Sci.* 2014;91:E-abstract 145192. 4. Gabriel MM, McAnally C, Bartell J, et al. Biocidal efficacy of a hydrogen peroxide lens care solution incorporating a novel wetting agent. *Eye & Contact Lens.* 2018;Epub ahead of print. 5. Alcon data on file, 2016. 6. Alcon data on file, 2016. 7. Guthrie S, Dumbleton K, Jones L. Contact lens compliance: Is there a relationship between care system and compliance? *Contact Lens Spectrum.* 2016;31:40-43. 8. Woods J, Srinivasan S, Jones L. Compliance with the use of hydrogen peroxide and multipurpose solution care regimens. *Contact Lens Spectrum.* In press.

Dead Set on Sclerals

Consider these options before choosing a scleral lens fitting set.

With the large array of scleral lens options, choosing “the right” scleral lens fit set can seem daunting. Common questions that eye care professionals ask prior to ordering a set are: What diameter will I need? Why is one lens set better than another? Do I need to have multiple fitting sets in order to fit specialty lenses?

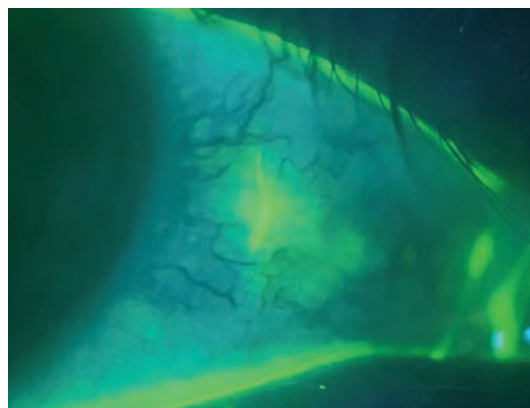
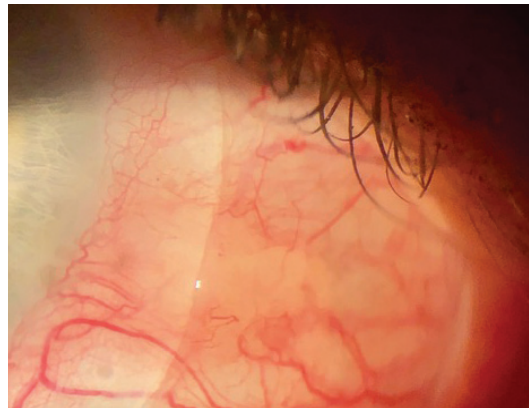
In general, it is safe to say that amongst all the lenses available, many will provide great options for your patients. There is not one perfect scleral lens fit set for all patients. Oftentimes, you will need a few different fitting sets in your office to manage a wide range of patient conditions.

Although this article is not a comprehensive list of factors to consider when purchasing a scleral lens fitting set, it does provide a starting point to find the best set for your office.

BASIC LENS DESIGNS

Start by considering what conditions you are trying to manage and how large the corneas are that you need to vault over. These two factors will help determine what initial diameter you may need.

Depending on whether you are trying to manage a patient with mild keratoconus vs. a Sjögren’s dry eye patient, you may decide to use lenses of different diameters. Often, using larger diameter lenses for dry eye patients is advisable to



Adding vaulting to a scleral lens can help with a pinguecula that interferes with proper alignment on the sclera.

provide more coverage to protect and heal the ocular surface. This also helps if you are managing a more advanced keratoconus patient who requires greater sagittal depth and distribution of weight across the conjunctival surface.

Some manufacturers offer large and small diameter sclerals, while others have set sizes to choose from. With this in mind, you may need to have a few fitting sets in order to provide adequate options for your patients’ needs.

Consider corneal shape when

deciding which lens set may be best for your patients. If your patient requires a flatter central curvature with a steeper mid-periphery, such as a post-corneal transplant or a post-radial keratotomy patient, it may be best to start with an oblate design rather than a prolate design to better contour the corneal shape and provide an equal distribution of clearance. However, not all lens designs may have the capability to customize shape from prolate to oblate or vice versa.

ADVANCED DESIGN OPTIONS

Other key items to consider when selecting a scleral lens are the add-on options that are available. Often, a more advanced adjustment is necessary to provide an adequate fit and all-day comfort. Some examples that could be beneficial include:


- **Toric peripheral landing**

curves: Allow for proper alignment-to-asymmetrical scleral shape by providing bitoric steep and flat meridians of curvature.

- **Microvault or edge vault:**

Allows vaulting over peripheral elevations, such as pinguecula, pterygia or an irregular conjunctiva, that might interfere with proper landing on the sclera. This can be helpful to eliminate unwanted injection and irritation caused by compression of blood vessels.

- **Quadrant-specific limbal and**



peripheral designs: Allow landing zone or limbal zone customization by flattening or steepening in a specified meridian.

- **Limbal clearance adjustment:**

Allows limbal clearance modification without affecting the other lens parameters.

- **Front surface toric:** Allows for correction of residual astigmatism.

- **Multifocal:** Allows eye care professionals to fit presbyopic patients who have irregular or regular corneas.

MATERIALS AND COATINGS

Materials may seem like a minor detail; however, not all companies carry the same materials. This is especially important if you want to order a higher Dk material to address corneal complications or one with Tangible Hydra-PEG (Ocular Dynamics) coating added.

Hydra-PEG is a permanent coating that can be applied to custom contact lenses. The Tangible Hydra-PEG coating is a 90% water, polyethylene glycol-based formulation incorporating two different polymers. The coating is designed to fill the microscopic pits on contact lenses and build up into a smooth, wet layer that is permanently bonded to the surface of the lens.

Hydra-PEG can be used to help extend comfortable wearing time in patients who remove and clean their lenses several times per day due to fogging or poor front surface wetting. This coating can also help prolong wear time in dry eye patients who get lens awareness or a gritty feeling after

several hours of wear. Hydra-PEG is beneficial to patients with dry eye symptoms, front-surface depositing, lens fogging and general lens discomfort.¹

By taking into account your patient's eye condition and what lens material they may need, you can help avoid having to refit them into a different lens design.

COSTS AND WARRANTIES

Although cost can be a big factor when deciding which scleral lens to choose, look at all lens features rather than fixating on pricing alone. Optometrists beginning to incorporate scleral lenses into their practice are advised to think about which features would work best for their patients. You will be able to manage patients with the best possible options in the shortest amount of time, saving money by minimizing follow ups and chair time.

When fitting specialty lenses, cost continues to be one of the greatest concerns for the doctor and the patient. What if the lens does not work out for the patient? What if we end up switching to a different lens design because the patient was unsuccessful with sclerals?

These are all valid concerns, but the great news is most companies offer 100% credit on patient cancellations. This gives eye care professionals peace of mind that if they encounter a roadblock during the fitting process, they will not be stuck with the cost of the scleral lens material. In general, most manufacturers offer a 90-day warranty with unlimited remakes during this period.

CONSULTANTS

Technical consultants are available for most contact lens manufacturers to help assist you in achieving the best fit for your patient. They are a great resource for asking questions and to help you decide which lens changes are essential for your patient. During a practitioner's first year of fitting scleral lenses, consultants will be the best resource for gaining knowledge and tips when working with their products. Consultants work with hundreds of doctors each year and have the greatest knowledge regarding common trends and troubleshooting.

Some manufacturers provide in-office training when purchasing their fitting set to assist doctors in fitting their first patients, providing them the opportunity to ask questions and learn side-by-side. This one-on-one training can be invaluable.

There are several factors to consider when selecting a scleral lens for a patient. This alone can appear overwhelming when first incorporating scleral lenses into your practice. The great news is regardless of your patient population, there are several scleral lens options from a variety of wonderful manufacturers across the country. Following these guidelines can help you build a steady foundation for sclerals in your practice and pick the best-suited fitting set for your patients. **RCCL**

1. Tangible Science. The science behind Tangible Hydra-PEG. tangiblescience.com/the-science-behind-tangible-hydra-peg/. March 16, 2018. Accessed August 6, 2019.

Getting Started with Scleral Lenses

Adding innovative technologies and services to your practice can seem daunting, but it doesn't have to be.

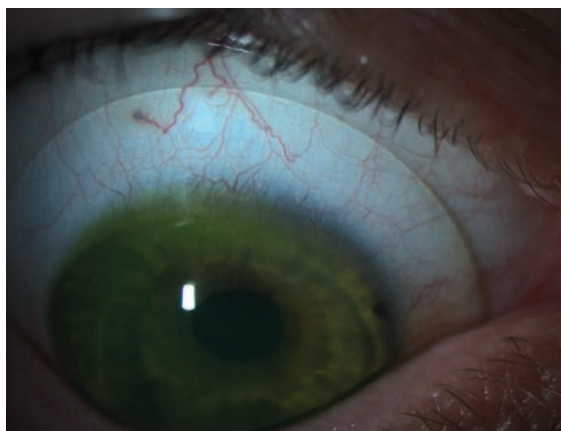
By Jeffrey Sterling, OD

As the scope of practice expands throughout the country, optometrists stay up-to-date by attending conventions and completing continuing education classes. The thought of implementing the latest optometric trends into your practice may motivate you in a grand lecture hall; however, upon returning to the scheduled routine of daily life in practice, your inspiration and motivation often dwindles away.

This does not need to be the case when it comes to fitting scleral lenses. You likely already have the knowledge and equipment needed to get started. Just look around. If you have a slit lamp, sterile saline and fluorescein, then you are ready to begin!

WHERE TO START

Now that you have made the commitment to offer this technology, you need to think about the kinds of patients you want to fit. Are you looking to fit diseased or healthy corneas? Do you want



Sclerals can provide even your most challenging patients the comfort and vision they deserve.

to offer multifocal lenses to your patients? It makes sense to start simple and move to more advanced cases as you become more confident. A good first fit would be a single vision lens on top of a normal or mildly ectatic cornea. Another good early patient is someone who can achieve good vision in a corneal lens but is not happy with their comfort.

Although there are several manufacturers of scleral lenses, you don't need to start off with multiple fitting sets. These products can be researched online, and their fitting guides are often downloadable. Many companies also offer

education and certification courses on their websites to get you familiar with their products. Do a little research to find a product and manufacturer that will fit well into your practice.

PREP THE OFFICE

The insertion and removal techniques for scleral lenses are vastly different than those for soft lenses. Most soft lens wearers can insert their lenses while standing in front of their bathroom mirror; however,

scleral lens insertion requires the patient to have their head parallel to the floor with their chin tucked to their chest. Technicians also need to get comfortable working with patients in this position.

There are a few extra items that are beneficial to have in the

ABOUT THE AUTHOR



Dr. Sterling practices at the Greenville VA Health Care Center in Greenville, NC, and is the trustee of administrative affairs for the North Carolina Optometric Society. He is a fellow of both the American Academy of Optometry and the Scleral Lens Education Society.

office before you get started. Use sterile, preservative-free solution to fill the bowl prior to insertion. Lacripure (Menicon) and ScleralFil (Bausch + Lomb) are FDA approved for scleral lenses. PuriLens Plus (PuriLens) and NaCl 0.9% are off-label but safe to use. These products can be hard to find at local retailers, so be sure to have an online option available to your patients if you are not selling them in your office.

Acquire scleral lens inserters and removers as well. It can be helpful to cut the bottom off the large inserter to make sure that it does not adhere to the lens. During the fitting, you can add fluorescein to the bowl, which can get a bit messy. A patient will appreciate an apron to protect their clothing. It is also handy to have a pen light with a blue filter to look for air bubbles immediately after insertion. Avoiding these problems will keep you from having to bring the patient back to the slit lamp after inserting each lens. Once you are ready to look at the lens in the slit lamp, use a Wratten filter to assess the fluorescein more efficiently.

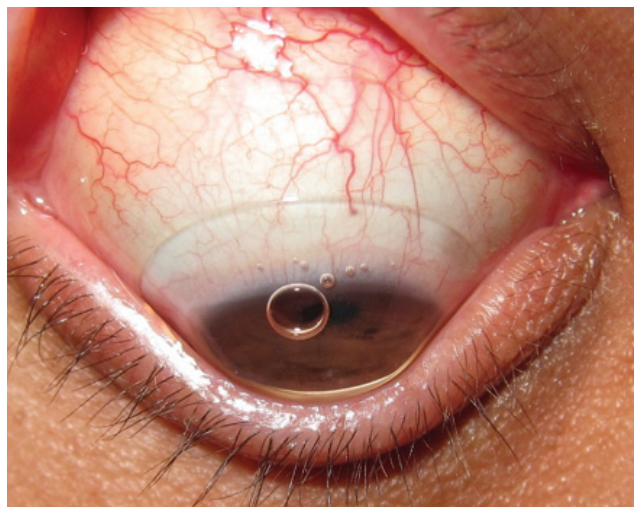
A well-trained staff can make all the difference in the world, so take the time at an office meeting to review with them these new lenses and how they are different from the others used in your practice. Valuable information, along with handouts and training videos are available online at www.sclerallens.org.

IN-OFFICE TECH

While a large obstacle to adding services to a practice is their start-up cost, this is not quite true for introducing scleral lenses. If you are already fitting soft contact lenses, there is a good chance that you have a topographer or at least an

auto-keratometer/refractor. Topographers help identify lens candidates by showing distorted corneas. Keratometers can aid in lens selection and help you evaluate potential lens flexure.

If you are tech savvy and like to make use of all your resources, your optical coherence topographer (OCT) can be a great tool for fitting scleral lenses. The pachymetry map measures corneal thickness and is helpful when evaluating for keratoconus. Measure corneal thickness before specialty contact lens wear and within six months after wear to rule out any edema caused by the contact lens. Also, take note of the lens's relationship to the cornea and the sclera. Precisely measuring how much



When a lens is inserted improperly, air bubbles that inhibit vision and make fitting assessment difficult appear.

clearance you have is important, as the clearance can impact your patient's visual outcome and ocular health.

Measure the exact sagittal (sag) height for each eye you are fitting to get a better idea of the necessary vault height and match an initial fitting lens.¹ You can also use rotating Schieimpflug cameras, such as the Pentacam (Oculus) to obtain a pachymetry map, anterior and posterior elevation maps and the familiar axial/sagittal curvature topographical map.² Some devices even allow you to export information to a third-party software application to help you better customize lenses for your patients.³

An anterior segment camera can also be helpful in the fitting process. You can send photos of the lens to consultants who will assist in making the proper modifications to best suit your patients. However, you don't need to spend a small fortune on a digital camera and software for your slit lamp. Your smart phone can be mounted to any slit lamp with an adapter that starts at around \$15. Then you can just text the images to your lab.



The larger, orange DMV inserter is for scleral lens insertion, and the smaller, white one is for removal.

GETTING STARTED WITH SCLERAL LENSES

PATIENT AND INITIAL LENS SELECTION

Once you identify a patient who would benefit from a scleral lens, educate them on what to expect during the fitting. They should expect to make several visits to your office for fitting, dispensing and follow-ups. Unlike soft lenses, trials are not available.

Next, you need to decide on the lens and parameters for the fit. Start by choosing the diameter of the lens. To do this, measure your patient's horizontal visible iris diameter (HVID). This can be done with an OCT, a tomographer, a millimeter ruler or just by observation. If the patient has a big eye, use the larger diameter in your set. Most fitting guides will tell you what lens to use first based on the patient's corneal condition and/or keratometry.

OBSERVE THE FIT

Sagittal height—the depth of the lens—is a key component to any scleral fit. Normal corneas can usually be fit with a shallower sag height, whereas abnormal corneas need a deeper sag height to ensure that the lens does not come in contact with the cornea.

Select your first trial lens and fill it with a sterile saline solution. Dab a strip of fluorescein in the bowl and insert the lens on the eye. After the lens is on the eye, check for air bubbles. Bubbles appear when the lens is not inserted properly; they can inhibit vision and make it difficult to assess how the lens is fitting. If an air bubble is present, remove and re-insert the lens before further evaluation.

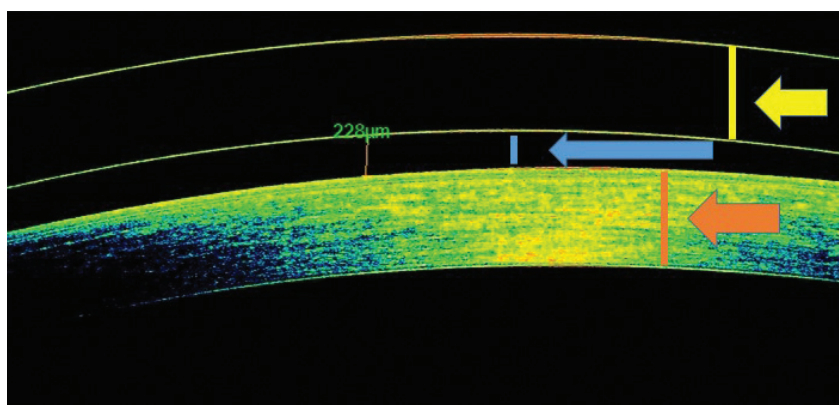
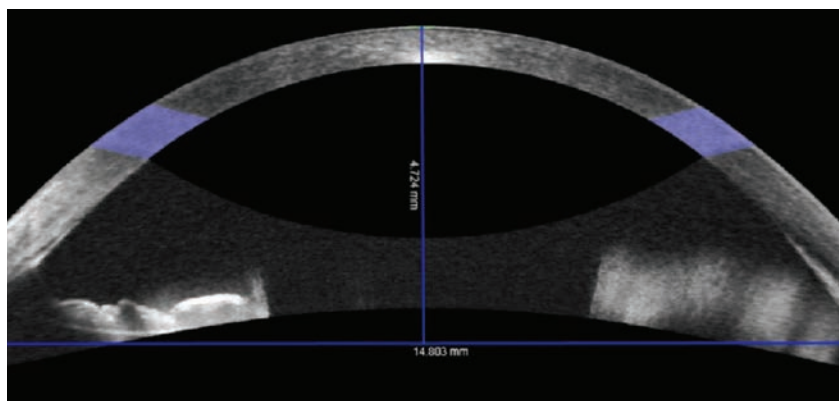
After the lens has settled for approximately 20 minutes, it is time to evaluate it. Start your

observations centrally and move to the periphery of the lens. First, judge how well the lens is vaulting the central cornea. In cases of keratoconus, you need to ensure the lens is vaulting over the apex of the cone. Using an optic section with a blue light on the slit lamp, three distinct features should be visible: the lens, the tear film and the cornea.

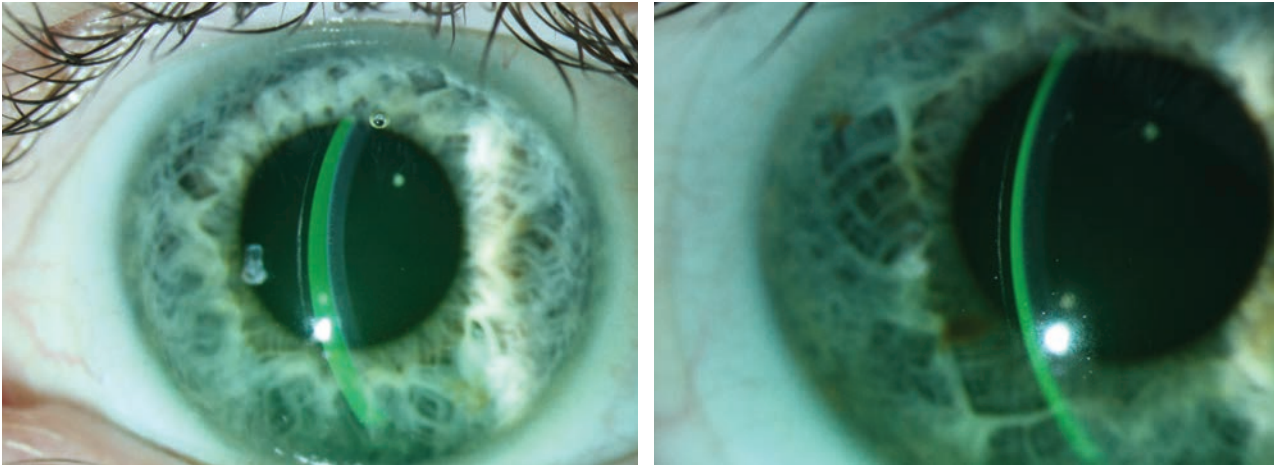
Evaluate the fluorescein to make sure there is no corneal bearing; if there is, remove the lens and choose one with a deeper sag height. Compare the thickness of the lens to the thickness of the tear film. Lens thickness varies by manufacturer but is usually 250 μ m to 350 μ m. Scleral lenses tend to settle by 100 μ m to 200 μ m after a few hours of wear time; therefore, you want to have enough clearance to allow for the settling while still avoiding any corneal bearing. On the other hand, too much clearance can lead to decreased vision, post-lens debris and conjunctival impingement.⁴ If you have an AS-OCT, you can get a more precise measurement of the clearance. This is especially helpful for your first few fits, but judging the tear film will suffice in most cases.

Next, move your beam to the mid-periphery and out towards the limbus. The thin, green tear film band will get narrower as you approach the edge of the cornea, but it should not disappear. If touch is seen in the mid-periphery or at the limbus, you need to change either the peripheral curves or lens diameter.

Now look at the edge of the lens and observe its relationship to the sclera. A smooth, tangential landing is ideal. If the edge of the lens is too steep, it will compress the conjunctiva and cause discomfort and possibly edema. When the



OCT of the anterior chamber can measure sagittal height as well as lens clearance—a beneficial tool for fittings.



At right, the tear film and lens thickness are almost equal. The lens on the left shows excessive clearance, which could lead to decreased vision, post-lens debris and conjunctival impingement.

lens is too flat, the edge lifts off the conjunctiva, and its shadow can usually be seen with the slit lamp. Flat lenses can lead to lens awareness and mid-day fogging due to debris entering the bowl.

Finally, over-refract the patient. Start with spherical lenses and add cylinder as needed. If cylinder is present, the lens may be flexing. Perform topography over the lenses to confirm this.⁵ Minimize lens flexure by increasing the center thickness of the lens or by adjusting the peripheral curves. If the astigmatism is lenticular in nature, a front-surface toric design should correct it.

Now, you are ready to order the lenses for your patient. Once they arrive, be sure to give your patient, your staff and yourself plenty of time to go over lens care, as well as insertion and removal training. Have a starter kit with lens cleaner, bowl filler and inserter and removal tools readily available.

After a successful training session, bring your patient back in one to two weeks for follow-up. A late morning or afternoon appointment is ideal, since you want to observe the lens after

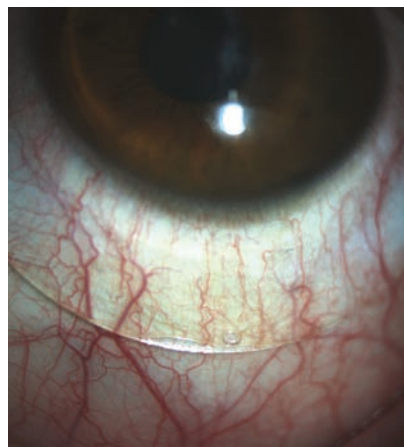it has been on the eye for at least four hours. Just like at the initial visit, start your evaluation centrally and make your way to the edge of the lens. How much clearance do you have? Is there any bearing on the mid-periphery or limbal regions? Are the edges of the lens sitting smoothly on the sclera without excessive compression or edge lift? Is the corneal epithelium intact?

Sometimes, Snellen acuity doesn't improve as much as we hope for, especially in ectatic corneas. Ask the patient about their vision; even if they are not 20/20

they will often notice a reduction in glare, improvement in contrast and ultimately be "20/happy."

Make adjustments to the power, sagittal height and peripheral curves and follow-up as indicated by your findings and patient history. If you have questions on what your next step needs to be, contact the manufacturer. Lab consultants are great resources for both the novice and advanced fitter.

Scleral lenses can provide excellent vision and comfort to your patients. Fitting them does not require a large investment, but the results of putting in the effort will pay dividends to your practice and your patients for years to come. **RCCL**



A scleral lens should sit smoothly and not display compression or edge lift, as seen here.

1. Caroline PJ, André MP. OCT aids in contact lens fitting. *CL Spectrum*. 2015;30(2):56.

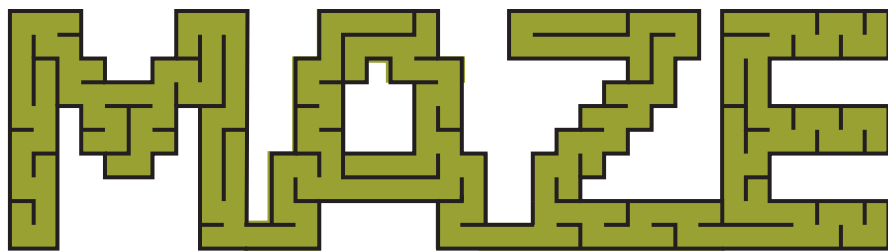
2. American Academy of Ophthalmology. Imaging the anterior segment: scheimpflug analysis. *Focal Points*. www.aaopt.org/focalpointssnip-petdetail.aspx?id=5b89b5e8-19d4-4e49-9edf-d791ce4497a1. Accessed July 23, 2019.

3. Oculus. Pentacam optional software modules: CSP Report. www.pentacam.com/int/ophthalmologist-diagnostic-without-pentacam/models/pentacam/optional-software.html. Accessed July 23, 2019.

4. van der Worp E. A Guide to Scleral Lens Fitting [monograph online]. Forest Grove, OR: Pacific University; 2010. commons.pacificu.edu/mono/4. Accessed July 23, 2019.

5. Jedlicka J. Solving scleral lens complications. *CL Spectrum*. 2012;27:40-4, 55.

Navigating the **SCLERAL LENS**



Here's how to avoid these common mistakes and complications and work through them when they occur.

By Emily Korszen, OD

There are many reasons scleral lenses have taken over such a large share of the contact lens market in such a short period of time. These devices offer a life-changing experience by bringing visual improvement and comfort to many patients while avoiding common issues associated with other contact lens modalities. Basic fitting techniques for scleral lenses can be implemented without much difficulty, but advanced troubleshooting takes time and effort to master. This article outlines mistakes and complications that commonly arise from scleral lens fittings and ways scleral lens fitters can navigate them to improve outcomes.

UNQUALIFIED PATIENTS

The importance of carefully choosing appropriate candidates for scleral lenses cannot be overstated, as patient motivation is critical for success. Due to the custom nature of these lenses, patients must understand that more specialized care and several office visits to finalize an optimal fit may be necessary.

Diagnostic fittings serve as an opportunity for patients to preview the vision and comfort of the lenses, which helps determine their level of motivation.

Indications for scleral lens wear fall under two main categories: irregular corneal shape and ocular surface disease. The rigid optics of scleral lenses provide clear vision to patients with keratoconus, corneal scarring and other causes of corneal irregularity, while the post-lens tear film continuously lubricates the cornea to treat ocular surface disease.¹

Many practitioners now fit scleral lenses on normal corneas due to the optics and comfort they offer. However, it's important to consider the risks that may be associated with long-term scleral lens wear, especially in eyes that do not require the lenses for vision correction and may be associated with a higher risk-benefit ratio.²⁻⁴ Patients with normal, healthy corneas may have less of an incentive to work through complications or setbacks with scleral lenses if other easier, more convenient options also provide clear vision.

INADEQUATE EDUCATION

If a patient is deemed an appropriate candidate for scleral lens wear and is motivated to move forward with the process, it is then the provider's responsibility to educate them on the expectations and the commitment level involved with lens fitting, wear and care. Fees and insurance reimbursement rates should also be topics of conversation. Having a well-trained staff and detailed protocols makes these discussions simple, efficient and beneficial. Investing time upfront can improve patient outcomes and satisfaction in the long run. It is important that patients first view scleral lenses as unique medical devices distinct from standard soft lenses so that they are fully pre-

ABOUT THE AUTHOR



Dr. Korszen practices in Spokane, WA, and is a fellow of the American Academy of Optometry and the Scleral Lens Education Society. She has a passion for specialty contact lens fitting and ocular surface disease management.

pared for what they are signing up for.

FITTING COMPLICATIONS

Once a patient is sufficiently educated and has realistic expectations on what is to come, they are then ready to be fit with scleral lenses. The “perfect fit” of a scleral lens involves complete vaulting over the cornea and limbus without excessive clearance and a smooth landing on the sclera.

The ideal amount of central clearance is up for debate but is generally around 200 μ m to 300 μ m.⁵ Highly irregular corneas may have lower or higher amounts of clearance. Corneal touch as a result of inadequate clearance often presents after lens removal as an area of epithelial staining. If this occurs, central clearance can be increased in large steps by increasing the sagittal depth of the lens and in smaller steps by steepening the peripheral curves.

Lens touch at the limbus can be addressed by increasing the diameter of the landing zone or steepening the curve overlying the limbus. Limbal bearing should be minimized as much as possible to avoid damage to the stem cells, although some amount of superior touch may be unavoidable.⁶ Excess limbal clearance, on the other hand, can induce hypoxia to the area and increase the chance of conjunctival prolapse—when loose conjunctival

tissue is pulled anteriorly under the lens and onto the cornea.⁷

Superior limbal touch is difficult to avoid due to the tendency for scleral lenses to decenter inferiorly and temporally. This is likely related to the elevation of the nasal sclera relative to the temporal sclera as well as gravity and downward force from the upper eyelid.⁸ Using a smaller lens diameter to decrease weight or toric peripheral curves can often improve lens centration.

Fitting concerns at the edge of the lens usually cause discomfort to the patient and can be addressed by customizing peripheral curves. Lab consultants can provide detailed information on how to best adjust each proprietary design.

Early on in the fitting process, epithelial bogging is sometimes described after lens removal as having a “water-logged” appearance. If lens parameters are appropriate and not causing excessive hypoxia, this complication often resolves on its own after a few weeks of lens wear.¹

HANDLING CHALLENGES

After the practitioner has successfully fit the scleral lens, the rest is up to the patient, and problems are bound to come up. Due to the large size of scleral lenses and the need for fluid to fill them, lens handling can pose a challenge, inconveniencing and frustrating many patients.

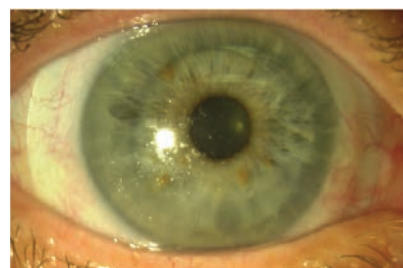

Fig. 2. This lens has poor wettability and a buildup of material on its front surface.

Some common aspects of lens care that patients struggle with are keeping both eyelids out of the way when applying the lenses, avoiding bubbles and overcoming Bell's phenomenon, which causes the eye to close and rotate up and out. There are many devices that hold the lens in place to free both of the patient's hands so that they're able to manipulate their eyelids.

If patients struggle with bubbles under the lens, more viscous, preservative-free artificial tears can be used to fill the lens. The lens diameter can also be reduced to allow for easier application as long as adequate limbal clearance is maintained. Unfortunately, handling difficulties are only one of the many issues scleral lenses can cause, and patients need to know how to approach each of them.

MID-DAY FOGGING

One of the most common complications of scleral lens wear, especially in patients with ocular surface disease or atopic disease, is lens fogging—or the buildup of particulate matter underneath or on the front of the lens (*Figures 1 and 2*).¹⁰ This can greatly inconvenience patients, as it causes a decline in vision throughout the day and often requires patients to remove, clean and reapply their lenses.⁹ The exact makeup of the lens debris is unknown but likely contains lipids and proteins from

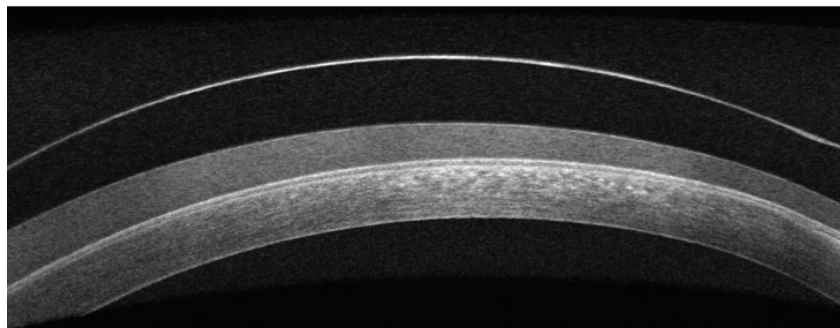


Fig. 1. OCT imaging shows fogging under a scleral lens.

NAVIGATING THE SCLERAL LENS MAZE

the tear film and white blood cells.^{11,12}

To address lens fogging, it helps to first determine if the buildup is occurring on the post-lens tear film, the front surface or both. Post-lens tear film fogging can be minimized by adding a few drops of a viscous, preservative-free artificial tear to the saline in the lens bowl.

Options for treating the front surface of the lens include adding a hydrophilic lens coating, using an enzymatic- or alcohol-based cleaner (do not use either on coated lenses), using preservative-free artificial tears for lubrication and spot-cleaning the lens with a moistened cotton swab.

Adjusting the lens fit can also reduce fogging by improving lens alignment to reduce tear exchange. Toric peripheral curves are usually needed to achieve better alignment, while decreasing corneal clearance minimizes the thickness of the foggy tear film and, therefore, reduces symptoms. Treating meibomian gland disease and ocular allergies and switching to preservative-free cleaning systems can help with both types of lens fogging.¹

CORNEAL HYPOXIA

The risk of corneal hypoxia is greater with scleral lenses compared with other lens types for several reasons. Scleral lenses are relatively thick compared with corneal gas permeable lenses to maintain their shape and prevent flexure. Minimal tear exchange occurs under a scleral lens, and oxygen trying to reach the cornea must travel through the lens material and the post-lens tear film.¹³ The modifiable variables that affect oxygen transmissibility are the lens material's oxygen permeability, lens thickness and corneal clearance of the lens.

Complications associated with

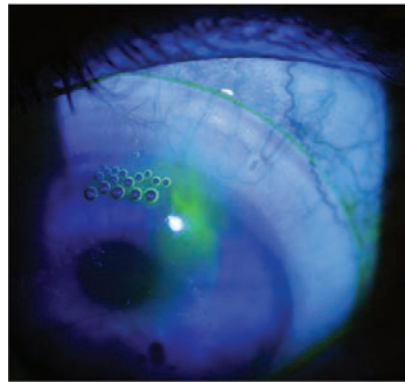


Fig. 3. Fluorescein dye and bubbles can leak under an area of edge lift.

hypoxia include corneal edema, epithelial microcysts and neovascularization. These signs of hypoxia are not common with scleral lens wear and are more likely to occur in patients with predisposing conditions that compromise endothelial function, such as corneal transplants.

Even without clinical evidence of hypoxia on slit lamp exam, low-grade corneal edema after scleral lens wear is measurable using optical coherence tomography (OCT). Therefore, it is important to use materials with high oxygen permeability, keep the clearance of the lens low while preventing corneal touch and avoid excessively thick lenses.¹⁴ Although materials high in oxygen permeability tend to have poor wettability, recent advances in lens coating technologies can keep these materials clean and comfortable.

Significant corneal neovascularization from scleral lens wear is rare and may be caused by contact lens over-wear or poor compliance, in addition to lens material and fitting variables. Discontinuation of lens wear along with medical therapy may be required to treat severe neovascularization. However, neovascularization that results from an underlying condition, such as Stevens-Johnson syndrome, may regress with scleral lens wear, so

it is important to determine the underlying cause and initiate treatment accordingly on a case-by-case basis.¹

If signs of corneal hypoxia appear in a scleral lens wearer, the first step is to adjust the lens parameters to maximize the oxygen transmissibility of the lens system. If this has been done already, it may be wise to consider other contact lenses, such as corneal gas permeable, specialty soft or hybrid lenses. In many cases, however, scleral lenses are the only option that provides comfortable, stable vision. For these patients, a reduced wearing schedule coupled with hypertonic saline drops may be a last resort.¹

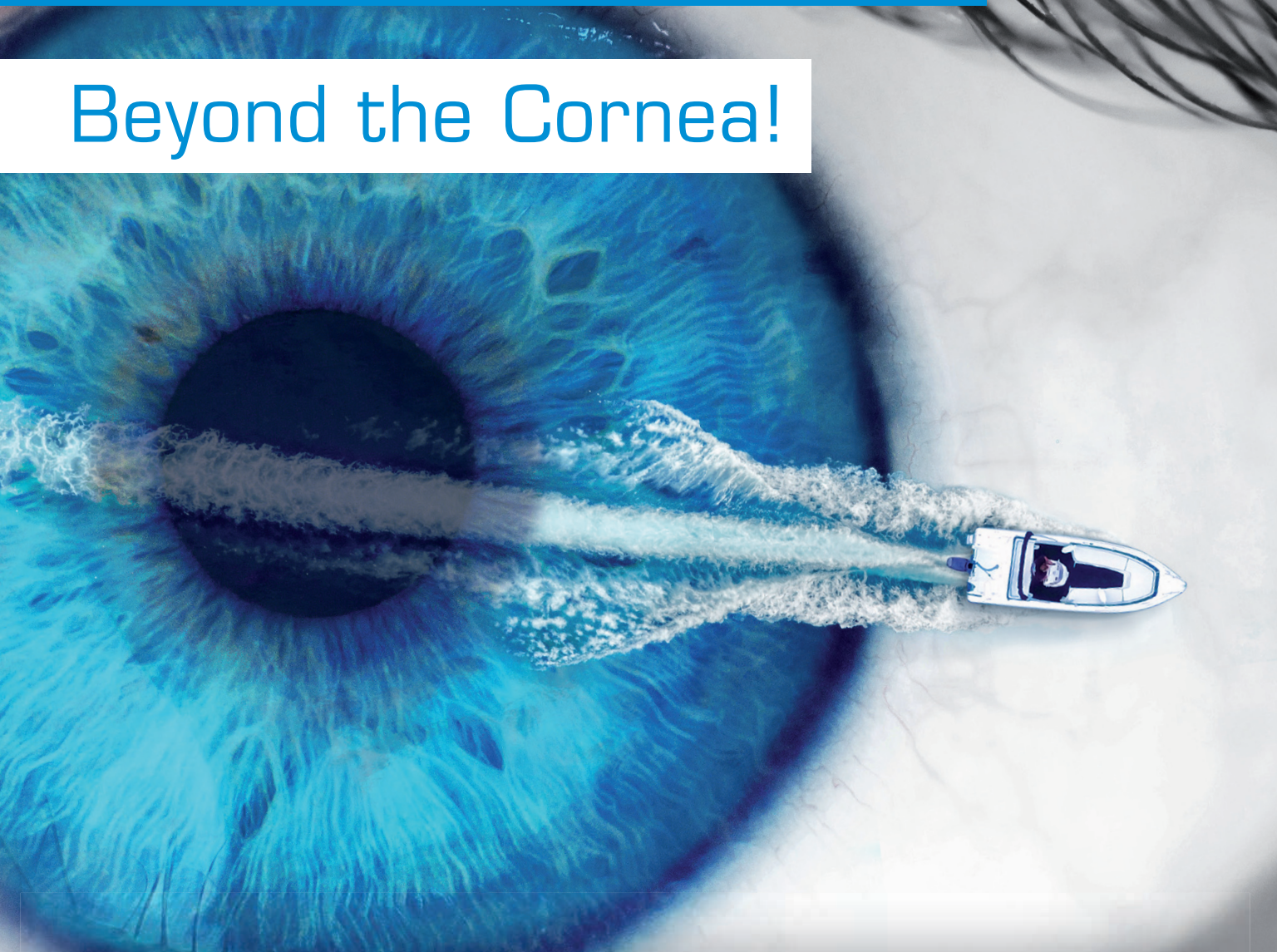
OCULAR IRRITATION

Scleral lenses are often regarded as a comfortable contact lens option, but issues can arise that cause irritation to the ocular surface. Fit-related comfort problems usually occur when the edge of the lens does not align with the sclera. If the edge lifts off the eye, it will rub against the lid when the patient blinks. A solution to alleviate this concern is steepening the peripheral curves. Compression—when the lens lands too abruptly and causes blanching of the conjunctival vessels—is the opposite problem and can lead to redness and irritation after lens removal.¹

Often, flattening the landing curves improves lens alignment in this situation, but the curves may need to be steepened if the compression occurs further from the lens edge. A careful slit lamp evaluation of the lens edge can usually detect these issues. Adding fluorescein dye to the anterior lens surface and watching where it flows under the lens can help pinpoint areas where the edge is not in contact with the eye (*Figure 3*).

NEW Cornea Scleral Profile Scan for the Pentacam®

Beyond the Cornea!



The new Pentacam® CSP Report measures, where others are just estimating

Measure beyond past boundaries when fitting scleral lenses. The new CSP Report creates 250 images within the measuring process. The tear film independent measurement with automatic release allows coverage up to 18 mm with the same fixing point.

Contact OCULUS today for more details!

Toll free 888-519-5375 [f](#) [t](#) [in](#) [y](#) Follow us!
ads@oculususa.com www.oculususa.com

 OCULUS®

Other tools for evaluating fit and optimizing lens alignment with the sclera include OCT and scleral mapping instruments (Figure 4). Toric peripheral curves can often help align the lens to the sclera, but sometimes even more customized peripheries are required.¹⁵ To alleviate pressure on a raised area of conjunctival tissue, such as a pinguecula or glaucoma-filtering bleb, many lens designs incorporate a localized vault of the lens edge. Use caution when fitting scleral lenses on eyes with filtering blebs due to the risk of bleb erosion.

Another possible source of discomfort is the lens solution. If punctate staining is noted, solution toxicity is the likely culprit and may indicate that the patient is using a preserved solution to fill the lens prior to application. To minimize solution-related irritation, first ensure patients are only using preservative-free saline to apply the lens, then consider switching to a preservative-free cleaning solution, such as a peroxide-based cleaner.

BLURRED VISION

If visual acuity after over-refraction is worse than expected with a scler-

al lens, there are several possible causes that you can correct. First, check for poor wettability and lens fogging. Next, perform a careful spherocylindrical over-refraction to determine if a front toric lens is required to correct residual astigmatism. Corneal topography can help detect lens flexure, which can be reduced by better aligning the landing zone of the lens with the sclera or by increasing lens thickness.

Visual quality can sometimes be improved with oblate lens designs, as the flatter base curves usually result in lower-powered lenses and less overall distortion.¹⁶ If pinhole acuity is not achieved with over-refraction and all other causes of blurred vision have been ruled out, consider higher-order aberrations (HOAs) as a potential cause. Some lens designs have aspheric curves on the front surface to minimize these distortions. Custom-designed lenses that address HOAs may help improve visual quality for these patients but are not commercially available at this time.¹⁷

RESOURCE UNDER-UTILIZATION

A major mistake that many new scleral lens fitters make is failing to take advantage of the array of resources available to learn advanced fitting techniques and navigate problems as they arise. Even seasoned fitters should pay attention to new lectures and articles, as scleral lens technology and research is rapidly advancing. Lab consultants are always available to help with difficult fits and are especially beneficial when using front toric lenses, multifocals, localized

vaults of the lens edge and other custom options. Online platforms also provide access to opinions and tips, case reports and new information.

Scleral lenses are generally well-tolerated and have relatively low complication rates. However, when challenges arise, steps must be taken to optimize vision, especially if the lenses are a last resort before invasive treatment, such as corneal transplantation. Give your scleral lens patients the best care possible by staying up-to-date in this quickly changing field and taking advantage of the resources available to further enhance your skills. [RCCL](#)

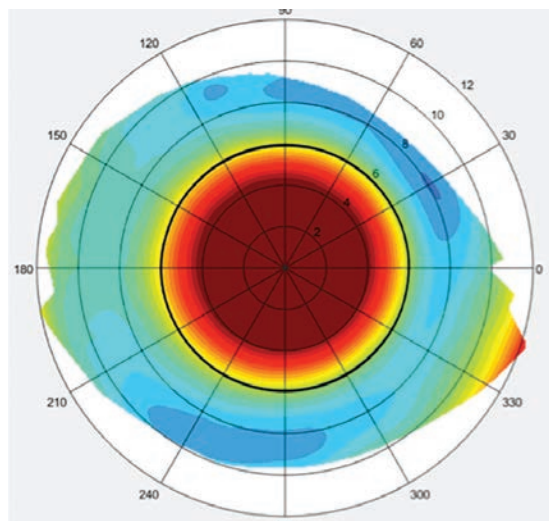


Fig. 4. This topographical scleral map was taken of an eye with a toric sclera.

1. Barnett M, Johns LK. Ophthalmology: current and future developments (volume 4): contemporary scleral lenses theory and application. In: Sharjah, UAE: Bentham Science Publishers.
2. Michaud L. Beyond irregular: scleral lenses for everyday use. *Cont Lens Spec.* 2015;30:30-2, 34, 36.
3. Van der Worp E, Bornman D, Ferreira DL, et al. Modern scleral contact lenses: a review. *Cont Lens Ant Eye.* 2014;37(4):240-50.
4. Ensley R, Miller H. Sclerals: the new normal? *RCCL.* 2018;155(3):8-10.
5. Van der Worp E. A Guide to Scleral Lens Fitting, Version 2.0. Forest Grove, OR: Pacific University; 2015.
6. Pucker AD, Laurent JM. Scleral contact lens complications. *Cont Lens Spec.* 2017;32:24-7.
7. Caroline PJ, André MP. A potential effect of conjunctival prolapse. *Cont Lens Spec.* 2013;28(9):56.
8. Ritzmann M, Caroline PJ, Börret R, et al. An analysis of anterior scleral shape and its role in the design and fitting of scleral contact lenses. *Cont Lens Ant Eye.* 2018;41(2):205-13.
9. McKinney A, Miller W, Leach N, et al. The cause of midday visual fogging in scleral gas permeable lens wearers. *Invest Ophthalmol Vis Sci.* 2013;54(15):5483.
10. Sindt CW, Longmuir RA. Contact lens strategies for the patient with dry eye. *Ocul Surf.* 2007;5(4):294-307.
11. Walker MK, Bergmanson JP, Miller WL, et al. Complications and fitting challenges associated with scleral contact lenses: a review. *Cont Lens Ant Eye.* 2016;39(2):88-96.
12. Postnikoff CK, Pucker AD, Laurent J, et al. Identification of leukocytes associated with midday fogging in the post-lens tear film of scleral contact lens wearers. *Invest Ophthalmol Vis Sci.* 2019;60(1):226-33.
13. Morrison S, Walker M, Caroline P, et al. Tear exchange beneath scleral lenses. Poster presented at: The 2014 Global Specialty Lens Symposium; 2014 Jan; Las Vegas, NV.
14. Compañ V, Aguilera-Arzo M, Edrington TB, et al. Modeling corneal oxygen with scleral gas permeable lens wear. *Optom Vis Sci.* 2016;93(11):1339-48.
15. Visser ES, Visser R, Van Lier HJ. Advantages of toric scleral lenses. *Optom Vis Sci.* 2006;83(4):233-6.
16. Shovlin JP. Scleral battle: oblate vs. prolate. *Rev Optom.* 2018;155(3):78.
17. Yoon G, Sabesan R, Johns L, et al. Custom correction of higher order aberration in keratoconus with a scleral lens prosthetic device. *Invest Ophthalmol Vis Sci.* 2012;53(14):1394.

Earn up to
18-28 CE
Credits*

NEW TECHNOLOGIES
& TREATMENTS IN
2020 EYE CARE
REVIEW
EDUCATION GROUP

Join us for our
2020 MEETINGS

FEBRUARY 14-17, 2020 - ASPEN, CO

Annual Winter Ophthalmic Conference

Westin Snowmass Conference Center

Program Co-chairs: Murray Fingeret, OD, FAO and Leo P. Semes, OD, FACMO, FAO

REGISTER ONLINE: www.skivision.com

APRIL 16-19, 2020 - AUSTIN, TX

Omni Barton Creek

Joint Meeting with OCCRS**

Program Chair: Paul M. Karpecki, OD, FAO

REGISTER ONLINE: www.reviewsce.com/austin2020

MAY 29-31, 2020 - SAN DIEGO, CA

Manchester Grand Hyatt

Program Chair: Paul M. Karpecki, OD, FAO

REGISTER ONLINE: www.reviewsce.com/sandiego2020

JUNE 5-7, 2020 - ORLANDO, FL

Disney Yacht & Beach Club

Program Chair: Paul M. Karpecki, OD, FAO

REGISTER ONLINE: www.reviewsce.com/orlando2020

NOVEMBER 6-8, 2020 - PHILADELPHIA, PA

Philadelphia Marriott Downtown

Program Chair: Paul M. Karpecki, OD, FAO

REGISTER ONLINE: www.reviewsce.com/philadelphia2020

Visit our website for the latest information: www.reviewsce.com/events
e-mail: reviewmeetings@jhihealth.com or call: 866-658-1772

Administered by:

REVIEW
EDUCATION GROUP

Medscape
LIVE!

COPE

*Approval pending

SALUS
UNIVERSITY
Pennsylvania College of Optometry

OCCRS
OPTOMETRIC, CONTACT
AND REFRACTIVE SOCIETY

**17th Annual Education Symposium
Joint Meeting with NT&T in Eye Care

Review Education Group partners with Salus University for those ODs who are licensed in states that require university credit.
See www.reviewsce.com/events for any meeting schedule changes or updates.

CONSIDER SCLERALS FOR DRY EYE

This treatment option may require more care
but provides patients with relief.

By Whitney Hauser, OD

Dry eye disease (DED) is a chronic, multifactorial condition that is one of the most commonly identified diagnoses in eye care. Some studies have found the symptomatic patient population in the United States to be approximately 20 million.¹ A recent population-based study found DED among the most identified eye diseases (fifth in females, ninth in males) providing additional epidemiological evidence for DED as a commonly occurring condition driving patients to seek medical care.²

A literature review of contact lens wear and dry eye disease could discourage a clinical practitioner from considering contact lenses for treating ocular surface disease. However, contact lenses are recognized not only for their refractive and aesthetic benefits to patients, but also as medical devices used in the management of ocular disease. DED patients may benefit from using scleral contact lenses.

LENS-ASSOCIATED DRYNESS

The diverse and overlapping etiologies of DED contribute to the condition's multifactorial nature and complexity of diagnosis and

treatment. Sex, changes in hormones, meibomian gland dysfunction (MGD), medications (systemic and ophthalmic), ophthalmic surgery, comorbid conditions and poor mechanics (blink mechanism) are among the most common suspects. Additionally, several studies have found contact lens wear to be a significant risk factor for DED. While its prevalence in the general population reportedly ranges from 0.39% to 33.7%, contact lens wearers have been found to experience dry eye symptoms much more frequently.

Approximately 50% of contact lens wearers report dry eye symptoms at least some of the time.² The same study noted contact lens wearers were 12 times more likely than emmetropes to report dry eye symptoms and five times more likely than spectacle wearers.² Numerous studies have identified contact lens wear as a potential risk factor for dry eye patients as a trigger to initiate symptoms or to exacerbate existing disease.

Potential origins of contact lens-associated dryness include increased tear film evaporation, increased osmolarity, dewetting of the contact lens related to poor biocompatibility or a combination of these.² DED in contact

lens wearers may contribute to alterations to tear film stability, resulting in desiccating stress to the ocular surface that can manifest in changes in osmolarity and loss of homeostasis.

SCLERALS' BENEFITS

As a practitioner at a tertiary dry eye center, I often make referrals to colleagues for services not performed at the center. The primary referral I make within optometry is to contact lens specialists. I have found increasing opportunity and success in treating recalcitrant dry eye disease with scleral lenses. While most lenses are prescribed for corneal irregularity (74%), a smaller but still valuable group (16%) is prescribed scleral lenses for ocular surface disease.⁵

The Tear Film and Ocular Surface Society (TFOS) Dry Eye Workshop II (DEWS II) has identified both symptomatic patients for ocular surface disease as well as those with neuropathic pain,

ABOUT THE AUTHOR



Dr. Hauser is an assistant professor at Southern College of Optometry and provides clinical care for patients at TearWell: Advanced Dry Eye Treatment Center and The Eye Center.

or keratoneuralgia, as potential candidates for scleral lens fits.⁶ Neuropathic pain, or “pain without stain,” is often difficult to treat due to the discordance between signs and symptoms.

Scleral lenses are thought to minimize symptoms by interrupting the pain cycle in some patients. In patients exhibiting signs of ocular surface disease like pigment epithelial defects (PEDs) and filamentary keratitis scleral lenses can provide improvement in both clinical signs and patient comfort.^{6,7} While soft contact lenses are inexpensive, readily available and prescribed more widely by practitioners, scleral lenses offer a unique environment for non-healing PEDs by creating an oxygenated precorneal fluid reservoir, which allows for continual hydration of the cornea, provides protection from the external environment with little contact to the cornea and provides optimal visual correction.⁵

Scleral lenses are often a viable option for patients with recalcitrant dry eye when other traditional therapies (artificial tears, autologous serum drops, ophthalmic steroids, cyclosporine, lifitegrast, punctal plugs) fail to provide clinically significant improvement. Lenses may be used alone or as part of a combination therapy with traditional treatments.⁵

CASE #1

A 69-year old, female was referred to the dry eye center for evaluation and treatment by her ophthalmologist. Her complaints of irritation and fluctuating vision began two or three years ago and were constant. She suspected her ocular discomfort was driven by a poorly fitting rigid gas permeable (GP) contact lens. Her current pair were two years old, and she had

worn them comfortably until the last several months. The patient had a history of GP wear for approximately 50 years. In addition to her dry eye complaints, she was also diagnosed with keratoconus (OD<OS) several years prior and reported stability.

The referring doctor prescribed cyclosporine A, 0.05%, ophthalmic emulsion twice daily and use of artificial tears as needed. However, the patient found the drops to burn too much to remain compliant and discontinued after one week of use. Currently, she was exclusively using artificial tears without success.

Her corrected entrance visual acuity was 20/25 OD and 20/30 OS, and her OSDI score was 27. MMP-9 testing was negative. Phenol red thread testing was 23/20 (OD/OS). Meibography revealed moderate gland atrophy in both of the lower lids. Remarkable findings in the physical examination included mild blepharitis (UL/LL), superficial punctate keratitis (SPK, OD<OS) and mild congestion of meibomian gland secretion (*Figure 1*). The patient’s lid margins had mild telangiectasias and scalloping of the inferior lid margin. Her tear break-up time was three seconds in each eye.

The patient was placed on an oral omega supplement. She was encouraged to resume cyclosporine A, 0.05% ophthalmic solution and continue artificial tear use. However, the patient reported she did not prefer to use ophthalmic medications for the management of her dry eye disease. In light of her preference and the pre-existing condition of keratoconus, we referred her for a scleral contact lens fit. Lenses were ordered for the patient, and she returned to the dry eye center

in the interim for follow-up at one month. She reported compliance with artificial tears and nutrition supplement. Symptoms and signs persisted similar to initial examination. At follow-up, we provided the patient with an in-office lid hygiene treatment with an okra-based polysaccharide lid hygiene treatment and instructed her to begin the at-home product twice daily.

After a series of lenses, an ideal scleral lens was selected for the patient. She noted good comfort and good vision, and the fitting doctor finalized the prescription. After the finalization, the patient returned to the dry eye center for evaluation after one month of lens wear (*Figure 2*). Her OSDI decreased from 23 to 2. The patient’s cornea was clear of SPK OD/OS, and her visual acuity was 20/20 (OD/OS).

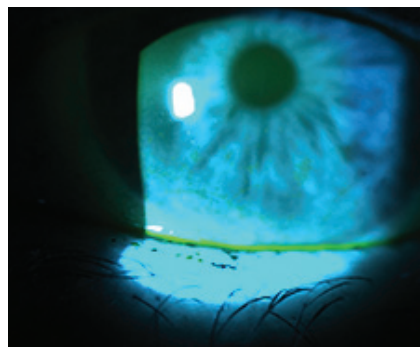


Fig. 1. Significant superficial punctate keratitis (SPK) prior to scleral lens fit.

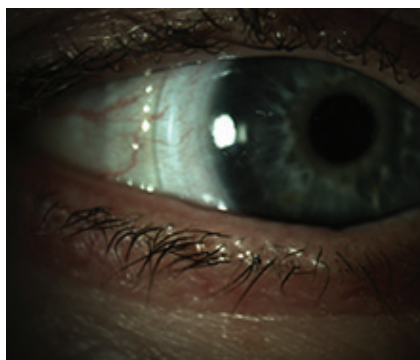


Fig. 2. After the scleral lens fit, the patient reported improvement in dry eye symptoms.

CONSIDER SCLERALS FOR DRY EYE

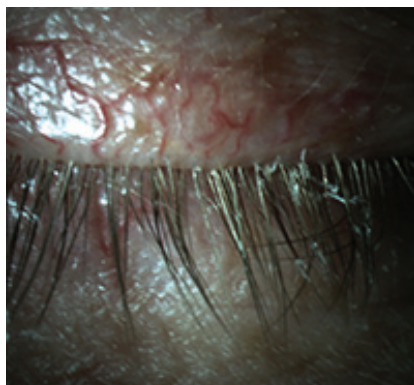


Fig. 3. Upper and lower lid telangiectasias with anterior blepharitis.

CASE #2

A 59-year old Caucasian male presented with the chief complaint of constant dryness and blur in his right eye. The patient's medical history also included hypertension, rheumatoid arthritis and Type 2 diabetes, all of which he was diagnosed with in 2008. His ocular history included a successful refractive surgery decades prior and current use of spectacles for reading only.

In 2016, the patient was diagnosed with a bacterial ulcer. The bacterial ulcer rapidly worsened under in spite of aggressive treatment by a trained cornea specialist. Cultures revealed the offending bacteria was methicillin-resistant *Staphylococcus aureus* (MRSA).

The patient was treated with a series of fortified antibiotics as well as amniotic membrane. Within six months a penetrating keratoplasty (PKP) was performed. However, several months post-PKP, the patient suffered a corneal perforation. The perforation was treated and the patient had been stable for several months but continued to suffer from dryness. His current treatment regimen included cyclosporine ophthalmic emulsion, 0.05% BID and loteprednol ophthalmic gel BID.

Upon initial exam in the dry eye clinic, visual acuity was 20/600 OD with 20/125 pinhole acuity and 20/20 OS. He presented with bilateral lid scalloping accompanied by telangiectatic vessels and lash debris (Figure 3). Anterior segment evaluation further revealed superficial punctate keratitis on both corneas (OD>OS). The right eye presented with filaments adhered to the cornea and geographic corneal scarring.

We considered treating the filamentary keratitis with amniotic membrane. However, the patient noted a poor experience previously and refused insertion. Instead, we prescribed N-acetylcysteine (NAC) drops to break up the corneal filaments, as well as hypochlorous acid lid hygiene spray and preservative-free hyaluronic acid artificial tears.

The patient returned for follow up two weeks later. At the visit, the filamentary keratitis had resolved. However, as expected, significant SPK remained. We decreased NAC ophthalmic drops to BID; loteprednol, cyclosporine and artificial tears were maintained as directed. We also added an okra-based polysaccharide lid hygiene gel to the patient's regimen. He was scheduled for scleral lens fit with the expectation to discontinue NAC drops with a successful

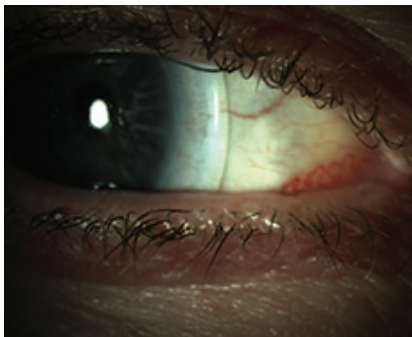


Fig. 4. This patient reported good comfort and significant improvement in vision after receiving sclerals.

fit as well as improve the patient's comfort and decrease his dryness complaint.

We referred the patient to a colleague for scleral lens fitting. He was initially fit in ZenLens with an oblate design. The lens had a 17.0mm diameter and parameters of +8.00-1.00X050. The patient reported no lens discomfort or dryness while wearing. The patient was allowed to wear the lens up to three hours per day until a second lens arrived with revisions (ZenLens Toric PC +7.50/9.7/17.0 with an additional 50 microns of clearance 360 degrees). The second lens provided good central clearance and improved limbal clearance with no blanching. The patient continued to report good comfort and significant improvement in vision with his acuity measured at 20/60+2 and 20/20 OS (Figure 4).

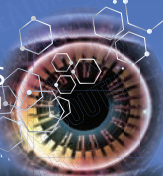
Scleral lens fitting and dry eye management present an opportunity for bidirectional referrals within optometry. Each physician in the equation can benefit from inter-professional referrals. In addition, patients will receive the most comprehensive care for their ocular surface disease. [\[1\]](#)

1. Gayton JL. Etiology, prevalence and treatment of dry eye disease. *Clin Ophthalmol*. 2009;3:405-12.
2. Nichols JJ, Sinnott LT. Tear film, contact lens and patient-related factors associated with contact lens-related dry eye. *Invest Ophthalmol Vis Sci*. 2006;47(4):1319-28.
3. Chen S, Han T, Huang W. Study of therapeutic bandage type contact lens in the treatment of 27 cases of severe tear and evaporative dry eye. *Mod Hosp*. 2018;18(5):750-2.
4. Lee YK, Lin YC, Tsai SH, et al. Therapeutic outcomes of combined topical autologous serum eye drops with silicone-hydrogel soft contact lenses in the treatment of corneal persistent epithelial defects: a preliminary study. 2016; 39(6):425-30.
5. Nau CB, Harthan J, Shorter E, et al. Demographic characteristics and prescribing patterns of scleral lens fitters: the SCOPE Study. *Eye Contact Lens*. 2018; 44(9) Suppl 1:S265-72.
6. Craig JP, Nichols KK, Akpek EK, et al. TFOS DEWS II definition and classification report. *Ocul Surf*. 2017;15(3):276283.
7. Jones L, Downie LE, Korb D, et al. TFOS DEWS II management and therapy report. *Ocul Surf*. 2017;15(3):575-628.

Earn up to
19 CE
Credits*

NEW TECHNOLOGIES
& TREATMENTS IN
2019 EYE CARE

REVIEW
EDUCATION GROUP



CHARLESTON, SOUTH CAROLINA

Date: November 1-3, 2019

Location:

Charleston Marriott

170 Lockwood Blvd,
Charleston, SC 29403
Reservations: 1-800-228-9290

Limited discounted room rate:
\$229/night. Please book with the
hotel directly by calling the number
above. Mention "Review's New
Technologies & Treatments" for
group rate.



Program Chair:

Paul M. Karpecki, OD, FAAO

Registration Cost: \$495

Faculty:

Marc Bloomenstein, OD, FAAO

Douglas K. Devries, OD

Jack Schaeffer, OD, FAAO

Robert P. Wooldridge, OD, FAAO

3 WAYS TO REGISTER:

Online: www.reviewsce.com/charleston2019

Phone: 1-866-658-1772 or **E-mail:** reviewmeetings@jobson.com

REGISTER ONLINE: WWW.REVIEWSCE.COM/CHARLESTON2019

Administered by:

REVIEW
EDUCATION GROUP

COPE[®]

*Approval pending



SALUS
UNIVERSITY
Pennsylvania College of Optometry

Partially supported by
unrestricted educational grants from:

Sun Pharmaceuticals

Bausch & Lomb

Carl Zeiss Meditec

Alcon

Review Education Group partners with Salus University for those ODs who are licensed in states that require university credit. See www.reviewsce.com/events for any meeting schedule changes or updates.

Multifocal Optics Expand the Reach of Scleral Lenses

**This modality gives presbyopic patients the break they've been looking for.
Follow this guide for the best results.**

By John Gelles, OD, Melissa Barnett, OD, and Jason Jedlicka, OD

Several options give presbyopic patients the opportunity to reverse the clock and enjoy improved vision and quality of life. Multifocal contact lenses, being one of these choices, provide patients good vision at all distances and freedom from reading glasses. There are many different optical designs and a few contact lens modalities that deliver multifocal optics, such as soft lenses, gas permeable lenses and hybrid lenses, but what about scleral lenses? Can we include them on this list?

Scleral lenses have seen tremendous growth over the past 10 years and are no longer a niche product. Traditionally, scleral lenses have been used in the non-surgical visual rehabilitation of irregular corneal conditions and as an adjunct therapeutic management strategy for ocular surface disease. Today, scleral lenses are also used to manage refractive error in patients with normal corneas.

Though many patients are thrilled with the distance vision and comfort these lenses provide,

presbyopic patients want great vision at all distances while remaining spectacle-free. The following article will go into detail on how to check off this box for patients when presbyopia presents because no matter the indication for scleral lens wear, we know all patients eventually develop the condition.

GOODBYE GLASSES

The search for spectacle-free near vision is nothing new. Patients have long searched for options to make this a reality.

One method, monovision, has been around for decades. By correcting one eye for distance and the other for near, monovision patients who are able to tolerate it can complete most of their daily activities without additional spectacle correction. This is a well-established strategy for presbyopic scleral lens users. Monovision drawbacks include loss of binocularity and depth perception. Some patients can not adapt to monovision due to the optical disparity.

Another option is adding front surface asphericity. Though not

a true multifocal design, this small change to the optics may be adequate enough to improve near vision in early presbyopes.

The last option is multifocal optics. A scleral lens with multifocal optics was rare 10 years ago, but

ABOUT THE AUTHORS




Dr. Gelles is director of the specialty contact lens division at the Cornea and Laser Eye Institute (CLEI) and the CLEI Center for Keratoconus in Teaneck, NJ.



Dr. Barnett is a principal optometrist at the UC Davis Eye Center in Sacramento, CA. She is a fellow of the American Academy of Optometry (AAO), a diplomate of the American Board of Certification in Medical Optometry and a fellow of the British Contact Lens Association.



Dr. Jedlicka is an associate professor and chief of the cornea and contact lens service at the Indiana Univ. School of Optometry in Bloomington. He is a diplomate of the AAO's Cornea, Contact Lens and Refractive Technologies section and a fellow of the Contact Lens Society of America.



Simulated center-near multifocal design image from focal points.

now nearly every lab offers at least one option.

IT'S ALL IN THE OPTICS

Unlike translating segmented bifocal and progressive corneal gas permeable lenses, scleral lenses do not translate on the eye. Compared with other contact lenses, scleral lenses have minimal movement and are very stable. Due to their customizable nature of matching the haptic or peripheral curves to the scleral geometry, these lenses tend not to rotate. In this sense, the lens is generally static, and, as such, simultaneous vision multifocal designs are necessary. The vast majority of multifocal optics are center-near designs. However, some labs offer center-distance designs.

Scleral lenses with multifocal optics exist in several different designs. Multifocal optics come with a gradual increase in add, allowing for more function at mid-range and near, whereas, bifocal optics cater to distance and near. Some

labs offer variable zone sizes to dial-in the multifocal performance based on a patient's pupil size.

Multifocal optics are added to the front surface of the lens in the vast majority of designs. Some labs have limited options since astigmatism correction is also added to the front surface

of the lens, forcing the practitioner to choose between toric and multifocal optics.

SETTING CANDIDATE EXPECTATIONS

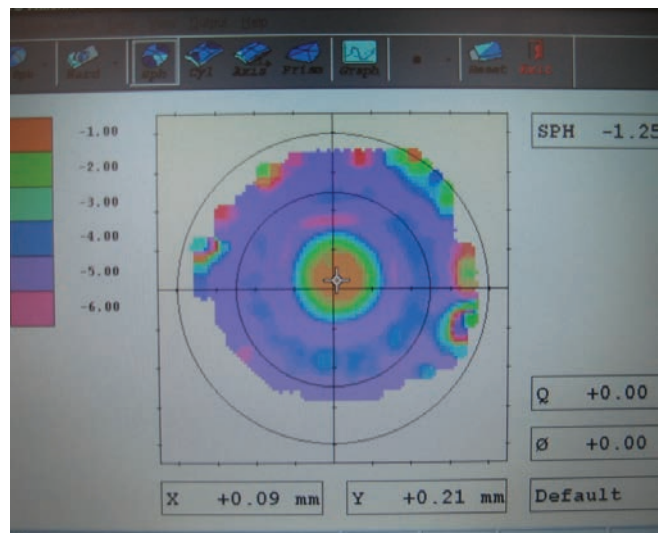
With the onset of presbyopia comes other changes to the eye, such as dryness and tear layer instability. These make soft contact lenses less tolerable for many patients. In addition, the complexity and lack of historical success with correcting astigmatism and presbyopia simultaneously with anything but corneal gas permeable lenses causes many patients

to use reading glasses in addition to contact lenses for their presbyopia or drop out of contact lens use altogether. Scleral lenses can fill a void in this patient population.

Multifocal scleral lenses can be used in most patients with presbyopia—but may not be the best option for all candidates—and are particularly helpful in cases of dry eye disease and regular or irregular astigmatism. Generally, patients should have less than +0.75D of residual astigmatism for the lenses to work as effectively as possible.

As with other types of multifocal contact lenses, determine best-corrected vision in each eye. If there are any complications with best-corrected vision due to things like corneal scarring, strabismus, cataracts and age-related macular degeneration, you can still prescribe multifocal scleral lenses and should educate the patient accordingly.

Just like with multifocal soft lenses, the practitioner must set realistic expectations, as vision will be functional at distance, mid-range and near but not necessarily perfect at all distances. Some patients fit with multifocal lenses



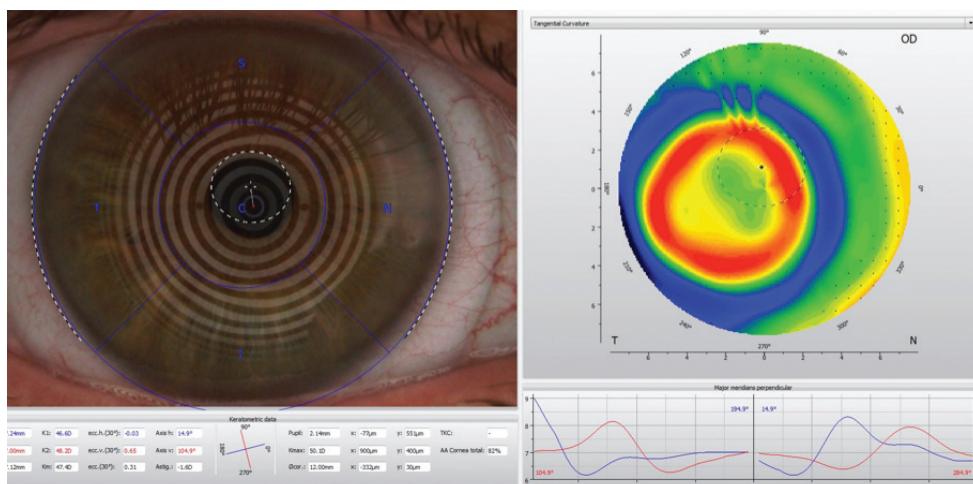
Optical metrology of a center-near multifocal design.

MULTIFOCAL OPTICS EXPAND THE REACH OF SCLERAL LENSES

feel like they are cheating if they use reading glasses. But they may be necessary in certain situations, such as threading a needle or reading a menu in a dimly lit restaurant. It's important to understand spectacle use is normal and glasses are just another tool that can help.

FINALIZING FIT

The process of prescribing a multifocal scleral lens starts with a diagnostic fitting. A profilometer can help understand the scleral shape. Once the lens is placed on the eye, perform a spherocylindrical over-refraction. If the patient has +0.75D or more of residual astigmatism, discuss visual blur with them. Then, use a trial frame to simulate spherical equivalent correction and gauge tolerability and response.



On the left is what appears to be acceptable centration of the center-distance multifocal scleral lens over the cornea. This method involves placido ring projection to identify the center of the lens and then compare it to the center of the pupil. The over-topography on the right shows that the placement of the add zone is inferior temporal to the visual axis and pupil. This is due to the natural placement of the visual axis superior nasal to the center of the cornea and the slightly inferior temporal lens fit.

Next, determine the patient's near add and ocular dominance. Pupil size is extremely important to take into consideration for a successful multifocal contact lens fit, and it's no different for multifocal scleral lens fits. There are several measurement methods that can be used, including a pupil

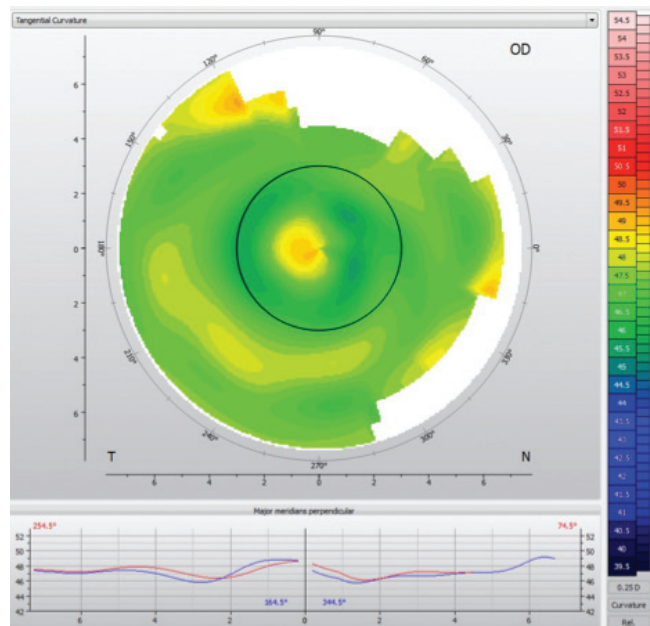
ruler, slit lamp reticule, pupilometer and topographer.

Remember to check pupil size under photopic and scotopic conditions. Keep in mind that, in some patients, starting with a low add or an aspheric multifocal design in both eyes is sufficient. Since so much of our time is spent

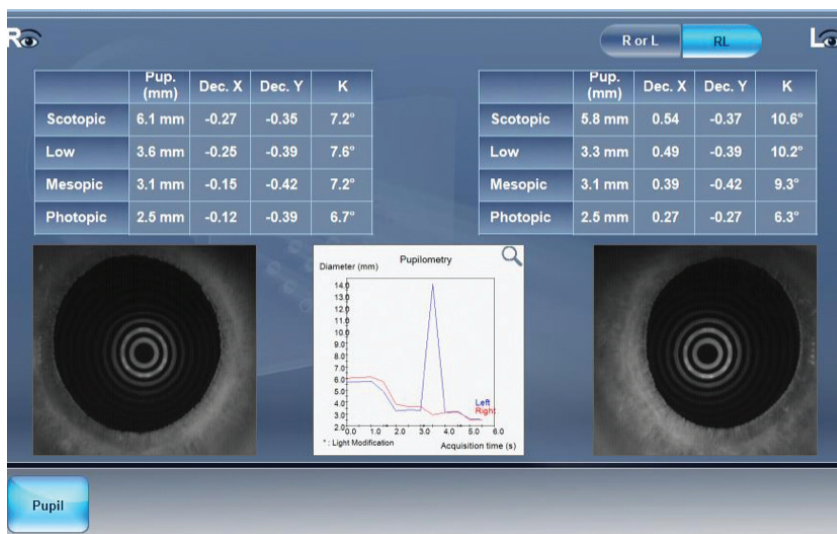
on digital devices doing mid-range tasks, a lower-than-expected add provides adequate vision at all distances.

Then, determine the dominant eye. To determine sight dominance, instruct the patient to create a triangle and look through it at a single letter. The eye they use is the dominant eye. Sensory dominance evaluates sensitivity to blur. Place a +1.50D lens over the eye, and evaluate vision. The eye that experiences the most reduced vision is usually the dominant eye.

Once the diagnostic fitting is complete, there are two methods to fit multifocal scleral lenses. One is to finalize the fit and then the optics. Prescribe and dispense a single vision lens for distance. If the fit is acceptable and the distance prescription is accurate at follow-up, reorder the lens with the multifocal optics added. This method ensures proper fit and lens position prior to adding optics, without which the optics would not be centered on the pupil and offset optics would need to be used. The only downside is that



Mapping over a multifocal scleral lens can help with troubleshooting distance and near acuity issues.



Pupillometry derived from topography.

patients are not immediately exposed to multifocal optics.

Another option is to finalize the fit and the optics at the same time. After a diagnostic fitting, order a lens with multifocal optics. If a lens is significantly different than the diagnostic lens, then the power may not be correct, making it more challenging to adjust base lens power and multifocal power simultaneously. Additionally, the lens position is dependent on the lens fitting relationship; adjustments to the fit may alter the lens position, moving the multifocal optics and creating variable optics from lens to lens.

OFF BALANCE

Lens decentration plays a significant role in the success or failure of multifocal scleral lenses. In general, the visual axis (and center of the pupil) is located slightly superior nasal relative to the geometric center of the cornea. Scleral lenses, on the other hand, usually settle in an inferior temporal position based on the shape of the sclera. Thus, the center of the lens is inferior temporal in relation to the line of sight of the eye.

One method to find the location of the multifocal optics relative to the pupil involves employing over-topography of the settled lens on the eye. Using subtractive tangential maps makes it easy to find the centration point of the multifocal optics. If the visual axis is significantly decentered relative to the lens center in its settled position, there are manufacturers that offer decentered optics to align the multifocal add zone with the visual axis. If the lens is significantly decentered, it is unlikely that changes in power will improve visual performance.

In some cases, expanding the size of the distance or near zone, depending on the design, may help distance, near or both. This technique can also be used to check near zone size in comparison with pupil size. Too large of a near zone will reduce distance performance, and too small of a near zone will reduce near performance.

PUSH FOR NEAR OR FAR

In cases of insufficient near vision, push plus while performing an over-refraction at distance prior to making changes to the add power. If no plus is accepted, then

adjust add power (particularly in aspheric designs) or add zone (more commonly in concentric designs). Additionally, flattening the base curve of a scleral lens while compensating for loss of sagittal depth in some designs will create additional plus, increasing magnification. Another option is switching lens designs. For example, if a center-distance design is selected first for both eyes, change the non-dominant eye to a center-near design to improve near vision.

If distance vision is poor, on the other hand, perform a spherocylindrical over-refraction at distance. This will help rule out residual astigmatism and flexure as causes of decreased vision. Assuming proper lens centration, the near zone size may need to be reduced in a center-near design or enlarged in a center-distance design. Decreasing the add power is another alternative if over-mapping demonstrates that the add zone size is appropriate. The add power may be decreased in the dominant eye and kept the same in the non-dominant eye.

Though multifocal optics add another layer of complexity to scleral lenses, the results are rewarding to patients and practitioners alike. Keep in mind that contact lens laboratories want you and your patients to be successful with their products and, as such, are a beneficial resource that should be explored. Consultants can help guide you through the fitting process and troubleshoot problems if and when they arise. Patients fit with scleral lenses are generally satisfied with the outcome, and those who wear lenses with multifocal optics are typically even more pleased. The age of multifocal scleral lenses has arrived. It's up to you to be a part of it. **cccl**

What Specular Microscopy Reveals About Your Patients

Visualizing the corneal endothelium aids in the diagnosis and management of myriad diseases.

By Daniel Epshtein, OD

The corneal endothelium is responsible for maintaining the delicate balance of stromal hydration to ensure adequate nutrition without sacrificing corneal clarity. The endothelium can be visualized by using specular reflection at the slit lamp. Though this technique is essential to the evaluation of the cornea, the slit lamp's limited magnification often makes it difficult to assess subtle endothelial changes.

Specular microscopy is a non-invasive imaging technique that produces high-magnification images of the corneal endothelium. These images can be analyzed qualitatively and quantitatively (using automated software) to help diagnose pathology, accurately monitor endothelial disease and aid in surgical comanagement.

CORNEAL ENDOTHELIUM

The corneal endothelium is a non-regenerative (though some evidence suggests that *in vivo* regeneration may be possible) single layer of cells comprising the most posterior portion of the cornea.¹ In a young and healthy individual, this monolayer is a relatively uniform mosaic of 500,000 hexagonally-shaped cells.²

The primary physiological purpose of the corneal endothelium is

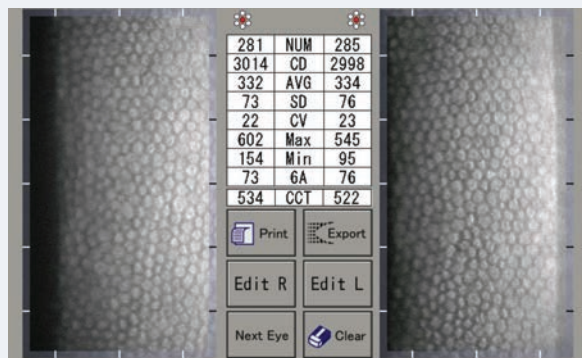
to create a porous barrier between the corneal stroma and aqueous humor.

Due to the cornea's avascularity, its nutrition is derived from passive diffusion of the tear film and aqueous humor into the cornea.²

To maintain proper corneal function, a relatively low amount of hydration is necessary, though the stroma tends to overhydrate under normal physiological conditions.

Overhydration of the stroma, clinically known as corneal edema, reduces corneal transparency and visual function. The passive flow of aqueous humor into the cornea is offset by active transportation via pumps in the corneal endothelium.

As endothelial cells age and slough off, neighboring cells stretch, relocate or fuse to maintain the leaky barrier. This process results in pleomorphism (cell shape variability) and polymegethism (cell size variability). Though both processes correlate with decreased corneal endothelial function, there is no direct relationship between the amounts of pleomorphism and polymegethism, suggesting that



A specular microscopy report of a normal 30-year-old male. Note the uniform hexagonal cells, high CD, low CV and high HEX/6A.

there is a variable structure-function relationship.³ The normal deterioration of the corneal endothelium can be accelerated by primary corneal endotheliopathies such as Fuchs' corneal dystrophy or secondary corneal endotheliopathies such as traumatic, surgical, contact lens-induced and inflammatory.

ABOUT THE AUTHOR



Dr. Epshtein practices in the ophthalmology department of Mount Sinai St. Luke's in New York. Previously, he held a position in a high-volume multispecialty ophthalmology practice where he supervised fourth-year optometry students as an adjunct assistant clinical professor of the SUNY College of Optometry. His research focuses on using the latest ophthalmic imaging technologies to elucidate ocular disease processes and to simplify equivocal clinical diagnoses.

SPECULAR MICROSCOPY

This diagnostic tool visualizes the corneal endothelium by taking advantage of specular reflection at the interface between the endothelium and the aqueous humor. This is accomplished with white light, similar to that used in slit lamp biomicroscopy, and a high magnification microscope. Only light at a specific plane (the plane of the endothelium) is captured, so any irregularities in the smooth planar surface of the endothelium are seen as hyper-reflective (more reflective) or hypo-reflective (less reflective) areas.

Hyper-reflective areas can signify inflammatory cells while hypo-reflective areas (which are more common) can denote guttata, endothelial pigment or endothelial swelling. Most specular microscopes also measure the central corneal thickness, which can serve as a biomarker of corneal endothelial function.

After imaging, an automated algorithm segments and counts the endothelial cells. From this, the specular microscope generates various indices that aid in the diagnosis and management of corneal disease. The cell density (CD), coefficient of variation (CV), variability

in hexagonal shape (HEX) and central corneal thickness (CCT) are the most important indices when evaluating for endotheliopathies.

CORNEAL ENDOTHELIOPATHIES

The quantitative and qualitative analysis of specular microscopy images can help in the diagnosis and management of various corneal endotheliopathies:

Age-related endothelial degeneration. As the cornea ages, the normal loss of endothelial cells with resultant pleomorphism and polymegethism can be detected. Guttata are often present and usually increase in number and size with time. Without disease or injury, age-related degeneration will not lead to corneal decompensation. The CD will decrease at a rate of 0.6% per year but never below the critical density of 300 to 600cells/mm² (Table 1). The CV will increase and the HEX/6A will decrease as well, but no appreciable corneal edema should be detected clinically or with serial CCT. Due to commonly comorbid cataracts, age-related corneal endothelial degeneration should be assessed to determine the risk of corneal decompensation with cataract surgery.

Table 1. Expected Cell Density Based on Decade of Life

Age	Average CS (cells/mm ²)
10-19	2,900-3,500
20-29	2,600-3,400
30-39	2,400-2,300
40-49	2,300-3,100
50-59	2,100-2,900
60-69	2,000-2,800
70-79	1,800-2,600
80-89	1,500-2,300

Fuchs' endothelial corneal dystrophy. This is a non-inflammatory bilateral corneal endothelial dystrophy characterized by progressive corneal endothelial degeneration and guttata. This condition is autosomal dominant but can be due to a sporadic mutation as well; the genetics are not well identified.² The guttata in Fuchs' endothelial corneal dystrophy tend to be central, with peripheral guttata appearing later in the disease process.

Early in the disease, patients may complain of poor vision or glare in the morning, which resolves by the early afternoon. This variation in vision is due to the decreased tear film evaporation with prolonged eyelid closure (during sleep), which

Release Date: September 15, 2019
Expiration Date: September 15, 2022
Estimated time to complete activity: 1 hour

Jointly provided by Postgraduate Institute for Medicine and Review Education Group.



Educational Objectives: After completing this activity, the participant should be better able to:

- Evaluate the corneal endothelium, and be able to differentiate between normal endothelial structure vs. abnormal endothelial structure.
- Identify the symptoms of moderate to advanced endothelial disease, such as blurred vision, fluctuating vision, or permanent visual impairment.
- Explain the importance of endothelial cell density, and the reasons why it may change.
- Recognize the characteristics of different corneal endotheliopathies using specular microscopy, including corneal guttata, Fuch's endothelial dystrophy, age-related endotheliopathy, contact lens-induced endotheliopathy, and others.

Target Audience: This activity is intended for optometrists engaged in the care of patients with a compromised corneal endothelium.

Accreditation Statement: In support of improving patient care, this activity has been planned and implemented by the Postgraduate Institute for Medicine and Review Education Group. Postgraduate Institute for Medicine is jointly accredited by the Accreditation Council for Continuing Medical Education, the Accreditation Council for Pharmacy Education, and the American Nurses Credentialing Center, to provide continuing education for the healthcare team. Postgraduate Institute for Medicine is accredited by COPE to provide continuing education to optometrists.

Faculty/Editorial Board: Daniel Epshtein, OD, Mount Sinai St. Luke's, New York, NY.

Credit Statement: This course is COPE approved for 1 hour of CE credit. Course ID is **64430-AS**. Check with your local state licensing board to see if this counts toward your CE requirement for relicensure.

Disclosure Statements:

Dr. Epshtein: Has received fees for non-CME/CE services from Carl Zeiss Meditec.

Managers and Editorial Staff: The PIM planners and managers have nothing to disclose. The Review Education Group planners, managers and editorial staff have nothing to disclose.



WHAT SPECULAR MICROSCOPY REVEALS ABOUT YOUR PATIENTS

increases hydration of the cornea. This physiological corneal edema, which occurs in all individuals, cannot be compensated for by the reduced function of the endothelium. As Fuchs' dystrophy progresses, endothelial function decreases and the corneal edema worsens.

Decreasing CD and HEX/6A and increasing CV will be noted before corneal edema is detected clinically or with serial CCT. As the CD and HEX/6A continue to decrease, and the CV and the number of guttata increase, the cornea decompensates and corneal edema is noted. This leads to significant fluctuation in vision and reduced vision. Even

without the presence of corneal edema, guttata can lead to glare and subjectively reduced vision.^{5,6} It is important to monitor the CCT during serial imaging to detect corneal edema. Though the CD, CV, HEX/6A and appearance of the corneal endothelium are related to the risk of corneal edema, a perfect structure-function relationship does not exist. Corneal edema can occur with seemingly moderate specular microscopy changes and may not occur with advances changes.

Posterior polymorphous dystrophy. This non-inflammatory bilateral corneal endothelial and Descemet's membrane dystrophy

is characterized by epithelial-like cells within the endothelium. This condition is autosomal dominant and is usually diagnosed during early to mid-childhood due to the presence of corneal opacities, edema and blurred vision. The pathology noted on presentation is usually nonprogressive or slowly progressive.

Clinically, these patients will have various blue-gray lesions of the endothelium that can be round, confluent, isolated or band-like. Specular microscopy will reveal irregular cells with scalloped edges that do not resemble the normal uniform hexagonal mosaic of endothelial cells.

Iatrogenic corneal endotheliopathy. Damage to the endothelium can occur with various intraocular surgeries. During routine cataract surgery, phacoemulsification energy directly damages the corneal endothelium. Intraoperative contact of the endothelium with various instruments or intracameral fluids can also lead to endothelial cell loss. Uncomplicated cataract surgery often leads to a 10% decrease in CD.⁷

Significant intraocular pressure spikes intraoperatively or perioperatively have been theorized as other possible etiologies of endothelial damage. Glaucoma drainage devices such as tubes or micro-stents have also been implicated in postoperative iatrogenic corneal endotheliopathy. Especially in patients with micro-stents, be sure to repeat specular microscopy periodically to evaluate corneal endothelial integrity.⁸

Preoperatively, it is important to clinically scrutinize the corneal endothelium to ensure there are no risk factors for postoperative corneal decompensation. Many surgeons and comanaging optometrists include specular microscopy

Specular Microscopy Indices Defined

Below is a quick summary on the various quantitative indices generated with specular microscopy.

Cell density (CD): The number of endothelial cells per mm². Cell density decreases with age and disease. When evaluating the cell density, it is important to consider age-expected values, as anything below the age-expected average value may be an indicator of underlying disease. Patients with a cell density less than 1,000 cells/mm² are at higher risk for developing pseudophakic bullous keratopathy.⁴ To maintain proper hydration of the cornea, 300 to 600 cells/mm² are necessary.² When cell density falls below this critical number, the balance of stromal hydration is tilted toward corneal edema and loss of corneal transparency.

Coefficient of variation (CV): Represents the amount of variation in cell size. The coefficient of variation is a measure of polymegathism, which occurs during corneal endothelial repair. A coefficient of variation less than 33 is considered normal. An elevated coefficient of variation is often considered an early sign of endothelial disease, as this is a marker of endothelial cell remodeling.


HEX or 6A: Represents the number of cells that have a hexagonal shape. Pleomorphism is the decrease of hexagonal cells within the corneal endothelium. As pleomorphism increases, the barrier function of the corneal endothelium decreases. A HEX or 6A less than 50% is considered abnormal.

Central corneal thickness (CCT): The central corneal thickness measured during image acquisition. A thickened central cornea may denote corneal edema and reduced endothelial function.

Number of cells counted (NUM): The number of cells counted in the analysis. Visualization of imaging of endothelial cells in diseased corneas may be difficult, so it is important that an adequate number of cells are included in the quantitative analysis.

Average cell area (AVG): Measurement of the average cell area. This number increases with age as polymegathism increases.

Standard deviation of mean cell area (SD): The standard deviation of mean cell area within the analysis.



Moderate (left) and advanced (right) Fuchs' corneal endothelial dystrophy. Note the asymmetric CCT of the patient on the right.

in their presurgical evaluation. Preoperatively, the presence of a low CD, low HEX/6A, numerous or confluent guttata or high CV is considered a risk factor for pseudophakic bullous keratopathy. In patients without endothelial disease, the rate of pseudophakic bullous keratopathy is 1% to 2%, but the rate increases to 14% in patients with a CD less than 1,000cells/mm².⁹

Patients who develop pseudophakic bullous keratopathy usually complain of glare and reduced vision, and they will have clinically appreciable corneal edema. The corneal edema in pseudophakic bullous keratopathy starts in the stroma but eventually leads to the formation of fluid-filled bullae within the epithelium and subepithelial space. These bullae are in direct contact with corneal nerves leading to sensations of pain, irritation and foreign body. The bullae can then burst, leading to epithelial breaks, which are extremely painful due to the exposure of corneal nerve endings. Cases that cannot be treated medically will have permanent vision loss and/or require penetrating or endothelial keratoplasty.

Postoperatively, pseudoguttata may be noted due to corneal edema

and inflammation. Pseudoguttata changes mimic guttata as seen in Fuchs' corneal endothelial dystrophy but are transient and related to anterior segment inflammation. Pseudoguttata resolve as the inflammation lessens. The hyporeflexive areas of pseudoguttata are not caused by actual structures extending from the cornea (such as guttata) but are due to cellular edema, which alters the planar surface of the endothelium, reducing reflection.

Inflammation. As with postoperative corneal endothelial changes, anterior segment inflammation such as uveitis or corneal endotheliitis can lead to pseudoguttata formation. These changes usually correlate with inflammation severity. Chronically, anterior segment inflammation can damage the corneal endothelium via immune pathway proteins or direct infiltration of inflammatory cells into the endothelium. Repeat episodes of anterior segment inflammation can lead to endothelial degeneration, reduced CD and HEX/6A, increased CV and an increased amount of guttata.

It is important to perform specular microscopy on patients with repeat inflammation because treatment regimens may need to be

altered if there is significant corneal endotheliopathy.

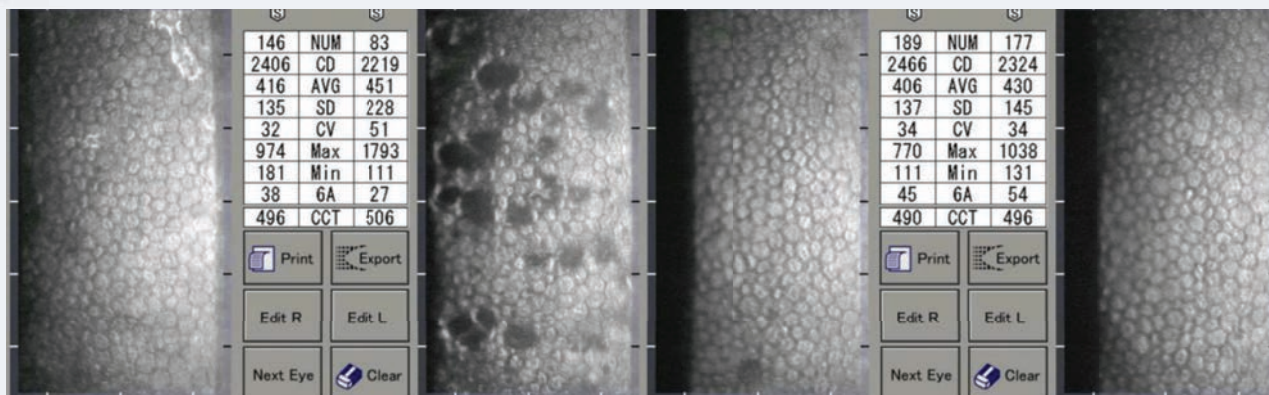
Trauma. Nonpenetrating trauma of the cornea can lead to corneal endothelial edema that resolves after several days. Acutely, the edema can be noted with biomicroscopy, but after resolution, corneal endothelial damage can usually only be detected with specular microscopy. A decreased CD is most often noted in areas of damage.

Glaucoma. Patients with glaucoma have been noted to have a lower CD and quicker rate of CD loss than age-matched norms.^{10,11} It's unclear whether the increased intraocular pressure directly causes these changes or if a metabolic insult, such as hypoxia caused by the increased intraocular pressure, is the culprit. Toxicity to topical antihypertensives has also been considered as a possible etiology.

Post-penetrating keratoplasty/ endothelial keratoplasty. Specular microscopy is essential in determining whether donor corneal tissue is adequate for transplantation and for annual (or more often) evaluation of graft endothelial structure and function. There is a dual-phase rapid loss of CD after corneal transplantation; a 7.8% per year CD decrease during the first three to five years and a 4.2% per year



WHAT SPECULAR MICROSCOPY REVEALS ABOUT YOUR PATIENTS



A patient with unilateral iritis OS. Note the resolution of the pseudoguttata and improvement in indices.

CD decrease in years six to 10.² As with Fuchs' corneal dystrophy, CD and HEX/6A decrease while CV and guttata presence increases.

CONTACT LENS-INDUCED ENDOTHELIOPATHY

Acutely, the insertion of contact lenses (especially scleral lenses) can create pseudoguttata or endothelial blebs. These blebs often disappear after minutes to hours, or with corneal adaptation to contact lens wear. These changes are always reversible with contact lens removal. Because similar changes occur during prolonged lid closure, researchers hypothesize that this is a hypoxic event.² The corneal endothelium swells, leading to changes similar to those in anterior segment inflammation.

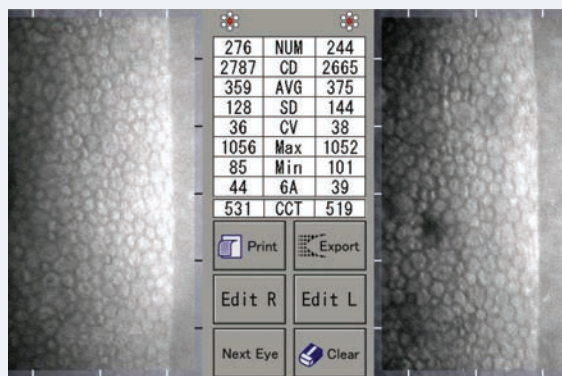Long-term contact lens wear leads to increased pleomorphism and

polymegethism, which correlates with decreased HEX/6A, increased CV and the presence of guttata. Chronic contact lens-induced endotheliopathy is much more common in low Dk lenses. The amount of corneal degeneration correlates with the length of wear.

Due to the corneal endothelium's nonregenerative nature, contact lens-induced endotheliopathy persists even after contact lens wear is discontinued or a higher Dk material is prescribed. Mild improvement in HEX/6A and CV may be noted after discontinuation of low Dk lenses, but this is due to a decrease in edema and improved visualization of the corneal endothelial mosaic. It is important to check specular microscopy in patients with a history of low Dk lens wear, blurred vision with contact lens wear, fluctuating vision or corneal edema.

A healthy corneal endothelium is imperative to corneal clarity and clear vision. Though visualization of the corneal endothelium is often inadequate with slit lamp biomicroscopy, specular microscopy is a useful, noninvasive modality

that can be easily incorporated into any optometric practice. The precise visualization of the corneal endothelium and the use of quantitative analyses aids in diagnosis and management of myriad corneal diseases in primary care practices, disease-oriented practices and those active in comanagement. **RCCL**



A 40-year-old patient with a history of low Dk contact lens use.

1. Van den Bogerd B, Dhuhghaill SN, Koppen C, et al. A review of the evidence for in vivo corneal endothelial regeneration. *Surv Ophthalmol.* 2018;63(2):149-165.
2. Copeland RA, Afshari NA, Dohlman, CH. Copeland and Afshari's Principles and Practice of Cornea. Vol. 1. New Delhi: Jaypee Brothers Medical Publishers; 2013.
3. Rao GN, Shaw EL, Arthur EJ, Aquavella JV. Endothelial cell morphology and corneal deturgescence. *Ann Ophthalmol.* 1979;11(6):885-99.
4. Corneal endothelial photography. Three-year revision. *American Academy of Ophthalmology. Ophthalmology.* 1997;104(8):1360-5.
5. Watanabe S, Oie Y, Fujimoto H, et al. Relationship between corneal guttae and quality of vision in patients with mild Fuchs' endothelial corneal dystrophy. *Ophthalmology.* 2015;122(10):2103-9.
6. Oie Y, Watanabe S, Nishida K. Evaluation of visual quality in patients with Fuchs endothelial corneal dystrophy. *Cornea.* 2016;35(Suppl 1):S55-S58.
7. Bourne RR, Minassian DC, Dart JK, et al. Effect of cataract surgery on the corneal endothelium: modern phacoemulsification compared with extracapsular cataract surgery. *Ophthalmology.* 2004;111(4):679-85.
8. FDA Safety Communication. Update: Potential eye damage from Alcon CyPass micro-stent used to treat open-angle glaucoma. www.fda.gov/medical-devices/safety-communications/update-potential-eye-damage-alcon-cypass-micro-stent-used-treat-open-angle-glaucoma-fda-safety. October 24, 2018. Accessed August 29, 2019.
9. Yamazoe K, Yamaguchi T, Hotta K, et al. Outcomes of cataract surgery in eyes with a low corneal endothelial cell density. *J Cataract Refract Surg.* 2011;37(12):2130-6.
10. Sihota R, Lakshmaiah NC, Titilal JS, et al. Corneal endothelial status in the subtypes of primary angle closure glaucoma. *Clin Exp Ophthalmol.* 2003;31(6):492-5.
11. Cho SW, Kim JM, Choi CY, Park KH. Changes in corneal endothelial cell density in patients with normal-tension glaucoma. *Jpn J Ophthalmol.* 2009;53(6):569-573.

CE TEST ~ SEPTEMBER/OCTOBER 2019

1. How many cells make up a healthy, young corneal endothelium?
 - a. >300,000 cells.
 - b. 3,500 cells.
 - c. 2,500 cells.
 - d. 1,000 cells.
2. The primary purpose of the corneal endothelium is:
 - a. To create Descemet's membrane.
 - b. To create nutrition for the cornea.
 - c. To control corneal hydration.
 - d. Refraction.
3. What is pleomorphism?
 - a. An increase in cell size.
 - b. An increase in cell shape variation.
 - c. A decrease in cell size.
 - d. A decrease in cell shape variation.
4. What is polymegethism?
 - a. An increase in cell size.
 - b. An increase in cell shape variation.
 - c. A decrease in cell size.
 - d. A decrease in cell shape variation.
5. Specular microscopy can measure all of the following, **except**:
 - a. Cell density.
 - b. Coefficient of variation.
 - c. Percentage of hexagonal cells.
 - d. Corneal endothelial pump function.
6. Specular microscopy takes advantage of reflection between the corneal endothelium and what other part of the eye?
 - a. Aqueous humor.
 - b. Descemet's membrane.
 - c. Tear film.
 - d. Iris.
7. Fuchs' corneal endothelial dystrophy can present with all of the following, **except**:
 - a. Vision loss.
 - b. Corneal edema.
 - c. HEX/6A of 100%.
 - d. Guttata.
8. Pseudoguttata changes can be associated with:
 - a. Anterior segment inflammation.
 - b. Fuchs' corneal endothelial dystrophy.
 - c. Posterior polymorphous dystrophy.
 - d. Age-related corneal endothelialopathy.
9. Specular microscopy findings in post-keratoplasty patients include all of the following, **except**:
 - a. Rapid decline of cell density.
 - b. Increasing pleomorphism and polymegathism.
 - c. Increasing HEX/6A.
 - d. Increasing CV.
10. Contact lens-induced corneal endotheliopathy is related to:
 - a. Lid closure.
 - b. Low Dk materials.
 - c. High Dk materials.
 - d. Lens rigidity.

EXAMINATION ANSWER SHEET

What Specular Microscopy Reveals About Your Patients

Valid for credit through September 15, 2022

Online: This exam can also be taken online at www.reviewsce.com. Upon passing the exam, you can view your results immediately and download a real-time CE certificate. You can also view your test history at any time from the website.

Directions: Select one answer for each question in the exam and completely darken the appropriate circle. A minimum score of 70% is required to earn credit.

Mail to: Jobson Healthcare Information, LLC, Attn.: CE Processing, 395 Hudson Street, 3rd Floor New York, New York 10014

Payment: Remit \$20 with this exam. Make check payable to: Jobson Healthcare Information, LLC.

Credit: This lesson is approved for 1 hour of CE credit. Course ID is 64430-AS.

Jointly provided by Postgraduate Institute for Medicine and Review Education Group.

Salus University has sponsored the review and approval of this activity.

Processing: There is a four-week processing time for this exam.

Answers to CE exam:

1. (A) (B) (C) (D)
2. (A) (B) (C) (D)
3. (A) (B) (C) (D)
4. (A) (B) (C) (D)
5. (A) (B) (C) (D)
6. (A) (B) (C) (D)
7. (A) (B) (C) (D)
8. (A) (B) (C) (D)
9. (A) (B) (C) (D)
10. (A) (B) (C) (D)

Post-activity evaluation questions:

Rate how well the activity supported your achievement of these learning objectives:

1=Poor, 2=Fair, 3=Neutral, 4=Good, 5=Excellent

11. Evaluate the corneal endothelium, and be able to differentiate between normal endothelial structure vs. abnormal endothelial structure. (1) (2) (3) (4) (5)
12. Identify the symptoms of moderate to advanced endothelial disease, such as blurred vision, fluctuating vision, or permanent visual impairment. (1) (2) (3) (4) (5)
13. Explain the importance of endothelial cell density, and the reasons why it may change. (1) (2) (3) (4) (5)
14. Recognize the characteristics of different corneal endotheliopathies using specular microscopy, including corneal guttata, Fuch's endothelial dystrophy, age-related endotheliopathy, contact lens-induced endotheliopathy, and others. (1) (2) (3) (4) (5)
15. Based upon your participation in this activity, do you intend to change your practice behavior? (choose only one of the following options)
 - (A) I do plan to implement changes in my practice based on the information presented.
 - (B) My current practice has been reinforced by the information presented.
 - (C) I need more information before I will change my practice.
16. Thinking about how your participation in this activity will influence your patient care, how many of your patients are likely to benefit? (please use a number) _____
17. If you plan to change your practice behavior, what type of changes do you plan to implement? (check all that apply)

(A) Apply latest guidelines	(B) Change in pharmaceutical therapy	(C) Choice of treatment/management approach
(D) Change in current practice referral	(E) Change in non-pharmaceutical therapy	(F) Change in differential diagnostics
(G) Change in diagnostic testing	(H) Other, please specify: _____	

18. How confident are you that you will be able to make your intended changes?

- (A) very confident
- (B) somewhat confident
- (C) unsure
- (D) not confident

19. Which of the following do you anticipate will be the primary barrier to implementing these changes?

- (A) Formulary restrictions
- (B) Time constraints
- (C) System constraints
- (D) Insurance/financial issues
- (E) Lack of interprofessional team support
- (F) Treatment related adverse events
- (G) Patient adherence/compliance
- (H) Other, please specify: _____

Rate the quality of the material provided:

- 1=Strongly disagree
 2=Somewhat disagree
 3=Neutral
 4=Somewhat Agree
 5=Strongly agree

21. The content was evidence-based. (1) (2) (3) (4) (5)
22. The content was balanced and free of bias. (1) (2) (3) (4) (5)
23. The presentation was clear and effective. (1) (2) (3) (4) (5)

20. Additional comments on this course: _____

Identifying information (please print clearly):

First Name _____
 Last Name _____
 Email _____
 The following is your: Home Address Business Address
 Business Name _____
 Address _____
 City _____ State _____
 ZIP _____
 Telephone # _____ - _____ - _____
 Fax # _____ - _____ - _____

By submitting this answer sheet, I certify that I have read the lesson in its entirety and completed the self-assessment exam personally based on the material presented. I have not obtained the answers to this exam by fraudulent or improper means.

Signature: _____ Date: _____
 Please retain a copy for your records. LESSON 118656, RO-RCCL-0919

Keep an Eye Out

Lisch corneal dystrophy is rare, but its unique appearance aids in its diagnosis.

A 49-year-old male was referred for an evaluation of a corneal problem he had in his right eye. He had been seen recently for a routine evaluation by his primary OD who thought he should make an appointment at a cornea clinic. The patient had no concerns with his vision or comfort and was simply following up on his doctor's orders.

PRELIMINARY TESTING

Entrance testing showed spectacle corrected vision of 20/20 OU. The patient had a full range of motility with extraocular muscle function, a full confrontation field, normal pupils and intraocular pressures of 14mm Hg OD and 15mm Hg OS.

The slit lamp exam of the patient's left eye was normal. His right eye was normal with the exception of the cornea, which was remarkable. The patient had a grayish feathery zone of anterior corneal tissue, which progressed from his 4 o'clock limbus to just below his visual axis in a whorled pattern. A thin optic section localized the irregularity in the epithelial layer. On close scrutinization, the lesion appeared to be a confluence of microcystic changes. The lesion did not stain positively or negatively with sodium fluorescein.

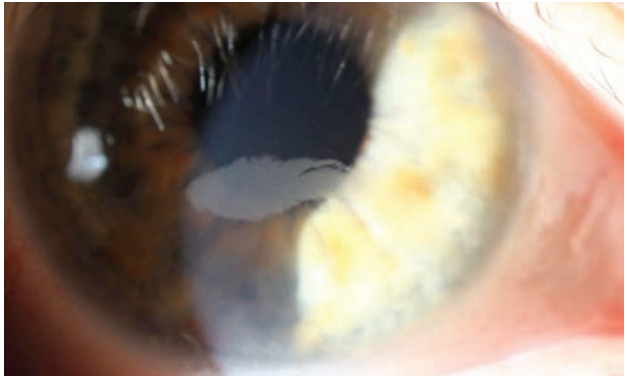
Corneal topography showed a small area of steepening near the corneal irregularity, though it was mild and outside of the visual axis, and a negative posterior elevation close to the lesion. Interestingly, even though the lesion was in the far anterior cornea, there was no corresponding zone of anterior elevation abnormality.

THE PROBLEM

My assessment was Lisch corneal dystrophy in the right eye on the basis of clinical evaluation alone. I asked the patient about his family history, which was unremarkable. As he was asymptomatic, I did not offer him treatment and asked him to follow up in six months.

Lisch corneal dystrophy, sometimes referred to as band-shaped, whorled microcystic corneal dystrophy, is a relatively recently recognized corneal dystrophy, having first been described in 1992, and is currently recognized in the epithelial/subepithelial group by the International Classification of Corneal Dystrophies.^{1,2} It is characterized as a unilateral or bilateral condition that affects the corneal epithelial tissue sectorally.

The lesions are gray and feathery in appearance and frequently present in a whorled pattern. Upon high magnification slit lamp examination, the lesions appear to be clusters of microcystic epithelial tissue. These cystic changes are most prominent on retroillumination. Given the whorled pattern sweeping from the limbus centrally, the condition looks somewhat like limbal stem cell dysfunction or advancing wavelike epitheliopathy. The involved epithelium in these other pathologies, however, tends to be coarse and gray rather than cystic.



The lesion is connected to the 4 o'clock limbus. Note the cystic appearance, which is most obvious at the margins.

On histology, light microscopy of the involved epithelium shows remarkable vacuolization of the cytoplasm of the cells, which are mostly optically empty.³ Pedigree analysis suggests the dystrophy is inherited in an X-linked dominant fashion.

Though there has been debate on whether it represents a truly unique corneal dystrophy and is not just a limited subtype of Meesmann microcystic corneal dystrophy, genetic analysis demonstrates abnormalities in different chromosomes of each dystrophy, indicating they are separate entities.⁴

Reduction of acuity predictably results when the visual axis is involved. Though mild topographic changes may accompany Lisch corneal dystrophy, its effects on vision are driven more by the ensuing opacification of the cornea rather than the induction of irregular astigmatism. Unlike the other anterior corneal dystrophies (most notably, epithelial basement membrane and Meesmann), patients with Lisch do not develop corneal erosions.⁴



SOLUTIONS

Best practices for the treatment of Lisch dystrophy have not been established. Obviously, asymptomatic patients don't need intervention beyond observation. For patients who are bothered by their vision, daily contact lens use may induce some degree of lesion regression, though this is temporary with the lesion returning on cessation of lens wear. This phenomenon has also been reported in patients with Meesmann corneal dystrophy or Fabry disease. Transient contact lens-induced epithelial thinning and hypoxia ruse may be responsible.⁵

For those with more severe pathology, debridement is effective in eliminating the dystrophic epithelium. This debridement may be paired with mitomycin-C (MMC) application; however, recurrence has been shown to occur frequently with or without MMC use. Recognizing that the whorled

appearance and tendency for the dystrophy to recur in the same zone following debridement suggests limbal involvement. Researchers paired debridement with focal limbal cautery of the involved limbus in an eye with Lisch dystrophy that had recurred twice with debridement alone. This treatment resulted in clearance of the dystrophy, with no subsequent recurrence over two years, though its application should be limited to small areas of the limbus given the ramifications of damaging large zones of limbal tissue.⁶

Lisch corneal dystrophy is a newly described entity and may not be too familiar to many of us in practice. Indeed, in my practice, despite over 60 years of cumulative experience, neither corneal specialist I work with nor my colleague or I had seen a case of Lisch dystrophy in our careers prior to this patient.

Interestingly, in the last 18 months alone, we have seen three non-related cases. Though many providers are not knowledgeable about the dystrophy, its very unique appearance being cystic, epithelial and whorled—which, in my experience, is unlike any other corneal pathology—aids in its diagnosis. **RCCL**

1. Lisch W, Steuhl KP, Lisch C, et al. A new, band-shaped and whorled microcystic dystrophy of the corneal epithelium. *Am J Ophthalmol.* 1992;114(1):35-44.
2. Weiss JS, Møller HU, Aldave AJ, et al. IC3D Classification of Corneal Dystrophies—Edition 2. *Cornea.* 2015;34(2):117-59
3. Alvarez-Fischer M, Álvarez de Toledo J, Barraquer RI. Lisch corneal dystrophy. *Cornea.* 2005;24(4): 494-5.
4. Lisch W, Büttner A, Oeffner F, et al. Lisch corneal dystrophy is genetically distinct from Meesmann corneal dystrophy and maps to xp22.3. *Am J Ophthalmol.* 2000;130(4):461-8.
5. Lisch W, Wasielica-Poslednik J, Lisch C, et al. Contact lens-induced regression of Lisch epithelial corneal dystrophy. *Cornea.* 2010;29(3):342-5.
6. Salvador-Culla B, Alonso-Agosta M, Álvarez de Toledo J, et al. Combined keratectomy and localized limbal cauterization for treating Lisch epithelial corneal dystrophy. *Cornea.* 2019;38(2):243-5.

11th Annual

OPTOMETRIC GLAUCOMA SYMPOSIUM

Join our faculty of renowned ODs, MDs, and PhDs for a highly interactive meeting covering the most up-to-date information in glaucoma care. **Earn up to 12 CE credits***

Earn up to
**12 CE
Credits***

PROGRAM CO-CHAIRS



Murray Fingeret, OD, FFAO



Robert N. Weinreb, MD



EAST COAST

October 4-5, 2019

Baltimore, Maryland

Renaissance Baltimore Harborplace Hotel

Discounted room rate: \$169**

REGISTER ONLINE: www.reviewscce.com/ECOGS2019



WEST COAST

December 13-14, 2019

Huntington Beach, California

Hyatt Regency Huntington Beach

Discounted room rate: \$239**

REGISTER ONLINE: www.reviewscce.com/WCOGS2019

REGISTER BY PHONE: 877-451-6514 **BY E-MAIL:** reviewmeetings@jhihealth.com **MORE INFO:** www.reviewscce.com/events

The Work-around

Don't let conjunctival obstacles get in the way of scleral lens success.

Today we can employ a growing repertoire of lens modifications and fitting strategies to maneuver scleral lenses around conjunctival and scleral obstacles. This case highlights a patient with a pair of conjunctival obstacles and provides a step-by-step approach to achieving a comfortable, healthy lens fit in similar patients.

THE CASE

A 69-year-old female was referred for a scleral lens fitting. She had a history of high frequency, bilateral filamentary keratitis recalcitrant to topical management. The disease was highly asymmetric, with the left eye experiencing more frequent and numerous filaments than the right. Scleral lenses are becoming more regularly indicated to help manage ocular surface disease.

The patient preferred to be fit with a scleral lens in her left eye and continue with topical management in her right due to her hesitation toward handling scleral lenses and her guarded optimism for success based on previous failures with therapy.

The patient's uncorrected visual acuities were 20/20 OU. She had clear lids and lashes, a clear cornea and a deep and quiet anterior chamber. I noted centered posterior chamber intraocular lenses with open capsules OU. She also had a clear conjunctiva OD; however, I observed a multi-lobulated, flesh-toned lesion inferior nasal to the limbus in her left eye. The referring cornea specialist had determined these lesions to be nonmalignant and was reluctant to remove them, citing the risk for exacerbation of ocular surface disease following ocular surface surgery.

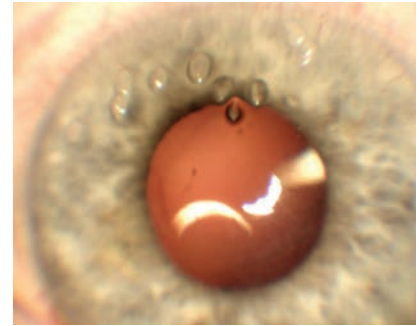
DIAGNOSTIC FITTING

I used a 15.80mm Custom Stable Elite lens (Valley Contax) to perform a diagnostic fitting. I selected this diameter to provide complete corneal coverage while minimizing interaction with the patient's conjunctival obstacles. This lens features a toric scleral zone to offer optimal stability, centration and comfort.^{1,2} The lens was -2.00/43.00/15.80 OS with standard limbal and scleral zones of +5 (flat)/-2 (steep).

An over-refraction of +4.25D yielded 20/20 vision. After settling, the central clearance was 200µm with a limbal clearance of 25µm and scleral alignment 360°. The lens was positioned with the flat meridian along the vertical meridian. The edge of the lens was in contact with the conjunctival nodules. Due to being semi-mobile, the nodules were displaced nasally by the lens edge, creating blanching of the surrounding tissue. Based on the multi-lobulated nature, width and height of the conjunctival nodules, I chose to proceed with an edge notch.

NOTCH DESIGN

The design of a lens notch is often enhanced by clinical experience and intuition; however, following a few guiding principles can significantly improve your chance of success. First, measure the distance of the lesion from the limbus to help determine how far into the lens the scleral notch should extend. Second, measure the widest portion of the lesion expected to interact with the lens edge. For our patient, the nodules were located 1.50mm outside of the limbus and measured 4.00mm at their widest point.



Imaging of the superior cornea shows several visible filaments.

To determine the depth of the lens notch, first subtract the horizontal visible iris diameter (HVID) from the diameter of the lens and divide the resulting number by two. Upon subtracting the patient's HVID (11.80mm) from the lens diameter (15.80mm) and cutting the number in half, I found that her lens coverage, or expected distance the lens would extend beyond the limbus, was 2.00mm.

Next, subtract the distance the lesion is located from the limbus from the lens coverage (2.00mm-1.50mm) to find the notch depth (0.50mm). Based on the diagnostic fitting, this starting point can be modified as needed. If significant decentration is unavoidable, you may need to adjust the depth of the notch accordingly.

To compensate for the curved shape of a notch while avoiding larger obstacles, additional depth may be needed. In this case, the width of the lesion was relatively large at 4.00mm, so I added an additional 0.25mm to my notch depth to avoid interacting with the entire width of the nodules. I have found that adding 0.50mm to 1.00mm allows for optimal avoidance of the lesion.



The final specification is the location on the lens the notch should be placed. When working with a toric scleral landing zone, the location of the notch must be specified in accordance with the lens's rotation on the eye. Each lens manufacturer may advise a point of reference for this measurement. For the lens design used in this case, the reference points are the flat meridian markings. I used my slit beam to measure the degrees from the reference points to where I wanted the middle of the notch to be. The lab then uses that information to design the rest of the notch.

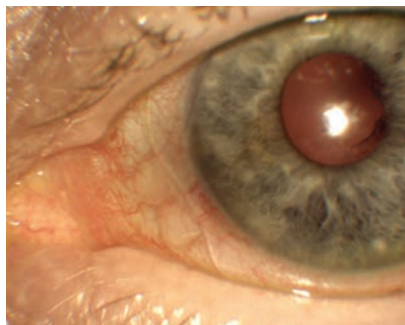
Based on my fitting and pre-fitting measurements, I ordered the following lens: +4.50/43.00/15.80 OS with standard limbal and scleral zones [+5 (flat)/-2 (steep)] with a notch 0.75mmx5.00mm centered 50° counterclockwise.

ORIGINAL DISPENSING

The patient returned three days later with new onset severe pain in the left eye, foreign body sensation, tearing and photophobia. Her slit lamp exam revealed 20 superior filaments. I removed the filaments without complication and sent the patient home in a soft bandage contact lens with antibiotic coverage.

DISPENSING REDO

The patient came back three days later with complete resolution of her previous symptoms. Following removal of the bandage lens, the cornea was deemed intact and the patient ready for dispensing. Upon insertion, the scleral notch abutted the conjunctival lesions without displacing them. The remainder of the fit was consistent with the diagnostic



Imaging displays appropriate notch size and location.

fitting. Based on the patient's propensity for rapid filament formation, I advised her to gradually increase lens usage from eight to 10 hours of daily wear on the day of dispensing to 12 to 16 hours of daily wear.

FOLLOW-UP

The patient returned to the clinic a week later having already worn the lens for six hours at the time of her visit. She reported excellent comfort and denied any new surface complications. The lens fit was unchanged from dispensing aside from an anticipated decrease in central clearance from 200µm to 150µm.

The patient had continued comfort in her scleral lens without any recurrences of her filamentary keratitis in her left eye throughout the following month. Her cornea and conjunctival tissue supported the lens well with no adverse signs noted.

DISCUSSION

Three primary strategies exist to address conjunctival obstacles in patients requiring scleral lenses. Occasionally, we can employ a small-diameter lens that lands between the lesion and the limbus. By selecting a smaller lens, we may

be able to avoid interacting with the lesion entirely. When this is not feasible, we are left deciding between an edge vault and a notch. Vaults allow for a controlled area of the lens to be lifted up and over conjunctival obstacles without having to remove a portion of the lens. They are designed to land in alignment with the conjunctival tissue and distribute weight evenly over the lesion. Vaults are created by the lathe during lens fabrication, allowing for a higher degree of precision and specification. This, however, also limits their size and depth, according to the limitations of modern lathing systems.

Unlike vaults, notches are created with hand-held tools. This inherently trades the specificity of a vault for more flexibility in size and depth. Notches are excellent for wider lesions, non-uniform or multi-lobulated lesions and lesions of greater height. In addition, tissues that are more prone to rapid change or are thinner and more delicate (i.e., filtering blebs, shallow-filtering tube coverage) may benefit from the complete avoidance of interaction offered by a notch.

While these fitting strategies often take on a trial and error approach, the severity and rapidity of filament formation in this patient reminds us that time is of the essence in patients with severe ocular surface disease. By following a few fundamental steps, we can get our patients the lenses they need as quickly and efficiently as possible and increase our likelihood of success. **RCLC**

1. Visser ES, Van der Linden BJ, Otten HM, et al. Medical applications and outcomes of bitangential scleral lenses. *Optom Vis Sci.* 2013;90(10):1078-85.
2. Visser ES, Visser R, van Lier HJ, et al. Modern scleral lenses part II: patient satisfaction. *Eye Contact Lens.* 2007;33(1):21-5.

Success Starts With Communication

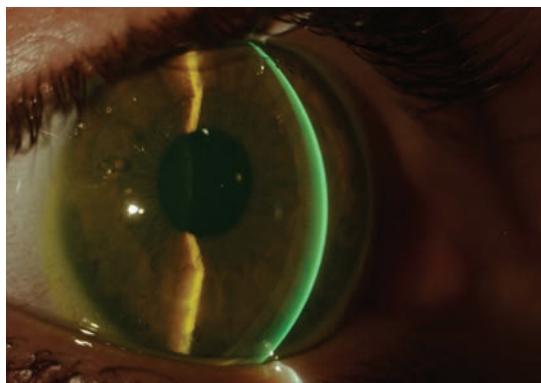Sclerals are their own type of lens and must be presented accordingly to set realistic patient expectations right off the bat.

Between the two of us, we have been fitting scleral lenses for over 25 years. We have encountered the steepest corneas, the worst LASIK ectasias, the flattest plateaus and the driest eyes. We've found that having a working laboratory partnership is critical to our scleral lens success. Equally important is completing training, being skilled and paying attention to detail to provide our patients good health, comfort and clarity.

Sclerals are unlike any lens a patient has seen or worn before. Maybe some have heard of them. Others can only imagine what they're like. But everyone is always shocked by how big the lenses actually are, even if they've been previously warned. As such, the initial insertion of the lens is always associated with a level of trepidation. These patients are encountering something alien to them that comes with a brand new set of wear and care instructions. We've learned that if you want to maximize your success and patient's outcomes, you need to start with proper communication and education.

LENS PRESENTATION

Performing scleral lens workshops around the country, we have observed hundreds of practitioners learning how to fit and evaluate contact lenses, but one crucial area that is often missed, even by us, is



Scleral lenses can make a world of difference once a patient is educated thoroughly.

teaching how to explain the lenses. Consequently, most practitioners use the lens itself to educate the patient, who, at this point, is too busy trying to comprehend how they'll be able to get the lens in their eye to hear a single word the practitioner is saying.

We have found that new patients perceive scleral lenses differently than conventional cornea-fit contact lenses, so, as such, it may be helpful to refer to them in a different way—as a device. It's important to make sure the patient can visualize the lens before you actually show them what it looks like by telling them that it will cover nearly all of their visible eye, including the white part. Generally, we tend to be more accepting of things, especially things we've never seen before, if we understand them first, and giving patients a good explanation of what a scleral lens is ahead of time may help reduce anxiety.

Next, we like to explain how the

lens works. Let the patient know that the larger surface of the lens vaults over the top of the cornea or, in most cases, the irregular part of their eye, and is filled with a moisturizing solution that is used when putting the lens in.

Lastly, we discuss insertion and removal methods with the patient. Explain that since scleral lenses are larger than conventional contact lenses, they require some simple tools to help get them in and out

of the eye. Then show them how to use these tools. We give patients several tools and have more at the office if they need them.

LENS FITTING

Now, it's time for the lens fitting. To start, we offer the diagnostic trial lens that we intend to place on the patient's eye to them to get them comfortable. We reassure them that the lenses are safe and comfortable, and, in the case that they are not, we make modifications. Clarify that diagnostic lenses are demonstration or fitting devices and are not intended to match the patient's prescription or correct their vision.

Once the patient is ready, we show them how to clean the lens, place it on the insertion device and fill it with solution. Then we demonstrate on our own eyes how we will hold their eyelid to insert the lens. It's important that the patient looks straight ahead when we place the lens on their eye. Once



we ensure there are no bubbles in the lens, we have the patient close their eye and let us know what the lens feels like.

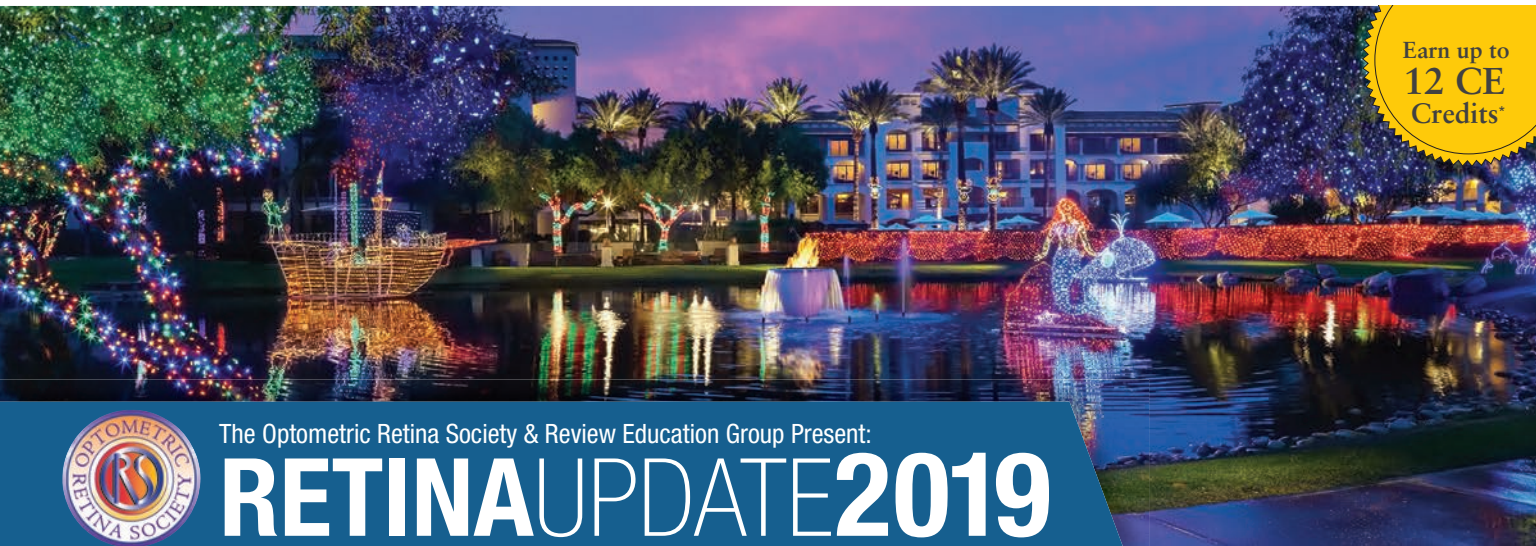At this point, different practitioners proceed in different fashions. Some check the fit with an OCT, while others use a slit lamp. Regardless of the method you choose, talk your patient through what you're doing and reassure them, especially if they are not finding the lens to be comfortable. Once the ideal fit is achieved, it is time for the over-refraction. Some practitioners only do spherical over-refractions and use over-glasses for cylinder and presbyopic correction. Others do spherocylindrical

over-refractions and put the cylinder in the lens. We strongly suggest not making any claims or promises about the patient's final vision based on the over-refraction. With lens settling, fogging and other complications that can arise, it is best to set expectations at a point when you can confidently say you've met your objective.

Some practitioners allow the patient to remove the lens after the initial insertion, while others like to remove it for them. We see the value in both and proceed based on the patient's demeanor. If the patient is comfortable with it, we allow them to remove the lenses to show them how easy it is and to

start removal training. However, if the patient shows signs of nerves or anxiety about the lenses or the fitting process, we elect to remove the lenses on their behalf to avoid overcomplicating the rest of the process.

The initial presentation and fitting of scleral lenses sets the tone for a patient's entire experience with them. Whether a patient is willing to try the lenses, how much effort they put into wearing them and their perceptions toward them all start here. If we can reduce a patient's anxiety and motivate them upfront, success becomes much more attainable. **RCCL**



Earn up to
**12 CE
Credits***



The Optometric Retina Society & Review Education Group Present:

RETINAUPDATE2019

DECEMBER 6-7, 2019 • SCOTTSDALE, AZ

Fairmont Scottsdale Princess 7575 E. Princess Drive, Scottsdale, AZ 85255

Limited rooms reserved at **\$269/night** + tax. Please call 480-585-4848 and mention "Review's Optometric Retina Society Meeting" for group rate.

Program Chair: Mohammad Rafieetary, OD, FAAO

Program Co-Chair: Steven Ferrucci, OD, FAAO

Early Bird Registration Cost: \$375

Early Bird pricing ends October 4, 2019



Review Education Group partners with Salus University for those ODs who are licensed in states that require university credit. *This activity, COPE Activity Number 117855, is accredited by COPE for continuing education for optometrists. Approved by the Florida Board of Optometry.

THREE WAYS TO REGISTER:

Online: www.reviewsce.com/ORSRetUpdate2019

E-mail: reviewmeetings@jhihealth.com

Call: 800-999-0975



A Dark Diagnosis

Iris melanoma patients face tough choices—and more so when the other eye is impaired, too.

A 93-year-old female presented with a suspicious conjunctival lesion in her left eye. Ocular history was significant for posterior chamber lenses in both eyes, status post YAG laser OD and posterior capsule opacification OS. She is being treated for bilateral macular degeneration, with significant vision loss OD. She had a bout of iritis OD two years prior and is currently taking hydroxychloroquine for rheumatoid arthritis.

Her entering visual acuities were counting fingers at one foot in the right eye and 20/30-2 in the left eye.

On exam, her left eye was noted to have a 2mm x 1.4mm deeply melanotic perilimbal lesion at 7:30 with no overlying vascularity. The iris showed an inferior sectoral melanotic nevus extending from the periphery to the pupillary edge with distortion

of the pupil. She also had melanotic lesions in the peripheral iris.

Gonioscopy revealed pigmented lesions invading the angle in the temporal, nasal and inferior quadrants. With echography the lesions were highly reflective, solid and involving almost all the posterior iris surface, with extensive inferior angle involvement. Her cornea showed mutton fat keratic precipitates.

Management options for the iris melanoma (brachytherapy, enucleation, observation) were discussed at length. Considering her age, unilateral vision and risk of vision loss from intervention, she opted to observe without treatment but will consider a metastatic work up.

Uveal melanoma is the most common intraocular tumor (incidence is 1:100,000).¹ Iris melanoma is largely a clinical diagnosis made with biomi-

croscopy; echography and anterior segment OCT are also helpful.

The Collaborative Ocular Melanoma Study found 34% of patients with uveal melanoma will develop metastatic disease within 10 years of diagnosis and 80% of those with metastatic disease will die within one year.² Chemotherapy, immunotherapy and small-molecule biologics have not improved survival rates. There is no standard of care treatment for uveal metastasis. Primary iris melanomas are most commonly treated by enucleation or radiation; both have similar survival outcomes. **RCCL**

1. Schank T, Hassel JC. Immunotherapies for the treatment of uveal melanoma—history and future. *Cancers*. 2019;11(8):1048.

2. Diener-West M, Reynolds SM, Agugliaro DJ, et al. Development of metastatic disease after enrollment in the COMS trials for treatment of choroidal melanoma: collaborative ocular melanoma Study Group report No. 26. *Arch Ophthalmol*. 2005;123:1639-43.



WHEN IT COMES TO GAS PERMEABLE LENS MATERIALS,

MAKE IT WITH BOSTON[®]



Available for use with
Tangible[®] Hydra-PEG[®]
coating technology for
enhanced lens wettability



tangible[®]
HYDRA-PEG[®]

Ask your lab for Boston[®] Materials today.

Visit bauschsvp.com for Important Safety Information.

Boston, Boston XO, Boston XO₂, Boston EO, Boston ES, Equalens, and Quantum are trademarks of Bausch & Lomb Incorporated or its affiliates. Tangible and Hydra-PEG are trademarks of Tangible Science, LLC used under license.

©2019 Bausch & Lomb Incorporated or its affiliates. BNL.0044.USA.19

Technology in balance



Health




Vision



Comfort

Miru 1 month: a unique family of silicone hydrogel monthly lenses.

MeniSilk™ and Nanogloss™ technologies designed to meet the demands of today's contact lens wearer.*



Material and surface technologies

MeniSilk™

- Ultra high Dk/t - 161 @ -3.00D
- Exceptional hydration
- Optimized transparency

Nanogloss™

- Super smooth surface
- Resistance to bacteria
- Excellent wettability



www.meniconamerica.com

*Menicon data on file April 2016

