

RCCL[®]

REVIEW OF CORNEA
& CONTACT LENSES

JANUARY/FEBRUARY 2019

CORNEAL
SURGERY
ISSUE

KERATOPLASTY: When and Why

Discover how long to monitor and treat symptoms before considering surgical interventions, PAGE 16

- GPs: A Reliable Post-PK Option, PAGE 8
- The Art of Corneal Transplantation, PAGE 20
- Post-cataract Surgery Inflammation: A Toxin or a Bug?, PAGE 26
- Transplantation for Limbal Stem Cell Deficiency, PAGE 30
(earn 1 CE credit)

ALSO: NEW LENSES FOR 2019 • MYOPIA CONTROL • CYL ADVICE • ANTERIOR STAPHYLOMA

INTRODUCING

Next Generation Hypochlorous Acid

Essential Daily Dry Eye Management

• HyClear™ is Pure.

With the antimicrobial activity* of pure hypochlorous acid .01%, HyClear™ is a non-cytotoxic, non-irritating solution.

• HyClear™ is Affordable.

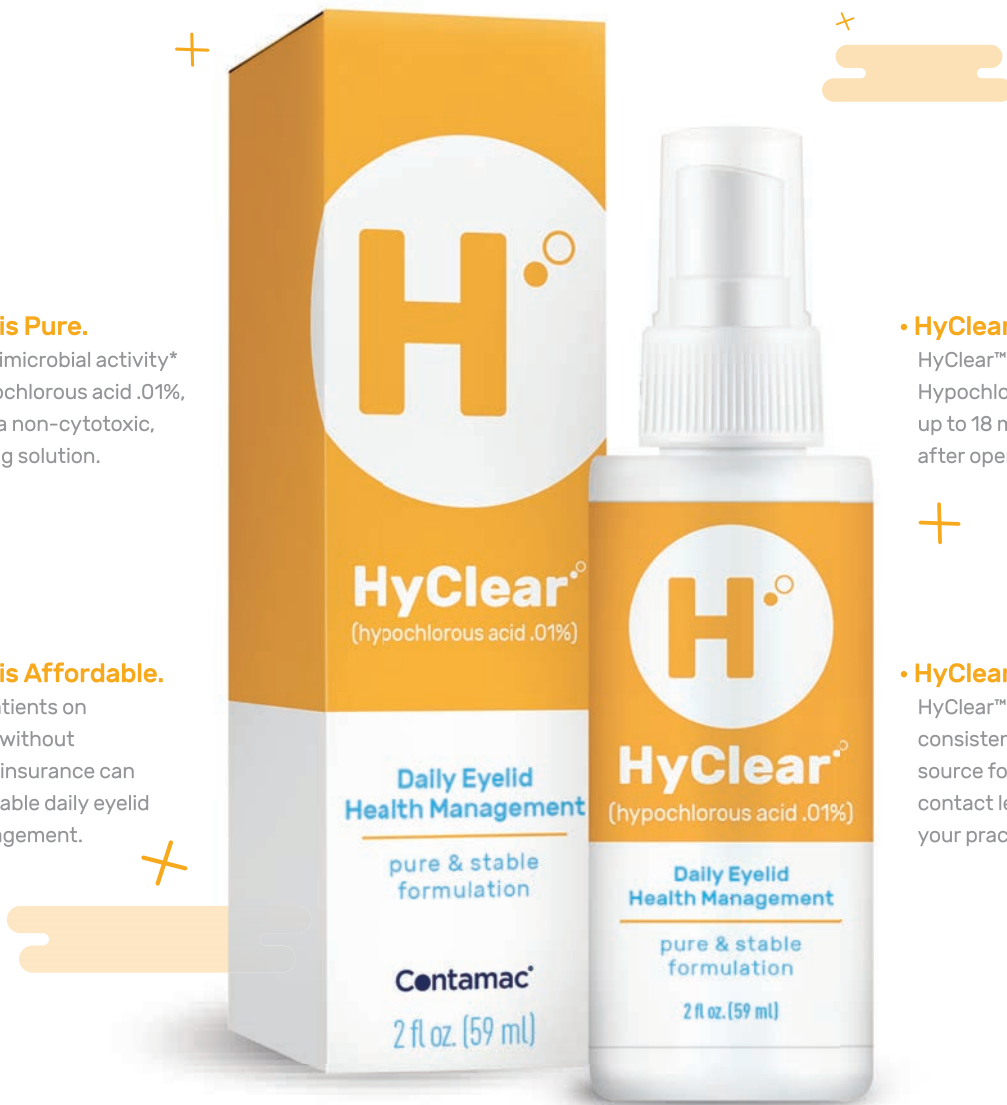Now your patients on Medicare or without commercial insurance can enjoy affordable daily eyelid health management.

• HyClear™ is Stable.

HyClear™ (Balanced Analytic Hypochlorous Acid™) provides up to 18 months shelf life after opening.

• HyClear™ is Profitable.

HyClear™ will provide a consistent, reliable revenue source for the dry eye and contact lens segments of your practice.



Contamac® is pleased to introduce HyClear™, the next generation Hypochlorous Acid for daily eyelid health management.

HyClear™

Call 833-266-8262 or visit gethyclear.com for information on how HyClear™ can improve your dry eye practice.

Contamac

*in solution

contents

Review of Cornea & Contact Lenses | January/February 2019

departments

4 News Review

Myopia Research Advances; CLs and MGD: a Mixed Bag

7 My Perspective

Perfecting the Art of Practice
By Joseph P. Shovlin, OD

8 The GP Experts

A Reliable Post-PK Option
By Robert Ensley, OD,
and Heidi Miller, OD

36 Corneal Consult

Was it a Failure or Rejection?
By Aaron Bronner, OD

38 Fitting Challenges

Depth Charge
By Vivian P. Shibayama, OD

40 Practice Progress

Don't be Nearsighted About Myopia
By Andrew Fischer, OD, Mile Brujic, OD,
and David Kading, OD

42 The Big Picture

Singing the Blues
By Christine W. Sindt, OD

features

10

New Lenses for a New Year

Highlights in 2019 will include toric multifocals, a photochromic contact lens and more.

By Jane Cole, contributing editor

16

Keratoplasty: When and Why

Discover how long to monitor and treat symptoms before considering surgical interventions.

By James Esposito, OD

20

The Art of Corneal Transplantation

Optometrists have several options when it comes to keratoplasties, each of which has its own pros, cons and management guidelines.

By Andrew Steele, OD

26

Post-cataract Surgery Inflammation: A Toxin or a Bug?

Although rare, TASS and endophthalmitis are possible complications, and clinicians must be able to recognizing the difference.

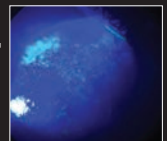
By Barbara J. Fluder, OD

30

CE — Transplantation for Limbal Stem Cell Deficiency

When severe disease calls for surgery, here's how you can be prepared for the pre- and post-op care.

By Cecelia Koetting, OD



Become a Fan on
Facebook

/ReviewofCorneaAndContactLenses



Follow Us on
Twitter

@RCCLmag

IN BRIEF

■ Researchers recently found that **African Americans have five times higher odds of developing infectious uveitis** and 1.5 higher odds of developing non-infectious uveitis compared with Caucasians. The study used data from the National Inpatient Sample (NIS) and collected patient's age, sex, race, median household income, payer status and ocular complications. **Medicare patients have double the odds of having complications from infectious uveitis** compared with those with private insurance, and Medicaid patients have a 1.7 higher risk. Medicare and Medicaid patients also have twice the odds of having complications from non-infectious uveitis compared with those with private insurance.

Chauhan K, Scaife S, Rosenbaum JT. Uveitis and health disparities: results from the National Inpatient Sample. *Br J Ophthalmol*. December 21, 2018. [Epub ahead of print].

■ **A new eye drop shows promise for reducing corneal scarring after *Pseudomonas aeruginosa* infection**, compared with traditional treatment. Developed by researchers from the University of Birmingham, the eye drop consists of a fluid gel that includes decorin, a naturally occurring protein that binds to collagen in the corneal stroma and regulates cell proliferation, survival and differentiation by modulating numerous growth factors. The drop acts similar to a therapeutic bandage, creating a barrier that protects the ocular surface from further damage caused by blinking. Researchers found the **eye drop resulted in reduced corneal opacity within 16 days**. Adding human recombinant decorin helped restore corneal epithelial integrity with minimal stromal opacity.

Hill LJ, Moakes RJA, Vareechon C, et al. Sustained release of decorin to the surface of the eye enables scarless corneal regeneration. *NPJ Regen Med*. 2018;3:23.

■ Researchers examined the benefits of toric contact lenses vs. sphericals on objective measures of visual performance for patients with low-to-moderate astigmatism. **High- and low-contrast visual acuities significantly improved with toric lenses compared with spherical lenses** at both fitting and follow-up. Electromyography recordings showed less orbicularis muscle activity, correlating with less eyestrain, with toric lenses compared with spherical lenses; however, the difference was only different at the fitting visit.

Berntsen DA, Cox SM, Bickle KM, et al. A randomized trial to evaluate the effect of toric versus spherical contact lenses on vision and eyestrain. *Eye Contact Lens*. 2019;45(1):28-33.

Myopia Research Advances

Two recent studies shed more light on the pathogenesis of this growing ocular condition:

MYOPIA BIOMARKER

A group of European researchers recently found conjunctival ultraviolet autofluorescence (CUVAF) can show clinicians how much time patients spend outdoors, and that can translate into a myopia monitoring tool. They assert their study, published in *Clinical and Experimental Optometry*, shows that the smaller a patient's area of CUVAF, the more time they spend outdoors.¹

"These findings suggest that CUVAF measures are a useful, non-invasive biomarker of the time spent outdoors in adults in northern hemisphere populations," the study reads.¹

To determine that, the team looked at 54 patients (24 with myopia and 30 without) and examined their CUVAF as well as self-reported sun exposure preferences. They also took the patients' blood samples to assess their vitamin D3 concentrations. While they found no significant association between sun exposure preferences or serum concentration of vitamin D3 and refractive status, they did find that, in nearly every case, CUVAF area was negatively associated with myopia.¹

The researchers concluded that the less cumulative ultraviolet B exposure from sunlight, the more likely patients were to be myopic.¹

PHYSIOLOGIC FACTORS

A second study found a mix of environmental and physiologic factors give rise to myopia, some of them quite surprising.²

In a new study conducted in the

UK, researchers analyzed a subset of the Twins Early Development Study, a longitudinal evaluation of 1,991 subjects recruited at birth between 1994 and 1996. Subjective refraction was obtained from the twins' optometrists, with myopia defined as mean spherical equivalent ≤ -0.75 diopters. Mean age of subjects was 16.3 years.²

The team used a 'life-course epidemiology' approach, which considers the influence of gestational and early childhood factors on long-term development, to appropriately weight myopia risk factors during critical periods of eye growth. Adjusted odds ratios (ORs) for myopia were estimated at each life stage.²

Factors significantly associated with myopia included level of maternal education (OR 1.33), fertility treatment (OR 0.63), summer birth (OR 1.93) and hours spent playing computer games (OR 1.03). In addition, the researchers noted associations with socioeconomic status, educational attainment, reading enjoyment and certain cognitive variable (particularly verbal cognition) at multiple points over the life course.²

"A greater understanding of contemporaneous, early life factors associated with myopia risk is urgently required, particularly in younger-onset myopia," the authors wrote in their study, "as this correlates with higher severity and increased complications in adult life."²

1. Kearney S, O'Donoghue L, Pourshahidi L, et al. Conjunctival ultraviolet autofluorescence area, but not intensity, is associated with myopia. *Clin Exp Optom*. 2019;102(1):43-50.

2. Williams KM, Krapohl E, Yonova-Doing E, et al. Early life factors for myopia in the British Twins Early Development Study. *Br J Ophthalmol*. November 6, 2018. [Epub ahead of print].

EDITORIAL STAFF

EDITOR-IN-CHIEF

Jack Persico jpersico@jobson.com

MANAGING EDITOR

Rebecca Hepp rhepp@jobson.com

ASSOCIATE EDITOR

Catherine Manthorp cmanthorp@jobson.com

ASSOCIATE EDITOR

Mark De Leon mdeleon@jobson.com

CLINICAL EDITOR

Joseph P. Shovlin, OD, jpshovlin@gmail.com

ASSOCIATE CLINICAL EDITOR

Christine W. Sindt, OD, christine-sindt@uiowa.edu

EXECUTIVE EDITOR

Arthur B. Epstein, OD, artepstein@artepstein.com

CONSULTING EDITOR

Milton M. Horn, OD, eyemage@mminternet.com

GRAPHIC DESIGNER

Ashley Schmouder aschmouder@jobson.com

AD PRODUCTION MANAGER

Scott Tobin stobin@jhihealth.com

BUSINESS STAFF

PUBLISHER

James Henne jhenne@jobson.com

REGIONAL SALES MANAGER

Michele Barrett mbarrett@jobson.com

REGIONAL SALES MANAGER

Michael Hoster mhoster@jobson.com

VICE PRESIDENT, OPERATIONS

Casey Foster cfoster@jobson.com

EXECUTIVE STAFF

CEO, INFORMATION SERVICES GROUP

Marc Ferrara mferrara@jhihealth.com

SENIOR VICE PRESIDENT, OPERATIONS

Jeff Levitz jlevitz@jhihealth.com

SENIOR VICE PRESIDENT,

HUMAN RESOURCES

Tammy Garcia tgarcia@jhihealth.com

VICE PRESIDENT,

CREATIVE SERVICES & PRODUCTION

Monica Tettamanzi mtettamanzi@jhihealth.com

VICE PRESIDENT, CIRCULATION

Emelda Barea ebarea@jhihealth.com

CORPORATE PRODUCTION MANAGER

John Caggiano jcaggiano@jhihealth.com

EDITORIAL REVIEW BOARD

Mark B. Abelson, MD

James V. Aquavella, MD

Edward S. Bennett, OD

Aaron Bronner, OD

Brian Chou, OD

Kenneth Daniels, OD

S. Barry Eiden, OD

Desmond Fonn, Dip Optom, M Optom

Gary Gerber, OD

Robert M. Grohe, OD

Susan Gromacki, OD

Patricia Keech, OD

Bruce Koffler, MD

Pete Kollbaum, OD, PhD

Jeffrey Charles Krohn, OD

Kenneth A. Lebow, OD

Jerry Legerton, OD

Kelly Nichols, OD

Robert Ryan, OD

Jack Schaeffer, OD

Charles B. Slonim, MD

Kirk Smick, OD

Mary Jo Stiegemeier, OD

Loretta B. Szczotka, OD

Michael A. Ward, FCLSA

Barry M. Weiner, OD

Barry Weissman, OD



CLs and MGD: a Mixed Bag

Research now shows silicone hydrogel contact lens (CL) materials don't cause cytokine-driven inflammation for patients with meibomian gland dysfunction (MGD), but they can affect morphological and functional changes to the meibomian glands.

One study evaluated MGD patients who had worn CLs for at least six months and found silicone hydrogel CLs didn't cause cytokine-driven ocular surface inflammation, but they may impact tear function, which could still lead to symptoms of dry eye disease (DED).¹

The researchers found the mean cytokine concentrations of CL wearers were not statistically significant compared with those of healthy controls. Even the concentrations of those with and without MGD didn't show statistically significant variation.¹

According to the research team, the TBUT and ocular surface staining in CL wearers with MGD were significantly worse compared with controls, but they did not correlate with tear cytokine levels, suggesting other factors are to blame for the symptoms. "The abnormal interaction between the meibomian lipids and the contact lens surface is thought to result in thinning of the tear lipid layer, accelerated tear evaporation and dewetting as a result of the increased lens-surface hydrophobicity," the report reads. "These changes are likely to be the underlying causes for reduced TBUT, higher ocular surface staining as well as higher OSDI scores previously reported in CL wearers."¹

A second study recently documented several morphological and functional changes to the meibo-

mian glands due to silicone hydrogel CL wear, some of which could help clinicians detect early MGD.²

Researchers examined 173 eyes of 87 soft CL wearers and 103 eyes of 55 controls, grouping them based on duration of wear: less than three years, between three and seven years and more than seven years.²

They found significantly higher upper and lower eyelid meiboscores in the CL wearers compared with controls, as well as higher mean OSDI scores, corneal staining scores, percentage of gland loss and percentage of thickened and curled meibomian glands in the upper and lower lids. Both the mean TBUT and meibomian gland expressibility were lower in CL wearers compared with the control groups.²

The study also found duration of wear was important, considering meiboscores were higher in patients who wore CLs for more than three years compared with those wearing lenses for less than three years. The earliest change the researchers documented was meibomian gland thickening in the upper eyelid—before deterioration of meiboscores or increase in gland dropout, the study says. This was the only finding that had the highest diagnostic ability for MGD, they noted.² **RCCL**

1. Yucekul B, Mocan M, Mehmet C, et al. Evaluation of long-term silicone hydrogel use on ocular surface inflammation and tear function in patients with and without meibomian gland dysfunction. *Eye & Contact Lens*. 2019;45(1):61-6.

2. Ucakhan Ö, Arslanturk-Eren M. The role of soft contact lens wear on meibomian gland morphology and function. *Eye Contact Lens*. 2018 December 28, 2018. [Epub ahead of print].

Advertiser Index

Art Optical.....Cover 3
CooperVisionCover 2
Menicon Cover 4

Earn up to
18-28 CE
Credits*

NEW TECHNOLOGIES
& TREATMENTS IN
2019 EYE CARE
RGVCE
REVIEW'S COMMITMENT TO
CONTINUING EDUCATION



Join us for our
2019 MEETINGS



MARCH 7-10, 2019 - ORLANDO, FL

Disney Yacht & Beach Club

Program Chair: Paul M. Karpecki, OD, FAAO

REGISTER ONLINE: www.reviewsce.com/orlando2019



APRIL 11-14, 2019 - SAN DIEGO, CA**

Manchester Grand Hyatt

Program Chair: Paul M. Karpecki, OD, FAAO

REGISTER ONLINE: www.reviewsce.com/sandiego2019



May 17-19, 2019 - NASHVILLE, TN

Gaylord Opryland

Program Chair: Paul M. Karpecki, OD, FAAO

REGISTER ONLINE: www.reviewsce.com/nashville2019



NOVEMBER 1-3, 2019 - BALTIMORE, MD

Renaissance Baltimore Harborplace

Program Chair: Paul M. Karpecki, OD, FAAO

REGISTER ONLINE: www.reviewsce.com/baltimore2019

Visit our website for the latest information: www.reviewsce.com/events
e-mail: reviewmeetings@jhihealth.com or call: 866-658-1772

Administered by
RGVCE
REVIEW'S COMMITMENT TO CONTINUING EDUCATION



*Approval pending



Pennsylvania College of Optometry



**16th Annual Education Symposium
Joint Meeting with NT&T in Eye Care

RGVCE partners with Salus University for those ODs who are licensed in states that require university credit.
See www.reviewsce.com/events for any meeting schedule changes or updates.



Perfecting the Art of Practice

These seven steps might help you start off your new year on the right foot.

Do you have a New Year's resolution? I'm fairly certain some of you will have already made and broken one for the new year by the time you read this. If so, make a new one! And if you haven't yet made a New Year's resolution, here is a suggestion.

I came across a fascinating article about a year ago by Thomas Egnew, EdD. It deals directly with what we do daily in clinical practice—caring for patients. I hope you find the highlights striking enough to make a new resolution to replace the one you didn't adhere to already, or to add to your list of resolutions.

THE MAGNIFICENT SEVEN

Here are the seven skills for mastery of practice that the author refers to as “the magnificent seven”:¹

1. *Take a moment to focus before you enter the examination room.*

It's important to clear your mind from the last encounter or recharge after the morning's tribulations. Then, it's time to focus on the next patient. As Dr. Egnew stresses, becoming mindful of the details of the next patient outside the consultation room is a precursor to being mindful inside the examination room.

2. *Establish a connection with the patient, develop rapport and agree on an agenda.* This initial interaction gives you a chance to connect with the patient interpersonally and intellectually. Spending a small amount of time socializing and listening is a worthy investment. Also, set an agenda. You don't need to address all of their concerns on the first visit, but be certain that they

know you plan on addressing each concern or complaint to the best of your ability in the future.

3. *Assess the patient's response to illness and suffering.* We must provide a precise diagnosis whenever possible. Dr. Egnew says that patients suffer in ways other than experiencing physical pain. We encounter patients with anterior and posterior segment anomalies that may not be painful physically but cause suffering from visual compromise.

4. *Communicate to foster healing.* Carl Rogers notes that anyone who counsels patients needs to display congruence (being authentic), acceptance (valuing the patient even if you don't agree with their actions) and understanding (being sensitive to what they are experiencing). However, on occasion, we are forced into confrontation. For example, “You have thyroid eye disease—you must stop smoking!”

5. *Use the power of touch.* Of course, we do not recommend anything that can be misconstrued as an unwanted gesture, but this article recommends a warm handshake. If you get the sense that a patient is uncomfortable with any touch because of their cultural or religious beliefs, avoid it.

6. *Laugh a little.* “Humor can be helpful in establishing rapport, relieving anxiety, communicating a message that you care, enhancing healing and providing an acceptable outlet for any anger and frustration.” Gentle self-deprecation also has worked well for all of us from time to time.

7. *Show some empathy.* This is seldom practiced, especially as

practitioners become somewhat hardened from our daily routine; we see so much pathology and visual loss that we run the risk of forgetting how devastating it can be. Dr. Egnew highlights the need for being explicit in your understanding of a patient's problem; in doing so, it actually allows them to be more open in sharing both personal and clinically important information.

CHECK IN

One way to incorporate these skills is to keep a list of patients you've seen over the past week who might benefit from a phone call to check on their progress. I've done this for years, and patients are always amazed that you have taken the time to call and are grateful for your concern. It goes a long way in saying, “I really care about you.” Of course, there's some risk that it may get you more than you bargained for, but the pluses seem to always outweigh the minuses.

Many of these seven skills may seem straightforward and even obvious, but I find it always good to reflect on how your patients and their families might perceive you. Carefully reflecting on each of these areas should serve us all well to be better care providers. I thank Dr. Egnew for his seven skills to promote mastery in clinical practice. I hope you also find them helpful. And if this is one New Year's resolution you can adopt—an attempt to master the art of practice—I hope it's one you keep for the remainder of your career. Wishing all a happy and healthy New Year! [RCCO](#)

1. Egnew TR. The art of medicine: seven skills that promote mastery. *Fam Pract Mangag.* 2014;21(4):25-30.

A Reliable Post-PK Option

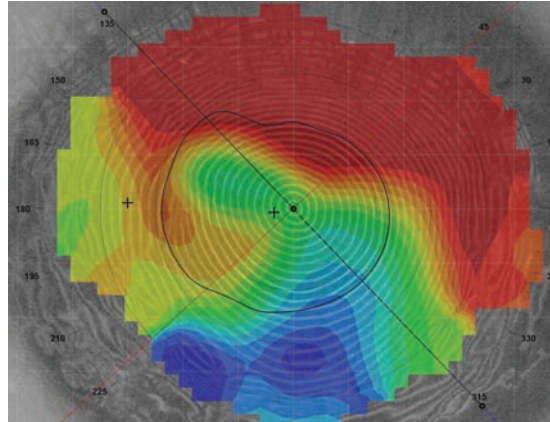
Scleral lenses are growing in popularity, but GPs have long been a mainstay in managing the complex corneas of these patients.

Since 2005, the annual number of penetrating keratoplasty (PK) procedures performed in the United States has decreased by 56%.¹ When transplantation is required, more selective procedures, such as anterior lamellar keratoplasty and endothelial keratoplasty, have contributed to the reduced need for full-thickness grafts. However, PKs are still performed in cases of advanced corneal disease or opacification.

A full-thickness PK replaces all layers of the cornea with a donor button, typically 7.5mm to 8.5mm in diameter, sutured in place to the host tissue.² Newer surgical techniques such as using a femto-second laser to create the donor button have improved postoperative wound stability and reduced healing time.³ However, refractive outcomes are still variable, and are largely impacted by the amount of astigmatism that the graft produces. High amounts of astigmatism are not uncommon, with one large cohort study reporting at least five diopters of astigmatism in 20% of grafts.⁴ If spectacles do not provide a successful visual outcome, contact lenses, specifically gas permeable (GP) lenses, may be required for vision rehabilitation.

LENS CONSIDERATIONS

Because of their ability to vault over the corneal surface, scleral lenses are becoming an increasingly popular lens choice for post PK patients. While mechanical stress



Post-PK, the cornea can take on a steep-to-flat pattern where the graft is tilted.

may be minimized, careful observation for signs of hypoxia is critical. Scleral lenses are made with highly oxygen permeable (DK) materials, but they must also take into account the diffusion of oxygen through the post-lens tear layer. If excessive hypoxic stress is placed on the endothelium, corneal edema may occur and increase the risk of rejection. Smaller-diameter corneal GP lenses use the same high DK materials and also benefit from a greater tear exchange beneath the lens. This improves oxygen tension and is suggested to play a role in the lower risk of microbial keratitis with GP lenses.^{5,6}

THE CORNEAL PROFILE

The goal of fitting GP lenses is to align the lens's back surface to the anterior curvature of the cornea. With a normal cornea, eyelid positioning and keratometry measurements are used to select diameter and base curve. For PK patients, analyzing astigmatism and corneal shape with the aid of corneal

topography will help dictate the proper contact lens fit.


Regular astigmatism has two principal meridians perpendicular to each other in a bow-tie pattern. Depending on the power of each half of the bowtie, regular astigmatism can be classified further as symmetrical or asymmetrical. When the cornea is non-uniform or principal meridians

are not 90 degrees apart, the astigmatism is considered irregular, with several pattern subtypes.⁷ Irregular astigmatism is the most common indication for fitting GP lenses post-transplantation.⁸

Corneal shape is typically classified into three basic patterns: prolate, oblate and mixed. Prolate-shaped corneas are steeper centrally and flatter in the periphery, while oblate-shaped corneas are flatter centrally and steeper in the periphery. Mixed-shape features both prolate and oblate areas of the cornea. Post-PK, the cornea can also take on a steep-to-flat pattern where the graft is tilted, steep on one side and flatter towards the other side.^{7,9}

FITTING STRATEGY

A well-fit GP lens will minimize mechanical trauma to the graft, optimize vision and be comfortable to the patient. Maintaining proper centration and distributing weight equally on the cornea can achieve these objectives.



In general, larger-diameter intralimbal lenses (10mm to 12mm) are preferred because their back optical zone diameter will extend beyond the graft-host junction.^{9,10} If small-diameter lenses must be used, care must be taken to avoid heavy bearing, especially on the junction.

Choosing a back surface design for the lens is dependent on the corneal profile. Prolate corneas with regular astigmatism and a normal eccentricity can often still be fit in a conventional spherical lens. If the regular astigmatism is 2.5D or more, a bitoric design can be fit to avoid lens rocking and areas of heavy touch. When the graft is steeper, a keratoconic design, which typically has a steeper base curve and smaller optic zone size, can be used. Proud grafts that protrude more from the host cornea may require a quadrant specific peripheral curve design if there is excessive edge lift. A reverse geometry lens, in which one or more peripheral curves are steeper than the optical zone curvature, can also reduce peripheral edge lift.⁹

Reverse geometry lenses are also useful for oblate corneas. A conventional GP would exhibit excessive central clearance, at risk for bubble formation, mid-peripheral bearing and edge lift. Flattening the base curve to match the central cornea and steepening the peripheral curves will better match corneal contour, with a fluorescein pattern appearing to be in

alignment. If the graft is tilted, a GP lens will tend to center over the steepest part of the cornea. Larger-diameter lenses help with centration, although in these cases scleral lenses may indeed be the preferred choice.

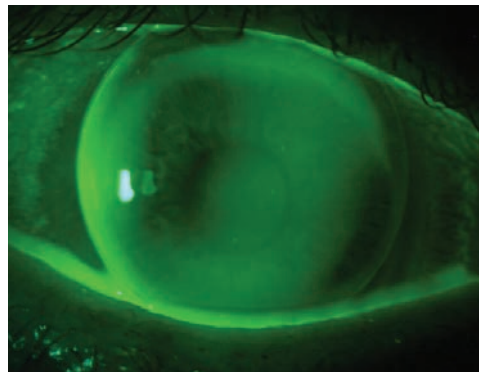
OTHER OPTIONS

Discomfort and decentration can potentially derail the success of GP lenses. A piggyback system may be an effective option to correct both complications. A soft silicone hydrogel (SiHy) lens can be placed under the GP lens to reduce friction on the cornea. The power profile of the soft lens can help manipulate centration. A high myopic powered soft lens will act as a carrier for the GP lens to rest on, while a high plus lens may “fill in” an oblate cornea.¹⁰ In a piggyback design, the soft lens will provide only 20% of the total optical power of the system.¹¹ Because oxygen must now diffuse through two lenses, careful monitoring for corneal hypoxia is warranted.

Contemporary hybrid lens designs are also available for

post-surgical corneas. The SynergEyes UltraHealth lens is designed using a hyper DK reverse geometry GP lens and a high DK SiHy skirt. The GP lens vaults over the cornea with minimal touch and the soft skirt maintains centration with minimal movement.

The versatility of scleral lenses makes them a popular choice for the post-PK patient; however, they are not without risk. If a graft patient cannot tolerate or afford a scleral lens, they have options. Don't be afraid to put your GP fitting skills to the test! **RCCL**



A well-fit GP lens will minimize mechanical trauma to the graft.

1. Eye Bank Association of America. 2016 Eye Banking Statistical Report. restoresight.org/wp-content/uploads/2017/04/2016_Statistical_Report-Final-040717.pdf. Accessed December 23, 2018.
2. Richard JM, Paton D, Gasset AR. A Comparison of penetrating keratoplasty and lamellar keratoplasty in the surgical management of keratoconus. *AM J Ophthalmol*. 1978;86(6):807-11.
3. Farid M, Pirouzian A, Steinert RF. Femtosecond laser keratoplasty. *Int Ophthalmol Clin*. 2013;53(1):55-64.
4. Kelly TL, Williams KA, Coster DJ. Corneal transplantation for keratoconus: A registry study. *Arch Ophthalmol*. 2011; 129(6):691-7.
5. Weissman BA. Corneal oxygen: 2015. *CL Spectrum*. 2015;30:25-29,55.
6. Fleiszig SM. The pathogenesis of contact lens-related keratitis. *Optom Vis Sci*. 2006;83:E866-73.
7. Karabatsas CH, Cook SD, Sparrow JM. Proosed classification for topographic patterns seen after penetrating keratoplasty. *BR J Ophthalmol*. 1999;83:403-9
8. Wietharn BE, Driebe WT Jr. Fitting contact lenses for visual rehabilitation after penetrating keratoplasty. *Eye & Contact Lens* 2004; 30(1):31-33.
9. Szczotka LB, Lindsay RG. Contact lens fitting following corneal graft surgery. *Clin Exp Optom*. 2003;86(4):244-9.
10. Louie DJ, Kawulok E, Kauffman M, Epstein A. Postsurgical contact lens fitting. In: Bennett ES, Henry VA, eds. *Clinical Manual of Contact Lenses*. 4th Ed. Philadelphia, PA: Lippincott, Williams & Wilkins; 2014:578-608.
11. Woo M, Weissman B. Effective optics of piggyback soft contact lenses. *CL Spectrum*. 2011;26(11):50.

New Lenses *for a* New Year

Highlights in 2019 will include toric multifocals, a photochromic contact lens and more.

By Jane Cole, Contributing Editor

Not too long ago, the contact lens marketplace seemed a bit stagnant. Practitioners had a stable line-up of offerings that served patients well, but it was essentially the same product lines year in and year out with some incremental updates. For 2019, however, industry has some ambitious new ideas to debut. Here, we offer a sneak peek of what's expected in the coming months, and optometrists weigh in on how these new lenses might fit into what's currently available.

"In general, the lenses will be a stab at what doctors and patients have been asking for over the last several years," says David Anderson, OD, of Miamisburg, Ohio. "We will see toric multifocals, lenses to treat medical conditions and lenses that change color like Transitions glasses. For the longest time, the lens advances have been all health driven, addressing compliance with daily disposables or more oxygen with silicone hydrogel lenses. Now, the companies are making an effort to focus on the cosmetic and medical arenas to help solve some needs that patients have had for years."

SUN PROTECTION

For the first time, photochromic technology is coming to the contact lens platform, with a new lens under the Transitions banner from Johnson & Johnson Vision (JJV) slated to hit the market in the first half of this year. Formally named Acuvue Oasys with Transitions Light Intelligent Technology, the lens is a two-week reusable product that continuously adapts from clear to dark and back, according to the company. The lenses become dark in 45 seconds when exposed to UV or HEV light and fade back to clear within 90 seconds in darker lighting. The lens also provides 100% protection against UVB rays, JJV says. The lens is the result of a joint partnership between JJV and Transitions Optical.

"This lens has been long awaited for," says Dr. Anderson. "The idea of both protecting your eyes from UV and shielding

them from the sun's brightness without carrying sunglasses has been on patients' minds for some time. Specifically, at least once a month for as long as I have been in practice, I've gotten the question about photochromic contact lenses. There is clearly a desire, and I am excited to answer 'yes' to this question several times a year, and possibly more, as awareness increases once the product is available."




Fig. 1. and Fig. 2. The Acuvue Oasys with Transitions Light Intelligent Technology lenses become dark in 45 seconds when exposed to bright light and fade back to clear within 90 seconds in darker lighting, according to the company.

Mile Brujic, OD, of Bowling Green, Ohio, likens this new lens option to a “sunglass contact lens.” Although it doesn’t provide ocular tissue protection, athletes who may not be able to wear sunglasses, for example, will be able to see comfortably in this new lens. “In my mind, that’s the bigger thing than the actual protective factors of the potential UV protection in the lens.”

Adds Glenda Secor, OD, of Huntington Beach, CA, “This lens should be great. Patients are anxious to try them.”

NEW PRESBYOPIC OPTIONS

Last fall, Alcon launched its monthly replacement Air Optix plus HydraGlyde Multifocal contact lens, giving the company a new monthly option to round out its multifocal product line. The HydraGlyde component is said to improve moisture retention and thus contact lens comfort, according to the company.

Other companies are also planning new multifocal offerings for this patient population:

Astigmatism. Bausch + Lomb is gearing up to debut a multifocal toric lens, the Ultra Multifocal for Astigmatism. The monthly replacement silicone hydrogel lens can correct near or distance vision, astigmatism and presbyopia and has an expected release of mid-2019.

This lens may help patients with uncorrected astigmatism stay in contact lenses because they won’t need to wear readers over their distance vision contacts or rely on monovision to help with near vision, says Dr. Anderson. “A multifocal option to also correct astigmatism offers an opportunity to help more patients as they lose their near vision, and provides an option as many patients have

an increase in astigmatism as they age, which alone can cause dropout,” Dr. Anderson adds.

“This is the first time we’ve had access to a toric contact lens that has presbyopia-correcting options available in our office without having to specialty order them,” says Dr. Brujic.

While a multifocal for astigmatism has existed for many years, it is a custom-fit lens, which presents myriad clinical and logistical barriers. “The process is lengthy because it is a made-to-order lens,” says Justin Bazan, OD, of Park Slope Eye in Brooklyn, NY. “It can take a couple of weeks just to get the first trial lenses. More times than not, a second or third trial is needed, adding several weeks to complete the fit. This drawn-out process often leads to frustration and many patients are lost to follow-up.”

Also, the fitting process for custom lenses is complicated and the visual outcome isn’t always satisfactory, Dr. Bazan says. “For me, the complication stems from numerous add powers and power designs. It’s rare to get a patient who is happy with their visual outcome.”

The forthcoming lens from B+L may help to resolve these issues, Dr. Bazan says. “It combines technology that has been proven successful, it is easy to fit and will be available on the spot in an in-office fitting kit. From our spherical presbyopic patients, we have learned that multifocal contact lenses are the preferred way to handle presbyopia, and now we are finally able to offer it to our astigmatic presbyopic patients.”

“It will be like fitting a spherical multifocal lens, and the Ultra material is a comfortable

Are CL Developments Meeting ODs’ Needs?

We asked experts from the Centre for Ocular Research & Education (CORE) at the University of Waterloo to weigh in on whether the new contact lenses being developed are bridging doctor and patient needs.

At a basic level, contact lenses need to enable patients to see clearly, with all-day comfort, while maintaining the health of the wearer’s eye, they say. For practitioners, lenses need to be quick and predictable to fit. “Many changes in contact lens design and technology over the last few years have helped us move closer to being able to provide those basics for a greater number of patients,” they say.

For example, silicone hydrogel materials provide the cornea with sufficient oxygen for daily wear, and, in many cases, adequate oxygen for overnight wear also. Materials have been engineered to try and maintain comfort throughout the day, and choice of design to correct astigmatic and presbyopic prescriptions has increased.

Yet, there are still improvements to be gained in delivering enhanced comfort for the many patients who experience contact lens-related dryness, they add. “We need to understand more about the interaction of contact lenses with both the tear film and contact lens solutions, and we would benefit from technology which enables the incidence of both microbial keratitis and corneal infiltrative events to be reduced.”

Acquisitions of instrument and therapeutic device intellectual property by some of the major vision care companies over the past few years demonstrate the focus that exists in this area, they add. “A better understanding of the tear film and how it interacts with the contact lens should lead to new technology and treatments which can help maintain, or even enhance, ocular surface health,” the CORE researchers explain.

NEW LENSES FOR A NEW YEAR

platform,” Dr. Brujic adds. “This is one I’m excited about.”

Dynamic refraction. Presbyopic patients may one day have access to a self-powered smart lens designed to dynamically change focus. The subject of much speculation for years, this concept is being pursued by at least two companies, Alcon and JJV. Both have publicly discussed their plans to develop a lens that adjusts its shape to change the refractive index as needed. JJV says it has overcome many technical hurdles, including onboard battery technology, and it is working closely with the FDA on the regulatory

pathway for their innovation. An accommodating contact lens still appears to be on Alcon’s product roadmap, too, according to public documents.

Though a product launch won’t make it into 2019, clinicians may be able to hear more about these technologies as plans proceed at both companies.

A MID-TIER SiHy LENS

Back in 2011, Alcon planted a flag at the high end of the daily disposable market with the launch of its DailiesTotal1 silicone hydrogel (SiHy) lens, using a water gradient lens matrix. Subsequent product

line extensions added correction for astigmatism and presbyopia. The company also has a non-SiHy workhorse lens in the Dailies Aqua Comfort Plus product line.

In 2019 or perhaps 2020, look for the company to add a third category in between those two, reportedly to be called Precision1. Few details are available, but the company expects the silicone hydrogel contact lens to use what it calls ‘advanced aqueous extraction and surface treatment,’ which it believes will help the contact lens compete with other mainstream silicone hydrogel options currently on the market.

Happy 20th, Silicone Hydrogels!

By Lyndon Jones, PhD, DSc, FCOptom, Jill Woods, BSc (Hons), MCOptom, Karen Walsh, BSc (Hons), MCOptom, and Doerte Luensmann, PhD, Dipl. Ing.

In 2018, silicone hydrogel (SiHy) contact lenses celebrated their 20th birthday. Now that these lenses have been available for two decades, we at CORE offer a walk down memory lane. Here is a look at SiHy’s milestones and challenges, from balancing properties for comfortable daily wear to increased understanding of how the lenses interact with the ocular surface and tear film, plus a glimpse into the future:

INFANT/TODDLER YEARS: 1998-2003

Prior to SiHy lenses, frequent replacement soft hydrogel lenses were available, but hypoxia-related complications existed with full-time daily and extended wear. The potential benefits of silicone were known, but researchers and manufacturers faced significant technical challenges when incorporating the hydrophobic element into a lens. The first generation of SiHy lenses were balafilcon A, with a plasma oxidation surface treatment that created silicate “islands” on the surface of the lens, and lotrafilcon A with a plasma coating. Both required surface modification to create a suitably hydrophilic surface.

The first years of the SiHy era delivered both a leap forward in oxygen delivery and some initial physiological challenges. Hypoxic responses, such as corneal striae,

epithelial microcysts, limbal hyperemia and corneal neovascularization were significantly reduced. However, mechanical complications arose from the combination of increased modulus and original base curve designs. These included contact lens induced papillary conjunctivitis, mucin balls, epithelial splits and discomfort.

ELEMENTARY YEARS: 2004-2009

This was a period of great advancements for SiHy with the launch of the first reusable SiHy lens with a daily wear-only indication. This material, galyfilcon A, had a bound internal wetting agent to achieve wettability. Further innovation saw the release of comfilcon A, an inherently wettable material. Practitioners had access to an increased choice of spherical lenses, along with the addition of toric and multifocal options across a number of new materials for both extended and daily wear. The first daily disposable SiHy lens, narafilcon A, was launched in 2008-2009.

Balancing the material properties of oxygen transmissibility, modulus, coefficient of friction and wettability was a focus through these years to drive increased comfort for daily wear. Packaging solutions also received attention, with comfort-enhancing agents added to the blister pack of several SiHy materials.

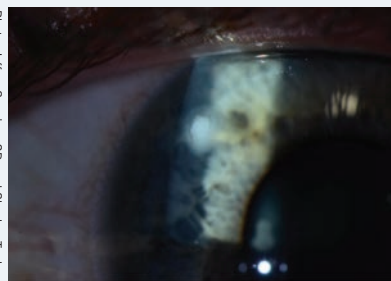

Photo: Jeffrey Sorsino, OD, and Shachar Taulber, MD

Researchers are investigating contact lens materials that may reduce the incidence of microbial keratitis.

In statements to financial analysts, the company said Precision1 “will be a daily disposable, SiHy contact lens intended to compete within the mainstream subcategory of the global daily disposable contact lens market” and it “will be engineered for the highest visual clarity of any contact lens in its class.” Positioned between the high-end Dailies Total1 and the non-SiHy Dailies Aqua Comfort Plus, this new, mid-tier lens could strike a balance between performance and cost that helps grow the daily disposable category as a mass-market product.

Further down the road, we may

also see an advance that builds upon the Dailies Total1 lens matrix technology. Investor presentations note a “next generation water gradient” material in the works, though no release date is specified.

INNOVATION ON THE HORIZON

Researchers from the Centre for Ocular Research & Education (CORE) at the School of Optometry & Vision Science at the University of Waterloo offer their insights on what’s ahead on the contact lens horizon. This research team is led by Lyndon Jones, PhD, DSc, FCOptom, CORE director,

professor and university research chair, and includes Jill Woods, BSc (Hons), MCOptom, clinical research manager and senior clinical scientist at CORE; and Karen Walsh, BSc (Hons), MCOptom, CORE clinical scientist.

Myopia. They predict an expansion of myopia control designs, including the MiSight (CooperVision) design they have been working with in clinical trials. This soft lens for myopia control has been available in Canada for a year and even longer in some East Asian and European markets. “It will be interesting to see the impact of this lens in the US market

However, adverse reactions still occurred, including the potentially sight-threatening complication of microbial keratitis. Additionally, reusable SiHys were found to be two times more likely to result in corneal infiltrative events compared with hydrogel lenses.¹⁻⁴

HIGH SCHOOL: 2010-2017

New research and development resulted in an increased understanding of the interaction of SiHys with the tear film. This included establishing protein and lipid deposition profiles, and the relevance of the conformational state of those tear components once adsorbed onto, and absorbed into, the contact lens. Further investigations also explored other variables that may impact comfort, such as the effect of contact lens wear on the ocular inflammatory response and the interactions that occur between SiHy materials and contact lens care systems.

Key milestones during this era included a new lens material, delefilcon A, with a silicone core and a hydrogel-like surface, updated designs from the original 1998 lenses, and the emergence of color SiHys. By the end of 2017, more than 40 SiHys were available in all prescriptions and modalities, including daily disposables for astigmatism and presbyopia. By 2017, two-thirds of all soft fits were SiHys, with the greatest use of this material occurring with reusable contact lenses.⁵

While understanding SiHy materials and their ocular interactions increased during this time, some ques-

tions remain and are the subject of ongoing research. Hopefully innovation will result in lenses with reduced complication rates and improved all-day comfort.

COLLEGE YEARS: 2018 AND BEYOND

Today, researchers are looking into the development of materials to reduce the incidence of infective (microbial keratitis) and inflammatory (corneal infiltrative) events. This may involve the addition of antimicrobial coatings to contact lens materials. In addition, improving comfortable wear times is another goal, and researchers are studying the controlled interaction with the tear film, which would encourage uptake of “good” proteins and lipids while resisting deposition of “bad” tear film components. Investigators believe the conformational state of deposits is important, with materials ideally being able to minimize the denaturation of proteins and oxidation of lipids. Further comfort enhancements may also involve differential deposition on the front vs. the back of the lens and the delivery of comfort enhancing components that could help to stabilize the tear film and enhance wettability.

Although an important area of development, no myopia-control designs are available in SiHy materials, but researchers expect this to change. They also anticipate innovation for presbyopia with the addition of novel optical designs for multifocal contact lenses.

With 20 years of lens advancements, the future looks promising for SiHy lenses.

NEW LENSES FOR A NEW YEAR

once it gains the necessary FDA approvals to launch,” the CORE team says.

Another new soft myopia control lens that could hit the US market in the future is NaturalVue (Visioneering Technologies), which was available in some global markets in 2018.

“Given the worldwide recognition of the myopia epidemic, and the real sight-threatening pathology associated with high myopia, the focus on myopia control is crucial. We are excited by the rate at which our collective knowledge grows in this area and the fact that optical designs really do seem to have an impact,” CORE says. “While it is true that there is much we don’t understand, this is a fast moving area of research, with new evidence being generated, and new contact lens and spectacle designs being tested and released with increasing regularity.”

In addition to these products, the group is aware of alternate myopia management approaches via the use of orthokeratology, pharmaceutical treatments and the future potential of combination therapies that may bring together contact lens optical designs and drug delivery.

Light moderation. Light management will be of interest in 2019, the CORE team says. In addition to the photochromic lens on the way from JJV, there is much interest around eyestrain from digital device use.

“This has led to modifications to the optical designs of some contact lenses, targeted to reduce digital eyestrain. It is also possible that the digital light management technology offered in certain spectacle designs may translate into the contact lens market,” they add.

Biosensing. A growth in specialty medical lenses is also expected.

Sensimed’s Triggerfish, a contact lens designed to evaluate changes in intraocular pressure, is commercially available in Europe and has FDA clearance.

“Biosensing technologies are a focus for many manufacturers and research institutions,” the CORE researchers say. “Parties are actively exploring the possibilities of this technology in a contact lens, as well as with other ocular and systemic applications, including detection of cancer markers, blood pressure monitoring, measuring tear film osmolarity and markers of dry eye disease.” While biosensing contact lenses are an exciting possibility, most technologies are still quite a few years away from being commercially available, the CORE team adds. Developers have several hurdles to overcome before bringing anything to market. In November 2018, Verily (Alphabet) and Alcon announced that they shelved development of a diabetes-monitoring contact lens, citing difficulties with obtaining consistent measures of glucose levels in tears.

Drug delivery. The CORE researchers also see growth in drug-delivering contact lenses to treat specific conditions, including glaucoma, inflammation, allergy and to aid ocular surface healing.

One such product in the pipeline is a JJV contact lens that includes the medication ketotifen fumarate. This drug-eluting contact lens is designed to help patients with itchy eyes due to ocular allergies, according to the company. JJV says it is on track to bring the product to market within five years.

CONTACT LENS WISH LISTS

Even though several new contact lenses are set to launch this year and others are working their way




Fig. 3. Patients with astigmatism now have a monthly replacement silicone hydrogel lens option in the form of Bausch + Lomb’s new Ultra Multifocal for Astigmatism, which is designed to provide stable, consistently clear vision and spherical aberration control in both axes to help reduce halos and glare.

through the approval process, optometrists still hope additional advances will help to fulfill their patient needs.

“A daily disposable toric multifocal lens is next on my wish list,” Dr. Anderson says. “I have more than 65% of my patients wearing daily disposable lenses. The next area needed is the daily toric multifocal lens.”

There are still two key areas where patient needs could be better met, the CORE team says. “First are the rates of infection and inflammatory events.” Daily disposables are the best way to minimize risk of these adverse events, they say, but reusable contact lenses could benefit from the addition of antimicrobial properties to help reduce the incidence of these complications. “Secondly, we are striving to minimize dryness/discomfort, which remains the main reason for ceasing contact lens wear. New technologies that can enhance the comfort of the contact lens, such as release of tear-film type components when

KERATOPLASTY: WHEN AND WHY

Discover how long to monitor and treat symptoms before considering surgical interventions.

By James Esposito, OD

Surgeons perform corneal graft surgery for a wide variety of indications, including stromal opacification, corneal ectasias and persistent corneal edema due to endothelial failure. Worldwide, four-and-a-half million individuals have moderate to severe vision impairment secondary to the loss of corneal clarity and more than 200 million are visually impaired.¹ Corneal disease is the fifth leading cause of blindness after cataract, uncorrected refractive error, glaucoma and macular degeneration.¹ Here we review common graft indications in the United States, clinical pearls for a timely and correct diagnosis and recommendations on when to obtain an initial surgical consult for keratoplasty.

COMMON INDICATIONS AND PROCEDURES

The Eye Bank Association of America's (EBAA) 2016 report revealed that the most common indication for any corneal graft surgery in the US is endothelial cell failure secondary to either Fuchs' endothelial dystrophy or cataract surgery [e.g., pseudophakic bullous keratopathy (PBK)]. Be aware that a significant portion of PBK patients also have undiagnosed Fuchs' endothelial dystrophy.² Therefore, a detailed case

history and clinical exam are necessary before referring patients for cataract surgery. The next two most common pathologies for corneal graft surgery are repeat graft surgery after failure and keratoconus.³

Currently, the United States has the highest rate of corneal transplants per capita.⁴ In the 2016 EBAA report, endothelial keratoplasty (EK) compromised 57% of surgeries performed in the United States, and full-thickness penetrating keratoplasty (PK) was performed in 38% of patients.³ Anterior lamellar keratoplasty (ALK) and deep anterior lamellar keratoplasty (DALK) procedures accounted for the small portion of remaining surgeries.

Since EK's introduction in 1999, there has been an impressive growth in the number of surgeries and literature publications, supplanting PK as the mainstay.^{5,6} In contrast, ALK and DALK surgeries were first introduced in 1959, but their popularity has waned, primarily due to the lack of properly trained ophthalmic surgeons.⁷ ALK and DALK also require a more prolonged operating room time and carry a high risk of perforation in older patients.

CASE HISTORY PEARLS

Many factors come into play when monitoring patients for corneal edema and considering referral for

keratoplasty. Questioning a patient on their visual symptoms is a crucial first step.

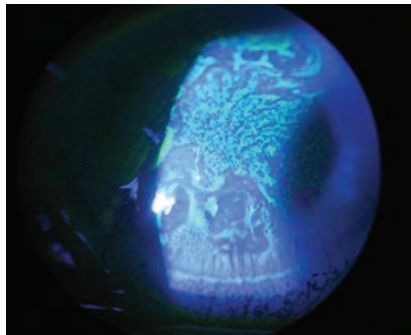
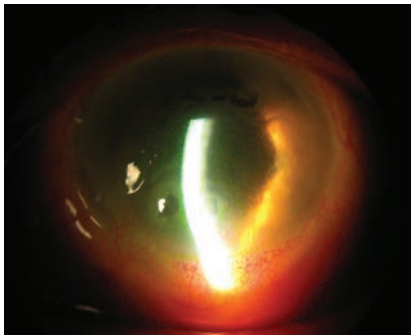
- Blurred or variable vision associated with corneal edema often has a diurnal nature—worse upon waking and improved later in the day. This is due to prolonged eyelid closure and a relatively hypotonic tear film, which reverses throughout the day with greater exposure. Symptoms of photophobia, glare, redness, tearing, pain or foreign-body sensation are also commonly associated with corneal edema.

- Most conditions associated with corneal edema present gradually over weeks, months or even years. Symptoms may be so gradual at times that the patient is able to function surprisingly well and at a much higher level than would be expected based on a slit-lamp biomicroscopy exam. Exceptions to this general rule would be edema caused by acutely elevated intraocular pressure (IOP),

ABOUT THE AUTHOR



Dr. Esposito is an attending provider and clinical researcher at the New Mexico Veterans Administration Health Care System Eye Clinic in Albuquerque, New Mexico. He is an adjunct clinical professor at the University of Houston College of Optometry, the Pacific University College of Optometry and the New England College of Optometry.



At left, this patient has severe corneal edema associated with complicated cataract surgery. At right, the same patient's corneal epithelium and irregularity can be easily seen with the sodium fluorescein dye pattern.

moderate corneal or intraocular inflammation or hydrops associated with corneal ectasias, such as keratoconus.

- Certain factors or special situations can also modify a patient's quality of vision and affect the surgery referral timeline. Low humidity and modest air movement may lead to visual improvement, whereas endothelial dysfunction from humid days or after a long shower can exacerbate corneal edema. A dehumidifier can be used as a trial and this may even help patients with concurrent ocular allergy. Visual acuity and function may not necessarily correlate well together when considering disabling glare during driving at night or other activities of daily living.

- Clinicians should always obtain a detailed medical history and current list of medications, as inflammatory conditions associated with uveitis (anklosing spondylitis, sarcoidosis) may also cause corneal edema. Amantadine, for example, helps treat Parkinson's disease and other neurologic diseases but may cause reversible corneal edema if used for a short period of time. Long-term use may cause permanent damage.^{8,9} Inadvertent exposure of the cornea to topical chlorhexidine preparation, commonly used during cosmetic facial surgery, may predispose a cornea to endothelial failure.¹⁰⁻¹³

- A number of systemic diseases and medications are associated with corneal opacification. These include metabolic/hereditary disorders such as mucopolysaccharidosis; immune-mediated diseases such as rheumatoid arthritis, Stevens-Johnson syndrome and ocular mucous membrane pemphigoid; and hematologic disorders such as monoclonal gammopathies and malabsorption syndromes, usually following colon resection. Amiodarone, dietary calcium supplementation, periocular radiation and various chemotherapeutic agents have all also been reported as causative agents for opacification.¹⁴⁻¹⁷

EXAMINATION PEARLS

After recording a detailed history, a comprehensive examination of the eye and adnexa is key to determining the etiology of most cases of corneal edema.

- Clinicians should test visual acuity with the lights on and off and compare to produce a qualitative assessment of the individual's functional status. When performing the external examination, pay careful attention to lid abnormalities, facial asymmetry and evidence of trauma. Slit-lamp biomicroscopy is exceedingly important, especially because it is universally available to ophthalmic providers, and other ancillary

testing may not be during initial examination.

- A differential diagnosis of corneal edema or opacification can be narrowed after noting the following: (1) unilateral or bilateral signs, (2) diffuse or localized edema, (3) primarily epithelial or stromal edema, (4) stromal infiltration, striae, thinning, scarring or vascularization and (5) endothelial guttae, Descemet's tears or detachments, endothelial vesicles, keratic precipitates and peripheral anterior synechiae.

- Clinicians can use various slit-lamp techniques such as sclerotic scatter, specular reflection or indirect illumination to evaluate all layers of the cornea. When performing a careful iris examination, note the shape of the pupil, as it is often evidence of past trauma, inflammation or complicated intraocular surgery. IOP measurement by Goldmann applanation tonometry is somewhat unreliable in abnormal corneas, so use alternative devices in concert, such as a pneumatonometer, a Tonopen device (Reichert) or a dynamic contour tonometer. Consider gonioscopy to rule out retained nuclear fragments, occult foreign bodies and secondary glaucomas that could cause elevated pressure and corneal decompensation.


ANCILLARY TESTING

Other tests can augment the clinical observations from the slit lamp exam.

- A potential acuity meter or pin-hole vision using an illuminated near card in a darkened room can assess potential acuity in an effort to bypass anterior segment pathology.

- Disruption of the central or paracentral ocular surface due to corneal edema or scarring can have a surprising impact on vision. Obtain best-corrected vision with spectacles and a rigid gas permeable (RGP) contact lens over-refraction.

KERATOPLASTY: WHEN AND WHY



The presence of stromal edema and linear folds of Descemet's membrane can help you narrow down a diagnosis.

This can quickly be done in-office by obtaining keratometry measurements and then fitting an RGP lens slightly flatter than the average keratometry reading. Be sure to note the mire pattern to correlate directly with the amount of anterior surface irregularity.

- Corneal pachymetry has become more readily available in ophthalmic offices and is important for quantifying corneal thickness and change over time. Ultrasonic pachymeters provide information about a single spot on the cornea, and their range is often limited to between 200 μm and 1,000 μm . With careful positioning and probe angulation, an interobserver standard deviation of 12 μm is the best to be expected.¹⁸

- If precision and peripheral measurements are important, anterior segment optical coherence tomography (AS-OCT) and Scheimpflug imaging systems provide greater accuracy. Since both of these techniques use light instead of sound, each one's accuracy decreases as stromal opacification worsens.

- The ultrasound biomicroscope provides the most accurate measurements when significant stromal edema is present. Keep in mind that measurements with different devices are not directly comparable in

clinical practice; however, most large studies report AS-OCT pachymetry measurements to be lower than ultrasound by between 7 μm and 26 μm .^{19,20}

- Scheimpflug imaging systems can assess the topographic characteristics of both the anterior and posterior corneal surfaces in addition to corneal thickness measurements. These systems have improved the ability to diagnose forme fruste keratoconus and other corneal ectasias immensely. They can also assess the depth of corneal opacification, which provides useful information for surgical planning.

- AS-OCT provides high resolution, cross-sectional images of the cornea, angle and anterior chamber. Measurement tools to document and follow changes in corneal thickness, angle and anterior chamber are standard with all models. Currently, AS-OCT has the greatest utility for imaging deep and retrocorneal structures, such as a large detached Descemet's membrane and a retrocorneal membrane. These conditions may arise with trauma, after EK surgery or acute corneal edema associated with keratoconic hydrops. Ultrasound biomicroscopy utility is similar to AS-OCT but is more useful when dealing with extremely opaque corneas and imaging deeper anterior segment structures.

- Endothelial cell count (ECC) is comparable using both specular and confocal microscopy.²¹ Confocal microscopy provides an advantage over specular when imaging the corneal endothelium in cases of corneal edema. This is particularly useful in cases of unilateral corneal edema where the preoperative diagnosis may be undetermined. Special cases like iridocorneal endothelial syndrome or posterior polymorphous corneal dystrophy have distinctive confocal appearances.

MANAGEMENT

Treatment for corneal edema or opacification may be optical, medical, surgical or a combination, depending on the etiology, nature and severity of the opacity. The needs, desires and health status of the patient also play a part.

The medical agents used to control corneal edema include all ocular hypotensive agents except two drug classes. Prostaglandin analogs should be avoided in patients for whom inflammation is a possible contributing factor—any history of graft rejection or uveitis.²² Also, when endothelial disease is a possible contributing factor, avoid carbonic anhydrase inhibitors as the first line of therapy because of their potential to interfere with the endothelial pump.²³ Use topical corticosteroids when inflammation is present and infection has been ruled out. Although hyperosmotic agents or hairdryers are commonly suggested treatment routines, there are no studies that have determined the optimal routines of either of these modalities.

Topical antibiotics and therapeutic contact lenses can be used in conjunction with bullae rupture in PBK to reduce the risk of infection and help control discomfort or pain. Although many different lenses may be used, thin lenses with high water content and a high Dk are thought to have the greatest advantages.²⁴ Ideally, use bandage contact lenses for a finite treatment period; however, longer-term use may be required in many cases, with periodic exchange of the lens.

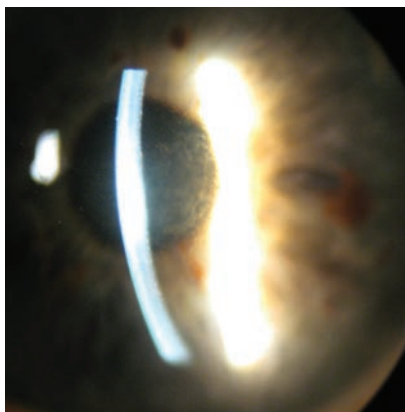
Patients with corneal edema and persistent discomfort but limited visual potential are better candidates for a conjunctival flap, amniotic membrane or one of many scarification procedures. While less common, a patient with good visual potential may opt for one of these procedures when extenuating circumstances

affecting general health or follow-up care/transportation become issues.

Timely referral of patients with endothelial dysfunction is extremely important because patients with chronic PBK often develop a layer of subepithelial fibrosis. If a patient already has considerable subepithelial scarring, this will prevent a good visual outcome following an EK. They would instead need full-thickness PK or a superficial keratectomy combined with EK.

For patients with endothelial dysfunction, it is important to address considerations beyond visual acuity assessment. EK as a combined procedure should be considered in the context of a visually significant cataract and even early cataracts with the presence of corneal edema. Ultrasound pachymetry measurement in excess of 640µm or the presence of epithelial edema suggest the cornea may decompensate with intraocular surgery.²⁵

An ECC below 800 has also been suggested as predictive of poor endothelial cell function post-cataract surgery. Confluence of guttae, even in the absence of stromal or epithelial edema, can reduce visual acuity, contrast sensitivity and increase symptomatic glare for patients.²⁵ Consider these criteria along with



In this patient with Fuchs' endothelial dystrophy and central stromal edema, note the light dots along the posterior aspect of the corneal light beam.

activities of daily living to prompt an early referral for EK. Once subepithelial scarring has occurred with chronic PBK, an early referral is less important, since PK will be the preferred surgical technique.

Prior to 2000, virtually all corneal transplant candidates with decompensated corneas underwent PK. However, according to the 2011 EBAA report, approximately 75% of patients with corneal edema are now managed with EK.²⁶ This broad acceptance of EK is due to its rapid visual recovery, its significantly greater optical (both astigmatic and refractive) predictability, the presence of greater wound strength and its lesser risk for rejection with a greater long-term survival rate.²⁶

For patients with corneal subepithelial or stromal scarring, the procedure of choice will be PK, and, therefore, early consultation for graft surgery is less important. These patients may benefit more from initially improving ocular surface health (addressing tear film stability, lid function and hygiene), controlling IOP in the setting of glaucoma and stabilizing glycemic control in diabetic populations.

As corneal graft surgery evolves, **Also** do our pre-op considerations. New surgical techniques make decisions regarding your patient all the more important, as each case may do better with one procedure over another. Practitioners must remain vigilant when observing patients for signs of edema and know when the time is right to refer them for keratoplasty. **RCCL**

1. Flaxman SR, Bourne RRA, Resnikoff S. Global causes of blindness and distance vision impairment 1990-2020: a systematic review and meta-analysis. *Lancet Glob Health*. 2017;5:e1221-34.
2. Eye Bank Association of America. 2016 Eye Banking Statistical Report. Washington DC: Eye Bank Association of America; 2017.
3. Afshari NA, Pittard AB, Siddiqui A. Clinical Study of Fuchs corneal endothelial dystrophy leading to penetrating keratoplasty: a 30-year experience. *Arch Ophthalmol*. 2006;124:777-80.

4. Gain P, Jullienne R, He Z. Global survey of corneal transplantation and eye banking. *JAMA Ophthalmol*. 2016;134:167-73.
5. Melles GR, Lander F, Beekhuis WH. Posterior lamellar keratoplasty for a case of pseudophakic bullous keratopathy. *Am J Ophthalmol*. 1999;127:340-1.
6. Terry MA, Ousley PJ. Endothelial replacement without surface corneal incisions or sutures: topography of the deep lamellar endothelial keratoplasty procedure. *Cornea*. 2001;20:14-8.
7. Hallermann W. Some remarks on keratoplasty. *Klin Monbl Augenheilkd Augenarztl Fortbild*. 1959;135:252-9.
8. Jeng BH, Galor A, Lee MS. Amantadine-associated corneal edema potentially irreversible even after cessation of the medication. *Ophthalmology*. 2008;115:1540-4.
9. Naumann GO, Schlotzer-Schrehardt U. Amantadine-associated corneal edema. *Ophthalmology*. 2009;116:1230-1.
10. Phinney RB, Mondino BJ, Hofbauer JD. Corneal edema related to accidental Hibiclen exposure. *Am J Ophthalmol*. 1988;106:210-5.
11. Van Rij G, Beekhuis VH, Eggink CA, et al. Toxic keratopathy due to the accidental use of chlorhexidine, cetrizime and cialit. *Doc Ophthalmol*. 1995;90:7-14.
12. Ohguro N, Matsuda M, Kinoshita S. The effects of denatured sodium hyaluronate on the corneal endothelium in cats. *Am J Ophthalmol*. 1991;112:424-30.
13. Varley GA, Meisler DM, Benes SC. Hibiclen keratopathy: a clinicopathologic case report. *Cornea*. 1990;9:341-6.
14. Kaplan LJ, Cappaert WE. Amiodarone keratopathy. Correlation to dosage and duration. *Arch Ophthalmol*. 1982;100:601-2.
15. Jhanji V, Rapuano CJ, Vajpayee RB. Corneal calcific band keratopathy. *Curr Opin Ophthalmol*. 2011;22:283-9.
16. Jeganathan VS, Wirth A, MacManus MP. Ocular risks from orbital and periocular radiation therapy: a critical review. *Int J Radiat Oncol Biol Phys*. 2011;79:650-9.
17. Van Meter WS. Central corneal opacification resulting from recent chemotherapy in corneal donors. *Trans Am Ophthalmol Soc*. 2007;105:207-13.
18. Miglior S, Albe E, Guareschi M. Intraobserver and interobserver reproducibility in the evaluation of ultrasonic pachymetry measurements of central corneal thickness. *Br J Ophthalmol* 2004;88:174-7.
19. Wirbelauer C, Scholz C, Hoerauf H. Non-contact corneal pachymetry with slit lamp-adapted optical coherence tomography. *Am J Ophthalmol*. 2002;133:444-50.
20. Zhao PS, Wong TY, Wong WL. Comparison of central corneal thickness measurements by visante anterior segment optical coherence tomography with ultrasound pachymetry. *Am J Ophthalmol* 2007;143:1047-9.
21. Mustonen RK, McDonald MB, Srivannaboon S, et al. In vivo confocal microscopy of Fuchs' endothelial dystrophy. *Cornea*. 1998;17:493-503.
22. Aydin S, Ozcura F. Corneal edema and acute anterior uveitis after two doses of travoprost. *Acta Ophthalmol Scand* 2007;85:693-4.
23. Wirtitsch MG, Findl O, Heinzl H, Drexler W. Effect of dorzolamide hydrochloride on central corneal thickness in humans with corneal guttata. *Arch Ophthalmol*. 2007;125:1345-50.
24. Foulks GN, Harvey T, Raj CV. Therapeutic contact lenses: the role of high-Dk lenses. *Ophthalmol Clin North Am* 2003;16:455-61.
25. Seitzman GD, Gottsch JD, Stark WJ. Cataract surgery in patients with Fuchs' corneal dystrophy: expanding recommendations for cataract surgery without simultaneous keratoplasty. *Ophthalmology*. 2005;112:441-6.
26. Wu EI, Ritterband DC, Yu G. Graft rejection following descemet stripping automated endothelial keratoplasty: features, risk factors, and outcomes. *Am J Ophthalmol*. 2012;153:949-57.

THE ART OF CORNEAL TRANSPLANTATION

Optometrists have several options when it comes to keratoplasties, each of which has its own pros, cons and management guidelines.

By Andrew Steele, OD

Corneal transplantation has changed dramatically since Eduard Zirm performed the first one on a human just over a century ago. As an avascular tissue lacking lymphatic vessels, the cornea enjoys immune privilege, resulting in it being associated with one of the lowest rejection rates of all human organs.¹ In recent years, the evolution of techniques and technologies has substantially improved outcomes and enabled a shift toward replacement of only the diseased layers. The different transplant types can be a bit disorienting, but understanding their indications and knowing how to perform perioperative care can make a world of difference for optometrists and their patients.

KERATOPLASTY INDICATIONS

The two main categories of keratoplasties are full-thickness and partial-thickness. As the latter procedures only remove one or more selected layers of the cornea, they are also referred to as lamellar. These keratoplasties can be further classified as either anterior or posterior. The indications for transplantation are numerous and include optical, tectonic and reconstructive, therapeutic and,

in rare cases, cosmetic needs. Patients who have a significantly reduced best-corrected visual acuity (BCVA) from a corneal pathology usually benefit from a graft. Occasionally, transplantation is required to save an altered corneal structure from perforation or thinning. Pain management for bullous keratopathy and non-healing ulcers can also be a primary therapeutic indication. Cosmetic reasons for surgery in eyes without visual potential remain controversial and are considered weak indications.

FULL- VS. PARTIAL-THICKNESS

Historically, full-thickness penetrating keratoplasties (PKP) have been the primary approach to corneal transplantation, during which all layers are replaced. The technique is standardized and familiar to most corneal surgeons. However, complications are relatively common, and recovery can be painstaking and take up to a year to stabilize. Vision may actually be worse at first and not improve for six months or longer, partially due to the unpredictability of the cornea's toricity, and often requires rigid contact lens correction. Penetrating trauma, corneal hydrops and diseases

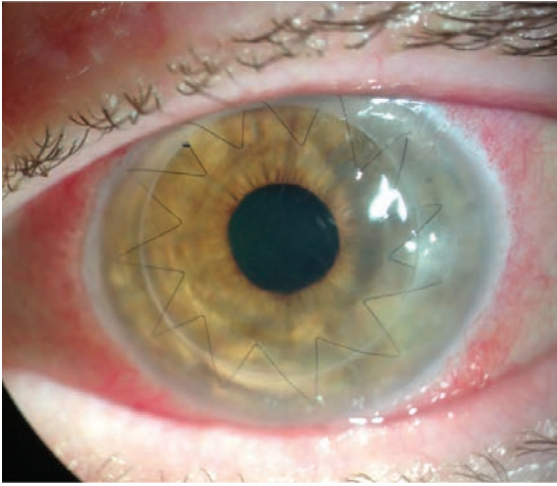
involving the stroma and endothelium still require full-thickness grafts. However, pathology involving 85% to 95% of the cornea, sparing Descemet's membrane (DM) and the endothelium, may be best suited for a partial-thickness graft or a deep anterior lamellar keratoplasty (DALK).

Corneal ectasias, stromal dystrophies and scarring from a previous infection often qualify for a DALK, which has major advantages over a PKP. The risks of infection, hemorrhage and traumatic wound dehiscence associated with "open sky" procedures are considerably reduced. DALKs also avoid the most common and serious type of rejection—endothelial—and cause significantly

ABOUT THE AUTHOR



Dr. Steele practices consultative, medical and surgical optometry at Bennett & Bloom Eye Centers in Louisville, KY. He is also an American Academy of Optometry fellow, an adjunct professor at the Indiana University and the University of Alabama-Birmingham schools of optometry, an attending for fourth-year interns and ocular disease residents and a lecturer for continuing education courses. He graduated with honors from the Ohio State University College of Optometry and completed resident training in ocular disease with Bennett & Bloom.



Ten months after a full-thickness PKP, a 68-year-old white female developed methicillin-resistant *Staphylococcus aureus* keratitis at the graft-host junction and early endothelial rejection after suture removal. She was treated with fortified antibiotics, steroids and an intrastromal injection. After a week, only a small scar remained.

THE ENDOTHELIAL ROUTE

Since 2011, the number of endothelial keratoplasties (EK) in the United States has surpassed full-thickness grafts.⁴ For posterior corneal disease, an EK is superior to a PKP or a DALK in nearly every aspect and is associated with a better visual acuity, a faster recovery time and a lower rejection rate. There are two primary types of EKs: a Descemet's stripping automated endothelial kerato-

plasty (DSAEK) and a Descemet's membrane endothelial keratoplasty (DMEK). A DSAEK graft includes some posterior stroma, DM and the corneal endothelium and comprises about 100µm to 200µm of tissue. A DMEK graft does not contain any stroma and may only be 10µm to 15µm in thickness. In 2017, the number of PKP grafts in the United States was 18,346

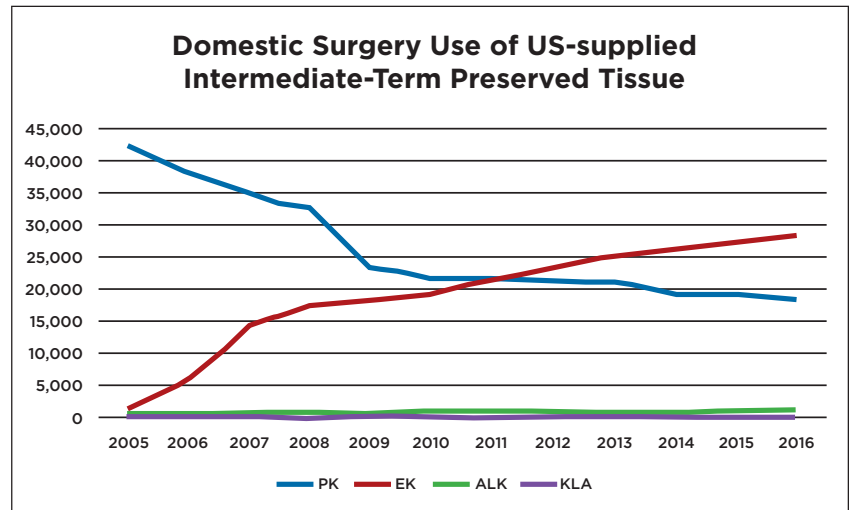
(a decrease of 1.3% since 2016), while EK numbers increased by 2.6% to 28,993, largely due to the 18.1% increase in DMEK procedures.⁵

The most common indication for an EK is Fuchs' endothelial dystrophy (FED).⁶ Others include pathologies confined to the endothelium and DM, such as posterior polymorphous dystrophy and some cases of pseudophakic bullous keratopathy. FED is usually inherited as an autosomal dominant condition that causes endothelial cells to die off faster than normal. Female patients commonly suffer from a more debilitating version of the disease.

The hallmark beaten-metal appearance we refer to as guttata starts to appear during a patient's third decade. Using a specular reflection technique when examining guttata with a slit lamp may produce the best results. Retroillumination of the iris or fundus is helpful if the beam width is moderately narrow, allowing for the appropriate contrast. Newer technologies provide endothelial cell counts via specular microscopy. The AC and corneal thickness

less endothelial cell loss than PKPs.² Patients who receive a DALK stabilize more rapidly, allowing for earlier suture removal and tapering of topical steroids. The surgery itself, however, is more challenging. While using the Anwar big-bubble technique to detach DM from the stromal layers aids in a faster and overall safer approach, it also increases surgical complexity and introduces other risks. Intraoperative DM tears may result in DM detachment, which is also called a double anterior chamber (AC).³

Postoperative management is similar to that of a full-thickness keratoplasty and requires a long course of topical steroids. Half of PKP patients end up with at least four diopters of astigmatism, which is often irregular and could produce significant anisometropia and aniseikonia. Unfortunately, the likelihood of high astigmatism is not lessened in a DALK, and satisfactory visual rehabilitation with rigid gas permeable lenses is often still required.



Improvements in surgical technique have allowed endothelial keratoplasties to thrive in recent years, eclipsing full-thickness procedures.

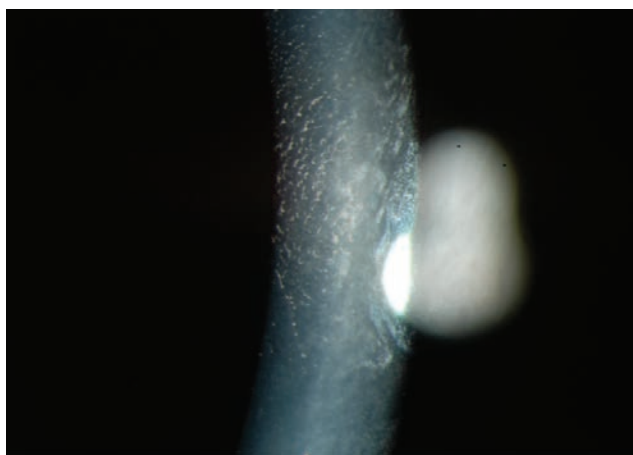
THE ART OF CORNEAL TRANSPLANTATION

can now be visualized with anterior segment OCT. Occasionally, guttata deposition may be so confluent that it has a whitish plaque appearance. Some corneal haze represents permanent fibrosis.

Ideally, an EK should be performed before any stromal scarring appears. Patients who notice morning worsening of their vision have started their descent toward corneal endothelial decompensation. Concentrated sodium chloride ophthalmic drops may help symptoms temporarily, but patients should be closely monitored, and transplantation should be seriously considered, especially if epithelial edema develops. Many cases, unfortunately, progress rapidly, with corneal bullae into dense subepithelial haze, possibly eliminating a patient's candidacy for an EK.

NEW AND IMPROVED TECHNIQUES

Educating patients on surgical expectations and the necessity of close monitoring postoperatively is crucial. Candidates must understand that their vision will be blurry for the first few days due to the intraoperative air bubble injected into the AC during surgery. Successful donor adhesion requires faithful supine positioning for the first 72 hours. Patients may sit up to eat, use the bathroom and bathe but are typically required to spend 45 to 50 minutes of every hour with their heads flat and chins elevated about 30 degrees. Maintaining the proper gas fill is critical for success, which is why tubes, aphakia and major iris defects are relative contraindications.



High magnification image of endothelial corneal guttata by specular reflection.

It is a challenge to keep air in these eyes, which makes attachment so difficult.

Injecting sulfur hexafluoride gas in place of air into the AC, a technique used in vitrectomies, is favorable due to its extended duration—about four to seven days of gas support on the donor—compared with air, which dissipates more rapidly.⁷ Due to risks of pupillary block from either bubble type, one or more peripheral iridotomies (PIs) should be placed inferiorly preoperatively with a YAG laser, as the bubble will block a superior PI when the patient is upright. Some choose to create a surgical PI intraoperatively, which does not come without risks. Surgical PIs can bleed, sometimes in delayed fashion.⁸ If blood is present in the AC, clots and fibrin may form.

Given the fragility of the tissue, manipulating the donor graft can be the most challenging part of performing a successful EK, especially a DMEK. The graft is susceptible to expulsion from an incision wound and may invert. If the patient is pseudophakic with posterior opacification, consider delaying the YAG.

The flattening of the AC in an

EK, which is key for unfolding, can cause the vitreous to prolapse through a large capsulotomy.

Patients who have undergone a vitrectomy are usually not good candidates for an EK. In some cases, the AC will not shallow when fluid is let out of the wound; the iris sags posteriorly like a hammock while the eye softens and wrinkles. This is problematic because the forward movement of the iris is needed

to hold the donor tissue partially open long enough for the surgeon to put in the initial bubble.

New techniques, especially in the arena of donor preparation, have made complex, delicate and sometimes frustrating DMEK surgeries more manageable. Corneal surgeons have slowly adopted DMEKs in part because of difficulties encountered with donor preparations and concerns about the potential loss of donor tissue. Early adopters reported tissue wastage and a failure rate of one in three during donor peeling.⁹

Lawrence Tenkman, MD, a corneal surgeon out of Louisville, KY, has modified the Giebel 2008 SCUBA (submerged cornea using backgrounds away) technique with impressive success, reporting only one tissue failure in over 600 DMEK cases. Scored with a blunt Y-hook, the donor edge is stained with VisionBlue, lifted with a glide technique and peeled by corridors, minimizing tension. This groundbreaking method provides guidance in handling excessive separation resistance and small breaks that form during peeling that Dr. Tenkman refers to as “horseshoe tears.”¹⁰

Other improvements facilitating the rise of DMEK procedures include instrumentation, such as the Straiko Modified Jones Tube, and Eye Bank stamping of an “S” (signifying “stroma”) on the donor tissue to prevent inverted grafts (iatrogenic graft failure can occur when a surgeon mistakenly places the endothelium in contact with the stroma).¹¹

POST-OP MANAGEMENT

On day one of the postoperative period, mild to moderate corneal edema with folds is expected. A bandage contact lens may have been placed in the operating room. The patient should be reassured that blurry vision is normal due to the bubble.

The goal is an attached DMEK donor and a deep AC with air filling 50% to 70% of the chamber. It is also imperative to ensure there is not an air-induced pupillary block, which pushes the pupil back against the lens and seals it to prevent the anterior flow of fluid. If the inferior PI is not functioning, the aqueous produced by the ciliary body cannot flow into the AC, and the iris bulges forward. Functionally, this is similar

to acute angle-closure glaucoma and requires immediate action. Surprisingly, some patients with this issue may experience symptoms of nausea but not eye pain.

The initial and least invasive approach involves putting the patient in a full supine position, parallel to the ground, and instructing them to look in the extreme superior gaze. This technique moves the bubble inferiorly in the AC, occasionally with enough force to break the adhesion between the iris and the cornea. If a closed PI is present, attempt to reopen it via YAG laser.

Sometimes, supine positioning is not enough, and performing a paracentesis is necessary. Sterile conditions must be prioritized, preferably with betadine 5% and antibiotic drops to the ocular surface. Attached to a 1mL syringe, a 30-gauge needle should be injected at the limbus and parallel to the iris to avoid the DMEK graft. The needle should be inserted into the bubble, and the plunger should be slowly withdrawn to let enough air out so the eye is no longer firm. Sometimes, re-bubbling is necessary to ensure proper peripheral donor attachment, especially in

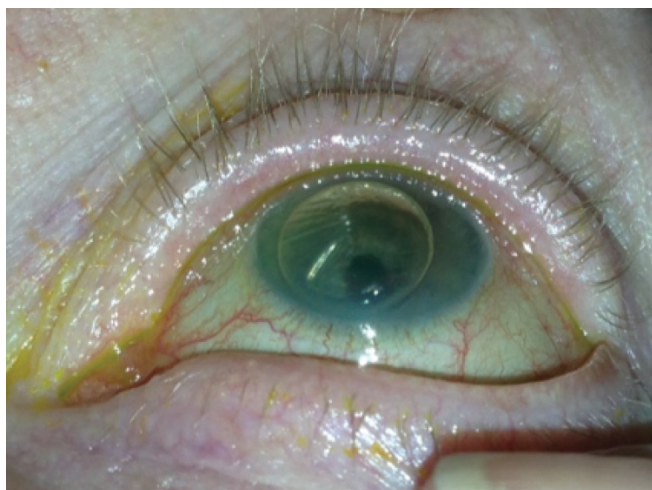cases of a total graft detachment. If the graft is not detached by more than a third or a fluid cleft is present, it may only require observation.

Even if postoperative findings are normal, positioning, restrictions

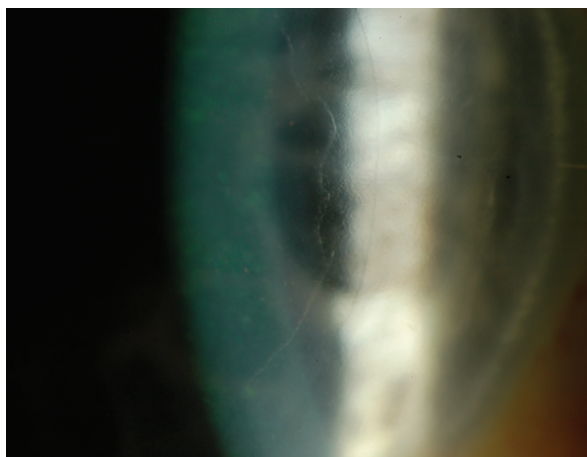
and drop scheduling should be reemphasized to the patient. By day three or four, there should be much less corneal edema, and the air bubble should only fill about 25% of the AC. Generally, more air time is needed if there is focal edema from the DM separation that is significant enough to cause blurry vision, in which case, patient instructions should favor positions that allow the bubble to press as directly against the dehisced zone as possible. At this point, the patient may not need to adhere to the supine position.

After one week, the bandage lens can be removed, and if a single suture is present, it can be taken out. The use of topical antibiotics can be discontinued three days after the suture is removed. It is appropriate to order anterior segment OCT imaging and/or endothelial cell counts at this stage. Beginning to slowly taper the steroid is not suggested until three to four months after surgery. Some surgeons recommend complete discontinuation by six months, but most experts agree that a daily dose of a topical steroid should be used indefinitely to reduce the risk of rejection.¹²

The learning curve is steep, but in most cases, outcomes from a DMEK are superior to those from a DSAEK, which is largely due to the problems that arise from the stroma-to-stroma interface of DSAEK grafts.¹³ A tissue with a certain radius of curvature confining itself to a smaller radius of curvature results in micro-irregularities. Bare stroma cannot be avoided in these cases, leading to edema and a significantly longer healing time. Eight percent to 10% of DSAEK grafts are rejected, according to recent studies.¹⁴ DMEK grafts, on the other hand, enjoy a rate of just above 1%.¹⁴



This is an example of the bubble that can be seen in the supine position one day after DMEK surgery.



Ideal donor attachment from DMEK surgery looks like this one-week postoperatively.

Postoperative stability following a DSAEK may take four to six months and delay a prescription update until then. In contrast, a DMEK mimics normal anatomy and is essentially refractive-neutral, creating a negligible hyperopic shift of only about +0.25D compared with a +1.00D to +1.50D shift in a DSAEK. DMEK patients may be ready for an updated prescription in one to three months. Nearly 50% of DMEK patients achieve 20/20 six months postoperatively, and some surgeons boast a higher rate.¹⁴ A much smaller percentage of patients who have had a DSAEK achieve 20/20, and they only do so when very thin tissue is used. More often than not, patients end up with a BCVA ranging from 20/20 to 20/60.¹⁵

Unfortunately, astigmatism created by a DSAEK is posterior and not easily measurable and, therefore, limits combined cataract procedures to implant a non-toric intraocular lens (IOL). But, DMEK patients are far more predictable. Using a slightly adjusted myopic target, toric IOLs can be successfully used.¹⁶ Commonly, EKs are combined with cataract surgery for convenience and a quicker re-

covery with a single procedure. Phakic patients over 50 years old who have moderate guttata may even benefit from a proactive approach. We know endothelial cell loss accelerates following cataract surgery, which could turn a mild FED case into a severe case requiring an EK.

LOOKING TOWARD THE FUTURE

The future of lamellar keratoplasties is bright. Since 2006, femtosecond lasers have been used to produce custom trephination patterns. Femtosecond laser-enabled keratoplasty has been praised for achieving better donor alignment, resistance to leakage, faster healing and less postoperative astigmatism. With the emergence of femtosecond technology, improvement in descemetorhexis is being examined and may prove to be a useful adjunct in DMEK and DSAEK cases.¹⁷ Pre-DMEK procedures, which are thought to include Dua's layer, are being seriously studied now. At 25 μ m to 30 μ m in thickness, these keratoplasties have an advantage over the ultra-thin 10 μ m to 15 μ m DMEK donors.¹⁸

Our role as optometrists goes well beyond visual rehabilitation. From surgical consultation and preoperative YAG PI to paracentesis and suture removal, optometrists across the country are learning how to do more. Education expansion and progressive legislation has allowed many to play an integral role in

the perioperative care of corneal transplantation. Working together with cornea surgeons will allow for fluid comanagement and undoubtedly better outcomes for our patients, as the ultimate goal of any keratoplasty is to improve quality of life through increased vision and/or comfort. **RCCL**

1. Amouzegar A, Chauhan SK, Dana R. Alloimmunity and tolerance in corneal transplantation. *J Immunol.* 2016;196(10):3983-91.
2. Huang A, Bogucki J, Sheybani A. Faculty of 1000 evaluation for Endothelial cell loss and visual outcome of deep anterior lamellar keratoplasty versus penetrating keratoplasty: a randomized multicenter clinical trial. *F1000Prime.* December 2011.
3. Daneshgar F, Fallahtafti M. 'Expanding bubble' modification of 'big-bubble' technique for performing maximum-depth anterior lamellar keratoplasty. *Eye (Lond).* 2011;25(6):803-8.
4. 2016 eye banking statistical report. Eye Bank Association of America. 2017:5.
5. 2017 eye banking statistical report. Eye Bank Association of America. 2018:9.
6. Le R, Yucel N, Khattak S, et al. Current indications and surgical approaches to corneal transplants at the University of Toronto: a clinical-pathological study. *Can J Ophthalmol.* 2017;52(1):74-9.
7. Von Marchtaler PV, Weller JM, Kruse FE, et al. Air versus sulfur hexafluoride gas tamponade in Descemet membrane endothelial keratoplasty: a fellow eye comparison. *Cornea.* 2018;37(1):15-9.
8. Hlinomazová Z, Horácková M, Pirnerová L. DMEK (Descemet membrane endothelial keratoplasty)—early and late postoperative complications. *Cesk Slov Oftalmol.* 2011;67:75-9.
9. Lie JT, Birbal R, Ham L, et al. Donor tissue preparation for Descemet membrane endothelial keratoplasty. *J Cataract Refract Surg.* 2008;34(9):1578-83.
10. Tenkman LR, Price FW, Price MO. Descemet membrane endothelial keratoplasty donor preparation: navigating challenges and improving efficiency. *Cornea.* 2014;33(3):319-25.
11. Veldman PB, Dye PK, Holiman JD, et al. Stamping an S on DMEK donor tissue to prevent upside-down grafts: laboratory validation and detailed preparation technique description. *Cornea.* 2015;34(9):1175-8.
12. Price MO, Scanameo A, Feng MT, et al. Descemet's membrane endothelial keratoplasty: risk of immunologic rejection episodes after discontinuing topical corticosteroids. *Ophthalmology.* 2016;123(6):1232-6.
13. Marques RE, Guerra PS, Sousa DC, et al. DMEK versus DSAEK for Fuchs' endothelial dystrophy: a meta-analysis. *Eur J Ophthalmol.* April 1, 2018. [Epub ahead of print].
14. Deng SX, Lee WB, Hammersmith KM, et al. Descemet membrane endothelial keratoplasty: safety and outcomes: a report by the American Academy of Ophthalmology. *Ophthalmology.* 2018;125(2):295-310.
15. Guerra FP, Anshu A, Price MO, et al. Descemet's membrane endothelial keratoplasty: prospective study of one-year visual outcomes, graft survival and endothelial cell loss. *Ophthalmology.* 2011;118:2368-73.
16. Schoenberg ED, Price FW Jr, Miller J, et al. Refractive outcomes of Descemet membrane endothelial keratoplasty triple procedures (combined with cataract surgery). *J Cataract Refract Surg.* 2015;41(6):1182-9.
17. Mckee HD, Jhanji V. Femtosecond laser-assisted graft preparation for Descemet membrane endothelial keratoplasty. *Cornea.* 2018;37(10):1342-4.
18. Narang P. Pre-Descemet's endothelial keratoplasty. Management of PHACO Complications: Newer Techniques. 2014:110-4.

Earn up to
28 CE
Credits*

NEW TECHNOLOGIES
& TREATMENTS IN
2019 EYE CARE
RGVCE
REVIEW'S COMMITMENT
TO CONTINUING EDUCATION

OCCRS
OPTOMETRIC CORNEA, CATARACT
AND REFRACTIVE SOCIETY

SAN DIEGO

APRIL 11-14, 2019

We invite you to attend a unique joint meeting held at the Manchester Grand Hyatt.

Review's New Technologies & Treatments in Eye Care and Optometric Cornea, Cataract and Refractive Society's annual meetings are combined to provide you with up to 28* COPE CE credits in one weekend.

Program Chairs:



Paul M. Karpecki, OD, FFAO
Review Program Chair



David Friess, OD, FFAO
President, OCCRS



Manchester Grand Hyatt

1 Market Place
San Diego, CA 92101
Phone: 619- 232-1234

Three Ways to Register

Online: www.reviewsce.com/sandiego2019

Call: 866-658-1772 • **E-mail:** reviewmeetings@jhihealth.com

Convenient opportunities to register for one or both meetings.**

A limited number of rooms have been reserved at **\$269 plus tax per night.**

Please make reservations with the hotel directly at 1-888-421-1442. For group rate, mention "Review's New Technologies and Treatments in Eye Care".

REGISTER ONLINE: WWW.REVIEWSCE.COM/SANDIEGO2019

Administered by
RGVCE
REVIEW'S COMMITMENT
TO CONTINUING EDUCATION

COPE
*Approval pending

SALUS
UNIVERSITY
Pennsylvania College of Optometry

New Technologies & Treatments
conference is partially supported by an
unrestricted educational grant from
Bausch & Lomb

**Additional registration fees if attending both meetings. Agenda subject to change. RGVCE partners with Salus University for those ODs who are licensed in states that require university credit. See www.reviewsce.com/events for any meeting changes or updates.

POST-CATARACT SURGERY INFLAMMATION: A Toxin **OR** A Bug?

Although rare, TASS and endophthalmitis are possible complications, and clinicians must be able to recognizing the difference.

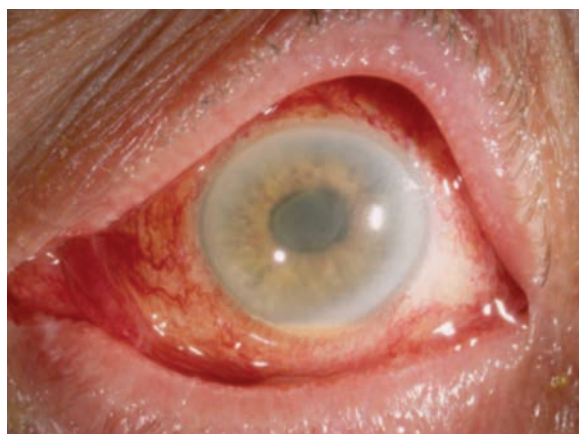By Barbara J. Fluder, OD

While cataract surgery has become an incredibly safe outpatient procedure, it's still surgery, and more than 738,000 surgical site infections occur every year involving outpatient surgery patients in the United States.¹ With the aging baby boomer generation, the number of cataract surgeries is expected to rise, and clinicians must be prepared to handle the possible increased prevalence of complications.

Two in particular—toxic anterior segment syndrome (TASS) and endophthalmitis—are often confused and pose significant risk if they arise.

Both can present early in the post-op period and share similar symptoms such as decreased visual acuity, redness and pain. The pain is usually mild with TASS but is often a deep ocular pain with endophthalmitis. Signs can be similar as well, including hypopyon, anterior chamber reaction such as fibrin formation and corneal edema. Endophthalmitis may show a vitritis and loss of red reflex.

While they can present with similar signs and symptoms, they have different etiologies and



Diffuse limbus-to-limbus corneal edema and anterior segment inflammation noted in a patient with TASS. Reprinted with permission from Deschênes J.¹¹

treatment paths—one of which requires swift changes to the surgical protocol and prompt reporting to state and local health departments.

A TOXIC SITUATION

TASS occurs when toxic substances enter the anterior chamber and cause a sterile, noninfectious postoperative inflammatory response. Signs and symptoms of TASS present within 12 to 24 hours of cataract or refractive surgery and can include hypopyon, fibrin formation in the anterior chamber, corneal edema, irregular pupil, decreased visual acuity, mild pain and redness. Cellular necrosis and apoptosis occur, resulting in acute postoperative inflammation. The

toxic substances break down the corneal endothelial junctions, causing the viable remaining cells to spread out over the damaged area in an effort to maintain the endothelial pumping system. If the remaining functional cells are unable to compensate for the loss, it can cause permanent corneal edema. Due to its inability to regenerate and replace dead cells, the corneal endothelium is often the most damaged structure. If the trabecular meshwork

is damaged as well, it can cause decreased aqueous outflow, peripheral anterior synechiae and increased intraocular pressure.²

Four situations can lead to TASS:²

1 *Inadequate sterilization of instruments.* To avoid this concern, manufacturers of reusable handpieces recommend the instruments be flushed with 120cc of sterile de-ionized or distilled water.

ABOUT THE AUTHOR



Dr. Fluder practices at Williams Eye Institute in Merrillville, IN.

2 *Enzymes and detergents remain on cleaned instruments.* This can be especially problematic with multi-specialty surgical centers that use enzymes and detergents generously to clean off tissue left on surgical instruments from several types of surgery. Any residue that remains on the instruments from this cleaning process can cause inflammation. Better education can help multispecialty surgical centers and hospitals understand that ophthalmic surgery rarely leaves tissue on instruments, and the use of these detergents and enzymes, which can be a cause of inflammation, may not be necessary.²

3 *Endotoxin contamination during instrument sterilization.* Even though gram-negative bacteria, which can reside in water baths and autoclave reservoirs, are killed during autoclaving, heat-resistant endotoxins from the bacteria can remain on instruments. The water used for these cleaning procedures must be changed regularly to avoid this complication.

4 *Preservatives from products and medications.* Products used during intraocular surgery, and intracameral drugs and balanced salt solutions used in the anterior chamber, must all be preservative-free.² Preservatives or stabilizing agents used in ophthalmic solutions can be toxic to the corneal endothelium, leading to TASS.

The most common preservative is benzalkonium chloride. While this product is relatively safe when used on the ocular surface, it can cause corneal edema and endothelial cell damage when it enters the anterior chamber. Stabilizing agents such as bisulfate are also toxic to the corneal endothelium if it enters the anterior chamber. This agent is often found in epinephrine and balanced

salt solutions. Any changes in pH, osmolarity or ionic composition of balanced salt solutions can also cause inflammation and damage to the corneal endothelium.³

TALES OF CONTAMINATION

Several products containing preservatives and other additives have been linked to TASS:

In December 2017, the American Society of Cataract and Refractive Surgery (ASCRS) published a clinical alert regarding intraocular use of epinephrine to maintain mydriasis during cataract surgery. According to the alert, in January 2017 PAR Pharmaceutical began shipping a new formulation of epinephrine that contained 0.457mg of sodium metabisulfite and 2.25mg of tartaric acid per ml. While there is no published data or experience with intracameral administration of solutions containing tartaric acid, ASCRS had become aware of several reports of TASS associated with inadvertent use of the PAR epinephrine.³

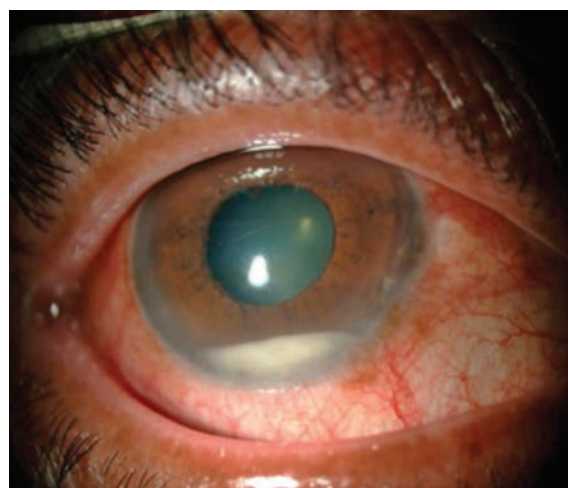
Since then, the indication of use and maintenance of mydriasis during intraocular surgery has been removed from the product's prescribing information. The 30ml bottles of epinephrine are clearly labeled "not for ophthalmic use," although the 1ml single-use vials are not.⁴

Some products contain 0.1% bisulfite, which is used to improve stability by delaying the oxidation of the active substance. This agent can cause damage to the corneal endothelium. Ideally, preservative-free and bisulfite-free (PFBF)

epinephrine is preferred, although corneas exposed to 0.05% sodium bisulfite have not shown any functional or structural damage to the corneal endothelium.⁴

In 2005, seven surgery centers across six states experienced a TASS outbreak related to a balanced salt solution contamination.⁵ Of 112 patients diagnosed with TASS from July 19, 2005 through November 28, 2005, 89% had been exposed to a single brand of balanced salt solution, AMO Endosol, manufactured by Cytosol Laboratories and distributed by Advanced Medical Optics.⁵ No significant breaks in sterile technique or instrument reprocessing occurred. Fourteen balanced salt solution lots were tested and five had elevated levels of endotoxin. The product was recalled, effectively containing the outbreak.⁵

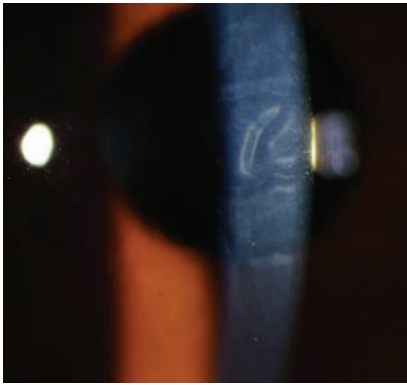
Another uptick of TASS occurred in October 2006 at a 25-bed community hospital in Maine.⁶ The facility's ophthalmologist noted increased inflammation and decreased visual acuity in eight out of 10 cataract surgery patients in one day.⁶ To prevent further cases, the surgical team suspended surgery and implemented



Anterior chamber inflammation with hypopyon. Reprinted with permission from Chaudhry IA, et al.

POST-CATARACT SURGERY INFLAMMATION: A TOXIN OR A BUG?

Photo: Nick Marmaris, MD



This patient has corneal striae and folds associated with TASS.

these changes: switched the epinephrine to a preservative-free formulation; began changing the ultrasonic bath solution used to clean surgical instruments twice a day instead of once; used medications with different lot numbers for future surgeries; used personnel with more experience with the ophthalmologist; had the manufacturer inspect the autoclave to ensure it was functioning normally; changed the topical iodine antiseptic to single-use vials; and began using a new phacoemulsification tip with each new patient.⁶

With these changes in place, the ophthalmologist performed cataract surgery on four patients the following week—and all four developed TASS. The team suspended cataract surgery again and made further adjustments to the protocol: new cannulas for each procedure; a new lot of balanced salt solution; rinsing equipment removed from the ultrasonic cleaning bath with sterile distilled water instead of tap water; and discontinuing use of enzymatic cleaner in the ultrasonic bath. In addition, they performed an endotoxin test on the solution from the ultrasonic bath, which came back positive. Patients who underwent surgery following these changes all had successful surgery.⁶

CONTROL AND REPORT

Once an infectious etiology has been ruled out, patients should start aggressive topical anti-inflammatory therapy with prednisolone 1% or similar steroid every hour, with daily monitoring for resolution of anterior chamber inflammation, corneal edema and intraocular pressure control.

In mild cases, patients usually improve quickly with no permanent damage. Moderate cases usually resolve within three to six weeks with possible residual corneal edema or damage. Severe cases can cause permanent damage leading to corneal transplant, cystoid macular edema, permanently dilated pupil and glaucoma due to damage to the trabecular meshwork.²

TASS outbreaks should be reported to both state and local health departments. Outbreak investigation assistance can be obtained from the Centers for Disease Control and Prevention's Division of Healthcare Quality Promotion. The Intermountain Ocular Research Center at the University of Utah and Emory University Eye Center can both assist with prevention and treatment. TASS cases associated with a certain product can be reported to the Food and Drug Administration's Medwatch Program.²

BEWARE THE BUGS

Endophthalmitis is an inflammatory reaction of the intraocular fluid and tissues as a result of a microbial organism entering the eye. Once bacteria enter the eye, they proliferate rapidly because the vitreous acts as an excellent medium, and initiates the inflammatory cascade.¹

Over an eight-year period from 1994 to 2001, there were 1,026 presumed endophthalmitis cases out of 477,627 cataract surgeries—an incidence rate of 2.15 per 1,000.⁷

Signs and symptoms usually begin two to 10 days postoperatively and include decreased visual acuity, deep ocular pain and redness. The average acute onset is between 72 and 96 hours after surgery. Delayed-onset endophthalmitis generally occurs greater than six weeks after surgery. Slit lamp examination often reveals lid edema, hyperemia, corneal edema, anterior chamber cells and flare, keratic precipitates, hypopyon, fibrin formation, vitritis and loss of red reflex.¹

Acute-onset endophthalmitis is usually caused by coagulase-negative gram-positive species such as *Staphylococcus epidermidis*, *Staphylococcus aureus*, *Streptococci*, *Enterococcus*, and about 25% of all cases are caused by gram-negative species such as *Pseudomonas aeruginosa*. Delayed onset endophthalmitis is usually

Avoiding Preservatives

Currently, only a few manufacturers produce PFBF epinephrine. Belcher Pharmaceutical, a small company in Largo, Fla., produces PFBF, and Imprimis Pharmaceuticals makes a non-preserved, methylparaben-free epinephrine. Compounding 1.5% phenylephrine with 1.0% lidocaine without bisulfite is also an option. Omidria (Omeros) contains 1% phenylephrine and 0.3% ketorolac once diluted and helps to maintain mydriasis. Although American Regent changed their epinephrine formulation in 2012 to contain bisulfite, they planned to re-release the PFBF formulation in May 2018 after ASCRS reached out to stress the need for such a formulation.⁴ There has been no update by American Regent as of August 2018.

caused by *Propionibacterium acnes*, coagulase-negative and *Corynebacterium* species.¹

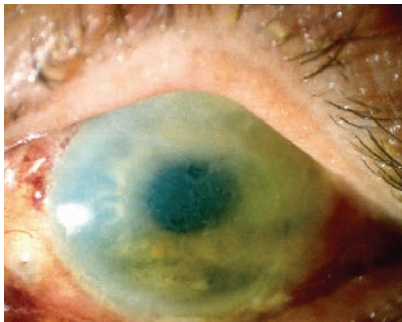Many of these organisms are part of the natural eyelid and nasal flora, and conditions such as blepharitis and nasolacrimal infections can increase the risk of endophthalmitis. Patients with systemic infections, diabetes and immunocompromise are also at a higher risk for infection. Bacteria can enter the eye via breaks in the sterile field from events such as improper draping and prepping of the surgical area, complex and prolonged surgeries, and inadequate sterilization of surgical equipment.⁷

Postoperatively, delayed wound healing can also lead to endophthalmitis. Posterior capsular tears, wound leaks, contaminated irrigation solutions and IOLs, surgeon experience, incision size and angle can all be risk factors for endophthalmitis.⁸

THE NEEDLE AND KNIFE

Endophthalmitis treatment is guided by the Endophthalmitis Vitrectomy Study (EVS), which recommends an injection of intravitreal antibiotics along with either a vitreous biopsy or PPV. The injections pass the blood-retinal barrier and often achieve successful therapeutic drug levels. Typically, treatment involves vancomycin (1mg/0.1cc) and ceftazidime (2.25mg/.01cc).

Photo: Nick Marnis, MD



TASS can cause both corneal edema and stromal haze, as seen here.

Concomitant steroid use to decrease inflammation remains controversial.⁹

The presenting visual acuity is a good predictor of final visual outcome and often aids in determining the best course of treatment:

- **Hand motion or better.**

Treatment usually consists of a vitreous tap and injection of intravitreal antibiotics. The vitreous fluid is sent for a gram stain and culture. If the vitreous is too dense and consists of inflammatory fibrin, an aqueous sample may be obtained via an anterior chamber paracentesis. Vitreous tap cultures are positive 56% to 70% of the time, while an anterior chamber paracentesis is positive in about 40% of cases.⁸

- **Light perception.** Treatment consists of a PPV with injection of intravitreal antibiotics. The vitrectomy allows for removal of the organism, reduction of vitreous fibrin and membranes that could lead to subsequent tractional retinal detachment and improved penetration of the antibiotics. Samples of the vitreous at the time of the vitrectomy are sent for gram stain and culture.

Patients with no improvement from a vitreous tap and injection should have a vitrectomy followed by repeated intravitreal antibiotic injection.⁸

The EVS shows that systemic antibiotic treatment has no benefit. While the antibiotics used in the study, ceftazidime and amikacin, have limited gram-positive coverage, newer fourth-generation fluoroquinolones have better efficacy and broader coverage when given systemically. Oral moxifloxacin, for example, can achieve therapeutic levels in the aqueous and vitreous in a non-inflamed human eye. A large

randomized study would help to determine the efficacy of newer systemic and topical medications in the treatment of postoperative endophthalmitis.⁸

Optometrists are comanaging more cataract surgery patients as baby boomers continue to age. Although both are rarities, TASS and endophthalmitis are possible complications every OD must be prepared to diagnose and manage should it arise. Their similar presenting signs and symptoms may cause initial confusion, and recognizing and understanding the differences between the two conditions is the key to initiating timely and appropriate treatment and referral to save our patients' vision. [rcccl](#)

1. Progressive Surgical Solutions, LLC. TASS and Endophthalmitis. 2013.
2. Sabbagh MD, Omar Mekari. Update on Toxic Anterior Segment Syndrome. Rev Ophthalmol. March 16, 2007.
3. American Academy of Ophthalmology. TASS etiology. www.aao.org/focalpointssnipdetdetail.aspx?id=35b758bf-71a0-4264-bdb6-62d4a7f5be12. Accessed January 14, 2018.
4. American Society of Cataract and Refractive Surgery. Clinical Alert: Intraocular use of epinephrine to maintain mydriasis during cataract surgery. December 13, 2017.
5. Kutty PK, Forster TS, Wood-Koob C, et al. Multistate outbreak of toxic anterior segment syndrome 2005. J Cataract Refract Surg. 2008;34(4):585-90.
6. CDC MMWR Weekly. Toxic anterior segment syndrome after cataract surgery-Maine. 2006;56(25):629-30.
7. West ES, Ashley Behrens A, McDonnell PJ, et al. The incidence of endophthalmitis after cataract surgery among the U.S. Medicare population increased between 1994 and 2001. Ophthalmology. 2005;112(8):1388-94.
8. Abelson MB, Kennedy K, Lilyestrom L. Unraveling the mystery of endophthalmitis. Rev Ophthalmol. January 24, 2008.
9. Tewari A, Shah GK. Cataract complications: the retinal perspective. Rev Ophthalmol. August 16, 2006.
10. Chaudhry IA, Al-Dhibi H, Al-Rashed W, et al. Endophthalmitis: experience from a tertiary eye care center. IntechOpen. May 8, 2013.
11. Deschênes J. Toxic Anterior Segment Syndrome (TASS). Medscape. May 3, 2017. <https://emedicine.medscape.com/article/1190343>. Accessed January 8, 2019.

Transplantation for Limbal Stem Cell Deficiency

When severe disease calls for surgery, here's how you can be prepared for the pre- and post-op care.

By Cecelia Koetting, OD

Corneal diseases, and our understanding of them, have advanced significantly over the last 15 to 20 years. One such disorder is limbal stem cell deficiency (LSCD). Diagnosis of patients with LSCD has greatly increased with technological advancements of corneal topography/tomography and anterior segment optical coherence tomography (AS-OCT). This has led to the need to improve treatment options for LSCD.

As optometrists, we are more familiar with non-surgical treatment options for LSCD, but it is also important for us to understand the surgical treatments and how to care for these patients postoperatively.

HOW LSCD OCCURS

The cornea is comprised of six layers: epithelium, Bowman's layer, stroma, Descemet's membrane, Dua's layer and the endothelium. The epithelium—the outermost layer of the cornea—is only five to seven cells thick (about 50 μ m).¹ Peripherally, the cornea is continuous with the conjunctiva and sclera with a 0.5mm to 1mm band of limbal stem cells at the corneoscleral junction.

Limbal stem cells, which are continually shed into the tear film,

are important for the regeneration of the entire corneal epithelium.¹ The limbal stem cells produce the basal cell layer of the epithelium.¹ These basal cells migrate towards the center of the cornea in the basal layer, moving up to become wing cells and then to become surface cells, allowing for the continued rejuvenation of the corneal surface.¹ This process of corneal epithelium turnover takes approximately seven days.¹

Not only are the limbal stem cells responsible for the regeneration of the corneal epithelium, but they also create a barrier to prevent conjunctival epithelial cells from migrating to the corneal surface.²

As you can imagine, damage to or dysfunction of these limbal stem cells can be devastating to the health and function of the cornea. In LSCD, the poorly functioning limbal stem cells are unable to properly regenerate the epithelial layer, resulting in replacement by conjunctival goblet cells.³

UNDERLYING CAUSES

Limbal stem cell deficiency can be either congenital or acquired, although it is most often considered an acquired condition. Congenital causes of LSCD include aniridia and ectodermal dysplasia.⁴

Acquired LSCD can occur from trauma due to alkaline and acidic injuries, contact lens wear, thermal injury or iatrogenic causes.⁴ Inflammatory issues such as chronic limbitis and bullous keratopathy and neurotrophic keratopathy from trigeminal neuralgia, diabetes mellitus, herpes simplex or herpes zoster may also lead to LSCD.^{4,5} Acquired LSCD can also be related to autoimmune disorders such as Stevens-Johnson syndrome and mucous membrane pemphigoid.⁴

DIAGNOSIS

Patients with LSCD present with varying degrees of ocular signs, depending on the severity and level of corneal conjunctivalization. Symptoms may include decreased vision, photophobia, tearing, blepharospasm and recurrent pain.⁶ They may present with superficial punctate late fluorescein stippled staining at the limbus, whorl-like epitheliopathy (*Figure 1*), progressive ingrowth of opaque

ABOUT THE AUTHOR



Dr. Koetting is the referral optometric care and externship program coordinator at Virginia Eye Consultants in Norfolk, VA. She is a fellow of the American Academy of Optometry and a trustee of the Virginia Optometric Association.

epithelium and superficial neovascularization.⁷ The conjunctivalized corneal surface stains abnormally because the conjunctival epithelium that has grown on the cornea is more permeable to the stain than true corneal epithelium.⁶

Patients with more severe disease may present with recurrent or non-healing epithelial defects, stromal scarring, or melting.⁷ As the cornea decompensates, the patient may experience more intense pain and loss of vision.

NON-SURGICAL TREATMENT

The overall goal in managing patients is to prevent disease progression. So, regardless of what stage of LSCD the patient presents with, management begins with addressing the underlying etiology, which is most often inflammatory in nature. Many ocular medications and over-the-counter artificial tears contain preservatives, such as benzalkonium chloride, which can cause or exacerbate inflammation. Removing these offending agents and replacing them with preservative-free alternatives is a good start to treating these patients.

Immediate use of topical steroids can calm the reaction, although the intent is to eventu-

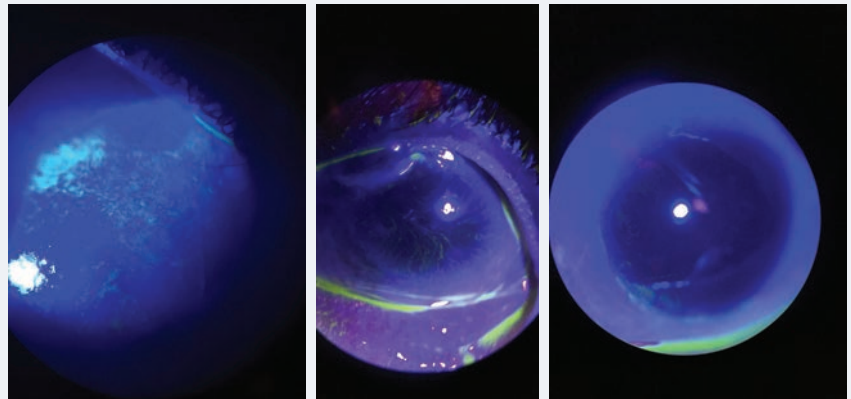


Fig. 1. At left, corneal staining in patient with early LSCD. Note the stippled, elongated, almost pill like shape to the areas of staining. Middle, traditional whorl pattern staining with fluorescein. Note that the pattern starts at the limbus and begins to circle towards the apex of the cornea. At right, subtle late staining inferior and temporal with fluorescein of conjunctival cells on cornea in patient with LSCD.

ally take patients off of these, if possible. Concurrently, the patient can be started on long-term use of ocular cyclosporine, which may help stabilize LSCD symptoms.^{8,9} Use of amniotic membrane grafts, or long-term amniotic membrane drops, helps to restore the function of limbal stem cells that may only be “stunned” in patients with mild to moderate LSCD.¹⁰

Discontinuation of contact lens wear or refitting patients into scleral lenses, which minimize trauma to the limbal area, can help eliminate mechanical rubbing and further corneal damage.^{11,12}

Both of these options have the potential to stop or reverse early acquired LSCD.^{11,12}

SURGICAL TREATMENT

The surgical journey of stem cell transplantation started in 1984 with keratoepithelioplasty using cadaver corneas in an allograft procedure, which was also used later in 1994 in a variation of keratolimbal allograft.^{13,14} This was followed shortly thereafter in 1989 with limbal autograft transplantation, which involved harvesting conjunctival and limbal tissue from the patient’s unaffected

Release Date: February 15, 2019
Expiration Date: February 15, 2022
Estimated time to complete activity: 1 hour

Jointly provided by Postgraduate Institute for Medicine and RGVCE



Educational Objectives: After completing this activity, the participant should be better able to:

- Discuss the needs and reasons for stem cell replacement.
- Identify appropriate candidates for limbal stem cell transplantation.
- Describe the current process (and a bit of the history) of harvesting and growing limbal stem cells.
- Recognize the pathophysiology of limbal stem cell diseases.
- Explain the most up-to-date procedure(s) for limbal stem cell transplantation.
- Discuss the comanagement of patients who received limbal stem cell allograft.

Target Audience: This activity is intended for optometrists engaged in the care of patients with limbal stem cell diseases.

Accreditation Statement: In support of improving patient care, this activity has been planned and implemented by the Postgraduate Institute for Medicine and RGVCE. Postgraduate Institute for Medicine

is jointly accredited by the Accreditation Council for Continuing Medical Education, the Accreditation Council for Pharmacy Education, and the American Nurses Credentialing Center, to provide continuing education for the healthcare team. Postgraduate Institute for Medicine is accredited by COPE to provide continuing education to optometrists.

Faculty/Editorial Board: Cecelia Koetting, OD, referral optometric care and externship program coordinator at Virginia Eye Consultants in Norfolk, VA.

Credit Statement: This course is COPE approved for 1 hour of CE credit. Course ID is **60687-PO**. Check with your local state licensing board to see if this counts toward your CE requirement for relicensure.

Disclosure Statements:

Dr. Koetting: Nothing to disclose.

Managers and Editorial Staff: The PIM planners and managers have nothing to disclose. The RGVCE planners, managers and editorial staff have nothing to disclose.



eye.^{13,15} By 1995, an early version of the living-related conjunctival limbal allograft technique used donor limbal and conjunctival grafts from any living relative.^{13,16}

Here are the common surgical transplantation methods, in order of their development:

Keratolimbal allograft (KLAL) uses allogeneic limbal tissue attached to a corneoscleral carrier from a cadaveric donor. This procedure can be indicated for patients who have either bilateral LSCD without a related donor or a unilateral LSCD whose contralateral eye is not a viable donor.¹⁷ KLAL can be used in patients with LSCD caused by aniridia, contact lens wear or iatrogenic event with primarily limbal damage. Severe conjunctival involvement decreases the likelihood of success. For instance, conjunctiva that has chronic inflammation or scarring will have decreased mucin and tear production, creating an increased likelihood for keratinization of the ocular surface.^{13,14}

Other etiologies of LSCD, such as mucous membrane pemphigoid

and Stevens-Johnson syndrome, can be treated with KLAL but require that the eye remain controlled and quiet for at least a year prior to surgery.

Conjunctival limbal autograft (CLAU) makes use of the conjunctiva and limbus from the unaffected eye of a patient with LSCD. Up to 40% of the stem cells can be harvested from the donor eye without risk, and no systemic immunosuppression is needed.^{13,18}

This procedure is overall extremely successful at 80% to 100% with between 25% and 100% improvement in visual acuity.^{12,13} The rejection rate of these grafts is minimal, with 76% at three years and 62% at six years after surgery.^{13,18}

Living-related conjunctival limbal allograft (LR-CLAL) uses harvested limbal and conjunctival tissue from the patient's living relative.¹³ It can be used in patients with both unilateral and bilateral LSCD, harvesting up to 40% of the donor's limbal tissue with no risk to the donor (*Figures 2 and 3*).¹³ This procedure harvests considerable amounts of conjunctiva along with the limbal tissue and is well-suited for patients with significant conjunctival deficiency such as Stevens-Johnson syndrome, mucous membrane pemphigoid and chemical injuries.¹³ Failure risk is higher in this procedure since it is an allograft, so it requires long-term systemic immunosuppression.¹³

Combined conjunctival limbal and KLAL (C-CL/KLAL or C-KLAL) uses cadaveric keratolimbal tissue with LR-CLAL, helping to treat severe LSCD patients.^{4,13} By combining the procedures, more conjunc-

Clinical Pearl

Corneal punctate staining in patients with dry eye disease (DED) appears differently from the punctate staining found in LSCD patients. The staining in LSCD appears more elongated and pill shaped. Early on, the staining will be concentrated more peripheral near the limbal area. As the disease progresses and worsens, the staining will spread centrally and become more diffuse. As the natural migration of the epithelial cells to the center, the whorl-like pattern will be noted spiraling from the limbus centrally to the apex of the cornea.

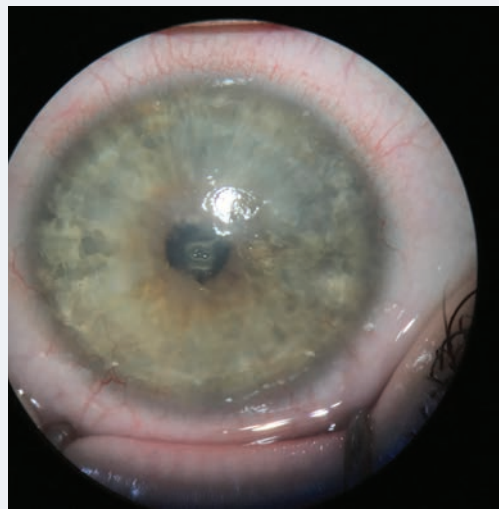

Fig. 2. A moderate LSCD patient pre-operative for lr-CLAL. Note the dullness and irregularity of the central cornea where the epithelium has begun to be replaced with conjunctival cells.

tiva is available that is lacking in KLAL alone and increased limbal tissue that is lacking in LR-CLAL alone. Patients whose condition is severe enough to require C-KLAL may also need restoration of the conjunctival fornices and possible mucous membrane grafting. Because of this, these patients are often evaluated by oculoplastic specialists before proceeding.

Cultured limbal epithelial transplantation (CLET) is the most commonly used *ex vivo* method for limbal stem cell transplantation. Cultivated limbal stem cells are harvested and grown on a substrate to be later implanted into the patient's cornea.⁴ The stem cells are harvested from either the patient's fellow eye, a cadaver or a living relative.⁴ Oral mucosa may also be used as a tissue source.

In autologous CLET, a 2mmx2mm piece of limbal stem cell tissue is excised from the superior limbus in the patient's healthy eye, 1mm from either side of the corneoscleral junction.^{4,13,18} The limbal tissue is then immediately cultured and

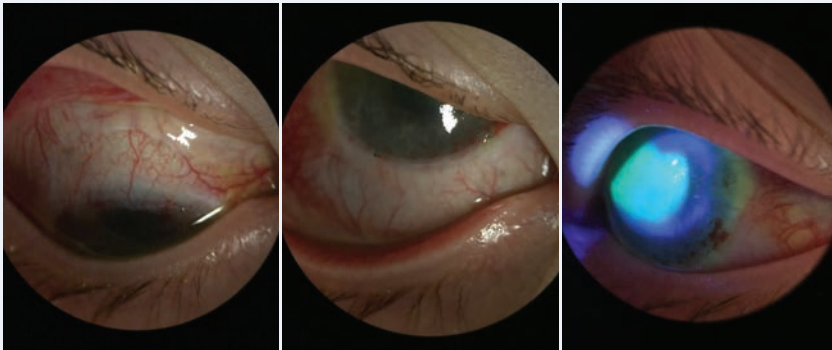


Fig. 3. Same patient from Figure 4, one week postoperative after Ir-CLAL. You can see the recessed conjunctiva superior and inferior along the limbus. The patient's central cornea has stain pooling as it continues to re-epithelialize, but there is no peripheral late staining.

seeded in one of multiple culture mediums.^{4,13,18} After the cell-seeded culture plates are allowed to grow for two to three weeks, the surgeon then implants two to three sheets of the cells in the patient's diseased eye.^{4,13}

Studies of eyes having undergone CLET have reported success rates between 67% and 77%, and yielded visual acuity improvement results in 51% to 75% of patients.^{10,18-21} Patients undergoing allografts vs. autografts had comparable success rates.^{19,20} Overall, CLET has a low complication rate, with living donor grafts having the highest safety.¹⁸

Simple limbal epithelial transplantation (SLET) is a newer technique first reported in 2012 to treat unilateral LSCD. In SLET, a 2mm-by-2mm donor limbal tissue is divided into eight to 15 small pieces and then distributed evenly over an amniotic membrane glued to the recipient's cornea.¹⁸ Reports show success rates at anywhere from 50% to 100% with up to 75% improvement in two-line visual acuity.¹⁸ Failure rate is low and tends to occur within the first six months in higher risk patients (i.e., pre-existing symblepharon or penetrating keratoplasty).¹⁸ The most common complication after the procedure is localized reoc-

currence of LSCD, which can be treated with a repeat SLET.¹⁸

LONG-TERM MANAGEMENT

Immunosuppression and control of inflammation both pre- and postoperatively is key to achieving successful outcomes. Following the current Cincinnati Eye Institute protocol, prior to surgery patients are prescribed oral prednisone 1mg/kg/day and tapered over one to three months, oral valganciclovir 225mg QD, trimethoprim/sulfamethoxazole (TMP/SMX) every MWF, oral tacrolimus 4mg BID, and oral mycophenolate mofetil (MMF) 1g BID.²² Valganciclovir and TMP/SMX are stopped at 12 months.²² Tacrolimus is tapered after six months and MMF after 12 months.²²

All medications are discontinued at approximately three years, but patients should continue to be monitored closely for possible rejection.²² This systemic protocol used over the last 10 years has shown to be safe and effective with minimal side effects and severe adverse events in only about 1.5% of the treated population.²²

Although LSCD has been recognized as a corneal disease process for quite some time, it is becoming diagnosed and treated with increasing frequency. As clinicians,

we must not only recognize the diagnosis early but also understand how it can be surgically treated and managed in severe stages. **RCCL**

1. Remington LA. Clinical Anatomy of the Visual System. 2nd ed. St. Louis, MO: Elsevier; 2005
2. Dua HS, Azuara-Blanco A. Limbal stem cells of the corneal epithelium. *Surv Ophthalmol.* 2000;44(5):415-25.
3. Biber JM, Holland EJ, Neff KD. Management of ocular stem cell disease. *Int Ophthalmol Clin.* 2010;50(3):25-34.
4. Mannis MJ, Holland EJ. *Cornea: Fundamentals, Diagnosis and Management.* 4th ed. Philadelphia: Elsevier; 2017.
5. Atallah MR, Palioura S, Perez VL, Amescua G. Limbal stem cell transplantation: current perspectives. *Clin Ophthalmol.* 2016 Apr 1;10:593-602.
6. Dua HS, Saini JS, Azuara-Blanco A, Gupta P. Limbal stem cell deficiency: concept, aetiology, clinical presentation, diagnosis and management. *Indian J Ophthalmol.* 2000;48(2):83-92.
7. Kim BY, Riaz KM, Bakhtiari P, et al. Medically reversible limbal stem cell disease: clinical features and management strategies. *Ophthalmology.* 2014;121(10):2053-8.
8. Baradaran-Rafii A, Javadi MA, Rezaei Kanavi M, et al. Limbal stem cell deficiency in chronic and delayed-onset mustard gas keratopathy. *Ophthalmology.* 2010;117(2):246-52.
9. Jadidi K, Ebrahimi A, Panahi Y, et al. Topical cyclosporine A for mustard gas induced ocular surface disorders. *J Ophthalmic Vis Res.* 2015;10(1):21-5.
10. Zhao Y, Ma L. Systematic review and meta-analysis on transplantation of ex vivo cultivated limbal epithelial stem cell on amniotic membrane in limbal stem cell deficiency. *Cornea.* 2015;34(5):592-600.
11. Schornack MM. Limbal stem cell disease: management with scleral lenses. *Clin Exp Optom.* 2011;94(6):592-4.
12. Jeng BH, Halfpenny CP, Meisler DM, Stock EL. Management of focal limbal stem cell deficiency associated with soft contact lens wear. *Cornea.* 2011;30(1):18-23.
13. Holland EJ. Management of limbal stem cell deficiency: A historical perspective, past, present, and future. *Cornea.* 2015;34(Suppl 10):S9-15.
14. Thoft RA. Keratolimbaloplasty. *Am J Ophthalmol.* 1984;97(1):1-6.
15. Kenyon KR, Tseng SC. Limbal autograft transplantation for ocular surface disorders. *Ophthalmology.* 1989;96(5):709-22.
16. Kwitko S, Marinho D, Barcaro S, et al. Allograft conjunctival transplantation for bilateral ocular surface disorders. *Ophthalmology.* 1995;102(7):1020-5.
17. Cheung AY, Holland EJ. Keratolimbal allograft. *Curr Opin Ophthalmol.* 2017;28(4):377-81.
18. Yin J, Jurkunas U. Limbal stem cell transplantation and complications. *Semin Ophthalmol.* 2018;33(1):134-41.
19. Baylis O, Figueiredo F, Henein C, et al. 13 years of cultured limbal epithelial cell therapy: a review of the outcomes. *J Cell Biochem.* 2011;112(4):993-1002.
20. Shortt AJ, Secker GA, Notara MD, et al. Transplantation of ex vivo cultured limbal epithelial stem cells: a review of techniques and clinical results. *Surv Ophthalmol.* 2007;52(5):483-502.
21. Haagdorens M, Van Acker SJ, Van Gerwen V, et al. Limbal stem cell deficiency: Current treatment options and emerging therapies. *Stem Cells Int.* 2016;2016:9798374.
22. Holland EJ, Mogilishetty G, Skeens HM, et al. Systemic immunosuppression in ocular surface stem cell transplantation: results of a 10-year experience. *Cornea.* 2012;31(6):655-61.

Earn up to
20 CE
Credits*

NEW TECHNOLOGIES
& TREATMENTS IN

2019 EYE CARE

RGVCE
REVIEW'S COMMITMENT TO
CONTINUING EDUCATION

Join us in

Orlando, Florida

March 7-10, 2019

Join us for *Review's* New Technologies & Treatments in Eye Care March 7-10, 2019 in Orlando at Disney's Yacht & Beach Club. Earn up to 20* COPE CE credits including interactive workshops!**



The program includes six (6) TQ/CEE Credits for those Optometrists licensed in Florida or other states requiring transcript quality courses for re-licensure.

REGISTRATION COST: \$595

FACULTY



Paul M. Karpecki, OD, FAAO
Program Chair



Doug Devries, OD



Blair Lonsberry, MS, OD, MEd, FAAO



Diana Shechtman, OD, FAAO



Joseph Shovlin, OD, FAAO

DISNEY'S YACHT & BEACH CLUB

1700 Epcot Resorts Boulevard
Orlando, Florida 32830
Phone: 407-934-7000

See website for updated hotel accommodations.



3 WAYS TO REGISTER

online: www.reviewscce.com/Orlando2019

email: reviewmeetings@jhihealth.com | **phone:** 866-658-1772

**Separate registration required. RGVCE partners with Salus University for those ODs who are licensed in states that require university credit. See event website for complete details.

Administered by
RGVCE
REVIEW'S COMMITMENT TO CONTINUING EDUCATION

cope
COUNCIL ON OPTOMETRIC PRACTICE EDUCATION

*Approval pending

SALUS
UNIVERSITY
Pennsylvania College of Optometry

Partially supported by an
unrestricted educational grant from
Bausch & Lomb

Was it a Failure or Rejection?

Identifying the right differential in a troubled transplant patient makes a world of difference when determining corrective action.

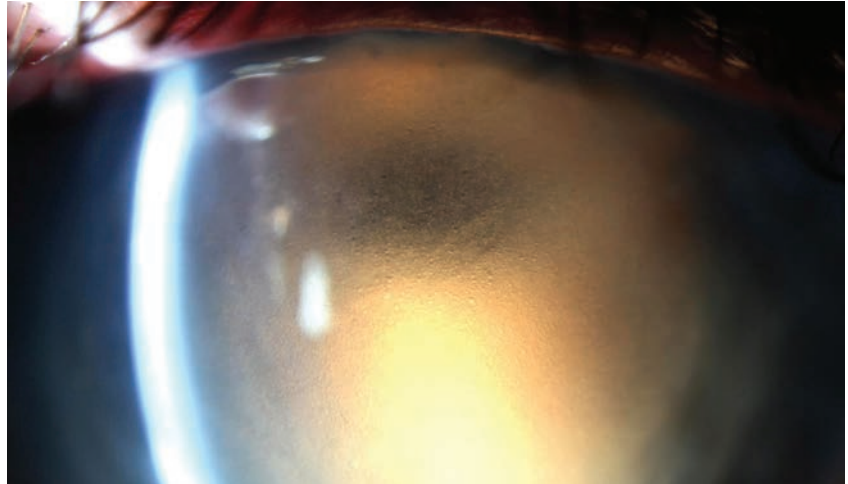A 59-year-old male presented to the clinic complaining of reduced vision in his right eye. He described his vision loss as generally painless (though he noted increasing photophobia) and occurring slowly over the last month. He stated, however, that his right eye is his poorer-sighted eye and said it was possible he had been experiencing reduced acuity over a longer period of time.

OBTAIN OCULAR HISTORY

The patient had a corneal transplant on his right eye 20 years ago due to keratoconus and then on his left eye three years later. His postoperative course was unremarkable, though he noted that high levels of astigmatism limited the vision in his right eye. At the time he presented, the patient was not using any medicated drops but was wearing glasses to see.

CONDUCT PRELIMINARY TESTING

Entrance testing showed the patient's habitually corrected vision to be hand motion on the right eye without improvement on pinhole and 20/40 on the left, improving to 20/25 through pinhole. It was not possible to assess the patient's pupillary response in his right eye due to a poor view of his iris, but his left eye showed brisk direct and consensual responses. Full and confrontation visual fields, which could only be grossly assessed on the right eye, were full to motion on the right and full to finger



We used retroillumination to highlight significant epithelial edema in this patient with a history of edematous PK.

counting on the left. Due to anterior media opacity, an intraocular pressure (IOP) evaluation was postponed until after the slit lamp exam.

The slit lamp exam of the right eye showed normal lids. Injection, which was greatest nasally and interpalpebrally, was noted at 1+ to 2+ levels. The cornea showed a central penetrating keratoplasty (PK) with inferior vascularization to the graft-host junction of the transplant, though the vessels did not bridge onto the transplant. The graft was edematous with 3+ to 4+ epithelial and stromal edema, though the peripheral cornea remained clear.

Views of the deep cornea and anterior chamber (AC) were extremely poor, though no keratic precipitates (KPs) were seen, and the AC appeared to be quiet and absent of cells. The iris detail was poor, but with magnification of the slit lamp, the pupil was seen react-

ing to light. Examining the left eye showed normal anterior segment structures, with the exception of a PK. The interface had mild vascularization but was otherwise clear and compact. IOPs were 23mm Hg OD and 14mm Hg OS.

DETERMINE THE PROBLEM

Though we could not rule out corneal graft rejection, we made a primary diagnosis of endothelial graft failure. To rule out rejection, the patient was instructed to use Pred Forte on his right eye every two hours for a week. A baseline pachymetry was gathered (1057 μ m OD and 712 μ m OS) to assess the patient's treatment response. He was sent home and asked to return in a week.

REASSESS AT FOLLOW-UP

After a week, the patient's exam results had not changed. Vision, IOP and pachymetry were stable. The slit lamp exam on the right eye



showed no reduction in edema and still no visible KPs or intraocular injections. At this point, the diagnosis was confirmed, and we gave the patient the option of a repeat PK or a Descemet's membrane endothelial keratoplasty (DMEK) behind the primary transplant. He elected to pursue the DMEK route. The patient underwent surgery uneventfully a month later. By the six-month postoperative visit, spectacle corrected visual acuity (VA) was limited to 20/60 minus, though the patient was pleased with the outcome.

DISCUSSION

A patient presenting with significant corneal edema without apparent corneal or AC inflammation has a relatively straightforward differential diagnosis: viral endotheliitis, acute IOP spike (though we expect patients with a high enough IOP to generate pain, this is a trend and not a rule), hypoxia from contact lens use, corneal transplant rejection and native or transplanted endothelium decompensation. In this case, we can immediately rule out IOP and contact lens influences. While viral endotheliitis remains on the differential, in this patient with a history of PK but no history of viral eye disease, it is more appropriate to consider endothelial graft rejection or failure as the most likely suspects.

Note that all corneal transplants involving the endothelium—PK, DMEK and Descemet's stripping automated endothelial keratoplasty (DSAEK)—fail eventually. Though some transplants last longer before

failing, their average life expectancy is 10 to 20 years. Endothelial graft failure manifests as corneal edema, which is often mixed stromal edema (stromal pleats and Descemet's membrane folds) and epithelial edema (microcystic corneal edema). It tends to occur slowly and without inflammation, though if bullae form, pain can develop.

On the other side of our differential is endothelial graft rejection. Though rejection is most likely to occur in the first year postoperatively, later cases of rejection do occur. Signs of this process are keratic precipitates on the graft and increasingly prominent corneal edema. Extracorneal inflammation may also be present but should be relatively mild. In some cases of rejection, the corneal edema may be too profound to visualize KPs. In this case, it can be impossible to clearly distinguish rejection from failure on exam.

In an eye with an endothelial graft and significant recent-onset corneal edema, use a high-dose steroid to differentiate failure from rejection. A few cases I thought for certain were cases of failed grafts showed improved edema and subsequent underlying KPs. In cases where edema clears, make a diagnosis of rejection. At this point, the patient should be very slowly tapered on the steroid (over six to 12 months) but should also be indefinitely maintained on a steroid dose greater than what was in effect when the rejection episode occurred. The longer a rejection episode goes on for, the

more permanent the damage to the transplant and the higher the risk of failure due to endothelial cell density loss. In cases where there is no resolution of edema with steroid use, the patient likely has underlying graft failure and needs an endothelial re-transplant, either via a DSAEK, DMEK or repeat PK.

The current standard practice is to perform a lamellar transplant, as repeat PKs are more prone to complications and failure than are original PKs and secondary DMEKs and DSAEKs. There are cases where a repeat PK, however, is worth considering.

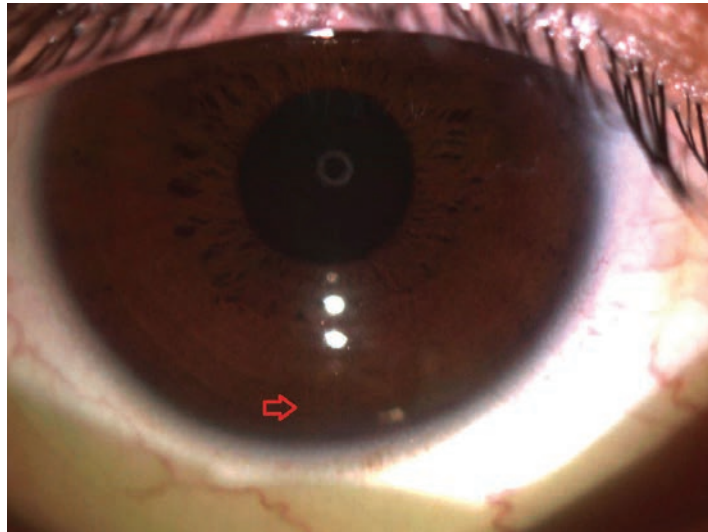
The patient noted that the vision in his right eye had never been as good as the vision in his left, owing to astigmatism. Though secondary DMEKs and DSAEKs have a more preferable safety profile than secondary PKs, do not expect these posterior lamellar surgeries to improve anterior corneal irregularities caused by an original PK. A repeat PK may be able to do just that. When we reviewed the course and recovery of all available options, however, the patient felt his acuity prior to graft failure was strong enough to function and knew he would be happy if he could get back to that level, so a DMEK was settled on.

When dealing with any new onset corneal edema in a transplant setting, it is important to arrive at the right differential and understand the diagnosis to effectively shape short- and long-term patient care. **RCCL**

Depth Charge

Undercorrected cylinder hindered the binocularity of this athlete. Here's how pushing the CYL took care of it.

In optometry school, we are trained to refract patients to 20/20 and undercorrect, rather than overcorrect, cylinder in contact lens prescriptions. However, in patients with higher visual demands, such as athletes, this may lead to subpar visual performance. If so, it's time to challenge our assumptions.



This soft toric lens aligns at 6 o'clock.

THE CASE

A 21-year-old male presented for an eye exam complaining that the vision in his right eye was blurry with contact lenses. He went through several iterations with his previous optometrist but said his vision never seemed right. He played collegiate golf, so his vision and depth perception were very important to his performance and ability to follow the small, high-velocity balls. However, he was having trouble finding his golf balls, and he said his depth perception seemed off at close distances.

His presenting visual acuities (VAs) were 20/25- OD and 20/15 OS, and he was wearing Acuvue Oasys (Johnson & Johnson) with a prescription of 8.4 -1.25 over-refraction plano OD and 8.4 -1.00 over-refraction plano OS.

CONTACT LENS EVALUATION

Manifest refraction revealed:

- -1.75 +0.50x070 (VA of 20/15) OD

- -1.00 (VA of 20/15) OS
- The patient's slit lamp exam revealed clear lids, lashes and conjunctiva with deep and quiet anterior chambers OU. His cornea, lids and irises were clear and normal OU. His intraocular pressures were 10mm Hg OD and 11mm Hg OS. The undilated posterior segment evaluation was within normal limits. His autokeratometry readings were 43.00/43.50 @173 OD and 43.00/43.25 @162 OS.

I explained to the patient that the uncorrected astigmatism in his contact lens was affecting his visual acuity and discussed further options with him, one of which involved over-correcting the cylinder with a soft toric lens. He was on board and wanted to give it a try.

CONTACT LENS FITTING AND DISPENSING

The following Acuvue Oasys lenses

were placed on the patient and evaluated:

- 8.6/-1.00-0.75 x165 (VA of 20/15) OD
- 8.4 (VA of 20/15) OS

The patient was extremely happy with the in-office performance of the trial lenses, so they were dispensed.

FOLLOW-UP

The patient returned a week later and reported clearer vision and better binocularity.

The fit was finalized.

DISCUSSION

Because each sport has its own unique demands, certain athletes have more visual demands than others. When assessing small balls that move at high speeds, VA and contrast can have a large impact on a golfer's performance, which can be negatively affected by axis mislocation, poor centration and imprecise cylinder correction.^{1,2}

Some patients are more sensitive to cylinder than others. We know this because we all have those patients who can confidently choose one or two even though we are making the most minute adjustments to check cylinder, whereas others hem and haw and can't decide. Patients with lower power-to-cylinder ratios are typically more sensitive to cylinder changes than those with higher ratios. For example, a -1.00D



Earn up to
**18 CE
Credits***

NEW TECHNOLOGIES
& TREATMENTS IN
2019 EYE CARE
RGVCE
REVIEW'S COMMITMENT TO
CONTINUING EDUCATION

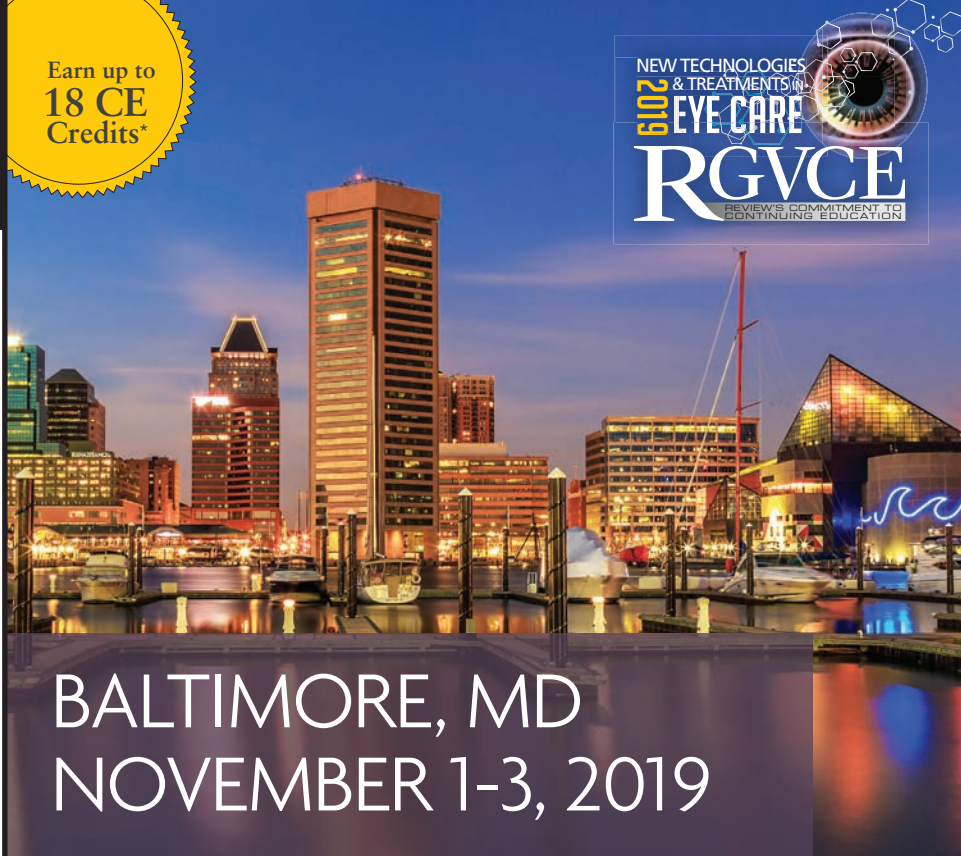

patient with 0.75D of cylinder will most likely see a difference with spherical contact lenses compared with glasses while a -6.00D with 0.75D of cylinder may not notice a difference.

Sensitivity to changes in cylinder rotation is one of the reasons we are taught to undercorrect cylinder in contact lenses; the higher the cylinder, the more sensitive the patient will be to lens rotation, which causes blur.² Some patients prefer constant slight blur over variable clarity, which makes us more likely to undercorrect cylinder than to overcorrect it. In this case, however, an overcorrection of cylinder gave the patient two additional lines of acuity and improved his visual performance.

Luckily, we have several choices when correcting cylinder. Planned replacement lenses are usually available in high oxygen materials and more cost-efficient for patients. However, they are only available in limited parameters, and it's the practitioner's job to decide if customization is needed. In this case, if a soft planned replacement toric hadn't worked for this patient, a custom-ordered soft lens would have been the next step. If the patient is sensitive to axis rotation, rigid gas permeable, scleral or hybrid lenses would be worth looking into since the performances of these lenses do not depend on rotational stability. **ccl**

1. Kirschen DG, Laby DM. Contact lenses for sports: a new ball game. *Cont Lens Spec*. December 1, 2006. [Epub ahead of print].
2. Bennet ES, Henry VA. Correction of astigmatism. *Clinical Manual of Contact Lenses*. 3rd edition. Philadelphia. 2009.



BALTIMORE, MD NOVEMBER 1-3, 2019

Join *Review's* New Technologies & Treatments in Eye Care November 1-3, 2019, at the Renaissance Baltimore Harborplace.

Renaissance Baltimore Harborplace

Located on coastal Inner Harbor, home to the National Aquarium.

**202 E. Pratt Street
Baltimore, MD 21202**

410-547-1200

Discounted Room Rate: \$169/night[†]

Program Chair



Paul M. Karpecki, OD, FAAO

See event website for additional information and faculty.

THREE WAYS TO REGISTER

ONLINE: www.reviewsce.com/baltimore2019

EMAIL: reviewmeetings@jhihealth.com

CALL: 866-658-1772

Administered by
RGVCE
REVIEW'S COMMITMENT TO CONTINUING EDUCATION

COPE
*Approval pending

SALUS
UNIVERSITY
Pennsylvania College of Optometry

Partially supported by an
unrestricted educational grant from
Bausch & Lomb

RGVCE partners with Salus University for those ODs who are licensed in states that require university credit. See www.reviewsce.com/events for any meeting schedule changes or updates. [†]Rooms limited.

Don't be Nearsighted About Myopia

With the groundbreaking new resources available, there's no excuse not to take advantage of myopia management.

We often welcome each year by reflecting on the preceding 12 months to identify changes we can make to enhance our lives, personally and professionally. Instead of looking backwards, though, let's shift our focus forward to 2019 to pinpoint what opportunities we can capitalize on to enrich the lives of our patients. With the myopia pandemic continuing to worsen—the prevalence in the United States has increased by 66% from the 1970s to the early 2000s, and by 2050 half of the world's population will be myopic—this year is the perfect time for optometrists to implement myopia management into their practices.^{1,2}

It's time to rethink myopia. For decades, we've thought of myopia as a refractive error and failed to acknowledge the extent of the impact the condition can have on patients. Myopes face an economic burden to satisfy their visual correction needs, experience a reduced quality of life and are at increased risk for ocular health conditions.^{3,4} While our priorities tend to gravitate toward higher levels of myopia, it is important to recognize that even a -1.00D prescription doubles the risk of glaucoma and triples the risk of retinal detachment (*Table 1*).⁴

We must see myopia for what it is: a progressive disease associated with long-term risks. With the multitude of technology, tools, research and information available to us, it would be a shame not to dive in to myopia management.

IDENTIFY AND TREAT

Many additive factors contribute to the development and progression of myopia, including genetics, minimal time spent outdoors, increased near demand and binocular vision characteristics.⁵

Emmetropia typically occurs when a patient is six to eight years old. Any amount of myopia preceding this age range is outside the norm and increases the likelihood of a higher myopic prescription later on.^{5,6} It is important to monitor existing myopes for changes of -0.50D or more over a one-year span, as these indicate myopic progression. Treatment should be initiated at the onset of myopia, regardless of the patient's age. The most effective and widely used forms of myopia management include orthokeratology (ortho-K) lenses, center-distance soft multifocal contact lenses and topical atropine eye drops.

When a myopic eye is corrected with spectacles or single-vision contact lenses, central rays are focused on the fovea, while peripheral rays are focused behind the eye. This peripheral hyperopic defocus is thought to stimulate axial elongation. While the mechanism by which atropine slows myopic progression is not yet fully understood, we know that the goals of ortho-k and multifocals are to address and correct for hyperopic

peripheral defocus and provide adequate central vision. Inducing peripheral defocus decreases eye elongation and slows myopic progression.

ORTHO-K LENSES

While ortho-K has been shown to slow axial length (AL) progression by 52% and is the primary myopia management technique for many practitioners, it may not be successful in every patient.⁷ Patients with greater than -4.00D of myopia, -1.75D of with-the-rule astigmatism or -1.00D of against-the-rule astigmatism tend to be more difficult fits. When working outside of these parameters, however, experienced ortho-K fitters regularly achieve great fits.

Despite having limited experience, new fitters have also shown impressive success rates. With the help of empirical fitting techniques, optometrists who have no previous ortho-K experience achieved 80% success on the first ordered lens.⁸ If they were unsuccessful with one lens, 95% were successful after one lens change and 99.5% after two lens changes.⁸

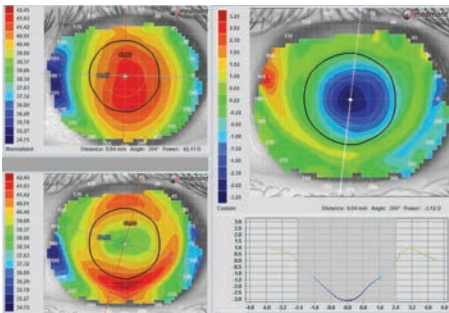
A successful ortho-K fit has been described as having good centra-

	Glaucoma	Cataract (PSCC)	Retinal detachment	Myopic Maculopathy
-1.00 to -3.00	2.3	2.1	3.1	2.2
-3.00 to -5.00	3.3	3.1	9.0	9.7
-5.00 to -7.00	3.3	5.5	21.5	40.6
>-7.00			44.2	126.8

Table 1. Odds ratios of different ocular health risks associated with increasing myopia.⁴



Photo: Randy Kojima and Patrick Caroline, Pacific University College of Optometry



Note the centration of the lens, bull's-eye pattern and textbook "V" pattern of AL change in this ideal ortho-k fit.

tion over the pupil, a bull's-eye fluorescein pattern when the lens is on the eye, a bull's-eye topographic pattern and acuities of 20/25 or better. Limiting myopic progression has been shown to be dependent on the relationship between the pupil size and the optic zone of the ortho-K lens—if the optic zone is much larger than the pupil, the peripheral hyperopic defocus may not be adequately corrected, making it important to maximize “plus in the pupil.”⁹

SOFT MULTIFOCALS

Similar to ortho-K, studies investigating the effectiveness of multifocals in managing myopia have shown a reduced AL progression of up to 49%.¹⁰ These lenses are ideal for patients who present with high refractive errors. In our clinic, we use a center-distance daily disposable soft multifocal with a gradient +3.00 add. For patients with excess cylinder, spectacles can be worn over multifocals to provide improved clarity. This treatment option can be easily integrated into a practice already familiar with soft contact lenses.

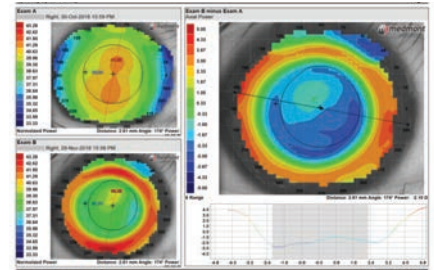
ATROPINE DROPS

Topical atropine has been shown to reduce the progression of myopia in children, with one study finding that 1% atropine had a 77% reduction in refractive progression and prevented AL progression after two years.¹¹ As expected, however, 1% atropine had significant side effects, including near blur and photophobia.¹¹ Another study compared the

effects of various concentrations of atropine on myopia progression and concluded that a once-daily dose of 0.01% atropine had the most significant effect on slowing myopia progression.¹²

Currently, many clinicians have accepted 0.01% atropine as the standard dosage for myopia management. Some argue that since the second study mentioned above reported a decrease in refractive progression rather than AL progression, 0.01% atropine should not actually be the concentration of choice. In reality, long-term use of a higher concentration may stave off AL progression more effectively.¹³

When presenting myopia management options to patients and their parents, it is important to set realistic goals and expectations. Be open and honest by acknowledging that, while we do everything we can to decrease AL progression, it is not always possible to stop myopia in its tracks. As optometrists, we pledge to maintain or enhance the general health of our patients. By recognizing myopia as an ocular disease and taking the necessary



Centrally, this patient has an irregular treatment zone with an optical zone that is too large and would not provide adequate “plus in the pupil.” The optical zone parameters were switched from 6.0mm to 5.4mm for a better fit.

steps to limit its progression, our patients can enjoy a lifestyle free, for the most part, of the ocular risks associated with high myopia. **icc**

- Vitale S, Sperduto RD, Ferris III FL. Increased prevalence of myopia in the United States between 1971-1972 and 1999-2004. *Arch Ophthalmol*. 2009;127(12):1632-9.
- Holden BA, Fricke TR, Wilson DA, et al. Global prevalence of myopia and high myopia and temporal trends from 2000 through 2050. *Ophthalmology*. 2016;123(5):1036-42.
- Resnikoff S, Pascolini D, Mariotti SP, et al. Global magnitude of visual impairment caused by uncorrected refractive errors in 2004. *Bulletin of the World Health Organization*. 2008;86:63-70.
- Flitcroft DI. The complex interactions of retinal, optical and environmental factors in myopia aetiology. *Prog Retin Eye Res*. 2012;31(6):622-60.
- Gifford K. Preparing your practice for the myopia control stampede. *Cont Lens Spec*. 2016;31:20-3, 25, 55.
- Flitcroft DI. Emmetropisation and the aetiology of refractive errors. *Eye (Lond)*. 2014;28(2):169-79.
- Chen C, Cheung SW, Cho P. Myopia control using toric orthokeratology (TO-SEE Study). *Invest Ophthalmol Vis Sci*. 2013;54:6510-7.
- Davis RL, Eiden SB, Bennett ES, et al. Stabilizing myopia by accelerating reshaping technique (SMART)-study three year outcomes and overview. *Adv Ophthalmol Vis Syst*. 2015;2(3).
- Chen Z, Bui L, Xue F, et al. Impact of pupil diameter on axial growth in orthokeratology. *Optom Vis Sci*. 2012;89(11):1636-40.
- Anstice NS, Phillips JR. Effect of dual-focus soft contact lens wear on axial myopia progression in children. *Ophthalmology*. 2011;118(6):1152-61.
- Chua W, Balakrishnan V, Chan YH, et al. Atropine for the treatment of childhood myopia. *Ophthalmology*. 2006;113(12):2285-91.
- Chia A, Lu QS, Tan D. Five-year clinical trial on atropine for the treatment of myopia 2: myopia control with atropine 0.01% eye drops. *Ophthalmology*. 2016;123(2):391-9.
- Yam JCS, Jiang Y, Tang SM, et al. Low-concentration atropine for myopia progression (LAMP) study. *Ophthalmology*. 2019;126(1):113-24.



Singing the Blues

A patient's complicated ocular history results in an anterior staphyloma, leaving him few treatment options.

This 18-year-old male has an ocular history of congenital Marfan's syndrome and Axenfeld-Rieger syndrome with bilateral dislocated lenses and iris hypoplasia. At age nine he suffered a large retinal tear, underwent a pars plana vitrectomy (PPV) repair and subsequently developed aphakic glaucoma. In the right eye, he was treated for lattice degeneration with a 360-degree laser, providing him good vision in that eye at 20/30.

Recently, he developed a choroidal neovascular membrane in the right eye and began treatments with Avastin (bevacizumab, Genentech). He subsequently developed a non-clearing vitreal hemorrhage requiring PPV. Unfortunately, he de-

veloped a worsening anterior staphyloma and was referred for a patch graft consult and vision assessment.

Staphylomas result from intraocular pressure pushing the uvea into an ectatic sclera.¹ This causes the sclera to have a bluish or even blackish appearance as the underlying pigmented tissue becomes visible through the thinning scleral tissue. While posterior staphylomas are generally congenital, anterior staphylomas develop in response to trauma, such as surgery, or infection, as with fungal ulcers.^{1,2} Anterior staphylomas are generally located over the ciliary body (ciliary staphyloma) or between the ciliary body and the limbus (intercalary staphyloma).

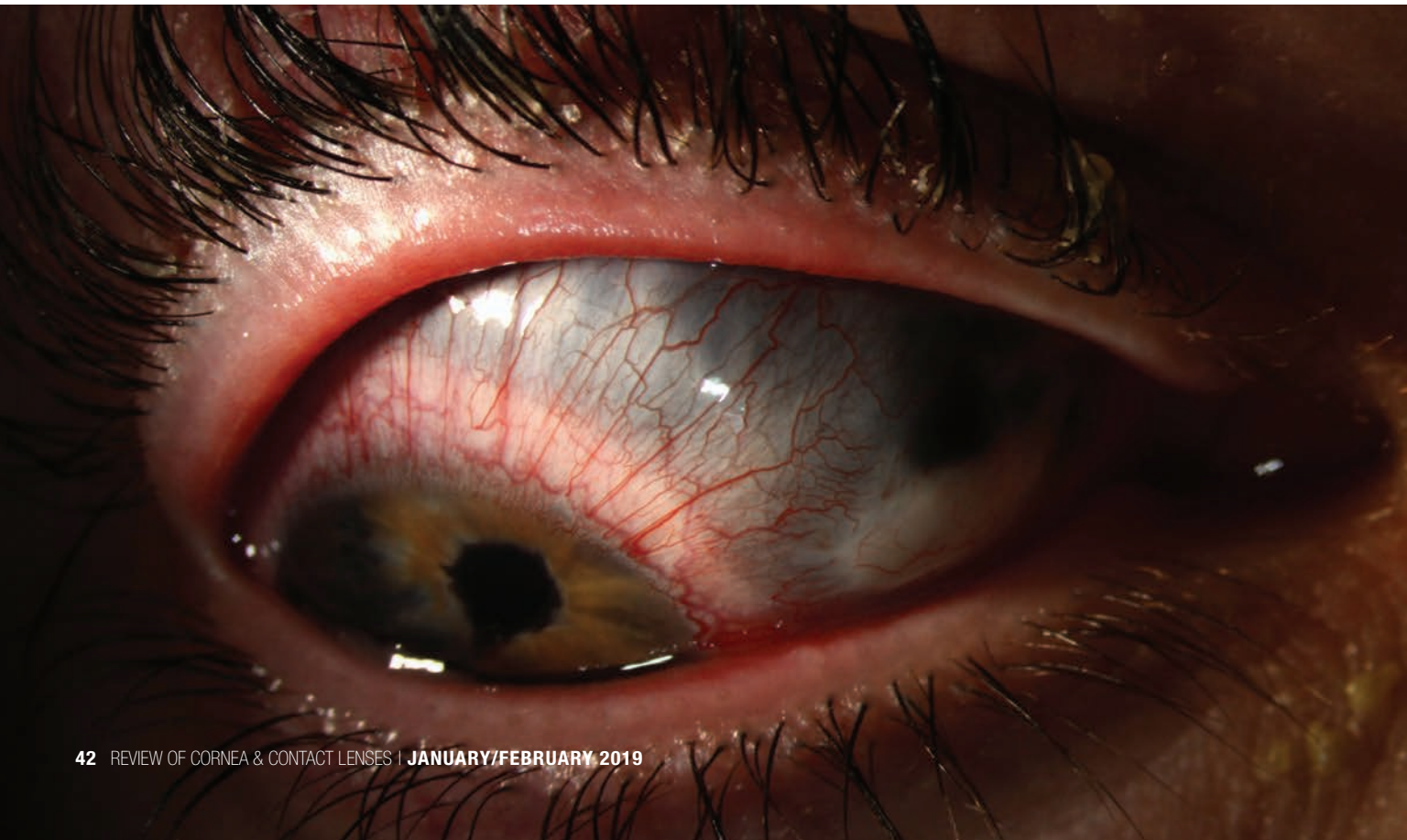Although reinforcement surgery with a scleral patch graft is the usu-

al course of action in staphyloma, it was contraindicated in this case because of the size of the thinned area and the risk of intraocular bleeding. Surprisingly, however, he pinholed to his baseline visual acuity. Refraction yielded lower plus power with a significant increase in astigmatism, providing him 20/80 vision.

While a contact lens correction, including the option of a scleral lens fit, would likely yield better optics, it is contraindicated in this case secondary to the risk of perforation. Safety goggles were prescribed. **RCCL**

1. (Corneal) Staphyloma, Anterior. Am J Neuroradiol. www.ajnr.org/ajnr-case-collections-diagnosis/corneal-staphyloma-anterior. Accessed January 30, 2019.

2. Grieser EJ, Tuli SS, Chabi A, et al. Blueberry eye: acquired total anterior staphyloma after a fungal corneal ulcer. Cornea. 2009;28(2):231-2.





They'll *Love* their lenses! When you prescribe Ampleye® Scleral with Tangible™ Hydra-PEG surface treatment, your patients will enjoy crisp optics, clean, clear surfaces, and comfort that lasts all day. *What's not to love?*

AMPLEYE® Scleral GP

INCREASED FIRST FIT SUCCESS

Novice and advanced fitters agree that Ampleye's efficient diagnostic system reduces chair time and improves first-fit success*

FDA INDICATED FOR DRY EYE/OSD

Enclosed chamber secures fluid to ensure soothing moisture retention and lasting hydration

VERSATILE DESIGN CONTROL FEATURES

Independent control of zones, parameters, quadrants, front surface cylinder & CN multifocal options. Diameters from 15.0 to 17.0mm are suitable for normal or irregular corneas

*data on file

OPTIMUM

tangible™
HYDRA-PEG

ENHANCED SURFACE

Distinctly wettable & lubricious
= fewer deposits, less irritation

A BETTER WEARING EXPERIENCE

Patients prefer* lenses coated in Tangible Hydra-Peg

www.artoptical.com

ARToptical
| contact lens, inc.

800.253.9364

Technology in balance



Health




Vision



Comfort

Miru 1 month: a unique family of silicone hydrogel monthly lenses.

MeniSilk™ and Nanogloss™ technologies designed to meet the demands of today's contact lens wearer.*



Material and surface technologies

MeniSilk™

- Ultra high Dk/t - 161 @ -3.00D
- Exceptional hydration
- Optimized transparency

Nanogloss™

- Super smooth surface
- Resistance to bacteria
- Excellent wettability



www.meniconamerica.com

*Menicon data on file April 2016

