

RCCL[®]

REVIEW OF CORNEA
& CONTACT LENSES

NOVEMBER/DECEMBER 2018

SHARPEN

Your **VIEW** Of
Specialty Lenses


- Spice it Up With Specialty Lenses, p. 6
- Unique Lenses for Unique Patients, p. 10
- Do You Follow These Fitting Principles?, p. 14
- The Ins and Outs of Wavefront Aberrometry, p. 18
- Making Sense of Scleral Lens Materials, p. 24
- Fitting the Surgically Compromised Cornea, p. 28

ALSO: *ACANTHAMOEBA* KERATITIS: A DISEASE IN DISGUISE, p. 36



Doctor Trusted. Patient Approved.

Biofinity[®] toric is
the most prescribed
toric lens on the market.¹



8 out of **10**

patients surveyed agreed or
strongly agreed that **Biofinity[®] toric**
lenses are the best they had worn.²

**Learn how you can fit virtually all your astigmatic patients
in a proven, premium contact lens that is bound to
drive satisfaction at OnlyBiofinity.com/toric**

FROM SPHERE TO SPECIALTY
OnlyBiofinity[®]



CooperVision[®]

SPHERE TORIC MULTIFOCAL

1. US industry data on file.
2. The results of an online survey involving patients who wear Biofinity[®] toric contact lenses. January 2018 Biofinity[®] toric wearer online survey. Data on file.
©2018 CooperVision 7537 10/18

contents

Review of Cornea & Contact Lenses | November/December 2018

departments

4 News Review

New Epi-on CXL Protocol Exceeds Expectations

5 My Perspective

Artificial Intelligence Lightens the Load
By Joseph P. Shovlin, OD

6 The GP Experts

Spice it Up With Specialty Lenses
By Robert Ensley, OD,
and Heidi Miller, OD

36 Corneal Consult

A Disease in Disguise
By Aaron Bronner, OD

38 Fitting Challenges

Out With the Old, in With the New
By Vivian P. Shibayama, OD

40 Practice Progress

Treating Presbyopia: An Armamentarium of Options
By Mile Brujic, OD, and David Kading, OD

42 The Big Picture

A Bump in the Road
By Christine W. Sindt, OD

features

10

Unique Lenses for Unique Patients

Understanding your patients' needs ahead of time is half the battle.

By Irene Frantzis, OD, and Eva Duchnowski, OD

14

You You Follow These Fitting Principles?

Supplementing the clinical experience with fitting guides will help you keep your custom contact lens patients happy.

By Shalu Pal, OD

18

The Ins and Outs of Wavefront Aberrometry

Combining this technology with corneal topography and medical imaging can help optometrists successfully manage their specialty contact lens patients.

By Thomas A. Wong, OD, and G. Timothy Petito, OD

24

Making Sense of Scleral Lens Materials

With so many options on the market, it's hard to make the right choice for each patient. These tips can help.

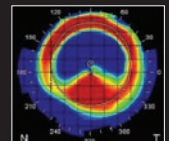
By Justin Manning, OD, MPH

28

CE — Fitting the Surgically Compromised Cornea

Specialty contact lenses are often the best option for post-corneal surgery patients. Here's how you can handle these challenging cases.

By Beth Summers, OD, MS, and Maayan E. Keshet, MD



Become a Fan on
Facebook

/ReviewofCorneaAndContactLenses



Follow Us on
Twitter

@RCCLmag

11 Campus Blvd., Suite 100
 Newtown Square, PA 19073
 Telephone (610) 492-1000
 Fax (610) 492-1049

Editorial inquiries: (610) 492-1006
 Advertising inquiries: (610) 492-1011
 Email: rccl@jobson.com

New Epi-on CXL Protocol Exceeds Expectations

An investigational new epithelium-on corneal crosslinking (CXL) protocol could be safer and provide more rapid visual recovery than current epi-on methods.

The intact epithelium in epi-on procedures reduces oxygen availability and hinders riboflavin penetration into the stroma, both needed for clinical success. But the epi-off method subjects patients to significant post-treatment pain and other potential complications.

Hoping to improve upon epi-on results typical of the established Dresden protocol, researchers used a new riboflavin formulation and application method, plus a pulsed (rather than continuous) dosing of ultraviolet A that “allows oxygen the time to go back into the cornea,” explained study author Doyle Stulting, MD, PhD at the Annual Meeting of the International Society of Refractive Surgery during the recent American Academy of Ophthalmology meeting in Chicago. Dr. Stulting noted that the new protocol can “safely stop progression of ectatic disease in corneas that are as thin as 302nm.”

The new formulation was used to treat 512 eyes with active or incipient keratoconus and 80 eyes with post-LASIK ectasia. After riboflavin dosing, patients received exposure to UV light (365nm) at 4mw/cm² with on-off cycling for 30 minutes.

Mean uncorrected and corrected distance visual acuities improved by 1.0 to 1.5 Snellen lines at one and two years postoperatively. After two years post-op, total higher-order aberrations and coma decreased 36% and 37%, respectively. Kmax decreased more than one diopter in three times as many eyes as it increased. No eyes progressed and there was no loss of effect in year two compared to year one post-op.

Dr. Stulting stated that his team saw no complications in the 592 eyes. Pain lasted for 24 hours, blurred vision lasted for two to three days and contact lens wear resumed within a week. He also believes that this new protocol may be able to retreat those who have previously received epithelium-on CXL and have experienced progression.

Stulting RD, Trattler WB, Woolfson JM, Rubinfeld RS. Corneal crosslinking without epithelial removal. J Cataract Refract Surg. 2018;44(11):1363-70.

IN BRIEF

■ Patients with unresponsive **persistent epithelial defect** may benefit from topical caciol, a matrix regenerating agent, according to a small study. Twenty of 23 eyes (86.9%) **showed complete corneal healing**, on average, after a week. Additionally, ulcers continued to decrease in size at a consistent rate, from 61.2% on the second day of treatment up to 85.5% on the tenth day.

Sevik MO, Turhan SA, Toker E. Topical treatment of persistent epithelial defects with a matrix regenerating agent. J Ocul Pharmacol Ther. Oct. 12, 2018. (E-pub, ahead of print).

■ **Drinking** may have a lasting **effect on the cornea**. A study of 161 alcohol dependence syndrome (ADS) patients and 161 controls found the ADS group had a **higher mean central corneal thickness** (529um vs. 510um) and a **lower cell count** per square millimeter (2571 vs. 2752). Both differences persisted after abstinence from alcohol. The study also notes a correlation between increased liver disease and corneal endothelial alteration.

Sati A, Moullick P, Shankar S. Corneal endothelial alterations in alcohol dependence syndrome. Bri J Ophthalmol. September 24, 2018 [Epub ahead of print].

EDITORIAL STAFF

EDITOR-IN-CHIEF

Jack Persico jpersico@jobson.com

MANAGING EDITOR

Rebecca Hepp rhepp@jobson.com

ASSOCIATE EDITOR

Catherine Manthorp cmanthorp@jobson.com

ASSOCIATE EDITOR

Mark De Leon mdeleon@jobson.com

CLINICAL EDITOR

Joseph P. Shovlin, OD, jpshovlin@gmail.com

ASSOCIATE CLINICAL EDITOR

Christine W. Sindt, OD, christine-sindt@uiowa.edu

EXECUTIVE EDITOR

Arthur B. Epstein, OD, artepstein@artepstein.com

CONSULTING EDITOR

Milton M. Hom, OD, eyemage@mminternet.com

GRAPHIC DESIGNER

Ashley Schmouder aschmouder@jobson.com

AD PRODUCTION MANAGER

Scott Tobin stobin@jhihealth.com

BUSINESS STAFF

PUBLISHER

James Henne jhenne@jobson.com

REGIONAL SALES MANAGER

Michele Barrett mbarrett@jobson.com

REGIONAL SALES MANAGER

Michael Hoster mhoster@jobson.com

VICE PRESIDENT, OPERATIONS

Casey Foster cfoster@jhihealth.com

EXECUTIVE STAFF

CEO, INFORMATION SERVICES GROUP

Marc Ferrara mferrara@jhihealth.com

SENIOR VICE PRESIDENT, OPERATIONS

Jeff Levitz jlevitz@jhihealth.com

SENIOR VICE PRESIDENT,

HUMAN RESOURCES

Tammy Garcia tgarcia@jhihealth.com

VICE PRESIDENT,

CREATIVE SERVICES & PRODUCTION

Monica Tettamanzi mtettamanzi@jhihealth.com

VICE PRESIDENT, CIRCULATION

Emelda Barea ebarea@jhihealth.com

CORPORATE PRODUCTION MANAGER

John Caggiano jcaggiano@jhihealth.com

EDITORIAL REVIEW BOARD

Mark B. Abelson, MD

James V. Aquavella, MD

Edward S. Bennett, OD

Aaron Bronner, OD

Brian Chou, OD

Kenneth Daniels, OD

S. Barry Eiden, OD

Desmond Fonn, Dip Optom M Optom

Gary Gerber, OD

Robert M. Grohe, OD

Susan Gromacki, OD

Patricia Keech, OD

Bruce Koffler, MD

Pete Kollbaum, OD, PhD

Jeffrey Charles Krohn, OD

Kenneth A. Lebow, OD

Jerry Legerton, OD

Kelly Nichols, OD

Robert Ryan, OD

Jack Schaeffer, OD

Charles B. Slonim, MD

Kirk Smick, OD

Mary Jo Stiegemeier, OD

Loretta B. Szczotka, OD

Michael A. Ward, FCLSA

Barry M. Weiner, OD

Barry Weissman, OD





Artificial Intelligence Lightens the Load

Technological advances present tangible benefits for diagnosis and care.

If we could get a glimpse into the future, what would clinical practice a decade or two from now look like? For certain, it would include a heavy emphasis on telemedicine that involves some form of artificial intelligence (AI). We've just witnessed the first fast-track FDA-approved example of an AI system (IDx-DR, IDx Technologies) to detect diabetic retinopathy, so AI has definitely entered the field of medicine and eye care in a formal fashion. Teams around the world are using AI for imaging diagnostics (image analysis and machine learning tools) to detect early macular degeneration and glaucoma. And I'm certain there's much more to come.

AI TODAY AND TOMORROW

By any standard, AI is not a recent development. We've used AI in its crudest form for many years—most of us just haven't realized it. Glaucoma management relies on regression analysis from images of the nerve fiber layer and ganglion cell complex. When we interpret visual fields, we receive automated information that helps us determine the best course of action for each patient.

Machine-learning AI also plays an important role in disease diagnosis verification with multiple optical coherence tomography (OCT) image readings and intraocular lens calculations of corneas with significant pathology or after corneal surgery to improve outcomes in cataract surgery patients.¹ Machine learning is a sub-field of AI, and deep learning is a sub-division of machine learning.¹ Diabetic

retinopathy detection currently uses machine-learning algorithms, which will continue to serve us well in other areas in the future.

Once an AI system can recognize patterns or markers of disease, it can be used for automated diagnosis and detection of almost any condition seen in clinical practice.² AI systems that feature deep learning with conventional neural networks can identify any number of disease features, leading the way to future uses in cornea and contact lens-related technologies.^{2,3} Using deep learning to learn more about a disease pattern of expression may provide additional markers for diagnosis and for staging and gauging prognosis.⁴

SURPRISES IN STORE

In addition to posterior segment applications, researchers are developing and validating AI systems for the automatic diagnosis and characterization of anterior segment diseases such as (1) grading cataracts in the pediatric/newborn population based on images obtained by slit lamp and (2) assessing keratoconus based on Scheimpflug images that provide measurements of curvature, thickness and opacity.³

An especially exciting initiative in eye care AI comes from a collaboration between the Moorfields Eye Hospital in London and the Google AI team, DeepMind. These teams created an AI system that combines two deep-learning systems with the ability to detect multiple ophthalmic diseases based on an analysis of 3D OCT data by creating a tissue map and then inspecting for potential markers of that disease.³

CONCERNS CONTINUE

Some experts worry about AI's limitations, such as the technology's ability to evaluate context accurately and the applicability for a system's use.⁴ AI systems will need model and performance metrics to assess efficacy and accuracy at the same standard as the rest of us. We'll still need humans to oversee the machine-driven technologies that will be developed in the near future.

Assistive AI won't make us more productive but it will allow greater patient access, lower costs and opportunities to learn more about a particular disease or condition for better outcomes possible.²

Artificial intelligence and, in particular, deep learning, will surely change the way we work and will indeed help us serve a broader patient base. AI is just one of the many ways practice will change in the future. As resources advance, disruptive technologies will flourish. It's difficult to predict how significantly future advances in AI systems will impact the management of anterior segment conditions. The future will be exciting but also poses new challenges to all of us engaged in practice. **RCCL**

1. AI Applications in Ophthalmology Achieve Human Expert-Level Performance. Healio Ocular Surgery News. June 10, 2018. <https://www.healio.com/ophthalmology/technology/news/print/ocular-surgery-news/%7B373d8cf8-f72b-43fe-b362-29ba35c-416ba%7D/ai-applications-in-ophthalmology-achieve-human-expert-level-performance>. Accessed November 15, 2018.

2. Roach L. Artificial intelligence. EyeNet. 2017;77-83.

3. Varma R. How AI benefits patients and physicians. Ophthalmology Times. 2018. <http://www.ophthalmologytimes.com/article/how-ai-benefits-patients-and-physicians>. Published September 15, 2018. Accessed November 15, 2018.

4. Trikhar, S. Embracing and managing AI in the eye care workplace. Ophthalmology Times Europe. <http://europe.ophthalmologytimes.com/ophthalmology/embracing-and-managing-ai-eye-care-workplace>.

Spice it Up With Specialty Lenses


Revitalize your practice and learn the services available that can improve your patients' quality of life.

Specialty contact lenses have grown in popularity over the past few years. Despite this rise, for many, the idea of incorporating a new service into an established office is intimidating. The thought of learning how to fit something new and to manage complex patient conditions alone can seem impossible. Starting anything from the ground up can be a challenge; however, incorporating a unique niche into your practice can be both financially and emotionally rewarding. Ultimately, if you have the passion to change lives with specialty lenses and the desire to grow your practice, patients will find you.

FIRST STEPS

Do you want to start incorporating specialty lenses in your office but do not know where to start? Whether you are adding orthokeratology, custom soft lenses or scleral gas permeable (GP) lenses, it is important that you do your homework, invest in the technology and prepare your staff for the changes to come. Your staff will be a huge asset in your efficiency with patient care and overall success of your office.

Contracts. Start by updating your office handouts and contact lens contract. This contract needs to clearly state fees, follow up period and warranties for lenses. Make sure each patient is aware of the differences between vision plans and medical insurances and whether



Don't shy away from incorporating specialty contact lenses in your office.

there are any global periods.

It is important that the contract states costs of procedure, materials and what follow up period these costs account for. Include the necessary testing and fees associated with additional testing as well. Your front office staff should briefly go over any important information with the patient before they sign any paperwork, confirming the patient understands office protocols and fees.

The more transparent and detailed your contract, the better off your office will be with handling specialty lenses. Many times, patients are frustrated at

the end of exams because they did not fully understand underlying fees prior to their visit. Avoid this by being more thorough with them when they check in.

Authorizations. If you have an established patient with a known diagnosis, it is best to submit authorizations to medical insurance with a letter of medical necessity prior to their office visit. This will ensure both the practitioner and the patient are aware of covered benefits ahead of

time. Your office staff should have this done for both medical and vision plans prior to scheduling a contact lens evaluation. Have your staff highlight benefits and attach it to the patient's record upon the patient's arrival to the appointment. If a patient is denied

BILLING AND CODING SPECIALTY LENSES


Specialty lenses not only allow a practitioner to manage a wide variety of conditions but also benefits your practice financially. Make sure to stay up-to-date on billing and coding as the insurance landscape is ever changing. The following is an example of a keratoconus specialty lens evaluation:

Patient Example: ICD 10 - CM: H18.623

Keratoconus, unstable, bilateral

•99204 - E/M level 4, New Patient	\$ 300.00
•92015-22 - Refraction, Complex	\$ 50.00
•92285 - External photography	\$ 35.00
•76514 - Pachymetry	\$ 18.00
•92025 - Corneal topography	\$ 44.00
•92286 - Specular Microscopy	\$ 42.00
•92072 - Prescribing for Keratoconus	\$ 650.00
•V2531-RT - Scleral Lens	\$ 700.00
•V2531-LT - Scleral Lens	\$ 700.00
TOTAL	\$2,539.00

(used for illustrative purposes only, not true fees)



for services or materials, the patient can try to contest and re-submit for reimbursement on their own.

THESE THINGS TAKE TIME

Give yourself adequate time during contact lens evaluations. In the beginning, you may want to block out 45 minutes or more to give yourself sufficient time to fit various lenses and appropriately evaluate the fit. If your technician has never fit a hybrid, corneal GP or scleral GP lens before, have them shadow you during each specialty lens encounter so they can learn the correct method of lens handling. They will also be able to see your technique for insertion and removal of lenses and apply what they learn to future patient encounters. It is very common at the start to require more time since you will be doing the majority of the work yourself. But once your technician learns how to perform diagnostic imaging, lens prep and insertion and removal, they can assist during the exam. They can also help review lens care and train patients on appropriate insertion/removal techniques for contact lens dispense visits.

You may start with having your technician practice insertion and removal on your staff initially so they can develop a safe technique for lid manipulation and lens handling. Once they feel confident, your technician can begin assisting you with insertion and removal while you are in the exam room. With practice, your technician will become more efficient in handling lenses and acquiring imaging.

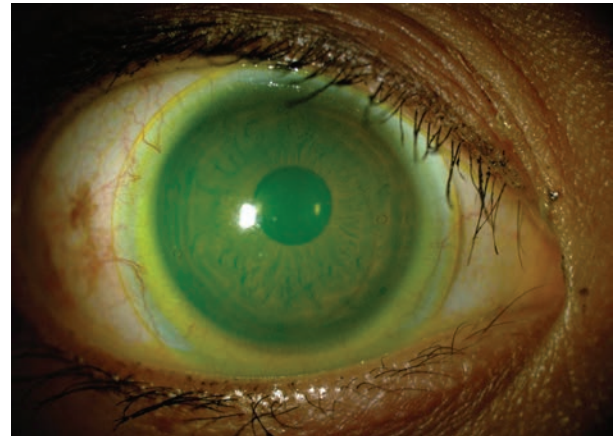
Depending on your comfort level, your technician may eventually complete the majority of the initial diagnostic fitting prior to you evaluating the lens and performing over-refraction, enhancing efficiency of patient care.

FINDING A GOOD CANDIDATE

Often, practitioners think about the cost of specialty contact lenses and assume a patient is not willing to pay for the services without even broaching the subject. It is important to change this mindset. We should want the best possible vision and quality of life for our patients, so we should offer any services we think might allow just that. This can range from a person with an irregular cornea, like keratoconus, to a high astigmatic patient desiring sharp, stable vision at all distances. If a person complains of dry eye and is no longer tolerant of their soft lenses, a scleral lens may be a good option. Not only will this provide a moisture chamber on their eye, but they will also get the enhanced optics of a gas permeable lens.

Patients who can benefit from specialty lenses include:

- *Keratoconus or pellucid marginal degeneration patients.*



A mini-scleral lens may be the option for your patient with high corneal astigmatism.

- *Myopia control treatment patients.*
- *Normal cornea patients intolerant to soft contact lenses.*
- *Patients with corneal scarring due to prior trauma or infection.*
- *Post corneal transplant patients.*
- *Ocular surface disease.*
- *Patients with high astigmatism.*
- *Patients with presbyopia who desire clear vision at all distances.*

Specialty lenses help set you apart from average practitioners, an especially important distinction as mass market soft lenses get commodified. Fitting specialty lenses is a rewarding experience for both patients and practitioners and can become a lucrative part of your practice. By taking the initiative to hone your skills with specialty lenses, you will be providing an invaluable service that can make a large difference in patients' lives. **RCCL**

Reasons to Reach for Silicone Hydrogel 1-Days

Expert views on the use of silicone hydrogel for 1-day wearers

Silicone hydrogel has become the first choice material in most practices, with ECPs fitting 90% of their monthly and two-week contact lens wearers in this material¹. This statistic aligns closely with practitioners' concerns about hydrogel materials. For example, 83% worry that frequent replacement hydrogel lens wearers' corneas aren't getting all the oxygen they require. But doctors aren't only concerned about material choice for their frequent replacement wearers. Research shows that 77% of ECPs worry that their hydrogel 1-day lens wearers' corneas aren't getting all the oxygen they require.

Research shows that even daily disposable wearers often don't follow safe wearing instructions and have lifestyles that present significant challenges to safe, comfortable lens wear.* When you consider modern lifestyle challenges, including digital device use, as well as how many hours 1-day patients typically wear their lenses, it becomes quite obvious that replacement schedule shouldn't dictate material choice.

We spoke with three optometrists who advocate the use of silicone hydrogel for 1-day wearers. In the interviews that follow, they explain why they are so committed to the material and how it has improved their relationship with patients as well as their practices.

The Practitioners



Melanie Frogozo OD, FAAO, FLS
The Contact Lens Institute of San Antonio – San Antonio, Texas



Ethan E. Huisman OD, FAAO
Elite Eye Care
West Des Moines, Iowa



Steve Rosinski OD
Crozet Eye Care
Charlottesville, Virginia

From a material standpoint, why do you reach for silicone hydrogel?

Dr. Huisman: In all patient populations, and especially in younger eyes, long-term eye health is paramount. Silicone hydrogel delivers meaningful ocular health thanks to outstanding oxygen permeability. In fact, 92% of ECPs say silicone hydrogel 1-day lenses are the best choice to safeguard their patients' eye health related to contact lens wear. That's a significant majority. Beyond oxygen benefits, the material also allows for easy insertion and removal as well as all-day comfort. About 80% of ECPs agree that silicone hydrogel 1-day lenses

are more comfortable than hydrogel 1-day lenses. Finally, because silicone hydrogel is so comfortable and doesn't dry out, patients aren't rushing home from work to remove their lenses.

Dr. Frogozo: Almost 90% of ECPs agree that if they were to create the perfect lens or if they could only fit one material it would be silicone hydrogel. Obviously, most of us know that silicone hydrogel is a healthier choice than hydrogel material, as evidenced by the changes we've made in material selection for frequent replacement wearers. Our 1-day wearers are no different—there's no reason to deprive them of silicone

hydrogel. This is one of the reasons why we have only one hydrogel set in our whole practice and our 1-day fits are entirely in silicone hydrogel material. We strongly believe in the benefits this material provides.

Dr. Rosinski: When any new lens comes out, I like to do my research to see what the studies have shown. I also solicit feedback from my colleagues. But, even if the reviews are glowing, it has to make my patients happy to earn space on my shelf. Silicone hydrogel, in general, and the clariti® 1 day family and MyDay®, in particular, have made my patients happy from a comfort perspective and from a handling perspective, and both have likewise proven to be outstanding from a clinical perspective.

What patient populations are particularly well suited to silicone hydrogel lenses?

Dr. Rosinski: Most, if not all, types of patients are good candidates for silicone hydrogel 1-day lenses. We now have a very broad range of options in this category, including a wide range of sphere, multifocal and toric parameters. I'm not sure why you wouldn't start with a silicone hydrogel 1-day lens as long as you were able to. Explain the benefits to the patients and let them try it.

Dr. Huisman: Almost every patient who can be fit in a soft lens is well suited to silicone hydrogel. There is no logical reason to limit silicone hydrogel fittings to frequent replacement wearers. Most 1-day wearers use their lenses full-time for as many hours as their frequent replacement lens-wearing counterparts. Clearly, the demands are every bit as great and require a lens that offers a healthier lens wearing experience.

84% of the ECPs agreed

that if they could, they would like to prescribe all **new contact lens wearers** with silicone hydrogel 1-day lenses.



About 80% of ECPs agree

that silicone hydrogel 1-day lenses are more comfortable than hydrogel 1-day lenses.



87% of ECPs say

that if they want to keep patients from dropping out of lens wear, they would refit them with 1-day silicone hydrogel lenses.



92% of ECPs say

silicone hydrogel 1-day lenses are the best choice to safeguard their patients' eye health related to contact lens wear.



Dr. Frogozo: There's a misconception that 1-day wearers don't need silicone hydrogel when, in fact, this is the perfect population for the material. These patients have already demonstrated that they value eye health and wellness. Furthermore, a lot of 1-day hydrogel wearers have end-of-day dryness and redness that interferes with daily life. I put all of my new sphere fits in silicone hydrogel and I refit patients who are currently using hydrogel 1-day lenses into 1-day silicone hydrogel.

Why should you switch to a silicone hydrogel material if your patient seems happy with their current 1-day lenses?

Dr. Rosinski: Patients come to me to get the most innovative product they can find. Silicone hydrogel 1-day lenses are exactly that. I sometimes hear colleagues say these lenses cost too much, but cost is relative. We should never make assumptions about what a patient can or can't afford. Offer the best every time. Even if a patient turns it down, you've

made it clear that you know what's best and you make it available to your patients. This goes a long way toward building a good reputation. And at the very least, it plants the seed for future visits.

Dr. Huisman: Switching to silicone hydrogel is preventative care. Recent research shows that 87% of ECPs say that if they want to keep patients from dropping out of lens wear, they would refit them with 1-day silicone hydrogel lenses. If a patient is wearing hydrogel on a full-time basis, proactively switching to silicone hydrogel can save the patient from the same type of symptoms you'd expect in a full-time frequent replacement hydrogel wearer.

Dr. Frogozo: I agree. Also, if the patient is currently wearing hydrogel lenses, they may already have hypoxia—in which case I point this out to illustrate why I'm making the change. If they don't yet have signs of hypoxia, they soon may. I don't want patients dropping out if there's something I can do to prevent it from happening in the first place.

Options for Your 1-Day Wearers

Offer your 1-day contact lens patients a healthier³ lens-wearing experience. CooperVision's broad range of silicone hydrogel 1-day contact lenses can provide up to four times the oxygen transmissibility of traditional hydrogel contact lenses².

From the clariti® 1 day family to the MyDay® family, you can fit virtually all patients into a 1-day contact lens that provides high oxygen, comfort, and convenience.

For more information, visit Coopervision.com



¹ Industry third-party data.

² Manufacturer stated oxygen transmissibility values (Dk/t): MyDay® daily disposable (100), clariti® 1 day (86), 1-DAY ACUVUE® MOIST® (25.5), SofLens® daily disposable (24).

³ With higher oxygen transmissibility than hydrogel materials, silicone hydrogel contact lenses minimize or eliminate hypoxia-related signs and symptoms during lens wear.

*It is essential that patients follow eye care practitioner's directions and all labeling instructions for proper use of lenses.

** With manufacturer's rebate. \$200 rebate applies to patients new to CooperVision contact lenses. © 2018 CooperVision, Inc. 7059 05/18

UNIQUE LENSES *for* UNIQUE PATIENTS

Understanding your patients' needs ahead of time is half the battle.

By Irene Frantzis, OD, and Eva Duchnowski, OD

We are often pressed for time with our patients and, in an effort to quickly see one patient and move on to the next to increase patient volume due to low insurance reimbursements, may skip what seems like ancillary testing during contact lens evaluations. While maybe not a direct result, contact lens dropout rates remain high due to factors such as discomfort and vision-related problems.¹ This makes it more important than ever to prioritize patient comfort and quality of care by taking the time to exercise basic contact lens exam principles and gather appropriate patient information upfront, thereby reducing contact lens problems down the road and increasing overall patient success and satisfaction.

We must first obtain thorough medical and ocular histories from our patients, including whether they wear or have worn contact lenses. ODs should consider taking anatomical measurements—horizontal visible iris diameter (HVID), pupil size in dim and bright illumination and palpebral aperture size—when necessary. We must also obtain a refraction, assess corneal curvature, evaluate binocular vision and perform a slit lamp evaluation. The following article

discusses a few steps ODs should follow to carry out a successful contact lens fitting.

MEASURE THE HVID

While soft lenses that are too small can cause irritation, soft lenses that are too large can cause insertion difficulties. Ordering the right contact lens parameters, therefore, is key and can be done by first taking a handful of anatomical measurements, including the HVID.

Ideally, a soft lens should overlap the limbal region by at least 0.5mm in every direction. As a general rule of thumb, adding 2.0mm to the HVID is a good approximation when determining an initial lens diameter that will comfortably fit an eye and provide enough coverage around the cornea.²

The average HVID is 11.8mm, so the majority of commercially available lenses range from 13.8mm to 14.5mm in diameter.³ If a patient falls outside of this range, a custom soft lens may be necessary, especially because lens coverage on the eye could already be less than expected. Decentration of the lens is one potential cause of this phenomenon. In addition, the HVID underestimates corneal diameter by approximately 1.0mm, and the limbal zone varies among patients.⁴ Soft lenses have also been

shown to shrink several tenths of a millimeter when placed on the eye due to the change in temperature and pH.⁴ Taking this information into consideration when fitting contact lens patients can greatly improve your success rate.

CASE EXAMPLE #1

A 20-year-old Caucasian female presented for a contact lens evaluation. The patient reported poor comfort in her current toric daily disposable soft lenses, which had a base curve (BC) of 8.5mm and a diameter of 14.5mm. Her vision with the current lenses was 20/20 OU, and ocular health findings were unremarkable. Upon evaluating the patient's current lens fit, we found adequate lens movement but temporal decentration and poor

ABOUT THE AUTHORS



Dr. Frantzis is an assistant clinical professor at the SUNY College of Optometry. She specializes in complicated contact lens fittings and myopia control.



Dr. Duchnowski is chief of the Contact Lens Service at the University Eye Care Center and director of the Cornea and Contact Lens externship at the SUNY College of Optometry.

coverage over the nasal limbus OU.

Manifest refraction revealed:

- +0.50 -1.25x170 (VA of 20/20) OD
- -0.50 -1.25x180 (VA of 20/20) OS

The patient's keratometry readings were 43.00/43.75@085 OD and 42.75/44.25@085 OS with clear and regular mires OU. Her HVID was larger than average at 13.1mm. We ordered custom C-vue soft toric lenses with a BC of 8.7mm and a diameter of 15.0mm. The patient maintained 20/20 vision OU with the new lenses, which had better centration and coverage over the limbal region, and reported an improvement in comfort compared with her previous lenses.

FIND THE CORNEAL CURVATURE

Corneal curvature should be evaluated in every contact lens patient. This is often done by keratometry or autokeratometry, which only measures the central 3.0mm of the cornea. Corneal topography provides more detailed information on corneal shape and usually measures out to 9.0mm to 10.0mm. Regardless, evaluating corneal curvature helps ODs determine which lens has the best chance of



Fig. 1. This patient has a high amount of astigmatism and wears a well-fitting GP. The fluorescein pattern shows a uniform green alignment and adequate edge lift.

successfully fitting certain patients.

Patients with small amounts (<1.00D) of corneal astigmatism can often be managed successfully in a soft lens. Patients with moderate amounts (1.00D to 3.00D) may benefit from a spherical gas permeable (GP) lens, while patients with high amounts (>3.00D) may benefit from a bitoric GP.⁵

According to a survey of diplomates in the Cornea and Contact Lens Section of the American Academy of Optometry, the majority of ODs prefer using bitoric GPs at 2.00D to 2.75D of corneal cylinder and implementing the Mandell-Moore guide when fitting these lenses.⁶ VA measurements do not differ significantly between soft lenses and GPs, and patients with moderate to severe amounts of astigmatism often report an improvement in the quality of their vision with GP lenses.⁷

CASE EXAMPLE #2

A 27-year-old Asian male was referred by his MD for a contact lens evaluation. He had a history of soft lens use but reported discontinuing lens wear because he achieved better vision with glasses.

Manifest refraction revealed:

- -6.50 -4.50x005 (VA of 20/20) OD
- -8.50 -3.50x170 (VA of 20/20-) OS

We obtained Pentacam topography images, which revealed average pachymetry values, and did not find any abnormalities on

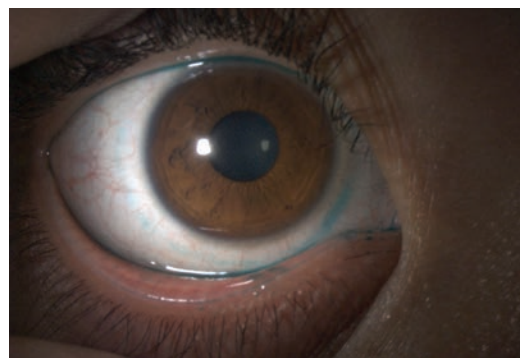


Fig. 2. Here, we can see lissamine green staining of the conjunctiva in a patient with a history of a tight-fitting soft lens.

the posterior or anterior elevation maps of either eye. We did find a large amount of corneal cylinder—3.30D OD and 3.10D OS—that led to us ordering bitoric GP lenses by X-Cel for the patient.

The amount of corneal and refractive astigmatism were not equivalent in the patient's right eye, so we ordered a lens with a cylinder power effect design with a diameter of 9.3mm, a power of -6.00D/-9.00D and a BC of 44.25D/46.75D. His left eye, on the other hand, had a similar amount of corneal astigmatism and refractive astigmatism, so we ordered a lens with a spherical power effect design with a diameter of 9.3mm, a power of -7.75D/-9.75D and a BC of 45.00D/47.25D. This type of bitoric lens has the added benefit of rotating without inducing any astigmatism or causing blurry vision.

We achieved an adequate alignment fit with the new lenses upon observation with fluorescein, and the patient achieved 20/20 vision OU (*Figure 1*). He also reported an improvement in comfort.

EVALUATE THE OCULAR SURFACE

Carefully checking the ocular surface for irregularities is an important part of any contact lens evaluation, as approximately 30%

UNIQUE LENSES FOR UNIQUE PATIENTS

to 50% of contact lens wearers report dry eye (DE) symptoms.⁸

During slit lamp examinations, lids and lashes should be carefully evaluated for any signs of blepharitis or meibomian gland dysfunction; contact lens wear has been associated with meibomian gland dropout, lower quality meibum and increased lid margin abnormalities.⁸ The conjunctiva should be evaluated by eyelid eversion, and conjunctival staining with lissamine green should be used over rose bengal, as it does not sting as much and has been helpful in diagnosing DE (Figure 2).⁹ The tear film and cornea should also be carefully evaluated with fluorescein staining. Based on the severity of the case, additional DE testing, such as osmolarity or MMP-9 testing, may be necessary.

For patients with moderate to severe ocular surface disease (OSD) who were not successful with more conservative treatment options, such as drops or punctal plugs, scleral lenses may be the solution. Scleral lenses can heal the cornea and resolve epithelial defects by providing mechanical protection and continuous hydration. Studies have demonstrated the safety and efficacy of scleral lenses in improving ocular comfort, protecting the ocular surface and resolving epi-

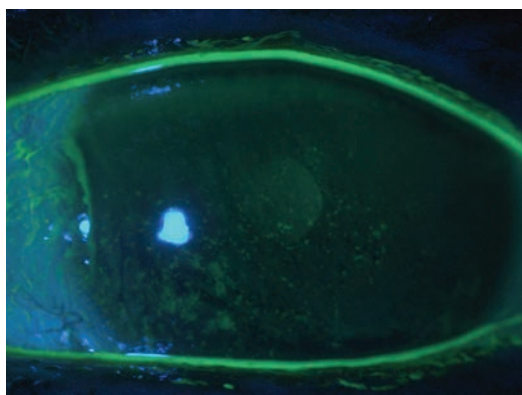


Fig. 3. This patient has severe dry eye and diffuse punctate epithelial defects.

theliopathy in patients with various types of OSD, including neurotrophic keratopathy, exposure keratopathy and limbal stem cell deficiency.¹⁰ In any case, DE should be managed appropriately prior to initiating contact lens wear.

CASE EXAMPLE #3

A 50-year-old female with a history of severe DE was referred for a corneal evaluation. The patient had been prescribed various artificial tears, ointments and steroids but experienced minimal relief. She was motivated to resume contact lens wear but reported poor vision in previous monovision soft lenses and custom soft toric multifocals. A slit lamp evaluation showed diffuse punctate epithelial erosions OU (Figure 3).

Manifest refraction revealed:

- -11.00 -1.00x035 (VA of 20/40) OD
- -10.75 -0.50x115 (VA of 20/40) OS

We managed the patient's DE by prescribing preservative-free tears and ointment for use at night. Unfortunately, the patient deferred treatment with topical cyclosporine and an amniotic membrane due to cost concerns. More consistent lubrication improved her ocular surface, and we fit her in scleral multifocals by Valley Contax due to ocular surface concerns and vision demands. The scleral fit showed adequate vault and edge alignment, and the patient achieved 20/20 vision OU (Figure 4). After several weeks of wearing the



Fig. 4. This optic section shows a 1:1 ratio of lens thickness to tear film layer in a scleral fit. We are comparing the dark layer (lens thickness) to the tear film layer (green band).

lenses, the patient's ocular surface showed improvement.

YOU GET OUT WHAT YOU PUT IN

The most important lesson for ODs who fit patients with contact lenses is to remember basic contact lens principles and gather appropriate information during initial contact lens evaluations no matter how much time it takes and how many patients you have to see. Putting in the time and effort upfront pays off in the long run and leads to more successful, satisfied patients. **RECL**

1. Sulley A, Young G, Hunt C. Factors in the success of new contact lens wearers. *Cont Lens Anterior Eye*. 2017;40(1):15-24.
2. Bennett ES, Henry VA. *Clinical manual of contact lenses*. 4th edition. 2014.
3. Caroline PJ, André MP. The effect of corneal diameter on soft lens fitting, part 1. *Cont Lens Spectrum*. 2002;17(4):56.
4. Jones L, Brennan NA, González-Méjome J, et al. The TFOS International Workshop on Contact Lens Discomfort: report of the contact lens materials, design and care subcommittee. *Invest Ophthalmol Vis Sci*. 2013;54(11):13-13215.
5. Kastl PR. Correction of astigmatism with rigid gas permeable lenses. *Ophthalmol Clin North Am*. 2003;16(3):359-63.
6. Blackmore K, Bachand N, Bennett ES, et al. Gas permeable toric use and applications: survey of Section on Cornea and Contact Lens Diplomats of the American Academy of Optometry. *Optometry*. 2006;77:17-22.
7. Michaud L, Barriault C, Dionne A, et al. Empirical fitting of soft or rigid gas permeable contact lenses for the correction of moderate to severe refractive astigmatism: a comparative study. *Optometry*. 2009;80(7):375-83.
8. Arita R, Fukuoka S, Morishige N. Meibomian gland dysfunction and contact lens discomfort. *Eye Cont Lens*. 2017;43(1):17-22.
9. Perry HD, Donnenfeld ED. Dry eye diagnosis and management in 2004. *Curr Opin Ophthalmol*. 2004;15:229-304.
10. Schornack MM, Pyle J, Patel SV. Scleral lenses in the management of ocular surface disease. *Ophthalmology*. 2014;121(7):1398-1405.

Earn up to
18-28 CE
Credits*

REVIEW GROUP
VISION CARE EDUCATION, LLC

NEW TECHNOLOGIES
& TREATMENTS IN
2019 EYE CARE



Join us for our
2019 MEETINGS



FEBRUARY 15-19, 2019 - ASPEN, CO

Annual Winter Ophthalmic Conference

Westin Snowmass Conference Center

Program Co-chairs: Murray Fingeret, OD, and Leo Semes, OD

REGISTER ONLINE: www.skivision.com



MARCH 7-10, 2019 - ORLANDO, FL

Disney Yacht & Beach Club

Program Chair: Paul Karpecki, OD, FAAO



APRIL 11-14, 2019 - SAN DIEGO, CA**

Manchester Grand Hyatt

Program Chair: Paul Karpecki, OD, FAAO



May 17-19, 2019 - NASHVILLE, TN

Gaylord Opryland

Program Chair: Paul Karpecki, OD, FAAO



NOVEMBER 1-3, 2019 - BALTIMORE, MD

Renaissance Baltimore Harborplace

Program Chair: Paul Karpecki, OD, FAAO

Visit our website for the latest information: www.reviewsce.com/events
e-mail: reviewmeetings@jhihealth.com or call: 866-658-1772

Administered by

Review Group Vision Care Education, LLC



*Approval pending



Pennsylvania College of Optometry



**16th Annual Education Symposium
Joint Meeting with NT&T in Eye Care

Review Group Vision Care Education, LLC partners with Salus University for those ODs who are licensed in states that require university credit.
See www.reviewsce.com/events for any meeting schedule changes or updates.

Do You Follow These **FITTING PRINCIPLES?**

Supplementing the clinical experience with fitting guides will help you keep your custom contact lens patients happy.

By Shalu Pal, OD

In optometry school, we learn the basic fitting principles of both soft and gas permeable (GP) lenses. While the methods for fitting various types of contact lenses and evaluating the lens parameters may vary from school to school, the underlying basic tenets are the same: focus on the fit, vision and comfort of the lens. Only once we are satisfied with all three components and we know we are not doing any harm to the cornea should we finalize our contact lens prescription parameters.

In addition to the clinical wisdom shared during our schooling and in subsequent years of practice, manufacturers also provide guidelines on how we should begin the fitting process and evaluate and modify the fit of the specific lens. These fitting guides often provide unique insights into the products that contact lens fitters uncover during beta testing, which can save significant chair time during the fitting process.

With this information at our disposal, we must decide when to use these guides to help us with our fits and when to rely on the common practices learned in school and in the clinic. The answer, more often than not, depends on the lens design we

choose for our patient and our knowledge base of that lens.

SOFT CONTACT LENSES

Several soft lens modalities exist, each with its own fitting principles:

Sphere and toric lenses. Most would agree that our schooling and clinical acumen allow us to fit all soft sphere and toric lenses on the market with relative ease, as the fitting process is quite simple and requires few follow ups. Manufacturers still provide fitting guides with all of their lenses explaining the basic principles of lens insertion, removal, assessment and prescription evaluation. When troubleshooting a patient complaint, we may turn to these resources to remind us of the type of prism design used in toric lenses or available base curve options.

- **Clinical pearl:** Contact lens fitters suggest, when fitting Dailies Total1 spherical lenses (Alcon), erring on the side of more plus and, when dealing with prescriptions higher than -3.00D, starting with a lens that is 0.25 less minus than what you would normally select.

Multifocal lenses. When multifocal contact lenses were first launched, optometrists fit them based on logical optical expecta-

tions. If a distance issue existed, clinicians simply added more minus. If a near issue was causing concern, a higher add power was needed. These simple principles, unfortunately, do not necessarily apply to the more complicated multifocal lenses of today.


Because each of today's multifocal designs is a unique and complex pattern, it is important to use a fitting guide that provides a multitude of insights gained from fitters and lens designers on how to properly fit and troubleshoot each lens based on the specific design. These fitting guides can help you save a significant amount of time and frustration by simplifying the process. The biggest mistake we can make is not following the fitting guide.

The basic steps to fit multifocal contact lenses are:

ABOUT THE AUTHOR



Dr. Pal runs a specialty contact lens and dry eye practice in Toronto. She is chair of the AOA Contact Lens and Cornea Section Council, a member of the Women's Advisory Board for Alcon and a speaker for Allergan's dry eye faculty in Canada. She is a consultant for Alcon, Allergan, Bausch + Lomb, CooperVision, Johnson & Johnson Vision Care and Menicon, as well as a facilitator of the STAPLE lens fitting workshops.



An assortment of fitting guides is available to help achieve the best possible comfort for your patient.

1. Perform a 'least minus, least add' refraction for your patient.
2. Determine eye dominance.
3. Choose your modality, lens brand and grab your fitting guide.
4. Choose your initial lenses based on the fitting guide and your spherical equivalent vertex refraction and add power.
5. Insert the lenses and let them settle for 20 to 30 minutes. (You can see another patient meanwhile.)

6. Evaluate binocular vision with real-world tasks at both distance and near.

7. Troubleshoot complaints with a binocular distance over-refraction to adjust the spherical component of the multifocal lens.

8. Make one change and let the patient try the lenses for a week.

9. At the follow up, perform another binocular distance over-refraction if problems exist. Follow the fitting guide to make changes to the add power of the lenses, if your patient's problem is not solved.

- **Clinical pearl:** When fitting Proclear toric multifocal lenses (CooperVision), choose the 8.4mm base curve initially for greater success. For Proclear 1 day multifocal lenses (also from Cooper), choose an initial lens that is +0.50 more plus than what the fitting guide

change at a time.

When stocking your office with the right fitting sets, most decide to stock only the lenses they use regularly. However, the reverse is also often true: if you have a fitting set for a new lens, you are more likely to use it. You can begin a fit right away and have lenses on hand to make changes.

Custom soft lenses. The same fitting strategies for disposable soft contact lenses are used when fitting custom soft lenses. However, a few things differ with respect to the fitting sets and fitting guides. Fitting sets are not customarily provided for sphere and toric lenses due to the vast parameters available and low frequency of use relative to disposable lenses.

However, soft custom multifocal and multifocal toric lenses have fittings sets you can purchase if you find that you use these lenses often enough. Lenses are typically ordered empirically with the assistance of

suggests. Our over-refractions have consistently shown a need for more plus.

- **Clinical pearl:** Keep the lights on during a multifocal fit, use real-world tasks to evaluate vision, over-refract with trial lenses (not your phoropter) and make only one

a lab consultant. An equivalent disposable lens can be helpful to test the fit of a lens prior to ordering the custom product.

Fitting guides for these lenses are most frequently used to remind us of the wide range of parameters available, as few practitioners have them memorized.

The data that you should provide your lab with to order these custom soft lenses include:

1. Keratometry readings
2. Prescription
3. Horizontal visible iris diameter (HVID)
4. Pupil size
5. Fissure size
6. Eye dominance
7. Topographies
8. Current contact lens brand, base curve and fit assessment if your patient is a current contact lens wearer.

Fitting guides provide strategies or tests to perform prior to contacting the lab for help if we run into a problem with a fit. An example is performing a keratometric reading over top of the lens or over-refracting a multifocal if vision is not acceptable to a patient.



Over-refracting the distance with both eyes open in bright illumination helps determine the most plus distance refractive correction.

DO YOU FOLLOW THESE FITTING PRINCIPLES?

HYBRID LENSES

Hybrid lenses combine the comfort of soft lenses with the exceptional optics of GP lenses. Currently, SynergEyes is the sole hybrid lens manufacturer in the United States, and the company provides several lens designs based on the type of cornea you are fitting. You can order some of their lenses empirically with their online calculators, while other designs require a fitting set. The Duette and Duette Progressive hybrid lens can be ordered empirically. You will need keratometry readings, a manifest refraction and the HVID. The other lenses in the hybrid portfolio should be fit with a fitting set.

The fitting sets, along with the fitting guides and training videos, are a great resource to learn how to fit these lenses. It's difficult to deviate from this learning structure in the beginning but, as you become more familiar with these lenses and how changing the base curve, sagittal height or skirt size impacts the overall fit, you will be able to choose a different starting point within the fitting set based on the topographies of your patient's eye profile.

Duette Empirical Lens Calculator

Enter Keratometry Readings (D or M):

Eye	Flat	Steep	HVID(mm)
OD	0.00	0.00	0.00
OS	0.00	0.00	0.00

Choose Lens Type (Choose one):

- Duette with Tangible Hydro-PED
- Duette Progressive with Tangible Hydro-PED

Account Number: _____

Patient First Name: _____

Patient Last Name: _____

Enter Manifest Refraction: S or - cyl

Eye	Sph	Cyl	Axis	Add
OD				0.00
OS				0.00

Recommended Duette Lens:

Eye	Base Curve	N/A	Power	OAP	Skirt Height	K.4 (Rate)	ADD
OD							0.00
OS							0.00

Base Curve not selected, Call Consultant 1-877-732-2912. Power outside offered range.

Calculated lens zones, base curve, skirt curve and zones are provided as a guideline only. Practitioner is responsible for choosing final lens parameters.

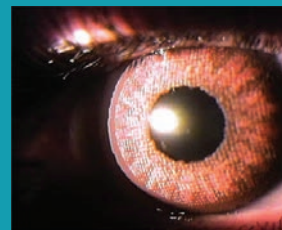
- Duette Progressive Center Distance Zone size will equal photopic pupil size minus 1.00mm. Photopic = room lights on
- HVID is not provided, and radius should be 10.00mm.
- Duette K.4 Flat only
- Duette Progressive K.4 (Skirt) only
- EP: all-norm center thickness.

N/A: Parameter Not Available

To order Duette or Duette Progressive hybrid lenses empirically, you can use the Duette online calculator.

Prosthetic Lenses

When fitting prosthetic colored contact lenses, fitting sets and fitting guides are particularly helpful. With them, you can demonstrate and perfect the color choice and meet the patient's expectations. Matching the non-affected eye is most often the patient's primary concern. Fitting guides allow you to understand the level of layering and complexity of coloring at your disposal to build the perfect prosthetic.



This custom prosthetic lens helped reduce glare and achieved 20/20 vision for the patient.

If changes need to be made to the diagnostic lens, a call to consultation can be very helpful until you become accustomed to the changes you can make to the available parameters.

Clinical pearls:

- When using the fitting set, start with the 250 medium skirt lens.
- The lens will settle and should be evaluated after three to four hours of wear in order to assess height.
- Medium skirts fit best with small corneas, and flat skirt fit best with large corneas.
- The multifocal lens design has both center near and center distance. The center distance design can be used for myopia control.

GP LENSES

These lenses are fully customizable, with specific curve, width, diameter and thickness. Many GP lens designs also come with pre-set parameters to aid in the fitting process. Clinicians have three different methods for properly designing a custom GP lens:

Formulas. We can design a bicurve, tricurve or tetracurve lenses, based on formulas and expected curves or we can use a fitting set. A fitting set chooses the parameters for you based on the lab's design of choice. Your job is to find the best matching lens and make small modifications to it to match your patient's needs.

When designing a lens from scratch based on lid anatomy, you need to decide if you are going to fit a lens that is lid-attached or fits interpalpebral. The method you choose will determine how to build your lens. Lid-attached lenses are fit larger and flatter, and interpalpebral lenses are fit smaller with a steeper base curve. Choose base curves and widths of the secondary, tertiary and quaternary curves yourself or you can use default standards that your lab provides. A great resource you can take advantage of to learn how to design GP lenses from scratch is *The Manual of Gas Permeable Contact Lenses, 2nd Edition*.

Empiric. You can also order GP lenses empirically, by giving the topographies, keratometric values, pupil sizes, iris diameters, lid positions, fissure heights and refractions to a lab consultant who then designs the lens for you.

Fitting sets. Many manufacturers provide a fitting set and corresponding fitting guide for their GP lenses. The fitting set will allow you to see the lens on the eye and determine any necessary lens adjustments. Because of the complexity and proprietary nature of lens designs, you may not know all of the specific parameters of a given lens, requiring you to rely on the fitting guide to help you understand the impact of the fitting process.

SCLERAL LENSES

As interest in these lenses grows, so does our refinement of fitting techniques and processes. When sclerals first hit the market, little could be done to modify their fit. Optometrists who continue to fit scleral lenses as they advance have learned how to fit them with each new breakthrough. With the use of available fitting guides, the learning curve is much smaller than it once was.

Despite having significant experience with scleral lenses, fitting sets and fitting guides are a must when learning about new products. They provide step-by-step instructions on how to fit a lens, evaluate each fitting curve and make any possible changes to the curve, power and diameter.

When fitting scleral lenses communication to help ease fear is the first and most important step to success. Insertion and removal is often the reason why patients fail with scleral lenses. Make sure to master this so you are able to teach your patients. Fit the lens first (sagittal height, limbal clearance and edge design) before you worry about optics.

The lens will rotate, and optics will change as you change the lens. Work with the sphere power of the prescription only until the



A scleral lens diagnostic fitting set, such as this one for the Valley Contax Custom Stable Elite, can help any practitioner learn more about on-eye performance of the final lens ordered.

fit is complete, and then do a final spherocylinder over-refraction to finalize the prescription. Do not add cylinder to the scleral lens unless there is a significant change in vision.

With these lenses, a single change to one curve can have a huge impact on all of the lens curves. Thus, you need to know the fitting properties of the landing zone, limbal zone and base curve and how changes to each will impact the others. The increments of change that are possible for each zone are important to know. Your lab consultant or the fitting guide will provide you with these vital pieces of information that will help you understand the lens design and achieve success with these specialty lenses.

Unique scleral lens features include quadrant-specific designs, toric peripheral curves, front toric prescription options, multifocal front surface designs, notching and micro-vaulting capabilities. Each of these specific

designs comes with their own fitting challenges, which can be alleviated by using the fitting guide or consulting with your lab. Understanding the modification options that your scleral lens brand has and the parameters for those modifications is the first step. If you have residual astigmatism in your refraction, you can add a front toric design to most scleral lenses on the market. We are using more toric peripheral curves these days because the sclera is more irregular the further you move away from the limbus. Toric peripheral curves help align the lens to the sclera.

Principles for multifocal lens designs apply to scleral lenses as well. Each company has their own method for choosing their starting design based on your refraction. Methods to adjust powers based on complaints can be found in their fitting guides. Notching and micro-vaults are great options to avoid filtering blebs and pingueculas.

Clinicians who order scleral lenses empirically with the assistance of a corneo-scleral imaging topographer may not need a fitting set and fitting guide.

Your knowledge and fitting experience with a particular lens modality determines the extent to which you need to use a fitting guide, if at all. When working with a new product, the corresponding guide helps you achieve efficiency in the fitting process and learn how to maximize the benefits of the new lens. As your comfort level widens, you may find yourself deviating from the fitting guide to experiment and pushing boundaries to try to solve a patient's complex issue. **RCCL**

The Ins & Outs OF WAVEFRONT ABERROMETRY

Combining this technology with corneal topography and medical imaging can help optometrists successfully manage their specialty contact lens patients.

By Thomas A. Wong, OD, and G. Timothy Petito, OD

Irregular astigmatism, often seen in corneal ectasia, can cause significant visual distortion in patients. The most common primary ectasia—keratoconus—presents challenges for eye care providers and patients alike.¹ To help meet these challenges head-on, wavefront aberrometry, corneal topography and medical imaging (e.g., pupillometry) have proven effective in the early detection and management of corneal ectasia, especially keratoconus. In addition to increasing our knowledge of refractive error, these technologies allow doctors to better understand the pathophysiology of different

conditions and how to improve patient outcomes with specialty contact lenses. Accumulating patient data with these instruments may also give us an opportunity to learn more about the prevalence and impact of certain conditions.

This article, adapted from a SpecialEyes blog post, discusses the benefits of modern wavefront aberrometry.² This powerful tool can aid in detecting and managing many corneal conditions as well as in evaluating patients for soft multifocal contact lenses to relieve them of the challenges they face living with associated diseases.

Note: one of the authors has an industry affiliation and will be using a particular product to illustrate various concepts, but the advice is often broadly applicable using other technologies as well.

ABERROMETRY AND ABERRATIONS

Wavefront aberrometers analyze the findings produced by optical systems using three distinct methods.

Based on these methodologies, clinically available instruments can be divided into three classifications: outgoing wavefront aberrometers (e.g., the Hartmann-Shack wavefront sensor), ingoing retinal imaging aberrometers (e.g., the Tscherning aberrometer) and ingoing feedback aberrometers (e.g., the Marco/Nidek Optical Path Difference (OPD)-Scan III). The devices belonging to these three categories differ based on their measurement speed, refractive error range, analysis and display

ABOUT THE AUTHORS

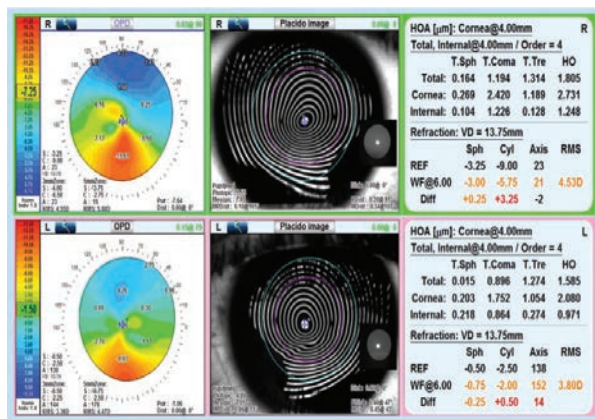


Dr. Wong is an associate clinical professor, director of new technologies and director of clinical externships at the SUNY College of Optometry.

He is on the Board of Governors at Georgetown University, a consultant for Marco Ophthalmics, an AOA representative to the Physician Consortium for Performance Improvement (PCPI) and on the PCPI Technical Expert Panel.



Dr. Petito is an author and a lecturer on various topics related to ocular care. He practices in St. Petersburg, FL, and specializes in complex contact lens and low vision patients. He is the primary AOA representative to the PCPI, on the PCPI Technical Expert Panel and the Director of Professional Relations for Marco Ophthalmics.



OPD aberrometry of the right and left eyes shows inferior steepening consistent with keratoconus. Placido disc imaging shows distortion of the mires consistent with primary corneal ectasia. HOAs with large amounts of corneal and internal coma are present, representing aberrations that extend to the posterior cornea.

options and ability to measure different aberrations. While these tools have their differences, all are more successful and provide more information when combined with other technologies (e.g., topography and medical imaging).

Carefully analyzing integrated wavefront aberrometry results can be useful in obtaining a detailed analysis of the optical pathway from the pre-corneal tear film to the vitreous humor and the retina. Characterizing the optics by the type and location of aberrations that are occurring allows clinicians to detect, diagnose and treat conditions that have optical consequences at every stage of development in an effort to reduce optical consequences. It can help also clinicians better understand contact lens and specialty contact lens interactions

with the entire optical system, not just the corneal surface.

The most important information added to a clinician's data stream with the use of integrated wavefront aberrometry is in regard to higher-order aberrations (HOAs) and the physiological alignment of the optical elements of the system.

The two most common HOAs in healthy eyes are vertical coma and spherical aberration.³ Diseases or conditions that affect the optical components of a patient's eye, including ectasia, can cause HOAs, such as trefoil, tetra-

foil and secondary astigmatism, which are located on the front or back surface of the cornea. Cataracts—often in very early stages—can be accompanied by high levels of trefoil due to the internal optics of the lens.

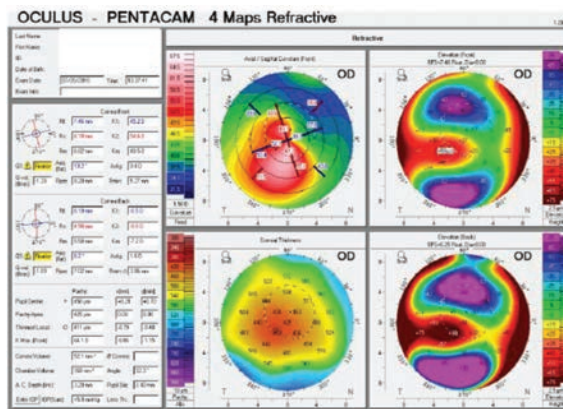
Analyzing HOAs helps differentiate conditions, such as keratoconus and pellucid marginal degeneration (PMD). In both, the mean axes of the coma are opposite those in healthy eyes.⁴ However, the magnitude of the coma is significantly lower in PMD than in keratoconus. Further setting the

two conditions apart, spherical aberrations in eyes with PMD have a plus sign while these aberrations in eyes with keratoconus have a minus sign.

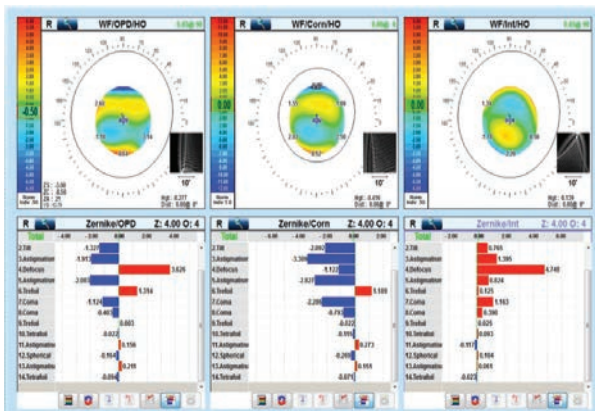
ANGLES KAPPA AND ALPHA

While wavefront aberrometers show us the characteristics of the total optics of the eye, they do not allow us to understand the functional consequences of each specific optic location and, thus, have limited value in evaluating patients for contact lenses. However, combining aberrometry with corneal topography, and pupillometry allows us to assess the physiological alignment of the optical structures in the eye, locate HOAs and lower-order aberrations in the optical pathway and analyze the effects of pupil size, which affects the angular aperture of light entering the posterior part of the eye.² Furthermore, the larger diameter analysis of refractive error helps us decide which contact lens to choose during a patient's evaluation.

Research into refractive surgery shows us that centering laser-ablation treatment zones over the pupil can be problematic for patients with large angle kappas—the angle between the visual axis and the

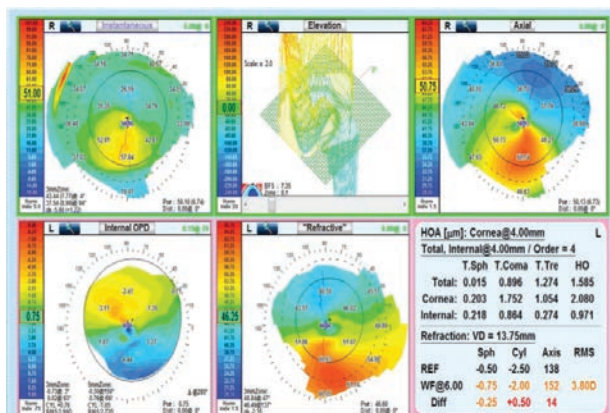


Oculus Pentacam refractive maps of the right and left eyes show adequate corneal thickness (>400 microns) and evidence of keratoconus in both eyes.



OPD aberrometry of the right and left eyes shows vertical coma often seen in patients with keratoconus.

THE INS AND OUTS OF WAVEFRONT ABERROMETRY



OPD elevation maps show an elevation, axial and instantaneous map in the right eye of this keratoconus patient.

pupillary axis—due to significant discrepancies between the axes.² A large angle kappa or angle alpha—the angle between the optical axis and the center of the cornea—can also present challenges when fitting patients with multifocal intraocular lenses.²

Combining corneal topography and wavefront aberrometry allows these devices to evaluate the distance between the pupillary center and the visual axis.² Many doctors rely on fixation patterns to estimate the location of the visual axis. Use of a device capable of finding the longest light ray (the optical axis) helps to identify the visual axis.² The device then calculates the distance and the angle from the optical axis to the center of the pupil under photopic and mesopic conditions.² It also identifies the limbus, locates the geometric center of the limbal ring (the cornea) and calculates the angle alpha.²

Contact lenses are usually centered or nearly centered on the cornea.² The closer the center of a lens is to the optical axis, the more symmetric the combined power distribution is around the optical axis.² The further the center of a lens is from the optical axis, however, the more asymmetric the

combined power distribution is around the optical axis.² This asymmetric power distribution creates HOAs, particularly coma, and results in negative visual symptoms.²

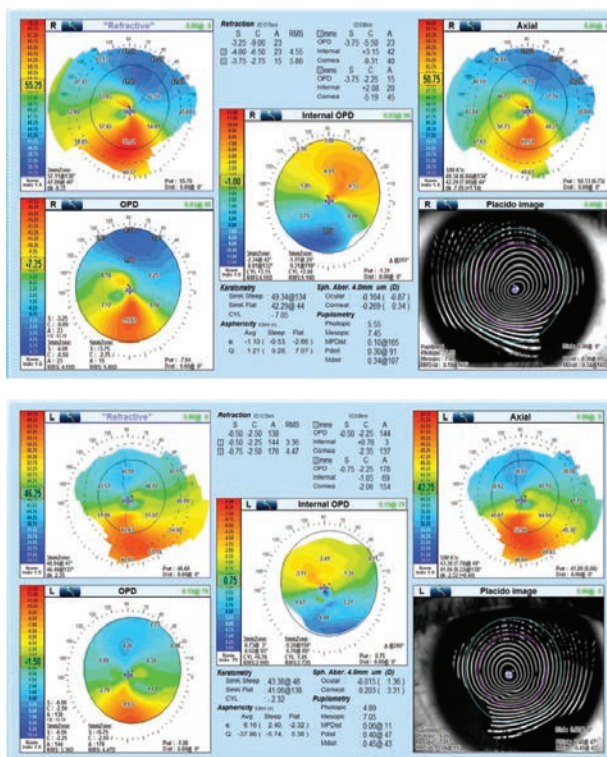
MULTIFOCAL FITS

When considering the large curvature change

and power distribution associated with soft multifocal contact lenses, success depends on the alignment of the multifocal optics with the visual axis.² Misalignment alters the way patients perceive visual clues and may occur for several reasons, including scleral or corneal misshape, nasal decentration of the pupil and/or temporally displaced foveas.² A significant misalignment can be problematic and may result in reduced visual acuity, induced aberrations and patient complaints of glare, shadows, 3D effects and halos.² Unfortunately, the conventional method of fitting soft multifocal contact lenses does not ensure appropriate alignment of multifocal optics over the visual axis, leading

to unsuccessful fits and unhappy patients.²

To investigate how often contact lenses decenter and whether the decentration is consistent or variable, researchers have employed corneal topographers to measure the surface profile of four different brands of similarly designed soft multifocal contact lenses.² After analyzing the topography maps of the soft multifocal contact lenses worn on-eye, a team found that the optical zones of the lenses were consistently displaced temporal to the visual axis.² They note that the misalignment amount among 18 patients varied from 0mm to 1.25mm temporally.² Another group discovered similar results, with an average misalignment of 0.78mm temporally among 63 eyes.² These studies found that lenses often decenter temporally to a variable amount.²



Internal OPD aberrometry of the right and left eyes shows refractive distribution mapping that illustrates refractive irregularities inferior central in both eyes.

MISALIGNMENT MANAGEMENT

Clinicians can evaluate misalignment between the multifocal optics and the visual axis by comparing the corneal topography of a patient without soft multifocal contact lenses with the corneal topography of the patient with soft multifocal contact lenses.² To effectively make this comparison, use the topographer's "difference display" map setting, which is also known as "subtractive" or "comparative" maps.² The topographer will then subtract the map taken over the contact lens from the baseline map of the patient's bare cornea to provide valuable information about the multifocal optics.²

The process looks like this:²

1. Perform baseline corneal topography without a contact lens.
2. Place a soft multifocal contact lens on the eye, preferably one with a high add power to enhance the view of the central optics when examining the topography results.
3. Allow the contact lens to settle in order to ensure good centration and proper lens alignment. If the lens does not fit well, choose another and start over.

4. Perform corneal topography while instructing the patient to view the proper fixation target.

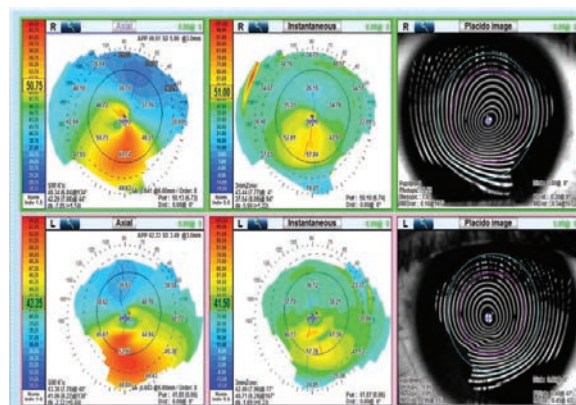
5. Display the maps in tangential power. Depending on the topographer make and model, the function may be labeled "tangential," "curvature" or "instantaneous."

6. Use the topographer's difference display or subtractive or comparative functions. The option will either appear as three topographic maps on the same button or on a dropdown menu reading "diff," "refractive compare" or "power difference."

7. Select the baseline map and the topographical map taken over the contact lens (both in tangential and instantaneous power) to produce a third "tangential power difference" map. A difference/comparative/subtractive map will also be generated next to the baseline and over-contact lens maps.

8. Adjust the color display scale on the difference map to highlight the power profile in the optical zone of the contact lens.

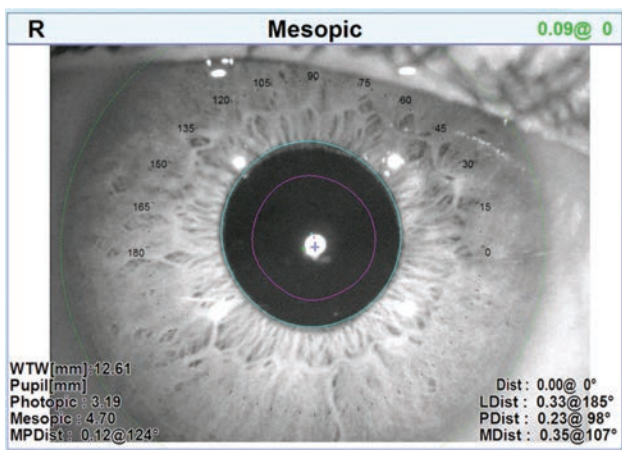
9. Measure the distance between the patient's visual axis (center of the map) and the center of the multifocal optics with the measurement function. If the



OPD corneal topography shows the axial or anterior corneal topography and the instantaneous or tangential topography.

distance is measured at 0.50mm or more, consider using offset optics.

Information regarding the aberration profile created when decentered soft multifocal contact lenses interact with the rest of the optical system is clinically predictive of success and helps doctors determine the fitting methodology they should employ for each patient but cannot be gathered using one technique alone. Integrating wavefront aberrometry with corneal topography and medical imaging can be valuable in helping doctors identify patients with irregular astigmatism who require specialty contact lenses. Early detection and diagnosis of conditions affecting a patient's optical system allow doctors to swiftly initiate examinations and fittings to successfully manage patient symptoms and improve visual performance over time. **RCCL**



The OPD-Scan III can take angle kappa and angle alpha measurements as well as photopic and mesopic measurements.

1. Vinciguerra R, Ambrósio Jr. R, Elsheikh A, et al. Detection of keratoconus with a new biomechanical index. *J Refract Surg.* 2016;32(12):803-10.
2. SpecialEyes. Three ways to identify multifocal misalignment issues. specialeyesqc.com/blog/identify-multifocal-misalignment-issues/. Published August 20, 2018. Accessed September 20, 2018.
3. Legerton J. Is wavefront aberrometry a good fit for contact lens practice? *RCCL.* 2013;150(8):24-6.
4. Kosaki R, Maeda N, Bessho K, et al. Magnitude and orientation of Zernike terms in patients with keratoconus. *Invest Ophthalmol Vis Sci.* 2007;48:3062-8.



**Jennifer
Lyerly, OD**

Triangle Visions
Optometry,
Cary, NC

Dr. Lyerly was compensated
by Alcon for her participation
in this advertorial.



SUCCESSFUL THE KEY

Practicing in North Carolina's Research Triangle area, I see a lot of patients with high visual demands: scientists, engineers, and business people who spend long hours in the lab or office, using computers and other digital devices. With daily life involving more and more computer time for everyone, these kinds of visual demands are increasingly common, even among my younger patients. I recently examined a preschool teacher in her early 20s who presented with 20/20 uncorrected eyesight, but complaints of headaches and eyestrain. She had no previous vision correction history,

of her young students in the classroom. And with Alcon's toric soft contact lens portfolio, I knew that I had truly unique lenses with the technology and design to support the kind of vision and comfort she deserves.

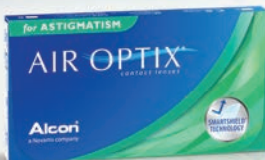Providing the best contact lens-wearing experience possible means prescribing lenses that combine the right material, surface technology, and design to meet our patients' individual needs. This is particularly important for astigmats — they need their contact lenses to help support tear film stability to stay comfortable all day long, but also remain stable on their eyes for clear vision,

Alcon's Dual Stability. Different lens materials have different physical properties, and therefore require different toric designs to maximize on-eye stability. Alcon toric contact lenses merge unique materials, surface technologies, and toric designs to support tear film and rotational stability.⁶⁻¹⁴

Tear Film Stability



Blink-Activated Moisture features the release of PVA with every blink to support tear film stability.⁶⁻⁸



SmartShield® Technology resists deposits and supports tear film stability.¹⁰⁻¹³



On-Eye Stability



PRECISION CURVE® Design is a dual thin zone design that allows both eyelids to apply equal pressure to keep the lens in the correct orientation



PRECISION BALANCE 8|4® Design is a modified prism-ballast design that has two anchor points for stabilization



but examination revealed that she was a low astigmat, which helped explain her visual symptoms. It's more than just professionals with computer jobs that are bothered by low amounts of prescriptions and digital eye strain - as a preschool teacher she is using computers and tablets more and more when instructing her students in the classroom. When I told her that contact lenses could help, she was clearly intrigued since she had never needed to wear glasses before and was apprehensive about going into spectacle wear with the active demands

no matter what they are doing.¹⁻³ Unfortunately, this dual need often goes unmet. Astigmats commonly cite discomfort, dryness, and vision problems as reasons for discontinuing contact lens wear.⁴

I fit Alcon toric contact lenses on my patients because they combine unique materials and optical designs to support the tear film stability and rotational stability that I look for in a toric lens. This Dual Stability is essential to my astigmatic patients' lens-wearing success.

Important information for AIR OPTIX® for Astigmatism (Iotrafilcon B) contact lenses: For daily wear or extended wear up to 6 nights for near / far sightedness and astigmatism. Risk of serious eye problems (i.e., corneal ulcer) is greater for extended wear. In rare cases, loss of vision may result. Side effects like discomfort, mild burning or stinging may occur.

References 1. Craig JP, Willcox MDP, Arguoso P, et al. The TFOS International Workshop on Contact Lens Discomfort: report of the contact lens interactions with the tear film subcommittee. *Invest Ophthalmol Vis Sci.* 2013;54:TFOS123-TFOS156. 2. Lindsay R. Soft Toric Lens Design and Fitting. In: Efron N, ed. *Contact Lens Practice.* Philadelphia, PA: Elsevier; 2018:95-102. 3. Epstein A, Remba M. Hydrogel toric contact lens corrections. In: Bennett E, Weissman B, eds. *Clinical Contact Lens Practice.* Philadelphia, PA: Lippincott Williams & Wilkins; 2005:515-548. 4. Multi Sponsor Surveys Inc. The 2014 Gallup target market report on the market for toric contact lenses. August 2014. 5. Mann A, Tighe B. Contact lens interactions with the tear film. *Exp Eye Res.* 2013;117:88-98. 6. Pruitt J, Lindley K, Winterton L. Triple-action moisturisers for increased comfort in daily disposable lenses. *Optician* 2007;11:27-28. 7. Marx S, Muller C, Sickenberger W. Subjective pre-lens tear film stability of daily disposable contact lenses using ring mire projection. *Cont Lens Anterior Eye.* 2015;38:e5.

CONTACT LENS WEAR IN ASTIGMATS IS DUAL STABILITY

A stable tear film promotes ocular health, clear vision, and comfort,⁵ while rotational stability keeps the correcting cylinder of a toric lens at the appropriate axis during wear. There is also an important link between these two forms of stability — toric lenses interact with the eyelid to ensure correct positioning on the eye,³ but lens surface dryness resulting from tear film breakup can increase friction between the eyelid and lens, leading to unwanted rotation or oscillation with blinking. A stable tear film therefore plays an important role in on-eye toric lens stability.³

Alcon toric lenses provide the Dual Stability required to meet the needs of today's astigmatic patients, no matter what their lifestyle needs. For astigmats who are candidates for daily disposable contact lenses, I recommend DAILIES® AquaComfort Plus® Toric contact lenses. With Blink-Activated Moisture, DAILIES® AquaComfort Plus® Toric lenses release the hydrophilic polymer polyvinyl alcohol (PVA) with every blink to support tear film stability,^{6,8} while the PRECISION CURVE® lens design supports stable on-eye performance.⁹ For patients better suited for monthly replacement lenses, AIR OPTIX® for Astigmatism lenses combine Smart-Shield® Technology to resist deposits and support tear film stability¹⁰⁻¹³ and the PRECISION BALANCE 8|4® lens design for rotational stability and excellent visual acuity.¹⁴

Fitting toric contact lenses also presents an important opportunity for practices. Nearly 50% of

people have astigmatism of 0.75D or greater in at least one eye,¹⁵ making a large proportion of our patients potential candidates for toric contact lenses. Studies show leaving even low amounts of astigmatism uncorrected is associated with much higher rates of contact lens drop out. In my experience, patients who wear contact lenses return more frequently for exams,¹⁶ providing more opportunities for comprehensive eye care — generating more practice revenue. Most importantly, with the Dual Stability of Alcon toric contact lenses, I know that I am setting my patients up for success. Like many other astigmats I see in my practice, wearing DAILIES® AquaComfort Plus® Toric contact lenses gave my young symptomatic patient the chance to enjoy the vision and comfort she deserves!



8. Wolffsohn JS, Hunt OA, Chowdhury A. Objective clinical performance of 'comfort enhanced' daily disposable soft contact lenses. *Cont Lens Anterior Eye*. 2010;33:88-92
9. Alcon data on file, 2010. In a subject-masked clinical trial (n=93). 10. Guillon M, Maissa C, Wong S, et al. Tear film dynamics over silicone hydrogel contact lenses with different lipid deposition profiles. *Optom Vis Sci*. 2014;91:E-abstract 145196. 11. Nash W, Gabriel M. Ex vivo analysis of cholesterol deposition for commercially available silicone hydrogel contact lenses using a fluorometric enzymatic assay. *Eye Contact Lens*. 2014;40:277-282. 12. Nash W, Gabriel MM, Mowrey-McKee M. A comparison of various silicone hydrogel lenses; lipid and protein deposition as a result of daily wear. *Optom Vis Sci*. 2010;87:E-abstract 105110. 13. Lemp J, Kern J. On-eye performance of lotrafilcon B lenses packaged with a substantive wetting agent. Presented at the American Optometric Association Annual Meeting, June 21-25, 2017, Washington, D.C. 14. Alcon data on file, 2005. In a randomized, subject-masked, multi-site clinical study with over 150 patients; significance demonstrated at the 0.05 level. 15. Young G, Sulley A, Hunt C. Prevalence of astigmatism in relation to soft contact lens fitting. *Eye Contact Lens*. 2011;37:20-25. 16. Dumbleton K, Richter D, Bergenske P, Jones LW. Compliance with lens replacement and the interval between eye examinations. *Optom Vis Sci*. 2013;90:351-358.

MAKING SENSE OF Scleral Lens Materials

With so many options on the market, it's hard to make the right choice for each patient. *These tips can help.*

By Justin Manning, OD, MPH

There is no lack of information on fitting and troubleshooting scleral lenses, as well as advertisements for new soft contact lens materials and parameters. But the same cannot be said for specific gas permeable (GP) materials. ODs also have a wide array of lens materials at their disposal in this modality, but many may not know how to select the best option for their scleral lens patients, especially with the significant increase in their use for both irregular and normal corneas. This article discusses how ODs can improve their scleral lens fittings with a better understanding of lens material choices.

GENERAL PRINCIPLES

Compared with corneal GPs, scleral lenses create a semi-seal around the conjunctiva and sclera, which limits tear exchange underneath the lens. This can result in reservoir fogging, a primary complication of an improperly fit scleral lens.¹ Because of the limited tear exchange, oxygen to the cornea must come via transmission through the lens and the tear reservoir itself. Thus, one of the most important lens parameters is the material's oxygen permeability, or Dk value. For scleral lenses, a high Dk lens

material is required, with greater than 100 to 150 being ideal.^{2,3}

When it comes to oxygen transmission, high Dk is only one piece of the puzzle. We can also control oxygen transmissibility through adjusting the center thickness of the scleral lens. Thicker lenses hinder oxygen transmission across the lens, while thinner lenses make oxygen transmission easier. According to theoretical models, a center thickness between 250 μ m to 400 μ m is ideal to prevent or limit corneal hypoxia.³ When designing center thickness, we must be careful to avoid lens flexure and the induction of residual astigmatism in a lens that is too thin. High oxygen transmissibility is especially important in more advanced corneal ectasias and in patients with corneal grafts. These compromised corneas require high levels of oxygen to prevent further endothelial degradation and risk of graft rejection. In addition, we also must be cognizant of oxygen transmission in older patients due to natural endothelial loss with age.

Other important characteristics in the consideration of scleral lens materials include wetting angle and refractive index. Many ways to measure wetting angle exist, making comparison across lens ma-

terials difficult. Generally speaking, a lower wetting angle corresponds to better lens wettability, although this does not always correspond to better lens wetting when on the eye. In theory, better wetting results in less transient dry spots on the contact lens surface. This increases the risk for anterior surface deposition, especially in patients with dry eye disease.

Anterior surface deposition must be differentiated from deposition on the back surface of the lens, which is most prevalent when an incomplete seal around the scleral haptic exists. This is also more common in patients with dry eye.

To help prevent anterior surface fogging and deposition, clinicians should consider the wetting angle when selecting a contact lens material. In general, we start patients in lens materials that have a good balance between high Dk and low

ABOUT THE AUTHOR



Dr. Manning is the founder and optometric medical director of the Keratoconus and Scleral Lens Institute at Bettner Vision, a specialty contact lens practice in Colorado Springs, CO. He has a passion for fitting scleral lenses and has taught internationally in contact lenses.

wetting angle to provide consistent oxygen transmissibility and low risk of anterior surface deposition.

The refractive index of most lens materials ranges from 1.3 to 1.5, which typically matters more in large prescriptions for patients with corneal complications such as severe keratoconus. Just as in a pair of glasses, clinicians should consider a higher refractive index in higher plus or minus prescriptions to keep the lens thinner.⁴

TODAY'S LENS OPTIONS

Many new GP lens materials have made their way into clinical practice in recent years, all of which provide certain benefits to scleral lens patients:

Roflufocon A-E (Optimum, Contamac) is a family of low- to high-Dk lens materials made of fluorosilicone acrylate (Figure 1). Roflufocon A and C are not used in scleral lens wear due to their low Dk values of 26 and 65, respectively. Roflufocon D, marketed as Optimum Extra, is a good starting material for most scleral lens patients, with its low wetting angle of 3 degrees (Dynamic Contact Angle) and high Dk of 100. Roflufocon E,

labeled Optimum Extreme, has a Dk of 125 and a wetting angle of 6, making it a better choice for higher prescriptions or lenses requiring greater center thicknesses.⁵

Roflufocon can also be paired with the Hydra-PEG (Tangible Science) coating to help improve comfort for patients with dry eye disease, surface wettability problems and those with significant lipid and protein depositions.

Hexafocon A (Acuity 100, Acuity Polymers; Boston XO, Bausch + Lomb) has a higher wetting angle than roflucon at 23 and may potentially be less wettable, but is still a good choice for any scleral lens wearer due to its high DK of 111.⁶

While not pertaining directly to scleral lens wear, a 2015 study in rabbits showed the lack of inflammation, epithelial or stromal thickening and neovascularization of hexafocon A when used as a stromal inlay.⁷

Hexafocon B (Boston XO2, Bausch + Lomb) is a well-known GP material with a Dk of 141, making it a good option for scleral lens wear. However, it has a high wetting angle of 38 degrees.⁸

A recent case series of overnight wear of Prose lenses in Boston XO₂ for persistent epithelial defects showed complete resolution of the defects and the oxygen permeability had no negative effects on corneal health.⁹

For patients with higher oxygen needs, Boston XO₂ should be among the first considered. Its higher wetting angle may pose a greater challenge for those with dry eye disease

compared with roflufocon D and E or hexafocon A, although this may be mitigated through the addition of Hydra-PEG.¹⁰

Hofococon A (TYRO-97, Lagado Corporation) is a go-to material for patients with wetting and depositing issues. It has a slightly lower Dk at 97 and a wetting angle of 23 degrees. According to the company, the surface of the fluorosilicone acrylate material is hydrophilic, which increases wettability and lubricity beyond other materials with similar wetting angles.¹¹

Despite having a Dk lower than 100, a study of new miniscleral lens wearers showed an average corneal edema of 1.51% after five hours of wear. Interestingly, this lack of edema was independent of post-lens tear thickness.¹² Switching patients that have a tendency to deposit to a hofococon A lens material is often a quick fix while managing their dry eye and anterior surface disease.

Tisilfocon A (Menicon Z, Menicon) was the first GP material FDA approved for continuous wear up to 30 days. It has the highest Dk of all GP materials at 163 and a polymer structure of siloxanylstyrene, fluoromethacrylate and benzotriazol UV blocker, makes it different than most fluorosilicone acrylate GP materials.¹³

It has a slightly higher wetting angle than others of 24 degrees after soaking the lens. Tisilfocon A is used extensively in overnight wear for orthokeratology and corneal GPs. In corneal lenses, an evaluation of 21 rigid GP wearers showed no corneal endothelial morphology changes after a year of nearly continuous wear.¹⁴

While overnight scleral lens wear is still not recommended, it is showing significant potential for the treatment of ocular surface diseases such as persistent corneal epithelial erosion, Stevens Johnson

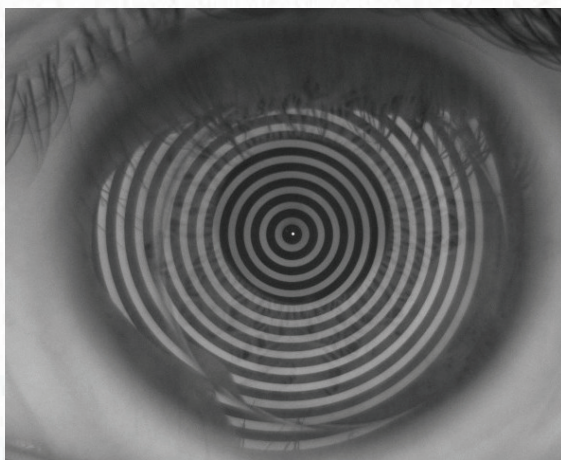


Fig. 1. Passive topographical analysis of tear break-up time shows a well-maintained tear layer over an untreated roflufocon scleral lens after more than 15 seconds.

MAKING SENSE OF SCLERAL LENS MATERIALS

disease, exposure keratitis and post-radiotherapy keratopathy.¹⁵ One study found no adverse effects of overnight wear of GP scleral lens in four healthy volunteers on four different occasions. Corneal edema ranged from 4.9% to 17.5% and was highly correlated with endothelial count density.¹⁶

When considering overnight scleral lens wear, clinicians must first weigh the risk of hypoxia against the benefit of the 24-hour hydration of the anterior segment. If overnight scleral use for ocular surface disease management is the chosen management strategy, tifocon A is the best lens material due to its hyper Dk properties.

HONORABLE MENTION

Onsifocon A (ONSI-56, Lagado Corporation) is a fluorosilicone acrylate rigid silicone hydrogel material with a low Dk of 56. Clinicians should follow patients fit with this material closely to ensure they do not show any signs of corneal hypoxia or edema. Onsifocon A does, however, have a much lower wetting angle than many other GP lens materials at 7.2 degrees, making it an ideal lens material for dry eye sufferers and heavy anterior surface depositors.¹⁷

Some patients motivated to wear scleral lenses continue to deposit heavily on their lenses despite efforts to improve the quality of their lid margins, resulting in poor vision. In these situations, a lower Dk material such as onsifocon A may help patients resist deposition.

MATERIALS MATTER: CASE EXAMPLES

A high Dk material is ideal to reduce the risk of corneal hypoxia and edema due to scleral lens wear. However, some patients are such strong depositors that even the best high-Dk materials deposit quickly. In this patient's case, aggressive dry eye and ocular surface management coupled with scleral lens material changes were key to decreasing the chance of depositing.

A 46-year-old female presented to

the clinic with visual distortion, secondary to corneal trauma, so severe that it caused intractable nausea. In the clinic, a GP lens trial removed the distortion. She was then fit in a 16.8mm Custom Stable Elite scleral by Valley Contax with a front surface toric.

This scleral contact lens design can be ordered in a multitude of materials, and we started with Optimum Extra for its balance of wettability and oxygen transmissibility. She deposited heavily on the anterior surface—an issue that improved when the lens was remade in TYRO-97. Despite manual cleaning and hydrogen peroxide-based solution, she continued to deposit on the new material within one to two days. The depositing improved significantly when switched to ONSI-56, improving the quality and stability of her vision (Figure 2).

Another patient, a 62-year-old keratoconic female sought a second opinion in our clinic due to poor success in scleral fitting at another local practice. She was refit into a 15.8mm Custom Stable Elite lens. Despite aggressive dry eye management, she deposited heavily by the end of the day in Optimum Extra lens material. She was switched to the ONSI-56, which allowed her three weeks of wear before the deposition returned. A biweekly Progent (Menicon) treatment regimen was added to resist further deposition.

Due to the material's low Dk, clinicians must pay close attention to the corneal health in patients wearing lenses of this material. Reservoir depth should be kept below 150µm whenever possible. Regular follow-ups are needed, and clinicians should educate patients to remove the lenses more often during the day to replenish the saline reservoir.

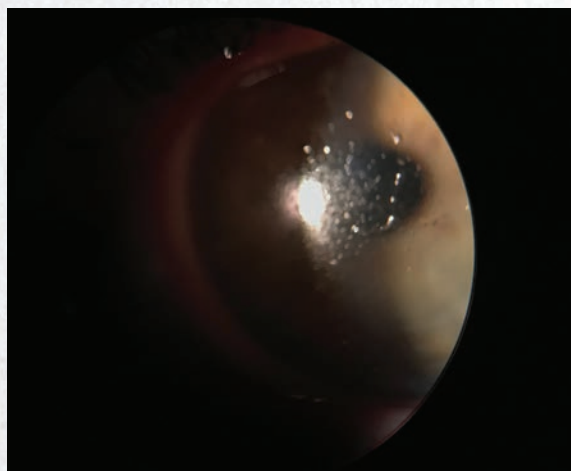
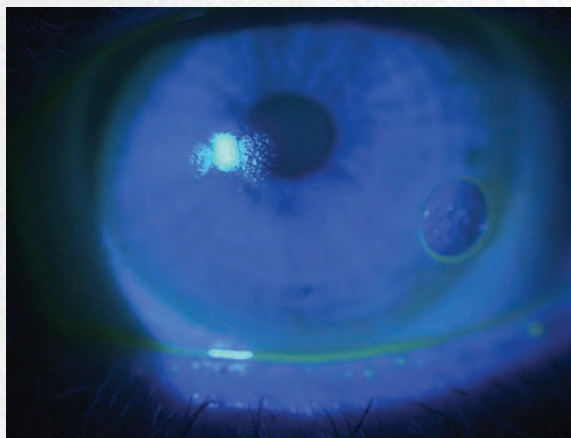


Fig. 2. This patient had anterior surface fogging and deposition while wearing hofocoon A lenses. The deposition resolved after switching the patient to an onsifocon A lens.

EXTRA PROTECTION

Hydra-PEG is a potential game changer in the specialty contact lens industry by significantly improving the wettability of a scleral lens on the eye, especially in bigger and more stationary lenses. The polyethylene glycol (PEG)-based polymer layer is covalently bonded to the lens surface—completely surrounding the front and back surface of the lens—and resists degradation often seen in plasma coatings. The PEG polymer acts as a mucin-like surface on the contact lens, significantly increasing the binding of the natural tear layers to the lens and maintaining a more intact lipid layer.¹⁸

Research shows Hydra-PEG can significantly improve wettability, lubricity and comfort in silicone hydrogel lenses. One study compared end-of-day comfort and surface quality of untreated silicone hydrogel lenses and lenses treated with Hydra-PEG. Those treated with the Hydra-PEG had both significant improvements in end-of-day comfort and improved lens surface quality after eight hours of wear.¹⁹

Research continues to evaluate Hydra-PEG-treated lenses.¹⁸ The first double-blind, randomized study of Hydra-PEG use in scleral lens wear began in January 2018. Thirty participants were randomized into wearing Hydra-PEG treated or untreated scleral lenses and were evaluated for contact lens discomfort and dry eye symptoms.²⁰ Results are currently under review.

The Optimum materials have been approved for use with Hydra-PEG for several years, and Bausch + Lomb recently announced a licensing agreement to use Hydra-PEG with its GP materials. Hydra-PEG will soon be available with Boston XO, XO₂, EO and ES in GP and scleral lenses.¹⁰

Because our practice is located nearly 7,000 feet above sea level and has an average daily humidity below 50%, Hydra-PEG greatly benefits our scleral lens patients who also have significant dry eye disease and depositing issues.

Monitoring endothelial health and corneal thickness as an indicator of corneal swelling is also important in patients wearing these lower Dk materials. Despite the added benefit of reduced anterior surface deposition, this lens material would not be recommended for those patients requiring higher oxygen needs.

Scleral lenses have become popular for the visual correction of those with irregular astigmatism, high astigmatism and normal corneas, and clinicians must be prepared to choose the right lens material for each patient. While the first fit is usually a high Dk lens with a good wettability profile, not all patients will do well with this choice. This is where a better understanding of the various lens materials on the market becomes crucial. Arming ourselves with ma-

terial knowledge will improve the success of our scleral lens fits and superior patient comfort. **RCCL**

1. Johns L. Scleral lenses 601: Advanced applications. *Contact Lens Spectrum*. October 31, 2016:28-30.
2. DeNaeyer GW. Today's scleral lens. *RCCL*. 2012 June;18-22.
3. Michaud L, van der Worp E, Brazeau D, et al. Predicting estimates of oxygen transmissibility for scleral lenses. *Cont Lens Ant Eye*. 2012;5(6):266-71.
4. Coronis T. Winning the high-index numbers game. *20/20 Magazine*. 2009 July. www.2020mag.com/article/winning-the-high-index-numbers-game. Accessed July 11, 2018.
5. Contamac. Tried, tested, and proven. www.contamac.com/sites/default/files/documents/documents/Optimum%7C%20Brochure.pdf. Accessed August 9, 2017.
6. Acuity Polymers. Package insert for daily wear corneal and semi-scleral lenses. www.acuitypolymers.com/images/pdf/AC100_Packaginsertweb.pdf. Accessed August 9, 2017.
7. Salamatrada A, Jabbarvand M, Hashemian H, et al. Histological and confocal changes in rabbit cornea produced by an intrastromal inlay made of hexafocon A. *Cornea*. 2015;34(1):78-81.
8. Bausch + Lomb. Boston XO₂. www.bausch.com/ecp/our-products/contact-lenses/gp-lens-materials/boston-xo2. Accessed July 5, 2018.
9. He X, Donaldson KE, Perez VL, Sotomayor P. Case series: Overnight wear of scleral lens for persistent epithelial defects. *Optom Vis Sci*. 2018;95(1):70-5.
10. Bausch + Lomb. Bausch + Lomb announces licensing agreement with tangible science for use of hydra-peg custom contact lens coating. *Eyewire News*. June 27, 2018. <https://eyewire.news/articles/>

[bausch-lomb-announces-licensing-agreement-with-tangible-science-for-use-of-hydra-peg-custom-contact-lens-coating](https://www.bausch.com/ecp/our-products/contact-lenses/gp-lens-materials/boston-xo2). Accessed July 5, 2018.

11. Lagado Corporation. Premium GP materials. www.lagadocorp.co/en/products/premium-gp-materials. Accessed July 11, 2018.
12. Tan B, Zhou Y, Yuen TL, et al. Effects of scleral-lens tear clearance on corneal edema and post-lens tear dynamics: a pilot study. *Optom Vis Sci*. 2018;95(6):481-90.
13. Menicon. Menicon Z. www.menicon.com/pro/our-products/gp-lens/menicon-z. Accessed August 9, 2017.
14. Barr JT, Pall B, Szczotka LB, et al. Corneal endothelial morphology results in the Menicon Z 30-day continuous-wear contact lens clinical trial. *Eye Contact Lens*. 2003;29(1):14-6.
15. Tappin MJ, Pullum K, Buckley RJ, Pullum KW. Scleral contact lenses for overnight wear in the management of ocular surface disorders. *Eye*. 2001;15(2):168-72.
16. Smith G, Mireskandari K, Pullum K. Corneal swelling with overnight wear of scleral contact lens. *Cornea*. 2004;23(1):29-34.
17. GP Lens Institute. GP materials list. www.gpli.info/materials. Accessed July 11, 2018.
18. Sindt CW. Tangible Hydra-PEG: A novel custom contact lens coating technology designed to improve patient comfort and satisfaction. *Tangible Science White Paper*. 2016. https://docs.wixstatic.com/ugd/dd2daf_6d730c1482f6450396c734d74c3017b6.pdf. Accessed July 11, 2018.
19. Caroline PJ, André MP. Hydra-PEG: a solution to contact lens discomfort? Poster presented at Global Specialty Lens Symposium, Las Vegas; 2015.
20. ClinicalTrials.gov. Tangible Hydra-PEG: a promising solution for scleral lens wearers with dry eye. <https://clinicaltrials.gov/ct2/show/NCT03417505>. Accessed July 5, 2018.

Fitting the SURGICALLY Compromised Cornea

Specialty contact lenses are often the best option for post-corneal surgery patients. Here's how you can handle these challenging cases.

By Beth Summers, OD, MS, and Maayan E. Keshet, MD

Corneal surgery often leaves patients with uncorrected refractive errors, including irregular astigmatism and atypical corneal shapes. For many of these patients, contact lenses are an excellent method of visual rehabilitation. However, each of these patient populations presents unique fitting characteristics that can challenge the fitting process. A firm grasp of the common corneal surgeries and the refractive issues they can create is the first step to properly fitting these patients in contact lenses. Here, we discuss the contact lens fitting considerations clinicians must keep in mind when fitting patients after incisional and laser refractive surgery, intrastromal corneal ring implantation and various keratoplasty techniques.

BLAST FROM THE PAST: RK

Although it is no longer used, incisional refractive surgery—especially radial keratotomy (RK)—grew in popularity in the early '90s. Generally, the procedure created four to eight radial corneal incisions (typically 85% to 90% of the corneal depth) to treat myopia. The incisions flattened the meridian and 90° away, and the closer the incisions came to the optical zone, the greater

their effect. In addition, increasing radial incision lengths also resulted in greater flattening.¹

RK was performed in myopes based on nomograms that included patient age, radial incision length, incision number and optical zone diameter. Because refractive results were inconsistent, staged adjustments were made empirically based on the initial postoperative refraction. Retreatment for highly myopic patients could result in as many as 32 incisions with exceedingly small clear optical zones.

Unfortunately, the initial flattening effect often progressed even 10 years after the initial procedure, causing an unpredictable and substantial hyperopic shift.² Keratometry may be as low as 30D in patients with a high number of incisions. Up to 40% of postoperative patients suffer from high hyperopic shifts and progressive hyperopia.³ Many patients experience daily refractive fluctuations of several diopters, with greater hyperopia in the morning and a myopic shift at night. Additionally, low oxygen pressure and high altitude can cause temporary hyperopic shifts.¹

Incisions that invade the visual axis, greater number of incisions and hypertrophic incisional scars

all contribute to more significant irregular astigmatism and higher-order aberrations (HOAs). According to one study, 3% of patients who underwent RK lost two or more lines of Snellen acuity due to irregular astigmatism.² In some cases, the destabilized cornea may become ectatic and require either penetrating keratoplasty (PK) or specialty contact lenses.

In the mid '90s, new data warned against the long-term effects of RK on the cornea, and it was abandoned in favor of laser *in situ* keratomileusis (LASIK) and photorefractive keratectomy (PRK).^{2,3}

Fitting considerations. Although surgeons no longer perform RK, patients with a history of RK likely need refractive correction and may benefit from specialty contact lenses.

ABOUT THE AUTHORS



Dr. Summers is an adjunct assistant clinical professor at SUNY College of Optometry and an optometrist practicing in NYC. She fits specialty contact lenses in an OD/MD setting.



Dr. Keshet is a cornea specialist in private practice in NYC. She is an adjunct assistant clinical professor at SUNY College of Optometry and an educational lecturer.

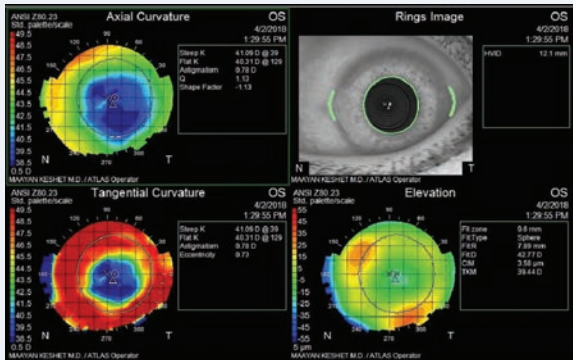


Fig. 1. On topography, this cornea post-RK (16 incisions) shows a wide circumferential band of peripheral corneal steepening and an oblate shape with a flatter center and a steeper periphery.

Clinicians should keep in mind that these patients can present with increased steepening in the mid-periphery, irregular and possibly elevated scarring, fluctuations in vision (especially with soft lenses) and incisional inclusion cysts that can rupture and increase the risk for infection.⁴ The steeper midperiphery and flat central cornea have a “reverse geometry” or oblate shape, which can affect the lens fitting process (Figure 1).

Although the method used to create the oblate effect in the contact lenses to match the cornea depends on the design and parameters of the lens, clinicians can generally increase the midperipheral clearance and the sagittal depth of the contact lens while reducing the central clearance, flattening the central base curve or both.

Visual quality tends to be better in gas permeable (GP) materials due to the improved neutralization of HOAs. Lens centration may be difficult to achieve, so large-diameter GPs or scleral lenses are usually preferable. Hybrid lenses may be another option to improve comfort without compromising vision. Because neovascularization of the incisions is a possible complication, clinicians should fit with high or hyper Dk material (>100). Poorly fitting lenses, especially small diame-

ter rigid GPs (RGPs), may wear away at the weakened cornea in the RK incisions and lead to corneal perforation.

LASERS AND KERATECTASIA

In PRK, an excimer laser ablates the de-epithelialized cornea to treat myopia, low hyperopia and regular astigmatism.

Research shows more than one diopter of induced astigmatism after PRK occurs in 2% to 5% of patients within one year after surgery due to either a decentered ablation, central islands or post-refractive surgery ectasia.¹

LASIK combines a c-shaped lamellar incision with corneal ablation of the stroma underlying the flap. The thickness and diameter of a LASIK flap depends on the instrument (manual keratome or femtosecond laser) used and affects the biomechanical stability of the cornea. Decentered ablations, flap folds and post-LASIK ectasia can all cause induced astigmatism. Additionally, visually significant macrofolds are possible with flap malpositioning or movement.

Post-LASIK keratectasia is, fortunately, declining: the 2006 rate

of 1.8% decreased to only 0.05% by 2014.^{5,6} Other than topographical signs of keratoconus, pellucid degeneration or forme fruste keratoconus, the following factors may help clinicians predict post-ablation ectasia: young patient age, increased flap thickness, residual stromal bed thickness less than 250µm to 300µm, higher myopic ablations, percentage of tissue altered over 40% and thin pachymetry (especially when the thinnest point is decentered).⁷

Fitting considerations. For patients with under- or over-correction following laser vision correction who are either ineligible for or do not desire an “enhancement,” contact lenses are a good option. During the lens fitting process, clinicians must take several factors into consideration, including dryness, fluctuation in refractive error and possibly decreased corneal sensitivity. These are especially relevant the first six months after the procedure.

Eyes with uncomplicated myopic ablations are usually easy to fit into standard sphere or toric soft contact lenses; however, visual quality is often subpar. GPs tend to yield the best visual results, and research shows an aspheric design is best for reducing HOAs under these circumstances.⁸ Additionally, for corneas undergoing higher ablations that result in a larger difference between

Release Date: November 15, 2018

Expiration Date: November 2, 2021

Goal Statement: Contact lenses are an excellent method of visual rehabilitation for post-cornea surgery patients. Understanding the refractive and lens fit issues these procedures can create is the first step to properly fitting these patients in specialty contact lenses. Clinicians must keep in mind these considerations when fitting patients after incisional and laser refractive surgery, intrastromal corneal ring implantation, and various keratoplasty techniques.

Faculty/Editorial Board: Beth Summers, OD, MS, and Maayan E. Keshet, MD

Credit Statement: This course is COPE approved for 1 hour of continuing education credit. Course ID is 59911-CL. Check with your state licensing board to see if this counts toward your CE requirements for relicensure.

Joint-Sponsorship Statement: This continuing education course is joint-sponsored by the Pennsylvania College of Optometry.

Disclosure Statement:

Authors: Drs. Summers and Keshet have no disclosures.

Editorial staff: Jack Persico, Rebecca Hepp, William Kekevan, Catherine Manthorp and Mark De Leon have no disclosures.

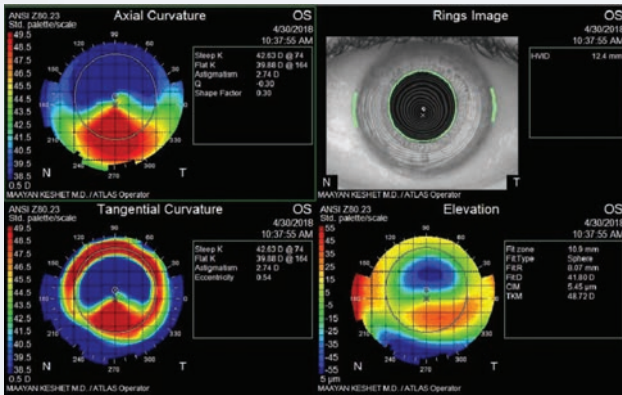


Fig. 2. This topography shows a patient with post-LASIK ectasia who was fit into a scleral lens.

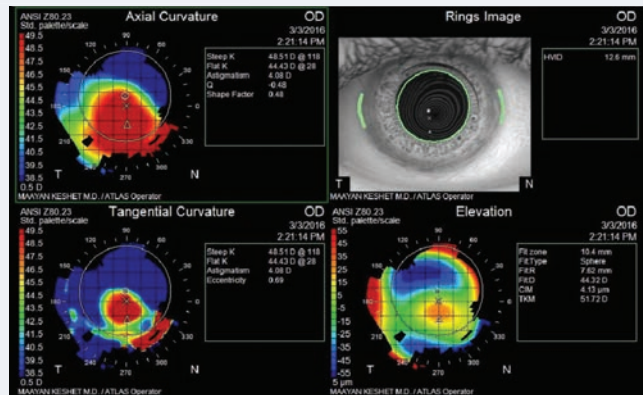


Fig. 3. This is the topography of a patient with two Intacs segments placed for keratoconus and a PK in his other eye.

a flat central cornea and a steeper periphery, oblate or reverse-geometry lenses are preferred.⁹ These lenses, though slightly more difficult to fit, provide a better approximation of the corneal profile in high ablation post-refractive surgery.

Eyes with post-ablation ectasia present more of a fitting challenge. Similar to keratoconus, corneal steepening most often occurs inferiorly and can be corrected with many different types of contact lenses, but complicated corneal shapes are often best neutralized by scleral lenses (Figure 2). One study indicates approximately 80% of patients with this condition can successfully wear specialty contact lenses (including small-diameter RGPs, soft toric contacts and hybrids).¹⁰ Current success rates may be even higher given recent improvements in modern contact lenses and the popularization of scleral designs.

CORNEAL IMPLANTS

Intacs (Addition Technology) is an intrastromal corneal ring segment (ICRS) designed to flatten the cornea and provide some degree of neutralization of the corneal cone. Although Intacs is indicated in the treatment of mild to moderate myopia (ranging from -0.50D to -5.00D with less than 1D of astigmatism), it is also currently used to treat kera-

toconus.¹¹ These ring segments are indicated for partial or full visual rehabilitation and are often used to try to avoid a corneal transplant (Figure 3). Currently, Intacs is the only FDA-approved ICRS design.

During Intacs placement, the surgeon inserts one or two plastic half rings into the midperipheral corneal stroma. The tunnel used for placement can be created with a manual device or a femtosecond laser. Made of polymethylmethacrylate and available in a range of thicknesses, the device has a set diameter and width and eyelets at either end to aid in placement.

If two segments are placed, they can be symmetric (for global or central cones) or asymmetric (for asymmetric cones, with the thicker segment placed inferiorly). When analyzing single-segment implants with laser-assisted placement, researchers found uncorrected and best-corrected visual acuity significantly improved one year after implantation.¹²

One literature review indicates that intracorneal ring segment implantation is both safe and effective in improving the uncorrected and best-corrected vision in the majority of patients.¹³ However, patients who are progressing at the time of implantation may have less than ideal outcomes, as one review

found patients who were progressing at the time of implantation and in whom acuity improved in six months experienced regression to preoperative acuity after five years.¹⁴ Additionally, corrected acuities of progressive cases had a statistically significant reduction at five years from implantation.¹⁴

Complications from Intacs can include decreasing visual acuity, inflammatory reactions, corneal perforation and segment extrusion related to constant eye rubbing and/or improper segment depth placement.^{15,16}

Although one study reported a fairly high explantation rate (12% were removed within one year), no significant complications resulting from the removal were noted.¹⁷ Another study found that decreasing visual acuity was the primary reason for explantation, not issues related to implantation or positioning. However, the researchers also found that best-corrected vision and keratometry readings returned to pre-Intacs implantation measurements.¹⁵

Fitting considerations. Many studies have emphasized the benefit of Intacs in improving contact lens tolerance. A follow-up study from the original Intacs study found 80% of patients who were previously contact lens intolerant were

able to tolerate contact lenses two years after Intacs implantation.¹⁸ Another study showed that more than 60% of patients with advanced keratoconus tolerated contacts after Intacs implantation.¹⁷ However, these studies did not specify which contact lens designs were attempted before patients with keratoconus were deemed intolerant.

With the increased popularity of lenses other than smaller RGP lenses, especially scleral contact lenses, even patients with high degrees of corneal ectasia tend to be able to adapt to contact lens wear with exceptional comfort and visual acuity.

The popularity of Intacs has been declining in recent years, yet many patients still have the implants and need visual rehabilitation with specialty contact lenses. Successful contact lens fits after Intacs implantation can be accomplished with specialty soft, RGP, piggyback,

COMBO PROCEDURES FOR KERATOCONUS

Newer keratoconus treatment methods combine Intacs placement with corneal collagen crosslinking (CXL) to help prevent progression. A recently published study examined a new technique called simultaneous intratunnel crosslinking and intrastromal corneal ring segment implantation.¹² The method involves injecting riboflavin into the corneal channel before segment implantation to increase penetration into the cornea without having to remove the epithelium.¹ Following segment placement, eyes are exposed to UVA radiation, leading to statistically significant outcome measures (improvement in uncorrected and corrected distance visual acuity, keratometry values and refractive error) similar to epi-off crosslinking after Intacs placement.²

1. Kilic A, Kamburoglu G, Akinci A. Riboflavin injection into the corneal channel for combined collagen crosslinking and intrastromal corneal ring segment implantation. *J Cataract Refract Surg.* 2012;38:878-83.
2. Hosny M, Nour M, Azzam S, et al. Simultaneous intratunnel cross-linking with intrastromal corneal ring segment implantation versus simultaneous epithelium-off cross-linking with intrastromal corneal ring segment implantation for keratoconus management. *Clin Ophthalmol.* 2018;12:147-52.

hybrid and scleral contact lenses.¹⁹⁻²² However, fitting a specialty contact lens over a cornea with Intacs can

be more complicated than it is for a patient with keratoconus without Intacs. Most issues are related to difficulty with centration, irregular shape (oblate) caused by the inserts and even erosions in the Intacs area.²³ GP lenses are preferably designed in a large diameter due to the physical obstruction to centration caused by the segment(s).

Alternatively, hybrids and smaller-diameter GPs with piggyback soft lenses can be beneficial.

When fitting a scleral contact lens, for example, the relative elevation created by the device in the midperiphery must be taken into account (Figure 4). Additionally, the cornea may have

a relatively oblate corneal profile due to the flattening effect of the segments. This is generally mild but often warrants an increased midperipheral clearance in scleral lenses.

KERATOPLASTY CASES

Many keratoplasty procedures now exist, including PK, deep anterior lamellar keratoplasty (DALK), Descemet's stripping automated endothelial keratoplasty (DSAEK) and Descemet's membrane endothelial keratoplasty (DMEK).

In PK and DALK, a circular incision of the host cornea is created either with mechanical or, occasionally, laser trephination. A circular button of host cornea is excised in its entirety during PK, and all but the host endothelium is removed in DALK. Both surgeries involve the suturing of a donor button in a similar fashion. A 2015 meta-analysis found the rate of graft rejection is lower for DALK, though failure rates are similar.²⁴ The final astigmatism of PK and DALK were not found to be statistically significantly different.²⁴ Postoperative

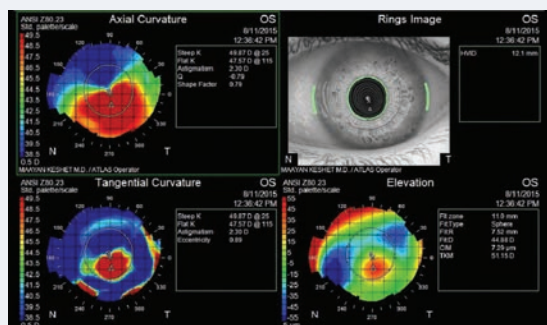


Fig. 4. This cornea with keratoconus has a single Intacs segment placed inferotemporally, as seen on topography. This patient was fit into scleral lenses.

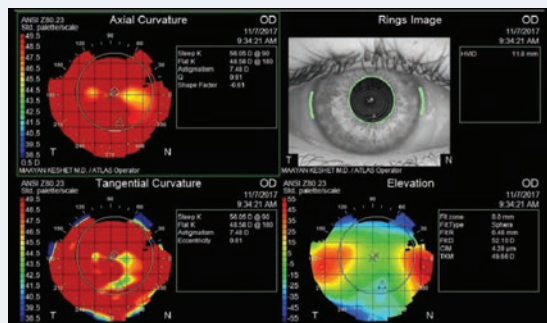


Fig. 5. This patient's topography reveals diffuse steepening post-PK for keratoconus. The patient was fit into a scleral lens.



astigmatism is a result of a combination of individual healing responses, suturing technique, graft diameter, centration and progression of ectasia, if present.

Sutures steepen the central cornea along their axis. There is a local flattening immediately around the suture and a compensatory steepening centrally in the graft. Interrupted sutures create the most astigmatism, followed by a single running suture, with the least astigmatism created by a double running suture.²⁵ However, selective suture removal in grafts with interrupted sutures affords the greatest control over astigmatism.

Following suture removal, astigmatism decreases or remains the same in 79% of patients who underwent excimer laser keratoplasty, while it increases in 80% of patients who underwent conventional motor trephination.²⁶

For treatment of the corneal endothelium, DSAEK or DMEK are preferred. The procedures selectively remove the patient's Descemet membrane and endothelium, followed by transplantation of donor corneal endothelium (with some posterior stroma in DSAEK and without stroma in DMEK). Indications include Fuchs' endothelial dystrophy, pseudophakic bullous keratopathy/edema, failed corneal graft and iridocorneal endothelial syndrome.

Fitting considerations. General considerations for fitting contacts for a cornea that has undergone keratoplasty involve patient vision and comfort, as well as graft health and integrity. Luckily, the fitting process is similar for post-PK and post-DALK eyes.

Visual rehabilitation following a PK is almost always afforded by a specialty contact lens fitting. Many

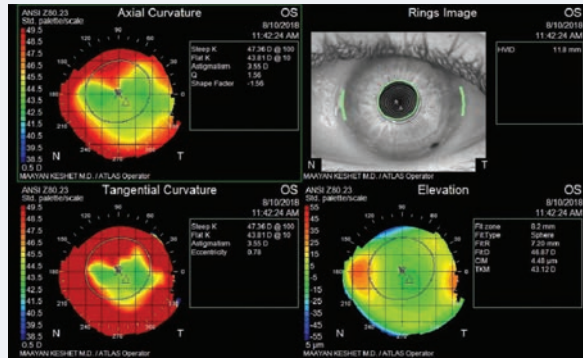


Fig. 6. Topography shows relative central flat and steep periphery (reverse geometry) in a post-PK cornea. This patient was fit into an oblate-shaped (steep skirt) hybrid lens.

post-PK patients experience dryness, and one study found approximately a third of eyes required dry eye management with topical lubrication and punctal occlusion.²⁷ To increase comfort and lens tolerance, clinicians can consider adding Hydra-PEG (Tangible Science) coating to eligible GP lenses.

Maintaining graft health is a top priority for contact lens fitters. Generally, fitting a minimum of six months postoperatively allows for some stabilization in astigmatism and decreased frequency of steroid drops. Additionally, fitting should only be initiated once the eye is stable, no active inflammation or infection is present and sutures are epithelialized. One study found PK sutures are present in 40% of eyes at the initiation of a contact lens fitting.²⁷ High or hyper Dk lens materials are critical to prevent hypoxia, infections and possible graft rejection or failure.

Graft shape will be a significant determining factor as to what lens will work best.

Proper RGP lens fitting should demonstrate no significant bearing on the graft or sutures/junctions. Often, larger-diameter GPs are needed to achieve proper centration. Oblate GP designs may provide better approximation to corneal shape.

Fitting a scleral contact lens over a PK graft can be challenging, depending on the shape and orientation of the graft (Figure 5). Arguably the most important issue is the host/graft junction. Because scleral lenses tend to decenter inferotemporally most often, clinicians should pay particular attention to the superonasal graft junction when monitoring contact lens wear in these patients.

Decentered grafts also can be a challenge to fit, and it is important to evaluate the most elevated point. Highly elevated grafts with relatively flat central curvature are best fit with oblate scleral lenses and increased midperipheral clearance. Scleral contact lenses may be fit over PK grafts with well-epithelialized sutures, but clinicians should take irregular astigmatism caused by sutures into account.

Suture removal may change the ametropia (especially astigmatism) of the eye. Often, elective suture removal for interrupted sutures is performed in the steep meridian in an effort to decrease corneal astigmatism. Contact lens fitters should carefully consider whether an anterior toric prescription (for remaining astigmatism correction) should be incorporated into the lens design when interrupted sutures are still present and astigmatism may possibly change at a later time with suture removal.

Additionally, lens thickness reduction may help to increase oxygen permeability across the lens. However, both reduced center thickness and the higher Dk materials preferred for PK fits may result in lens flexure. To check for this complication, clinicians should perform topography over the lens. Astigmatism on the topography of a

lens indicates flexure.

Hybrids may also be beneficial for PK fits, especially considering the availability of newer hybrid lenses with oblate designs. Additionally, steep skirts are a valuable tool to stabilize the lens on an eye with a steep periphery, as they decrease bubble formation in the skirt portion of the lens (*Figure 6*).

Silicone hydrogel specialty lenses that provide adequate Dk are a possibility, but may not provide a proper fit or vision for complex corneal shapes. Clinicians often achieve greatest success in soft lenses with aberration control and customizable base curves and periphery.

Corneas that have undergone DSAEK or DMEK do not generally require specialty contact lenses, but refractive changes may occur. A study found that anterior corneal shape typically does not change much following a DSAEK; however, patients often demonstrate a hyperopic shift from posterior curvature changes.²⁸ The average hyperopic shift on manifest refraction was $+0.670 \pm 0.158D$ following a DSAEK.²⁸

Advanced endothelial disease

causing anterior corneal changes or stromal scarring may play a role in determining the patient's final vision in spectacles and need for specialty contact lenses (*Figure 7*). This effect, however, is often mild.

Fitting patients with contact lenses after corneal surgery can challenge even the most seasoned contact lens fitter. Each case presents a slightly different cornea with its own unique considerations. But the promise of better visual outcomes for these patients is well-worth the hard work in restoring vision for this population. [accu](#)

1. Sutphin JE, Chodosh J, Dana MR, et al. Basic and Clinical Science Course: External Disease and Cornea. San Francisco: American Academy of Ophthalmology; 2005.
2. Waring GO, Lynn MJ, McDonnell PJ. Results of the prospective evaluation of radial keratotomy (PERK) study 10 years after surgery. *Arch Ophthalmol*. 1994;112(10):1298-308.
3. Dalton M. Addressing the post RK hyperopic shift. *EyeWorld*. August 2012. www.eyeworld.org/article-addressing-the-post-rk. Accessed July 27, 2018.
4. Efron S. Post-refractive Surgery. Third Edition Contact Lens Practice e-Book. Philadelphia: Elsevier Health Sciences; 2016.
5. Klein SR, Epstein RJ, Randleman JB, Stulting RD. Corneal ectasia after laser in situ keratomileusis in patients without apparent preoperative risk factors. *Cornea*. 2006;25(4):388-403.
6. Moshirfar M, Smedley JG, Muthappan V, et al. Rate of ectasia and incidence of irregular topography in patient with unidentified preoperative risk factors undergoing femtosecond laser-assisted

LASIK. *Clin Ophthalmol*. 2014;8:35-42.

7. Santhiago MR, Smadja D, Gomes BF, et al. Association between the percent tissue altered and post-laser in situ keratomileusis ectasia in eyes with normal preoperative topography. *Am J Ophthalmol*. 2014;158(1):87-95.
8. Porcar E, España E, Montalt JC, et al. Post-LASIK visual quality with a corneal scleral contact lens to treat irregular corneas. *Eye Cont Lens*. 2017;43(1):46-50.
9. Martin R, Rodriguez G. Reverse geometry contact lens fitting after corneal refractive surgery. *J Refract Surg*. 2005;21(6):753-6.
10. Alió JL, Belda JI, Artola A, et al. Contact lens fitting to correct irregular astigmatism after corneal refractive surgery. *J Cataract Refract Surg*. 2002;28(10):1750-7.
11. Amanzadeh K, Elham R, Jafarzadehpour E. Effects of single-segment Intacs implantation on visual acuity and corneal topographic indices of keratoconus. *J Curr Ophthalmol*. 2017;29(3):189-93.
12. Hashemi H, Amanzadeh K, MirafTAB M, Asgari S. Femtosecond-assisted intrastromal corneal single-segment ring implantation in patients with keratoconus: a 12-month follow-up. *Eye Cont Lens*. 2015;41(3):183-6.
13. Giacomini NT, Mello GR, Medeiros CS, et al. Intracorneal ring segments implantation for corneal ectasia. *J Refract Surg*. 2016;32(12):829-39.
14. Alió JL, Vega-Estrada A, Esperanza S, et al. Intrastromal corneal ring segments: How successful is the surgical treatment of keratoconus? *Middle East African J Ophthalmol*. 2014;21(1):3-9.
15. Chhadva P, Yesilirmak N, Cabot F, Yoo S. Intrastromal corneal ring segment explantation in patients with keratoconus: Causes, technique, and outcomes. *J Refractive Surg*. 2015;31(6):392-7.
16. Moshirfar M, Bean AE, Desautels JD, Birdsong OC. Corneal hydrops secondary to intrastromal corneal ring intrusion into the anterior chamber 7 years after implantation: a case report. *Ophthalmol and Therapy*. 2017;6(2): 373-9.
17. Shetty R, Kurian M, Anand D, et al. Intacs in advanced keratoconus. *Cornea*. 2008;27(9):1022-9.
18. Colin J, Cochener B, Savary G, et al. INTACS inserts for treating keratoconus. *Ophthalmology*. 2001;108(8):1409-14.
19. Caroline PJ, Andre MP. Contact lens case reports: intacs and keratoconus. *Contact Lens Spectrum*. April 1, 2008.
20. Dalton K, Sorbara L. Fitting an MSD (Mini Scleral Design) rigid contact lens in advanced keratoconus with INTACS. *Cont Lens Ant Eye*. 2011;34(6):274-81.
21. Rathi VM, Mandathara PS, Dumpati S, Sangwan VS. Scleral lens after intracorneal ring segments in patients with keratoconus. *Cont Lens Ant Eye*. 2018;41(2):234-7.
22. Smith KA, Carrell JD. High-Dk piggyback contact lenses over Intacs for keratoconus: a case report. *Eye Cont Lens*. 2008;34(4):238-41.
23. Szczotka-Flynn LB. Research review: How intracorneal rings affect lens fitting for keratoconus. *Contact Lens Spectrum*. May 1, 2010.
24. Liu H, Chen Y, Wang P, et al. Efficacy and safety of deep anterior lamellar keratoplasty vs. penetrating keratoplasty for keratoconus: A meta-analysis. *PLoS ONE*. 2015;10(1):e0113332.
25. Naydis I, Klemm M, Hassenstein A, et al. Postkeratoplasty astigmatism: comparison of three suturing techniques. *Ophthalmologie*. 2011;108(3):252-9.
26. Seitz B, Hager T, Langenbacher A, Naumann GOH. Reconsidering sequential double running suture removal after penetrating keratoplasty: A prospective randomized study comparing excimer laser and motor trephination. *Cornea*. 2018;37(3):301-6.
27. Driebe WT. Contact Lenses after Corneal Transplant. *Rev Ophthalmol*. December 2005.
28. Wainright WB, McNabb R, Carlson A, et al. Relationship between hyperopic shift after DSAEK and corneal anterior curvature, posterior curvature, and thickness. *Invest Ophthalmol Vis Sci*. 2014;55(13):2702.

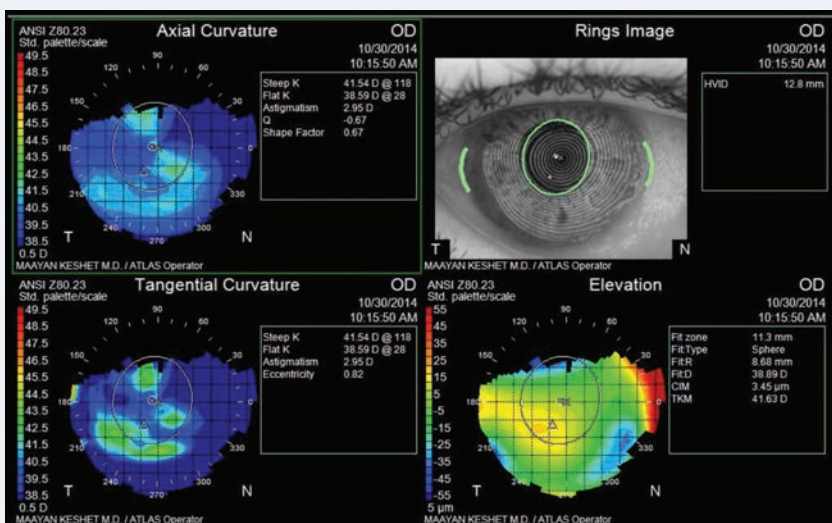


Fig. 7. This topography reading reveals mild irregular astigmatism following DSAEK for Fuchs'. The patient's uncorrected visual acuity in this eye was approximately 20/30 and no further correction was desired.



CE TEST ~ NOVEMBER 2018

- The flattening effect of RK continues to progress for how long after the incisions are made?**
 - Days.
 - Weeks.
 - Months.
 - Years.
- Which of the following may cause astigmatism following LASIK?**
 - Decentered ablation.
 - Flap folds.
 - Post-LASIK ectasia.
 - All of the above.
- Predictors for post-LASIK ectasia include all of the following, except:**
 - Thick pachymetry.
 - Large ablations.
 - Stromal bed thickness of less than 250µm to 300µm.
 - Forme fruste keratoconus.
- Considerations for a contact lens fitting for ametropia following post-refractive surgery include:**
 - Dryness, HOAs, decreased corneal sensation.
 - Dryness, HOAs, increased corneal sensation.
 - Flap thickness, ghosting, refractive error prior to ablation.
 - Epithelial ingrowth, corneal stability, refractive error prior to ablation.
- Corneas with larger amounts of reverse geometry best approximate a(n):**
 - Spheroid shape.
 - Prolate shape.
 - Oblate shape.
 - None of the above.
- Which of the following corneas is most likely to have an oblate shape?**
 - Keratoconus.
 - Post-LASIK ectasia.
 - Post-PK.
 - Post-DSAEK.
- Which of the following is an option for Intacs implantation?**
 - Two symmetrical segments.
 - Two asymmetrical segments.
 - Single segment.
 - All of the above.
- Which is a contraindication for initiation of a contact lens fit in a post-PK eye?**
 - Epithelialized sutures.
 - Mild, well-controlled dry eye syndrome.
 - Active infection.
 - Oblate corneal shape.
- Which of the following is an option for fitting contact lenses for a post-PK eye?**
 - Large diameter RGP lens.
 - Scleral lens.
 - Hybrid lens.
 - All of the above.
- Which of the following changes is most likely to occur after a DSAEK?**
 - Myopic shift.
 - Hyperopic shift.
 - Anterior corneal steepening.
 - Neutralization of astigmatism.

EXAMINATION ANSWER SHEET

Fitting the Surgically Compromised Cornea

Valid for credit through November 2, 2021

Online: This exam can also be taken online at www.reviewofoptometry.com/ce. Upon passing the exam, you can view your results immediately. You can also view your test history at any time from the website.

Directions: Select one answer for each question in the exam and completely darken the appropriate circle. A minimum score of 70% is required to earn credit.

Mail to: Jobson Healthcare Information, LLC, Attn.: CE Processing, 395 Hudson Street, 3rd Floor, New York, NY 10014.

Payment: Remit \$20 with this exam. Make check payable to Jobson Healthcare Information, LLC.

Credit: This lesson is approved for 1 hour of CE credit. Course ID is 59911-CL.

Sponsorship: Joint-sponsored by the Pennsylvania College of Optometry

Processing: There is a four-week processing time for this exam.

Answers to CE exam:

- | | | |
|--|--|---|
| 1. <input type="radio"/> A <input type="radio"/> B <input type="radio"/> C <input type="radio"/> D | 4. <input type="radio"/> A <input type="radio"/> B <input type="radio"/> C <input type="radio"/> D | 8. <input type="radio"/> A <input type="radio"/> B <input type="radio"/> C <input type="radio"/> D |
| 2. <input type="radio"/> A <input type="radio"/> B <input type="radio"/> C <input type="radio"/> D | 5. <input type="radio"/> A <input type="radio"/> B <input type="radio"/> C <input type="radio"/> D | 9. <input type="radio"/> A <input type="radio"/> B <input type="radio"/> C <input type="radio"/> D |
| 3. <input type="radio"/> A <input type="radio"/> B <input type="radio"/> C <input type="radio"/> D | 6. <input type="radio"/> A <input type="radio"/> B <input type="radio"/> C <input type="radio"/> D | 10. <input type="radio"/> A <input type="radio"/> B <input type="radio"/> C <input type="radio"/> D |
| | 7. <input type="radio"/> A <input type="radio"/> B <input type="radio"/> C <input type="radio"/> D | |

Post-activity evaluation questions:

Rate how well the activity supported your achievement of these learning objectives:

1=Poor, 2=Fair, 3=Neutral, 4=Good, 5=Excellent

- Improve my clinical knowledge of the post-op refractive concerns related to incisional and laser refractive surgeries. 1 2 3 4 5
- Become familiar with the specialty contact lens fitting considerations for post-refractive surgery patients. 1 2 3 4 5
- Increase my understanding of corneal inlays and the possible post-procedure refractive concerns. 1 2 3 4 5
- Better understand the challenges of fitting specialty contact lenses for patients with corneal inlays. 1 2 3 4 5
- Increase my knowledge of various keratoplasty techniques and their respective post-op refractive concerns. 1 2 3 4 5
- Improve my understanding of fitting patients with specialty contact lenses post-procedure. 1 2 3 4 5

Rate the quality of the material provided:

1=Strongly disagree, 2=Somewhat disagree, 3=Neutral, 4=Somewhat agree, 5=Strongly agree

- The content was evidence-based. 1 2 3 4 5
- The content was balanced and free of bias. 1 2 3 4 5
- The presentation was clear and effective. 1 2 3 4 5
- Additional comments on this course: _____

Identifying information (please print clearly):

First Name

Last Name

Email

The following is your: Home Address Business Address

Business Name

Address

City State

ZIP

Telephone # - -

Fax # - -

By submitting this answer sheet, I certify that I have read the lesson in its entirety and completed the self-assessment exam personally based on the material presented. I have not obtained the answers to this exam by fraudulent or improper means.

Signature: _____ Date: _____

Please retain a copy for your records.

LESSON 117235, RO-RCCL-1118



OPHTHALMIC INNOVATION SUMMIT

SAVE
THE
DATE

NEW
ORLEANS

FEB 21
2019

**FACILITATING MEANINGFUL INTERACTIONS AND THE EXCHANGE OF
INFORMATION BETWEEN INDUSTRY AND CLINICAL LEADERS SINCE 2009.**

OIS has expanded our mission of highlighting innovations for the comprehensive ophthalmic community by launching the inaugural OIS@SECO. This exclusive half-day meeting is limited to the leading eye care and industry professionals to enhance networking and the exchange of insights. Attendees will experience rapid fire presentations on innovative treatments and hear lively panel discussions addressing challenges and opportunities impacting patient care.

FOR MORE INFORMATION, VISIT WWW.OIS.NET

A Disease in Disguise

Acanthamoeba keratitis may resemble other conditions, making it difficult to catch early enough to preserve visual function.

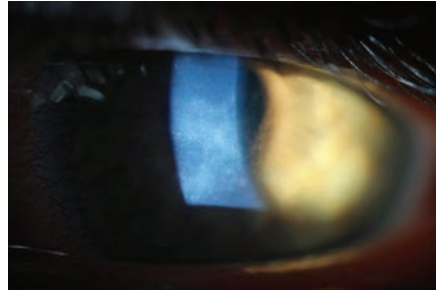
Of the eye findings corneal specialists encounter, the one that tends to cause the greatest concern is corneal ring infiltration. It is not the ring, however, that raises a red flag. It is what the ring is often associated with: *Acanthamoeba*, one of the most dreaded etiologies of corneal infection. Though infrequently encountered, *Acanthamoeba* keratitis (AK) is known for its destructive path, which could cause blindness. To make matters worse, AK looks and behaves similarly to other forms of microbial keratitis (MK), making it difficult to diagnose and treat appropriately.

OPPORTUNITY STRIKES

Acanthamoeba is a genus of free-living protozoan found throughout the world that tends to reside near its food sources. It is not naturally pathogenic and only causes disease under opportunistic conditions.^{1,2} Nearly all adults carry immunoglobulins to *Acanthamoeba*, and up to 24% of exposed populations have nasal mucosal colonization of the organism despite not having a known infection.^{3,4}

RISKY BUSINESS

While AK only affects just under one in two million contact lens wearers per year, lens use is the most important risk factor for AK and is associated with nearly 85% of cases.^{3,5,6} Though the absolute risk is elevated in both soft and rigid gas permeable lens users, the relative risk is almost 9.5 times higher



Due to early diagnosis, this AK patient was able to make a full visual recovery.

among soft lens wearers; the amoebae seem to adhere more readily to soft lens materials.^{1,3,5,6}

Of the different types of soft lenses, first-generation silicone hydrogels have the highest risk, newer generation and more conventional hydrogels have the next highest risk and daily disposables have the lowest risk.⁶ Ortho-K has also been linked to a disproportionately high number of AK cases.⁶

In most cases of AK, lens use combines with other risk factors—poor lens care, contaminated water exposure and corneal epithelium trauma—to cause disease.^{1,3} Although lens use is the biggest risk factor for AK, it is important to be cognizant of other factors, as 15% of cases develop in non-lens users.

AK TAKES ITS COURSE

The prognosis for AK varies dramatically depending on the stage at which it is caught; diagnosing the disease early is crucial. While the history you gather from an AK patient is often indistinguishable from that of a bacterial or fungal keratitis patient, the initial clinical picture of AK looks distinctly different than those of other forms of MK.

While we essentially need some degree of ulcerated stromal infiltration to guide suspicion of MK, the same is not true for AK. Instead, early AK is characterized by irregular, well-demarcated zones of cystic epitheliopathy, which are generally lightly infiltrated and non-ulcerated. These zones are thought to be superficial tracks caused by motile protozoans as they move through the superficial cornea. The lesions may be dendriform in shape and, as such, are often misdiagnosed as herpes simplex virus (HSV) keratitis. Any epithelial irregularity diagnosed as HSV keratitis that does not respond to treatment in two weeks should be reconsidered as AK.^{1,3,4,6}

Another early finding of AK is stromal perineuritis, which is nearly pathognomonic. While rare, *Pseudomonas* and *Mycobacterium leprae* can also cause perineuritis, but AK is far more likely to produce this finding; perineuritis develops in nearly 63% of AK cases.⁵ Perineuritis is thought to represent active protist movement along corneal nerves with subsequent infiltration of polymorphonuclear cells around the nerves and may be the cause of the severe pain classically associated with AK. Pain greater than the clinical picture indicates, however, really only applies to the early stages of AK when infiltration is mild and ulceration is usually absent. By the later stages of AK, when ulceration is typically present, the eye looks like it should hurt and usually does, though patients may develop a degree of neurotrophy as a result of perineural inflammation.⁵

Due to irregular and localized



epitheliopathy, greater pain than the clinical picture indicates and perineural inflammation generally without stromal infiltration and ulceration, early AK should not be mistaken for other forms of MK. Only when AK is caught at this stage can we dramatically alter the outcome with medical intervention. Effectively treating early AK with therapy can completely clear the disease and restore vision without leaving a scar.

Owing to isolate and individual immune differences, there is no exact timeline for AK progression. By the end of the first month, however, findings typically begin to change. Ring infiltration, a late presenting sign of AK, becomes increasingly common and, in most cases, manifests as a ring ulcer—meaning the lesion has an epithelial defect—typically centered on the corneal apex with the area of densest infiltration located along its edges. Though there are other causes of ring infiltration—gram-negative bacteria, fungal corneal ulcers, herpes and anesthetic abuse—and there is no explanation for why AK causes apical ring ulcers, they are 10 times more likely to develop in AK cases than in others.⁷ It is worth noting that AK-related ring ulcers are different than non-ulcerated ring infiltrates, which are generally not apical or ulcerated, are associated with viral keratitis and carry a relatively good prognosis when not caused by AK.

THE TREATMENT LADDER

Though corneal scrapings can be ordered for AK, my facility sends all suspected AK cases to teaching hospitals for confocal microscopies,

which can non-invasively confirm the condition. These centers also initiate therapy as soon as possible, usually the same day. While clinicians can order effective anti-amoebic therapy through compounding pharmacies, it often takes one to two days for patients to receive therapeutic treatment.

Because AK takes on two distinct forms during its life cycle, medical treatment should include both amoebicidal and cysticidal medications. Of the medications currently used to treat AK, polyhexamethylene biguanide 0.02% and chlorhexidine 0.02% (biguanides and cationic antiseptics) are the most successful, with dosed concentrations being 100 times greater than the minimum cysticidal concentration.⁸ Both, however, are unavailable at commercial pharmacies in the United States and must be obtained from compounding pharmacies.

While not first-line therapies, members of the diamidine family of medications, Brolene (propamidine isethionate 0.1%, May and Baker) and Desomedine (hexamidine 0.1%, Chauvin), also show fairly good efficacy in AK treatment. Diamidines are well-tolerated and not overly toxic, but due to the chronicity of treatment, propamidine can lead to a medicamentosa response.^{5,8} Obtaining these medications is also a hurdle, as neither is available in the United States. Propamidine can be purchased over the counter in the United Kingdom and online. Though diamidines are easier to acquire given their online availability, they are not strong enough to be considered for monotherapy.

In the later stages of AK, our ability to dramatically alter the course of the disease is limited; sterilizing the eye for subsequent surgery is generally the only option. Regardless of its source, I have never seen a ring ulcer heal without needing a keratoplasty to remove the resultant scar. While the prognosis of therapeutic keratoplasty in eyes with active AK is poor and is associated with a high risk of recurrence, penetrating keratoplasties and deep anterior lamellar keratoplasties have good outcomes when treating corneal scarring and irregularity in eyes with definitively cleared infection and resolved inflammation.^{1,3,5,8}

As with most pathologies, the earlier AK is detected, the better the outcome. However, AK can easily be mistaken for other forms of MK, often resulting in misdiagnosis. This is why it is important to provide care when AK is most recognizable in its earliest stages to avoid sight-threatening implications and preserve visual function before the disease escalates to a severe form of keratitis. **RECL**

1. Illingworth CD, Cook SD. *Acanthamoeba keratitis*. *Surv Ophthalmol*. 1998;42(6):493-508.

2. Berra M, Galperin G, Boscaro G, et al. Treatment of *Acanthamoeba keratitis* by corneal cross-linking. *Cornea*. 2013;32(2):174-8.

3. Alizadeh H, Niederkorn JY, McCulley JP. *Acanthamoeba keratitis*. In: Krachmer JH, Mannis MJ, Holland EJ, eds. *Cornea*. 2nd ed. St. Louis: Mosby; 2004:1043-74.

4. Clarke B, Sinha A, Parmar DN, et al. Advances in the diagnosis and treatment of *Acanthamoeba keratitis*. *J Ophthalmol*. 2012;2012:484892.

5. Dart JK, Saw VP, Kilvington S. *Acanthamoeba keratitis*: diagnosis and treatment update 2009. *Am J Ophthalmol*. 2009;148(4):487-99.

6. Hammersmith KM. Diagnosis and management of *Acanthamoeba keratitis*. *Curr Opin Ophthalmol*. 2006;17(4):327-31.

7. Mascarenhas J, Lalitha P, Prajna NV, et al. *Acanthamoeba*, fungal and bacterial keratitis: a comparison of risk factors and clinical features. *Am J Ophthalmol*. 2014;157(1):56-62.

8. Lindquist TD. Treatment of *Acanthamoeba keratitis*. *Cornea*. 1998;17(1):11-6.

Out With the Old, in With the New

This patient was able to take off her glasses once and for all and focus solely on contact lens wear with the help of available fitting technologies.

The available technology for fine-tuning scleral lens fits has become more advanced throughout the years. As someone who has been fitting a high volume of scleral lenses since the beginning of my career in 2011, seeing this evolution has been exciting. In the beginning, all we had to base our fits on were spherical diagnostic sets and fluorescein patterns. Now, we have anterior segment optical coherence tomography, scleral topographers, the ability to take impressions of a patient's eye and newer designs that incorporate our increasing knowledge of the scleral shape.

The following case highlights a patient whose initial scleral lens fitting required multiple visits to ensure the right lens parameters were ordered. She returns a few years later and, with innovative, new technologies, is refit with new lenses in significantly less chair time.

THE CASE

A 62-year-old female with corneal ectasia OU secondary to LASIK surgery presented complaining she did not want to have to wear glasses over her contact lenses at the same time to correct her residual astigmatism. She had not had an eye exam in three years and was wearing the same lenses that had been prescribed for her previously. The lenses were comfortable, and her vision was clear, but wearing both scleral lenses and glasses to correct her astigmatism was frustrating for her.

Three years ago, we went through

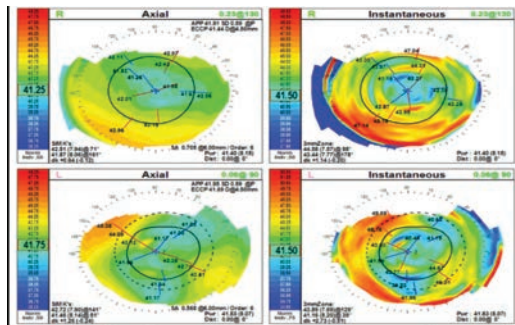


Fig. 1. Pictured here is a plateau-shaped corneal topography OU.

many iterations of scleral lenses with front surface toric optics that were weighted with prism ballast. However, her vision was constantly fluctuating, and her over-refraction was inconsistent. My lab at the time was unable to make back surface toric haptics to stabilize the lens, so the toric markers were at different locations during each of the patient's visits, regardless of the amount of prism ballast that was added. Eventually, I ended up ordering spherical lenses and forward spectacles to correct the patient's astigmatism.

Her presenting visual acuities (VA) were 20/20 OD and 20/20 OS. Her scleral lenses had a base curve (BC) of 44mm OU, a sagittal depth (sag) of 4.48mm OU, a diameter of 16mm OU and powers of -2.50D OD and -2.00D OS. Her glasses prescription was -0.75+0.50x175, add +2.50 OD and -1.75+1.25x153, add +2.50 OS.

CONTACT LENS EVALUATION

The patient's pupils were equal, round and reactive to light. I did not note any relative afferent pupillary defects in either eye. Her extraocular movements were full OU. A slit lamp exam revealed clear lashes

OU, clear corneas with low tear lakes OU and deep and quiet anterior chambers OU. I noted 1+ nuclear sclerosis OU. The patient's intraocular pressure was 15mm Hg OU. Topography showed plateau-shaped corneas with mild inferior ectasia OU. Her keratometry readings were 42.51/41.87@071 OD and 44.58/43.44@088 OS (Figure 1). An undilated posterior segment evaluation revealed a healthy fundus OU.

CONTACT LENS FITTING

The SynergEyes VS is a scleral lens that comes standard with toric haptics to stabilize it. These lenses are non-rotationally symmetrical and use bitangential peripheral landings that rest gently on the sclera and respect the natural contour of the scleral shape. This design also achieves better centration, improving optics and fits.¹ A fitting set of this design was chosen to refit the patient with the hopes of stabilizing her forward astigmatism correction.

The initial diagnostic lens was placed on the patient's eyes with parameters of 3600 sag/plano/16.0 haptics, 36/42 OD and 3600 sag/plano/16.0 haptics, 34/40 OS. Centrally, the sag was adequate with about 250µm of central clearance OU after initial insertion, there was adequate limbal clearance and the haptic sat nicely aligned OD, but the left lens had 360 slight edge lift, causing the patient to feel that lens a lot more.

Over-refraction revealed:

- +0.50 +0.75x170 (VA of 20/20) OD (toric marker line at 5:30 clock hour)



Earn up to
12 CE
Credits*

10TH ANNUAL
2018

WEST COAST Optometric Glaucoma Symposium

DECEMBER 14-15

Join our faculty of renowned ODs and MDs at the Monarch Hotel in Dana Point, CA, for a highly interactive meeting covering the most up-to-date information in glaucoma care.

**Up to 12* CE credits
for only \$325.**

MEETING CO-CHAIRS:
Murray Fingeret, OD
Robert Weinreb, MD

SPEAKERS:
Andrew Camp, MD
Ben Gaddie, OD
Alex Huang, MD, PhD
Richard Madonna, OD

MONARCH HOTEL
1 Monarch Beach Resort
Dana Point, CA 92629
949-234-3900

Three Ways to Register
www.reviewsce.com
/WCOGS2018

email: reviewmeetings@jhihealth.com
call: 877-451-6514

Administered by
Review Group Vision Care Education, LLC



*Approval pending



Partially supported by unrestricted educational grants from
Bausch + Lomb Aerie Novartis

Review Group Vision Care Education, LLC partners with Salus University for those ODs who are licensed in states that require university credit. See event website for up-to-date information.

- +0.50 +1.00x155 (VA of 20/20) OS (toric marker line at 7:30 clock hour)

The axis was adjusted to accommodate the position of the toric markers per the lab's formula, and the following lens parameters were ordered: +1.25-0.75x155 OD and +1.50-1.00x155 OS. The lenses had a sag of 3600, a BC of 8.4mm, a diameter of 16mm and toric haptics of 36/42.

CONTACT LENS DISPENSING

Two weeks later, I placed the lenses on the patient's eyes. Her vision was 20/20 OU. The fit was optimal with 200µm of central vault upon settling. The toric line was aligned at the expected positions—5:30 OD and 7:30 OS (*Figures 2 and 3*). Over-refraction was plano OU. The lenses were dispensed.

FOLLOW-UP

Two weeks later, the patient presented and reported she was thrilled with her vision. She could clearly see objects further away without her glasses and was able to enjoy a more active lifestyle. The fit was finalized.

DISCUSSION

Stabilizing front surface toric optics

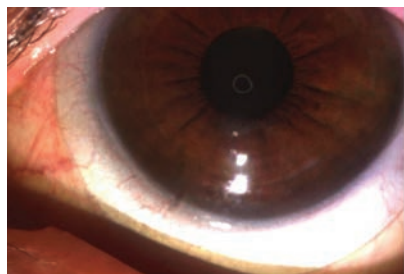


Fig. 2. The toric marker in this eye is aligned to 7:30 clock hour OS.

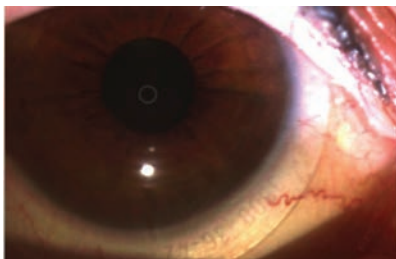


Fig. 3. The toric marker in this eye is aligned to 5:30 clock hour OD.

with toric haptics is a lot more predictable, comfortable and effective than with prism ballast.² Allowing the lens to settle in its natural place causes the toric haptic lines to land where they are expected to every time. Toric haptics can also improve centration of lens optics, reducing induced cylinder from a decentered lens.

Prism ballast, on the other hand, can add thickness to the lens, making edge awareness more prevalent in patients. It is also not as secure as a toric haptic. In addition, prism ballast lenses tend to rotate, especially if a patient has a non-spherical sclera, which is true of most patients.^{3,4}

The SynergEyes VS lens design has helped me fit front surface astigmatism scleral lenses more confidently in less chair time, making these scleral lenses valuable in my practice. **CCL**

1. Hellem A. A lens designed to fit true scleral shape. blog.synergieyes.com/blog/a-lens-designed-to-fit-true-scleral-shape. Accessed October 1, 2018.
2. Johns LK, Barnett M. Contemporary scleral lenses: theory and application. *Bentham Science*. 2017.
3. Van der Worp E, Graf T, Caroline PJ. Exploring beyond the corneal borders. *Contact Lens Spectrum*. 2010;6:26-32.
4. Visser ES, Visser R, Van Lier HJ. Advantages of toric scleral lenses. *Optom Vis Sci*. 2006;83(4):233-6.

Treating Presbyopia: An Armamentarium of Options

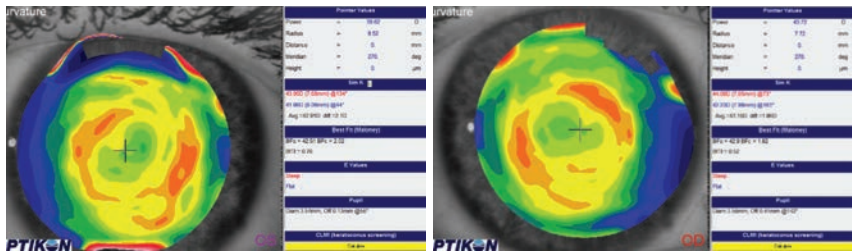
There's no lack of methods—just a lack of motivation among many. Patients deserve a chance.

While managing presbyopia can be challenging, many opportunities exist to correct distance and near vision with contact lenses. Presbyopic patients, however, are more likely to develop dry eye and suffer from the resulting discomfort that studies have found is the most common reason for discontinuing lens wear.^{1,2} To give presbyopic patients a better chance of success with contacts, we must optimize the ocular surface by keeping it as healthy as possible.

As the population continues to age, presbyopia affects more people, yet few presbyopic patients wear contacts. There is a large unmet need that we have the opportunity to rectify. This article summarizes multiple vision correction options for patients with presbyopia. By keeping an open mind and knowing your options, you will be able to optimize your patients' visual outcomes.

MULTIFOCAL LENSES

These are one of the most frequently discussed vision correction options for presbyopic patients. Multifocal designs are all based on the principle of simultaneous vision, which often requires some degree of adaptation for the best visual outcomes. With simultaneous vision, distance and near optics focus on the retina at the same time to provide binocularity for patients. The differences in the way each multifocal design delivers optics to the eye are often



Post ortho-K scans display inferior temporal centration of the treatment zone.

the deciding factors when patients are presented with multiple lens options.

While patients with less than 1.00D of refractive astigmatism are often successful with multifocals, those with more than 1.00D are usually not compensated for appropriately and may notice the uncorrected astigmatism. In these cases, we turn to toric multifocal lenses—customizable specialty lenses.

Even though soft multifocal contact lenses are a top choice for doctors who are fitting presbyopic patients, gas permeable (GP) lenses present another opportunity for vision correction. These lenses are designed to have a smaller diameter than the horizontal visible iris diameter. The distance optics are usually in the center and progress to near optics in the periphery of the optical zone. When the lenses are aligned appropriately over a patient's visual axis, most of the optical zone will be devoted to the patient's distance optics. As the patient moves their eyes down to look at something in close proximity, the lens shifts so the patient is able to look through a portion of the lens devoted to the near optics.

If a patient's corneal astigmatism is similar to their refractive astigmatism, it is usually corrected with a spherical lens through the tear film created between the posterior surface of the GP lens and the cornea. If the astigmatism increases, there is a greater chance of lens flexure, which could potentially cause residual astigmatism to manifest. In this case, the lens may either need a back surface toric or a bitoric design. Fortunately, these designs can be incorporated into multifocal lenses.

An alternate option available in a GP is a segmented bifocal. In this design, the distance optics are located in the superior portion of the lens, and the inferior portion of the lens contains the near optics. There is a definitive separation between the superior and inferior portions of the lens. In order to stabilize the lens, it can be truncated, prism ballasted or both. The best vision is achieved when there is appropriate centration while viewing through the distance portion and appropriate translation while viewing through the near portion. Therefore, having an appropriate inferior lid position is critical.



MONOVISION

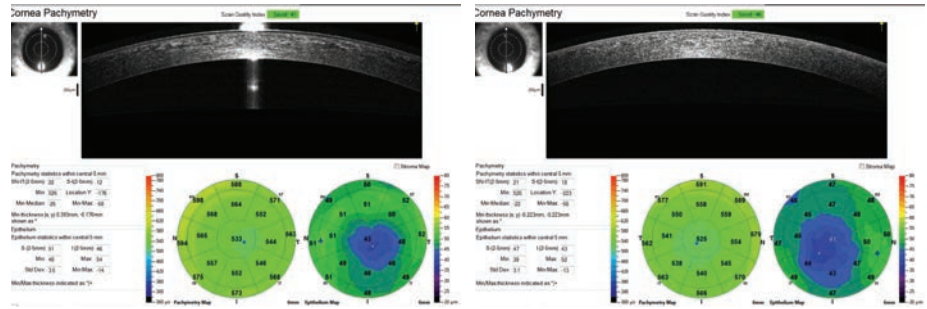
While not as widely discussed as other treatment options, monovision provides vision correction opportunities for presbyopic patients who are unable to adapt to multifocal lenses but are still interested in continuing or initiating lens wear. Monovision corrects dominant eyes for best-corrected distance vision and non-dominant eyes for best-corrected near vision. Each monovision patient is able to view distant objects with their dominant eye and near objects with their non-dominant eye.

ORTHO-K

With a longstanding record of success, ortho-K is an important treatment option for myopia management, provides a viable option for patients interested in alternate ways to treat their refractive error and mitigates symptoms of lens-induced dry eye. This procedure, however, is often overlooked when correcting myopia and astigmatism.

Appropriate centration of the treatment zone is critical in obtaining the best visual results. Post-treatment topography and OCT measurements of the cornea provide valuable data about the centration of the treatment zone and whether the fit needs to be altered to optimize centration.

There is a significant reverse geometry curve created outside the pupil border that provides the early presbyopic patient some level of low add power. To picture this, consider a lens with its distance optics in



Corneal and epithelial thickness mapping shows inferior temporal thinning consistent with a decentered treatment zone after treatment.

the center and its near optics in the periphery. Modifying the treatment zone by making it smaller in the non-dominant eye can also add additional plus power. For situations in which there is not enough plus power delivered to the eye, monovision may be the way to go.

HYBRID LENSES

This unique design presents another option for presbyopic patients and combine the characteristics of a GP and a soft lens—the center of the lens is a GP, and the peripheral portion is a soft lens. The GP part delivers the prescription and appropriate fit characteristics. When refractive astigmatism is similar to corneal astigmatism and is present in a low to moderate amount, the GP center can correct the astigmatism. The soft skirt of the lens provides similar stability and comfort to a soft lens, which requires less adaptation time than a GP.

SCLERAL LENSES

Usually reserved for fitting corneal abnormalities (e.g., ectasia, irregular surfaces, severely compromised corneas), scleral lenses are also

available to presbyopic patients. When fit appropriately, these lenses should rest on the conjunctiva and underlying sclera and vault over the cornea and limbus. Those who are unsuccessful with scleral multifocal designs should consider monovision. Overall, scleral lenses allow patients to experience remarkable improvements to their sight and can minimize the need for glasses.

When working with presbyopic patients, we must maximize their functionality and minimize their need for glasses. Because we cannot promise we will be able to eliminate glasses use entirely, it is important to set realistic expectations before beginning the fitting process. Our presbyopic patients are bound to have success with at least one of the numerous vision correction options available to them. Our job then is to help each patient find the best fit for them. [RCC](#)

1. Dumbleton K, Woods CA, Jones LW, et al. The impact of contemporary contact lenses on contact lens discontinuation. *Eye Cont Lens*. 2013;39(1):93-9.

2. Chalmers RL, Hunt C, Hickson-Curran S, et al. Struggle with hydrogel contact lens wear increases with age in young adults. *Cont Lens Anterior Eye*. 2009;32(3):113-9.



A Bump in the Road

Superficial granuloma need not contraindicate scleral lens wear—just design around it.

This patient is a 46-year-old male who suffered an alkaline burn to the right eye that resulted in severe limbal stem cell deficiency, corneal neovascularization and scarring, as well as recurrent erosions and pain. He was fit into a scleral device for pain relief. After several years of successful wear, he reported to our office with complaints of rapid-onset redness and irritation adjacent to the lens edge. He was diagnosed with a pyogenic granuloma.

Prednisolone was prescribed, which improved but did not resolve the granuloma. Surgical resection was discussed, but because he would need to be without the comfort-giving scleral device until healed, he opted for impression technology using an elevation-specific scleral design. An impression of the ocular surface was

obtained using a polyvinylsiloxane mold and a custom scleral device was designed to shield and cover the granuloma. A few months later, the granuloma had completely resolved.

A pyogenic granuloma is a mix of inflammatory cells, blood vessels and conjunctival tissue. It is commonly seen after ocular surface surgeries when there is a chronic irritation, such as a scleral lens or exposed suture, or in inflammatory conditions such as Steven-Johnson syndrome. Histologically, they are either inflammatory or fibrotic lesions.¹

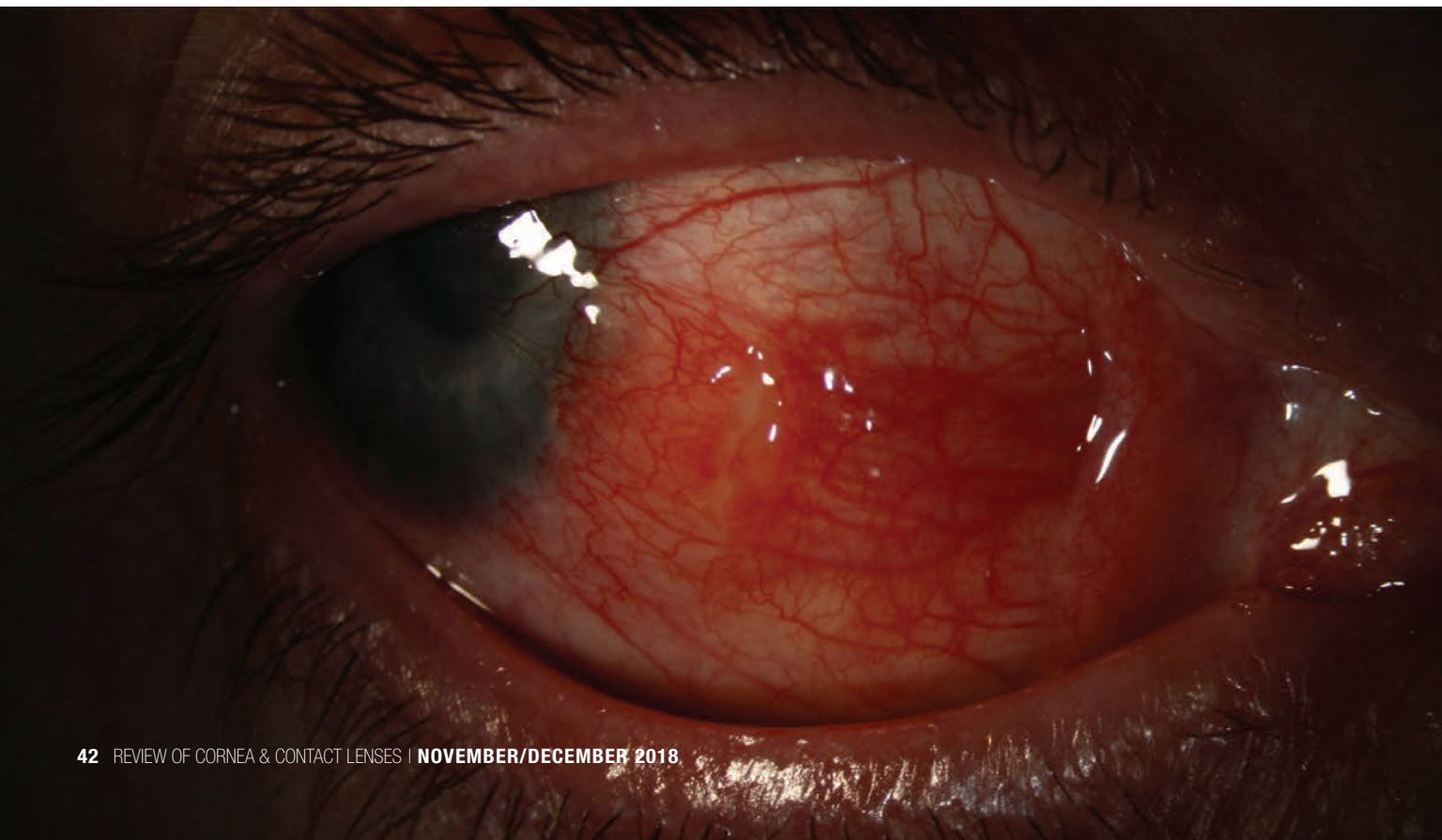Inflammatory lesions, characterized by proliferation of capillaries and inflammatory cells, are mainly associated with bulbar conjunctiva surgery or injury. Fibrotic granuloma, characterized by loose fibrous stroma, is mainly associated with chronic chalazion on the tarsal conjunctiva.²

Pyogenic granuloma must be differentiated from malignant lesions. A major distinguishing factor is timing. Granulomas develop rapidly, while lesions such as squamous cell carcinoma have a slower onset.

The main treatment includes topical steroids QID for one to two weeks. If this does not resolve the lesion, surgical excision is generally recommended. However, other treatments have been prescribed: topical 0.5% timolol BID for three weeks, cryosurgery and chemical cauterization are potential options. Avoidance of the inciting factor is also effective at resolving the lesion. [RCCL](#)

1. Wu D, Qian T, Nakao T, et al. Medically uncontrolled conjunctival pyogenic granulomas: correlation between clinical characteristics and histological findings. *Oncotarget*. 2017 Jan 10; 8(2): 2020-2024.

2. Oke I, Alkharashi M, Petersen RA, Ashenberg A, Shah AS. Treatment of ocular pyogenic granuloma with topical timolol. *JAMA Ophthalmol*. 2017 Apr 1;135(4):383-385.

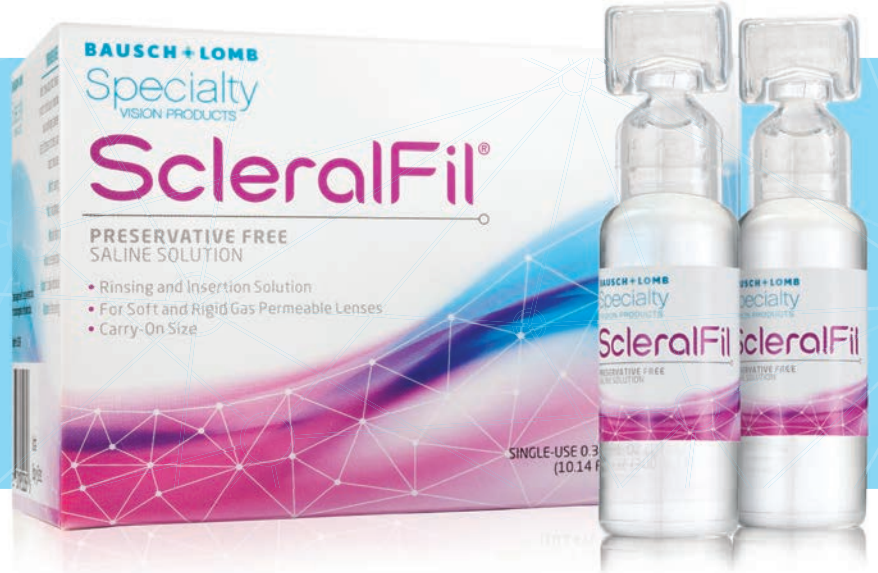



ScleralFil[®] preservative free saline solution

BAUSCH+LOMB
Specialty
VISION PRODUCTS

Offer the solution indicated for scleral lens insertion.




Scleral Lens Case Now Available

The Boston[®] Scleral Lens Case is specially designed to hold scleral lenses up to 23.5 mm in diameter and up to 10.0 mm in sagittal depth.

Available separately online at bauschSVPstore.com

NEW



ScleralFil[®] preservative free saline solution.

From Bausch + Lomb Specialty Vision Products, ScleralFil[®] is indicated as a scleral insertion solution – an alternative for rinsing and inserting scleral lenses. It is a sterile, buffered isotonic saline solution that can be used to rinse soft and gas permeable lenses.

- Buffered to maintain pH
- Travel-friendly, single-use, 10 mL vials stand upright
- Each carton contains a 30-day supply
- Indicated for soft and gas permeable lenses

ScleralFil[®] is available at bauschSVPstore.com and other select laboratories, including Alden Optical[®].

800.253.3669 | info@bauschSVP.com

Technology in balance



Health




Vision



Comfort

Miru 1 month: a unique family of silicone hydrogel monthly lenses.

MeniSilk™ and Nanogloss™ technologies designed to meet the demands of today's contact lens wearer.*



Material and surface technologies

MeniSilk™

- Ultra high Dk/t - 161 @ -3.00D
- Exceptional hydration
- Optimized transparency

Nanogloss™

- Super smooth surface
- Resistance to bacteria
- Excellent wettability



www.meniconamerica.com

*Menicon data on file April 2016

