

RCCL[®]

REVIEW OF CORNEA
& CONTACT LENSES

Sclerals: The New Normal?, p. 8

Get Started With Sclerals, p. 12

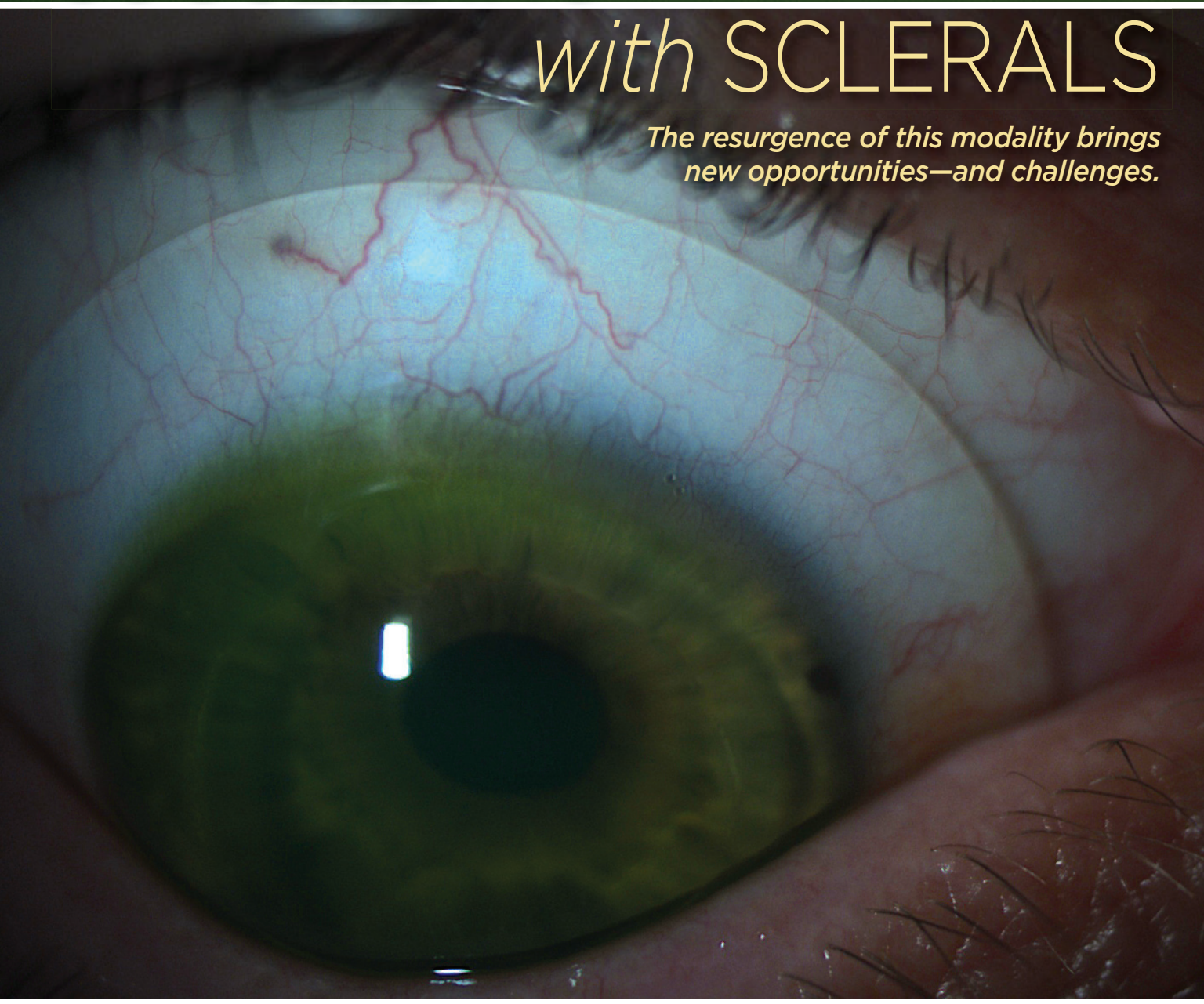
**Foggy with No Chance
of Moisture, p. 16**

**Post-keratoplasty:
Consider Sclerals, p. 22**


SUCCEEDING

with SCLERALS

*The resurgence of this modality brings
new opportunities—and challenges.*



**EVERY DAY.
TO ITS FULLEST.**



INTRODUCING: MyDay® toric. Utilizing the same proven design features as acclaimed Biofinity® toric and made of the healthiest¹ lens material available. MyDay® toric is our softest² silicone hydrogel toric ever.

Prescribe the contact lens of conquerors.



iPhone:
aim Camera at code
Android:
use QR code app

contents

Review of Cornea & Contact Lenses | May/June 2018

departments

4 News Review

Omega-3 Fatty Acids Don't Aid Dry Eye Management; Multifocal CL Acuity Similar to Spectacles for Myopic Kids

6 My Perspective

Safety First
By Joseph P. Shovlin, OD

8 The GP Experts

Sclerals: the New Normal?
By Robert Ensley, OD,
and Heidi Miller, OD

36 Pharma Science & Practice

ROCK and Whorl
By Elyse L. Chaglasian, OD,
and Tammy Than, MS, OD

38 Fitting Challenges

Lend Color to the Fit
By Vivian P. Shibayama, OD

40 Corneal Consult

What's Better for MK, One or Two?
By Aaron Bronner, OD

42 The Big Picture

Back for Seconds
By Christine W. Sindt, OD

features

12

Getting Started with Sclerals

Identifying candidates, picking a fitting set and knowing what to look for during a trial fitting will help you lay the groundwork for success.

By Brooke Messer, OD

16

Foggy with No Chance of Moisture

Poor front surface wettability and lens fogging can complicate scleral lens wear; identifying the cause can help you pick the right treatment strategy.

By Melissa Barnett, OD

22

Post-keratoplasty: Consider Sclerals

Corneal GP lenses have traditionally been a go-to option for these cases, but some patients may benefit from another modality.

By Jennifer S. Harthan, OD

26

Why Contact Lens Care Still Matters

Daily disposables may seem like a cure-all, but patient behavior doesn't allow for such a simple solution. Here's how to navigate today's lens care environment.

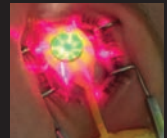By Nicole Carnt, BOptom, PhD

30

CE — CXL: a First-line Therapy for Keratoconus

Eye care professionals have a new leading treatment option to combat this disease.

By Clark Y. Chang, OD, MSA, MSc, and Christopher J. Rapuano, MD



Become a Fan on
Facebook

/ReviewofCorneaAndContactLenses



Follow Us on
Twitter

@RCCLmag

IN BRIEF

■ **Cosmetic products** containing **benzalkonium chloride (BAK)** and **formaldehyde (FA)** preservatives are **toxic to ocular cells**, a recent study found. Researchers tested the influence of BAK and FA on the morphology, survival, and proliferation and signaling ability of meibomian gland, corneal and conjunctival epithelial cells. Results show that both preservatives cause dose-dependent changes in the morphology, survival and proliferation of all types of cells tested.

Chen X, Sullivan DA, Sullivan AG, et al. Toxicity of cosmetic preservatives on human ocular surface and adnexal cells. *Exp Eye Res.* 2018;170:188-97.

■ A new study published in *Cornea* reveals results of **long-term follow up post-corneal collagen crosslinking (CXL)**—and the data is promising. Researchers looked at 62 eyes of 47 pediatric keratoconic patients who underwent epithelium-off CXL and evaluated uncorrected distance visual acuity, corrected distance visual acuity, Scheimpflug corneal tomography and optical coherence tomography demarcation line measurement at baseline and up to 10 years after treatment. They found CXL was effective at slowing keratoconus progression in nearly **80% of study participants**, while also improving functional performance.

Mazzotta C, Traversi C, Baiocchi S, et al. Corneal collagen cross-linking with riboflavin and ultraviolet a light for pediatric keratoconus: ten-year results. *Cornea.* 2018;37(5):560-6.

■ Results from a recent study suggest **iontophoretic administration of dexamethasone phosphate 40mg/mL solution is safe and well tolerated for patients with anterior scleritis**. Researchers used this treatment on 18 non-infectious scleritis patients at three different doses on day zero and day seven of the study. The primary and secondary endpoints at day 56 were dose-limiting toxicity and improvement on scleritis scale score, respectively. They found a suggestion of efficacy even in the lowest dose group, and **five of seven eyes met the primary efficacy outcome** within 28 days.

O'Neil EC, Huang J, Suhler EB, et al. Iontophoretic delivery of dexamethasone phosphate for non-infectious, non-necrotizing anterior scleritis, dose-finding clinical trial. *Br J Ophthalmol.* April 17, 2018. [Epub ahead of print].

Omega-3 Fatty Acids Don't Aid Dry Eye Management

Using an oral omega-3 fatty acid supplement to manage dry eye disease (DED) signs and symptoms offers no improvement over a placebo, a new study found.

The Dry Eye and Assessment Management (DREAM) Study, a randomized clinical trial, set out to gauge the long-term safety and efficacy of omega-3 fatty acids for DED treatment. “Many clinicians recommend, and many patients take, dietary supplements of n-3 fatty acids (often called omega-3 fatty acids), because they have anti-inflammatory activity and are not associated with substantial side effects,” the study said.

Researchers randomly assigned 535 patients with moderate to severe DED to receive a daily oral dose of either 3000mg of fish-derived n-3 eicosapentaenoic and docosahexaenoic acids or an olive oil placebo. They primarily looked at mean change in Ocular Surface Disease Index (OSDI) score at six and 12 months, but they also monitored mean changes in conjunctival staining score, corneal staining score, tear film break-up time (TBUT) and Schirmer’s test score to assess supplement efficacy. The results were less than encouraging for use of omega-3 supplementation as a possible dry eye solution, however.

After one year of supplementation, the mean OSDI score change was not significantly different between the omega-3 group and placebo. There was also no significant difference in conjunctival staining score, corneal staining score, TBUT and Schirmer’s test score between the groups.

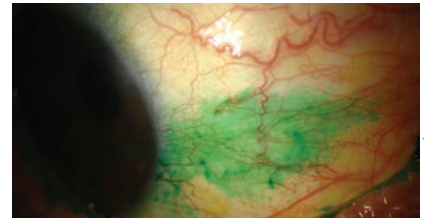


Photo: Michelle Hassan, OD

DREAM Study results show no notable difference in conjunctival staining score between patients treated with omega-3 and those given a placebo.

These results come as a surprise to those who have followed recent positive reports associated with omega-3 fatty acids. “Given the number of other studies that support fish oil, it’s definitely a surprise to hear this outcome,” says Jeffrey Anshel, OD, of Encinitas, CA. “However, I am one who agrees that fish oil does not represent the ‘whole story’ on treating DED.” Instead, Dr. Anshel uses a product with “some fish oil in addition to other ingredients to address the anterior ocular structures.”

Additionally, Dr. Anshel notes that this study may not represent the omega-3 fatty acids as a whole. “Given that many of the trial participants were already using other treatments upon recruitment and continued to use them throughout the study, this was not a study of omega-3 alone,” he says. According to the study, many patients were also treated using included artificial tears, cyclosporine drops, warm lid soaks, lid scrubs or baby shampoo and ‘other’ treatments. “Although the study was well designed, this is a curious aspect to consider,” Dr. Anshel says.

The Dry Eye Assessment and Management Study Research Group. n-3 fatty acid supplementation for the treatment of dry eye disease. *N Engl J Med.* April 13, 2018. [Epub ahead of print].

EDITORIAL STAFF

EDITOR-IN-CHIEF

Jack Persico jpersico@jobson.com

MANAGING EDITOR

Rebecca Hepp rhepp@jobson.com

ASSOCIATE EDITOR

Michael Iannucci miannucci@jobson.com

CLINICAL EDITOR

Joseph P. Shovlin, OD, jpshovlin@gmail.com

ASSOCIATE CLINICAL EDITOR

Christine W. Sindt, OD, christine-sindt@uiowa.edu

EXECUTIVE EDITOR

Arthur B. Epstein, OD, artepstein@artepstein.com

CONSULTING EDITOR

Milton M. Hom, OD, eyemage@mminternet.com

GRAPHIC DESIGNER

Ashley Schmouder aschmouder@jobson.com

AD PRODUCTION MANAGER

Scott Tobin stobin@jhihealth.com

BUSINESS STAFF

PUBLISHER

James Henne jhenne@jobson.com

REGIONAL SALES MANAGER

Michele Barrett mbarrett@jobson.com

REGIONAL SALES MANAGER

Michael Hoster mhoster@jobson.com

VICE PRESIDENT, OPERATIONS

Casey Foster cfoster@jobson.com

EXECUTIVE STAFF

CEO, INFORMATION SERVICES GROUP

Marc Ferrara mferrara@jhihealth.com

SENIOR VICE PRESIDENT, OPERATIONS

Jeff Levitz jlevitz@jhihealth.com

SENIOR VICE PRESIDENT,

HUMAN RESOURCES

Tammy Garcia tgarcia@jhihealth.com

VICE PRESIDENT,

CREATIVE SERVICES & PRODUCTION

Monica Tettamanzi mtettamanzi@jhihealth.com

VICE PRESIDENT, CIRCULATION

Emelda Barea ebarea@jhihealth.com

CORPORATE PRODUCTION MANAGER

John Caggiano jcaggiano@jhihealth.com

EDITORIAL REVIEW BOARD

Mark B. Abelson, MD

James V. Aquavella, MD

Edward S. Bennett, OD

Aaron Bronner, OD

Brian Chou, OD

Kenneth Daniels, OD

S. Barry Eiden, OD

Desmond Fonn, Dip Optom M Optom

Gary Gerber, OD

Robert M. Grohe, OD

Susan Gromacki, OD

Patricia Keech, OD

Bruce Koffler, MD

Pete Kollbaum, OD, PhD

Jeffrey Charles Krohn, OD

Kenneth A. Lebow, OD

Jerry Legerton, OD

Kelly Nichols, OD

Robert Ryan, OD

Jack Schaeffer, OD

Charles B. Slonim, MD

Kirk Smick, OD

Mary Jo Stiegemeier, OD

Loretta B. Szcotka, OD

Michael A. Ward, FCLSA

Barry M. Weiner, OD

Barry Weissman, OD



Multifocal CL Acuity Similar to Spectacles for Myopic Kids

A center-distance soft multifocal contact lens with an over-refraction provides children with myopia the same visual acuity a spectacle lens, according to research published in the April issue of *Optometry and Vision Science*.

“There is increasing interest in the ophthalmic industry in slowing myopia progression, and early evidence suggests that multifocal contact lenses may be an effective option,” says Daniel J. Press, OD, director of Pediatric Eye Care, Binocular Vision and Vision Therapy Services at North Suburban Vision Consultants in Illinois.

However, “Practitioners fitting contact lenses for myopia control frequently ask whether a myopic child sees well with a high-add multifocal,” says study author Krystal Schulle, OD, of the University of Houston College of Optometry. Her research team decided to find out.

The study enrolled 294 children, ages seven to 11, with myopia of -0.75D to -5.00D and 1.00D cylinder or less. The children were fitted bilaterally with +2.50D add Biofinity (CooperVision) multifocal lenses. The initial multifocal power was the spherical equivalent of a standardized subjective refraction, rounded to the nearest 0.25D step.

“This study found that children who have between -0.75D and -5.00D with less than 1.00D of astigmatism can achieve high contrast best-corrected visual acuity (BCVA) that is equivalent to spectacle correction,” Dr.

Press says, “but expect to incorporate an additional -0.50 to -0.75 spherical power in the final lens.”

In addition, neither pupil size nor degree of myopia or astigmatism influenced that amount of over-refraction needed for BCVA, he said.

With a careful over-refraction, these +2.50D add multifocal contact lenses provide good distance acuity, making them viable candidates for myopia control in children, the investigators concluded.

“It is important to note that this study’s purpose is not to evaluate effectiveness of myopia control in bifocal contact lenses, and we will have to wait until completion of the Bifocal Lenses in Nearsighted Kids (BLINK) group for that critical information,” Dr. Press said. BLINK is evaluating the same set of subjects as those in the current report. “What we can take away is confidence in achieving acceptable BCVA in children fit in Biofinity Multifocal +2.50D contact lenses.” **RCCL**

Schulle K, Berntsen D, Sinnott L, et al. Visual acuity and over-refraction in myopic children fitted with soft multifocal contact lenses. *Optom Vis Sci*. 2018;95(4):292-8.

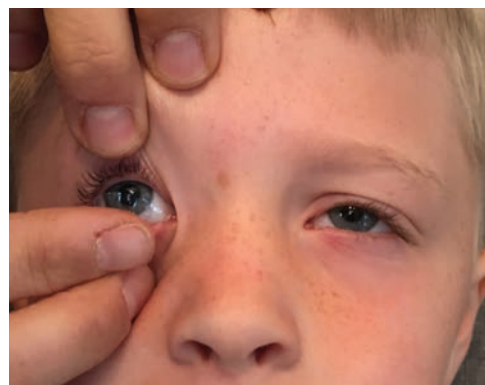

Photo: Daniel J. Press, OD

A new study shows fitting myopic kids with a +2.50D add center-distance soft multifocal contact lens provides similar visual acuity as spectacles.



Safety First

As the FTC considers a change to the Contact Lens Rule, its priority should be the patient.

The Federal Trade Commission (FTC) recently held a public workshop to explore issues regarding competition in the contact lens marketplace, consumer access to contact lenses and patient prescription release and portability. It held the workshop in conjunction with the regulatory review of their Contact Lens Rule.¹

Topics of discussion included the consumer's ability to comparison shop for contact lenses; use of electronic health records, patient portals and other new technology to improve prescription portability; interaction between the Contact Lens Rule and emerging telehealth business models; the potential for new technologies to improve prescription verification; and possible changes to the Contact Lens Rule to help foster competition and maximize consumer benefits.¹ Unfortunately, abuses or violations to the current Contact Lens Rule that could impact patient safety seemed to be a relatively low priority for the FTC during the workshop.

Over 60 optometrists and other eye care providers, as well as representatives from most major contact lens manufacturers, attended the workshop. American Optometric Association (AOA) representatives David Cockrell, OD, and Zachary McCarty, OD, teamed up with American Academy of Ophthalmology representative Tim Steinemann, MD, to share some sobering statistics on the matter.

The group cited numerous abuses in filling and requesting prescription verifications, including surveys that

reveal nearly a third of consumers still order and purchase lenses with an expired prescription (often more than a year beyond the expiration date). These surveys also show that many consumers were given lens brands other than what was prescribed by their eye care providers.² Robo-calls and faxes to these patients were filled with errors such as prescription requests for patients who had never seen a provider for contacts, meaning no prescriptions existed. Other verification requests were made and filled, even when inadequate follow-up or no follow-up was performed.

The trio also provided evidence that prescriptions were filled at the end of the expiration date to carry the patients well beyond their yearly examination period.² In other words, many consumers are stretching their annual visits out to two years or beyond by filling a prescription early and again near the end of the prescription expiration date.

Some additional issues with the Contact Lens Rule involve its interaction with emerging telehealth business models and the possibility for new technology to improve the prescription verification process. The current passive verification model doesn't seem to work and is teeming with potential for abuse. As such, this topic deserves attention, and hopefully new technology can ease the burden of this process.

A PROPOSED RULE CHANGE

In December 2016, the FTC issued a Notice of Proposed Rulemaking to announce suggested changes to the Contact Lens Rule.¹ If approved, the rule changes may require

providers to obtain a signed patient acknowledgement with each new contact lens prescription. The rule would also require prescribers to keep the signed document on file for at least three years.

However, between 2011 and 2016, a Freedom of Information Act request from the AOA showed only 309 consumer complaints—out of roughly 200 million contact lens prescriptions—were related to obtaining a contact lens from a seller.² Also of interest, the recent omnibus spending bill includes language directing the FTC to abandon its proposed rule change and instead prioritize patient safety.³

Currently, the Contact Lens Rule does not live up to its intended purpose: to protect the consumer and provide access to contact lenses in both a safe and verifiable manner. To turn things around, the FTC should prioritize its efforts to rein in online and “big-box” tactics by sellers and retailers.

Let's hope the FTC sees the new proposed rule change as an overreach, and instead zeroes in on the rampant abuses and violations of the Fairness to Contact Lens Consumer Act and the Contact Lens Rule by many retailers. After all, the first concern should always be patient safety. **RCCL**

1. The Contact Lens Rule and the Evolving Contact Lens Marketplace. FTC. www.ftc.gov/news-events/events-calendar/2018/03/contact-lens-rule-evolving-contact-lens-marketplace?utm_source=govdelivery. Accessed April 5, 2018.

2. Doctors of optometry make optometry's case to Federal Trade Commission. AOA. www.aoa.org/news/advocacy/ftc-workshop-wrapup. Accessed April 5, 2018.

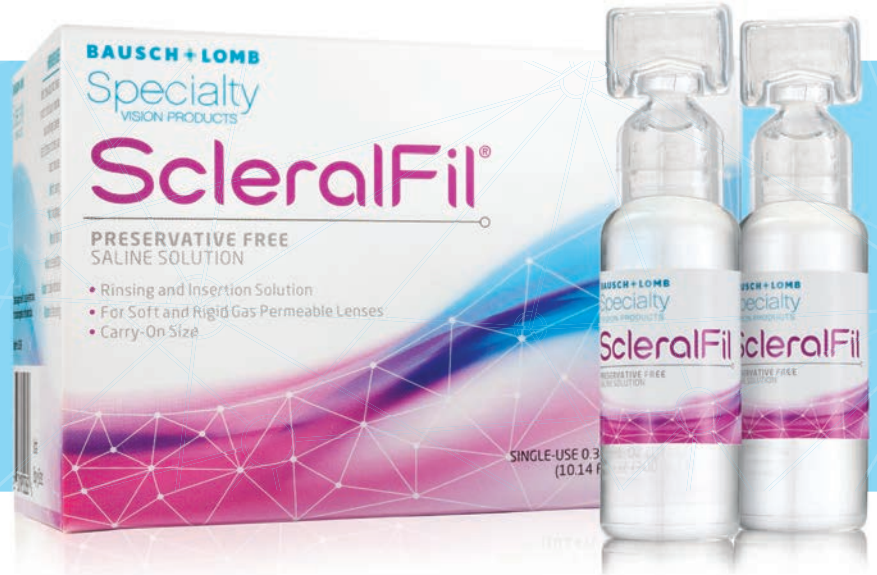3. American Optometric Association First look. American Optometric Association. March 26, 2018. aoa.bulletinhealthcare.com/briefing?id=2018-03-26&doctype=aoa. Accessed April 1, 2018.



ScleralFil[®] preservative free saline solution

BAUSCH+LOMB
Specialty
VISION PRODUCTS

Offer the solution indicated for scleral lens insertion.



Scleral Lens Case Now Available

The Boston[®] Scleral Lens Case is specially designed to hold scleral lenses up to 23.5 mm in diameter and up to 10.0 mm in sagittal depth.

Available separately online at bauschSVPstore.com



ScleralFil[®] preservative free saline solution.

From Bausch + Lomb Specialty Vision Products, ScleralFil[®] is indicated as a scleral insertion solution – an alternative for rinsing and inserting scleral lenses. It is a sterile, buffered isotonic saline solution that can be used to rinse soft and gas permeable lenses.

- Buffered to maintain pH
- Travel-friendly, single-use, 10 mL vials stand upright
- Each carton contains a 30-day supply
- Indicated for soft and gas permeable lenses

ScleralFil[®] is available at bauschSVPstore.com and other select laboratories, including Alden Optical[®].

800.253.3669 | info@bauschSVP.com

Sclerals: the New Normal?

This modality could be helpful for patients with healthy corneas, but concerns about its effect on corneal physiology still exist.

Practitioners often only think of scleral lenses as indicated for those with irregular corneas, ocular surface disease or those intolerant to corneal gas permeable (GP) lenses. However, manufacturers continue to introduce new designs that make these lenses a potentially helpful option for healthy eyes with hyperopia, myopia, astigmatism and presbyopia. Here's an overview of the benefits these lenses can provide normal corneas, as well as some concerns, and two case examples help to bring it all home.

ADVANTAGES

A scleral lens's large size allows for minimal lens-to-lid interaction, resulting in maximal comfort from the start. These lenses also provide good vision stability due to lack of rotation and minimal movement with blink. This is especially advantageous for athletes who require stable, comfortable vision all day without the risk of a lens dislocating and ejecting from the eye on blink.

Scleral lenses are filled with fluid, which provides constant ocular surface hydration, meaning they cause fewer factors related to lens-induced discomfort compared with soft lenses.¹ This tear layer also helps reduce a certain amount of the higher-order aberrations that result from irregular corneas or lenticular opacities. Additionally, the larger optic zone provides minimal halos and glare, resulting in enhanced vision.

What's more, research shows few complications associated with scleral lens wear. Current literature

includes only isolated case reports of microbial keratitis.²⁻⁴ According to the SCOPE study, the most commonly reported complication was ocular surface injury due to handling or application error.⁵ A relatively small number of patients in this study experienced various forms of corneal pathology, including corneal edema, neovascularization, corneal infiltrates and toxic keratopathy. Of the 84,375 patients represented in the study, only 70 cases of microbial keratitis were reported. Results from this study suggest that vision-threatening complications associated with scleral lens wear may be rare.

Astigmatism. A spherical scleral lens design can compensate for up to 3.5D of corneal cylinder in an astigmatic patient, exceeding the range provided by corneal GP lenses.⁶ This is due to the fluid tear layer vaulting over the cornea and masking corneal astigmatism. Because soft lenses rely on rotational stability for clear vision, lens rotation while blinking can result in vision fluctuation during the day. If this occurs, patients often feel they are compromising their vision to wear contact lenses.

One recent study reports scleral lenses as a viable alternative to soft toric lenses for astigmatic subjects. Subjects wore each modality for one month, with 75% preferring the vision of the scleral lenses compared with the soft toric lenses, and 53% expressing a preference to continue with the scleral modality.⁷


Fluctuating vision can also be an issue with corneal GP lenses if they are not well centered or have

excessive movement on blink. With scleral lenses, meanwhile, there is minimal movement with blink, and corneal astigmatism is bypassed due to the fluid tear layer, resulting in stable, clear vision. Scleral lenses also feature an 8mm to 9mm optic zone, which enhances the field of vision and limits interaction with the pupil diameter and the perception of higher-order aberrations.⁶

Once a scleral lens is placed on the eye, there may be a small degree of residual astigmatism related to lenticular astigmatism. If this happens, adding a front-toric design to the lens can provide the patient with optimal vision. Residual astigmatism can also come from lens flexure.⁶ This is often related to poor alignment of the scleral landing to the patient's conjunctiva. To resolve this, practitioners can incorporate toric haptics to achieve a better lens alignment in all quadrants.

Presbyopia. With today's increasing number of available multifocal scleral lens options, this modality is clearly a viable option for presbyopes and patients with concomitant dry eye. Despite several newly available soft lens options for these patients, contact lens dropout remains high in the presbyopic population due to unstable tear film and complaints of dry eye.⁶ Many of these patients also display significant refractive astigmatism that, if not adequately corrected by optical means, can lead to fluctuating and distorted visual acuity.⁶ Unfortunately, few toric multifocal contact lenses offer a positive outcome for presbyopes with astigmatism.⁶

However, several multifocal



scleral lens options—including dual aspheric, center-distance and center-near designs—provide exceptional vision at all distances.⁸ Scleral multifocals provide the dual advantages of GP optics along with constant ocular surface hydration and, as a result, stabilized tear film.

Additionally, these lenses compensate for high degrees of refractive astigmatism without the need for a front surface toric design. The larger optic zone of traditional scleral lens designs also provides room for larger add power zones with unaffected distance vision.⁶ As with any multifocal lens, centration is crucial to provide optimal visual performance.

CONCERNS

Given the variety of scleral lens designs available today, some practitioners still do not jump straight into scleral lenses for regular corneas. Currently, there are questions about how the combination of lens material, lens thickness and post-lens tear reservoir affect corneal physiology.

Early scleral lens designs came with complications due to their non-permeable materials. The lack of oxygen transmissibility led to corneal edema and neovascularization, resulting in hazy vision and increased risk of eye infections.⁸ With the advent of GP materials, this risk is minimized; however, proper lens alignment and central clearance is still necessary. Various studies have suggested that, despite the availability of highly breathable materials, hypoxia is still a concern.^{7,9}

Research shows a consensus that scleral lenses should be manufactured with highly oxygen permeable

(Dk) materials (>125 to 150+), low center thickness (200µm to 250µm) and low corneal clearances (less than 150µm to 200µm).^{7,9,10} One study acknowledged that wearing large scleral lenses is associated with chronic oxygen deprivation, leading to 2% to 3% of edema at the end of the wearing period if the lens is thick (more than 300µm) and clearance remains high (more than 250µm) throughout the wearing period.¹¹ Another study found that the amount of corneal edema was 1.7% after eight hours of scleral lens wear.¹⁰ Clinically, this level of edema is not significant and similar to the 4% of physiological edema present upon waking.¹² Still, practitioners generally use smaller diameter scleral lenses known as mini-scleral lenses for normal corneas.⁸

Most concerning with large scleral wear for normal corneas is uncertainty about the long-term effects of low-grade corneal edema. For patients with irregular corneas or chronic ocular surface disease, the risk is minimal compared with the benefits of restoring visual acuity or treating the ocular surface. Some clinicians will argue, however, that the benefits do not outweigh the risks for patients with healthy corneas.⁶ Until we have more evidence, this will remain a gray area. For now, mini-scleral lenses with limited thickness and clearance may be the safest method to provide normal corneas with scleral lens benefits.

CASE EXAMPLE #1

A 16-year-old male presented to clinic for a contact lens evaluation. He was wearing spectacle correction and reported monocular double

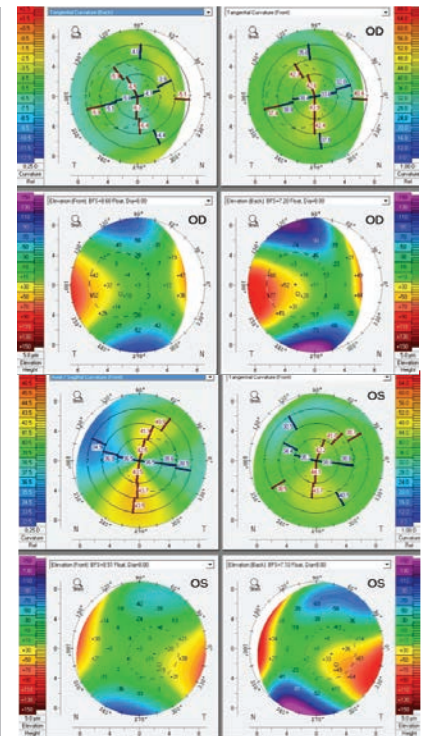


Fig. 1. Corneal topography for this patient shows anterior corneal astigmatism 7.8D OD and 5.5D OS.

vision in both eyes. He had ocular history of ocular albinism, nystagmus and refractive amblyopia in both eyes. Due to his high degree of hyperopic and astigmatic correction, he was self-conscious about wearing glasses at school. He reported the magnification of his eyes made students stare and he felt they could notice his eyes shake.

The patient's spectacle correction was +7.00 -5.00x180 OD and +6.75 -5.00x175 OS. His entering acuity with spectacle correction was 20/150 OD and 20/100 OS. Due to his degree of corneal astigmatism, he was fit into a scleral contact lens (Figure 1). The patient had a horizontal visible iris diameter of 11.5mm. Since he did not have any

corneal ectasia requiring excessive vaulting or dry eye complaints, we used a smaller diameter of 15.4mm.

The final scleral lenses ordered had a front surface toric due to residual astigmatism on over-refraction and toric periphery in both eyes. The toric periphery provided better alignment to the scleral landing while also improving centration and rotational stability. Best-corrected vision with scleral contact lenses was 20/100+1 OD and 20/70+1 OS.

The patient was able to wear his contact lenses for 10 to 12 hours daily. He had no issues inserting and removing lenses despite his nystagmus and reduced vision. He also reported improvement in the quality of his vision and felt more confident at school while wearing his contact lenses.

CASE EXAMPLE #2

A 33-year-old male presented for a contact lens evaluation. His left corneal GP lens had recently broken. He had previous history of high myopia with intolerance to corneal GP lenses and recurrent corneal abrasions while wearing them. The patient wore spectacle correction for back up; however, he had much better quality of vision

with GP lenses. Given his history and degree of refractive error, he was re-fit into scleral contact lenses. His spectacle correction was -17.50 -2.25x034 OD and -17.75 -1.75x150 OS. Entering acuity with spectacle correction was 20/40 OD and 20/40 OS. He also had anterior corneal astigmatism of 1.4D OD, OS. His horizontal visible iris diameter was 12.1mm in each eye.

Given the patient's larger corneal diameter, we fit him for a 17.0mm scleral lens. He trialed a diagnostic lens with a spherical landing zone; however, there was blanching along the horizontal meridian and uptake along the vertical meridian when sodium fluorescein was inserted (*Figure 2*). As such, a toric periphery was necessary to provide best alignment and avoid chamber clouding during daily wear. Best-corrected vision with scleral contact lenses was 20/25 OD and 20/30 OS.

The patient had around 220µm of central vault with 11 steps of total toricity between flat and steep meridians. He was able to wear his contact lenses for 14 hours with minimal clouding. On occasion, he would take his lenses out to clean the surfaces. Overall, the patient is happy with the vision and comfort he receives with his scleral lenses.

lenses may be more suitable for correcting normal corneas with refractive errors such as astigmatism, high myopia and presbyopia. These lenses may also accommodate low-to-moderate corneal irregularities.⁶ Larger lenses (15.8mm to 18mm in diameter) are more often used for managing severe ocular surface disease, severe ectasia and corneal irregularity.⁶

Practitioners should consider scleral lenses for both irregular and regular corneas. Using more than one trial fit set will allow management for a diverse patient population. Lens manufacturers and educational aids, such as the Scleral Lens Education Society, can help guide practitioners to provide successful lens fits for all patients. **RCCL**

1. Alipour F, Kheirkhah A, Jabarvand Behrouz M. Use of mini scleral contact lenses in moderate to severe dry eye. *Cont Lens Anterior Eye*. 2012;35(6):272-6.
2. Zimmerman AB, Marks A. Microbial keratitis secondary to unintended poor compliance with scleral gas-permeable contact lenses. *Eye Contact Lens*. 2014;40(1):e1-4.
3. Fernandes M, Sharma S. Polymicrobial and microsporidial keratitis in a patient using Boston scleral contact lens for Sjogren's syndrome and ocular cicatricial pemphigoid. *Cont Lens Anterior Eye*. 2013;36(2):95-7.
4. Bruce AS, Nguyen LM. Acute red eye (non-ulcerative keratitis) associated with mini-scleral contact lens wear for keratoconus. *Clin Exp Optom*. 2013;96(2):245-8.
5. Schornack M. The SCOPE Study: An overview. *CL Spectrum*. 2017;32:25-31.
6. Michaud L. Scleral lens fitting: Once rare, now routine? *RCCL*. 2016;153(3):12-6.
7. Michaud L, van der Worp E, Brazeau D, et al. Predicting estimates of oxygen transmissibility for scleral lenses. *Cont Lens Anterior Eye*. 2012;35(6):266-71.
8. Barnett M. Scleral lenses for everyone. *CL Spectrum*. 2017;40-5.
9. Jaynes JM, Edrington TB, Weissman BA. Predicting scleral GP lens entrapped tear layer oxygen tensions. *Cont Lens Anterior Eye*. 2015;38(1):44-7.
10. Vincent SJ, Alonso-Caneiro D, Collins MJ, et al. Hypoxic Corneal Changes following Eight Hours of Scleral Contact Lens Wear. *Optom Vis Sci*. 2016;93(3):293-9.
11. van der Worp E, Bornman D, Ferreira DL, et al. Modern scleral contact lenses: A review. *Cont Lens Anterior Eye*. 2014;37(4):240-50.
12. Caroline P MJ, Lotoczky, J, Rosen C, Michaud L. Scleral lenses: new opportunities, new challenges. Presented at the Global Specialty Lens Symposium, January 22-25, 2015; Las Vegas.

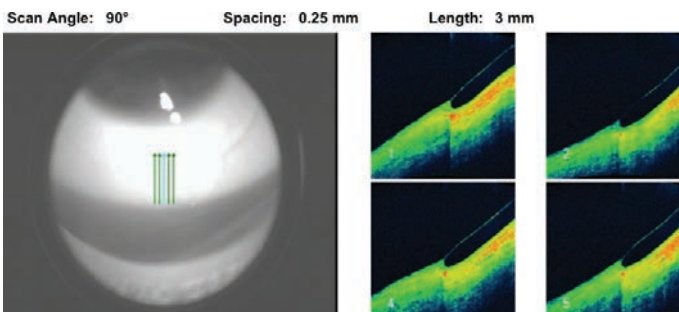


Fig. 2. This lens shows mildly tight landing in the vertical meridian.

Scleral lenses can help manage a wide variety of irregular and normal corneas. Smaller scleral

Earn up to
20 CE
Credits*

— save the date —

2019

WINTER OPHTHALMIC CONFERENCE

FEBRUARY 15-19, 2019
ASPEN, COLORADO
(WESTIN SNOWMASS)

The Longest Running Winter CE Meeting in Eye Care

www.skivision.com

Administered by
Review of Optometry®

cope
*Approval pending

SALUS
UNIVERSITY
Pennsylvania College of Optometry

Review of Optometry® partners with Salus University for those ODs who are licensed in states that require university credit

Get Started with Sclerals

Identifying candidates, picking a fitting set and knowing what to look for during a trial fitting will help you lay the groundwork for success.

By Brooke Messer, OD

The level of scleral lens interest we're experiencing today hasn't been seen in nearly a century. Contact lens specialists of the early 1900s conceptualized new designs, developed better materials and perfected the fitting of these large-diameter, cornea-vaulting lenses. We—their 21st century successors—have taken up the mantle and continue to refine the designs, expand the candidate pool and improve the wearing experience to the point that sclerals can often stand shoulder-to-shoulder against corneal lenses as a viable alternative.

If you're new to sclerals, don't worry. The lenses are easier to fit than you may think. This start-up guide can help you learn how best to approach a scleral lens fitting.

MEET THE CANDIDATES

To identify ideal candidates for scleral lenses, you must first understand the benefits large-diameter gas permeable (GP) lenses can provide. At the top of the list is the fluid layer created between the cornea and back surface of the lens. This fills in the hills and valleys of an irregular corneal surface to negate irregular astigmatism, just like corneal GP

lenses. The fluid layer also bathes the entire cornea during lens wear, while the large lens size protects the ocular surface from environmental agents, eyelid friction and air exposure. The lens sits behind both eyelids, and the large diameter limits interaction with the lens edge, significantly improving comfort for patients that have had trouble tolerating corneal lenses in the past. Also, a properly fit scleral lens does not move much, if at all, further improving comfort.

Based on these benefits, patients with irregular corneas make excellent candidates for scleral lenses. According to the SCOPE study, 74% of scleral contact lenses are prescribed for patients with irregular corneas. Conditions such as keratoconus, corneal transplants, Salzmann's nodular degeneration and post-surgical conditions have all responded positively to the vision correction scleral lenses provide.¹

Those with ocular surface diseases significant enough to cause burning, pain and light sensitivity generally have the best response to scleral lens wear in terms of ocular surface protection. Sjögren's syndrome, basement membrane dystrophies and exposure keratitis are in this category and make

good scleral lens candidates. These patients account for about 16% of all scleral lens evaluations.¹

The other 10% of scleral lenses are prescribed for patients with normal corneas and healthy ocular surfaces looking for improved contact lens performance.¹ This category includes patients with active lifestyles, high refractive error and high astigmatism.

FIRST THINGS FIRST

A successful scleral lens fitting begins with an understanding of how these lenses differ from corneal GP lenses. For one thing, the techniques used to measure the cornea and select a lens from the fitting set are different. Corneal GP lenses are designed based on topography and keratometry measurements, and you must select a lens base curve to align with the corneal surface. The goal of the fit in these cases is to facilitate movement and

ABOUT THE AUTHOR



Dr. Messer received her doctor of optometry degree and completed a cornea and contact lens residency at Southern California College of Optometry. She now practices in Edina, MN, with special interests in scleral, multifocal and orthokeratology contact lenses.

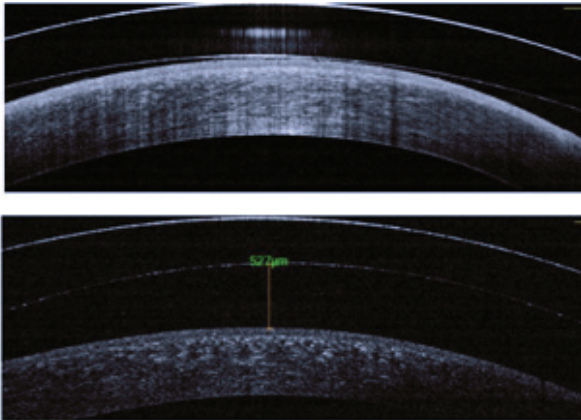


Fig. 1. Anterior segment OCT images of a scleral lens with excessive and insufficient corneal clearance.

tear exchange with blinking.

During scleral lens fittings, however, you must select lenses from fitting sets based on the sagittal depth of the cornea. Here, the lens should vault the ocular surface. While you can use topography for complete medical management and understanding of the corneal condition at hand, only a small amount of topographical information is used in selecting the trial lens from a fitting set. The important information includes corneal diameter and overall corneal shape (i.e., prolate or oblate). Anterior segment optical coherence tomography (OCT) can also be helpful when selecting trial lenses, but only if the system can measure a large area of the ocular surface. This allows you to determine sagittal depth at a certain chord diameter.

Additionally, because keratometry readings do not correlate with sagittal depth of the anterior chamber, the base curve of a scleral lens does not need to correlate with corneal measurements.² For example, a patient with keratoconus may have a small nipple cone with steep keratometry readings and a shallow anterior chamber, or a corneal transplant patient can have a deep anterior chamber with

flat keratometry readings.

SELECT A FITTING SET

Those interested in scleral lens fitting often wonder which fitting set is the best choice. Sclerals come in a wide variety of shapes, so there is no definitive, one-size-fits-all design. While there is no

wrong answer when selecting your first fitting set, following certain guidelines can help you pick the set most applicable to your patient base.

Many fitting sets offer multiple diameters, allowing you to fit both large and small corneas. This immediately opens up your options.

Having a range of lens shapes on hand can also make your life easier. It would also be prudent to look for a set with designs to fit both oblate and prolate cor-

neas. Beyond that, consider the extras you'll need to perfect the lens fitting. These can include front-surface toric correction, toric peripheral curves and multifocal optics. The larger your applicable population, the more likely you are to use all of these tools, and you'll want to make sure the lab you choose has the ability to provide them. Following these guidelines should get you off to a good start, and you can always fill in gaps with additional sets as you gain experience.

START THE TRIAL

After you've selected your fitting set, your attention should turn to the lens trial. Here, the ability to swiftly make lens selections and adjustments is essential. Your fitting set may group the lenses by diameter, lens shape or edge lift. Within those groups, the lenses are often further sorted by sagittal depth. Some lens sets have a 100µm difference in sagittal depth between each lens, others more than 300µm; familiarizing yourself

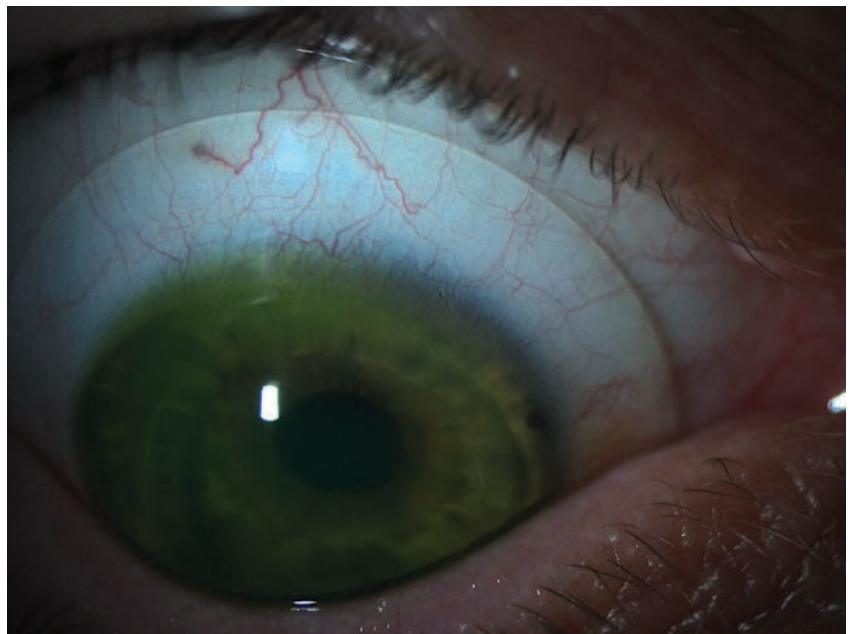


Fig. 2. A scleral lens with appropriate alignment to the scleral shape.

GET STARTED WITH SCLERALS

with the difference will make lens fittings and selections much more efficient.

For example, imagine your initial lens has far too much apical clearance and you need to decrease it by around $300\mu\text{m}$. If the set has a $100\mu\text{m}$ difference between lenses, you need to jump down three lens steps to reach ideal corneal vault. For a set with a $300\mu\text{m}$ difference, meanwhile, you only need to jump one lens step to achieve the required vault. Getting a feel for this can take some practice. In cases where I can visualize a patient's corneal ectasia by looking at their corneal profile from outside the slit lamp, I select a lens from the deeper end of the fitting set. If the corneal shape looks normal to the naked eye, I start with a lens from the shallower end of the set instead.

Once you've made an appropriate selection, it's time to prep the lens for application. Start by placing a clean lens on a large DMV lens plunger (DMV Corp.) and filling it with preservative-free saline. Next, dab a sodium fluorescein strip in the saline to lightly dye the liquid. Now you can apply the lens evenly to the ocular surface, making sure to avoid forming bubbles in the lens chamber. With scleral lenses, a bubble under the lens will not work itself out as it would with some corneal GP lenses, so the lens must be removed and reapplied when a bubble forms. The Scleral Lens Education Society website (www.sclerallens.org) provides an in-depth list of application and removal techniques you might find helpful.

EVALUATE THE FIT

With the lens on eye, the fit evaluation can begin. Evaluating a scleral lens used to have an artsy/

instinctive feel, and while there still is an art to lens modifications, instruments such as anterior segment OCT and scleral topographers have dramatically improved our ability to analyze how a lens behaves on an eye. With technologies like these, clinicians can determine the clearance between the lens and corneal apex as well as the amount of scleral toricity. These advances are getting us closer and closer to empirically designed scleral lenses, but for now an in-office fitting from a trial set is still the first step.

Start by evaluating the central vault at the slit lamp and compare the clearance of the lens over the cornea with the lens thickness at the anterior-most point of the cornea. If the vault is significantly thicker, the lens is too deep and you'll need to switch it out for another one. The lens should also be replaced if it shows cornea touch or minimal central clearance.

Next, move the slit beam from

the central cornea through the mid-peripheral cornea and to the limbus to evaluate the amount of clearance over the limbus. Keep in mind that while there may be clearance over the limbus, fluorescein is not always visible in small spaces. In these cases, OCT measurements are needed to confirm clearance. Ideal measurements have changed over the years, but today acceptable amounts range from about $250\mu\text{m}$ to $100\mu\text{m}$ of central clearance and about $20\mu\text{m}$ to $40\mu\text{m}$ over the limbal area after lens settling.³ Scleral lenses settle into the conjunctival tissue between $76\mu\text{m}$ and $146\mu\text{m}$ on average; thus, at the initial scleral lens evaluation, your goal corneal vault should be about $150\mu\text{m}$ greater than the desired endpoint (*Figure 1*).^{4,5}

Last but not least, evaluate the relationship between the lens and the scleral surface. The vasculature under the lens landing curves should appear normal and without

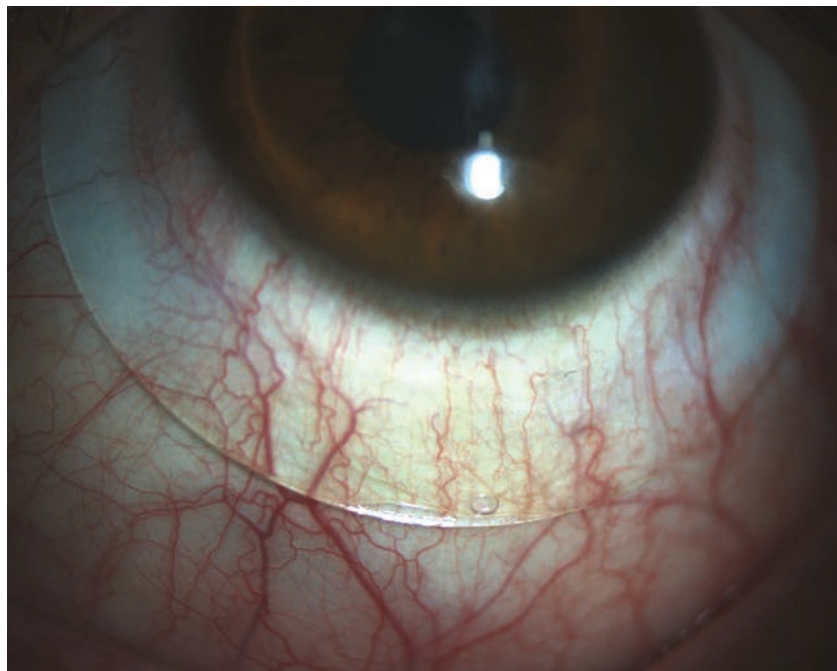


Fig. 3. A scleral lens showing both compression and edge lift in the landing zone. A toric peripheral curve system would improve the alignment of this lens.

compression or impingement (Figure 2). If the edge of the lens is digging into the conjunctival tissue, causing a visible gutter or compression ring after the lens is removed, you'll need to flatten the peripheral curves. Steeper peripheral curve systems are also necessary if the patient comments on lens awareness or if debris seeps into the fluid chamber and cloud the patient's vision.

If a scleral lens patient requires both steeper and flatter curves, you'll need to turn to a toric peripheral curves system. In these cases, there may be obvious compression in the nasal-temporal meridian and edge lift superior-inferior, or just asymmetry in the appearance of the vasculature under the lens landing curves (Figure 3).

The process of determining power with a scleral lens fit is similar to any other contact lens design. Since over-refractions do not change significantly as the lens settles, you can perform them soon after the lens is placed on the eye.⁶ Retinoscopy is a great starting point because it gives you an idea of the improvement in the corneal reflex through the lens material. Try a spherical over-refraction and assess visual acuity and vision quality. If the visual acuity is unacceptable, repeat the over-refraction with a spherocylindrical assessment. If this improves the patient's visual acuity, a consultant from your laboratory can help you decide if a front-toric scleral lens design is the best route or if a design change may negate some of the astigmatism in the over-refraction.

MAKE ADJUSTMENTS

More often than not, lens shape adjustments are needed to achieve an optimal fit. Some basic tweaks

include vault and peripheral curve changes, while more advanced techniques include working around pingueculae and other bumps in the conjunctiva (Figure 4).

When changing the central vault of the lens, be sure to evaluate the highest point of the cornea, which is not always at the center of the lens. For example, in most keratoconus patients, the apex may be below the line of sight, and in post-keratoplasty patients it may be in the superior cornea. Also, be sure to specify whether you need to increase clearance throughout the entire lens chamber or just at the central area.

Limbal curve adjustments can be made in two ways. The first option is to adjust where the curves land on the sclera. If insufficient limbal clearance is present, you can make the corneal chamber larger so the lens lands posterior to the limbus rather than on top of it. This tends to be the case for patients with large corneal diameters. The second option is to adjust the angle at which the curve contacts the scleral surface. If the angle is too wide and excessive limbal clearance exists, the patient may say the lens feels tight after a few hours of wear. If the angle is too shallow and it causes the lens to land on the limbus or peripheral cornea, the patient may complain of pain and the lens will move with the blink.

The peripheral curve system is designed to fit the contour of the sclera, which can vary greatly in shape from patient to patient. One indication for adding a toric peripheral curve system

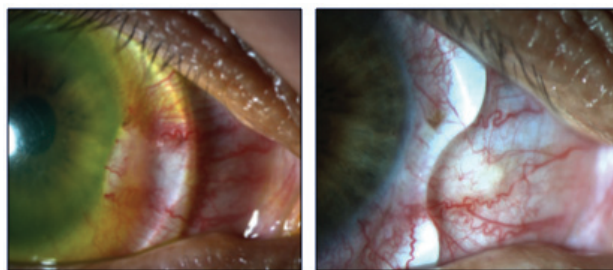


Fig. 4. A notched scleral lens will decrease irritation of a pinguecula.

to a scleral lens is significant lens movement on blink. This indicates a loose superior-inferior meridian, allowing the lens to rock back and forth on the steeper scleral curves. Another indication is the patient commenting on progressive clouding of the fluid chamber, which could also indicate a loose edge. Lastly, toric peripheral curve systems can improve scleral lens centering and, as a result, overall performance of the lens optics, especially in cases of front-toric or multifocal prescriptions.

The basic fitting techniques described here are enough to get you started with scleral lens prescriptions in your practice. While the initial learning curve may seem steep, scleral lenses can provide you and your patients with rewards that far outweigh the required effort. [RCL](#)

1. Nau CB, Harthan J, Shorter E, et al. Demographic characteristics and prescribing patterns of scleral lens fitters: The SCOPE Study. *Eye Contact Lens*. June 14, 2017. [Epub ahead of print].
2. Schornack M, Patel S. Relationship between corneal topographic indices and scleral lens base curve. *Eye & Contact Lens*. 2010;36(6):330-3.
3. Jedlicka J. Critical measurements to improve scleral lens fitting. *Rev Cornea Cont Lens*. 2015;152(6):26-31.
4. Vincent S, Alonso-Caneiro D, Collins M. The temporal dynamics of miniscleral contact lenses: central corneal clearance and centration. *Cont Lens Anterior Eye*. July 14, 2017. [Epub ahead of print].
5. Caroline P, Andre M. Scleral lens settling. *CL Spectrum*. 2012;27(5):56.
6. Bray C, Britton S, Yeung D, et al. Change in over-refraction after scleral lens settling on average corneas. *Ophthalmic Physiol Opt*. 2017;37(4):467-72.

Foggy with No Chance of Moisture

Poor front surface wettability and lens fogging can complicate scleral lens wear; identifying the cause can help you pick the right treatment strategy.

By Melissa Barnett, OD

In recent years, scleral lens popularity has grown tremendously, with fits and refits up to 16% in 2017 compared with 13% in 2016.¹ Although these lenses are problem solvers that can correct for anything from irregular astigmatism and severe ocular surface disease to refractive error and mild-to-moderate dry eye disease, they also present some unique challenges.²

For many scleral lens wearers, the fit may be pristine, the patient may report excellent vision and comfort and handling may be smooth, but poor anterior lens surface wetting hampers comfortable long-term wear (Figure 1). This common issue can cause suboptimal or “cloudy” vision, diminished lens comfort and increased chair time and cost for both the patient and practitioner.³

Also, minimal tear exchange exists during scleral lens wear, causing the potential for fogging in the post-lens fluid reservoir.^{4,6} Debris accumulation between the scleral lens and cornea can cause lens fogging either rapidly after insertion (sometimes even during the diagnostic lens fitting) or more slowly, worsening throughout the day.^{7,8}

This article discusses the causes of these two frustrating complications in scleral lens wear—and how you can combat them in your practice.

WHAT'S BEHIND THE CURTAIN

Understanding the risk factors and underlying mechanisms at play can

help you better understand why a patient is struggling with wettability, fogging or both.

Wettability refers to how easily a liquid spreads over the surface of a contact lens. It is determined by the wetting angle or contact angle. The contact angle is the angle formed when a drop of liquid is placed on a surface. This angle determines the ability of moisture to spread. Small contact angles are associated with an increased ability of the tears to spread over the surface of a contact lens, leading to a more stable tear film.⁹⁻¹¹ A contact angle of zero degrees is a completely wettable surface.^{12,13}

Patients with certain ocular surface diseases are especially at risk for poor surface wettability. Poor tear film quality and stability, lens surface deposits, eyelid disease, allergies, environmental factors and medications can all impede successful contact lens wear.¹⁴

This includes those with meibomian gland dysfunction (MGD), ocular rosacea, atopic conditions, graft-versus-host disease, Stevens-Johnson syndrome, Sjögren's syndrome and other severe ocular surface diseases or filamentary keratitis.

Other culprits for poor surface wettability include excessive lipids in the tear film, exposure from eyelid surgery such as ptosis repair or blepharoplasty, a history of stroke or nerve palsy, poor scleral lens plunger hygiene and use of make-

up or oil-based skincare products such as lotions, makeup removers and hand soaps with moisturizing agents. Occasionally, older blocking compounds used during lens manufacturing such as blocking pitch or wax may be the culprit. Exposed silicone on gas permeable lenses, which are innately hydrophobic, inhibits lenses from wetting completely. Low-melt wax is recommended for gas permeable materials due to the polymers being sensitive to heat that could impact the on-eye performance of the material.

Fogging. Risk factors for, and causes of, this complication are not so easily identified. Even with an ideal scleral lens fit and a thorough lens care regimen, fogging may still occur. Factors that have been linked to scleral fogging include increased accumulation of tear debris in the lens reservoir, minimal tear exchange, increased mucin production from conjunctival tissue rubbing, accumulation of protein and lipid deposits on the front surface of the lens and corneal edema.¹⁵

ABOUT THE AUTHOR



Dr. Barnett is a principal optometrist at the University of California Davis Eye Center in Sacramento, Calif. and Past President of the Scleral Lens Education Society. She is a fellow of the American Academy of Optometry, a diplomate of the American Board of Certification in Medical Optometry and a fellow of the British Contact Lens Association.

FINDING CLARITY

Today, practitioners dealing with poor wettability or lens fogging in their scleral lens wearers have a number of management strategies at their disposal. Here's how to approach these tricky complications:

Wettability. The first strategy to improve surface wettability in scleral lens patients is simply lens removal, manual cleaning to eliminate deposits (and improve the lens surface), rinsing and reapplication. However, this may be time consuming and inconvenient.

For patients concerned about finding the time and a clean location to perform these steps, on-eye surface cleaning using a saline moistened cotton swab, moistened eye shadow applicator or wet DMV applicator can be used to remove surface debris. Using preservative-free artificial tears throughout the day to increase lubrication over the lens may also be beneficial.

Treating the patient's underlying condition will yield the best outcome for lens surface wettability. For example, when dealing with poor surface wettability due to MGD, aggressive treatment is critical. If ocular surface disease is not properly managed, the scleral lens surface may continue to be compromised despite changes in lens material and designs.⁴

Management strategies for these patients include commercial eyelid cleaners, warm compresses, topical eye drops, oral antibiotics and topical antibiotic ointment in the evening. Clinicians should ensure patients using topical antibiotic ointment are educated on the need to remove the ointment using a warm compress on a closed eye prior to scleral lens application. Dietary changes such as omega fatty acid supplementation and reducing fried and fatty foods may help reduce anterior surface debris by

creating a more stable and healthier tear film.

Residue left on scleral lens plungers can compromise front surface wettability, and daily disinfection with alcohol may disrupt the hydrophilic lens surface, cause cracks and prevent good suction on the lens. As such, plungers eventually need to be replaced. Some practitioners recommend replacement every three to six months, similar to contact lens case replacement, or sooner if the plunger edges become rough and uneven or if suction is insufficient.^{16,17}

A material with a low wetting angle may improve lens wettability and reduce hydrophobic areas that can attract deposits. In one study, GP materials with a lower wetting angle (less than 90 degrees) may have improved on-eye wettability.¹⁸

Plasma treatment may be a unique option to combat lens surface wettability issues. During this process, a finished GP lens surface is bombarded with high frequency radio waves in an ionized gas chamber. This makes hydrophobic surfaces more hydrophilic. Once treated, the lens surface will become ionized, increasing its ability to attract liquids. This results in a decreased (and thus improved) wetting angle, surface tension and deposition of lipids, proteins and bacteria.¹⁹ Additionally, this improves wettability and resistance to protein and bacterial deposits. In addition, patients will experience less lens awareness and improved comfort.

Fogging. When dealing with this issue, it is first important to distinguish between anterior surface fogging and post-lens tear reservoir fogging. To do this, note whether the appearance of the presenting fog is more like oil on water or whether it looks milk-like. The former points

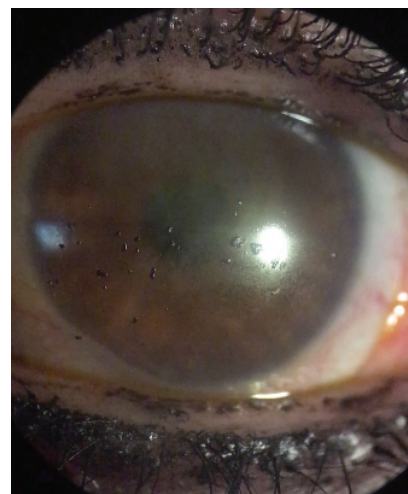


Fig. 1. A scleral lens with front surface debris, as seen here, could cause wettability issues or fogging, both of which complicate comfortable lens wear.

to anterior surface fogging while the latter represents post-lens tear reservoir fogging.

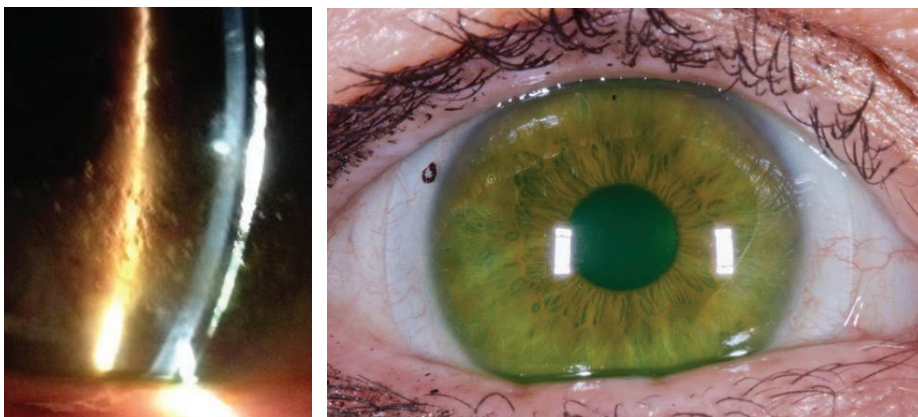
Clinicians should also rule out corneal edema before assuming the issue is scleral lens fogging. If the patient has hazy vision and sees rainbows around lights, it is critical to evaluate the cornea for microcystic edema, also known as Sattler's veil. If this is present, scleral lens removal and reapplication will not resolve symptoms—instead, the patient needs medical management for the underlying condition. In these cases, scleral lens wear may need to be discontinued completely or may be worn on a limited wear basis. Instruct patients to monitor how many hours scleral lenses are worn prior to experiencing hazy vision or rainbows around lights. Be sure to specify prescribed scleral lens wearing time for each eye.

If patients are otherwise healthy, management for lens fogging due to debris varies depending on the type of debris you're dealing with.²⁰

Opaque, white, fluffy, small debris in the post-lens fluid reservoir is known as mucin debris. For these cases, practitioners should first

FOGGY WITH NO CHANCE OF MOISTURE

Images: Tom Arnold, OD



Figs. 2a and 2b. At left, significant surface debris on the lens surface before Hydra-PEG treatment. At right, improved surface wettability after Hydra-PEG treatment.

evaluate the scleral lens fit and look for any signs of giant papillary conjunctivitis (GPC) or peripheral edge lift of the lens.

If GPC is present, try prescribing mast cell stabilizer antihistamine drops, reducing lens wearing time and deep cleaning the lens with sodium hypochlorite-potassium bromide-based system, alcohol based cleaners and enzymatic cleaners. If the lens is treated with Tangible Hydra-PEG (Tangible Science), however, only the first two options are recommended, as deep cleaning will remove the coating.

If peripheral edge lift of the lens is present, the lens edge to eyelid interaction may be the source of the papillary reaction. From there, management strategies include eliminating peripheral edge lift by tightening the peripheral curves or adding toric peripheries, reducing lens wearing time, removing and reapplying the lens, cleaning the lens with an enzymatic cleaner or a sodium hypochlorite-potassium bromide-based system and eliminating preservatives in the cleaning or soaking solution.

The second type of debris has to do with an association between atopic disease and keratoconus.²¹ These patients present with a diluted milk-like fogging in the post-lens

fluid reservoir under the lens. Here, treatment options include reducing excessive edge lift, reducing toric peripheries (if the lens has meridional edge lift), topical mast cell stabilizers, topical (soft) steroids in extreme cases and lens removal and reapplication. Practitioners should also carefully monitor intraocular pressures and rule out infection for patients on daily steroids is strongly advised due to the risk for increased intraocular pressure, cataracts and glaucoma.²² Soft steroids generally come with fewer risks.

Lastly, meibomian debris, caused by MGD or blepharitis, is semi-transparent and looks like olive oil floating on water. Often, it can be refractile and a yellowish color. Aggressively treating the eyelids can reduce this debris. Reducing excessive tear exchange by altering the peripheral curves of the scleral lens can also be beneficial for these patients. If issues with meibomian debris persist, try removing and reapplying the lens.

It's worth noting that these three types of debris can occur in combination.²⁰ As a result, multiple management strategies may be needed.

Knowing where front surface debris is coming from can also steer your management. A murky lens surface may be due to external

sources such as oil-based lotions, makeup or face and hand soaps. In these cases, verify that the patient washes their hands with mild hand soaps such as contact lens or acne treatment hand soaps before handling their lenses and make sure they apply face cream or makeup after lens application. Patients should also avoid using oil-based moisturizers on the eyelids and applying makeup to the inside area of the eyelid margin or meibomian

gland orifices, as this increases the risk for MGD or obstruction.²³

For patients who regularly wear makeup, using eyeliner pencils and sharpening them before every application can help avoid debris issues.²³ Some additional tips for makeup-wearing patients include:²³

- Replace moist cosmetics such as mascara monthly.
- Clean makeup brushes regularly.
- Remove makeup daily with a makeup remover or eyelid hygiene product.
- Avoid use of facial cleansers or hand soap to remove eye makeup.
- Remove makeup after removing scleral lenses to prevent lens surface residue.

KEEPING IT SPICK AND SPAN

Many strategies can help improve both lens surface wettability and lens fogging. Hydrogen peroxide can be helpful in eradicating lens surface deposits, and according to the Scleral Lenses in Current Ophthalmic Practice study, it is the most commonly recommended disinfection system for this modality.²⁴ Hydrogen peroxide-based solutions are effective for all scleral lenses, especially if the patient has a sensitivity to chemicals or preservatives.

The majority of scleral lenses fit in a standard hydrogen peroxide

lens case. However, since these cases were not designed for scleral lens use, some larger diameter lenses may require a larger case. Make sure your patients avoid using tap or distilled water when cleaning their lenses or storage cases due to a risk of *Acanthamoeba* keratitis.^{25,26} By the same token, patients should not store their scleral lenses in saline due to a risk of microbial keratitis.²⁷

Traditional gas permeable (GP) contact lens disinfection solutions are thick and viscous, which could result in chamber debris and lens surface fogging. As such, some patients may require additional cleaners. Here, alternating between a daily GP lens cleaner and an extra strength or alcohol-based daily cleaner could be helpful.

Patients can add proteolytic enzymes in liquid form such as Opti-free Supraclean (Alcon) and Boston One Step Liquid Enzymatic Cleaner (Bausch + Lomb) directly to hydrogen peroxide or other GP disinfection solutions to remove protein. Some effective alcohol-based cleaners with manual rubbing, meanwhile, include MiraFlow or Optimum extra strength cleaner (Lobob Laboratories).

Another option is Menicon Progent, a chemical biweekly cleaner with a 30-minute soak. This contains sodium hypochlorite and potassium bromide, which serve to loosen and remove surface protein, deposits, bacteria, fungus, molds and yeasts after a 30-minute soak without manual rubbing.²⁸

TREAT THE LENS, NOT THE PATIENT

Tangible Hydra-PEG is a newly FDA-approved treatment option that can help address both wettability and lens fogging concerns. It consists of a 90% water polyethylene glycol-based polymer mixture that permanently encapsulates the lens.

This creates a mucin-like wetting surface that shields the lens from the ocular surface and tear film. Hydra-PEG may be used on any type of contact lens to achieve optimal wettability, lubricity, tear film stability and resistance to deposits, so it is no surprise that the treatment has been effective for scleral lens wearers (*Figures 2a and 2b*).²⁹

Although Hydra-PEG can be used by any contact lens patient, good candidates include scleral lens wearers with a heavy amount of deposits, those experiencing dry eye or discomfort with their lenses and those experiencing lens fogging. Further, Hydra-PEG has no contraindications and requires no lens design changes.

As always, patient education on lens handling remains imperative, especially considering Hydra-PEG treatment results in a more slippery scleral lens. Patients should be instructed to clean their lenses daily with a multi-purpose or hydrogen peroxide solution and to avoid tap water and abrasive or alcohol-based solutions.

Scleral lenses can be a great option for any number of patients, even if wettability and fogging enter the clinical picture. These management strategies, along with proper lens care, can go a long way to ensure healthy life-long scleral lens wear for your patients.

1. Nichols J. Contact lenses 2017. CL Spectrum. January 1, 2018. www.clspectrum.com/issues/2018/january-2018/contact-lenses-2017. Accessed March 22, 2018.

2. van der Worp E, Bornman D, Ferreira DL, et al. Modern scleral contact lenses: A review. Cont Lens Anterior Eye. 2014;37(4):240-50.

3. Barnett M, Toabe M. Scleral lens care and handling. CL Spectrum. October 1, 2016. www.clspectrum.com/supplements/2016/october-2016/scleral-lenses-understanding-applications-and-max/scleral-lens-care-and-handling. Accessed March 22, 2018.

4. Barnett M, Johns LK, eds. Contemporary Scleral Lenses: Theory and Application. Sharjah, UAE: Bentham Science Publishers; 2017.

5. Vance KD, Miller W, Bermangson J. Measurement of tear flow in scleral contact lens wearers. Poster presented at the Annual American Academy of Optometry Meeting, 2015; New Orleans.

6. Visser ES, Visser R, Van Lier HFF, Otten HM. Modern scleral lenses part II: patient satisfaction. Eye Cont Lens. 2007;33(1):21-5.

7. McKinney A, Miller W, Leach N, et al. The cause of midday visual fogging in scleral gas permeable lens wearers. Invest Ophthalmol Vis Sci. 2013;ARVO E-abstract 5483.

8. Walker MK. Scleral lenses, clearing the fog. ISITE Online J. October 2014. www.netherlens.com/october_2014. Accessed March 29, 2018.

9. Lin MC, Svitova TF. Contact lenses wettability in vitro: Effect of surface-active ingredients. Optom Vis Sci. 2010;87:440-7.

10. Maldonado-Codina C, Morgan PB. In vitro water wettability of silicone hydrogel contact lenses determined using the sessile drop and captive bubble techniques. J Biomed Mater Res A. 2007;83:496-502.

11. Tonge S, Jones L, Goodall S, Tighe B. The ex vivo wettability of soft contact lenses. Curr Eye Res 2001;23:51-9.

12. French K. Contact lens material properties: Part 1 - Wettability. Optician. 2005;230:20-8.

13. Campbell D, Carnell SM, Eden RJ. Applicability of contact angle techniques used in the analysis of contact lenses, part 1: comparative methodologies. Eye Cont Lens. 2013;39:254-62.

14. Sindt CW, Longmuir RA. Contact lens strategies for the patient with dry eye. Ocul Surf. 2007;5(4):294-307.

15. Barnett M, Johns LK, eds. Contemporary Scleral Lenses: Theory and Application. Sharjah, UAE: Bentham Science Publishers; 2017:326-34.

16. Vijay A, Willcox M, Zhu H, Stapleton F. Contact lens storage case hygiene practice and storage case contamination. Eye Contact Lens. 2014;41(2):91-7.

17. Barnett M, Johns LK, eds. Contemporary scleral lenses: theory and application. Sharjah, UAE: Bentham Science Publishers; 2017:346-70.

18. Bennett E, Henry V. Clinical Manual of Contact Lenses, 4th ed. Philadelphia: Lippincott Williams and Wilkins; 2014:94.

19. Huang Y. The application of low-temperature plasma technology on the surface modification of biomaterials. Mater Rev. 2004;18:72-4.

20. Walker M, Morrison S, Caroline P, et al. Laboratory analysis of scleral lens tear reservoir clouding. Poster presented at the 2014 Global Specialty Lens Symposium, January 2014; Las Vegas.

21. Harrison RJ, Klouda PT, Easty DL, et al. Association between keratoconus and atopy. Br J Ophthalmol. 1989;73(10):816-22.

22. Abelson M, Sleeper A. Insights on anti-inflammatories. Rev Ophthalmol. 2005;12(6):80-4.

23. O'Dell L, Sullivan AG, Perriman LM. When beauty talk turns ugly. Advanced Ocular Care. January 2017.

24. Harthan J, Nau CB, Barr J, et al. Scleral lens prescription and management practices: The SCOPE study. Eye Cont Lens. 2017 Apr 6. [Epub ahead of print].

25. Bonilla-Lemus P, Rameriz-Bautista GA, Zamora-Munoz C, et al. Acanthamoeba spp. in domestic tap water in houses of contact lens wearers in the metropolitan area of Mexico City. Exp Parasitol. 2010;126(1):54-8.

26. Legarreta JE, Nau AC, Dhaliwal DK. Acanthamoeba keratitis associated with tap water use during contact lens cleaning: manufacturer guidelines need to change. Eye Cont Lens. 2013;39(2):158-61.

27. Mela EK, Anastassiou ED, Gartaganis SP, Christofidou M. Fungal isolation from disinfectant solutions of contact lens storage cases among asymptomatic users. Eye Cont Lens. 2015;41(2):87-90.

28. Barnett M, Johns LK, eds. Contemporary Scleral Lenses: Theory and Application. Sharjah, UAE: Bentham Science Publishers; 2017:350-50.

29. Walker M, Redfern R. Scleral lens surface coating improves vision and comfort. Poster presented at the 8th International Conference of the Tear Film and Ocular Surface Society, September 2016; Montpellier, France.

Don't Hold Back

There are many good reasons to switch patients to silicone hydrogel—whether they're wearing frequent replacement or 1-day lenses.

If you ask most optometrists which lens material is their go-to for monthly and two-week fits, the answer is overwhelmingly silicone hydrogel. Due to its increased oxygen transmissibility, silicone hydrogel offers patients a healthier* lens-wearing experience. Indeed, on average, ECPs fit 91% of their monthly and two-week contact lens wearers in silicone hydrogel lenses. This is in stark contrast to how many 1-day patients they fit in silicone hydrogel—they fit only 30% of 1-day patients in silicone hydrogel.

This begs the question: Why don't doctors routinely fit 1-day wearers in the same material they prefer for frequent replacement wear? Unfortunately, the answer to this question remains a mystery, particularly in light of startling new research, which demonstrates that doctors' lens prescribing patterns lag far behind their beliefs about what's best for patients.

We spoke with three optometrists for insight on this disconnect between beliefs and behavior. In the interviews that follow, these 1-day silicone hydrogel advocates explain why they are committed to this material for 1-day fits and share advice on how to always recommend the lens you trust the most.

Is hydrogel good enough for most 1-day lens wearers?

Dr. Rosinski: I strongly believe that silicone hydrogel 1-day lenses provide better long-term eye health for my patients than hydrogel 1-day lenses. Furthermore, 91% of my colleagues agree according to recent research. We also need to consider the increasing demands of modern life. In this digital era, patients are prone to dryness, discomfort and fluctuating vision. Silicone hydrogel lenses outperform hydrogel in terms of all-day comfort and eye health. Furthermore, we know from experience with frequent replacement lenses that increased oxygen permeability leads to clinically meaningful outcomes. It has an impact on corneal edema, limbal hyperemia, neovascularization, refractive error change, epithelial thinning, and more. With all this in mind, I would say silicone hydrogel is an obvious choice for the health and comfort of 1-day lens wearers.

The Practitioners



Melanie Frogozo
OD, FAAO, FSLs
The Contact Lens Institute of San Antonio
San Antonio, Texas



Ethan E. Huisman
OD, FAAO
Elite Eye Care
West Des Moines, Iowa



Steve Rosinski
OD
Crozet Eye Care
Charlottesville, Virginia

Dr. Huisman: I have a relatively young patient population, so I'm very focused on preserving ocular surface health for 20, 30 or even 40 years or more. In my practice, making compromises isn't in the patient's long-term best interests. Also,

consider the fact that more than 75% of contact lens wearers admit to napping in their lenses and 28% admit to sleeping in their lenses at least once a month. Whether they are telling you about it or trying to hide from you, these patients need as much oxygen as they can get—no matter how frequently they replace their lenses.

Dr. Frogozo: I agree. We need to be more realistic about how our patients are wearing their lenses. The reality is that most patients don't wear their lenses for just a few hours per day. Research shows that 1-day wearers in the U.S. habitually wear their contact lenses for at least 15 hours per day, seven days per week. Before reaching for a 1-day hydrogel, ask yourself if hydrogel would be your first choice for the patient if he or she was wearing a frequent replacement lens. If the answer is no, then why would you deprive the 1-day wearer of this same opportunity?

What meaningful advantages does silicone hydrogel have in a 1-day lens?

Dr. Frogozo: I agree with 92% of ECPs who say silicone hydrogel 1-day lenses are the best choice to safeguard patients' eye health related to contact lens wear. This same study shows that 92% likewise believe that silicone hydrogel 1-day lenses provide the best benefits to their patients. In terms of my own personal beliefs and how that guides how I practice, I'm concerned that the hydrogel wearer will develop hypoxia and eventually drop out of lens wear. It's a familiar story that we've seen play out when hydrogel was the go-to lens in frequent replacement.

Dr. Huisman: Doctors want health, but patients care about comfort. Silicone hydrogel 1-day lenses offer both.



with the current lenses, I shift the conversation focus around preventative care.

Dr. Frogozo: My practice is primarily referral-based, which means patients walk in wearing many different types

of lenses. Despite this, I fit my sphere patients almost exclusively in 1-day silicone hydrogel lenses. And, as the toric parameters expand, I'm fitting more and more astigmats in 1-day silicone hydrogel as well. Patients rarely object to my recommendation. I proactively educate my patients on the need for oxygen in lens wear and advise them that silicone hydrogel is healthiest.

Dr. Rosinski: I go beyond generic, traditional questioning. You won't get much information by asking, "how are your contacts?" Patients are likely to say, "FINE," which in my view means "Feelings I've Not Expressed." The more pointed questions you ask, the more you are likely to discover something to improve upon. Upgrading to silicone hydrogel doesn't require a huge change in mindset for a current 1-day wearer. On the contrary, it's an obvious choice because 1-day patients are already health conscious. Moving to silicone hydrogel is simply a logical next step.

Does the lens trial play a significant role in convincing 1-day wearers about the benefits of silicone hydrogel?

Dr. Frogozo: In my practice, the conversation is usually more powerful

than the trial. A strong recommendation from a doctor is all most patients need to hear. If you believe silicone hydrogel is a superior material, the patient will likely believe it too. However, if you have a patient who is already wearing a 1-day lens in a hydrogel material and you want to switch to silicone hydrogel, the lens trial can be a tipping point. In these cases, I tell the patient that their current lenses are based on older technology, so I'm offering them an opportunity to trial something newer and healthier.

Dr. Huisman: I agree. Trials are great but the conversation has to precede it. I don't want patients to think I'm making a change for change's sake. Eighty-two percent of ECPs believe that silicone hydrogel should be the standard of care for 1-day contact lens patients and 87% say silicone hydrogel material should be the first choice of material for daily disposable lenses. When patients hear that from us, they're more likely to approach the lens trial with enthusiasm.

Dr. Rosinski: Trialing silicone hydrogel 1-day lenses also helps strengthen our relationships with patients. First, we make the recommendation and educate the patient on the benefits. Next, they take the lens for a test drive. Finally, when they return satisfied with the comfort and vision of their new lenses, they're more confident than ever in our knowledge and our commitment to providing the best possible care.

Silicone hydrogel 1-day lenses are great for my younger patients because they're so easy to insert and remove—plus they're extremely comfortable. My patients aren't rushing home from work so they can take out their lenses. That's a meaningful, practical advantage.

Dr. Rosinski: The number one advantage is ocular health. When the clariti 1 day family of lenses was introduced, it was a no-brainer for me to switch my 1-day patients. Silicone hydrogel creates a highly "breathable" lens that promotes whiter, brighter** eyes.

How do you get patients on board with your decision to switch to a silicone hydrogel material—especially if they seem happy with their current hydrogels?

Dr. Huisman: Patients are confident in your recommendation when you cite a specific reason for change. I educate them on the benefits and advantages of silicone hydrogel generally and for their case specifically. Quite often, my hydrogel patients have signs of neovascularization or hyperemia, so I take a photo of this and show it to the patient, explaining that this is the reason change is needed. In the event that the patient has no signs and is very happy

More Options Help You Offer What's Best, More Often

Offer your 1-day contact lens patients a healthier lens-wearing experience. CooperVision's broad range of silicone hydrogel 1-day contact lenses can provide up to four times more oxygen transmissibility than traditional hydrogel contact lenses. From the clariti® 1 day family to MyDay®, you can fit virtually all patients into a 1-day contact lens that provides high oxygen, comfort, and convenience.

For more information, visit Coopervision.com



* With higher oxygen permeability than hydrogel materials, silicone hydrogel contact lenses minimize or eliminate hypoxia-related signs and symptoms during lens wear.

** Data on file; clariti® 1 day offers whiter eyes than 1-DAY ACUVUE® MOIST®.

POST-KERATOPLASTY: Consider Sclerals

Corneal GP lenses have traditionally been a go-to option for these cases, but some patients may benefit from another modality.

By Jennifer S. Harthan, OD

Contact lens fitting has always played a valuable role in the visual rehabilitation following keratoplasty. Many types of lenses can be used in the management of patients who have undergone corneal transplantation (ranging from full-thickness keratoplasty to anterior and posterior lamellar keratoplasties), including custom soft lenses, corneal gas permeable (GP) lenses, hybrid lenses, piggy-back lenses and sclerals. However, these patients often present with varying degrees of corneal elevation, as well as high amounts of astigmatism and lack of symmetry, making the fit a challenge. As a result, many patients experience suboptimal vision and contact lens intolerance when fit with traditional soft or GP contact lens options. In these cases, scleral lenses in particular may be able to help.

KEYS TO A POST-OP FIT

Keratoplasty procedures continue to evolve. Only the diseased or affected layers of the cornea are replaced during anterior and posterior lamellar procedures (deep anterior lamellar keratoplasty [DALK], Descemet's stripping automated endothelial keratoplasty [DSAEK] and Descemet's membrane endothelial keratoplasty [DMEK]) compared

with the entire cornea during a full-thickness penetrating keratoplasty (PKP).

Complications have decreased and visual outcomes have improved with newer lamellar procedures.¹⁻⁴ Patients who have undergone posterior lamellar procedures tend to have less surface irregularities compared with those who have had an anterior lamellar or PKP. Following a DSAEK or DMEK procedure, spectacles or traditional contact lens options tend to provide satisfactory visual improvement unless corneal scarring has occurred.⁵

Following a PKP, the epithelium is more fragile, and the endothelial cell density (ECD) is lower. Post-PKP corneas in particular are more prone to inflammatory events, increased risk of neovascularization and rejection.^{4,6}

Contact lenses may be required following keratoplasty to enhance vision and to rehabilitate the ocular surface.⁷ These factors should influence the practitioner's decision in selecting a contact lens.

Additional factors practitioners should consider when determining which type of contact lens to fit post-procedure include the amount of astigmatism present, any ocular surface disease, diameter, location and shape (prolate or oblate) of the graft, elevation between

the host and donor cornea, and amount of corneal eccentricity.¹⁰⁻¹² A contact lens fitting may also be needed to improve a patient's anisometropia or aniseikonia.⁷

While some patients have sutures remaining following keratoplasty, it is generally safe to proceed with contact lenses. However, protruding or exposed sutures may cause irritation, infection or stimulate neovascularization, so they must be removed promptly.^{1,7,13}

Postoperative astigmatism is the main reason for unsatisfactory vision after keratoplasty. Studies indicate between 27% and 34% of grafts have more than 3D of corneal astigmatism two years after the procedure.^{10,14,15} Corneal topography or tomography should be performed on each post-keratoplasty patient to help determine which lens option is most suitable for the corneal shape.

The donor corneal graft is usually between 7.5mm and 8.5mm in diameter. Grafts that

ABOUT THE AUTHOR

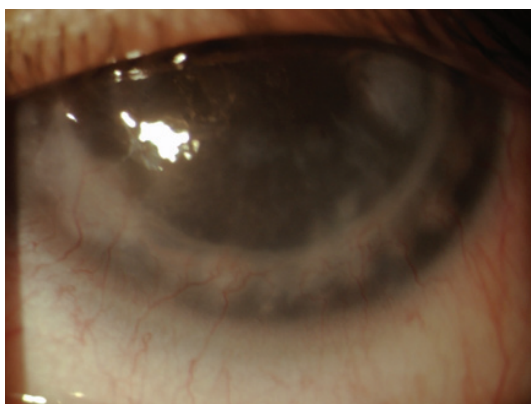


Dr. Harthan is an associate professor at the Illinois College of Optometry and chief of the Cornea Center for Clinical Excellence at the Illinois Eye Institute. She lectures, publishes and participates in research on OSD and contact lenses.

fall outside these parameters have lower survival rates and may complicate the contact lens fitting process.¹³ Grafts that are smaller than the pupil margin may cause vision distortion, and grafts close to the limbus have an increased risk of neovascularization and graft rejection.⁷

Many practitioners turn to GP contact lenses because they provide improved visual acuity, are able to correct for high amounts of astigmatism, have high oxygen permeability and are relatively low risk for the development of microbial keratitis and corneal neovascularization.^{11,15,16}

Back surface or bi-toric GP lens designs have been used in some cases; however, due to the lack of rotational symmetry they are often not indicated as a first option. Instead, larger diameter corneal GP lenses (>10mm) are typically indicated so the back optic zone radius of the lens spans the graft-host junction.⁷ Reverse geometry designs are also common, especially in slightly protruding and oblate grafts, as they provide improved vision for patients with irregular corneal surfaces and elevation differences between the graft-host junction.^{12,16}



This patient has stromal and endothelial graft rejection. Note the stromal edema and haze. The corneal neovascularization extends into two quadrants and was responsible for the rejection.

These designs have one or more peripheral curves that are steeper than the base curve.⁷

THE CASE FOR SCLERALS

Although corneal GP lenses are often the first choice for corneal transplants, they may not be the ideal option for certain complex cases. High variances in corneal curvature and elevation of the graft-host junction may cause GP lenses to decenter, leading to corneal staining and ocular inflammation.⁸

Corneal grafts that protrude slightly—as the graft is steeper than the host cornea—have a significant change in corneal curvature at the graft-host junction.^{7-9,14} When a practitioner fits these cases with corneal GP lenses, there may be edge lift and poor stability.^{7,14} This is where scleral contact lenses may be best suited.

Scleral contact lenses are large diameter GP lenses (14mm to more than 20mm) that rest entirely on the sclera.¹⁵⁻¹⁷ Scleral lenses have become more regularly prescribed for the management of corneal irregularity, uncomplicated refractive error and ocular surface disease.^{10,18-21} In 2015, the Scleral Lenses in Current

Ophthalmic Practice Evaluation study group reported that 16% of scleral lenses are being prescribed for ocular surface disease, 74% for corneal irregularity and 10% for uncomplicated refractive error.²²

Scleral lenses may provide post-keratoplasty patients with all of the benefits of corneal GP lenses in addition to a well-centered, stable fit that vaults the cornea, protects the epithelial

The Procedures:

Today, four main types of keratoplasty exist:^{2,3}

PKP. During this procedure, the entire cornea is replaced with a donor cornea. PKP may be indicated for advanced keratoconus, bullous keratopathy, corneal dystrophies and degenerations, significant corneal scarring, contact lens intolerance or when all other means of correction have been exhausted.²⁷⁻³¹ Post-procedure, patients are on chronic topical steroids and have an accelerated rate of endothelial decompensation. They are often dependent on specialty contact lenses due to irregular astigmatism and have a long visual recovery period.³¹

DALK. Here, all corneal tissue is removed except the recipient's endothelium, Descemet's membrane and, at times, deep stroma.²⁷ Indications include keratoconus, corneal scarring and any corneal dystrophy or disease not involving the endothelium. Advantages over PKP include no risk of endothelial rejection, less residual astigmatism, faster visual recovery, increased graft survival and less long-term dependence on topical corticosteroids.^{32,33}

DSAEK or DSEK. This involves removal of diseased endothelium, Descemet's membrane and posterior stroma. Indications include Fuch's dystrophy, pseudophakic bullous keratopathy, failed corneal graft and iridocorneal endothelial syndrome.

DMEK. The newest form of endothelial transplantation, DMEK replaces one layer of endothelial cells and Descemet's membrane (15µm to 20µm).²⁷ Patients with uncomplicated cases of pseudophakic bullous keratopathy, Fuch's and endothelial decompensation are potential candidates. Compared with PKP and DSEK, DMEK improves visual acuity and quality, as well as a lower rejection rate.^{1,34}

POST-KERATOPLASTY: CONSIDER SCLERALS

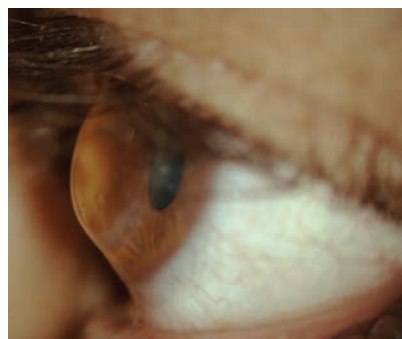surface and improves comfort. Most custom labs manufacture scleral lenses, and impression prosthetic scleral devices designed to match the contours of the eye are now available for complex graft fits. Sclerals can be designed with spherical, front-surface toric, back-surface toric or bitoric optics to optimize both scleral alignment and visual acuity.^{10,23}

While scleral lenses provide many benefits, corneal thickness and endothelial cell density (ECD) measurements should be performed on all keratoplasty patients prior to the contact lens fitting and during follow-up. For post-keratoplasty corneas that fall between 400cells/mm² and 700cells/mm², scleral lenses may be contraindicated unless the benefits outweigh the risks.

SCLERAL DESIGN CHOICES

While scleral lenses can play an important role in healing or maintaining the ocular surface in post-transplant patients, practitioners need to keep a watchful eye. The use of scleral lenses for these patients is considered controversial due to decreased oxygen transmission and unknown long-term complications.^{24,25} Here, practitioners can use topographic or tomographic maps, such as elevation maps, to review the patient's profile and identify whether or not the graft is more prolate or oblate prior to fitting.

Corneas with a prolate shape are steeper centrally and flatter in the periphery whereas oblate corneas are flatter centrally and steeper in the periphery.^{7,9,14} A corneal graft



The corneal profile of a post-PKP patient, demonstrating a prolate shape.

that has an oblate shape may require a reverse geometry or oblate scleral lens design.

Practitioners should use an optic section of the slit lamp or anterior segment optical coherence tomography to determine the amount of central corneal clearance during the scleral lens evaluation. Central corneal clearance can be estimated by comparing the center thickness of the lens with the thickness of the post-lens tear film reservoir with white light. If excessive central vault exists, practitioners should select a diagnostic lens with decreased sagittal depth. Conversely, if there is central touch, a higher sagittal depth may be needed.

Scleral lenses are thicker than corneal GP lenses and a post-lens tear reservoir is created between the lens and the cornea, potentially contributing to physiological edema at a subclinical level.²⁴⁻²⁶ One study reported that the post-lens tear layer should be no greater than 200µm to avoid corneal edema using a high Dk (>150µm) lens with a maximum central thickness of 250µm.²⁵

Once the central clearance is adequate, the next step is to ensure sufficient limbal clearance 360 degrees. Ideally, the lens edge or haptic should be aligned with the sclera. Excessive edge lift can

Density Matters

The life expectancy of a corneal graft following a PKP is between 15 and 25 years.³⁵ In the past, PKP success was determined by the maintenance of corneal clarity over time; now, success is measured by both clarity and functional vision.^{27,29,32,33}

ECD should be measured on all patients who have undergone keratoplasty prior to initiating the contact lens fitting. In a healthy adult patient, normal ECD is between 2,000cells/mm² and 2,500cells/mm².¹⁰ Corneas with ECD below 1000cells/mm² are at an increased risk for swelling and decompensation.¹² Chronic endothelial decompensation occurs when ECD is reduced to 400-700cells/mm².¹² For corneas that fall within this range, scleral lenses may not be an option unless the benefits notably outweigh the risks. ECD decreases by approximately 30% following the procedure itself, and corneas that have undergone a keratoplasty decompensate at a faster rate than normal corneas.^{29,32,33}

In patients who have undergone PKP, the average ECD is 800cells/mm² at 15 years post-procedure, which is when the cornea starts to lose its clarity.²

When using a slit lamp, it can be difficult to measure small changes in the endothelium, especially during early stages of graft rejection or endothelial dystrophy. Practitioners should perform non-contact specular microscopy on patients who have had a corneal transplant at each follow-up visit because the instrument allows for quick and accurate visualization of endothelial cell counts.^{32,33} This can also be helpful in determining when to make contact lens fitting modifications for the patient or when to refer for further surgery.⁹

be tightened while areas of vascular compression can be loosened. A toric peripheral system (some designs have four quadrant options available) may provide better alignment and centration.^{10,15} Once fit, the fluid-filled lens protects the epithelium and masks irregular astigmatism, improving best-corrected visual acuity.

POST-FIT PEARLS


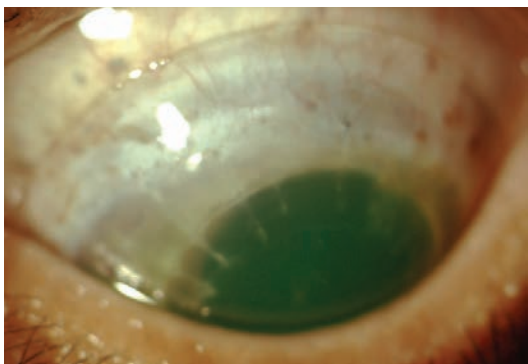
Post-keratoplasty patients fit with a scleral lens require close monitoring (every three to four months) for signs of corneal hypoxia, neovascularization or transplant rejection. In addition to careful slit lamp examination, baseline and follow-up corneal pachymetry and endothelial cell counts are essential. If signs of corneal swelling or hypoxia arise, modifying the scleral lens fit or prescribing a shorter wear time may help. If additional troubleshooting is needed, practitioners can flatten the scleral lens haptic to increase tear film exchange, use a higher Dk lens material (>150 μm) or introduce fenestrations.

Scleral lenses are quite versatile, and clinicians should not shy away from their use with this patient population. With a firm

grasp of the post-keratoplasty eye and the many contact lens parameters that can be adjusted to provide an optimal fit, clinicians can fit scleral lenses to provide visual and therapeutic enhancements for their complicated corneal transplant patients. **RCCL**

1. Melles GR. Posterior lamellar keratoplasty: DLEK to DSEK to DMEK. *Cornea*. 2006;25:879-81.
2. Melles GR, Lander F, Rietveld FJ, et al. A new surgical technique for deep stromal, anterior lamellar keratoplasty. *Br J Ophthalmol*. 1999;83:327-33.
3. Melles GR, Ong TS, Ververs B, van der Wees J. Descemet membrane endothelial keratoplasty (DMEK). *Cornea*. 2006;25:987-90.
4. Tan DT, Dart JK, Holland EJ, Kinoshita S. Corneal transplantation. *Lancet*. 2012;379:1749-61.
5. van Dijk K, Parker J, Liarakos VS, et al. Incidence of irregular astigmatism eligible for contact lens fitting after Descemet membrane endothelial keratoplasty. *J Cataract Refract Surg*. 2013;39:1036-46.
6. Panda A, Vanathi M, Kumar A, et al. Corneal graft rejection. *Surv Ophthalmol*. 2007;52:375-96.
7. Szczotka LB, Lindsay RG. Contact lens fitting following corneal graft surgery. *Clin Exp Optom*. 2003;86:244-9.
8. Severinsky B, Behrman S, Frucht-Pery J, Solomon A. Scleral contact lenses for visual rehabilitation after penetrating keratoplasty: long term outcomes. *Cont Lens Anterior Eye*. 2014;37:196-202.
9. Barnett M, Lien V, Li JY, et al. Use of scleral lenses and miniscleral lenses after penetrating keratoplasty. *Eye Contact Lens*. 2016;42:185-9.
10. Visser ES, Van der Linden BJ, Otten HM, et al. Medical applications and outcomes of bitangential scleral lenses. *Optom Vis Sci*. 2013;90:1078-85.
11. Okumura N, Kinoshita S, Koizumi N. Application of rho kinase inhibitors for the treatment of corneal endothelial diseases. *J Ophthalmol*. 2017;2017:2646904.
12. Lass JH, Sugar A, Benetz BA, et al. Endothelial cell density to predict endothelial graft failure after penetrating keratoplasty. *Arch Ophthalmol*. 2010;128:63-9.
13. Williams KA, Muehlberg SM, Lewis RF, Coster DJ. How successful is corneal transplantation? A report from the Australian Corneal Graft Register. *Eye (Lond)*. 1995;9(Pt 2):219-27.
14. Wietharn BE, Driebe WT, Jr. Fitting contact lenses for visual rehabilitation after penetrating keratoplasty. *Eye Contact Lens*. 2004;30:31-3.

15. Van der Worp E. *A Guide to Scleral Lens Fitting*. 2nd ed. Forest Grove, OR: Pacific University; 2015.
16. DeNaeyer G, Sanders DR. sMap3D corneo-scleral topographer repeatability in scleral lens patients. *Eye Contact Lens*. July 21, 2017. [Epub ahead of print].
17. DeNaeyer G, Sanders DR, Farajian TS. Surface coverage with single vs. multiple gaze surface topography to fit scleral lenses. *Cont Lens Anterior Eye*. 2017;40:162-9.
18. Pullum KW, Whiting MA, Buckley RJ. Scleral contact lenses: the expanding role. *Cornea*. 2005;24:269-77.
19. Visser ES, Visser R, van Lier HJ, Otten HM. Modern scleral lenses part II: patient satisfaction. *Eye Contact Lens*. 2007;33:21-5.
20. Visser ES, Visser R, van Lier HJ, Otten HM. Modern scleral lenses part I: clinical features. *Eye Contact Lens*. 2007;33:13-20.
21. Nau CB, Harthan J, Shorter E, et al. Demographic characteristics and prescribing patterns of scleral lens fitters: The SCOPE Study. *Eye Contact Lens*. June 14, 2017. [Epub ahead of print].
22. Shorter E, Harthan J, Nau CB, et al. Scleral lenses in the management of corneal irregularity and ocular surface disease. *Eye Contact Lens*. September 29, 2017. [Epub ahead of print].
23. Visser ES, Visser R, Van Lier HJ. Advantages of toric scleral lenses. *Optom Vis Sci*. 2006;83:233-6.
24. Walker MK, Bergmanson JP, Miller WL, et al. Complications and fitting challenges associated with scleral contact lenses: A review. *Cont Lens Anterior Eye*. 2016;39:88-96.
25. Michaud L, van der Worp E, Brazeau D, et al. Predicting estimates of oxygen transmissibility for scleral lenses. *Cont Lens Anterior Eye*. 2012;35:266-71.
26. Giasson CJ, Morency J, Melillo M, Michaud L. Oxygen tension beneath scleral lenses of different clearances. *Optom Vis Sci*. 2017;94:466-75.
27. Fares U, Sarhan AR, Dua HS. Management of post-keratoplasty astigmatism. *J Cataract Refract Surg*. 2012;38:2029-39.
28. Reinhart WJ, Musch DC, Jacobs DS, et al. Deep anterior lamellar keratoplasty as an alternative to penetrating keratoplasty: a report by the american academy of ophthalmology. *Ophthalmology*. 2011;118:209-18.
29. Sutton G, Hodge C, McGhee CN. Rapid visual recovery after penetrating keratoplasty for keratoconus. *Clin Exp Ophthalmol*. 2008;36:725-30.
30. Frost NA, Wu J, Lai TF, Coster DJ. A review of randomized controlled trials of penetrating keratoplasty techniques. *Ophthalmology*. 2006;113:942-9.
31. Brierly SC, Izquierdo L, Jr., Mannis MJ. Penetrating keratoplasty for keratoconus. *Cornea*. 2000;19:329-32.
32. Jackson AJ, Robinson FO, Frazer DG, Archer DB. Corneal guttata: A comparative clinical and specular micrographic study. *Eye (Lond)*. 1999;13(Pt 6):737-43.
33. Palay DA, Kangas TA, Stulting RD, et al. The effects of donor age on the outcome of penetrating keratoplasty in adults. *Ophthalmology*. 1997;104:1576-9.
34. Dapena I, Ham L, Melles GR. Endothelial keratoplasty: DSEK/DSAEK or DMEK--the thinner the better? *Curr Opin Ophthalmol*. 2009;20:299-307.
35. Borderie VM, Boelle PY, Touzeau O, et al. Predicted long-term outcome of corneal transplantation. *Ophthalmology*. 2009;116:2354-60.



Example of an acceptable scleral lens fit on a post-PKP patient. Central clearance is 200 μm and there is no haptic blanching or compression.

Why Contact Lens Care *Still Matters*

Daily disposables may seem like a cure-all, but patient behavior doesn't allow for such a simple solution. Here's how to navigate today's lens care environment.

By Nicole Carnt, BOptom, PhD

often come across eye care providers who primarily focus on the downsides of contact lenses, such as sterile corneal infiltrates, microbial keratitis and, in some clinics, limbal stem cell dysfunction. They often simply advise patients, “If you are going to wear contact lenses, switch to daily disposables and don't sleep in them.” Although an understandable perspective—the two main risk factors for microbial keratitis are overnight wear and poor hygiene (often involving lens reuse)—today's contact lens care landscape is not so cut and dry.¹ We can serve our contact lens patients best by understanding the spectrum of lens care options and how to educate wearers appropriately.

DAILY DISPOSABLE DILEMMA

While epidemiological studies do not show a lower risk of microbial keratitis events such as bacterial, fungal and amoebic infections with daily disposables (although there is a reduced risk of sterile corneal infiltrates), research does show a reduced rate of severe infection and vision loss.¹⁻³

This is, presumably, due to the modality's reduced need for contact lens cases, which can be colonized by *Pseudomonas aeruginosa* and other environmental organisms associated with more severe disease. Endogenous or skin-borne organisms such as *Staphylococcus epidermidis*. The latter are more common in cases of daily disposable-associated

microbial keratitis.⁴

For many, this leads to an assumption that reducing lens care needs eliminates the complications of contact lenses.

But that's not necessarily true. In a recent unpublished audit of contact lens wearers with Acanthamoeba keratitis, for example, researchers from Moorsfield Eye Hospital in London found about one-third of subjects wore daily disposables. Continued risk for infection exists, for three reasons:

1. Daily disposable wearers may be tempted to misuse the lenses by over-wearing them and storing them in the lens packaging or another convenient vesicle or solution that contains no disinfectant.

2. The increased risks associated with water-contact lens exposure during activities such as swimming, showering and using wet hands to manipulate lenses are likely just as prevalent in daily disposable lens patients as they are for reusable lens wearers.

3. Because there are fewer lens care-related steps involved, daily disposable wearers may be less likely to recognize their lenses as medical devices. Instead, many may see them as something closer to a cosmetic product.

Daily disposable lens wearers are still at risk for microbial keratitis, especially if they do not wash their hands before handling the lenses.⁴ In addition, certain types of these

lenses have been more difficult to handle and remove from the eye, often leading to adverse mechanical events, infection and inflammation.⁵

In most cases, the benefits of daily disposables outweigh the risks. However, a large patient population of reusable lens wearers still exists, both by choice and because of the wider availability of lens prescriptions. As such, contact lens practitioners cannot ignore lens care needs for these modalities, which include most presbyopic and high sphere or cylinder power soft lenses and all rigid gas permeable (GP) lenses, including the expanding orthokeratology (ortho-K) market.

SOLUTION REGULATION

Lens care systems are primarily designed to reduce microbial contamination introduced during wear and handling. The Food and Drug Administration (FDA) and the International Organization for Standardization (ISO) each specify

ABOUT THE AUTHOR



Dr. Carnt is a Scientia Research Fellow at the UNSW School of Optometry and Vision Science. Previously, she worked in private practice in Australia and the UK before taking a position with the Brien Holden Vision Institute in Sydney in 1999, where she held a variety of roles, including principal investigator on contact lens clinical trials. She completed a PhD in Epidemiology of Contact Lens Related Infection and Inflammation in 2012.

the safety and efficacy requirements for lens care products to reach the market.

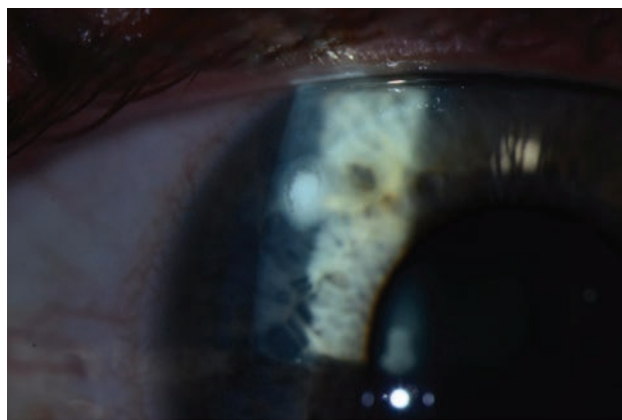Historically, the ISO has had two pathways for lens care product approval: the stand-alone test and the regimen test. In the first, a solution must reduce *Pseudomonas aeruginosa* by an inoculum of 6 log units, *Staphylococcus aureus* and *Serratia marcescans* by 3 log units and *Fusarium* and *Candida* by 1 log unit. For the regimen test, administrators place a higher inoculum on the contact lens, and a solution cannot allow more than 10 colony-forming units of micro-organisms to remain on the lens.

Despite these regulations, highly publicized issues with contact lens disinfecting solutions began in the United Kingdom in the 1990s when chlorine disinfection tablets were associated with *Acanthamoeba* keratitis.⁶ In the 2000s, Bausch + Lomb withdrew its ReNu MoistureLoc solution when it caused an outbreak of *Fusarium* keratitis, and Advanced Medical

Optics' Complete MoisturePlus solution followed after reports of *Acanthamoeba* keratitis.^{7,8} Both outbreaks were associated with wearer hygiene issues ("topping off" lens solution was a common problem in both the *Fusarium* and *Acanthamoeba* keratitis outbreaks), prompting the FDA to consider "human factor engineering" to incorporate a margin of safety for how these products are used in the real world.

In 2008, these outbreaks prompted the FDA to hold a workshop in which they recommended:

1. *Acanthamoeba* be added to the pool of organisms tested.
2. Lens case and biofilm formation evaluations be added to the regimen test.



Despite the reduced lens care needs of daily disposables, wearers are still at risk for microbial keratitis, as seen here.

Photo: Jeffrey Sosnino, OD, and Shachar Tauber, MD

3. Organic soil, a measure of lens handling contamination, be added to the stand-alone test.

4. Solution products would include and specify a rub regimen on their labeling.

In 2014, the ISO updated the standards to include the evaluation of solutions in the presence of contact lenses and lens cases, as well as the addition of organic soil to testing regimens. However, the 2014 revision left out *Acanthamoeba* from the organisms included on the test panel. *Acanthamoeba* feeds on bacteria, and the ISO felt its growth would be limited by adequate antibacterial activity. However, research shows a high rate of culture-positive contact lens storage cases despite adherence to manufacturer guidelines.⁹⁻¹¹

Contact lens manufacturers routinely test products against various strains and species of *Acanthamoeba*, but a lack of consistency in the testing regimens exists due to variables such as the species and strains tested, the methods of culturing *Acanthamoeba* trophozoites and the methods for inducing encystment.

Another ISO standard update in 2015 provided some clarity on this front by specifying a method for

INTERNET ISSUES

During a recent Federal Trade Commission workshop regarding changes to the Contact Lens Rule, the group discussed internet supply and practitioner contact issues. While recent research found US contact lens wearers who purchase their lenses online are just as compliant as those who do not, the study may have contained sampling bias, as all participants had agreed previously to take part in marketing surveys.¹³ Two additional studies show that contact lens wearers who purchase their lenses online are more predisposed to adverse events, and though the source of the association is unclear, a lack of education from practitioners is likely to have some influence.^{1,14}

Today's contact lens population is expanding to include more children and adults older than 50. We know little about the immune signatures of children and how they will respond to infection and inflammation; but in older adults, we often see worse corneal infection outcomes. This could possibly stem from adaptive immune responses mounting a more severe response or less defense against organisms, as well as a shift in the biome of the skin as patients age.^{15,16}

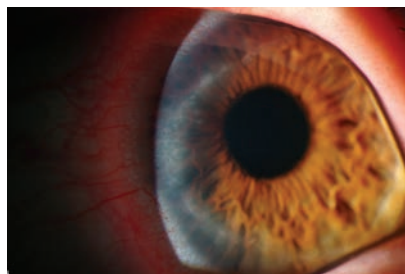WHY CONTACT LENS CARE STILL MATTERS

evaluating the encystment potential of *Acanthamoeba*. However, this excludes the evaluation of oxidative systems such as those using hydrogen peroxide that require special, vented lens cases, and the FDA has yet to adopt the method. Still, many hold out hope that the FDA will soon adopt testing guidelines that include the complete range of existing and new lens care products. This would provide us with a better understanding of each product's performance and, hopefully, improve safety margins.

WEARER BEHAVIOR

Despite all the industry standards and the publicity of severe events, contact lens wearer behavior has changed little. A recent study reports a high incidence of all lens wearers using tap water in their care regimen.¹² While GP lens wearers traditionally have used water to rinse off the sticky lens cleaner, non-scratch lenses clear of tear protein build-up—a new option in this modality—lowers the risk of infection significantly for this modality. Nonetheless, high oxygen permeable RGP, ortho-K and scleral lenses are all likely to be more problematic when water is used before lens insertion.

Added to this, many patients

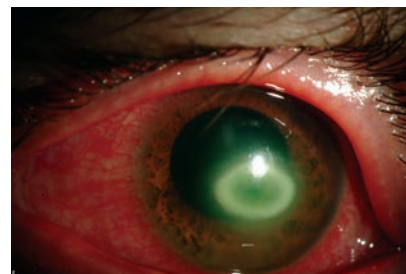


Though contact lens manufacturers test their products against *Acanthamoeba* keratitis, seen here, a lack of consistency creates contamination issues.

do not understand the different lens care protocols between rigid and soft lenses, so there is a high potential for misinformation being spread from GP lens wearers to soft lens wearers.

The industry is making some progress in addressing these issues, however. Although FDA recommendations still include using water to rinse GP lenses, at least one large manufacturer has plans to move in the opposite direction. Additionally, the British Contact Lens Association, the American Academy of Optometry and the Cornea and Contact Lens Association of Australia have adopted a “no water” symbol for product packaging. Thus far, this visual cue is used on product packaging to alert contact lens wearers to the danger of non-sterile water on lenses and lens care regimens; those involved are hoping to incorporate the symbol into the printed literature and packaging of contact lens paraphernalia in the future.

The contact lens practitioner's role in proper contact lens care is key, not only in tracking the patient's ocular response to lens wear and care, but also in ensuring the patient is well educated on the lens care necessary for each modality. Whether wearing daily disposable or reusable lenses, a patient must understand that proper handling, cleaning, storage and replacement are all crucial factors that will



Photos: Christine W. Sindi, OD

dictate if the patient is successful in their contact lens wear. [BCCL](#)

1. Stapleton F, Keay L, Edwards K, et al. The incidence of contact lens-related microbial keratitis in Australia. *Ophthalmol*. 2008;115(10):1655-62.
2. Dart JKG, Radford CF, Minassian D, et al. Risk factors for microbial keratitis with contemporary contact lenses: a case-control study. *Ophthalmol*. 2008;115(10):1647-54.
3. Chalmers RL, Keay L, McNally J, Kern J. Multi-center case-control study of the role of lens materials and care products on the development of corneal infiltrates. *Optom Vis Sci*. 2012;89(3):316-25.
4. Stapleton F, Naduvilath T, Keay L, et al. Risk factors and causative organisms in microbial keratitis in daily disposable contact lens wear. *PLoS One*. 2017;12(8):e0181343.
5. Radford CF, Minassian D, Dart JK, et al. Risk factors for nonulcerative contact lens complications in an ophthalmic accident and emergency department: a case-control study. *Ophthalmol*. 2009;116(3):385-92.
6. Radford CF, Minassian D, Dart JKG. *Acanthamoeba* keratitis in England and Wales: incidence, outcome and risk factors. *Br J Ophthalmol*. 2002;86:536-42.
7. Chang DC, Grant GB, O'Donnell K, et al. Multistate outbreak of *Fusarium* keratitis associated with use of a contact lens solution. *JAMA*. 2006;296(8):953-63.
8. Joslin CE, Tu EY, Shoff ME, et al. The association of contact lens solution use and *Acanthamoeba* keratitis. *Am J Ophthalmol*. 2007;144(2):169-80.
9. Wu YT, Teng YJ, Nicholas M, et al. Impact of lens case hygiene guidelines on contact lens case contamination. *Optom Vis Sci*. 2011;88(10):e1180-1187.
10. Wu Y, Carnit N, Willcox M, Stapleton F. Contact lens and lens storage case cleaning instructions: whose advice should we follow? *Eye & Cont Lens*. 2010;36(2):68-72.
11. Yoder JS, Verani J, Heidman N, et al. *Acanthamoeba* keratitis: the persistence of cases following a multistate outbreak. *Ophthalmic Epidemiol*. 2012;19(4):221-5.
12. Zimmerman AB, Richdale K, Mitchell GL, et al. Water exposure is a common risk behavior among soft and gas-permeable contact lens wearers. *Cornea*. 2017;36(8):995-1001.
13. Chalmers RL, Wagner H, Kinoshita B, et al. Is purchasing lenses from the prescriber associated with better habits among soft contact lens wearers? *Cont Lens Anterior Eye*. 2016;39(6):435-41.
14. Sorbara L, Zimmerman AB, Mitchell GL, et al. Multicenter testing of a risk assessment survey for soft contact lens wearers with adverse events: a contact lens assessment in youth study. *Eye Cont Lens*. 2018;44(1):21-8.
15. Carnit N, Robaei D, Minassian DC, Dart JKG. *Acanthamoeba* keratitis in 194 patients: risk factors for bad outcomes and severe inflammatory complications. *Br J Ophthalmol*. January 3, 2018. [Epub ahead of print].
16. Keay L, Edwards K, Naduvilath T, et al. Factors affecting the morbidity of contact lens related microbial keratitis: a population study. *Invest Ophthalmol Visual Sci*. 2006;47(10):4302-8.

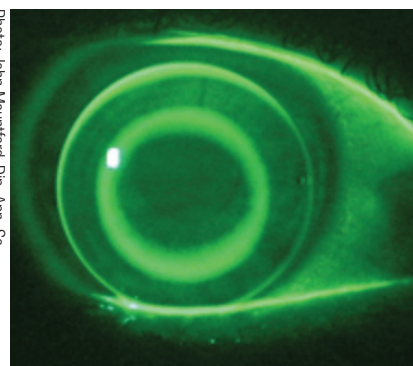


Photo: John Mountford, Dip. App. Sc

While many of today's patients opt for daily disposable lenses, don't forget about those still in reusable modalities such as ortho-K lenses.

Earn up to
19 CE
Credits*

NEW TECHNOLOGIES
& TREATMENTS IN
2018 EYE CARE



REVIEW OF OPTOMETRY®
EDUCATIONAL MEETINGS OF CLINICAL EXCELLENCE

ARLINGTON, VIRGINIA NOVEMBER 2-4, 2018

Join *Review of Optometry's* New Technologies & Treatments in Eye Care
November 2-4, 2018, at the Westin Arlington Gateway.

The Westin Arlington Gateway

801 N Glebe Road
Arlington, VA 22203
Phone: (703) 717-6200



Program Chair:
Paul Karpecki, OD, FAAO

See website for additional information.

Registration Cost: **\$495**
Early Bird Special: **\$420**

Must register before Sept. 21, 2018,
for early bird special pricing.

A limited number of rooms have been reserved at the rate of **\$159/night**. Please book with the hotel directly by calling the number above. Mention "Review of Optometry" for group rate.

THREE WAYS TO REGISTER

ONLINE: www.reviewofoptometry.com/ARLINGTON2018
EMAIL: reviewmeetings@jobson.com -or- **CALL:** 866-658-1772

REGISTER ONLINE: WWW.REVIEWOFOPTOMETRY.COM/ARLINGTON2018

Administered by
Review of Optometry®


*Approval pending

 **SALUS**
UNIVERSITY
Pennsylvania College of Optometry

Review of Optometry® partners with Salus University for those ODs who are licensed in states that require university credit. See event website for complete details.

CXL: a First-line Therapy for Keratoconus

Eye care professionals have a new leading treatment option to combat this disease.

By Clark Y. Chang, OD, MSA, MSc, and Christopher J. Rapuano, MD

Under the conventional keratoconus (KCN) management model, clinicians have generally accepted the notion that an earlier KCN diagnosis is inconsequential, as early detection will not alter the disease's natural course or prevent onset of visual deficits. This gave rise to a simple binary treatment plan for all KCN patients: spectacles or contact lenses for those with early to moderate disease, and corneal transplantations for the 10% to 20% who either have severe KCN or cannot tolerate contact lens wear.^{1,2}

Notwithstanding, even a well-performed keratoplasty has risks such as donor tissue rejection, infection, cataract, glaucoma, ocular surface disease, anisometropia and irregular corneal astigmatism.³ Thus, clinicians generally reserve keratoplasty as a last resort.

But today's access to corneal collagen crosslinking (CXL) shatters this binary treatment path and opens the door to a whole new mindset and therapy regimen.

THE OLD WAY OF THINKING

The primary goals of KCN management are to restore visual function, preserve quality of life and defer corneal transplantation. Thus, minimizing risk factors that increase a patient's likelihood of needing a

corneal transplant is key. One study of 131 KCN eyes reported younger age (≤ 30), recent diagnosis (≤ 5 years from time to diagnosis), poor best-corrected visual acuity (BCVA) (20/40 or worse) and greater ectatic steepening (55D or higher) as main risk indicators associated with a higher likelihood of requiring corneal transplantations.¹

Since clinicians cannot currently modify the age of onset and have only recently gained the ability to arrest progressive corneal steepening, they traditionally opt to improve BCVA with contact lenses. A well-fitting contact lens can improve visual functions and defer the need for keratoplasty; however, it does not prevent worsening of KCN or further loss of uncorrected visual acuity (UCVA).^{2,4} In addition, despite use of gas permeable lenses, residual higher-order aberrations and persistent BCVA reductions can still remain.⁵ The lack of emphasis on KCN stabilization in conventional management could explain why some patients continue to report significant decline in vision-related quality of life.⁶

ALONG CAME CXL

When first exploring ultraviolet (UV)-induced CXL in the late 1990s, researchers realized the feasibility of a photochemical CXL

induction process that produced stiffer corneal tissues with increased resistance to enzymatic digestion and thermal damages.⁷ Additionally, a landmark pilot study of 23 progressive KCN eyes that underwent CXL reported not only that all eyes were stabilized with no adverse events, but 70% also showed an average reduction of 2.01D in maximal keratometry.⁸

Needless to say, the advent of CXL instigated a new era of KCN management that now focuses on stabilizing KCN as early as possible. CXL is a photochemical polymerization process in which monomers are rearranged into a three-dimensional network of polymers, subsequently enhancing the tensile strength of a tissue structure.

CXL is also a naturally occurring

ABOUT THE AUTHORS



Dr. Chang is director of cornea specialty lenses at Wills Eye Hospital-Cornea Service and director of clinical services at TLC Vision. Also, he is an advisory board member for the International Keratoconus Academy, the Gas Permeable Lens Institute and the Optometric Cornea, Cataract and Refractive Society.



Dr. Rapuano is chief of Cornea Service at Wills Eye Hospital. He has published several books, numerous book chapters and over 175 peer-reviewed articles, including having co-authored *The Wills Eye Manual*.

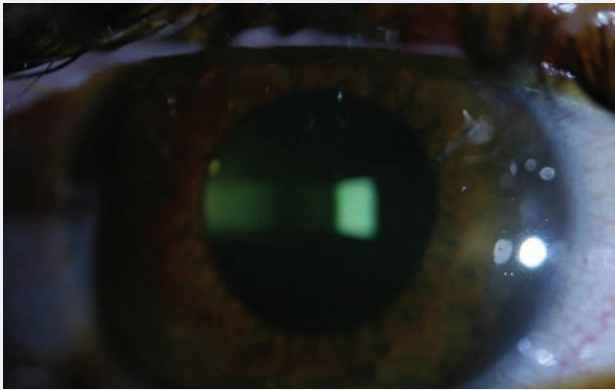


Fig 1. Riboflavin staining in aqueous seen here after 30 minutes of riboflavin loading during CXL treatment.

biological process involving the gradual stiffening of connective tissues over time. The natural, age-associated CXL process is facilitated by lysyl oxidase, an endogenous enzyme derived from the LOX gene pathway (see “Diagnostic Woes,” p. 5). It catalyzes the required oxidative reactions to create additional covalent bonds (or “crosslinks”) between and within collagen fibrils—yielding increased tissue biomechanical strength and halting KCN progression.^{9,10}

The relative stability observed in many KCN patients after the fourth decade of life is a potential consequence of cumulative age-associated CXL within the corneal stroma. However, the slow and time-dependent natural crosslinking reactions cannot neutralize the cumulative damages accrued in a majority of KCN patients, especially when disease onset has been reported as early as age six.¹ Thus, monitoring KCN patients until development of contact lens intolerance while they continue to experience BCVA loss is insufficient to proactively protect patients from the need for a corneal transplantation. Today, accelerating the formation of corneal crosslinks now enables clinicians the possibility of preserving maximal visual functions and halting the rate of ectatic steepening, both of which are

protective factors against the need for keratoplasty.¹

CXL DOs AND DON'Ts

To achieve the most efficient and homogeneous stromal saturation of photosensitizer molecules within 30 minutes of the ribofla-

vin-loading phase, central epithelium is debrided to fully remove the barriers of epithelial tight junctions. Debridement also disrupts the physiological barrier that slows stromal oxygen replenishment during CXL treatment and removes antioxidant enzymes that can be counter-productive to maximum CXL efficacy. Epithelium shows high levels of antioxidant-acting molecules such as ascorbate and tryptophan residues that can scavenge high-energy reactive oxygen species and impede intended UV transmission from reaching stromal treatment sites.^{11,12}

Standard (epi-off) FDA-approved CXL treatment begins with epithelial removal similarly to a photorefractive keratectomy (PRK). Under topical anesthesia and through

standard aseptic technique, the epithelium is removed from the central 9mm. Photrex Viscous (riboflavin 5'-phosphate in 20% dextran ophthalmic solution, Avedro) is instilled on the cornea in two-minute intervals for 30 minutes.⁸

Since riboflavin serves as both a photosensitizing agent to propagate CXL chemical reactions and a tissue protector by reducing UV transmittance beyond the intended treatment depth, it is essential that clinicians ensure full saturation within the corneal stroma prior to UV irradiation. Clinicians can achieve this by checking for stromal and aqueous riboflavin staining in the slit lamp after the 30 minutes of riboflavin loading (*Figure 1*).

A minimum corneal thickness of 400µm, typically measured with an ultrasound pachymeter, is required prior to UV exposure. If pachymetry fails to show proper corneal thickness, hypotonic Photrex Riboflavin (riboflavin 5'-phosphate ophthalmic solution, Avedro) is administered every five to 10 seconds until the cornea is swollen to at least 400µm.

Minimum corneal thickness of 400µm and full stromal riboflavin saturation help to attenuate UV energy and protect post-stromal structures such as the endothelium, crystalline lens and retina. For

Release Date: April 27, 2018

Expiration Date: April 27, 2021

Goal Statement: Prevalence rates for keratoconus could be as high as one in 375 in general populations, according to recent research. As such, management of this disease is more important than ever. This article provides a comprehensive review of corneal collagen crosslinking, which could provide clinicians with a safe and effective first-line therapy for keratoconus patients.

Faculty/Editorial Board: Clark Y. Chang, OD, MSA, MSc, and Christopher J. Rapuano, MD

Credit Statement: This course is COPE approved for 1 hour of continuing education credit. Course ID is 57877-AS. Check with your state licensing board to see if this counts toward your CE requirements for relicensure.

Joint-Sponsorship Statement: This continuing education course is joint-sponsored by the Pennsylvania College of Optometry.

Disclosure Statement:

Authors: Dr. Chang has a speaker's bureau arrangement with Avedro.

Dr. Rapuano is a consultant for Allergan, Avedro, Bio-Tissue, GSK, Novartis, Shire, Sun Ophthalmics and TearLab. He is also a stock shareholder for RPS and has speaker's bureau arrangements with Avedro, Bio-Tissue and Shire.

Editorial staff: Jack Persico, Rebecca Hepp, William Kekevan and Michael Iannucci all have no relationships to disclose.



Disease Basics

KCN is a bilateral corneal condition that typically manifests with substantial contralateral asymmetry. Its presentation is typically non-inflammatory and non-vascularized, although inflammatory components in its pathogenesis have been proposed.²⁹ Since KCN patients are often visually asymptomatic when the disease is emerging, clinicians may not suspect KCN until the condition crosses certain visual or anatomical thresholds where loss of vision may become permanent (*Figure 2*).

As KCN progresses or when both eyes are affected, the optical consequences such as irregular astigmatism and increased higher-order aberrations escalate. Here, patients will start to experience wide-ranging visual compromises leading to loss of BCVA. The onset of KCN is often during puberty but can occur even earlier in life, and it tends to progress until around the fourth decade of life, after which relative stability is often observed. Nonetheless, a risk of progression still exists later in life or after a period of stability.¹

Clinicians often educate patients that KCN's prevalence rate is approximately one in 2,000.^{30,31} However, recent epidemiological evidence shows that the KCN prevalence rate may actually be as high as one in 375 among general populations or even higher in certain subgroups.^{32,33} A recent study of 1,044 pediatric eyes from Saudi Arabia reported a potential pediatric KCN prevalence rate as high as one in 21.³³ As such, it's likely the impact of KCN has been grossly underestimated and the clinical consequences underappreciated.

example, if a riboflavin-saturated cornea has a minimum pachymetry of 400µm, the calculated UV irradiance will dissipate to about 0.18mW/cm², which is nearly 50% less than the endothelial damage threshold of 0.35mW/cm². The energy level projected to reach the lens and retina is even lower and well within their respective damage threshold levels.^{13,14}

Once appropriate riboflavin satu-

ration and pachymetric compliance have been verified, the KXL UV device (Avedro) is programmed for 30 minutes of continuous emission (3mW/cm²) with a calibrated total energy dose of 5.4J/cm² (*Figure 3*).⁸ After initiating UV exposure, Photrexa Viscous continues to be administered in two-minute intervals until treatment conclusion. This maintains maximal concentration of active photosensitizing agents in the stromal treatment zone. The reactive oxygen species are energetically robust and can activate the lysyl oxidase enzymatic pathway. This causes the formation of new covalent bonds within the stromal treatment zone and a stiffer corneal composition.

Post-procedure, clinicians can rinse excess riboflavin off with balanced salt solution. A bandage contact lens should be placed on the treated eye and maintained for three to five days or until epithelial closure

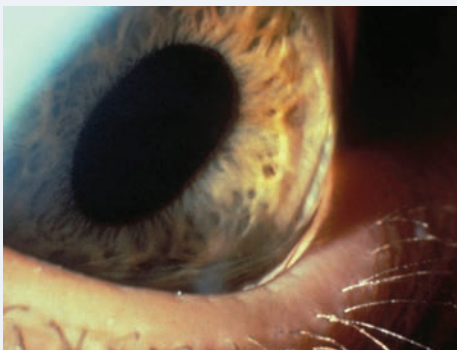


Fig 2. Advanced keratoconus with Munson's sign. Despite disease severity, note the otherwise clear cornea with no other discernable clinical signs via slit lamp examination.

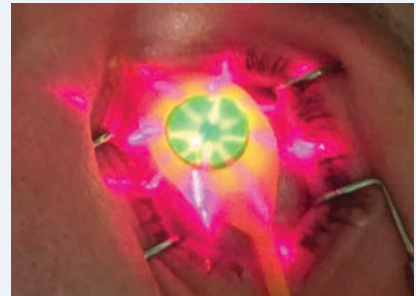


Fig. 3. Crosshair guidance helps clinicians maintain proper working distance between the UV emission device and the treatment site.

(*Figure 4*). Patients are also typically managed with a topical antibiotic four times a day for one week and a topical corticosteroid four times a day for the first week with a tapering schedule over two to six weeks. The exact prescribed medications, frequencies and length of treatment may vary.¹⁵

FUTURE IMPROVEMENTS

Many studies show epi-off CXL renders a good safety profile and high level of efficacy in halting KCN progression.^{15,16} Some reports also suggest CXL can improve topographic, refractive and aberrometric parameters.^{8,17,18} Researchers have yet to discover specific patient variables that reliably predict such improvements, so clinicians should continue to educate KCN patients on corneal stabilization as the primary treatment purpose.

Although rare, CXL complications exist. Postoperative complications can include the common issues expected with any epithelial delamination process such as variable epithelial healing rate, eye pain, microbial keratitis and sterile infiltrates. Other adverse events associated with CXL include transient corneal haze, persistent corneal edema/endothelial decompensation, corneal scarring, unexplained loss of visual acuity and the need for CXL retreatment due to continued KCN progression (*Figure 5*).

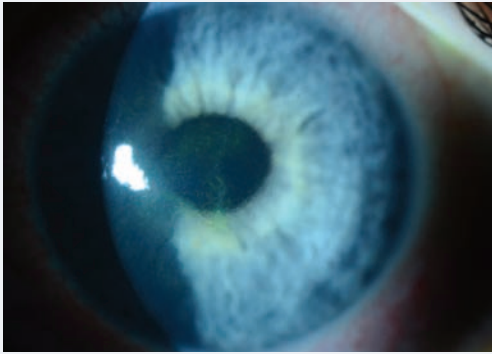


Fig. 4. This patient presented with nearly complete epithelial closure, and the bandage lens remained in position, on day three following CXL treatment.

TE-CXL VS. EPI-OFF

As safe as epi-off CXL is in clinical practice, some researchers have raised concerns about epithelial removal due to postoperative pain, slow visual recovery and infection risk. The desire to further improve CXL delivery through a minimally disrupted epithelium has fueled numerous clinical studies. While research shows fewer associated adverse events when the epithelium is left mostly intact, some clinical investigations have also demonstrated lower efficacies with transepithelial, or epi-on, CXL (TE-CXL).¹⁹⁻²¹

TE-CXL patients may be at a higher risk for requiring CXL re-treatment. In one study of TE-CXL, pediatric KCN patients showed regression rates of up to 50%. Within a two-year follow-up period, these patients demonstrated continual ectatic steepening after primary TE-CXL, necessitating retreatments with epi-off CXL.¹⁷ In addition, a patient noncompliant with follow-up after TE-CXL treatment may have more cumulative risks for continual ectatic steepening. Thus, many researchers still favor the epi-off CXL technique due to its greater treatment efficacy. Nonetheless, because of TE-CXL's quicker recovery course and increased comfort during the initial post-operative period, continual research may bring about

enhanced treatment effects in future technologies.

Overall, epi-off CXL is considered safe and highly effective, so much so that cornea experts from four international corneal societies recently reached a consensus that clinicians should consider CXL in KCN individuals with high risk profile for progression, even if progression has not yet been documented.²² While what constitutes a high risk profile

still needs clarification, it may include young age, severe allergy and eye rubbing.²³

HOW CXL ENHANCES MANAGEMENT

By using CXL as a first-line KCN treatment, clinicians can induce corneal stability immediately after disease detection and spare patients from experiencing unnecessary hardship with their vision and quality of life. This new management concept can proactively preserve visual function as well as diminish or

even eliminate the need for corneal transplantation.²⁴ For example, in countries that adopted the new KCN management paradigm early, CXL is associated with a more than 50% reduction in keratoplasties for KCN patients.^{25,26}

KCN stability after CXL may also enhance success with long-term contact lens wear either by keeping the cornea in a stage that may be easier to fit or by maintaining UCVA and BCVA. Keep in mind that immediately after CXL, epithelial cells may become more fragile and it may take a few months for the initial cellular remodeling to occur. Because persistent epithelial disruption may be associated with corneal opacity development, clinicians need to exercise caution when recommending contact lens refittings after CXL.²⁷ Our clinical guidelines at Wills Eye Hospital are to wait a minimum of four to six weeks after standard epi-off CXL before refitting patients in contact lenses, although the exact time frame will depend on the contact lens type and the CXL procedure itself.²⁸

Diagnostic Woes

One diagnostic challenge of KCN is the lack of pathognomonic characteristics specific to early phases of the disease. Research shows increased odds of disease development when patients present with a positive family history of KCN in close relatives.³⁴ Connective tissue, atopic and inflammatory bowel diseases are also associated with KCN.³⁵ Recent genome-wide studies have found LOX genes to be a promising source in KCN pathogenesis.^{29,36} Defects in LOX gene (protein coding for lysyl oxidase) can cause attenuation of crosslinking between stromal collagen fibers, and down-regulation of LOX expression has been observed in KCN corneal epithelium.³⁷ However, the most commonly encountered form of KCN presents without any known associations, and clinicians cannot rely on genetic or systemic history to screen for KCN.^{32,38}

KCN patients don't often recognize vision loss until the disease advances in the better-seeing eye; thus, clinicians also cannot rely on patients' subjective visual symptoms to diagnose KCN. Consequently, patients are often left undiagnosed until both eyes are significantly affected. With more severe KCN, visual impairment in at least one eye may no longer be correctable via spectacles or soft contact lenses.



With the new KCN management approach, clinicians can combine the treatment benefits of CXL and contact lenses to help KCN patients achieve maximal improvement in their lives. Ideally, this combination will significantly reduce the number of patients who

The Effect of Age

KCN progression after CXL is more likely in pediatric patients, leading to higher retreatment rates. In one long-term study of pediatric patients, 25% of eyes showed progression during a 10-year follow-up period.⁵ Conversely, a study of predominantly adult patients reported only 5% needed retreatment after a 10-year follow-up.³⁹ Thus, clinicians should identify KCN early, start CXL protective efforts and monitor or possible retreatment needs.

If KCN diagnosis cannot be concluded from the baseline presentation, patients should be followed in time intervals that match their risk profile for progression. At Wills Eye Hospital, we believe shorter monitoring intervals of three to six months are justified for patients with one or more of the following characteristics:

1. Pediatric patients (age 18 or younger).
2. Eye rubbing that cannot be controlled with anti-allergy or dry eye medications.
3. A family history of KCN in one or more first degree relatives.
4. Minimum corneal thickness less than 450µm but greater than 400µm (to ensure patients receive CXL before their corneal thickness drops below the general safety guideline of 400µm).

Early intervention with CXL can help prevent unnecessary loss of BCVA or UCVA, as well as minimize the need for keratoplasty.

will require corneal grafts, a goal once unimaginable with traditional KCN management. **RECL**

1. Reeves SW, Stinnett S, Adelman RA, Afshari NA. Risk factors for progression to penetrating keratoplasty in patients with keratoconus. *Am J Ophthalmol.* 2005;140(4):607-11.
2. Koppen C, Kreps EO, Anthonissen L, et al. Scleral lenses reduce the need for corneal transplants in severe keratoconus. *Am J Ophthalmol.* 2018;185:43-7.
3. Mannis MJ. Keratoconus: Why and when do we turn to surgical therapy? *Am J Ophthalmol.* 2006;142(6):1044-5.
4. Bilgin LK, Yilmaz S, Araz B, et al. 30 years of contact lens prescribing for keratoconic patients in Turkey. *Cont Lens Ant Eye.* 2009;32(1):16-21.
5. Parker JDE, Pesudovs K, Donnelly WJ, Applegate RA. Uncorrected wavefront error and visual performance during RGP wear in keratoconus. *Optom Vis Sci.* 2007;84(6):463-70.
6. Kymes SM, Walline JJ, Zadnik K, et al. Collaborative Longitudinal Evaluation of Keratoconus Study Group. Changes in the quality-of-life of people with keratoconus. *Am J Ophthalmol.* 2008;145(4):611-7.
7. Spoerl E, Wollensak G, Seiler T. Increased resistance of crosslinked cornea against enzymatic digestion. *Curr Eye Res.* 2004;29(1):35-40.
8. Wollensak G, Spoerl E, Seiler T. Riboflavin/ultraviolet-A-induced collagen crosslinking for the treatment of keratoconus. *Am J Ophthalmol.* 2003;135(5):620-7.
9. Schumacher S, Mrochen M, Wernli J, et al. Optimization model for UV-riboflavin corneal cross-linking. *Invest Ophthalmol Vis Sci.* 2012;53(2):762-9.
10. Mazzotta C, Traversi C, Baiocchi S, et al. Corneal collagen cross-linking with riboflavin and ultraviolet A light for pediatric keratoconus: Ten-year results. *Cornea.* 2018 Jan 9.
11. Bottós KM, Schor P, Dreyfus JL, et al. Effect of cornea epithelium on ultraviolet-a and riboflavin absorption. *Arq Bras Oftalmol.* 2011;74(5):348-51.
12. Richoz O, Hammer A, Tabibian D, et al. The biomechanical effect of corneal collagen cross-linking (CXL) with riboflavin and UV-A is oxygen dependent. *Transl Vis Sci Technol.* 2013;2(7):6.
13. Spoerl E, Mrochen M, Sliney D, et al. Safety of UVA-riboflavin cross-linking of the cornea. *Cornea.* 2007;26(4):385-9.
14. Schumacher S, Mrochen M, Wernli J, et al. Optimization model for UV-riboflavin corneal cross-linking. *Invest Ophthalmol Vis Sci.* 2012;53(2):762-9.
15. Chang CY, Hersh PS. Corneal collagen cross-linking: a review of 1-year outcomes. *Eye Contact Lens.* 2014;40(6):345-52.
16. Shalchi Z, Wang X, Nanavaty MA. Safety and efficacy of epithelium removal and transepithelial corneal collagen crosslinking for keratoconus. *Eye (Lond).* 2015;29(1):15-29.
17. Hersh PS, Greenstein SA, Fry KL. Corneal collagen crosslinking for keratoconus and corneal ectasia: One-year results. *J Cataract Refract Surg.* 2011;37(1):149-60.
18. Vinciguerra P, Albè E, Trazza S, et al. Refractive, topographic, tomographic, and aberrometric analysis of keratoconic eyes undergoing corneal cross-linking. *Ophthalmology.* 2009;116(3):369-78.
19. Caporossi A, Mazzotta C, Paradiso AL, et al. Transepithelial corneal collagen crosslinking for progressive keratoconus: 24-month clinical results. *J Cataract Refract Surg.* 2013;39(8):1157-63.
20. Soeters N, Wisse RP, Godefrooij DA, et al. Transepithelial versus epithelium-off corneal cross-linking for the treatment of progressive keratoconus: a randomized controlled trial. *Am J Ophthalmol.* 2015;159(5):821-8.
21. Kocak I, Aydin A, Kaya F, Koc H. Comparison of transepithelial corneal collagen crosslinking with

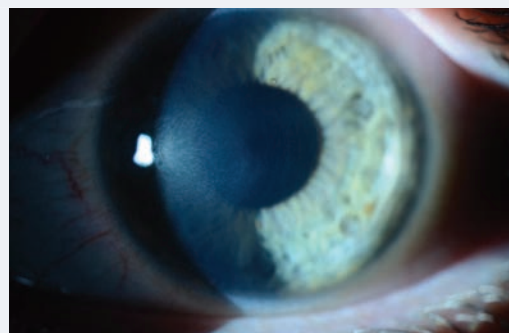


Fig. 5. This patient shows mild CXL-associated haze and demarcation lines seven weeks after CXL treatment.

- epithelium-off crosslinking in progressive keratoconus. *J Fr Ophtalmol.* 2014;37(5):371-6.
22. Gomes JA, Tan D, Rapuano CJ, et al. Global consensus on keratoconus and ectatic diseases. *Cornea.* 2015;34(4):359-69.
23. Chatzis N, Hafezi F. Progression of keratoconus and efficacy of pediatric corneal collagen cross-linking in children and adolescents. *J Refract Surg.* 2012;28(11):753-8.
24. Hashemi H, Seyedian MA, Miraftab M, et al. Corneal collagen cross-linking with riboflavin and ultraviolet A irradiation for keratoconus: long-term results. *Ophthalmology.* 2013;120(8):1515-20.
25. Sandvik GF, Thorsrud A, Råen M, et al. Does corneal collagen cross-linking reduce the need for keratoplasties in patients with keratoconus? *Cornea.* 2015;34(9):991-5.
26. Godefrooij DA, Gans R, Imhof SM, Wisse RP. Nationwide reduction in the number of corneal transplantations for keratoconus following the implementation of cross-linking. *Acta Ophthalmol.* 2016;94(7):675-8.
27. Wilson SE, Medeiros CS, Santhiago MR. Pathophysiology of corneal scarring in persistent epithelial defects after PRK and other corneal injuries. *J Refract Surg.* 2018;34(1):59-64.
28. Chang, C, Rapuano CJ. Top 12 crosslinking FAQs. *Rev Optom.* 2018;155(1):40-5.
29. Bykhovskaya Y, Margines B, Rabinowitz YS. Genetics in Keratoconus: where are we? *Eye Vis (Lond).* 2016;3:16.
30. Kennedy RH, Bourne WM, Dyer JA. A 48-year clinical and epidemiologic study of keratoconus. *Am J Ophthalmol.* 1986;101(3):267-73.
31. Rabinowitz YS. Keratoconus. *Surv Ophthalmol.* 1998;42(4):297-319.
32. Godefrooij DA, de Wit GA, Uiterwaal CS, et al. Age-specific incidence and prevalence of keratoconus: A nationwide registration study. *Am J Ophthalmol.* 2017;175:169-72.
33. Torres Netto EA, Al-Otaibi WM, Hafezi NL, et al. Prevalence of keratoconus in paediatric patients in Riyadh, Saudi Arabia. *Br J Ophthalmol.* 2018 Jan 3.
34. Karimian F, Arahesh S, Rabei HM, et al. Topographic evaluation of relatives of patients with keratoconus. *Cornea.* 2008;27(8):874-8.
35. Tréchet F, Angioi K, Lataarhe C, et al. Keratoconus in inflammatory bowel disease patients: A cross-sectional study. *J Crohns Colitis.* 2015;9(12):1108-12.
36. Li X, Rabinowitz YS, Tang YG, et al. Two-stage genome-wide linkage scan in keratoconus sib pair families. *Invest Ophthalmol Vis Sci.* 2006;47(9):3791-5.
37. Shetty R, Sathyanarayananamoorthy A, Ramachandra RA, et al. Attenuation of lysyl oxidase and collagen gene expression in keratoconus patient corneal epithelium corresponds to disease severity. *Mol Vis.* 2015;21:12-25.
38. Rabinowitz YS. The genetics of keratoconus. *Ophthalmol Clin North Am.* 2003;16(4):607-20.
39. Raiskup F, Theuring A, Pillunat LE, Spoerl E. Corneal collagen crosslinking with riboflavin and ultraviolet-A light in progressive keratoconus: ten-year results. *J Cataract Refract Surg.* 2015;41(1):41-6.

CXL: A FIRST-LINE THERAPY FOR KERATOCONUS

CE TEST ~ MAY 2018

- Which of the following is an optical consequence of keratoconus?
 - Divergence excess.
 - Increased higher-order aberrations.
 - Strabismus.
 - None of the above.
- Recent evidence suggests the rate of KCN may actually be as high as:
 - One in 1,000.
 - One in 5.
 - One in 375.
 - One in 2,000.
- Which of the following is associated with KCN?
 - Positive family history of KCN in close relatives.
 - Connective tissue disease.
 - Atopic disease.
 - All of the above.
- Which of the following is a postoperative risk or complication for corneal transplantation?
 - Donor tissue rejection.
 - Cataract.
 - Anisometropia.
 - All of the above.
- While performing corneal collagen crosslinking per FDA-approved protocol, the most efficient and homogenous stromal saturation of photosensitizer molecules is achieved by:
 - Debriding the central epithelium.
 - Leaving the central epithelium intact.
 - Placing a soft bandage lens on eye during treatment.
 - Instilling riboflavin in 10-minute intervals.
- As per FDA-approved protocol in the United States, minimum corneal thickness of _____ is required prior to the UV exposure phase during CXL.
 - 300µm.
 - 400µm.
 - 500µm.
 - 600µm.
- Transepithelial CXL may have a higher chance of requiring retreatment than epi-off CXL because:
 - It uses a UV light that emits less energy.
 - The presence of epithelial tight junctions may lower its potency.
 - Its quicker recovery course makes patients rub their eyes more.
 - Patient noncompliance with postoperative medication dosing schedules.
- Shorter monitoring intervals can be justified for patients with these characteristics, except:
 - Symptoms of night glare without clinical signs of keratoconus.
 - 18 years of age or younger.
 - A family history of KCN in one or more first degree relatives.
 - Minimum corneal thickness less than 450µm but greater than 400µm.
- Under conventional KCN treatment, _____ is/are typically the first choice to improve visual function.
 - Intacs.
 - Keratoplasty.
 - Contact lenses.
 - CXL.
- Using CXL as the first line of KCN treatment can help clinicians:
 - Achieve corneal stability over time by halting KCN progression.
 - Preserve patients' best possible visual functions.
 - Diminish or even eliminate the need for corneal transplantation.
 - All of the above.

EXAMINATION ANSWER SHEET

CXL: A First-line Therapy for Keratoconus

Valid for credit through April 27, 2021

Online: This exam can also be taken online at www.reviewofoptometry.com/ce. Upon passing the exam, you can view your results immediately. You can also view your test history at any time from the website.

Directions: Select one answer for each question in the exam and completely darken the appropriate circle. A minimum score of 70% is required to earn credit.

Mail to: Jobson Medical Information, Dept.: Optometric CE, 440 9th Avenue, 14th Floor, New York, NY 10001.

Payment: Remit \$20 with this exam. Make check payable to Jobson Medical Information LLC.

Credit: This lesson is approved for 1 hour of CE credit. Course ID is 57877-AS.

Sponsorship: Joint-sponsored by the Pennsylvania College of Optometry

Processing: There is a four-week processing time for this exam.

- Answers to CE exam:**
- | | | |
|------------|------------|-------------|
| 1. A B C D | 4. A B C D | 7. A B C D |
| 2. A B C D | 5. A B C D | 8. A B C D |
| 3. A B C D | 6. A B C D | 9. A B C D |
| | | 10. A B C D |

Post-activity evaluation questions:

Rate how well the activity supported your achievement of these learning objectives:

1=Poor, 2=Fair, 3=Neutral, 4=Good, 5=Excellent

- | | | | | | |
|---|---|---|---|---|---|
| 11. Better understand the potential impact of KCN on general populations. | ① | ② | ③ | ④ | ⑤ |
| 12. Better able to differentiate between the traditional KCN management model and the new KCN management model. | ① | ② | ③ | ④ | ⑤ |
| 13. Improved my ability to educate patients about the potential options for KCN treatment. | ① | ② | ③ | ④ | ⑤ |
| 14. Improved my understanding of the standard epi-off CXL procedure. | ① | ② | ③ | ④ | ⑤ |
| 15. Increase my grasp of which patients are more likely to require CXL intervention. | ① | ② | ③ | ④ | ⑤ |
| 16. Improve my knowledge of the differences between TE-CXL and epi-off CXL. | ① | ② | ③ | ④ | ⑤ |

Rate the quality of the material provided:

1=Strongly disagree, 2=Somewhat disagree, 3=Neutral, 4=Somewhat agree, 5=Strongly agree

- | | | | | | |
|--|-------|---|---|---|---|
| 17. The content was evidence-based. | ① | ② | ③ | ④ | ⑤ |
| 18. The content was balanced and free of bias. | ① | ② | ③ | ④ | ⑤ |
| 19. The presentation was clear and effective. | ① | ② | ③ | ④ | ⑤ |
| 20. Additional comments on this course: | _____ | | | | |

Identifying information (please print clearly):

First Name _____

Last Name _____

Email _____

The following is your: Home Address Business Address

Business Name _____

Address _____

City _____ State _____

ZIP _____

Telephone # _____ - _____ - _____

Fax # _____ - _____ - _____

By submitting this answer sheet, I certify that I have read the lesson in its entirety and completed the self-assessment exam personally based on the material presented. I have not obtained the answers to this exam by fraudulent or improper means.

Signature: _____ Date: _____

Please retain a copy for your records.

LESSON 116820, RO-RCCL-0518



ROCK and Whorl

Rhopressa may be a big help with glaucoma, but it could have some corneal side effects.

The approval of Rhopressa (netarsudil ophthalmic solution 0.02%, Aerie Pharmaceuticals) provides practitioners with the first novel agent for the treatment of intraocular pressure (IOP) for open-angle glaucoma and ocular hypertension since the approval of the prostaglandin analogue latanoprost in 2003. This combination Rho-kinase (ROCK) inhibitor is an exciting development for those who manage glaucoma because it will allow the addition of a second once-daily topical medication when there is inadequate control with a once-daily prostaglandin. In the past, practitioners would often need to add a medication dosed two or three times a day. This is beneficial from the standpoint of improved patient compliance, reduced cost and less issues with exacerbation of co-existing dry eye disease.¹

In Rhopressa's Phase III FDA clinical trials, dubbed Rocket 1, 2, 3 and 4, the efficacy of netarsudil 0.02% QD or BID was compared with timolol 0.5% BID. The results showed great potential for glaucoma patients, but not without some corneal concerns.²

THE TROUBLE

In both Rocket 1 and 2, more subjects in the Rhopressa group discontinued use due to adverse events than those using timolol.² One of the more common adverse events was conjunctival hyperemia. This is an expected pharmacological effect, considering ROCK inhibition is known to cause vasodilation, and the medication is preserved with benzalkonium chloride 0.015%. While patients did not report

noticing an increase in redness, researchers noted some worsening of hyperemia in their slit lamp findings. If the redness is especially problematic for the patient, the medication can be discontinued and substituted with something that contains a different preservative or a preservative-free formulation.

Another more notable event was the incidence of corneal verticillata, or vortex keratopathy, which was present in about 21% of patients given once-a-day Rhopressa at the one-month mark in the four trials (*Figure 1*).² These brownish/grayish subepithelial corneal deposits radiate in the central cornea in a "whorl" pattern, and are a notable side effect in patients taking a number of medications such as amiodarone, an antiarrhythmic drug. In once-a-day Rhopressa patients, corneal verticillata was noted as similar in appearance to that associated with amiodarone, though milder and less distinct.

A follow-up study of 45 subjects who had ongoing corneal verticillata showed resolution with discontinuation in all but three subjects.² After study completion, it was resolved in one of the remaining subjects and improved in the other two with no meaningful changes in visual function. So, while corneal verticillata appears to be a common side effect of this drug, it also appears to cause no degradation in vision and resolves with discontinuation.

About 17% of subjects in Rocket 1 and 2 also showed mild subconjunctival hemorrhages, which can be striking in appearance and can cause concern in uninformed patients. Prior to starting the medication, clinicians should educate patients that these hemorrhages can occur, and

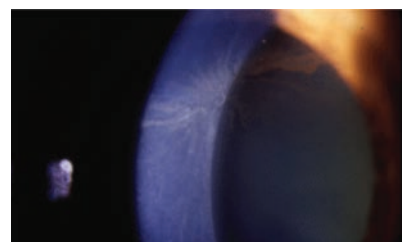


Photo: Jay S. Pense, MD, PhD

Fig. 1. Corneal verticillata may be a common side effect of Rhopressa.

if they do, the "blood" in the eye is benign and will quickly resolve.

Additionally, a study that compared netarsudil with latanoprost found the most frequently reported adverse event was conjunctival or ocular hyperemia, which was noted in 24% of netarsudil subjects vs. 11% in latanoprost subjects (though this was generally mild and transient).³

In another netarsudil vs. latanoprost study, researchers found a greater incidence of mild, diminishing conjunctival hyperemia (40% in netarsudil patients vs. 14% in latanoprost patients).⁴

When prescribing Rhopressa for your open-angle glaucoma and ocular hypertension patients, keep in mind that a significant amount of them may experience mild, transient conjunctival hyperemia, and almost one quarter of patients may manifest corneal verticillata. **RCCL**

1. Chaglasian EL, Than T. Juggling Dry Eye and Glaucoma. *RCCL*. 2017;154(5):10-1.

2. BusinessWire. Aerie Pharmaceuticals Announces FDA Advisory Committee Vote in Favor of Rhopressa (netarsudil ophthalmic solution) 0.02%. October 13, 2017. www.businesswire.com/news/home/20171013005587/en/Aerie-Pharmaceuticals-Announces-FDA-Advisory-Committee-Vote. Accessed February 13, 2018.

3. Bacharach J, Dubiner H, Levy B, et al. Double-masked, randomized, dose-response study of AR-13324 versus latanoprost in patients with elevated intraocular pressure. *Ophthalmology*. 2015;122(2):302.

4. Lewis RA, Levy B, Ramirez N, et al. Fixed-dose combination of AR-13324 and latanoprost: a double-masked, 28-day, randomised, controlled study in patients with open-angle glaucoma or ocular hypertension. *Br J Ophthalmol*. 2016;100:339-44.

SAVE THE DATE



November 7-10, 2018 San Antonio, TX Henry B. Gonzalez Convention Center

Nearly **200** hours of
optometry CE

21 CE hours dedicated
to contact lenses

CONTACT LENS LECTURE & SYMPOSIA SCHEDULE

Wednesday, Nov. 7

Post-Surgical Contact Lens Fitting and Management

Rutvi Doshi, Ellen Shorter

Rapid Fire: Managing Complications, Preventing Hypoxia, Fitting the Post-Transplant Cornea and Literature Update

Maria Walker, Pam Satjawatcharaphong, Melissa Barnett, Sandrine Malaisson-Tremblay

Recent Advances in Orthokeratology for Myopia Control

Randy Kojima, Patrick Caroline

Thursday, Nov. 8

Rapid Fire: OrthoK Update

Michael Lipson, Stephanie Ramdass, Paul Levine, Clarke Newman

Clinical Use of Therapeutic Bandage Contact Lenses

Bruce Baldwin

Bigger is Not Always Better: Corneal GP Contact Lenses for Post-Surgical Patients

Annie Chang, Dawn Lam

Prosthetic Contact Lenses

Marsha Malooley

Rapid Fire: Celebrating 20 Years of Silicone Hydrogels: The Past, Present, and Future

Karen Walsh, Lyndon Jones, Lakshman Subbaraman, Jill Woods

Friday, Nov. 9

Section on Cornea, Contact Lenses and Refractive Technologies Symposium: The U.S. Military Approach to Treating the Corneal and Ocular Surface Disease and Refractive Surgery in the Armed Forces

Loretta Szczotka-Flynn, Gary Legault, Anthony Johnson, Kelly Olson, J. Richard Townley

Contact Lenses for Infants: Indication, Evaluation, and Technique

Maureen Plaumann, Elaine Chen

Rapid Fire: Scleral Lenses: The Undiscovered Country

Langis Michaud, Jason Jedlicka, Greg DeNaeyer, Daniel Brazeau

New Advances in Contact Lens Care

Susan Gromacki

Scleral Shape Update: Publications, Instrumentation, Interpretation, Application

Jason Jedlicka

Nuts and Bolts of Fitting the Irregular Cornea

Tiffany Andrzejewski, Lindsey Sicks

This Is My Patient's Condition: Can Scleral Lenses Help?

Alan Kwok, Karen Carrasquillo

Saturday, Nov. 10

Rapid Fire: What's New in Scleral Lenses?

Chandra Mickles, Melissa Barnett, Gregory Denayer, Jennifer Harthan

Tips for Prescribing Soft Contact Lenses in Presbyopes

Alex Dominic Nixon, Erin Rueff

Pediatric Contact Lenses – Beyond the Basics

Yos Priestley

Corneal and Contact Lens Considerations in Glaucoma

Karen Lai Yin Lee, Jane Kuo

Learn more at
www.aaopt.org/2018

Schedule subject to change. Visit www.aaopt.org/2018 for updated information.



AMERICAN ACADEMY
of OPTOMETRY



Lend Color to the Fit

The transition from soft lenses to GPs can be difficult, but this creative solution could win over some of your patients.

For aphakic children younger than two, contact lenses are the primary choice for vision correction.¹⁻³ Unfortunately, no perfect lens modality exists for this therapy. Soft lenses such as Silsoft (Bausch + Lomb) are usually the top choice due to ease of fitting and high Dk material; however, these high plus lenses are only available in limited sizes and 3D changes in power, which does not allow for precision fitting. They can also soil, and replacements are expensive.

Some practitioners choose to fit custom soft lenses to control the lens parameters, but these are generally low Dk and have a higher risk of hypoxia.⁴ Others choose gas permeable (GP) lenses because of the premium optics, ease of handling, simple retinoscopy abilities and verification ability. However, these can be a challenge to fit.

These complications often force practitioners to get creative with their lens choices and remain flexible throughout the child's development. A younger child might be less sensitive to blurry vision compared with a teenager who may be ready to drive. Poor vision can also impact a child's learning, and it is our job to make their vision as clear as possible to allow them to succeed in school. This case highlights one of the common challenges associated with switching a soft lens aphakic patient to GPs: comfort.

THE CASE

A 16-year-old female presented with history of bilateral aphakia

and a primary complaint that her vision with her contact lenses was blurry and inconsistent. Her cataracts were removed in infancy, and she had a history of neovascularization with low Dk soft lenses.

She wore MetroSoft Definitive (MetroOptics) soft contact lenses at 8.6/+19.00/15.0 OD, 8.6/+20.00/15.0 OS. Her presenting visual acuity was 20/25- OD, 20/30- OS.

The patient's pupils were slightly decentered and peaked, but they were still reactive to light with no relative afferent pupillary defect in either eye. Extraocular movements were full OU. A slit lamp exam revealed clear lashes and corneas OU and deep and quiet anterior chambers OU. Aphakia was noted in both eyes. Her intraocular pressure was 15mm Hg OU. Keratometry readings showed 45.00/46.00@045 OD and 44.00/44.50@150 OS. Undilated posterior segment evaluation revealed normal fundus OU.

CONTACT LENS EVALUATION

Both soft lenses were centered with adequate movement. Over-refraction revealed:

- Plano +1.50x133 (VA of 20/20) OD
- -0.75 +1.75x060 (VA of 20/20) OS

I discussed lens options with the patient and her mother. GP lenses would offer the best vision but would require adaptation. Soft toric lenses may be more comfortable with less consistent vision. The patient was resistant to the idea of

rigid lenses and opted for soft toric lenses. The following MetroSoft Definitive lenses were ordered:

- 8.6/+20.50-1.50x 043/15.0 OD
- 8.6/+21.00-1.00x165/15.0 OS

SOFT LENS DISPENSING VISIT

The patient presented two weeks later with no new complaints. I placed the lenses on her eyes and allowed them to settle. On slit lamp examination, the lenses were well centered with adequate movement and toric markers at 6 o'clock. Visual acuities were 20/25- OD, 20/30 OS.

At this point, the patient reported that her vision fluctuated with each blink, and over-refraction did not improve vision OU. The patient's mother asked to try rigid lenses in office. I then placed diagnostic GP lenses of the following parameters on the patient's eyes:

- 7.90/ +15.00/9.8 OR: +3.00 20/20 OD
- 8.0/+15.00/9.8 OR: +2.00 20/20 OS

A spherical over-refraction brought the patient's vision to 20/20 OU. She was still resistant to GP wear, however. She said the lenses were uncomfortable and she wouldn't wear them. We discussed the adaptation period and I informed the patient that if she could not get used to the lenses, we could use soft lenses to piggyback for comfort. With much persuasion from her mother, the patient agreed to give the rigid lenses a try. The diagnostic GPs dropped low on the patient's eye and would likely drop lower due to the increase in plus power. As such, I made the front



optic zone smaller to decrease the weight of the lens. The following lenses were ordered:

- 7.90/+18.00/9.8, standard edge, BXO material, green, Foz: 7.5 standard edge OD
- 8.00/+17.00/9.8, standard edge, BXO material, blue, Foz: 7.5 standard edge OS

GP DISPENSING VISIT

The patient presented after another two weeks. After placing lenses on the patient's eyes and allowing them to settle, they were lid attached and centered with adequate movement. Vision was 20/20 OU with no over-refraction. The patient was still uncomfortable, however, and could not keep her eyes open. She was trained on lens insertion and removal and asked to build up wear time a few hours per day.

FOLLOW-UP VISIT #1

The patient returned two weeks later with complaints that she was not able to adapt to her GP lenses and the most she could wear them was four hours per day. Even though her vision was clear, the patient still felt she couldn't keep her eyes open.

We discussed alternate options, including piggyback lenses and scleral lenses. While scleral lenses often provide good comfort, I had concerns about the thickness of the high plus lens with her history of corneal neovascularization. When discussing piggyback lenses, the patient was resistant to the idea of wearing two sets of lenses. However, she also expressed

interest in changing her eye color, so I brought up the option of piggybacking colored lenses under her GPs and she agreed.

I placed plano power Air Optix Colors (Alcon) lenses in green on the patient's eyes underneath the GPs. The lenses did not interfere with her vision and she reported that they were significantly more comfortable, so I sent her home to try the combination.

FOLLOW-UP VISIT #2

The patient presented another two weeks later with both sets of lenses on her eyes. She was able to wear them for 12 to 14 hours per day, and her mother reported that the patient was more motivated to extend her wear time due to the color changing effect of the soft lenses. Her vision was stable and clear and comfort was good, so the prescription was finalized.

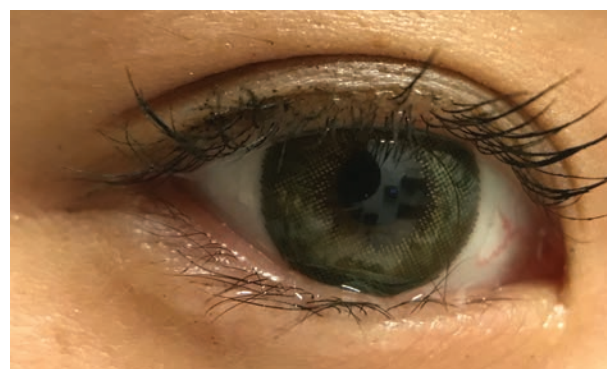DISCUSSION

Transitioning a soft lens wearer to GP lenses can be difficult for many patients, with infants and young children often adapting more easily than adults. In my clinical experience, it is easier to prescribe GP lenses for young children than it is to wait for a problem with soft lens wear before switching lens modalities. But when a soft lens

wearer does present with problems, clinicians can often be successful at transitioning them to GP lenses for better vision. It simply takes patience, flexibility and—sometimes—a little creativity.

In this case, using colored soft lenses in a piggyback system was a unique approach that motivated this teenager into full-time GP wear, ultimately providing her both the vision and comfort she needed. Now that colored silicone hydrogel lenses are available, this is a safe option and something to consider with tough patients.⁵ [RCLL](#)

1. Cromelin CH, Drews-Botsch C, Russell B, Lambert SR. Association of contact lens adherence with visual outcome in the Infant Aphakia Treatment Study: A secondary analysis of a randomized clinical trial. *JAMA Ophthalmol.* 2018;136(3):279-85.
2. Koo EB, VanderVeen DK, Lambert SR. Global practice patterns in the management of infantile cataracts. *Eye Cont Lens.* 2018. [Epub ahead of print].
3. Repka MX. Visual rehabilitation in pediatric aphakia. *Dev Ophthalmol.* 2016;57:49-68.
4. Levin AV, Edmonds SA, Nelson LB, et al. Extended-wear contact lenses for the treatment of pediatric aphakia. *Ophthalmology.* 1988;95(8):1107-13.
5. Weissman BA, Ye P. Calculated tear oxygen tension under contact lenses offering resistance in series: piggyback and scleral lenses. *Cont Lens Anterior Eye.* 2006;29(5):231-7.



Soft colored contact lenses, shown above, can serve to make other modalities more appealing through piggybacking options.

What's Better for MK, one or two?

Fluoroquinolone monotherapy can be just as effective as dual therapy for these cases.

Given the possibility of profoundly negative outcomes when dealing with microbial keratitis (MK), careful consideration is critical when deciding what initial treatment is appropriate. Prescribing a standard medication across all ulcer appearances and histories is a sure-fire way to eventually end up with a terrible outcome. For this reason, mining the case for clues of the most likely etiology and treating appropriately is a mandatory part of corneal ulcer care.

While sensitivity testing can help tailor the treatment for the specific organism, all antimicrobial treatment begins empirically since getting results back from a culture can take anywhere between one and seven days (unless you perform in-house gram stain interpretation). As such, the onus is always on the clinician to select the most appropriate initial treatment.

THE PARADIGM SHIFT

Over the last 20 years, we've been fortunate to practice in an era of relatively effective antimicrobial monotherapy. Fluoroquinolones are an effective treatment tool for most common etiologies of bacterial corneal infection—and while original coverage favored gram-negative pathogens, newer generations have expanded to cover gram-positive pathogens as well. This allows care delivery to move away from the cornea clinic standard of care (dual broad-spectrum fortified agents) to a single agent that is undoubtedly

easier to acquire and prescribe. As a result, monotherapy now predominates the management of corneal ulcers across the United States.

What's more, this shift has not led to any poor outcome trends, and in most cases, fluoroquinolone monotherapy has been effective. Research shows that single new-generation fluoroquinolones may be just as effective as dual broad-spectrum antibiotics, and one recent meta-analysis in particular shows no difference in treatment success, time to heal or risk of severe complication between the two.¹ The study also found no difference among the various fluoroquinolone agents, suggesting that ofloxacin may be as effective as moxifloxacin, and both may be as effective as dual fortified agents.

A caveat exists in applying this data universally, however, in the form of antibiotic resistance by methicillin-resistant *Staphylococcus aureus* (MRSA) and methicillin-resistant *Staphylococcus epidermidis* (MRSE). Based on data from both the Ocular TRUST 2 and ARMOR studies, we know that occurrences of MRSA and MRSE isolates are on the rise in the United States and that *in vitro* fluoroquinolones aren't terribly effective against them.^{2,3} The studies reviewed by the aforementioned meta-analysis suffer from a few similarities that makes them difficult to directly apply to clinic with today's resistance trends.

First, the studies in this review are drawn from across the globe, but distribution of micro-organ-

isms varies widely from region to region—as would be the case for MRSA and MRSE incidence. Therefore, studies from Thailand or India may not necessarily apply to a United States cohort, and expecting the results to tell us something about a problem as specific as antibiotic resistance in the United States is flawed thinking.

Second, nearly all of the US studies reviewed in the meta-analysis predate the ARMOR study, the Ocular TRUST 2 or both. Those two studies should serve as the ground floor for gram-positive resistance trends, which are most likely expanding.

Because of these issues, I believe that while monotherapy is still appropriate as frontline therapy for many bacterial corneal ulcers, it may be inappropriate in other cases such as co-infection, non-bacterial and resistant organisms despite support from research.

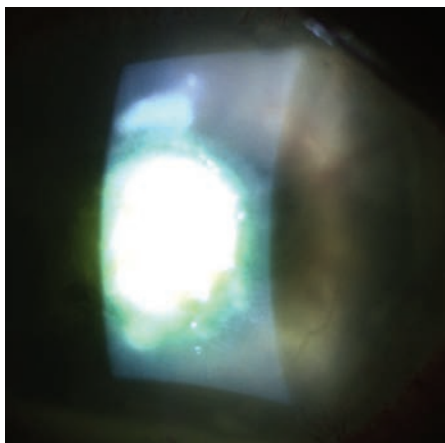
MAKING THE CALL

When deciding whether you want to proceed with initial fluoroquinolone monotherapy or pair it as a dual therapy, you should consider the most likely source of infection. Though it's impossible to fully differentiate ulcers based on clinical appearance and their supportive history, it is still possible to get down to some general assumptions.

We know that resistance to fluoroquinolones among gram-negative pathogens is a relatively rare phenomenon and that these medications work exceptionally well as monotherapy among this group. For that reason, fluoroquinolone



Photo: Scott G. Hauswirth, OD, and Richard Mangan, OD



Initial treatment for ulcers that are Staphylococcal in origin should be adjusted for the possibility of antibiotic resistance.

monotherapy would be reasonable for ulcers that support a conclusion of likely gram-negative involvement (i.e., those that look wet and mucousy and those with a contact lens history).

However, ulcers occurring as a result of ocular surface disease, in elderly patients, in those with rheumatoid arthritis or with a dry-looking infiltrate are more likely to be Staphylococcal in origin, so treatment should be adjusted for the possibility that an antibiotic resistant isolate may be causative. This doesn't necessarily require a move to fortified agents, however.

According to Ocular TRUST 2, a handful of commercially available agents such as trimethoprim/polymyxin B, aminoglycosides and bacitracin may be useful against these ulcers when paired with a fluoroquinolone. This gives you good coverage across a broad spectrum, including potential resistant organisms.² It should be noted, however, that bacitracin ointment

may be useful to limit the need for multiple nighttime doses, but probably shouldn't be used as paired therapy during the day because it may reduce penetration of other antimicrobial agents.

When deciding on the initial dosage, the severity of the ulcer you're dealing with will play a role—but again, it's possible to make some general recommendations. First, all antibiotics are concentration dependent, so the initial goal is to raise the local tissue concentration of the antibiotic to levels as high as possible. This requires a series of in-office loading doses every five to 15 minutes to rapidly achieve high stromal concentrations.

After this, instruct the patient to use the drop regularly, generally on an hourly basis during the day and every one to two hours at night. Again, the goal here is to maintain the elevated tissue concentration first achieved with the loading dose. If dual agents are required, we generally recommend they be used on alternating hours or half hours (if the ulcer is severe) during the day and then paired together during nighttime dosing.

Carefully considering all facets of the case to help select the most appropriate initial therapy will improve your comfort in managing these cases and, perhaps, the outcomes you achieve. However, initial therapy is still, at best, based on educated guesses about the etiology, so close follow-up is necessary to confirm your "best guess treatment" was appropriate.

Follow-up should be performed

daily until signs of improvement are noted, at which point the antibiotic dosing and frequency of follow-up should each be reduced in a stepwise fashion with continued improvement. In the face of treatment failure (i.e., the ulcer worsening over two days or not improving over several days), the only categorically inappropriate step would be continuing with the current therapy. Signs of worsening should be taken as indicative of treatment failure and the practitioner should consider culturing/re-culturing, referral or empiric treatment change.

While much research explores initial treatment options for MK, monotherapy with fluoroquinolones is no less effective than dual therapy. The influence of resistance on this strategy has not been fully explored. So, for each corneal ulcer, regardless of the culturing strategy, practitioners should scrutinize the elements of the case—including clinical appearance, history and response to any previous treatments—that may suggest one infectious etiology over another and consider how likely that etiology is to be resistant to fluoroquinolones prior to initiating empiric therapy. [RCLL](#)

1. McDonald EM, Ram FS, Patel DV, McGhee CN. Topical antibiotics for the management of bacterial keratitis: an evidence-based review of high quality randomized control trials. *Br J Ophthalmol.* 2014;98(11):1470-7.

2. Asbell PA, Sahm DF. Longitudinal nationwide antimicrobial susceptibility surveillance in ocular isolates: Results from Ocular TRUST 2. *Invest Ophthalmol Vis Sci.* 2008;49:1986.

3. Haas W, Pillar CM, Torres M, et al. Monitoring antibiotic resistance in ocular microorganisms: results from the Antibiotic Resistance Monitoring in Ocular Microorganisms (ARMOR) 2009 surveillance study. *Am J Ophthalmol.* 2011;152(4):567-74.



Back for Seconds

A keratoconic patient developed corneal protein deposits, requiring keratectomy—twice.

This 50-year-old male with keratoconus underwent collagen crosslinking in 2013 and subsequently developed white, elevated subepithelial deposits within the visual axis, requiring superficial keratectomy (SK). He presented in 2016 for a scleral lens evaluation secondary to persistent foreign body sensation. At the time, best-corrected vision was 20/25; however, in 2018 it had dropped to 20/70. An increased density of central scarring was noted and OCT showed deposits localized to the subepithelial region. SK is again indicated.

Amyloid is an insoluble, abnormal protein that aggregates in the cornea, numerous other ocular structures and elsewhere in the body.¹ Amyloidosis is an inherited disorder caused by de-

fects of the TGFBI gene. Depending on the type and position of the amino substitution, aggregates may be fibrillary or amorphously globular. The protein composition explains the different corneal phenotypes and depth of deposition. It typically appears as a greyish-white deposit.

Amyloidosis can be primary or secondary, with each further divided into systemic or localized forms. Primary corneal amyloidosis includes autosomal-dominant entities such as lattice, granular and Avellino dystrophies, as well as autosomal recessive drop-like gelatinous dystrophy.

Secondary localized amyloidosis, while uncommon, has been reported following corneal trauma and wound healing. It has also been associated with trichiasis, keratoconus and numerous ocular inflammatory

and degenerative conditions.²

While the mechanism of secondary localized corneal amyloidosis is unknown, research suggests it results from altered transforming growth factor β -induced protein, produced by injured keratocytes. Lactoferrin in the tear film and keratoepithelin from the corneal epithelium may also be involved.²

While this patient clinically appears to have secondary amyloidosis, his specimen will be sent to the pathology lab after his next SK. **CCCL**

1. Araki-Sasaki KI, Hirano K, Osakabe Y, et al. Classification of secondary corneal amyloidosis and involvement of lactoferrin. *Ophthalmology*. 2013;120(6):1166-72. .

2. Al-Dujaili LJ, Clerkin PP, Clement C, et al. Ocular herpes simplex virus: how are latency, reactivation, recurrent disease and therapy interrelated? *Future Microbiol*. 2011 Aug;6(8):877-907.

3. Knickerbein JE, Hendricks RL, Charukamnoetkanok P. Management of herpes simplex virus stromal keratitis: an evidence-based review. *Surv Ophthalmol*. 2009;54(2):226-34.



SYSTANE® COMPLETE:

OUR MOST ADVANCED SOLUTION. ONE SIMPLE CHOICE.¹⁻²

Our most innovative drop works to restore the tear film. It provides optimal relief by addressing **every major type of dry eye**.¹⁻⁷

- Evaporative Dry Eye**
- Aqueous-deficient Dry Eye**
- Mixed Dry Eye**



The Relief is Real™



With **advanced, lipid nano-droplet technology**, the lubricant is rapidly delivered across the ocular surface—resulting in **better coverage*** to provide fast hydration and locking in moisture for long-lasting relief.^{1-2,5,6,8}

TALK TO A REPRESENTATIVE TO LEARN MORE

*Compared to SYSTANE® BALANCE.

1. Ketelson H, Rangarajan R. Pre-clinical evaluation of a novel phospholipid nanoemulsion based lubricant eye drops. Poster presented at: The Annual Meeting of the Association for Research in Vision and Ophthalmology (ARVO); May 7-11, 2017; Baltimore, Maryland, USA. 2. Data on file. Alcon; 2017. 3. Fernandez KB, Epstein SP, Raynor GS, et al. Modulation of HLA-DR in dry eye patients following 30 days of treatment with a lubricant eyedrop solution. *Clin Ophthalmol*. 2015;9:1137-1145. 4. Davitt WF, Bloomenstein M, Christensen M, Martin AE. Efficacy in patients with dry eye after treatment with a new lubricant eye drop formulation. *J Ocul Pharmacol Ther*. 2010;26(4):347-353. 5. Korb D, Blackie C, Meadows D, Christensen M, Tudor M. Evaluation of extended tear stability by two emulsion based artificial tears. Poster presented at: 6th International Conference of the Tear Film and Ocular Surface: Basic Science and Clinical Relevance; September 22-25, 2010; Florence, Italy. 6. Lane S, Paugh J, Webb JR, Christensen MT. An evaluation of the in vivo retention time of a novel artificial tear as compared to a placebo control. Poster presented at: The Annual Meeting of the Association for Research in Vision and Ophthalmology (ARVO); May 3-7, 2009; Fort Lauderdale, FL. 7. Craig JP, Nichols KK, Akpek EK, et al. TFOS DEWS II definition and classification report. *Ocul Surf*. 2017;15:276-283. 8. Torkildsen G. The effects of lubricant eye drops on visual function as measured by the Inter-blink interval Visual Acuity Decay test. *Clin Ophthalmol*. 2009;3:501-506.

Technology in balance



Health



Vision




Comfort

Miru 1month: a unique family of silicone hydrogel monthly lenses.

Coming Spring 2018

MeniSilk™ and Nanogloss™ technologies designed to meet the demands of today's contact lens wearer.*



Material and surface technologies

MeniSilk™

- Ultra high Dk/t - 161 @ -3.00D
- Exceptional hydration
- Optimized transparency

Nanogloss™

- Super smooth surface
- Resistance to bacteria
- Excellent wettability



www.meniconamerica.com

*Menicon data on file April 2016

