

RCCL[®]

REVIEW OF CORNEA
& CONTACT LENSES

STAND OUT *With* *Specialty Lenses*

Avoid one-size-fits-all sameness by
tailoring your designs to each patient.

- SCLERAL AND GP EDUCATIONAL RESOURCES, p. 14
- GP FITTING OPPORTUNITIES, pp. 12, 26 & 40
- HYBRIDS AND PIGGYBACKS, p. 18
- TECHNOLOGY FOR CUSTOM FITS, p. 22

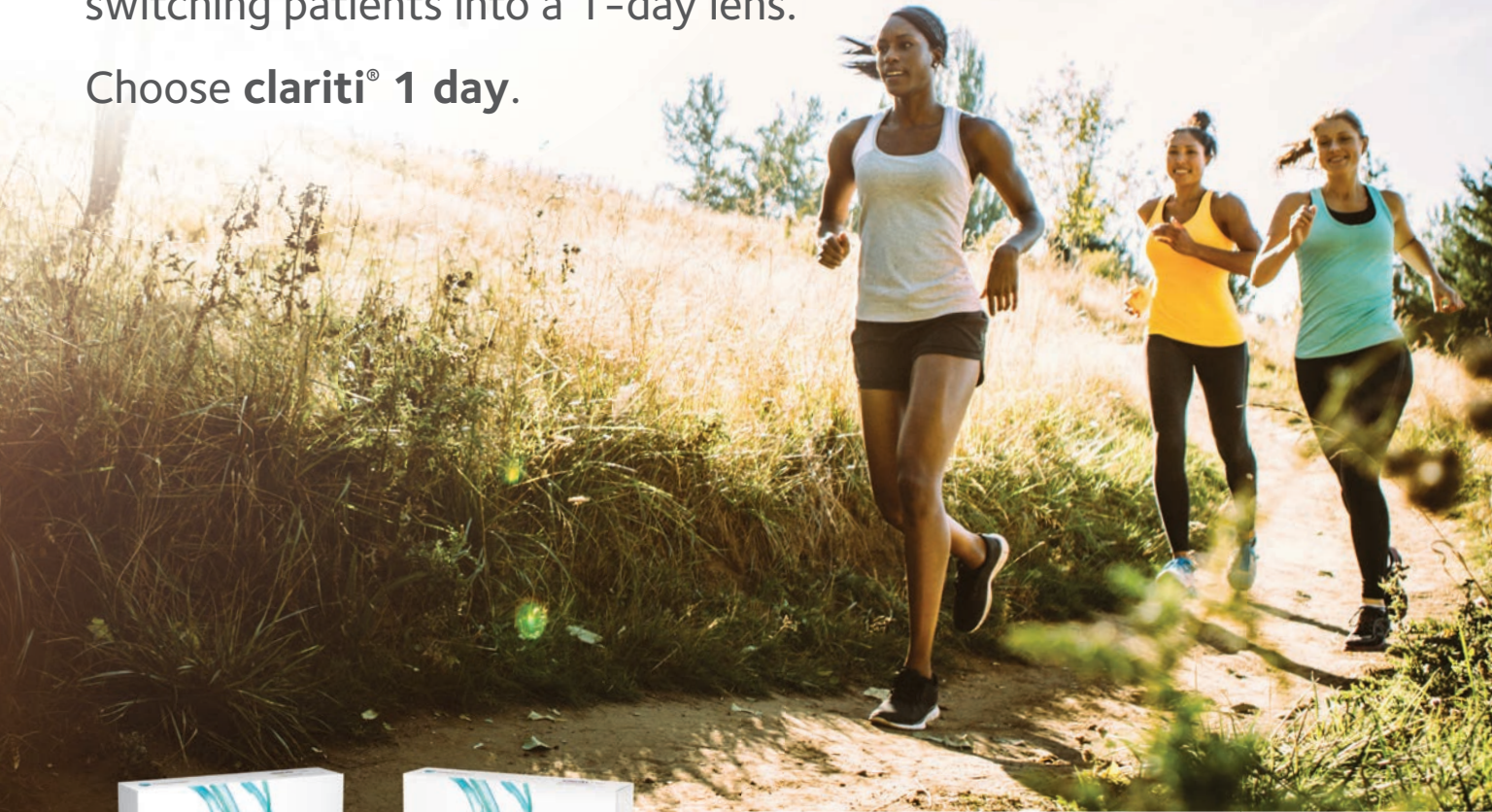
Supplement to

REVIEW[®]
OF OPTOMETRY

Comfort that can breathe.

Don't revert to low oxygen when switching patients into a 1-day lens.

Choose **clariti® 1 day**.



- Silicone hydrogel material with up to **3x** the oxygen transmissibility*
- All clariti® 1 day wearers **SAVE \$130** on an annual supply purchase†

Make the right choice for your patients. Prescribe oxygen.™



* When compared to some leading hydrogel 1-day lenses. Manufacturer reported Dk/t values: clariti® 1 day: 86; 1-DAY ACUVUE® MOIST®: 25.5; DAILIES® AquaComfort PLUS™: 26
† \$130 savings via manufacturer mail-in rebate (valid 5/1/17 - 12/31/17) following an annual supply purchase of clariti® 1 day brand contact lenses. Terms and conditions apply.

©2017 CooperVision 4414 04/17

clariti® 1 day

contents

Review of Cornea & Contact Lenses | September/October 2017

departments

- 4 News Review**
HSV-1 Inflammatory Mediator Found
- 6 My Perspective**
Report Your Adverse Events to the FDA
By Joseph P. Shovlin, OD
- 8 Guest Editorial**
FDA Efforts: Patient Perspective on LASIK
By Michelle E. Tarver, MD, PhD, Gene Hilmantel, OD, MS, and Malvina Eydelman, MD
- 10 Pharma Science & Practice**
Know Your Systemic Meds
By Elyse L. Chaglasian, OD, and Tammy Than, MS, OD
- 12 The GP Experts**
Overcoming GP Lens Obstacles
By Robert Ensley, OD, and Heidi Miller, OD
- 36 Corneal Consult**
Watch Out for HSV Endotheliitis
By Aaron Bronner, OD
- 38 Fitting Challenges**
Fitting CLs Post Trabeculectomy
By Vivian P. Shibayama, OD
- 40 Practice Progress**
Three GP Lenses to Grow Your Practice
By Mile Brujic, OD, and David Kading, OD
- 42 The Big Picture**
Crocodile Rock
By Christine W. Sindt, OD

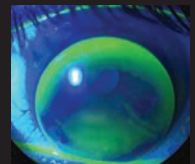
features

14 Starting Up with GPs: Use Your Resources
The field is replete with unique tools to aid practitioners in learning how to manage gas permeable lenses.
By Michael Iannucci, Associate Editor

18 Combining Optics and Comfort: Piggyback and Hybrid Lenses
Although less commonly used, these lenses could be a big help for some patients. Here's what you need to know.
By Suzanne Sherman, OD, and Nolan Wilson, BS

22 Sclerals & GPs: How to Build a Better Lens Fitting Experience
Practitioners have many tools available to help make the scleral and GP fitting process more efficient than ever.
By Shalu Pal, OD

26 CE — Expand Your Horizons: Think GPs for Presbyopes
Thanks to technological advances, multifocal gas permeable lenses are no longer a last resort for practitioners.
By Thuy-Lan Nguyen, OD, Zoeanne Schinas, OD, and Perla Najman, OD



32 A Closer Look at Corneal Inlays
This new option for dealing with presbyopia shows promise. Here's what you should know when considering a corneal approach.
By Justin Schweitzer, OD



Become a Fan on
Facebook

/ReviewofCorneaAndContactLenses



Follow Us on
Twitter

@RCCLmag

Cover images: Thuy-Lan Nguyen, OD, Zoeanne Schinas, OD, Perla Najman, OD; Tony Caporali, OD; Suzanne Sherman, OD; Getty Images.

IN BRIEF

■ Patients with **persistent epithelial defect** after bacterial keratitis who did not have success with topical fortified antibiotics may have a **new treatment** option with a matrix regenerating agent (RGTA), according to new research. In a case series of 14 patients, investigators found 78.6% achieved complete corneal healing after one drop of RGTA every other day for a month. After three months, 100% of study participants had complete corneal healing.

Chappelet MA, Bernheim D, Chiquet C, Aptel F. Effect of a new matrix therapy agent in persistent epithelial defects after bacterial keratitis treated with topical fortified antibiotics. *Cornea*. 2017;36(9):1061-8.

■ After evaluating 100 consecutive eyes undergoing SMILE refractive surgery at a tertiary care ophthalmic center, researchers found **the learning curve of SMILE can be challenging**. For the initial 100 eyes, surgeons experienced intraoperative difficulties such as suction loss, black spots, opaque bubble layer, epithelial defect and difficult lenticule extraction. The researchers note lenticule dissection and extraction is the most challenging step, and **complications dropped from 16% in the first 50 cases to 2% in the next 50 cases**. They found most complications led to delayed visual recovery in the first 50 cases.

Titiyal JS, Manpreet Kaur M, Anubha Rathi A, et al. Learning curve of small incision lenticule extraction: challenges and complications. *Cornea*. August 9, 2017. [Epub].

■ **Inflammation** may cause **end-of-day discomfort in contact lens wearers**, according to a recent study. After evaluating the concentration of certain proteins and inflammatory mediators in the tears of both symptomatic and asymptomatic contact lens wearers, researchers found that **leukotriene B₄ (LTB₄) levels were significantly higher** in symptomatic patients. No other compounds showed significant differences between the two groups, leading researchers to conclude that LTB₄ may play a role in contact lens discomfort and could be a target for therapy.

Masoudi S, Stapleton FJ, Willcox MDP. Differences in tear film biochemistry of symptomatic and asymptomatic lens wearers. *Optom Vis Sci*. 2017;94. [Epub ahead of print].

Enzyme Behind HSV-1 Inflammation Identified

In a recent study, researchers at the University of Illinois at Chicago identified the chief molecule responsible for herpes simplex virus-1 (HSV-1) infection-related corneal inflammation.¹ According to the findings, heparanase, a corneal enzyme that degrades heparan sulfate, becomes significantly upregulated during an HSV-1 infection. As a result, the enzyme triggers inflammation, lasting even after the infection has cleared.

“I think it’s easy for clinicians to forget that there are long-lasting complications of herpetic eye disease that last after the initial infection has cleared up,” says Bhawan Minhas, OD, assistant professor and director of on-campus residency programs at the Pennsylvania College of Optometry. “Sometimes they deal with the presenting infection successfully through antivirals and steroids but fail to consider the inflammatory cascade initiated by the event that requires more follow-up and management to prevent opacities and neovascularization of the cornea leading to further decrease in vision.”

Heparanase is normally active in the cornea, but only in low levels. In past studies, it was evaluated for its role as a cancer regulator. Here, however, researchers found that high levels of heparanase damaged cell junctions in the cornea and stimulated production of pro-inflammatory molecules, leading to inflammation.

According to Dr. Minhas, this means practitioners may need to consider keeping patients on a topical steroid for an extended period to inhibit sequelae of post-infection

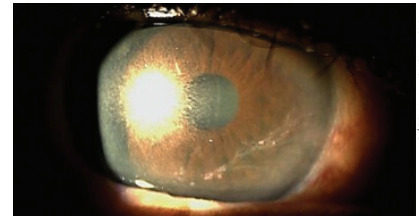


Photo: Bhawan Minhas, OD

Heparanase blockers could provide a potential treatment for corneal herpetic dendrites.

inflammation. “Ideally, a drug that specifically targets heparanase could be used as an adjunct well after antivirals and steroids are stopped,” she adds. Results from the study show that use of OGT 2115, a heparanase blocker, causes corneal lesions to heal quickly, while lesions not treated with OGT 2115 did not heal. As researchers believe this could lead to a new treatment option for HSV-1, Dr. Minhas wonders whether any drug companies have taken notice, and what possible side effects could be associated with heparanase blockers.

One important area for future studies to address is the effect of heparanase on other inflammatory ocular conditions. “I would like to see how this can be linked to other conditions that have similar issues with disruption of immune privilege of the cornea that cause scarring and ultimately further deterioration of vision,” says Dr. Minhas. [RCCU](#)

1. Agelidis AM, Hadigal SR, Jaishankar D, Shukla D. Viral Activation of Heparanase Drives Pathogenesis of Herpes Simplex Virus-1. *Cell Reports*. 2017;20(2):439-50.

Advertiser Index

Alcon	Page 5, Cover 3
CooperVision	Cover 2
Menicon	Cover 4
SynergEyes.....	Page 7

A FLEXIBLE LENS-WEARING EXPERIENCE TO HELP PATIENTS SEE, LOOK, AND FEEL THEIR BEST... DAY OR NIGHT



Scot Morris, OD, FAAO

Optometrist
Eye Consultants of Colorado
Conifer, Colorado

In my 20 years of practicing optometry, I have come across various types of patients with a multitude of visual and lifestyle needs - busy professionals, frequent travelers, new mothers, doctors and nurses with unpredictable work schedules, and even those who live in low-humidity environments like right here in Conifer, Colorado (elev. 8,200 feet). It is only by listening to our patients and understanding their needs that we can recommend the contact lens option that will give them the best contact lens experience.

These patients share one common need—a flexible lens-wearing experience which will allow them to wake up with comfortable, clear, immediate vision to perform their best. The one contact lens that immediately springs to my mind for these patients is AIR OPTIX® NIGHT & DAY® AQUA contact lenses from Alcon.

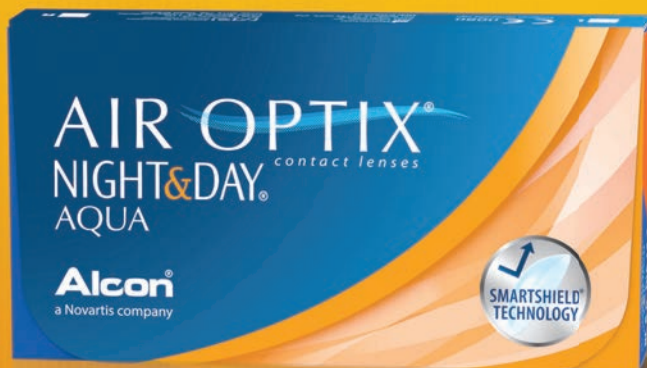In addition to the proprietary SmartShield® Surface Technology, which is featured in the entire AIR OPTIX® family,⁴ I like that AIR OPTIX® NIGHT & DAY® AQUA contact lenses are made of a material (Iotrafilcon A) which has the highest oxygen transmissibility in the market,^{5*} and an established safety profile.⁶

AIR OPTIX® NIGHT & DAY® AQUA contact lenses are the first to be introduced with these features and the only contact lenses designed to provide comfort for up to 30 nights of continuous wear. They are the #1 practitioner-recommended contact lens for people who sleep in their lenses,⁷ and ideal for people who lead busy lives. I also prescribe these to my patients who not only sleep in their lenses but also face lens dehydration and discomfort from living in our low-humidity environment, knowing that lenses from the AIR OPTIX® family maintain lens surface wettability and provide comfort throughout the wearing period.⁴

I am confident in recommending AIR OPTIX® NIGHT & DAY® AQUA contact lenses for extended periods and encourage you to give them a try. The benefits are quick and easy to communicate, and you can rest assured that they will give your patients the flexible lens-wearing experience they need to see, look, and feel their best.

Unpredictable Work Schedules	Busy Professionals	Frequent Travelers	Moms with Young Kids
Need immediate vision waking up for shift	Eyes feel strained looking at my mobile devices	Travel too often to hassle with my lenses	Can't see clearly getting up throughout the night

When patients express dissatisfaction with their contact lens-wearing experience, it may stem from their sleeping habits. Around 30% of contact lens-wearing patients admit that they sleep in their lenses,⁷ with a whopping 64% of these patients doing so for at least a week at a time in lenses not approved for this use.^{2,3} In addition, many patients may not have been offered contact lenses approved to meet their needs.



Our passion is to help your patients see, look, and feel their best.



*Dk/t = 175 @ 3.00D. Other factors may impact eye health.

Important information for AIR OPTIX® NIGHT & DAY® AQUA (Iotrafilcon A) contact lenses: Indicated for vision correction for daily wear (worn only while awake) or extended wear (worn while awake and asleep) for up to 30 nights. **Relevant Warnings:** A corneal ulcer may develop rapidly and cause eye pain, redness or blurry vision as it progresses. If left untreated, a scar, and in rare cases loss of vision, may result. The risk of serious problems is greater for extended wear vs. daily wear and smoking increases this risk. A one-year post-market study found 0.18% (18 out of 10,000) of wearers developed a severe corneal infection, with 0.04% (4 out of 10,000) of wearers experiencing a permanent reduction in vision by two or more rows of letters on an eye chart. **Relevant Precautions:** Not everyone can wear for 30 nights. Approximately 80% of wearers can wear the lenses for extended wear. About two-thirds of wearers achieve the full 30 nights continuous wear. **Side Effects:** In clinical trials, approximately 3-5% of wearers experience at least one episode of infiltrative keratitis, a localized inflammation of the cornea which may be accompanied by mild to severe pain and may require the use of antibiotic eye drops for up to one week. Other less serious side effects were conjunctivitis, lid irritation or lens discomfort including dryness, mild burning or stinging. **Contraindications:** Contact lenses should not be worn if you have eye infection or inflammation (redness and/ or swelling); eye disease, injury or dryness that interferes with contact lens wear; systemic disease that may be affected by or impact lens wear; certain allergic conditions or using certain medications (ex. some eye medications). **Additional Information:** Lenses should be replaced every month. If removed before then, lenses should be cleaned and disinfected before wearing again. Always follow the eye care professional's recommended lens wear, care and replacement schedule. Consult package insert for complete information, available without charge by calling (800) 241-5999 or go to myalcon.com.

References 1. In a survey of 2,115 daily and extended wear contact lens patients. Alcon data on file, 2012. 2. In a survey of 284 daily and extended wear contact lens patients. Alcon data on file, 2012. 3. Alcon data on file, 2012. 4. Eiden SB, et al. Prospective study of Iotrafilcon B lenses comparing 2 versus 4 weeks of wear for objective and subjective measures of health, comfort, and vision. *Eye & Contact Lens*. 2013; 39:290-294. 5. Based on published manufacturer-provided Dk and thickness values in: Tyler's Quarterly Soft Contact Lens Parameter Guide, June 2016. 6. Schein O, McNally J, Katz J, Chalmers R, et al. The incidence of microbial keratitis among wearers of a 30-day silicone hydrogel extended-wear contact lens. *Ophthalmology*. 2005;112:2172-2179. 7. In a survey of 301 optometrists in the US; Alcon data on file, 2016.



Report Your Adverse Events to the FDA

Sharing your issues through the FDA's online voluntary reporting system is simple and could have a meaningful impact on public health and safety.

When was the last time you reported a corneal ulcer from lens wear or a severe keratopathy secondary to inadvertent hydrogen peroxide instillation prior to neutralization to the Food and Drug Administration (FDA)? The answer is likely never. Fortunately, sight-threatening experiences in contact lens wearers are relatively rare. But when they do occur, there is little tolerance by the affected patient. This is especially true for family members when the patient is under the age of 18.

For a better assessment of risk, the FDA strongly encourages voluntary reporting by healthcare providers, patients, caregivers and consumers on any significant adverse event or problem with medical products.¹

FOR SAFETY'S SAKE

The FDA receives several hundred thousand reports of suspected device-related deaths, serious injuries and malfunctions every year.¹ Occasionally, eye care providers ask me: "Am I required to report adverse events related to contact lens use or any other medical device or drug?" While the FDA's Medical Device Reporting does not require health care professionals, including eye care providers, to report adverse events and product problems to the FDA by law, manufacturers, drug and device importers, and device user facilities are required to be mandatory reporters.

Unfortunately, the FDA relies heavily on reports of adverse events as a part of its charge for post-market surveillance of the drugs and devices it approves each year. It uses this information to monitor drug and device performance, detect potential device-associated safety issues and contribute to risk vs. benefit assessments of drugs, devices and products.^{1,2} Post-market surveillance of ophthalmic devices, including contact lens and refractive laser safety, is certainly an important part of the reporting system assessment. These reports and information gleaned from other sources can provide critical information to help improve overall safety.¹

WHERE TO REPORT

Practitioners can—and should—report contact lens complications to the FDA through the MedWatch online voluntary reporting form for medical devices, or through the MedWatcher mobile app using a smart phone or tablet.^{2,3} Alerting the FDA to complications is a salient mechanism by which laws, regulations, guidelines and labeling can be updated to improve public health and safety. It is also important to note that the FDA accepts reports on any medical product.

Additionally, the FDA's Adverse Event Reporting System is a valuable data system containing information on adverse events and medication errors that have been submitted to FDA for post-market drug safety surveillance. This tool helps the FDA evaluate new

potential safety concerns and manufacturer's compliance in reporting adverse events. Based on any safety concern that may arise, "the FDA may take regulatory action(s) to improve safety and protect the public."² Possible actions include labeling changes, restricting device or drug use, communicating new safety information to consumers or, in rare instances, removing a product from the market.²

Those who are interested can search the FDA Safety Information and Adverse Event Reporting Program database, which contains mandatory reports filed by manufacturers and importers as far back as 1996, reports filed by mandatory user facilities dating back to 1991 and voluntary reports filed as far back as 1993.^{1,2} While this passive surveillance system has its limitations, it still contains worthwhile information.

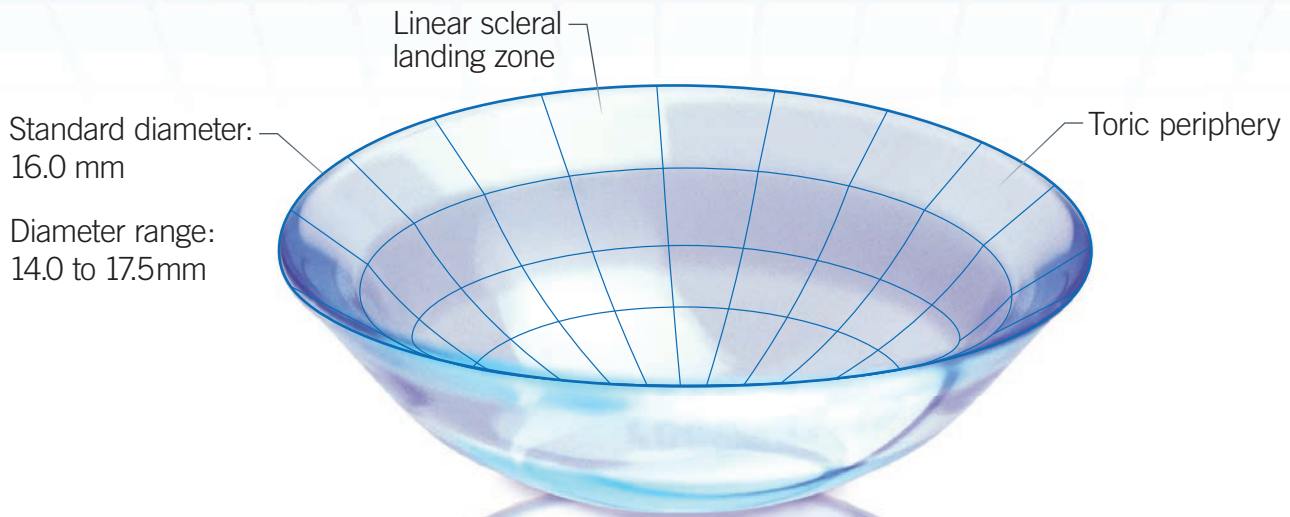
The next time your patient experiences an adverse event you suspect might be related to using a medical device or drug, consider reporting it to the FDA. It's easy, relatively quick and might just provide some valuable information to both the FDA and public. In the long run, this will help improve contact lens safety as a whole. **CCCL**

1. Medical Device Reporting. US Food & Drug Administration. www.fda.gov/MedicalDevices/Safety/ReportaProblem/default.htm-overview. Accessed August 10, 2017.

2. Questions and Answers on FDA's Adverse Event Reporting System. US Food & Drug Administration. www.fda.gov/drugs/guidancecomplianceregulatoryinformation/surveillance/adversedrugs-facts/. Accessed August 10, 2017.

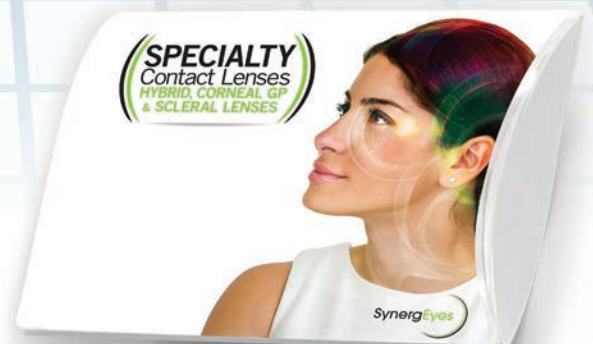3. MedWatch Online Voluntary Reporting Form. US Food & Drug Administration. www.accessdata.fda.gov/scripts/medwatch/. Accessed August 10, 2017.

Innovative Scleral Lens with a Distinctive Linear and Toric Periphery



SIX REASONS to Prescribe SynergEyes VS™ Scleral Lens:

- ① Proven lens, designed by experts, and already clinically successful with thousands
- ② Standard toric peripheral system aligns with the toricity of the sclera
- ③ Linear landing zones that follow the straight anatomy of the para-limbal sclera
- ④ Menicon Z material has a Dk of 163 and high deposit resistance
- ⑤ Each parameter may be adjusted independently, without affecting other parameters
- ⑥ 16-lens diagnostic set enables in-chair sagittal depth and peripheral alignment adjustments



FDA Efforts: Patient Perspective on LASIK

A new assessment tool may help to reveal unspoken symptoms post-refractive surgery.

Within the last three decades, the ophthalmic field has made great strides in refractive surgery. Laser in situ keratomileusis (LASIK), for example, accounted for approximately 600,000 surgeries in 2015, with most patients reporting satisfaction following the procedure.¹

While this surgical intervention generally improves vision, we at the US Food and Drug Administration (FDA) have received reports of some patients experiencing debilitating ocular and visual symptoms—such as dryness and glare—that significantly interfered with their daily functioning following

ABOUT THE PROJECT

The LQOLCP questionnaire development was conducted with input from the Study Group (who developed the protocols and questionnaire), the Administrative Operational Group (who oversaw the conduct of the studies) and the Steering Committee (who reviewed the protocols and the results of the studies). While the Study Group and Administrative Operational Group were comprised of federal employees and federal contractors, the Steering Committee was comprised of patients who underwent LASIK surgery with variable outcomes, as well as members with expertise in refractive surgery, clinical research and patient-reported outcome development selected from various professional societies and organizations (*Table 2*).

LASIK. In response, the FDA formed a collaborative effort with the National Eye Institute (NEI) to develop a questionnaire to better measure patient symptoms following LASIK. The LASIK Quality of Life Collaboration Project (LQOLCP) enlisted the clinical expertise of the Navy Medical Center San Diego and five civilian clinical sites across the United States to evaluate the tool.²

NEW MEASURES

Based on findings from LQOLCP pilot work showing the equivalence of paper and web-based ocular surface symptom questionnaires, the group developed a questionnaire that addressed many of the concerns mentioned in the literature following LASIK surgery, including: expectations prior to surgery, visual disturbances and satisfaction with vision and surgery.

In addition, we incorporated portions of legacy questionnaires such as the NEI Visual Function Questionnaire and Refractive Error Quality of Life Instrument, the Ocular Surface Disease Index and questionnaires assessing work productivity, depressive and anxiety symptoms, optimism, health proneness and social desirability responses.³

We then used the resultant multi-domain questionnaire in the Patient-Reported Outcomes with LASIK (PROWL) studies to evaluate the measurement properties of these scales (i.e., glare, halos, double images, starbursts, satisfaction with vision and satisfaction with surgery).

The PROWL-1 study was conducted at the Navy Medical Center San Diego, and the PROWL-2 at five private practice and academic clinical centers across the United States. Both studies were designed to determine how well the scales measured the concept of symptom burden on patients and to provide preliminary estimates of the prevalence of these symptoms in the pre- and post-LASIK patient population. We administered the questionnaires prior to LASIK surgery and following surgery for up to three months (PROWL-2) and six months (PROWL-1).

RESULTS

Our studies found that the scales measured the concepts of interest and were responsive to a change in the clinical state.^{3,4} Notably, we found that patients are more reluctant to report negative symptoms to their eye care provider than on questionnaires, possibly due in part to social desirability, because the responses to the questionnaire were “anonymous.”⁴ This underscores the importance of administering standardized questionnaires, which measure concepts of interest to patients and providers,

ABOUT THE AUTHORS

Dr. Tarver is a medical officer in the Division of Ophthalmic and Ear, Nose and Throat Devices, Office of Device Evaluation, Center for Devices and Radiological Health (CDRH), FDA, in Silver Spring, Md.

Dr. Hilmantel is an expert optometrist in the Division of Ophthalmic and Ear, Nose and Throat Devices, Office of Device Evaluation, CDRH, FDA.

Dr. Eydelman is the director for the Division of Ophthalmic and Ear, Nose and Throat Devices, Office of Device Evaluation, CDRH, FDA.



both before and after refractive procedures.

These results suggest the newly developed scales are a useful adjunct to the clinical examination to help elicit unspoken symptoms that can impact patients' satisfaction with their surgical outcomes.

We hope these publicly available scales will be used not only by device manufacturers in clinical

trials, but also in a host of other health care contexts, including assessment of long-term LASIK outcomes.² Only by listening to the patient's perspective during the development, evaluation and use of medical devices will we ensure the devices address patients' needs. ^{RCCL}

1. Statista. Number of LASIK surgeries in the United States from 1996-2020 (in thousands). www.statista.com/statistics/271478/

[number-of-lasik-surgeries-in-the-us](#). Accessed April 19, 2017.

2. US Drug and Food Administration. FDA LASIK Quality of Life Collaboration Project. www.fda.gov/MedicalDevices/ProductsandMedicalProcedures/SurgeryandLifeSupport/LASIK/ucm190291.htm. Accessed April 19, 2017.

3. Hays RD, Tarver ME, Spritzer KL, et al. Assessment of the psychometric properties of a questionnaire assessing Patient-Reported Outcomes with Laser In Situ Keratomileusis (PROWL). *JAMA Ophthalmol.* 2017;135:3-12.

4. Eydelman M, Hilmantel G, Tarver M, et al. Symptoms and satisfaction of patients in the Patient-Reported Outcomes with Laser In Situ Keratomileusis (PROWL) Studies. *JAMA Ophthalmol.* 2017;135:13-22.

Table 1. Overview of LASIK Quality of Life Collaboration Project

Phase	Objective	Location
Pilot	Compare patient-reported outcomes (PROs) of subjects using web-based questionnaires vs. paper versions of the same validated questions	NEI
Phase I	Design a web-based instrument for assessing PROs appropriate for the evaluation of healthcare-related quality of life issues in LASIK patients	Emmes (NEI contract research organization)
Phase IA	Conduct cognitive interviews to ensure ease of question understandability, user-friendly format, and comprehensive coverage of issues related to LASIK	Rand through Emmes
Phase II (PROWL-1)	Determine an initial estimate of the prevalence of post-LASIK PROs in a select patient population of naval LASIK patients as well as a step in the validation of the questionnaire	Naval Medical Center San Diego
Phase III (PROWL-2)	Further validate the newly developed questionnaire in the general population	National multicenter NEI Intramural clinical study

Table 2. Administrative Groups Involved in the Conduct of the PROWL Studies

Group	Task	Members
Study Group and Administration Operational Group (subset of Study Group)	Designed the protocols and questionnaire; Monitored study conduct	FDA (n=8 members) NEI (n=5 members) Department of Defense (n=2 members)
Steering Committee	Independently reviewed the protocols and study results, providing feedback and edits	Two patient representatives One member from each of the following: American Academy of Ophthalmology; American Optometric Association; American Society of Cataract and Refractive Surgery; Department of Defense; International Society for Quality of Life Research; NEI; Society for Clinical Trials
Clinical Sites	PROWL-1	Naval Medical Center San Diego
	PROWL-2	Durrie Vision; 20/20 Vision Indianapolis; Stanford University School of Medicine; The Johns Hopkins University Wilmer Eye Institute; Vance Thompson Vision

Know Your Systemic Drugs

Understanding what medications are linked to ocular conditions could help you solve enigmatic cases.

Consider the following situation: One of your established patients who has successfully worn contact lenses for years presents with bilateral contact lens intolerance and red eyes. Has the patient gone rogue and started using an inferior cleaning regimen or suddenly started overwearing the lenses? Perhaps, but an adverse ocular effect from a systemic drug should also be on your radar, especially if they recently started a new medication.

The eye is prone to drug-related adverse effects due, in part, to its extensive blood supply and relatively small mass.¹ Elderly patients are especially susceptible because of the increased likelihood of using multiple systemic medications for chronic conditions and impaired ability to metabolize and excrete medications.¹

We are very familiar with the potential of certain oral medications to cause ocular sequelae such as hydroxychloroquine, prednisone, topiramate, tamoxifen and amiodarone. But could lesser-known medications cause ocular side effects? How would you know?

This question can be overwhelming, as the United States Food and Drug Administration (FDA) Center for Drug Evaluation and Research approves hundreds of new medications each year. While most are existing products that have new approvals, from 2009 to 2016, the FDA approved 251 new molecular entities.^{2,3} In 2017 alone, 26 new drugs and biological products

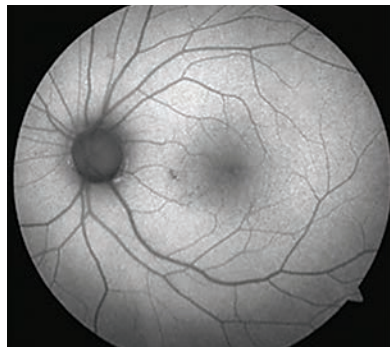


Photo: Beth Norris, OD, and Sara Henney, OD

Hydroxychloroquine is a well-known medication that can cause toxicity, shown here as an area of hypofluorescence nasal paracentral to the macula. But what other systemic medications and supplements should clinicians be on the lookout for?

have already been approved.³ Additionally, these approvals do not include the vast array of herbals and nutritional supplements that do not go through the FDA approval process.

As such, there is much to learn about new medications and supplements and their effects on the eye.

AVAILABLE RESOURCES

It is often challenging to determine if a systemic medication is causing an ocular condition. One useful resource is the book *Drug-Induced Ocular Side Effects*, which was written to help practitioners determine if a visual condition is related to a medication, an herbal supplement or another chemical.⁴ Ocular side effects are gathered from reports obtained by the FDA, MedWatch, the National Registry of Drug-Induced Ocular Side Effects (NRDIOSE) and the World Health Organization (WHO). The WHO Causality Assessment Guide

of Suspected Adverse Reactions is then used to classify the reported adverse drug-related events as certain, probable, possible, unlikely or unclassified.⁴

As the number of systemic medications is ever-increasing, it is difficult for literature to track every potential adverse event. When practitioners observe an ocular adverse event from a systemic medication that has not been previously documented, they should report it at www.eyedrugregistry.com or www.fda.gov/safety/medwatch. Another beneficial resource is the NRDIOSE, which provides practitioners with data on any drug that has significant ocular side effects, as well as updated literature on particular drugs.⁵

SUPPLEMENTS

Practitioners should ask patients about herbal and nutritional supplement use, as that could be another cause of ocular issues. Chamomile and psyllium have shown to cause nonspecific conjunctivitis, while niacin can cause dry eyes.^{4,6} Jimson weed (*Datura stramonium*), an annual herb used for a wide variety of conditions including asthma, analgesia and motion sickness, contains high concentrations of atropine and scopolamine, making it a potential cause of pupil dilation.^{6,7}

A DIAGNOSIS OF EXCLUSION

Even if a patient is taking a systemic medication that has been linked to ocular adverse effects, other pathologies should still



11 Campus Blvd., Suite 100
Newtown Square, PA 19073
Telephone (610) 492-1000
Fax (610) 492-1049

Editorial inquiries: (610) 492-1006
Advertising inquiries: (610) 492-1011
Email: rccl@jobson.com

EDITORIAL STAFF

EDITOR-IN-CHIEF

Jack Persico jpersico@jobson.com

MANAGING EDITOR

Rebecca Hepp rhepp@jobson.com

ASSOCIATE EDITOR

Michael Iannucci miannucci@jobson.com

CLINICAL EDITOR

Joseph P. Shovlin, OD, jpshovlin@gmail.com

ASSOCIATE CLINICAL EDITOR

Christine W. Sindt, OD, christine-sindt@uiowa.edu

EXECUTIVE EDITOR

Arthur B. Epstein, OD, artepstein@artepstein.com

CONSULTING EDITOR

Milton M. Hom, OD, eyemage@mmineternet.com

GRAPHIC DESIGNER

Ashley Schmouder aschmouder@jobson.com

AD PRODUCTION MANAGER

Scott Tobin stobin@jhihealth.com

BUSINESS STAFF

PUBLISHER

James Henne jhenne@jobson.com

REGIONAL SALES MANAGER

Michele Barrett mbarrett@jobson.com

REGIONAL SALES MANAGER

Michael Hoster mhoster@jobson.com

VICE PRESIDENT, OPERATIONS

Casey Foster cfoster@jobson.com

EXECUTIVE STAFF

CEO, INFORMATION SERVICES GROUP

Marc Ferrara mferrara@jhihealth.com

SENIOR VICE PRESIDENT, OPERATIONS

Jeff Levitz jlevitz@jhihealth.com

SENIOR VICE PRESIDENT, HUMAN RESOURCES

Tammy Garcia tgarcia@jhihealth.com

VICE PRESIDENT, CREATIVE SERVICES & PRODUCTION

Monica Tettamanzi mtettamanzi@jhihealth.com

VICE PRESIDENT, CIRCULATION

Emelda Barea ebarea@jhihealth.com

CORPORATE PRODUCTION MANAGER

John Caggiano jcaggiano@jhihealth.com

EDITORIAL REVIEW BOARD

Mark B. Abelson, MD

James V. Aquavella, MD

Edward S. Bennett, OD

Aaron Bronner, OD

Brian Chou, OD

Kenneth Daniels, OD

S. Barry Eiden, OD

Desmond Fonn, Dip Optom M Optom

Gary Gerber, OD

Robert M. Grohe, OD

Susan Gromacki, OD

Patricia Keech, OD

Bruce Koffler, MD

Pete Kollbaum, OD, PhD

Jeffrey Charles Krohn, OD

Kenneth A. Lebow, OD

Jerry Legerton, OD

Kelly Nichols, OD

Robert Ryan, OD

Jack Schaeffer, OD

Charles B. Slonim, MD

Kirk Smick, OD

Mary Jo Stiegemeier, OD

Loretta B. Szczotka, OD

Michael A. Ward, FCLSA

Barry M. Weiner, OD

Barry Weissman, OD

be ruled out first. When trying to determine whether an ocular side effect is linked to a systemic medication, it is essential to obtain a thorough medication history either from the patient or an electronic health record (if linked to the patient's medication history).

Take bisphosphonate calcium regulating agents, for example. They are most often used in the management of osteoporosis and include many well-known medications such as Fosamax (alendronate, Merck), Actonel (risedronate sodium, Proctor & Gamble Pharmaceuticals), Boniva (ibandronate, Roche Laboratories) and Zometa (zoledronic acid, Novartis). Ocular adverse effects of these medications include blurred vision, transient conjunctivitis, uveitis and scleritis. This does not imply that every patient will get these side effects, but if a patient does present with one of these ocular manifestations within a few days of beginning therapy with a bisphosphonate, it may be attributed to the medication.

It is imperative for practitioners to be aware of which common systemic drugs can cause adverse ocular effects. They must also maintain a high level of suspicion when looking at a patient's medication history. It is important to realize that even in the absence of officially-reported ocular adverse events, systemic medications may be affecting the ocular

health of patients. Because many of the medications linked to ocular side effects are prescribed by other providers and may not be able to be discontinued, practitioners should communicate both the findings and subsequent management plans to the patient's primary care practitioner or specialists. Most of these adverse events are infrequent, but they do occur and we need to be on the alert. **RCCL**

1. Santaella RM, Fraunfelder FW. Ocular adverse effects associated with systemic medications. *Drugs*. 2007;67(1):75-93.2. *Drugs@FDA*: FDA approved drug products. FDA.gov. www.accessdata.fda.gov/scripts/cder/daf/index.cfm?event=report.page. Accessed July 30, 2017.

3. New drugs at FDA: CDER's new molecular entities and new therapeutic biological products. FDA.gov. www.fda.gov/Drugs/Development/ApprovalProcess/DrugInnovation/default.htm. Accessed July 30, 2017.

4. Fraunfelder FT, Fraunfelder FW, Chambers WA. Drug-induced ocular side effects. 7th ed. Philadelphia: Elsevier Saunders;2015.

5. National Registry of Drug-Induced Ocular Side Effects. www.eyedrugregistry.com. Accessed July 29, 2017.

6. Wilkinson JT, Fraunfelder FW. Use of herbal medicines and nutritional supplements in ocular disorders: an evidence-based review. *Drugs*. 2011;1(18):2421-34.

7. Soni P, Siddiqui AA, Dwivedi J, Soni V. Pharmacological properties of Datura stramonium L. as a potential medicinal tree: an overview. *Asian Pac J Trop Biomed*. 2012;2(12):1002-8.

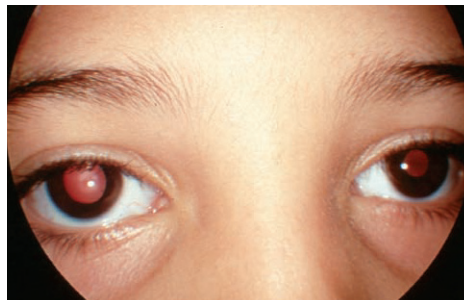

Photo: Joseph W. Sowka, OD, and Alan G. Kaba, OD

Handling plants such as Jimson weed, which contains atropine and scopolamine, is the likely cause of this patient's dilated tonic pupil OD.

Overcoming GP Lens Obstacles

Despite proven advantages, many practitioners shun GPs. Here's how to get over the hump.

The advent of soft disposable contact lenses permanently altered the contact lens landscape, resulting in the steady decline of corneal gas permeable (GP) lens fitting. At one point, it was even opined that GP lenses would be rendered obsolete.¹ Although this prediction has not come to fruition entirely, GP lenses are increasingly relegated to patients with complex prescriptions or high vision demands. Additionally, specialty designs such as custom soft toric, hybrid and scleral lenses are now widely available and steadily growing in popularity. Consequently, corneal GP lenses are often overlooked as a first choice for our patients.

Research shows GP lenses can provide superior vision quality compared with soft lenses.² Their smooth refracting surface in combination with the post-lens tear layer delivers crisp, stable optics, especially for patients with corneal astigmatism. Despite this advantage, practitioners are still hesitant to fit GP lenses. Let's address a few reservations practitioners may have.

INCREASED CHAIR TIME

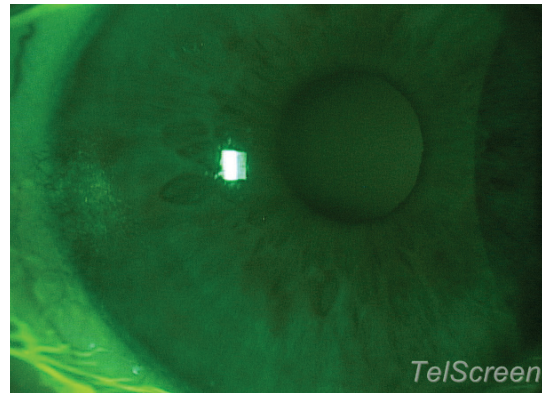
In a survey of contact lens fitters in the United Kingdom, GP lens fitting was perceived to require more technical skill and chair time than soft lenses.³ When a diagnostic fitting set is used, multiple diagnostic lenses may be assessed to find the appropriate lens-to-cornea relationship. An over-refraction is then required to determine the final power of the contact lens to be ordered. While

this fitting method may involve more chair time on the initial visit, fewer modifications should be required after ordering the initial contact lens. To choose an initial diagnostic lens, fitting calculators are available from resources such as the Gas Permeable Lens Institute, EyeDock and the GP laboratories themselves.

An alternative method to fitting GP lenses that can potentially save chair time is empirically ordering an initial lens. Laboratories can design lenses using only keratometry readings and a subjective refraction, although additional measurements such as corneal topography, horizontal visible iris diameter and pupil size can improve the precision of the initial lens design. The power of empirically ordered GP lenses is typically accurate, allowing for great initial vision to provide the "wow effect" that is especially critical for new wearers. To fine-tune the lens fit, usually only small adjustments are required. This approach also reduces the hassle of verifying, disinfecting and maintaining diagnostic lens sets.

COMFORT

Discomfort is the leading cause of contact lens discontinuation across all modalities.^{4,5} Therefore, it should come as no surprise that practitioners may be apprehensive about the initial comfort level of a GP lens. The smaller diameter allows for greater movement on




Here is a look at three and nine o'clock corneal staining with mild pannus.

Photo: Gaddie Vision Center

the eye and interaction of the lens edge with the eyelids, creating the sensation of lens awareness. Although the majority of contact lens wearers prefer the initial comfort of a soft contact lens, it does not mean they cannot be successful with GP lenses.⁶

The first step towards achieving optimal comfort begins before the lens is placed on the eye. Proper education about the adaptation process is paramount to the success of a new GP wearer. One study of neophyte GP wearers suggests the first 10 to 15 days are a good predictor of successful adaptation.⁷ Patients must understand that lens awareness will dissipate over time. A helpful analogy is to compare a GP lens to a new dress shoe and a soft contact lens to a slipper. New dress shoes must be broken in before they are comfortable, while slippers start out comfortable, but gradually break down over time. It is also helpful to be confident when presenting GP lenses. A positive attitude may be just enough for the patient to persist through the first few days of lens awareness.



With GP lenses, centration and lid interaction are important factors that contribute to the initial comfort. Fortunately, advances in automation have allowed modern GP lenses to be manufactured thinner with improved back surface geometry and more consistent edges.⁸ When the upper lid is at or below the superior limbus, a lid-attached fit using a slightly larger lens (9.2mm to 9.8mm) is recommended. If the upper lid is positioned higher, an inter-palpebral fit with a smaller diameter (<9.0mm) lens is preferred.

Lastly, for the neophyte GP wearer, research shows using a topical anesthetic at the initial dispensing appointment improves initial comfort and perception of adaptation. This also helps the practitioner evaluate the lens on eye without excessive tearing or blinking. Initial use of topical anesthetic can also improve the rate of satisfaction over the course of one month, reducing the risk of dropout.⁹

ADVERSE EVENTS

Like any contact lens, there are risks associated with GP lens wear; however, complications are typically mechanical in nature.¹⁰ One of the most common complications induced by GP lens wear is corneal desiccation. The vertical movement of the lens during the blinking motion can disrupt the adjacent tear film, causing dehydration of the peripheral cornea. This leads to punctate staining of the cornea both nasally and temporally, referred to as three and nine o'clock staining. In severe cases of desiccation, dellen

formation or vascularized limbal keratitis can occur. It has been reported that up to 90% of GP wearers will present with signs of desiccation, although improvements in lens design, such as peripheral curve and diameter changes, may reduce this to closer to 30%.^{11,12} When symptomatic, patients report dryness and redness, which can be typically managed with topical lubrication.

It can be easy to forget that GP lenses have an excellent safety profile with a lower rate of microbial keratitis (MK) and corneal inflammatory events (CIEs) than soft contact lenses.^{10,13-14} Most modern GP lenses are made with fluoro-silicone/acrylate polymers, which are highly permeable to oxygen, provide good surface wettability and lack any significant water content. These lens properties make it difficult for microorganisms to adhere to the lens. In addition to functioning as a flushing mechanism, the ability of GP lenses to facilitate tear exchange underneath the lens surface also provides a biochemical protection against microbes.¹⁵ Reducing the bacterial load helps to lower the risk of both CIEs and MK. CIEs are also caused by hypoxia; however, GP lenses are less commonly worn for extended periods than soft contact lenses.

Tear exchange also improves oxygen tension reaching the corneal surface.¹⁶ This may be part of the reason CIEs occur less frequently with GP wearers.

GP lenses have several benefits, including superior optics and an excellent safety profile.

Although initial comfort may be a factor, if a patient is motivated to adapt to the lens they can be quite successful. Don't hesitate to discuss GP lenses with your patients, including contact lens neophytes. **RCCL**

1. Efron N. Obituary--rigid contact lenses. *Cont Lens Anterior Eye*. 2010;33:245-52.
2. Michaud L, Barriault C, Dionne A, Karwatsky P. Empirical fitting of soft or rigid gas-permeable contact lenses for the correction of moderate to severe refractive astigmatism: a comparative study. *Optometry*. 2009;80:375-83.
3. Gill FR, Murphy PJ, Purslow C. A survey of UK practitioner attitudes to the fitting of rigid gas permeable lenses. *Ophthal Physiol Opt*. 2010;30:731-9.
4. Pritchard N, Fonn D, Brazeau D. Discontinuation of contact lens wear: a survey. *Int Contact Lens Clin*. 1999;26(6):157-62.
5. Richdale K, Sinnott LT, Skadahl E, Nichols JJ. Frequency of and factors associated with contact lens dissatisfaction and discontinuation. *Cornea*. 2007;26(2):168-74.
6. Fonn D, Gauthier CA, Pritchard N. Patient preferences and comparative ocular responses to rigid and soft contact lenses. *Optom Vis Sci*. 1995;72(12):857-63.
7. Carracedo G, Martin-Gil A, Peixoto de Matos SC, et al. Symptoms and signs in rigid gas permeable lens wearers during adaptation period. *Eye & Contact Lens: Science & Clinical Practice*. 2016;42(2):108-14.
8. Bennett ES, Sorbara L, Kojima R. Gas-permeable lens design, fitting and evaluation. In: Bennett ES, Henry VA, eds. *Clinical Manual of Contact Lenses*. 4th Ed. Philadelphia, PA: Lippincott, Williams & Wilkins; 2014:112-56.
9. Bennett ES, Smythe J, Henry VA, et al. The effect of topical anesthetic use on initial patient satisfaction and overall success with rigid gas permeable contact lenses. *Optom Vis Sci*. 1998;75:800-5.
10. Morgan PB, Efron N, Maldonado-Codina C, Efron S. Adverse events and discontinuation with rigid and soft hyper DK contact lenses used for continuous wear. *Optom Vis Sci*. 2005;82:528-35.
11. Edrington TB, Barr JT. Peripheral corneal desiccation. *CL Spectrum*. 2002;17:46.
12. Azhar J, Bennett ES, Castellano CF. Corneal desiccation in today's GP lens wearers: results. *CL Spectrum*. 2015;30:17.
13. Stapleton F, Keay L, Edwards K, et al. The incidence of contact lens-related microbial keratitis in Australia. *Ophthalmology*. 2008;115(10):1655-62.
14. Stapleton F, Keay L, Jalbert I, Cole N. The epidemiology of contact lens related infiltrates. *Optom Vis Sci*. 2007;84(4):257-72.
15. Fleiszig SM. The pathogenesis of contact lens-related keratitis. *Optom Vis Sci*. 2006;83:E866-73.
16. Weissman BA. Corneal oxygen. 2015. *CL Spectrum*. 2015;30:25-29, 55.

Starting Up with GPs: USE YOUR RESOURCES



By Michael Iannucci,
Associate Editor

The field is replete with unique tools to aid practitioners in learning how to manage gas permeable lenses.

Although many thought rigid gas permeable (GP) contact lenses were on their way out when soft contact lenses came to dominate the market in the 90s and early 2000s, innovation and technology have kept them alive and relevant.^{1,2} Today, they are an effective route to better vision and long-term comfort, as well as reduced risk of sight-threatening complications.²

Despite their utility, many practitioners still shy away from prescribing GP lenses in their practices. While learning how to fit patients for GP lenses may seem like a daunting task, there is an abundance of industry resources available to make adding them to your toolbox easier. And better yet, many of these resources are available right at your fingertips.

“Some of the best resources for GP lenses, including scleral lenses, can be found online,” says Heidi Miller, OD, of UC Davis Eye Center in Sacramento, Calif.

Here is a closer look at what’s out there to help practitioners add GP lenses to their repertoires.

THE GP LENS INSTITUTE

Since starting out as a seminar sponsor, the GP Lens Institute (GPLI)—the educational division

of the Contact Lens Manufacturers Association (CLMA)—has branched out to an all-encompassing resource with online webinars, educational materials for practitioners and more.³ According to GPLI Executive Director Edward S. Bennett, OD, the goal is to serve as the “go-to resource for GP and custom soft lens clinical education.”

Many of the GPLI’s resources are available on its website, www.gpli.info. These include:³

- More than 65 archived *webinars* by renowned specialty lens fitters covering crucial topics related to GPs.
- A *coding and billing module* under the direction of Clarke Newman, OD. This includes a webinar, as well as FAQs, letters and pamphlets to use for reimbursement purposes.
- A *grand rounds troubleshooting guide* featuring 52 case reports to show how specific GP designs (i.e., spherical, toric) can be successful.
- A *staff training module* to help practitioners guide their personnel in educating patients about different types of contact lenses. In addition to a detailed guide, the module features training videos and webinars.
- A collection of *laboratory consultant FAQs* covering the

most common questions asked of laboratory consultants and their responses.

- A *searchable lens database* for practitioners to browse and compare available options. According to Dr. Bennett, this is a “‘Tyler’s Quarterly’ of GP lens designs.”
- A *GP specialist database* for practitioners to help relocating patients find a GP lens specialist when they move.

- *Consumer brochures* on topics such as sclerals, multifocals, corneal reshaping and lens care.

The website also allows practitioners to narrow down their resource search results by lens type from the following categories: bitoric/high astigmatism, corneal reshaping, keratoconus/post-surgical, presbyopia/multifocals, scleral lenses, soft specialty lenses and spherical GP lenses.³

“Under the spherical GP category there are a number of different resources, some of which are ideal for students and practitioners desiring to have a very good understanding of the basics of GP fitting and evaluation,” says Dr. Bennett. “For example, ‘Click N’ Fit’ consists of a 15-lens diagnostic fitting set with varying base curve radii and overall/optical zone diameters, for which you can select to perform a virtual fitting on a patient” (Figure 1). Another of Dr. Bennett’s

recommendations under the spherical GP lens category is “GP Fitting, Evaluation and Problem-Solving,” an interactive, video-based tool that delves into fluorescein patterns and how to work through common GP problems such as decentration, surface wettability and desiccation.³

The bitoric/high astigmatism tab features several empirical bitoric guides and calculators. The GPLI Toric and Spherical Lens Calculator, for example, provides lens design parameters for recommended bitoric or spherical lenses after the user enters refraction and keratometry values (*Figure 2*).³

Among the resources found under the presbyopia/multifocals tab is a module on “Building Your Practice with GP Bifocals and Multifocals.”³ This includes videos and documents about GP multifocal fitting, evaluation and patient education on lens insertion and removal, as well as a fee calculator.

The scleral tab includes a number of scleral lens-related webinars, and “Scleral Lens Troubleshooting FAQs,” a guide with over 110 photos dedicated to scleral lens fitting, care and problem-solving.³

THE SCLERAL LENS EDUCATION SOCIETY

For practitioners looking to learn how to prescribe scleral lenses specifically, the Scleral Lens Education Society (SLS) is a valuable resource.⁴ Like GPLI, SLS serves as something of a go-to resource for all things scleral lenses, and the SLS website, www.sclerallens.org, contains a multitude of educational content for its members:⁴

- A “*living library*” of up-to-date, peer-reviewed research. “The research library is a great way to share with other providers,” says Melissa Barnett, OD, SLS im-

mediate past president. “For example, practitioners can share information about scleral lenses for keratoconus with a corneal specialist or scleral lenses for Sjögren’s syndrome with a rheumatologist.”

- A searchable *scleral lens fitter database* with the option to narrow the list down by state. The database is solely made up of practitioners who have completed an SLS fellowship, meaning they have proven their proficiency in scleral lens fitting, evaluation and patient management.

- A “*For Patients*” section contains scleral lens use instructions, FAQs, relevant links and more. Practitioners can send their new scleral lens patients here for quick, at-home answers.

- *Audio presentations* and *webinars* from top experts in the field cover topics such as fitting basics, billing and coding and answers to commonly asked questions.

- *Written information* and *FAQs* on scleral lens indications, selection, complications and care are quick resources for practitioners with specific questions.

Among SLS’s most popular resources is an all-encompassing video on scleral lens insertion, removal, troubleshooting and lens care, which can be found on the SLS homepage (*Figure 3*).⁴ “This video is widely shared on websites and is helpful for patients, practitioners and staff prior to the in-office dispense appointment,” says Dr. Barnett. SLS also offers a quiz to introduce practitioners to scleral lenses.⁴

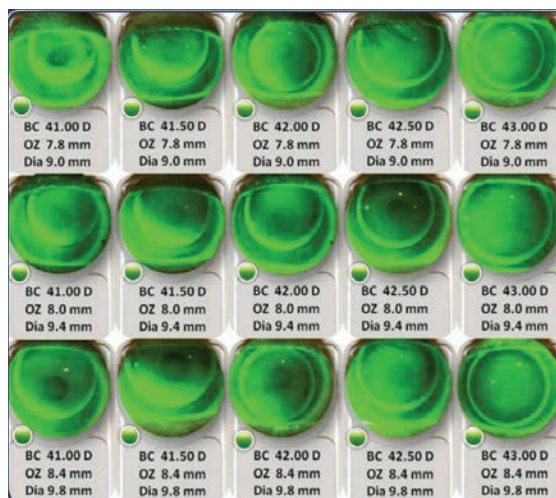


Fig. 1. GPLI’s “Click N’ Fit” online diagnostic fitting set gives practitioners a way to fit GP lenses interactively before trying the real thing.

Image: Edward S. Bennett, OD

LABS AND CONSULTANTS

One of the most helpful ways for practitioners to get started with GP lenses is to contact laboratories and their consultants. “There is no question so simple that a laboratory consultant has not heard it before, and they will assist you through the entire lens selection, fitting and problem-solving process,” says Dr. Bennett. “This could be a routine evaluation of a current GP wearer, a potential multifocal fit, an irregular cornea patient in need of GP lenses, a bitoric for high astigmatism or a scleral lens.”

In addition, “each manufacturer will have their own certification video tailored to their scleral design that must be completed prior to fitting,” Dr. Miller adds.

Using online calculators such as GPLI’s Toric and Spherical Lens Calculator, practitioners can fit spherical, bitoric and aspheric multifocal lenses empirically.⁵ “This, of course, makes GP fitting very simple,” says Dr. Bennett. “The consultant can provide diagnostic fitting sets, as well as useful advice on problem-solving all types of GP lens designs.”

STARTING UP WITH GPs: USE YOUR RESOURCES

Image: The GP Lens Institute

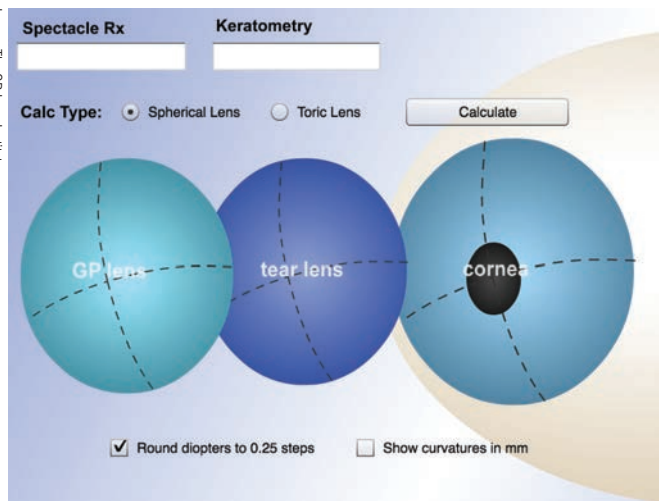


Fig. 2. The GPLI Toric and Spherical Lens Calculator gives practitioners lens design parameters for bitoric or spherical lens recommendations.

Laboratory consultants also offer in-office, hands-on training, says Dr. Barnett.

Another option is to use a smart phone-slit lamp adapter to take photos and video of the GP fitting relationship and send them to the laboratory. If corneal topography is available for the patient, sending it to the laboratory can also be a big help.

SELECTING A LAB

Today, choosing a quality GP lens laboratory is easier than ever before. “One of the great blessings today is that, although there are not as many laboratories as there were 10 to 20 years ago, the laboratories available today typically make consistent, high-quality GP lenses,” says Dr. Bennett. “Problems with inconsistent edge quality, poor initial surface wettability, less-than-optimal optics on toric lenses have all but disappeared.”

Also, “one of the hallmarks of the laboratories in existence today is the desire to work closely with each eye care practitioner to make them comfortable and successful in fitting GP lenses,” says Dr. Bennett.

Here are some of the most imperative qualities to look for when on the hunt for a GP lens laboratory:

- **A CLMA membership.** These laboratories must pass a stringent quality control program.⁶ “Whenever you hear of

a highly recommended specialty GP design, it is very likely that it is manufactured from a CLMA member laboratory,” says Dr. Bennett.

- **Lens types.** While all laboratories produce multifocal, irregular cornea and scleral lens designs, the design that you’re looking for—whether it be a specific multifocal lens, a keratoconic or post-surgical lens or a scleral lens—may only be made by a limited number of laboratories, so it is prudent to make this a priority in your search.

- **Peer recommendations.** Looking to your colleagues when making your laboratory decision can make the process much easier. “Fortunately, every region of the country has numerous high-quality laboratories to choose from, and it is very highly recommended that you use GP designs manufactured from as many as three or more laboratories,” says Dr. Bennett. As such, peer recommendations can be invaluable when deciding which laboratories to create accounts with.

- **Service, warranties, etc.** Quick turnaround on GP lenses is important to compete with soft lenses, so selecting a laboratory that can

keep up is important. By the same token, warranty and exchange programs vary by lens type, so practitioners should be sure that the laboratory they choose has a program that will work for their patients.

- **Available resources.** If a laboratory has a high-quality online help interface, chances are it is a high-quality laboratory, says Dr. Bennett. Look for easy access to conversion charts, webinars discussing lens fit scales, troubleshooting guides, searchable databases, detailed FAQs and anything else relevant to the questions you may have. Practitioners can find a list of CLMA member laboratories, including many with available resources, in GLPI’s Specialty Lab Directory.³

MEETINGS AND CONFERENCES

SLS provides COPE-approved education through lectures, webinars and workshops at annual meetings such as the American Academy of Optometry, Vision Expos East and West and Vision By Design.⁴ According to Dr. Barnett, “workshops with hands-on training are an ideal way to learn.”

New for this year is the **GPLI-sponsored GPLIwire2017: The Virtual Specialty Lens Conference.**⁷ Billed as “the first online continuing education event focused exclusively on specialty contact lens education,” the entirety of this COPE-approved conference will be available on-demand until December 1, 2017, for practitioners who can’t make it to the conference in person.⁷ Coursework covers scleral lenses, orthokeratology, custom soft lenses, presbyopia, hybrid lenses, ocular condition management with contact lenses and specialty contact lens fitting instrumentation.⁷

For practitioners looking to cover all their bases at one meeting, Dr. Barnett believes the *Global Specialty Lens Symposium (GSLs)* is “one of the best meetings for scleral lenses in the United States.” While GSLs focuses on the full spectrum of today’s specialty lenses, Dr. Barnett notes that its scleral lens coverage is especially expansive, often featuring introductions to new scleral lens designs and technology.⁸

Another new meeting on the circuit is the *International Congress of Scleral Contacts*, which just completed its second annual run on July 28, 2017.⁹ Dedicated entirely to scleral lenses, this full-day meeting gives practitioners information all over the scleral landscape. This year’s topics included scleral technology, marketing, ocular surface complications, an ophthalmology perspective and more.⁹

Also a scleral-exclusive meeting, the *International Forum for Scleral Lens Research* focuses on evidence-based information about scleral lenses.¹⁰ One of this meeting’s main purposes is to address the lack of consensus surrounding scleral lenses.¹⁰

Other international meetings that cover specialty contact lenses include the *British Contact Lens Association*, the *Cornea & Contact Lens Society of Australia* and the *Netherlands Contact Lens Congress*.¹¹⁻¹³

ADDITIONAL RESOURCES

Some other tools available to practitioners include:

- “*A Guide to Scleral Lens Fitting*” by scleral lens expert Eef van der Worp provides a “general understanding on everything you need to know about scleral lenses,” according to Dr. Miller.¹⁴ A free, downloadable version of this book is available through Pacific University at <http://commons.pacificu.edu/mono/4>.¹⁴

- *Scleral Lens Fit Scales*, available through Ferris State University’s website, are a helpful way to “demonstrate how to correctly estimate clearance by comparing the tear layer thickness with the center thickness of the lens,” says Dr. Barnett.¹⁵ The scales feature example photos of central vaulting, limbal vaulting and edge relationship to provide “visual ex-

amples on what to look for behind a slit lamp when fitting a scleral lens,” says Dr. Miller.¹⁵

While these resources can give practitioners a solid basis on which to build their GP lens practices, it is up to the individual to keep up with the necessary steps for successful lens fitting. “Whichever resources you choose, it is important to develop a strong understanding on how to appropriately fit each type of GP lens,” says Dr. Miller. “Following the fit guides provided by each company and using the specialty lens consultants from each manufacturer will help develop the confidence and efficiency to manage a variety of patients with specialty GP lenses.” **nccu**

1. Efron N. Contact lens practice and a very soft option. *Qin Exp Optom*. 2000;83(5):243-5.
2. Gill FR. Turning the tide for gas permeable contact lenses. Cardiff University. 2010. orca.cf.ac.uk/54980/1/U585369.pdf. Accessed August 4, 2017.
3. GP Lens Institute. www.gpli.info. Accessed August 4, 2017.
4. The Scleral Lens Education Society. www.sclerallens.org.
5. GPLI Toric and Spherical Lens ulator. www.gpli.info/lens-calculator. Accessed August 4, 2017.
6. Code of Ethics. Contact Lens Manufacturers Association. www.clma.net/about-the-clma. Accessed August 4, 2017.
7. GPLIwire2017: The Virtual Specialty Lens Conference. www.vconferenceonline.com/microsite/html/event.aspx?id=1296. Accessed August 7, 2017.
8. Global Specialty Lens Symposium. www.gsl-symposium.com. Accessed August 4, 2017.
9. International Congress of Scleral Contacts. www.icscmeeting.com. Accessed August 7, 2017.
10. International Forum for Scleral Lens Research. University of Houston College of Optometry. ce.opt.uh.edu/live/2017/international-forum-for-scleral-lens-research1. Accessed August 8, 2017.
11. British Contact Lens Association. www.bcla.org.uk. Accessed August 8, 2017.
12. Cornea & Contact Lens Society of Australia. www.cclsa.org.au. Accessed August 8, 2017.
13. Netherlands Contact Lens Congress. ncc2018.com. Accessed August 8, 2017.
14. van der Worp E. *A Guide to Scleral Lens Fitting* [monograph online]. Forest Grove, OR: Pacific University; 2010. commons.pacificu.edu/mono/4. Accessed August 4, 2017.
15. Lotoczky J, Rosen C, Norman CW. *Scleral Lens Fit Scales*. Ferris State University Michigan College of Optometry Vision Research Institute. 2014. www.ferris.edu/HTMLS/colleges/michopt/vision-research-institute/pdfs-docs/Scleral-lens-fit-scales_v2.pdf. Accessed August 4, 2017.

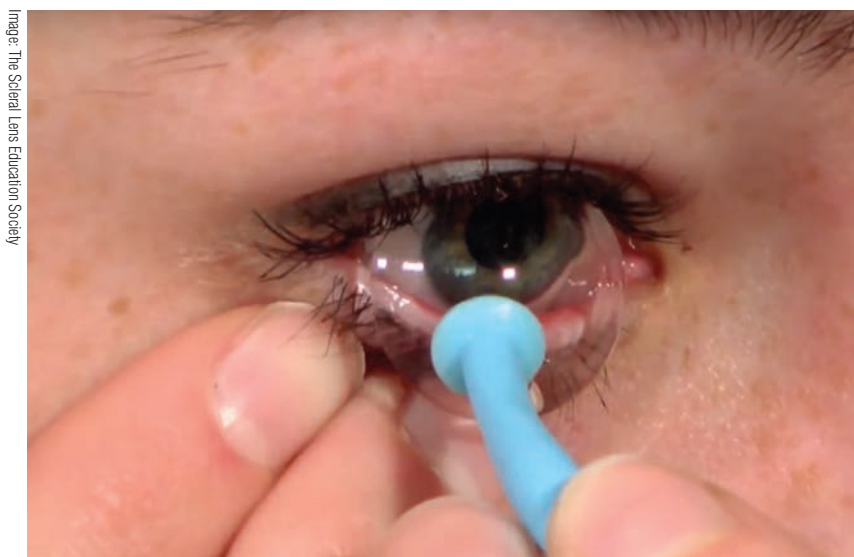

Fig. 3. The SLS homepage features a video that walks users through the basics of scleral lens insertion, removal, troubleshooting and lens care.

Image: The Scleral Lens Education Society

Combining Optics and Comfort: Piggyback and Hybrid Lenses

Although less commonly used, these lenses could be a big help for some patients. Here's what you need to know.

By Suzanne Sherman, OD, and Nolan Wilson, BS

With the recent boom of scleral lenses, practitioners are flooded with a range of lens designs to choose from. Although scleral lenses are the new hot trend, some patients might do better with alternative options such as piggybacking and hybrid contact lenses to improve vision and comfort and maintain long-term corneal health.

The piggyback system consists of a gas permeable (GP) lens fit on top of a soft contact lens. It offers the optics of a GP lens with the comfort of a soft contact lens. Hybrid lenses have a GP lens center surrounded by a soft contact lens skirt.^{1,2} They are similar to the piggyback system in that they, too, provide the optical quality of a GP lens with the comfort of a soft contact lens; but, unlike the piggyback system, they do so in one contact lens. Both of these options can be used as an alternative to conventional lenses. Here, we review the piggyback system and hybrid contact lenses and how they have progressed over the years.

PIGGYBACK

The term *piggyback* was initially used to describe a GP lens fit on top of another GP lens for a bifocal effect.³ Today, it describes the doubling of a soft contact lens with a GP lens.

Before the invention of silicone hydrogel soft contact lenses, the

low-Dk value of regular hydrogel soft contact lenses was insufficient for tear exchange around both soft and GP contact lenses, and users often developed corneal edema or neovascularization secondary to hypoxia.^{4,5} Today, providers can prescribe a silicone hydrogel lens under a GP and know the combination will not compromise the health of the cornea.^{3,4}

Indications. Practitioners commonly consider piggybacking in current GP wearers with regular or irregular corneas who may need to be switched out of their GP lenses due to discomfort or corneal compromise.

While GP lenses are generally a comfortable option, a number of factors may contribute to lens discomfort, including: edge awareness, lens decentration or apical bearing. GP wearers can experience low tolerance to the lens and may complain of an upper or lower lid foreign body sensation. Due to a poor fit, GP lenses can rub against the cornea, causing pain and foreign body sensation, and possibly lead to central and peripheral superficial punctate keratitis—and even apical scarring. Long-term contact lens wearers with corneal ectasia may also experience corneal flattening with GP lens use. Additionally, it can be challenging to center a GP lens for a patient with significant irregular astigmatism, leading to decreased vision and comfort.⁶ A piggyback system can alleviate

many of these factors and help to protect the cornea from contact-lens related adverse events.

In irregular corneas—for example, keratoconus—significant damage can occur with too much apical bearing. Keratoconic patients with signs and symptoms of corneal compromise are ideal candidates for piggybacking or a design change.

How it works. The soft contact lens shields the cornea from the GP lens, acting as a cushion between the GP lens and the cornea. In addition, the soft contact lens covers the entire cornea, minimizing the possibility of corneal abrasions or peripheral corneal abnormalities.⁷

The ideal soft contact lens in this system is a silicone hydrogel disposable lens. A daily disposable lens is often preferable to avoid having two lens cleaning systems. Silicone

ABOUT THE AUTHORS



Dr. Sherman is an instructor in Optometric Science (in Ophthalmology) at Columbia University Medical Center. She received her undergraduate degree from the University of Michigan and graduated from SUNY College of Optometry. She completed her optometric residency in Ocular Disease and Primary Care at Bronx Lebanon Hospital Center. She specializes in complex and medically necessary contact lens fittings and ocular disease.



Mr. Wilson is a graduate of Yale University and a third year OD/MS candidate at SUNY College of Optometry. He is interested in specialty contact lenses and the management of corneal disease.

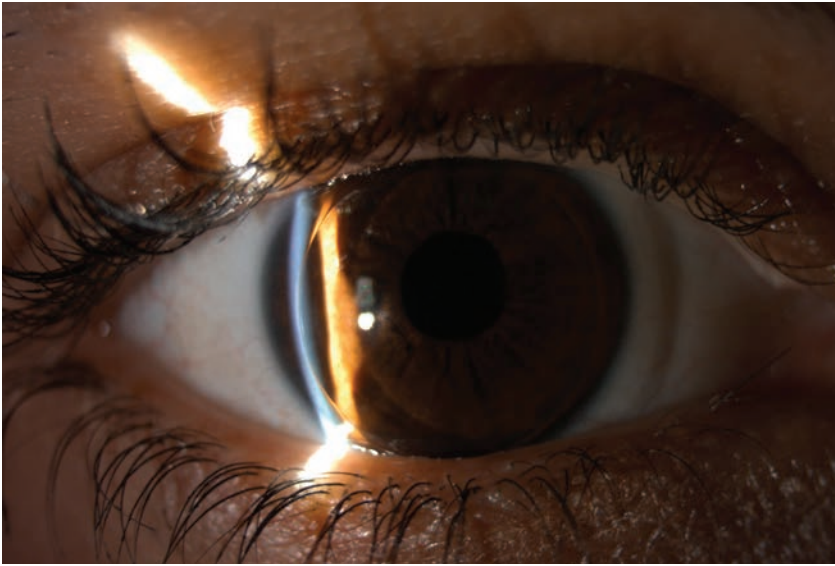


Fig. 1. This patient is wearing a GP lens fit on top of a silicone hydrogel lens due to daily RGP lens awareness.

hydrogels are superior because they have higher Dk values than regular hydrogels and are more rigid, which allows them to drape around—rather than cling to—irregular corneas.

More than one fitting approach exists for a piggyback system, but some basic concepts are universal. When working with a current GP lens wearer who has discomfort, start with a low minus or plus silicone hydrogel lens below the GP lens. Some practitioners prefer to start with an insignificant amount of $-0.5D$ or $+0.5D$ power and then use the previous GP lens or fit a new GP as though the soft lens was not in place. In this case, practitioners often do not have to worry about a change in refractive power because the soft lens only accounts for about 20% of its power in the piggyback system.⁸ In a patient who does not always wear their soft lens, this is the best approach. If a stock lens results in stand-off, a custom soft lens with a steeper base curve may be necessary.⁹ In a new contact lens patient, keratometry measured over the soft contact lens can provide a starting point. Patients with a low apex may do well with a

low to moderate plus lens.⁹ The GP lens should be well centered over the soft contact lens, with minimal edge lift and good movement upon blink.^{9,10,11}

Pros: Patients do not need time to adjust to their lenses, and they have the optics necessary to see. The silicone hydrogel soft lens is in contact with the cornea and provides epithelial protection, which aids in maintaining the health of the cornea.⁸ Often, they can use their previous GPs comfortably. For irregular cornea patients, putting a soft contact lens underneath their current GP lens is a practical and safe option to keep them in their current lens modality.

Cons: The piggyback system requires insertion, removal and care for two different sets of contact lenses—which means twice as much money and time.

In addition, patients should use a multipurpose solution approved for both soft and GP lenses. However, a daily disposable soft contact lens can mitigate some of these issues.^{4,12,10} For patients with a more progressed inferior cone, silicone hydrogels tend to wrinkle, making a successful fit difficult.

HYBRIDS

The first hybrid contact lens, debuted in 1985, was made of cross-linking materials that locked together the GP center and soft skirt. The polymer materials, however, often failed and left users with ripped lenses. Moreover, the lens frequently had poor edge lift and inadequate movement, creating the potential for corneal neovascularization.¹³

In 2005, SynergEyes manufactured a new generation of hybrid contact lenses with new technologies aimed at reducing lens tears and increasing oxygen permeability (*Figure 2*). The new launch included lenses tailored to astigmatic (SynergEyes A), presbyopic (SynergEyes multifocal), keratoconic (SynergEyes KC) and postoperative (SynergEyes PS) patients.^{1,13}

Soon after, the company came out with a second generation of hybrid contact lenses with GP lenses covalently bonded to soft skirts made of silicone hydrogel (*Figure 3*). The new unveiling included Duette,

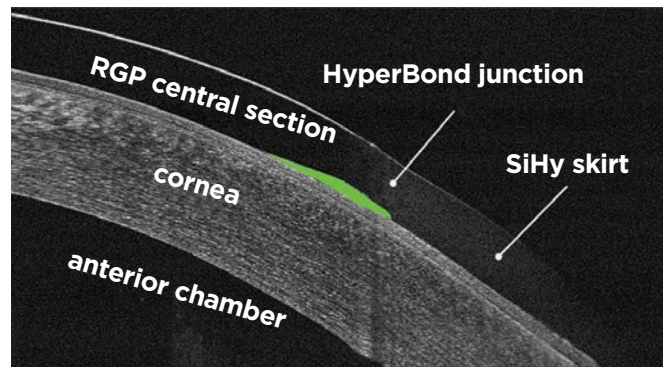


Fig. 2. This OCT image highlights the company's so-called "HyperBond" junction, designed to help reduce lens tearing.

COMBINING OPTICS AND COMFORT: PIGGYBACK AND HYBRID LENSES

Duette multifocal, UltraHealth and UltraHealth FC with central and peripheral Dk values of 130 and 84, respectively (Figure 4).^{13,14} These new lenses provide a lower wetting angle and ultraviolet blocking, according to the company.¹⁵

Indications. These hybrid lenses do not correct for lenticular astigmatism and should only be considered for patients with little to no residual astigmatism. For most other cases, they work well on regular and irregular corneas, on patients with and without a history of GP lens use, and are generally good alternative to scleral contact lenses (Figure 4).¹³

How it works. Here is a quick look at each of the SynergEyes hybrid contact lenses:¹⁶

Duette (astigmatism and spherical). This lens is an option for highly myopic patients, soft toric lens wearers and GP intolerant patients. It offers stable, comfortable vision with its improved tear exchange and lens movement, according to the company. With the aspheric GP at 8.4mm in diameter and the

silicone hydrogel skirt, the entire lens diameter is 14.5mm. These lenses are also available with Hydra-PEG polymer coating (Tangible Science) to improve contact lens comfort and wettability (Figure 5).¹⁶ These lenses are fit empirically with Ks and Rx, so practitioners do not need to use a diagnostic set.

Duette multifocal. This lens has a silicone hydrogel skirt, corrects for astigmatism and provides simultaneous vision. The center zone is aspheric and provides progression of power from near to distance. Practitioners can choose from three add powers (+1.00, +1.75 and +2.50D) and can choose to include the Hydra-PEG polymer coating. These lenses are also fit empirically with Ks and Rx without the need for a diagnostic set.¹⁶

UltraHealth. This second generation lens was designed to vault

corneal ectasia and is indicated for patients with keratoconus, ectasias, post-surgery, post-corneal collagen crosslinking, Intacs corneal implant (AJL Ophthalmic) and other corneal irregularities. It has an aspheric reverse geometry GP center of 8.5mm and a total diameter of 14.5mm with the silicone hydrogel skirt and is also available with the Hydra-PEG polymer coating. Practitioners can use a diagnostic fitting set for these lenses.¹⁶

UltraHealth FC. An extension of UltraHealth, these lenses are indicated for post-corneal surgery or trauma and work well for oblate corneas. They include flatter base curves than the standard UltraHealth, have a silicone hydrogel skirt and are available with the Hydra-PEG polymer coating. A diagnostic fitting set is necessary when fitting patients.¹⁶

SynergEyes A. This hybrid lens—the first with FDA clearance—has a hema skirt and is indicated for patients with high astigmatism and early stages of keratoconus.¹⁶

SynergEyes KC. This option, also with a hema skirt, is designed for more advanced cases of keratoconus (Figure 6).¹⁶

SynergEyes ClearKone. This lens, with a hema skirt, is designed to vault over an irregular cornea to avoid compromising the ocular surface. The ClearKone lens has the ability to center independent of the location of the cone, according to the company. It can be used for

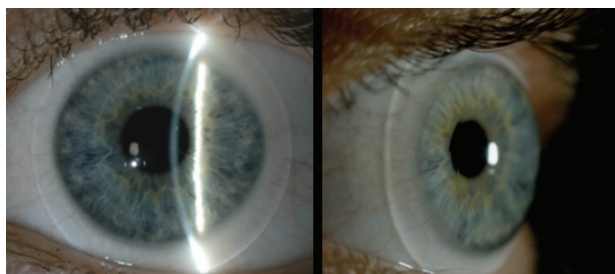


Fig. 4. This patient with ocular surface disease achieved clear and comfortable vision with a hybrid lens.

Photo: Alan M. Berman, OD

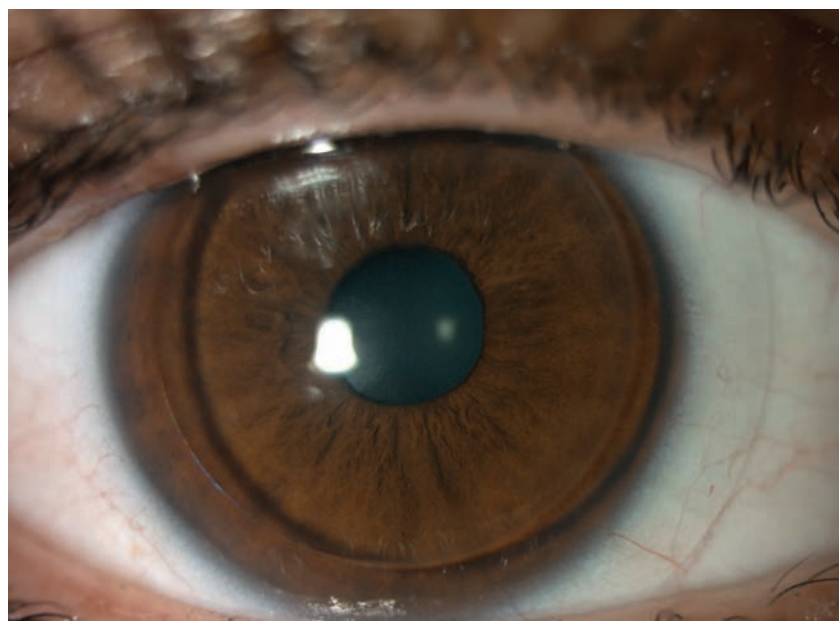


Fig. 3. This patient was fit with a Duette hybrid lens with a silicone hydrogel skirt.

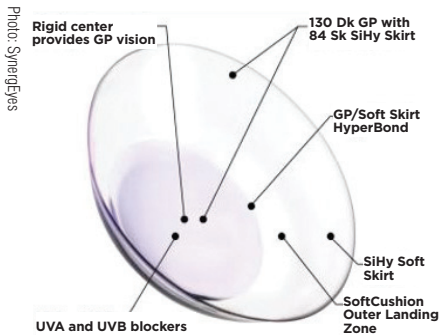


Fig. 5. The Duette hybrid lens provides a GP lens center surrounded by a soft contact lens skirt.

irregular corneas, as well as post-PRK, PRK and LASIK patients.¹⁶

You can fit these lenses empirically or with diagnostic lenses. Empirical fittings require data on keratometry, horizontal visible iris diameter and refraction. The fit should focus on good centration and coverage with movement of one millimeter upon blink in forward gaze. The most important aspect is making sure there is adequate tear exchange to prevent tight lens syndrome. Flattening the skirt curvature can address inadequate movement. The GP base curve is calculated from flat K measurements.

Patients should be educated that they might experience initial, though temporary, discomfort while adapting to a low modulus lens. UltraHealth, UltraHealth FC and ClearKone allow providers to select vault size, and Duette multifocal comes in three different add powers.

Pros: Hybrid contact lenses offer patients clear, comfortable vision while maintaining corneal health. They are good for patients with and without a history of GP lens use and for patients with irregular corneas. They have six-month replacement schedules, and patients must order them through your office because they are not available online or through discount retailers. Thus, they are especially beneficial for

practitioners interested in patient retention and practice building.^{2,14}

Hybrid contact lenses are easier to care for than piggyback systems because only one cleaning solution, usually a hydrogen peroxide solution, is required. Patients should also be educated on using a daily cleaner approved for both soft and GP lenses.

Cons: Patients may have difficulty with lens insertion and removal because many only have a history of soft contact lens use and are not yet comfortable removing a low modulus lens. Practitioners must set aside extra time to instruct these patients. Older generation hybrid lenses (SynergEyes A, KC and ClearKone) have hema skirts, which is a hydrogel monomer and has a low oxygen permeability.⁹ In relation to the piggyback system, hybrid lenses will be more expensive. To help address any complications, SynergyEyes has a patient hotline available 24/7 to answer any questions, as well as an online resource to help practitioners select the initial lens.¹³

Piggyback systems and hybrid contact lenses can offer many patients clear, comfortable vision with few disadvantages.

Practitioners should consider these modalities for a variety of patients, especially now that the technology behind them has improved significantly. Knowing when to implement both of these lenses will differentiate you and add to your specialty lens practice. **RCCL**

1. Potter R. The history of hybrid contact lenses. Contact Lens Spectrum. 2015. www.clspectrum.com/issues/2015/november-2015/the-history-of-hybrid-contact-lenses. Accessed June 10, 2017.

2. Woo SL. Say hi to hybrids!

Review of Cornea and Contact Lenses. September 2014:30-1.

3. Baldone JA. The fitting of hard contact lenses onto soft contact lenses in certain diseased conditions. Contact Lens Med Bull. 1973;6:15-7.

4. Michaud L, Brazeau D, Corbeil M-E, et al. Contribution of soft lenses of various powers to the optics of a piggy-back system on regular corneas. Cont Lens Anterior Eye. 2013;36(6):318-23.

5. López-Aleman A, González-Méjome JM, Almeida JB, et al. Oxygen transmissibility of piggyback systems with conventional soft and silicone hydrogel contact lenses. Cornea. 2006;25(2):214-9.

6. Nichols JJ, Willcox MDP, Bron AJ, et al. The TFOS International Workshop on Contact Lens Discomfort: Executive summary. Invest Ophthalmol Vis Sci. 2013;54(11):TFOS7-TFOS13.

7. The Vision Care Institute of Johnson and Johnson Medical Ltd. Soft contact lens fitting: essential contact lens practice. www.thevisioncareinstitute.ae/library. Accessed July 30, 2017.

8. Gas Permeable Lens Institute. Contact lens clinical pearls pocket guide. www.gpli.info/fitting-guide/. Accessed July 31, 2017.

9. Bennett E, Henry V. Clinical Manual of Contact Lenses. 4th ed. Philadelphia: LWW; 2013.

10. Romero-Jiménez M, Santodomingo-Rubido J, Flores-Rodríguez P, et al. Which soft contact lens power is better for piggyback fitting in keratoconus? Cont Lens Anterior Eye. 2013;36(1):45-8.

11. Steele C. Contact lens fitting today: fitting the irregular cornea. October 21, 2015. www.davidthomas.com/assets/Uploads/pdfs/Contact_lens_fitting_today_for_the_irregular_cornea-Chris_Steele.pdf. Accessed June 15, 2017.

12. Chang CY, DeNaeyer GW. Specialty contact lenses: treat your keratoconus patients right. Review of Cornea and Contact Lenses. March/April 2017:14-7.

13. Sicks LA. Hybrid lens basics. American Optometric Association. 2016. www.aoa.org/Documents/Hybrid_Lens_Basics_Article.pdf. Accessed June 10, 2017.

14. Tyler's Quarterly Soft Contact Lens Parameter Guide. 2016;34(1):60.

15. Sonsino J, Davis R. Keeping hybrids in focus. Contact Lens Spectrum. 2017. www.clspectrum.com/issues/2017/june-2017/keeping-hybrids-in-focus?eid=372303843&bid=1774827. Accessed June 16, 2017.

16. SynergEyes. <http://synergieyes.com/professional/>. Accessed July 26, 2017.

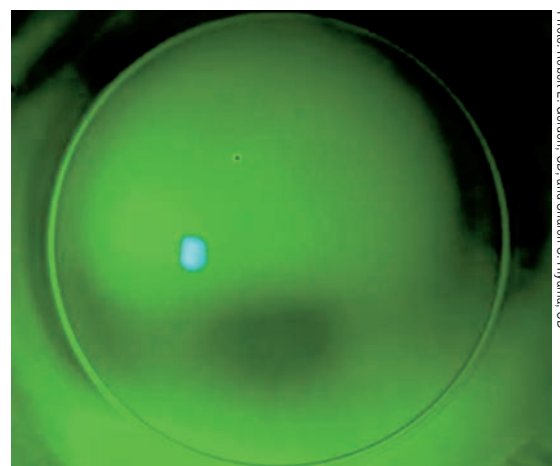


Fig. 6. The right SynergEyes KC lens on this patient demonstrates "feather" touch with intermediate tear pooling.

Photo: Robert L. Gordon, OD and Sharon S. Hiyama, OD

How to Build a *Better* Lens Fitting Experience

Practitioners have many tools available to help make the scleral and GP fitting process more efficient than ever.

BY SHALU PAL, OD

Scleral lenses have opened up a new realm of possibilities to provide patients with improved vision correction and relief for dryness, so it's no surprise practitioner interest is booming.¹ Likewise, interest in gas permeable (GP) lenses is burgeoning, as contact lens experts are looking to expand their repertoires.¹

As a result of the scleral and GP lens explosion, technology has evolved to improve specialty lens fitting. For practitioners looking to get started with scleral and GP lenses, it is especially important to know what options are out there. Here is a review of today's scleral and GP lens fitting technology and how it can make a difference in your practice.

OCT IMAGING

When it comes time to fit and assess lenses, optical coherence topography (OCT) can be a powerful tool. To achieve a proper fit, scleral lenses must vault the entire cornea and limbus region. As such, accurate corneal diameter is imperative to determine the correct size of the lens. Using an OCT, practitioners can see this and the vault of a lens relative to the cornea to help ensure there is no touch and an adequate vault remains after the lens has settled. The limbal clearance zone

can also be evaluated for adequate lift (*Figure 1*).

The desired sagittal height of a scleral lens can also be measured using anterior segment OCT. For a 15mm diameter scleral lens, the desired sagittal height is calculated by measuring the sagittal height of the cornea at the 10mm chord and adding 2,350 μ m (2,000 μ m for the average height of cornea from the 10mm to 15mm chord and 350 μ m of desired tear film vault above the cornea) (*Figure 2*).² For each 1mm increase in size of the scleral lens, practitioners should add 150 μ m.²

Another important OCT imaging capability is assessment of the edge profile of a scleral lens. A flat edge that creates lift or a steep edge that digs into the sclera can cause many problems for the wearer. A flat lens edge can create discomfort, lid awareness, fogging and debris build up under the lens, while a steep edge can cause compression, blanching of vessels, redness and discomfort. With quadrant-specific designs, practitioners can evaluate the lens edge design and make changes with toric peripheral curves as needed (*Figure 3*).

CORNEAL TOPOGRAPHERS

While OCT imaging is an effective tool in its own right, corneal topographers also have some tricks up their sleeves. For one, many corneal

topographers have a built-in contact lens module that allows practitioners to design GP lenses or scleral lenses, thus reducing chair time with fitting sets.

The sMap3D (Visionary Optics) is one corneal topographer that stitches together a series of three images—up gaze, straight gaze and down gaze—to create a scleral elevation map and provide a complete picture of the cornea and sclera. It is designed with two cameras and one light source to give three independent triangulations over a 22mm field of view, including the superior sclera and inferior sclera. It is also the only topographer that provides a 360° view of the scleral shape.²

Before imaging with the sMap3D, practitioners should instill fluorescein into the patient's eye and lift the top lid while the patient pulls down the lower lid. This will provide the widest view of the

ABOUT THE AUTHOR



Dr. Pal runs a specialty contact lens and dry eye practice in Toronto. She is the vice chair of the AOA Contact Lens and Cornea Section Council, a member of the Women's Advisory Board for Alcon and a speaker for Allergan's dry eye faculty in Canada. She is a consultant for Allergan, Alcon, Bausch + Lomb, CooperVision, Johnson & Johnson Vision Care and Menicon, as well as a facilitator of the STAPLE lens fitting workshops.

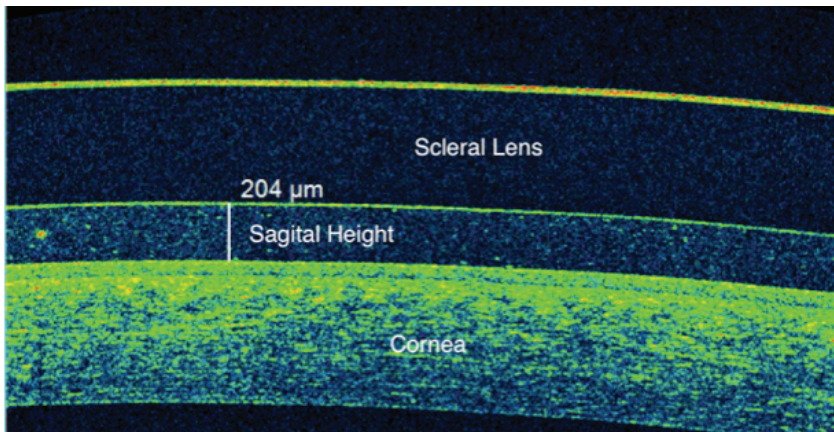


Fig. 1. Corneal vault and limbal clearance can help practitioners ensure that the lens isn't touching the cornea and an adequate end of vault remains after the lens has settled.

cornea, sclera and limbus without any obstruction.²

After topographic evaluation, the practitioner can place a diagnostic lens on the eye to get an accurate over-refraction. Practitioners send this information, along with the maps, to the company to have it custom design a lens for that eye. The practitioner also has the option to change any parameter to alter the design of the lens and see how it will fit on the eye. The sMap3D's accompanying software is designed to allow for virtual fitting to demonstrate how the custom-designed lens fits on the stitched 3D maps of the cornea and sclera. Practitioners can also see a sodium fluorescein pattern simulation, and any parameter can be adjusted to provide the best fit prior to ordering.

In the past, scleral toricity has been difficult to measure when fitting lenses. With the sMap3D topographer, however, practitioners can figure out the requirements for toric peripheral curves, as well as how to reduce the amount of toricity, edge design complications and flexure stemming from a spherical lens put on a toric sclera.

The sMap3D's current limitation is that it cannot be used with all scleral lens designs. At the moment,

it is designed for the Europa and the Elara scleral lens designs (Visionary Optics). The company plans to add other designs by the end of the year, however.

Using profilometry technology—a non-contact 3D shape measuring technique—the Eye Surface Profiler (Eaglet-Eye) projects a fringe pattern onto a diffuse target surface and the resulting deformed fringe pattern is captured by a digital camera to be processed into an image. Prior to image capture, two light sources project moiré patterns onto fluorescein in the patient's eye. Through this process, the Eye Surface Profiler measures more than 350,000 data points over a 20mm diameter of the eye, providing 3D anterior segment height maps of the surface.³ One of its key features is eye asymmetry imaging, allowing practitioners to accurately fit both scleral and GP lenses.

Based on the 3D map of the eye and the back-surface designs of particular lenses, the software al-

gorithms will suggest five custom-fit sizes of contact lenses. This reduces chairtime and increases patient comfort.

In the past, scleral toricity has been difficult to measure when fitting lenses. With scleral topographers, however, practitioners can figure out the requirements for toric peripheral curves, the amount of toricity, edge design complications and flexure stemming from a spherical lens.

SOFTWARE FOR COMPUTER-DESIGNED LENSES

Practitioners who prefer to use their own topographers still have options to create detailed scleral and GP lens designs. Here are some software programs currently on the market:

EyeSpace and Scleral EyeSpace (Innovatus Technology) are desktop software platforms created to help practitioners design scleral and GP lenses with their own topographers and fitting sets. The company's goal is to improve the success rate of the first lens ordered through education about lens parameters and how changing them impacts the fitting relationship of many GP lens designs.

Both programs are compatible with the E300 (Medmont) and Keratograph (Oculus) topographers, and others can be adapted for compatibility upon request. To choose an initial trial lens, practitioners can import data from their topographers into the




Fig. 2. The desired sagittal height of a scleral lens can be measured using an OCT, shown here, or a corneal topographer.

SCLERALS & GPs: HOW TO BUILD A BETTER LENS FITTING EXPERIENCE

software, which then guides them through the process. Once all the data has been entered and the software has made its calculations, there is an override option if the presented calculations are not ideal. EyeSpace and Scleral EyeSpace also give practitioners the ability to simulate the created lens on the eye. When practitioners are satisfied, they can order the final lens directly through the software.

Wave and OrthoTool are third-party software programs that provide a GP and scleral lens construction module similar to that of EyeSpace and Scleral EyeSpace. Practitioners can import data from topographers to design custom lenses for their patients.

CORNEAL-SCLERAL PROSTHETIC MOLDS

For practitioners who prefer to forego imaging, corneal-scleral prosthetic molds can provide a precise fitting experience.

The *EyePrintPro* (Eyeprint Prosthetics) is a scleral lens shell made from an impression mold of the eye. The impression process

allows practitioners to capture the precise curvatures of the ocular surface within one to two microns of accuracy.⁴ The EyePrintPro is customizable in areas such as spherical and toric optics, unlimited add powers, prism in any direction to reduce diplopia, decentered optics, and rotationally stable optics.⁴

The EyePrintPro is designed to allow practitioners to make lenses into front or back surface multifocal designs with exact visual axis specification to provide ideal multifocal vision for irregular corneas. To adjust for nighttime reduced distance vision associated with enlarged pupils, practitioners can place a peripheral distance correction on the front surface.⁴

In 1994, the *BostonSight Prose* (Boston Foundation of Sight) received FDA approval for corneal disorder treatment.⁵ The lens has a diameter ranging from 15mm to 23mm, a 12mm central optic zone and a 2mm wide transitional zone that vaults the limbus. Its haptic zone has channels that allow for tear exchange at the scleral interface.⁵

When fitting the BostonSight Prose, practitioners use computer software to create a front and back surface design of second-order continuity.

In 2017, the Boston Foundation of Sight launched a new lens fitting system, the *BostonSight*

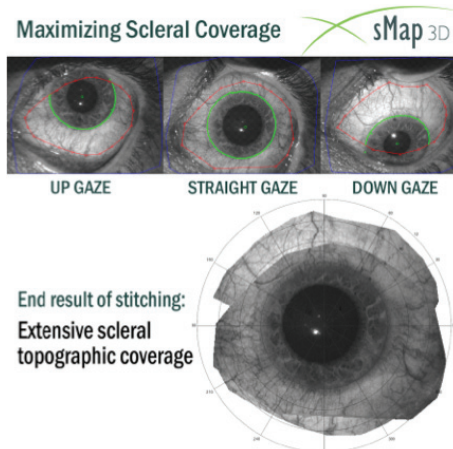


Fig. 4. The sMap3D stitches together up gaze, straight gaze and down gaze images to create a scleral elevation map.

Scleral. This 22-lens system was designed based on six years of clinical and scleral anatomy data from approximately 7,000 eyes.⁶ It is the first scleral lens to provide right and left specific eye designs, as well as the first to have a front surface eccentricity option to improve vision to a higher order.⁶ Other options for this lens system include quadrant-specific toric peripheral curves, front surface toric optics and three different diameters: 18mm, 18.5mm and 19mm. A web-based fitting and online ordering system are also available.⁶

GP LENS COATING

After going through the process of designing and fitting the best lens for a patient, the last thing a practitioner wants to deal with is material that wets poorly, deposits quickly or creates irritation. However, appropriate materials, coatings and solutions should always be a focus of the custom lens process for a successful fit.

For years, discomfort has been the number one reason for contact lens discontinuation.⁷ However, preventing discomfort recently got easier. Hydra-PEG (Tangible Science), a polyethylene glycol-based polymer

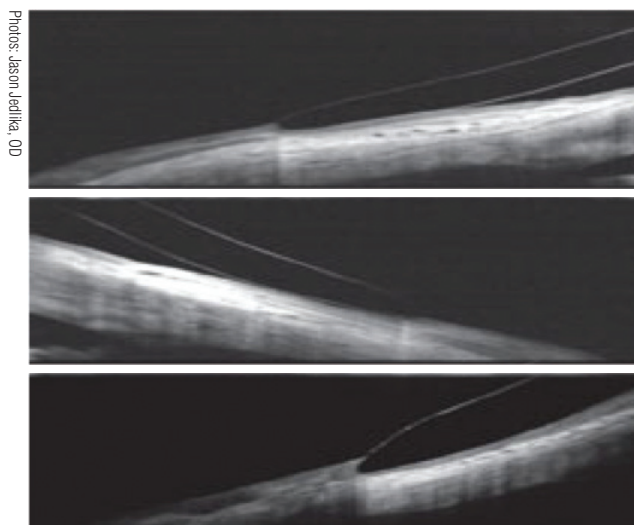


Fig. 3. Here are some OCT image examples. At top, good edge alignment. In the middle, a flat edge lifting off of the conjunctiva. At bottom, a steep edge digging into the conjunctiva.

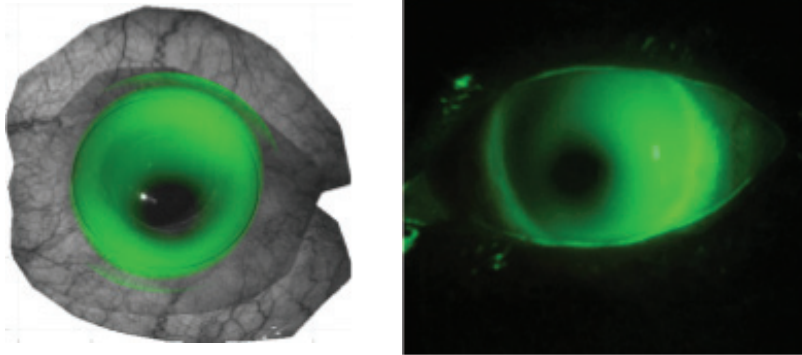


Fig. 5. At right, an actual fluorescein pattern through the slit lamp compared to a simulated image from the sMapPro software, at left.

mixture coating that can be applied to hydrogel, silicone hydrogel, GP and hybrid lenses, has effectively improved wettability, lens surface water retention, lubricity, tear break-up time, patient comfort and overall wear time while minimizing friction, protein and lipid deposition, lens fogging and lens irritation.^{6,8}

Hydra-PEG is compatible with most multipurpose and peroxide-based cleaning solutions, but water and alcohol-based cleaners should be avoided. Because it bonds permanently to the contact lens surface, Hydra-PEG is a permanent coating. It will become thinner with cleaning, but the base layer will remain intact even after a year of cleaning.⁶ It may be a beneficial option for patients who have had trouble maintaining comfort and lens wettability, or those who simply want less irritation from dryness and deposits.

WAVEFRONT-GUIDED SCLERALS

Custom wavefront technology is often used with refractive surgeries, glasses and contact lenses. It was recently the subject of a study that evaluated the level of higher-order aberration (HOA) correction that is possible with wavefront-guided scleral lenses in keratoconic patients.⁹ The study concluded that wavefront-guided scleral lenses

are capable of compensating for the harmful effects of HOA and can provide visual image quality equivalent to that of normal eyes.⁹ The ability to produce these lenses and how they will compare with non-ectatic eyes still need to be investigated, however.⁹

For almost a decade, Greg Gemoules, OD, creator of the LaserFit Scleral Lens System, has been developing his own software to create customized wavefront-guided scleral lenses that eliminate HOAs.¹⁰ His LaserFit system uses anterior segment OCT images from the Visante (Zeiss) and wavefront data from the iTrace (Tracey Technologies) aberrometer to design lenses. The lens design is then sent to the Truform Optics Lab, where fabrication takes place. This technology aims to reduce or eliminate HOA issues, including ghosting, smearing of images, halos, glare and both monocular and binocular diplopia.

Custom lens fitting technologies have dramatically changed over the last decade. Now, with the right technology, practitioners can ensure their patients experience faster fits, less chair time and better visual outcomes. **RCCL**

1. Bennett ES. GP annual report 2016. Contact Lens Spectrum. October 1, 2016. www.clspectrum.com/issues/2016/october-2016/gp-annual-re-

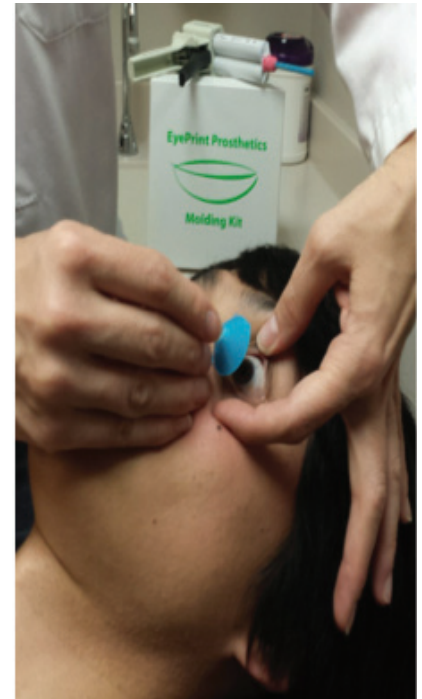

Fig. 6. Here is a look at the EyePrintPro's impression mold system in action.

port-2016-1. Accessed July 20, 2017.

2. Jedlicka J. Critical measurement to improve scleral lens fitting. Review of Optometry. Sept 2015. www.reviewofoptometry.com/ce/critical-ocular-measurements-to-improve. Accessed July 20, 2017.

3. Caroline PJ, Andre MP. Contact lens case reports: understanding corneal and scleral shape. Contact Lens Spectrum. Jan 1, 2015. www.clspectrum.com/issues/2015/january-2015/contact-lens-case-reports. Accessed July 20, 2017.

4. Barnett M. Multifocal Scleral Lenses. Contact Lens Spectrum. Dec 1, 2015. www.acculens.com/pdf/article-multifocal-sclerals.pdf. Accessed July 20, 2017.

5. Carrasquillo K, Barnett M. Scleral Lens Applications in Unique. Contact Lens Spectrum. February 1, 2014. www.acculens.com/pdf/article-scleral-lens-applications-in-unique-populations.pdf. Accessed July 20, 2017.

6. BostonSight® Introduces Innovative Scleral Lens Fitting System. Boston Foundation for Sight. January 25, 2017. static.ow.ly/docs/PressRelease-%20Intro-BostonSightSCLERAL_final_5P1m.pdf. Accessed August 18, 2017.

7. Rumpakis J. New data on contact lens dropouts: an international perspective. Review of Optometry. January 15, 2010. www.reviewofoptometry.com/article/new-data-on-contact-lens-dropouts-an-international-perspective. Accessed July 20, 2017.

8. Sindt CW. The great silicone cover up. Review of Cornea and Contact Lens. April 15, 2015. www.reviewofcontactlenses.com/content/d/technology/c/53979/. Accessed July 20, 2017.

9. Marsack JD, Ravikumar A, Nguyen C, et al. Wavefront-guided scleral lens correction in keratoconus. Optom Vis Sci. 2014 Oct;91(10):1221-30.

10. Gilhawley C. Custom made scleral lenses attract clients from around the world. Invision. March 31, 2016. invisionmag.com/best-of-the-best/1773-best-of-the-best-fit-for-success.html. Accessed July 20, 2017.

EXPAND YOUR HORIZONS: **Think GPs for Presbyopes**

Thanks to technological advances, multifocal gas permeable lenses are no longer a last resort for practitioners.

By Thuy-Lan Nguyen, OD, Zoanne Schinas, OD, and Perla Najman, OD

As researchers estimate 22% of our population will be older than 60 by 2050, it's no surprise our patient population is demanding an ever increasing array of vision correction options.¹ Generation X is beginning to struggle with presbyopia, and baby boomers continue to stay in the work force, calling for innovative solutions.¹ And although the percentage of presbyopic patients is increasing, presbyopic contact lens fits have struggled to keep up.¹ This may be due to a lack of technical knowledge among practitioners, the perception that fitting presbyopes with multifocal contact lenses (MFCLs) takes up too much chair time or concern that MFCLs do not work.

However, recent advances in multifocal gas permeable (GP) lens technology are working to turn this around. This article reviews multifocal GP lens designs, including new hybrid and scleral multifocal options, and how to best incorporate them in everyday optometric practice.

WHY MULTIFOCAL GP LENSES?

While GP contact lenses only represent approximately 11% of all contact lenses prescribed worldwide and only 9.4% of fittings in the United States, they still offer

many advantages over soft contact lenses.² GP lenses typically provide excellent vision and can be customized for a patient's individual visual needs, such as modifying add powers and correcting astigmatism, therefore making them a possible lens of choice for astigmatic patients, critical observers, patients requiring good range of vision or depth perception, dry eye patients and those at risk for giant papillary conjunctivitis.

ASPHERIC DESIGNS

The majority of multifocal GP lenses are simultaneous vision designs, meaning all vision zones (distance, intermediate and near) are within the pupil at the same time. These lenses are available in concentric or aspheric designs. Most multifocal GP lenses are aspheric designs, which have a gradual change in curvature and become flatter towards the periphery to create more plus power. Centration with limited lens movement on blink is critical for proper vision with these lenses, so multifocal GPs typically have larger overall diameters compared with single vision GPs. To provide best possible near vision, aspheric lenses should translate some in down gaze. This allows a greater amount of near plus to enter the pupil zone during near tasks.

Aspheric lens designs can be categorized as front aspheric, back

aspheric or bi-aspheric. Front aspheric designs have the power change on the front surface while the back surface is spherical. This reduces spherical aberration and minimizes distortion during lens translation on down gaze. In back aspheric designs, the posterior eccentricity provides a power gradient without inducing corneal warpage. This is an ideal design for astigmatic presbyopes where the toricity is mostly corneal. Bi-aspheric designs allow for more

ABOUT THE AUTHORS



Dr. Nguyen is an assistant professor at Nova Southeastern University College of Optometry. She lectures, publishes and participates in research on specialty contact lenses. She also recently volunteered her time in the Dominican Republic and Nicaragua to provide eye exams and glasses to those in need.



Dr. Schinas is an assistant professor at Nova Southeastern University College of Optometry, where she teaches several contact lens courses and serves as lab coordinator. She is active in contact lens-related research and has authored abstracts on ocular disease and its management.

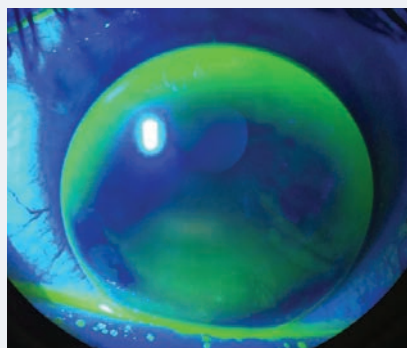


Dr. Najman is an assistant professor at Nova Southeastern University College of Optometry, where she has twice earned the "Contact Lens Preceptor of the Year" award. She has published work on ocular disease and contact lenses. Her current research focuses are specialty contact lenses and primary care optometry.

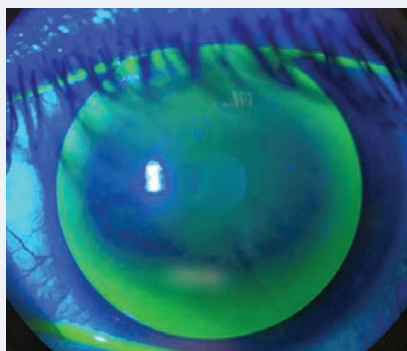
customized control of fit and optics by allowing for precise fit on the back surface and visual correction on the front surface. The ability to correct for both corneal and internal astigmatism can reduce glare and halos, especially in dim lighting, such as night driving.²

The ideal candidates for aspheric multifocal GP lenses are current GP wearers just entering presbyopia or advanced presbyopes who have significant intermediate vision demands. Patients who spend significant amounts of time using computers placed at arm's length and eye level may also be successful with aspheric multifocal GPs.

The problems associated with aspheric multifocal GPs typically



An inferiorly decentered multifocal GP with excessive movement will cause blurred, fluctuating vision and discomfort.



To improve fit and vision for a multifocal GP lens that is decentered with excessive movement, steepen the base curve and increase the overall diameter.

involve four factors: decentration, excessive movement, insufficient add power and glare. Decentration and excessive movement usually occur at the same time, so solving one typically resolves the other as well. If a lens is decentered inferiorly with excessive movement, it is likely too flat. This will cause blurred and fluctuating vision as well as discomfort. In these cases, steepening the base curve will often improve both fit and vision. Similarly, if a lens is riding high or tucked under the upper eyelid excessively, steepening the base curve by 0.50D should help. This will also prevent corneal distortion. Decentration can also be avoided by increasing the overall diameter, and a larger diameter is recommended for any horizontal (nasal or temporal) decentration.

Inadequate add powers will result in decreased near vision. Newer aspheric designs provide higher adds by increasing plus in the concentric zone on the front surface of the lens.³ Unlike silicone hydrogel soft multifocal lens designs, a slight increase in the near add power of a multifocal GP lens won't necessarily affect distance vision. For example, if a patient's spectacle add power is +1.75, a +2.00 add or higher is recom-

mended for their multifocal GPs.

Glare, especially in dim illumination, is a common subjective complaint from patients wearing aspheric designs. Glare typically occurs because the intermediate and near zones are in the pupillary axis during straight ahead distance gaze. Fixing centration is one way to reduce glare and improve overall vision and discomfort. If the lens is well centered and the patient still experiences excessive glare, consider increasing the optic zone diameter. Another potential cause of glare is lens material dryness. Problems with non-wetting can be one of the most frustrating parts of any contact lens practice, and it can also lead to lens deposits and discomfort. Many GP designs are available in high or hyper Dk materials, but the higher oxygen often compromises the wetting angle, so changing to a slightly lower Dk material may improve symptoms of dryness and glare.

One new way to combat dryness and front surface deposits is with Hydra-PEG treatment by Tangible Science. Hydra-PEG, which can be applied to many GP materials and hybrid lenses, is a polyethylene glycol polymer that is covalently bonded to the

Release Date: September 15, 2017

Expiration Date: September 15, 2020

Goal Statement: Presbyopic contact lens fits are struggling to keep up with patient needs, but new multifocal GP lens technology may be able to reverse this. This lesson reviews multifocal GP lens designs, new technology, and how to incorporate these lenses in everyday practice.

Faculty/Editorial Board: Thuy-Lan Nguyen, OD, Zoëanne Schinas, OD, and Perla Najman, OD.

Credit Statement: This course is COPE approved for 1 hour of continuing education credit. Course ID is 54550-CL. Check with your state licensing board to see if this counts toward your CE requirements for relicensure.

Joint-Sponsorship Statement: This continuing education course is joint-sponsored by the Pennsylvania College of Optometry.

Disclosure Statement:

Authors: Dr. Nguyen has a financial relationship with Paragon and the Vision Service Plan.

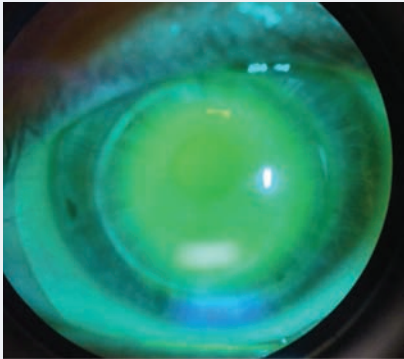
Dr. Schinas has a financial relationship with the Staple Program and Alcon.

Dr. Najman has a financial relationship with the Staple Program

Editorial staff: Jack Persico, Rebecca Hepp, William Kekevan, Michael Riviello and Michael Iannucci all have no relationships to disclose.



EXPAND YOUR HORIZONS: THINK GPs FOR PRESBYOPES



Here, a 49-year-old patient is wearing Synergeyes Duette Progressive lenses. The fluorescein pattern of the gas permeable center shows proper fit with minimal apical clearance throughout while the soft outer skirt provides stability.

contact lens surface, creating a permanent wetting surface on the lens.⁴ Before dispensing lenses with Hydra-PEG treatment, you should advise patients on proper cleaning and disinfection techniques. This includes avoiding any alcohol-based or abrasive cleaners, as they can damage the surface of lens. Instead, try recommending peroxide-based solutions.

TRANSLATING DESIGNS

Although they are less popular than aspheric designs, translating or segmented multifocal GP lenses are another potentially beneficial option. They rely on proper lower lid interaction with the lens and an upward movement of the lens during down gaze. This allows the patient to see through a different segment other than straight ahead gaze. Translating lenses are typically prism ballasted and can be truncated for additional stability. When fit properly with stable translation, they can offer exceptional distance and near vision. Intermediate vision is a known problem in these lenses, however, so they may not be adequate for computer users who often look straight ahead.³

Problems with translating designs typically revolve around excessive rotation or poor translation. If a lens aligns properly but rotates excessively, it can result in fluctuating distance vision and inadequate near vision. This can be resolved by increasing the amount of prism ballast. Likewise, if a lens is not translating properly, patients will not achieve adequate near vision. To fix this, try flattening the base curve or increasing the amount of prism. Translation can be confirmed by having the patient look down during the slit lamp examination. During down gaze, the lens should shift superiorly so that the near segment rests in the pupillary zone.³ Translation relies on proper lower lid interaction, so patients with loose lower lid tension or lower lids that are positioned far below the lower corneal limbus should not be fit with translating designs.

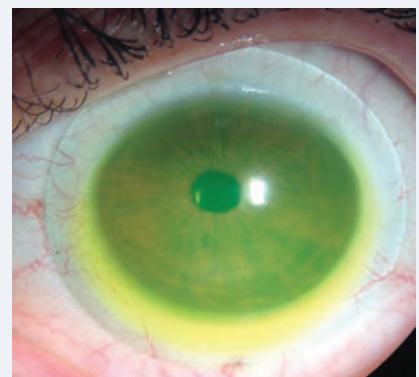HYBRID GP LENSES

For patients who have difficulty adapting to the initial lens awareness of multifocal GP lenses, hybrid and scleral GPs are now available in multifocal designs. Newer hybrid lenses are composed of a high Dk GP center surrounded by a silicone hydrogel soft skirt. In theory, the GP center offers clear vision, while the soft skirt provides good comfort, centration and stability.⁵ Some of these designs can be ordered empirically with keratometry readings and a spectacle prescription. A key point to remember here is that the GP portion of the lens can correct for corneal astigmatism, so when ordering empirically, start with a distance power that is the spherical component of the spectacle prescription rather than the spherical equivalent. Patients should be properly educated on insertion

and removal techniques before dispensing. If the soft portion folds in during insertion, it can cause discomfort. Also, if the patient has problems with dexterity, removing the lens can be a challenge.

SCLERALS

The newest category of multifocal GP lenses is multifocal scleral lenses. This broadens the scope of treatment for irregular cornea patients, such as those diagnosed with keratoconus, pellucid marginal degeneration, Salzmann's nodular degeneration, post-refractive surgery complications, post-penetrating keratoplasty and severe ocular surface disease. Scleral lenses can also provide visual correction for regular corneas with high refractive error or astigmatism. By vaulting the cornea completely and resting on the scleral tissue, these lenses can also offer better initial comfort.⁶ The continuous tear layer between the lens and the cornea creates an aqueous reservoir that can protect the cornea.⁷ Thus, scleral lenses are a good therapeutic option for managing ocular surface disease. Patients should be taught proper handling techniques using insertion and removal devices as well as non-preservative saline to fill the lens before inserting.



A 47-year-old patient wearing an Elara P (Visionary Optics) scleral multifocal GP lens.

OTHER CONSIDERATIONS

With so many multifocal GP lenses available, initial lens selection can be challenging, even for expert contact lens fitters. Because every patient is different, no one multifocal GP will work for everyone.

Of course, before choosing a design, a proper refraction, careful slit lamp examination and accurate keratometry reading are necessary. Corneal topography and anterior segment optical coherence tomography are also helpful. However, when it comes to multifocal lenses, patient selection, as well as education before and after fitting, may have a larger impact on patient success.

Practitioners should interview patients about their visual goals, as well as their daily activities. Knowing the specific task a patient wants to be able to do with their contact lenses will better focus and customize their fitting.⁸ Once the patient's lifestyle is established, set realistic expectations of vision and wear time. Some patients may have their own preconceived notion of what multifocal GP lenses can do for them, so it is up to practitioners to educate them on the benefits and challenges. Inform patients of the adaptation time required for multifocal GP lenses in advance. It may take a new wearer a few weeks to fully adapt to the initial lens awareness of corneal multifocal GP lenses and the handling of hybrid or scleral multifocal lenses. Success in any of these areas often requires a high level of commitment from both the practitioner and the patient.

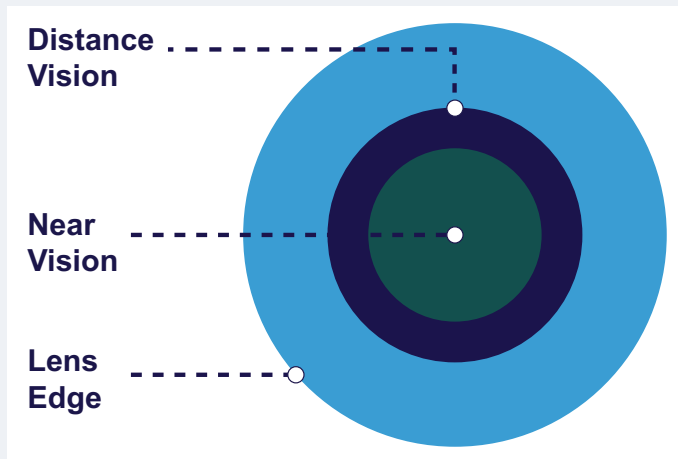
Glasses can be worn over multifocal GPs as needed to enhance vision—something that is extremely helpful in certain lighting and during long hours spent on certain tasks. For example, multifocal GPs can provide excellent overall visual

results for daily tasks, but when a patient goes to a dimly lit restaurant for dinner, they may need a low plus spectacle prescription to read the menu. Similarly, a patient may ex-

perience excellent daytime driving with their multifocal GPs but requires a low spectacle prescription with non-glare lenses for long distance or nighttime driving. In addition, a patient who spends eight to nine hours a day on the computer can achieve comfortable vision with multifocal GPs, but if they need to do any additional computer work at home after hours, they may require a spectacle prescription to enhance near vision when experiencing visual fatigue.

Ocular dominance should be measured for every presbyopic patient interested in contact lenses. While this is necessary for monovision patients, it is also extremely helpful for multifocal patients. A modified monovision prescription with multifocal lenses may be needed to provide adequate vision at all ranges. Simply overplussing the non-dominant eye by 0.50D can have a dramatic effect on binocular near vision without necessarily decreasing distance vision or depth perception.

Prescribing contact lenses for presbyopic patients is a continuing challenge for any optometric practice. While current trends are skewed towards daily disposable and silicone hydrogel lenses,



Visionary Optics Elara P scleral multifocal is a concentric bifocal design with a near center.

multifocal GP technology also continues to improve.⁹ Newer multifocal GP designs with more customizable features can prevent problems before they even occur. The explosion of scleral lenses has revolutionized the management of regular and irregular corneas, and with these advances, multifocal GP lenses can once again be the lens of choice for practitioners instead of the last resort. **INCL**

1. Moran PB, Efron N, Woods CA. An international survey of contact lens prescribing for presbyopia. *Clin Exp Optom*. 2011;94:87Y92.
2. Ortiz-Toquero S, Martin M, Rodriguez G, et al. Success of rigid gas permeable contact lens fitting. *Eye Cont Lens*. 2016;0:1-6.
3. Bennett E, Hom M, eds. *Manual of Gas Permeable Contact Lenses*. 2nd ed. Philadelphia: Elsevier Saunders; 2004.
4. Sindt CW. Tangible™ Hydra-PEG: A novel custom contact lens coating technology designed to improve patient comfort and satisfaction. 2016. http://docs.wixstatic.com/ugd/dd2daf_6d-730c1482f6450396c734d74c3017b6.pdf. Accessed June 16, 2017.
5. Piñero DP, Carracedo G, Ruiz-Fortes P, Pérez-Cambrodí RJ. Comparative analysis of the visual performance and aberrometric outcomes with a new hybrid and two silicone hydrogel multifocal contact lenses: a pilot study. *Clin Exp Optom*. 2015 Sep;98(5):451-8.
6. Kauffman MJ, Gilmartin CA, Bennett ES, Bassi CJ. A comparison of the short-term settling of three scleral lens designs. *Optom and Vis Sci*. 2014;91(12):1462-6.
7. Segal O, Barkana Y, Horovitz D, et al. Scleral contact lenses may help where other modalities fail. *Cornea*. 2003;22(4):308-10.
8. Perez-Prados R, Pinero D, Perez-Cambrodí R, Madrid-Costa D. Soft multifocal simultaneous image contact lenses: a review. *Clinical and Experimental Optometry*. 2017;100:107-27.
9. Efron N, Nichols J, Woods C, Morgan P. Trends in US contact lens prescribing 2002 to 2014. *Optometry and Vision Science*. 2015 Jul;92(7):758-67.



EXPAND YOUR HORIZONS: THINK GPs FOR PRESBYOPES

CE TEST ~ SEPTEMBER 2017

- What type of lens design results in a gradual change in curvature, becoming flatter towards the periphery?
 - Spherical.
 - Aspheric.
 - Concentric.
 - None of the above.
- Multifocal GP lenses can be beneficial for which patients?
 - Astigmatic patients.
 - Dry eye patients.
 - Patients at risk for giant papillary conjunctivitis.
 - All of the above.
- Which is a potential benefit of bi-aspheric designs?
 - Spherical aberration reduction.
 - Glare and halo reduction.
 - Customized control of fit and optics.
 - Both b and c.
- Which of the following types of lenses need prism ballasting for stability?
 - Spherical.
 - Aspheric.
 - Bi-aspheric.
 - Translating.
- Which of the following is a problem associated with aspheric multifocal GP lenses?
 - Glare.
 - Decentration.
 - Excessive movement.
 - All of the above.
- What can cause glare with multifocal GP lenses?
 - Decentered lens.
 - Excessively steep fit.
 - Excessive movement of lens.
 - Visual fatigue.
- Which of the following may improve near vision in a patient with a translating multifocal GP?
 - Steeper base curve.
 - Increase prism ballasting.
 - Decrease prism ballasting.
 - None of the above.
- In hybrid multifocal GP lenses, what is beneficial about the silicone hydrogel soft skirt?
 - Centration.
 - Glare reduction.
 - Improved optics.
 - Cosmetic tint.
- Which of these patients may do well with a scleral GP lens?
 - A patient with keratoconus.
 - A patient with pellucid marginal degeneration.
 - A patient with Salzmann's nodular degeneration.
 - All of the above.
- What should practitioners discuss with patients before considering prescribing multifocal GP lenses?
 - Individual visual needs and expectations.
 - Adaptation and wearing time.
 - Potential need for glasses over contact lenses as needed.
 - All of the above.

EXAMINATION ANSWER SHEET

Expand Your Horizons: Think GPs for Presbyopes

Valid for credit through September 15, 2020

Online: This exam can also be taken online at www.reviewofoptometry.com/ce. Upon passing the exam, you can view your results immediately. You can also view your test history at any time from the website.

Directions: Select one answer for each question in the exam and completely darken the appropriate circle. A minimum score of 70% is required to earn credit.

Mail to: Jobson Medical Information, Dept.: Optometric CE, 440 9th Avenue, 14th Floor, New York, NY 10001.

Payment: Remit \$20 with this exam. Make check payable to Jobson Medical Information LLC.

Credit: This lesson is approved for 1 hour of CE credit. Course ID is 54550-CL.

Sponsorship: Joint-sponsored by the Pennsylvania College of Optometry

Processing: There is an eight- to 10-week processing time for this exam.

Answers to CE exam:

- | | | |
|--------------------|--------------------|---------------------|
| 1. (A) (B) (C) (D) | 4. (A) (B) (C) (D) | 8. (A) (B) (C) (D) |
| 2. (A) (B) (C) (D) | 5. (A) (B) (C) (D) | 9. (A) (B) (C) (D) |
| 3. (A) (B) (C) (D) | 6. (A) (B) (C) (D) | 10. (A) (B) (C) (D) |
| | 7. (A) (B) (C) (D) | |

Post-activity evaluation questions:

Rate how well the activity supported your achievement of these learning objectives:

1=Poor, 2=Fair, 3=Neutral, 4=Good, 5=Excellent

- | | |
|--|---------------------|
| 11. Better understand the different designs and clinical impact of multifocal GP lenses. | (1) (2) (3) (4) (5) |
| 12. Better identify which multifocal GP lenses can be beneficial for which patients. | (1) (2) (3) (4) (5) |
| 13. Improved my ability to set expectations with patients before fitting for multifocal GP lenses. | (1) (2) (3) (4) (5) |
| 14. Increase skill in fitting and managing multifocal GP lenses in presbyopic patients. | (1) (2) (3) (4) (5) |
| 15. Increase my knowledge of multifocal GP lenses and their effect on presbyopic patients. | (1) (2) (3) (4) (5) |
| 16. Improve my knowledge of potential problems associated with each multifocal GP lens design. | (1) (2) (3) (4) (5) |

Rate the quality of the material provided:

1=Strongly disagree, 2=Somewhat disagree, 3=Neutral, 4=Somewhat agree, 5=Strongly agree

- | | |
|--|---------------------|
| 17. The content was evidence-based. | (1) (2) (3) (4) (5) |
| 18. The content was balanced and free of bias. | (1) (2) (3) (4) (5) |
| 19. The presentation was clear and effective. | (1) (2) (3) (4) (5) |
| 20. Additional comments on this course: | _____ |

Identifying information (please print clearly):

First Name _____

Last Name _____

Email _____

The following is your: Home Address Business Address

Business Name _____

Address _____

City _____ State _____

ZIP _____

Telephone # _____ - _____ - _____

Fax # _____ - _____ - _____

By submitting this answer sheet, I certify that I have read the lesson in its entirety and completed the self-assessment exam personally based on the material presented. I have not obtained the answers to this exam by fraudulent or improper means.

Signature: _____ Date: _____

Please retain a copy for your records.

LESSON 114831, RO-RCCL-0917

2017

EAST COAST Optometric Glaucoma Symposium

Up to
12 CE
Credits*

OCTOBER 6-7, 2017

Join our faculty of renowned ODs and MDs for a highly interactive meeting covering the most up-to-date information in glaucoma care. Up to 12 CE credits for only \$275.

GRAND HYATT WASHINGTON

1000 H Street NW
Washington, DC 20001

Discounted room rate: \$229/night + tax. Please call the hotel directly at 202-582-1234 and mention "ECOGS" for group rate.

MEETING CO-CHAIRS:



Murray Fingeret, OD



Robert Weinreb, MD

SPEAKERS: David Greenfield, MD
Jeffrey Liebmann, MD
Michael Chaglasian, OD

THREE WAYS TO REGISTER

www.reviewofoptometry.com/ECOGS2017

Email: ReviewMeetings@Jobson.com

Call Lois DiDomenico: 877-451-6514

A CLOSER LOOK at CORNEAL INLAYS

By Justin Schweitzer, OD

This new option for dealing with presbyopia shows promise. Here's what you should know when considering a corneal approach.

A 50-year-old Caucasian female presents to the clinic reporting that she is tired of her reading glasses. She has perfect ocular health, no distance vision complaints and a distance manifest refraction of -0.5D in both eyes. She wants to know what her options are to reduce her dependence on reading glasses. This scenario is not unusual, and with the recent increased interest in reducing reading spectacle dependence, it will become even more common.

Traditional surgical approaches of monovision with laser-assisted *in situ* keratomileusis (LASIK), photorefractive keratectomy (PRK) or intraocular lenses (IOLs) following a refractive lens exchange are reasonable options. Contact lenses are less of a commitment than surgery but have downsides of their own. With presbyopia affecting an estimated 1.04 billion people worldwide, options continue to emerge and introduce new advantages.¹

Among the newer additions for presbyopic correction are corneal inlays, which feature their own unique array of benefits and limitations. This article focuses on corneal inlays in the marketplace and how they are making a difference in the lives of presbyopic patients.

INLAYS TODAY

Corneal inlays have a variety of mechanisms of action, including index of refraction change, corneal

curvature change and small-aperture optics.² They are most often placed in the nondominant eye, but—unlike in monovision—a significant decrease in distance visual acuity does not occur in that eye. This allows for continual good binocular vision, which means little to no decrease in stereoacuity.^{3,4} Other benefits of corneal inlays include removal and repositioning abilities, and since the procedure is limited to the cornea, risks associated with intraocular procedures are not a concern.

Corneal inlay implantation is achieved with the assistance of a femtosecond laser, which helps create a dependable stromal pocket or flap where the inlay is placed. This improves the accuracy of the depth at which it is implanted, as well as centration.^{5,6} Creating a pocket has several advantages over a flap, such as saving peripheral corneal nerves (which maintain corneal sensation) and reduce the incidence of dry eye and preservation of corneal biomechanical stability.^{6,7}

Research reports glare and halos in the early postoperative period, but these tend to become less intense during follow-up visits.^{7,8} The literature also shows a loss of contrast sensitivity, something that is believed to occur because of increased total higher-order aberrations (HOAs).^{7,8} An increase in HOAs can also occur with slight decentration of the corneal inlay.^{7,8}

Preoperatively, examining for and identifying dry eye disease is crucial

when preparing a patient for a corneal inlay procedure. The cornea makes up two-thirds of the refractive power of the eye, so if the ocular surface is not healthy, especially in a unilateral procedure, the image quality will be degraded, resulting in a loss of quality of vision that cannot be compensated for with the fellow eye.

Here is a closer look at some specific cornea inlays:

Kamra. Using a small aperture to increase depth of field in a patient's nondominant eye, the Kamra corneal inlay (AcuFocus) was FDA approved in 2015. The 1.6mm aperture in the central optical zone acts as a pinhole, blocking peripheral rays of light to enhance depth of focus.⁹ The inlay is 5µm thick and has an outer diameter of 3.8mm.⁹ Its design maintains metabolic flow—holes or “fenestrations” in the disc allow movement of nutrients—and continued hydration of the cornea, which prevents epithelial decompensation and corneal thinning.¹⁰

The Kamra inlay can be used in emmetropes, post-LASIK emmetropes, in pseudophakic patients or combined with LASIK correction, but the ideal patient to consider for the procedure is one with refraction

ABOUT THE AUTHOR



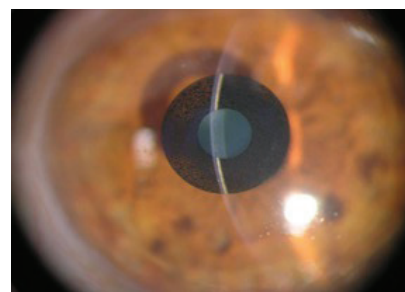
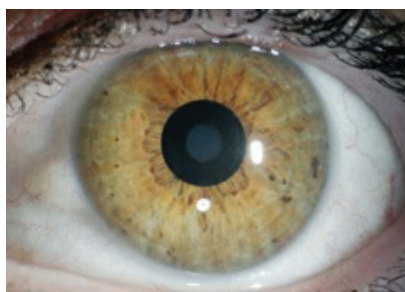
Dr. Schweitzer practices at Vance Thompson Vision in Sioux Falls, SD, and is an adjunct clinical professor at the Illinois College of Optometry.

between plano and -0.75D, as well as astigmatism less than 0.75D.^{10,11} The procedure involves implanting the inlay into a corneal pocket made with a femtosecond laser at a depth of 250 μ m or, if previous LASIK has been performed, at least 100 μ m below the LASIK flap.

Complications of the Kamra inlay are consistent with those typical for any refractive procedure. There have been reports of corneal epithelial iron deposits and haze that is visually significant.¹⁰ When these cases are caught early enough, the inlay can be removed with no loss of corrected visual acuity.^{11,12} In patients with light-colored irides, the implant can be visible to the naked eye from an angle; in most other patients, visualization is negligible.

Research has shown improved near vision, stable or improved intermediate vision and stable or mildly worsened distance vision in the implanted eye.¹² A recent study of 50 eyes with Kamra inlays showed significant improvement of uncorrected near visual acuity (UNVA) from J8 to J2 and median uncorrected distance visual acuity (UDVA) improved from 20/32 to 20/22 at 12 months.¹² Complications were minimal and only included one implant removal due to unsatisfactory UNVA and UDVA as well as slight corneal haze.¹² There was no loss of best-corrected distance visual acuity after removal.¹²

Raindrop Near Vision. Another FDA-approved option is the corneal-reshaping Raindrop Near Vision inlay (ReVision Optics). The Raindrop is a 30 μ m-thick permeable hydrogel lenticule. It allows natural nutrient flow, has no refractive power itself and expands depth of focus by increasing central cornea curvature.^{13,14} Because the inlay makes a hyperprolate corneal shape and features epithelial remodeling, a multifocal cornea is created.^{13,14} This



Photos: Vance Thompson, MD

Kamra inlays, shown here, are implanted into a corneal pocket made with a femtosecond laser.

improves both near and intermediate vision.^{13,14} Distance visual acuity remains largely unchanged as light rays pass paracentral to the 2mm diameter of the inlay and remain focused on the retina.²

Through the use of a femtosecond laser, the Raindrop is inserted under a LASIK flap or corneal pocket at a shallow depth of 120 μ m to 130 μ m in the nondominant eye.²

Like the Kamra inlay, the Raindrop can be repositioned or removed if necessary.¹⁵ Complications related to this inlay include blurred vision, glare and halo.¹⁵

In a study of 373 presbyopic subjects implanted with the Raindrop in the nondominant eye, results showed UNVA improved by five lines, uncorrected intermediate visual acuity (UIVA) improved by 2.5 lines and UDVA decreased by 1.2 lines at a one-year follow up.¹⁵ From three months through one year, 93% of subjects achieved UNVA of 20/25 or better, 97% achieved UIVA of 20/32 or better and 95% achieved UDVA of 20/40 or better.¹⁵ Binocularly, the mean UDVA exceeded 20/20 from three months through one year.¹⁵ Eleven cases required inlay explantations, but all of those patients achieved a corrected distance visual acuity of 20/25 or better by three months after explant.¹⁵

Flexivue Microlens Inlays. Designed to change the refractive index of the cornea, the Flexivue

Microlens (Presbia) is a refractive optic corneal inlay that provides distance vision through a central plano zone surrounded by one or more rings of varying additional powers for intermediate and near vision.^{6,16} The Flexivue is a transparent, 3mm-diameter hydrogel implant with a 0.15mm opening to allow nutrient flow and oxygen transfer.⁷ The opening is surrounded by an optically neutral central zone and a refractive peripheral zone that has add powers between +1.25D and +3.5D in +0.25D increments.⁷ The Flexivue is placed in a femtosecond-created corneal pocket at a depth of 280 μ m to 300 μ m.² Changes to the corneal topography are usually not seen due to the depth at which the inlay is placed.²

The Flexivue Microlens received a “Conformité Européenne” mark, which represents standards of safety, health and environmental protection met for marketability in the European Economic Area, in 2009 and is currently undergoing FDA clinical trials in the United States. In a prospective study of 47 emmetropic presbyopes with a Flexivue Microlens inserted inside a corneal pocket in the nondominant eye, UNVA was 20/32 or better in 75% of operated eyes 12 months after surgery, and mean UDVA decreased three lines from 20/20 preoperatively to 20/50 postoperatively.⁷ Mean binocular UDVA was not

A CLOSER LOOK AT CORNEAL INLAYS

statistically significantly affected, and there were no postoperative complications noted, as well as no inlay explantation or replacement.⁷ Patient satisfaction and spectacle independence was high, but 12.5% of patients experienced halos and glare at one year.⁷

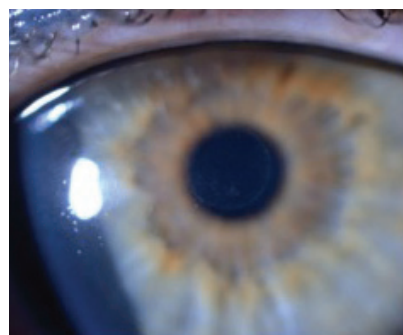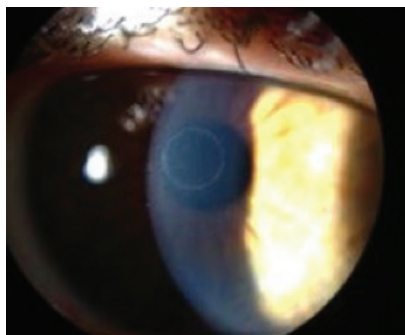
POSTOPERATIVE MANAGEMENT

Managing a patient with an inlay postoperatively differs from managing a LASIK patient postoperatively. The healing time is longer, and it generally takes one to three months for complete visual recovery. Patients should be made aware of probable fluctuations in vision and halo or glare secondary to mild corneal edema during the initial healing period. As a result, it is important to place them on a broad-spectrum antibiotic for one week and a topical corticosteroid tapered over a three-month period. Also, make sure to check intraocular pressure at each follow-up visit, as patients are at risk for pressure spikes secondary to the topical corticosteroid use.

If any signs of ocular surface disease exist, aggressive treatment should be initiated immediately. The inlay and cornea need to be examined closely for areas of irregularity, damage, epithelial ingrowth, stromal inflammation and striae. An increase in corticosteroid treatment will be needed in the case of any haze formation. Frequent manifest refractions should be performed to monitor for hyperopic shifts or myopic shifts that could indicate a central steepening or flattening over the inlay. These occur as a result of tear film irregularities caused by ocular surface disease or corneal haze.

HOW DO THEY HOLD UP?

Corneal inlays are a relatively new treatment option competing directly against lens-based surgeries such as



Photos: Vance Thompson, MD

Through a hyperprolate corneal shape and epithelial remodeling, Raindrop Near Vision Inlays, shown here, create a multifocal cornea.

multifocal IOLs, accommodating and enhanced depth of focus IOLs, and monovision approaches such as LASIK or PRK—not to mention the externally worn corrective lens options of multifocal contact lenses, progressive addition spectacle lenses and simple reading glasses.

Advantages of corneal inlays over traditional monovision correction and lens-based surgeries include improved UNVA and maintained or improved UIVA, as well as minimal effects on UDVA, contrast sensitivity and stereoacuity. There are also fewer risks associated with corneal inlay surgery compared with lens-based surgery, as corneal inlay surgery is limited to the cornea.

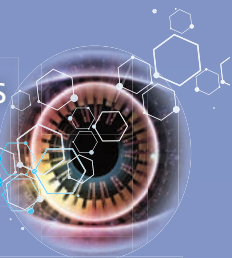Corneal inlays are not without their disadvantages, such as unpredictable wound healing and tear film health. The procedure is not covered by insurance and patients pay out of pocket. As a result, patient selection and education is critical. A patient with a mild or early cataract is going to be better suited for a lens-based surgery, while a patient just entering presbyopia is likely better suited for a mild monovision correction. For corneal inlays to continue to be successful, there will need to be continual advancements in material biocompatibility with the cornea, reduced rates of complications, expanded indications beyond emmetropes/low myopes and continued attention to careful

patient selection with predictable outcomes. **RECU**

1. Murphy SL, Xu JQ, Kochanek KD. Deaths: preliminary data for 2010. *Natl Vital Stat Rep*. 2012;60:30.
2. Greenwood M, Bafna S, Thompson V. Surgical correction of presbyopia: lenticular, corneal, and scleral approaches. *Int Ophthalmol Clin*. 2016;56(3):149-66.
3. Alarcon A, Anera RG, Villa C, et al. Visual quality after monovision LASIK. *J Cataract Refract Surg*. 2011;37:1629-35.
4. Linn S, Hoopes PC. Stereopsis in patients implanted with a small aperture corneal inlay. *Invest Ophthalmol Vis Sci*. 2012;53:1392.
5. Papadopoulos PA, Papadopoulos AP. Current management of presbyopia. *Middle East Afr J Ophthalmol*. 2014;21(1):10-7.
6. Binder P. New femtosecond laser software technology to create intrastromal pockets for corneal inlays. *ARVO*. 2010;51:2868.
7. Limnopoulou AN, Bouzoukis DI, Kymionis GD, et al. Visual outcomes and safety of a refractive corneal inlay for presbyopia using femtosecond laser. *J Refract Surg*. 2013;29:12-8.
8. Pallikaris IG, Bouzoukis DI, Kymionis GD, et al. Visual outcomes and safety of a small diameter intrastromal refractive inlay for the corneal compensation of presbyopia. *J Refract Surg*. 2012;28:168-73.
9. AcuFocus. Kamra Inlay. <https://kamra.com/kamra-inlay/>. Accessed July 24, 2017.
10. Dexl AK, Jell G, Strohmaier C, et al. Long-term outcomes after monocular corneal inlay implantation for the surgical compensation of presbyopia. *J Cataract Refract Surg*. 2015;41:566-75.
11. Yilmaz OF, Bayraktar S, Agca A, et al. Intracorneal inlay for the surgical correction of presbyopia. *J Cataract Refract Surg*. 2008;34:1921-7.
12. Jalali S, Aus der Au W, Shaarawy T. AcuFocus corneal inlay to correct presbyopia using femto-LASIK. One year results of a prospective cohort study. *Klin Monbl Augenheilkd*. 2016;233(4):360-4.
13. Garza EB, Gomez S, Chayet A, Dishler J. One-year safety and efficacy results of a hydrogel inlay to improve near vision in patients with emmetropic presbyopia. *J Refract Surg*. 2013;29(3):166-72.
14. Lang AJ, Holliday K, Chayet A, et al. Structural changes induced by a corneal shape-changing inlay, deduced from optical coherence tomography and wavefront measurements. *Invest Ophthalmol Vis Sci*. 2016;57(9):154-61.
15. Whitman J, Dougherty PJ, Parkhurst GD, et al. Treatment of presbyopia in emmetropes using a shape-changing corneal inlay: one-year clinical outcomes. *Ophthalmology*. 2016;123:466-75.
16. Arlt E, Krall E, Mousa S, et al. Implantable inlay devices for presbyopia: the evidence to date. *Clin Ophthalmol*. 2015;9:129-37.

Up to
18 CE
Credits*

NEW TECHNOLOGIES
& TREATMENTS IN
2017 EYE CARE



REVIEW OF OPTOMETRY®
EDUCATIONAL MEETINGS OF CLINICAL EXCELLENCE

Philadelphia

November 3-5, 2017

Join *Review of Optometry's* New Technologies & Treatments in Eye Care November 3-5, 2017 in Philadelphia, PA. This meeting provides up to 18* COPE CE credits including interactive workshops!*

Review of Optometry partners with Salus University for those ODs who are licensed in states that require university credit.

Registration cost: \$495

Receive \$75 off if registered before September 18, 2017.

Loews Philadelphia Hotel

1200 Market Street,
Philadelphia, PA 19107
Phone: (215) 627-1200

Discounted room rate: \$189/night†



Program Chair: Paul Karpecki, OD, FAO

Faculty: Michael Chaglasian, OD, FAO
Douglas Devries, OD
Steven Ferrucci, OD, FAO

EARLY BIRD SPECIAL

**\$75 OFF
REGISTRATION**

must register before
Sept. 18, 2017



Three Ways to Register

Online: www.reviewofoptometry.com/philadelphia2017

E-mail: reviewmeetings@jobson.com

Phone: 866-658-1772



Administered by
Review of Optometry®

cope
*Approval pending

SALUS
UNIVERSITY
Pennsylvania College of Optometry

Partially supported by
unrestricted educational grants from

Shire Alcon

†Rooms limited. *Subject to change, separate registration required. See event website for complete details.

Watch Out for HSV Endotheliitis

If you only consider dendritic HSV or HSK, you could be missing out on this clinical entity.

Herpes simplex virus (HSV) can affect the anterior cornea in a wide variety of patterns. Dendritic disease sets up the cornea for the many manifestations of inflammatory herpes stromal keratitis (HSK). However, once dendritic disease has occurred, the posterior cornea may just as easily become involved. The posterior cornea is a big target and its involvement presents so differently from its anterior cornea counterpart that if you only consider HSV keratitis as dendritic keratitis, you may miss the diagnosis of HSV endotheliitis. Here is a closer look at HSV endotheliitis, a clinical entity that may seem completely distinct from dendritic HSV or HSK but often follows similar rules.

HSV ENDOTHELIITIS DEFINED

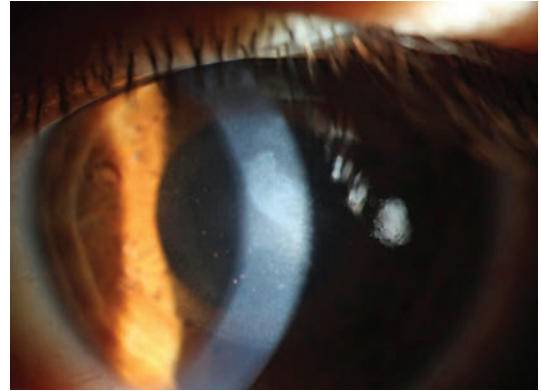Since herpetic endotheliitis may be foreign to some ODs in the trenches, here is its definition: *herpetic endotheliitis is an attack on the corneal endothelium precipitated by a corneal herpes infection.* As with HSK, a previous episode of dendritic keratitis is speculated to be a necessary precursor, but sometimes there is no history available in clinic. While HSK is presumed to be a non-infectious inflammation of the stroma secondary to previous epithelial infection, herpetic endotheliitis is a bit more nebulous. Though research shows it responds well to topical corticosteroid, live virus has been isolated in histologic studies from the endothelium in involved eyes.¹ A 1999 classification system includes a few variations of HSV endotheliitis, but the one

linking presentation is unusual distribution of keratic precipitates (KP) behind zones of edema.² Depending on the presentation, however, KP may or may not be visible.

CASE EXAMPLE

Consider the following example. A 50-year-old contact lens wearer presents with concerns of a sore left eye and blurry vision that developed three days earlier and has been getting worse even after discontinuing lens wear two days earlier. Vision is reduced to 20/400 with no improvement with pinhole. You can see from across the room that the patient's eye is red. Given the history and general appearance, you would be justified in thinking of this as a possible microbial case. However, when you look closer, you see 2+ injection, diffuse epithelial and stromal edema, intraocular pressure (IOP) of 20mm Hg and absence of ulceration despite the initial concerns of a microbial source. Because there is no infiltrate or ulcer, the only remote possibility for microbial keratitis would be *Acanthamoeba* keratitis (AK). In its early stages, AK does not have ulceration, but it would be uncommon for AK to generate this level of edema, and we'd also expect a well-defined zone of epitheliopathy, so it almost certainly isn't AK either.

Here, the diagnostic key is the corneal edema. The general differential for an eye without surgical or traumatic history displaying



This resolving corneal edema has keratic precipitates directly behind it.

sudden onset corneal edema is brief: viral keratitis, contact lens induced hypoxia, a sudden dramatic spike in IOP (either from Posner Schlossman or acute angle-closure glaucoma) and corneal hydrops.

Of this group, we can rule out IOP, because, although epithelial edema is frequently paired with elevated IOP, much higher pressures than 20mm Hg are generally needed to cause edema. It should be noted that most cases of corneal edema primarily show stromal edema at first, and only into chronicity does prominent epithelial edema develop. Severe IOP spikes, viral endotheliitis and allograft rejection are exceptions that often show epithelial edema acutely.

Another possibility in this case would be hypoxic stress from contact lens use; but here, the patient's symptoms have continued to worsen despite contact lens discontinuation two days earlier. In most cases, contact lens-related edema shows improvement relatively quickly after lens discontinuation.

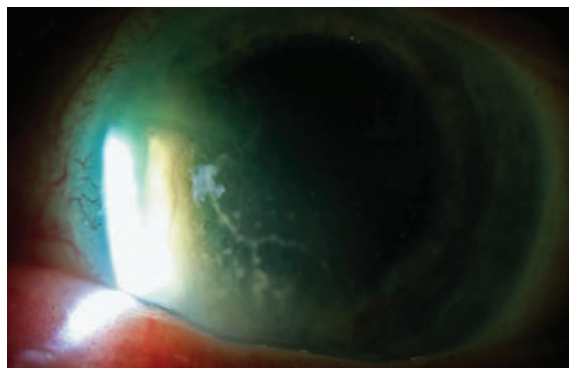
Finally, corneal hydrops only occurs in advanced keratoectasia



with distortion of the corneal curve that should be plain on slit lamp exam.

That brings us to a likely diagnosis of HSV, which is always one of the primary differentials for an eye with sudden corneal edema. Though nomenclature varies somewhat across the globe, this specific form of HSV is often referred to as disciform endotheliitis. Though the term *disciform* suggests a localized circular pattern of edema, it may be generalized across the entire cornea, with the central cornea having the greatest involvement. Mid-sized granulomatous KP, while almost always present, are typically obscured by corneal edema early in the process and only unveiled as the edema clears. These are most heavily distributed behind the zones of greatest edema, usually in a circular distribution. Also typical of these cases is an anterior chamber reaction that becomes visible with clearing of edema and the possibility of moderately elevated IOP from trabeculitis.

In this case example, because the patient already discontinued contact lens wear to no effect, the next step is the standard treatment for all non-dendritic HSV keratitis: an antiviral (in this case, oral is preferable given the penetration concerns) and a topical corticosteroid. The patient's eye will respond quickly to this, though total clearing of edema may take several weeks. In severe or recurrent cases, this treatment may actually lead to corneal endothelial decompensation and require an endothelial transplant.



Here is an example of severe linear endotheliitis. This branching lesion is a single contiguous KP on the endothelium.

DIFFUSE AND LINEAR ENDOTHELIITIS

Though disciform endotheliitis tends to be the most common form of herpetic endotheliitis, diffuse and linear endotheliitis are other possibilities.^{1,2} These forms will also have corneal edema, but the initial edema is less profound. In general, any eye with an unusual pattern of KP unilaterally should have HSV on the differential.

Here, “unusual” bears some defining. In most cases of endotheliitis or iritis, KP, particularly if they are granulomatous, are distributed along with convection currents in a pattern known as Arlt's triangle. Herpetic KP typically fall outside of this triangle. In diffuse endotheliitis, the distribution of KP is widely spread across the corneal endothelium. These tend to be small to moderate granulomatous lesions but may aggregate in severe disease into a retro-corneal plaque.

Alternately, herpetic KP may be distributed as a solid line, sometimes with branching extensions. This is known as linear endotheliitis. It is the most severe form of HSV

endothelial disease and also the most difficult form to treat.

Coexisting iritis and trabeculitis are possible with all types of HSV endothelial disease. The differential diagnosis in diffuse endotheliitis is Fuchs' heterochromic iridocyclitis (FHI), anterior extension of toxoplasmosis choroiditis, herpes zoster endotheliitis and some forms of corneal graft rejection.

In FHI, KP is prominently stellate, heterochromia is often present and patients are typically asymptomatic of mild iritis. Unlike herpetic endotheliitis, FHI patients do not develop corneal edema. The differential for linear endotheliitis is almost always viral (HSV vs. cytomegalovirus), with an exception for Khodadoust's line, which can be seen in endothelial graft rejection.

So far, in this column series on HSV, I've stated, “any unilateral keratitis without a compelling history is HSV unless proven otherwise,” which seems at first perhaps too sweeping. As we've moved along, however, to HSK and now endotheliitis, you can see that the original statement isn't complete hyperbole. I believe you will never be criticized for treating any unilateral keratitis without a history or clinical picture of microbial disease as HSV. Of course if it doesn't respond, revisit your diagnosis, but it's always a reasonable starting point. **RCCL**

1. Holland EJ, Brilakis HS, Schwartz GS. Herpes simplex keratitis. In: Krachmer JH, Mannis MJ, Holland EJ, eds. *Cornea*. 2nd ed. St. Louis: Mosby; 2004:1043-74.

2. Holland EJ, Schwartz GS. Classification of herpes simplex virus keratitis. *Cornea*. 1999;18:144-55.

Fitting CLs Post Trabeculectomy

It's a tough balance between maintaining the bleb's integrity and providing the best possible vision. Here's how to handle the situation.

The number of patients diagnosed with glaucoma is expected to exceed 70 million by 2020.¹ When pharmacological or laser treatments fail to control intraocular pressure (IOP), surgical options such as trabeculectomy can be effective.² But what happens when these patients need contact lenses? To prevent fibrosis, the conjunctiva above the bleb is usually treated with mitomycin C or 5-FU, both of which can make the conjunctiva thin and more susceptible to infection.³⁻⁴ Additionally, if soft or rigid lenses induce mechanical trauma to the bleb, they can lead to blebitis or endophthalmitis.

To respect the integrity of the bleb, contact lens practitioners have three options: a soft low modulus lens that vaults the entire bleb, a notched scleral lens or a small, well centered rigid gas permeable (RGP) lens fit with minimal excursion.⁵

CASE

An 84-year-old female presented with long-standing blurred vision OS for a contact lens evaluation after referral by her glaucoma specialist. Her vision did not correct well with glasses and she felt it was worsening. Her history included glaucoma OU, herpes simplex virus infection OS in 2012 with residual scarring, s/p trabeculectomy OS in 2014 and bleb revision OS in 2016. Her medical history was positive for hypertension, hyperlipidemia and osteoporosis.

Her presenting visual acuity (VA) was 20/20 OD and 20/200 OS,

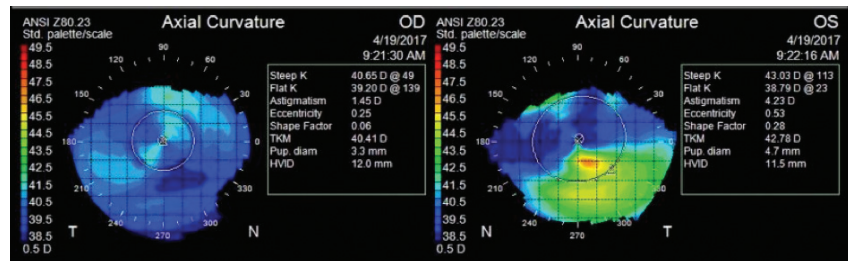


Fig. 1. Topographical map of this patient revealed a normal cornea OD and an elevated scar inferior temporal OS.

pinhole: 20/40, with a spectacle prescription of -1.25 +1.50x 27 OD and plano +0.75x156 OS. Her manifest refraction was -1.25+1.50 x027 VA 20/20 OD and -0.25+2.50 x 120 VA 20/150 OS, pinhole to 20/40. A slit lamp exam revealed 1+blepharitis OU, a clear cornea OD and inferior corneal scar OS and an elevated avascular bleb adjacent to the superior limbus OS (Figure 1). The anterior chamber was deep and quiet OU. Her irises were normal with posterior chamber intraocular lenses OU. IOP was soft and equal by digital palpation OU.

DIAGNOSTIC CONTACT LENS FITTING

We performed a diagnostic RGP over-refraction in office to determine the best potential acuity of the left eye. An 8.33/-3.00/9.6 diagnostic lens with standard curvatures was placed on the patient's eye. Over-refraction of +4.50 brought the vision to 20/25+. The lens was aligned, but it was riding high

and hit the bleb with each blink. We ordered the lens smaller with the central base curve steepened to compensate for the flattening effect of the decrease in diameter. A half-diaptor of prism base down was added to weigh the lens down and away from the bleb.

The parameters of this first lens were 8.23 BC/+1.25 power/9.2 diameter/0.5 diopter base down.

DISPENSING VISIT #1

The patient presented for a dispensing visit one week later with no new complaints. Her VA was 20/20 with no over-refraction. The position of the lens was lower but was still too close to the bleb (Figure 2). Each blink caused the lens to hit the bottom of the bleb. As a result, we ordered another

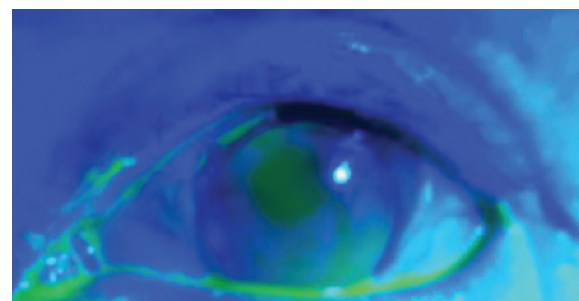


Fig. 2. Here, the first lens is positioned under the patient's bleb, but is still too close.



lens with an additional half-step of prism base and 0.2mm smaller than the previous.

Parameters for this lens were 8.23 BC/+1.25 power/9.0 diameter/1D base down.

DISPENSING VISIT #2

One week later, the patient presented for another dispensing visit. This time, the lens sat low and did not touch the bleb on blink (*Figure 3*). However, when vision was evaluated the patient was 20/40-. Pushing the lens up brought her to 20/25+. Because of this, we determined that she was looking through decentered optics, which resulted in her suboptimal vision. As a result, we ordered another lens, this time with reduced prism weight and a steeper edge profile to decrease lens mobility.

New lens parameters were 8.23 BC/+1.25 power/9.0 diameter/0.5D base down/1 step steep edge.

DISPENSING VISIT #3

When the patient presented for another dispensing visit a week later, her vision was measured

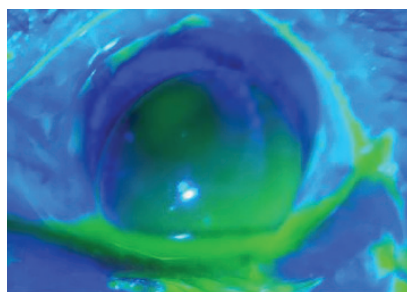


Fig. 3. At the second dispensing visit, although the lens sat low and did not touch the bleb on blink, vision was less than ideal due to decentered optics.

at 20/20 with no over-refraction. The lens alignment was slightly steep but more centered over the pupil (*Figure 4*). There was less mobility on blink, but the amount was still adequate and the lens did not disturb the bleb. We trained the patient on lens insertion and removal and sent her home to try for a week.

FOLLOW-UP

The patient presented one week later with no complaints. She was thrilled with the new vision in her left eye and was able to wear the lens comfortably. Her vision was 20/20. A slit lamp examination revealed a well-fit lens that cleared the bleb on each blink without punctate staining from the tighter than usual edge. The lens was finalized.

Patients who undergo glaucoma surgeries sometimes present with comorbidities that require RGP correction for better vision (i.e., corneal irregularities or aphakia). Fitting contact lenses on patients post trabeculectomy continues to be a bit controversial, and there are arguments to be made on both sides of the equation. Not fitting a lens will deprive the patient of better vision, while wearing a lens can compromise the integrity of the bleb and put the patient at risk for infection. However, the success rate of RGP lenses post trabeculectomy shows some promise.⁶⁻⁸

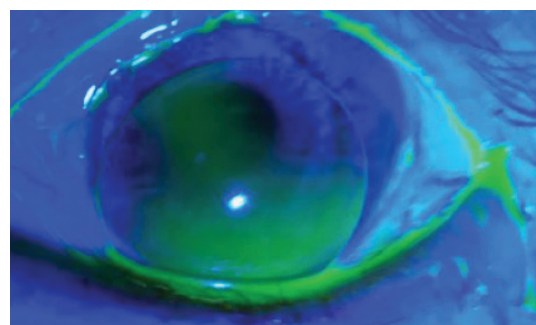


Fig. 4. Here is the lens clearing the bleb during the third dispensing visit. Its alignment was slightly steep but more centered over the pupil than the previous lens.

When a patient presents for a contact lens fit, practitioners should consider the status of the bleb and any history of prior infection or instability, as this can put the patient at greater risk for infection.⁶ Additionally, patients should be well educated on the signs and symptoms of an infection. These patients can be challenging to fit; as such, vigilant follow-up is an essential part of their success. **RCCL**

1. Tham YC, Li X, Wong TY, et al. Global prevalence of glaucoma and projections of glaucoma burden through 2040: a systematic review and meta-analysis. *Ophthalmology*. 2014;121(11):2081-90.
2. Guttman C, Singh K. Clinicians must weigh value of randomized clinical trial results. *Ophthalmology Times*. 2004;29(11):18.
3. Ticho U, Ophir A. Late complications after glaucoma filtering surgery with adjunctive 5-fluorouracil. *Am J Ophthalmol*. 1993;115(4):506-10.
4. Franks WA, Hitchings RA. Complications of 5-fluorouracil after trabeculectomy. *Eye*. 1991;5:385-9.
5. DeNaeyer GW. Contact lenses After Trabeculectomy. *Contact Lens Spectrum*. January 1, 2010. www.clspectrum.com/issues/2010/january-2010/contact-lenses-after-trabeculectomy. Accessed July 28, 2017.
6. Samples JR, Andre M, MacRae SM. Use of gas permeable contact lenses following trabeculectomy. *CLAO J*. 1990;16(4):282-4.
7. Lois N, Dias JL, Cohen EJ. Use of contact lenses in patients with filtering blebs. *CLAO J*. 1997;23(2):100-2.
8. Pederson K. Enhance postoperative filtering bleb-induced vision difficulties with well-fitted GP contact (oxygen-permeable) lenses. *Optometry*. 2005;76(2):115-22.

Three GP Lenses to Grow Your Practice

Make the most of your available options, and your practice will reap the benefits.

When we started out in practice, gas permeable (GP) lenses were a mainstay. Practitioners readily fit everyday patients for them, and both practitioners and patients saw them as normal. However, over the last 10 years, opinions surrounding GP lenses have shifted. For example, many patients and practitioners began to overlook the benefits of GP lenses as a result of the increased availability of soft lenses.

One of the benefits of soft lenses, generally, is near immediate comfort for most patients. GP lenses, meanwhile, have historically been known for exceptional performance in vision. Recently, however, interest in GP lenses has picked back up in the marketplace.¹ Here is an overview of three GP lenses and how they can help dramatically grow your practice in patient loyalty and satisfaction.

ORTHOKERATOLOGY

In the 1970s, practitioners started to see the benefits of fitting lenses flatter than the corneal shape. Although most of these lenses were worn during the day and provided variability in vision, the realization started the movement around orthokeratology (ortho-k). This resulted in dramatic growth of the understanding and knowledge of reverse geometry lenses. The rest is history.

Orthokeratologists began anecdotally reporting that some of their patients appeared to have slower myopia progression compared with

their eyeglass-wearing counterparts. In 2004, one study showed that both the anterior chamber and vitreous chamber depths increased nearly twice as much in patients wearing spectacle lenses compared with those wearing ortho-k contact lenses.² The body of evidence continues to grow around the benefits of ortho-k for children who are progressing or may progress in their myopia.³

Despite the evidence, many practitioners are reluctant to initiate ortho-k in their practice, whether stemming from a lack of understanding, a lack of knowledge about effects or concern about chair time. However, myopia stabilization through accelerated reshaping technique has revealed incredible success with ortho-k.⁴ In one study of myopia stabilization, about 80% of patients had success with their initial lens fitting, and nearly 95% of them had success with, at most, one lens change. This type of success is rarely achieved with soft toric lenses, let alone soft multifocal lenses. Seeing a lens perform so successfully is a helpful way to pull back hesitation barriers for both chair time and fitting complexity.

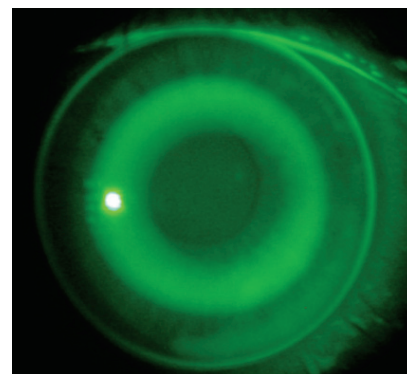
The investment required to start prescribing ortho-k is small, while the patient and financial benefits can be large. If you're looking to dip your toe in, be sure to form a good relationship with one of the major orthokeratology manufacturers. Generally, clinical consultation will be your best ally. To get started, try calling an orthokeratology company to find out about the process.

If what they outline seems complicated and difficult, simply try another lab. Once you find a process that fits you and your practice, you will need to take a short course outlining the lens and its fitting system followed by a certification test. Although this may seem like a waste of time, rest assured that the small investment will be well worth it as you begin fitting.

Next, you will need to identify a patient to start with. Working with a low myope (-0.75D to -1.5D) is a good way to maximize your success and build your confidence. If you are fitting empirically, order the lens based on the parameters set forth by your chosen manufacturer (usually Ks, Rx and HVID). A follow-up visit will then allow you to determine whether the case is a success or another lens order is required.

Calling the laboratory and sharing your experience will be helpful in either case. A great company will have consultants to coach you on the next steps.

Typically, ortho-k is an out-of-pocket cost for patients. Its



Ortho-k lenses are a potentially beneficial option for myopes.



benefits are best known for myopia control, but it also allows the freedom from daytime contact lenses and glasses, something that often goes over well with adults and parents of school-aged children. Ortho-k is an excellent way to reshape your practice financially and, more importantly, for your patients' benefit.

MULTIFOCALS

We see presbyopic patients in our offices every day, but sometimes forget to mention multifocal contact lenses as an available option for them. When we do mention them, however, it sparks great conversations. Some of these patients have dropped out because of comfort issues, in which case it is important to address their ocular surface disease more aggressively. Others may be unaware that they can still wear contact lenses. Despite this, you'll likely find that a good number of patients want to wear lenses. For many, simultaneous vision soft multifocal contact lenses are suitable options to meet visual demands, but for those seeking full-time wear, soft multifocals can fail to provide crisp clarity. For these patients, GP multifocal lenses are in order, of which there are two different types that need to be considered:

Aspheric. Both anterior and posterior aspheric powers can be incorporated into multifocal lenses. Due to the optics, amount of add that can be placed on the anterior surface is limited. However, it is easier to move a spherical single vision patient into a lens by simply adjusting the curvature of the

anterior surface. As the demand for add goes up, many patients will require additional power adjustments to the posterior surface.

Segmented. Like a lined bifocal, some patients need a segmented or translating GP multifocal lens. These lenses require a unique fitting system to ensure the patient gets into the add zone upon downward gaze. Although these are somewhat complicated to fit, they can provide incredible value to patients who require their visual benefits.

Multifocals are an excellent way to grow your practice. They help keep patients in lens wear longer and provide an incredible amount of value for patients who want to be spectacle-free. They can provide financial benefits both in the short-term and long-term.

SCLERALS

Since starting to fit scleral lenses in 2004, we have seen them dramatically grow in popularity. Our understanding of their effect on the eye, coupled with our ability to better fit patients, has helped bring them into the mainstream awareness. Because these lenses fit under the upper lid, they tend to provide much better initial comfort for patients. Also, since they are large and do not move or translate on the eye, they provide much better stability of vision for patients.

While there are always some cases that need advanced troubleshooting or a more advanced lens design, for most patients scleral lens fittings can be achieved by

following three simple steps:

1. *Clear the central cornea by around 100 to 300 μ m.*
2. *Clear the limbus.*
3. *Land the scleral landing zone on the conjunctival surface as tangentially as possible.*

There are many fitting guides, groups and training tools to help you get started in fitting scleral lenses. Our recommendation: Get started.

There are several practice management situations you will need to consider depending on the reason you are fitting a patient for scleral lenses. If you're fitting for medical reasons (i.e., keratoconus), you will need to make sure your billing and coding team knows the proper codes to use. However, if you are fitting for astigmatism or presbyopia, you will likely be charging the patient out of pocket. With the increased cost of goods for scleral lenses, it is important to understand how to set your lens fees as well as your chair time costs.

Fitting patients for myopia management lenses, multifocals and scleral lenses can have a huge impact on your practice. Give all three a try as soon as you can. RCCL

1. Nichols JJ. Contact lenses 2016. *Contact Lens Spectrum*. 2017;32:22-25.
2. Cho P, Cheung SW, Edwards M. The longitudinal orthokeratology research in children (LORIC) in Hong Kong: a pilot study on refractive changes and myopic control. *Curr Eye Res*. 2005;30(1):71-80.
3. Walline JJ, Jones LA, Sinnott LT. Corneal reshaping and myopia progression. *Br J Ophthalmol*. 2009;93:1181-5.
4. Eiden BS, Davis RL, Bennett ES, et al. The SMART Study: background, rationale, and baseline results. *Contact Lens Spectrum*. October 1, 2009. www.clspectrum.com/issues/2009/october-2009/the-smart-study-background,-rationale,-and-baseline. Accessed August 5, 2017.



Crocodile Rock

Can you identify this corneal anomaly? Does it contraindicate contact lens wear?

An 81-year-old male presented with a 60-year history of aphakia OU secondary to idiopathic crystalline lens dislocations. He was referred over concerns about corneal edema and whether he should discontinue wear of his gas permeable (GP) contact lenses.

Slit lamp exam showed posterior crocodile shagreen centrally with microcystic edema 360 degrees in the periphery with 2mm of peripheral neovascularization, consistent with Brown-McLean syndrome (BMS). This condition is typically observed after intracapsular cataract surgery, but has also been

reported in extracap procedures with phaco, pars plana lensectomy/vitreotomy and Marfan's syndrome with lens subluxation.

While the exact etiology of BMS is unknown, it is generally benign and rarely affects vision. Stromal/microcystic edema is seen in the peripheral 2mm to 3mm of the cornea with orange or brown deposits at the level of Descemet's membrane.¹ The edema often begins inferiorly and spreads circumferentially. In some cases, the patient will present with a foreign body sensation or bullae, which can be treated with lubrication or hyperosmotics.

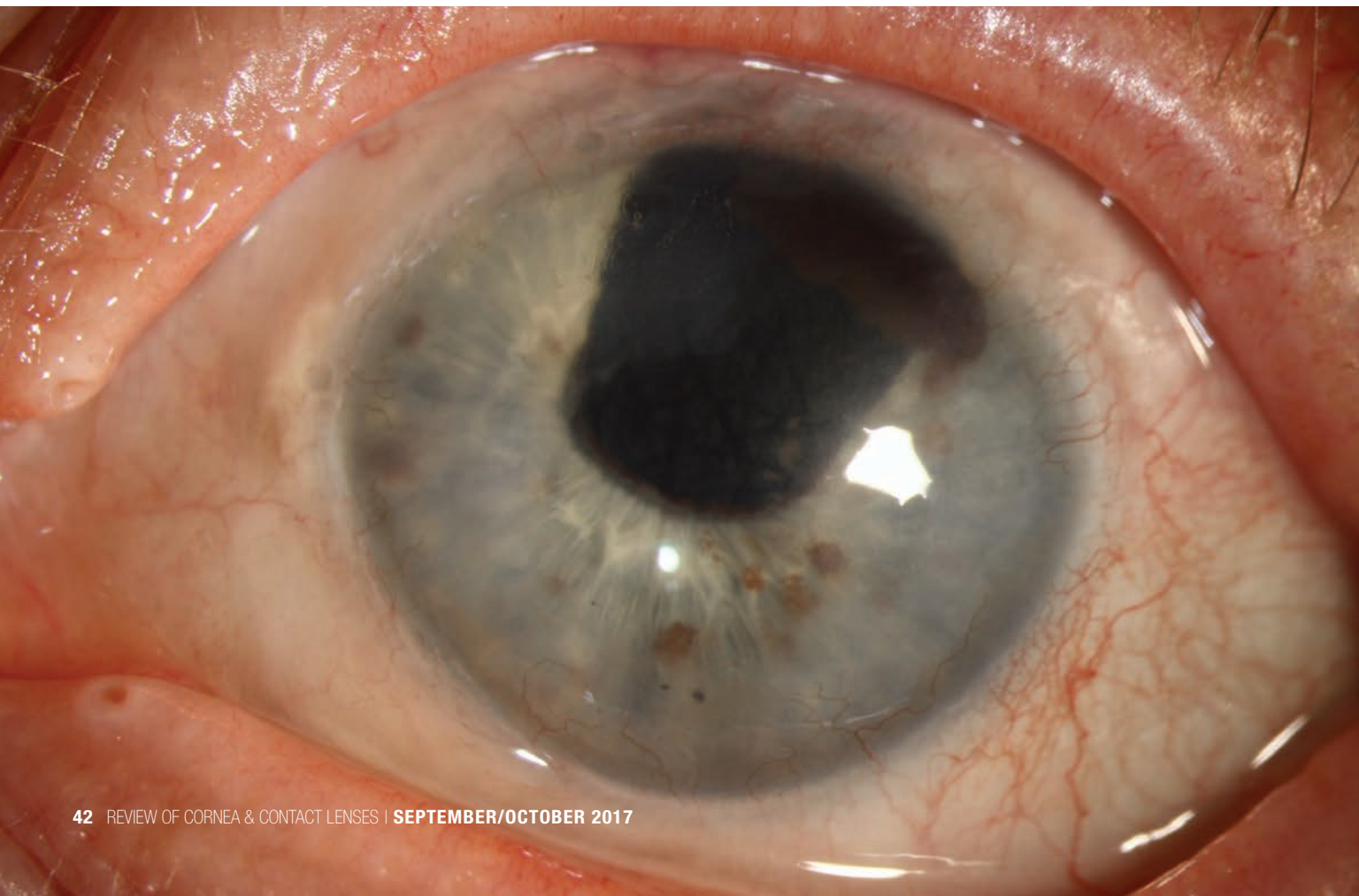
Central posterior crocodile shagreen is believed to be a primary

degenerative process involving rearrangement of the posterior stromal lamellae.²

Brown-McLean syndrome is not a contraindication to contact lens wear. The high oxygen transmissibility of GP materials is favorable over soft lenses in this case, given the propensity for edema formation. The patient was advised to continue GP lens wear and instructed to alert the clinic of any untoward events or discomfort. **RCCL**

1. Gothard TW, Hardten DR, Lane SS, et al. Clinical findings in Brown-McLean syndrome. *Am J Ophthalmol.* 1993 June 15;115(6):729-37.

2. Belliveau MJ, Brownstein S, Agapitos P, Font RL. Ultrastructural features of posterior crocodile shagreen of the cornea. *Surv Ophthalmol.* 2009 Sep-Oct;54(5):569-75.



WH₂O₂A!

Patients Love Our Bubbles



Winner Eye Care Category

Survey of 40,000 consumers by TNS



Go Beyond MPS.

Upgrade your patients to the bubbling power of CLEAR CARE® PLUS for:

- Unsurpassed disinfection^{1,2}
- Better comfort and cleaner feeling lenses^{3*}
- No preservatives to be more like natural tears

Pick the winner that makes loving lenses easy for your patients. Recommend the bubbling power of CLEAR CARE® PLUS.

To learn more, visit clearcareprofessional.com.

PERFORMANCE DRIVEN BY SCIENCE™

CLEAR CARE® PLUS
formulated with

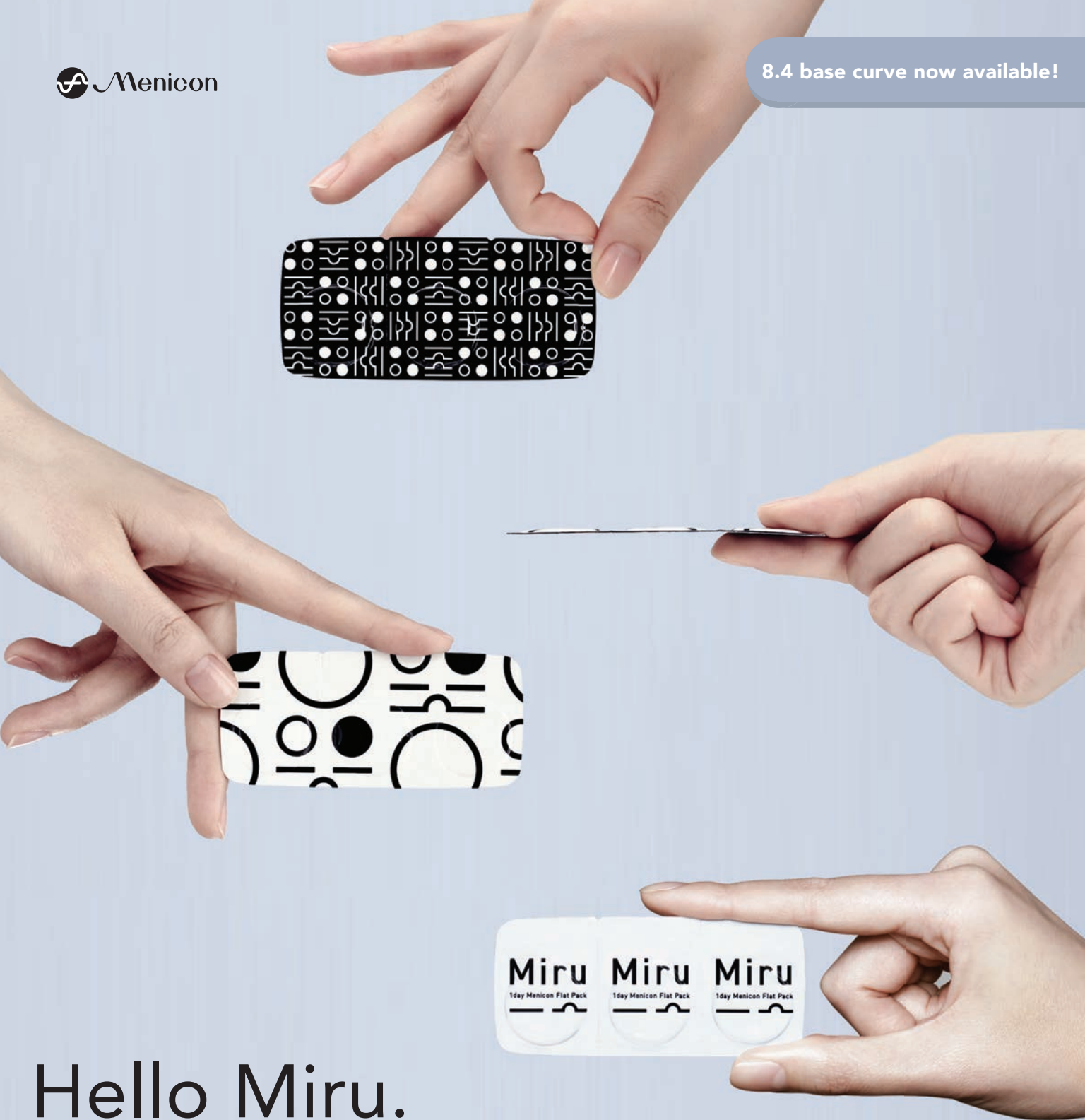

MPS, multipurpose solution.
*Compared to MPS in symptomatic users.

References: 1. Gabriel M, Bartell J, Walters R, et al. Bicidal efficacy of a new hydrogen peroxide contact lens care system against bacteria, fungi, and Acanthamoeba species. *Optom Vis Sci*. 2014;91:E-abstract 145192. 2. Alcon data on file, 2014. 3. Alcon data on file, 2015.

© 2016 Novartis 04/16 US-CCS-16-E-1913

Alcon
a Novartis company



Hello Miru. Bye, bye blister pack.

Introducing Miru 1day, the world's thinnest package for daily disposable contact lenses.

Miru's ultra lightweight 1mm thin package is about 1/8th the thickness of a traditional blister pack and was specifically developed to reduce the risk of microbial contamination. When opened, the lens is presented on a special disk, oriented correctly for proper insertion.

To learn more and request trials, please visit: www.meniconamerica.com

©2017 Menicon America, Inc. Miru is a registered trademark of Menicon Company Ltd.