

RCCL[®]

REVIEW OF CORNEA
& CONTACT LENSES

APRIL 2016

LOOK Before You LEAP
p. 6

FITTING:
A Three-Point Plan
p. 8

Tailoring with TORICITY
p. 10

Does RESEARCH
SUPPORT
ROUTINE Use?
[EARN 1 CE CREDIT]
p. 12

Treating
Corneal
DISEASE
p. 18

Prepping the
NEW PATIENT
p. 24

TROUBLESHOOTING
Complications
p. 28

SPECIAL ISSUE

SOLVING SCLERALS

Mastering this modality isn't as tricky as you may think. Experts explain.

Supplement to
REVIEW[®]
OF OPTOMETRY

ALSO: A CAPRICIOUS CORNEAL INFECTION RESPONSE • RETHINK YOUR PRACTICE PROTOCOLS

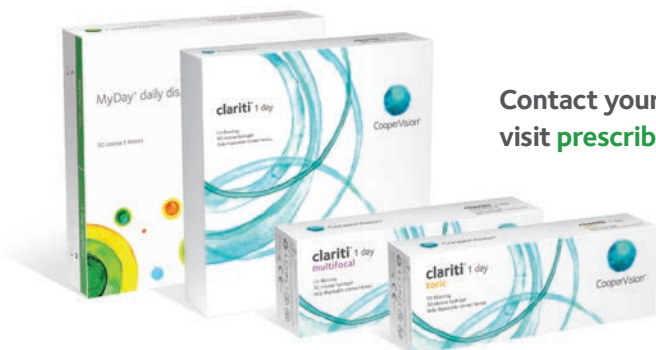

Ready to be your patients' most trusted expert? **Prescribe oxygen.**

 MyDay® daily disposable  clariti® 1 day  clariti® 1 day multifocal  clariti® 1 day toric

With CooperVision's largest portfolio of silicone hydrogel 1-day contact lenses you can fit virtually all patients into a 1-day lens that provides high oxygen, comfort and convenience. From the uncompromising performance of MyDay® to the breadth of the clariti® 1 day family, CooperVision is the only one you need to serve your 1-day patients.

For brighter, healthier eyes ready to take on the world, the prescription is oxygen. And the opportunity is yours.



Contact your CooperVision sales representative or visit prescribeoxygen.com for more information.



CooperVision®
Live Brightly.™

contents

Review of Cornea & Contact Lenses | April 2016

departments

4 News Review

What Increases the Need for Refractive Surgery Retreatment?; Ozone, Humidity Factors in Dry Eye

6 My Perspective

Big Gains for Big Lenses
By Joseph P. Shovlin, OD

8 Practice Progress

Sclerals: Easy as 1-2-3
By Mile Brujic, OD, and
Jason R. Miller, OD, MBA

10 The GP Experts

Happy Landings
By Robert Ensley, OD, and
Heidi Miller, OD

32 Corneal Consult

Complications from a Corneal Issue
By J. James Thimons, OD

34 Out of the Box

To Do or Not to Do?
By Gary Gerber, OD

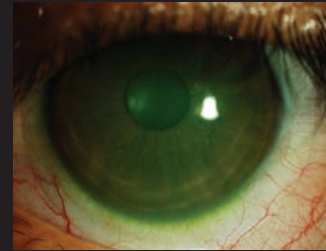
features

12

CE — Scleral Lens Fitting: Once Rare, Now Routine?

As these specialty lenses continue to gain in popularity, should they be adopted for wear in uncomplicated cases as well?

By Langis Michaud, OD



18

Scleral Lenses in Action: Solving Problems With Specialty Lenses

These lenses are good for more than just the irregular cornea. Five cases illustrate their potential.

By Marsha Malooley, OD,
and Jeffrey Sonsino, OD

24

Off on the Right Foot: Preparing the Patient for Scleral Lens Wear

Are you fitting a first-timer? Keep these tips in mind for a smoother process.

By Stephanie L. Woo, OD

28

Simple Tips for Troubleshooting Sclerals

These lenses can pose unique challenges, especially for newcomers to the modality. Here's how to improve chances of success.

By Chandra Mickles, OD, MS,
and Melissa Barnett, OD

Cover photo courtesy of Stephanie Woo, OD
Cover design by Ashley Schmouder
©Jobsonhealthcare



/ReviewofCorneaAndContactLenses

@RCCLmag

IN BRIEF

■ Wear of **scleral lenses** over longer periods of time may exacerbate **corneal swelling**, reports a study in the March 2016 issue of *Optometry and Vision Science*.¹

Researchers used **Scheimpflug imaging** to examine the corneas of healthy patients before and immediately after **eight hours** of high Dk miniscleral lens wear, finding that a low level of **corneal edema** occurred by the eight-hour mark. Though the level of swelling was **less than typically observed following overnight eyelid closure**, these findings do contradict earlier research that suggests hypoxia-related changes to the cornea **stabilize at three hours** of wear time, the researchers note.^{2,3} They suggest further research be conducted.

1. Vincent, S, Alonso-Caneiro D, Collins M, et al. Hypoxic corneal changes following eight hours of scleral contact lens wear. *Optometry and Vision Science*. 2016 Mar. 93(3):293-9.

2. Sarver MD, Polse KA, Baggett DA. Intersubject difference in corneal edema response to hypoxia. *Am J Optom Physiol Opt*. 1983 Feb;60(2):128-31.

3. Holden BA, Sweeney DF, Sanderson G. The minimum precorneal oxygen tension to avoid corneal edema. *Invest Ophthalmol Vis Sci*. 1984 Apr;25(4):476-80.

■ An **unstable tear film** may indicate candidates who will **fail** to take to **gas permeable** lens wear, reports a study in the March 2016 issue of *Eye & Contact Lens*.¹ Twenty-two participants were given GP lenses to wear **daily for one month**, with follow-up visits scheduled at one, seven, 15 and 28 days. Six patients dropped out due to discomfort; those that remained but reported dissatisfaction exhibited **lower comfort scores and wear time due to dryness**.

1. Carracedo G, Martin-Gil A, Peixoto-de-Matos S, et al. Symptoms and signs in rigid gas permeable lens wearers during adaptation period. *Eye & Contact Lens*. 2015 Mar;42(2):108-14.

■ Including **organoselenium** in the polymer of **contact lens cases** could inhibit biofilm formation, suggests a study published online in *Eye & Contact Lens*.¹ Researchers tested the effects of the material on the growth of ***Pseudomonas aeruginosa*, *Staphylococcus aureus*, *Stenotrophomonas maltophilia* and *Serratia marcescens*** by incubating the bacteria overnight in the presence of both a polypropylene polymer containing organoselenium and the same polymer without organoselenium. Results indicated the presence of the organoselenium **inhibited growth of all bacteria by nearly 100%**.

1. Tran P, Huynh E, Pham P, et al. Organoselenium polymer inhibits biofilm formation in polypropylene contact lens case material. *Eye & Contact Lens*. 2016 Mar. [Epub ahead of print]

What Increases the Need for Refractive Surgery Retreatment?

Refractive surgeons have reduced the need for retreatment in recent years—from 4.52% in 2005 to just 0.18% in 2012—but older patient age, higher degree of astigmatism, the presence of hyperopia, surgeon inexperience and colder operating room temperature increase the likelihood of an enhancement procedure. So says a retrospective review of 21,313 LASIK and PRK patients published online in *Cornea*.¹

Though research comparing the safety and efficacy of laser in-situ keratomileusis (LASIK) and photorefractive keratectomy (PRK) exists, data on the factors that dictate need for retreatment remain scarce.^{2,3}

Researchers at Ben-Gurion University of the Negev and Care-Vision Laser Centers in Tel Aviv, Israel analyzed data from patients who had undergone either LASIK or PRK at the latter institution between January 2005 and December 2012. Patients were separated into one of two groups according to whether they had undergone additional refractive surgery after the initial procedure. A total of 41,504 eyes were evaluated. LASIK flap creation was performed with a Moria microkeratome.

Data indicated that during the study period, 2.1% of eyes underwent a single retreatment, while 0.05% of eyes underwent two retreatments and a single eye underwent three retreatments. All retreated patients (compared with those who only underwent their initial refractive procedure) exhibited significantly older age, better initial best-corrected visual acuity (BCVA) and higher preoperative Kmax,

sphere and degree of cylinder values. Curiously, both patients with better BCVA (>1.35 logMAR) and worse BCVA (<0.45 logMAR) demonstrated higher retreatment rates, possibly due patient misconceptions regarding what outcomes to expect, the researchers say. The correlation between retreatment and patient age may reflect “the use of conservative nomograms, which attempt to avoid overcorrection in older patients,” the researchers wrote.

Additionally, patients requiring retreatment are also more likely to have a preoperative clinical cylinder greater than 1D; hyperopia rather than myopia; a 6.5mm optical zone (rather than 7mm) treatment; have undergone PRK (rather than LASIK); and been treated in higher humidity, lower temperature operating rooms. These results, the researchers say, could occur because “current methods, including the nomograms applied, are less accurate when it comes to treating astigmatism, as opposed to sphere.”

The team also noted that while no significant differences in mean K power were detected in the patient population, those with greater than 46D exhibited higher retreatment rates. Patients treated with ablation depths less than 30µm and greater than 120µm, as well as those who were treated by less experienced surgeons, exhibited the same. **RCCL**

1. Mimouni M, Vainer I, Shapira Y, et al. Factors predicting the need for retreatment after laser refractive surgery. *Cornea*. 2016. [epub ahead of print].

2. Shortt AJ, Allan BD, Evans JR. Laser-assisted in-situ keratomileusis (LASIK) versus photorefractive keratectomy (PRK) for myopia. *Cochrane Database Syst Rev*. 2013;1:CD005135.

3. Settas G, Settas C, Minos E, et al. Photorefractive keratectomy (PRK) versus laser-assisted in situ keratomileusis (LASIK) for hyperopia correction. *Cochrane Database Syst Rev*. 2012;6:CD007112.

EDITORIAL STAFF

EDITOR-IN-CHIEF

Jack Persico jpersico@jobson.com

SENIOR ASSOCIATE EDITOR

Aliza Becker abecker@jobson.com

CLINICAL EDITOR

Joseph P. Shovlin, OD, jpshovlin@gmail.com

ASSOCIATE CLINICAL EDITOR

Christine W. Sindt, OD, christine-sindt@uiowa.edu

EXECUTIVE EDITOR

Arthur B. Epstein, OD, artepstein@artepstein.com

CONSULTING EDITOR

Milton M. Hom, OD, eyemage@mmineternet.com

SENIOR GRAPHIC DESIGNER

Matthew Egger megger@jhihealth.com

GRAPHIC DESIGNER

Ashley Schmouder aschmouder@jobson.com

AD PRODUCTION MANAGER

Scott Tobin stobin@jhihealth.com

BUSINESS STAFF

PUBLISHER

James Henne jhenne@jobson.com

REGIONAL SALES MANAGER

Michele Barrett mbarrett@jobson.com

REGIONAL SALES MANAGER

Michael Hoster mhoster@jobson.com

VICE PRESIDENT, OPERATIONS

Casey Foster cfoster@jobson.com

EXECUTIVE STAFF

CEO, INFORMATION SERVICES GROUP

Marc Ferrara mferrara@jhihealth.com

SENIOR VICE PRESIDENT, OPERATIONS

Jeff Levitz jlevitz@jhihealth.com

SENIOR VICE PRESIDENT,

HUMAN RESOURCES

Tammy Garcia tgarcia@jhihealth.com

VICE PRESIDENT,

CREATIVE SERVICES & PRODUCTION

Monica Tettamanzi mtettamanzi@jhihealth.com

VICE PRESIDENT, CIRCULATION

Emelda Barea ebarea@jhihealth.com

CORPORATE PRODUCTION MANAGER

John Caggiano jcaggiano@jhihealth.com

EDITORIAL REVIEW BOARD

- Mark B. Abelson, MD
- James V. Aquavella, MD
- Edward S. Bennett, OD
- Aaron Bronner, OD
- Brian Chou, OD
- Kenneth Daniels, OD
- S. Barry Eiden, OD
- Desmond Fonn, Dip Optom M Optom
- Gary Gerber, OD
- Robert M. Grohe, OD
- Susan Gromacki, OD
- Patricia Keech, OD
- Bruce Koffler, MD
- Pete Kollbaum, OD, PhD
- Jeffrey Charles Krohn, OD
- Kenneth A. Lebow, OD
- Jerry Legerton, OD
- Kelly Nichols, OD
- Robert Ryan, OD
- Jack Schaeffer, OD
- Charles B. Slonim, MD
- Kirk Smick, OD
- Mary Jo Stiegemeier, OD
- Loretta B. Szczołka, OD
- Michael A. Ward, FCLSA
- Barry M. Weiner, OD
- Barry Weissman, OD



Ozone, Humidity Shown to Be Factors in Dry Eye Disease

Dry eye disease may be linked to specific levels of pollutants in the atmosphere, reports a study published online in *JAMA Ophthalmology*.¹ Though air contaminants have previously been associated with adverse health effects like pneumonia and heart disease, few studies to date have examined their effects on the ocular surface.^{2,3,4}

Researchers in South Korea evaluated the ocular surface conditions of 16,824 participants in the fifth Korea National Health and Nutrition Examination Survey, asking if their eyes have ever felt dry or irritated and whether they had ever been clinically diagnosed with dry eye. An initial compilation indicated females between the ages of 60 and 69 who live in urban areas and who have university-level education or higher responded positively the most.

In the second part of the study, the team collected measurements on relative humidity, ozone, nitrogen dioxide and sulfur dioxide levels, as well as the concentration of ambient particulate matter (PM) measuring less than 10µm in diameter from 283 monitoring stations nationwide. Resulting data suggested decreased humidity levels and increased ozone levels correlated with the presentation of dry eye disease (DED). Nitrogen oxide levels were also somewhat associated with the condition, though the concentration of ambient PM was not, possibly due to reflex tearing flushing debris from the surface of the eye.

“Low humidity is a well-known

risk factor for dry eye disease,” the researchers wrote. “Our study expands the evidence of the association of low humidity with DED from indoor humidity to outdoor humidity. We suggest that outdoor humidity may also be important in DED.”

Previous research has also indicated ozone exposure in mice increases the production of inflammatory cytokines in tears and damage to corneal integrity and conjunctival goblet cells, they add. “To our knowledge, our study is the first epidemiologic investigation to observe that increased ozone levels are associated with DED,” the authors wrote.

The researchers conclude by cautioning that “these results are just associations and do not definitively indicate a cause-and-effect relationship between DED and outdoor air pollution.” Additional research is necessary to make that connection. **RCCL**

1. Hwang SH, Choi YH, Paik HJ, et al. Potential importance of ozone in the association between outdoor air pollution and dry eye disease in South Korea. *JAMA Ophthalmol*. 2016 Mar. [Epub ahead of print.]
2. Medina-Ramon M, Zanobetti A, Schwartz J. The effect of ozone and PM10 on hospital admissions for pneumonia and chronic obstructive pulmonary disease: a national multicity study. *Am J Epidemiol*. 2006;163(6):579-88.
3. Kunzli N, Medina S, Kaiser R, et al. Assessment of deaths attributable to air pollution. *Am J Epidemiol*. 2001; 153(11):1050-5.
4. Torricelli AA, Matsuda M, Novaes P, et al. Effects of ambient levels of traffic-derived air pollution on the ocular surface: analysis of symptoms, conjunctival goblet cell count and mucin GAC gene expression. *Environ Res*. 2014;131:59-63.

Advertiser Index

CooperVision	Cover 2
Alcon	Cover 3
Menicon	Cover 4



Big Gains for Big Lenses

Though sclerals are widely used today, is there any peril to their growing popularity?

The first contact lenses, produced by Adolf Fick nearly 130 years ago, were made from glass and fashioned in a scleral configuration.¹ After waxing and waning in popularity since then, scleral lenses have lately experienced a remarkable resurgence among contact lens practitioners, with their use broadening significantly to cover more and more challenging cases.¹⁻³

Three decades ago, only a few pioneers were touting the merits and benefits of scleral lenses. Now, the marvelous attributes of

resultant infection rate.

But, do we really have all the data necessary to proceed with vigor in fitting these lenses on non-diseased corneas, or should we proceed with caution? The jury, in my opinion, is still out. Though I rely heavily on these lens options for the corneas that need them most, many practitioners will argue that we still have thousands of patients and a few decades of observation left to judge. Thus, the current pressing question is: “Are we proceeding with some potential peril?”

Much has been written about

tential solution-related corneal toxicity.

Solutions to these problems and similar issues will only come with time.^{1,2} Specifically, what are the long-term effects of oxygen and tear exchange deprivation? What are the best care solutions for scleral lens use to minimize the dreaded disaster of corneal infection?

Scleral lenses are certainly not new, but definitely have been revitalized over the last few years. Many will argue that enough time has passed with clinical observation to deem them both safe and effective. Additional research to examine certain problem areas and greater vigilance for unexpected or unanticipated complications is essential for any device or drug. Ongoing surveillance and scientific study to enhance outcomes and expand clinical indications for this wonderful lens modality is crucial.

For the most part, however, we remain excited about this revisited lens modality for managing severe dryness and ocular surface disease and for restoring adequate vision to those who can't wear spectacles or other contact lenses.

What do you think? Do *you* still have reservations or are you confident these lenses carry no excessive risk or potential for morbidity? [RCCL](#)

“DO WE REALLY HAVE **ALL** THE DATA **NECESSARY** TO PROCEED WITH VIGOR IN FITTING THESE LENSES ON **NON-DISEASED** CORNEAS?”

these lenses, which can be worn by patients who are otherwise intolerant of contact lenses, are well accepted.^{1,3}

THROUGH THE LOOKING GLASS

This month's issue highlights scleral lenses—namely, their benefits and some of their complications. Pros to prescribing scleral lenses in a specialty practice are numerous and include increased comfort (due to their large diameter), crisper vision (due to their rigidity) and a seemingly low

the problems unique to using scleral lenses. Experts have raised concerns regarding their potential effects on intraocular pressure (i.e., episcleral venous pressure), premature endothelial morbidity including cell loss, and mechanical changes related to compression and edge impingement of the lens periphery on vital goblet cells and limbal stem cells. Smaller issues also remain, including conjunctival bunching and prolapse, epithelial “boggling,” lens debris adherence, misting and fogging, conjunctival blanching and po-

1. Walker MK, Bergmanson JP, Miller WL, et al. Complications and fitting challenges associated with scleral contact lenses: A review. *Cont Lens Anterior Eye*. Sept., 2015.

2. Caroline PJ, Andre MP: The unknowns of scleral lenses. *Contact Lens Spectrum*. 2013 Oct.

3. Caceres V. Taking a second look at scleral lenses. *EyeWorld*. 2009 Jun.

BERMUDA

Up to
18 CE
Credits
(COPE approval pending)

Image courtesy of Hamilton Princess & Beach Club, A Fairmont Managed Hotel

REVIEW OF OPTOMETRY®
EDUCATIONAL MEETINGS OF CLINICAL EXCELLENCE



JUNE 9-12, 2016

Superior Education with 3 Interactive Workshops

Fairmont Hamilton Princess

A Fairmont Managed Hotel

76 Pitts Bay Road | Hamilton, BERMUDA HM 08 | 441-295-3000

Discounted room rate **\$299-\$329/NIGHT**

Program Chair: **Paul Karpecki, OD**



SPEAKERS:



Marc Bloomenstein, OD Douglas Devries, OD Mark Dunbar, OD Benjamin Gaddie, OD Jack Schaeffer, OD

REGISTER NOW!

www.ReviewofOptometry.com/Bermuda2016

Or Email **Lois DiDomenico**: ReviewMeetings@Jobson.com | Call: 866-658-1772

REGISTRATION: 4 DAYS - 18 CE CREDITS* - \$595

Please see registration website for a list of sponsors and meeting agenda.

Administered by
Review of Optometry®





Sclerals: Easy as 1-2-3

Advice new fitters and veterans alike can benefit from.

Despite a wave of advances that have greatly improved our capabilities at disease diagnosis and management, patients continue to present to clinical practices with challenging corneal conditions. Practitioners are fortunate to have options like specialty soft contact lenses, small-diameter gas permeable lenses and hybrids to treat these cases—increasing the ranks of our contact lens patients while helping to improve corneal health for many.

In the spirit of this month's issue focusing on scleral lenses, *Practice Progress* will review a few key improvements to scleral lens options that exist today. This knowledge is critical for contact lens practitioners to be able to provide adequate vision to those who need our services the most. We have always felt that the best strategies involve identifying unmet needs in our patient base and then providing them the services they need.

The following three-step procedure is suitable for practitioners who are either neophyte scleral lens fitters or those who have begun to fit sclerals and wish to increase their confidence levels with this specialty design.

LOW-TECH LESSONS

There are a number of new designs available that help us more successfully fit scleral lenses. For example: practitioners can order toric scleral landing zones, and some manufacturers even make their diagnostic lenses with this technology. Additionally, a number

of scleral lenses have incorporated reverse geometry into their design to adequately clear the limbal corneal area while not excessively vaulting the central cornea. Multifocal scleral lenses are also available for presbyopic patients.

Regardless of these advancements, there are still three primary fitting rules to keep in mind:

1. *Make sure the scleral lens clears the central cornea.*

Simultaneously, we also need to keep in mind that the non-preserved saline used to fill the bowl of the lens has a resistance to oxygen permeability. As such, we want to balance the appropriate scleral lens clearance with avoiding the provision of excessive resistance to oxygen permeability. The generally accepted that the goal of central corneal clearance is between 100 μ m and 300 μ m.¹ Of course, in some of our more irregular cornea patients, it may be impossible to obtain clearance of this level across the entire cornea, but still—keep these clearance levels in mind when fitting scleral lenses, and attempt to meet this target as much as possible (*Figure 1*).

2. *Respect the limbal region of the cornea.* This is where the limbal stem cells of the cornea are located and, when fitting scleral lenses, this area must be cleared. When filling the bowl of the lens with non-preserved saline prior to installation, we can also add fluorescein to the bowl to help identify a level of clearance. Using the slit lamp to observe an optic cross section through any portion of the lens, practitioners can identify the level of clearance by examining the

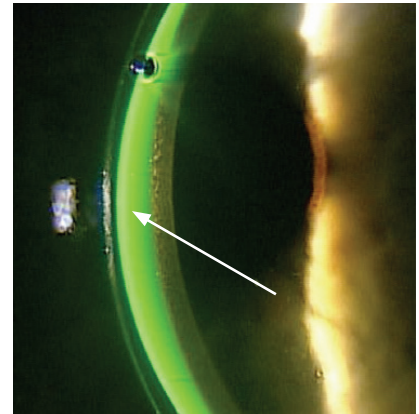


Fig. 1. Excessive clearance is noted. The contact lens thickness is about 350 μ m. The fluorescein seen between the lens and the cornea is about three times the thickness of the contact lens, which makes the lens clearance over 1,000 μ m.

presence of fluorescein between the lens and cornea. Additionally, looking at the lens using a wide beam can help determine whether fluorescein is visible at the limbal area of the cornea: if none is seen between the lens and the cornea in the limbal region, then the limbal zone of the lens should be steepened to provide additional clearance (*Figure 2*).

3. *Monitor the scleral landing zone.* Ideally, the scleral lens bearing area should mimic the curve of the sclera and overlying conjunctiva to lie flat on the tissue. When the landing zone profile is steeper than the sclera, impingement of the conjunctival tissue will occur, requiring that the lens be flattened; when the landing zone profile is flatter than the sclera, compression in the proximal portion of the scleral landing zone can occur, necessitating that the lens be steepened instead.

HIGH-TECH HELP

If faced with a more complex case, practitioners can also consider incorporating new advances into their fitting process. There have been numerous developments in scleral lens designs, and technology continues to support lens fit efforts. For example, one of the most widely used devices in the area of scleral lens fitting is optical coherence tomography (OCT), which gives us greater precision in determining sagittal height and the anatomical structure of the peripheral cornea and sclera for better lens edge design.

OCT technologies now exist that are capable of capturing a central 6mm radius circle in the center of the cornea. This can now be applied to scleral lenses that are on eye, allowing practitioners to visualize the clearance of the lens over the cornea. For years, we have had the ability to manually measure clearance: the examiner would identify the anterior surface

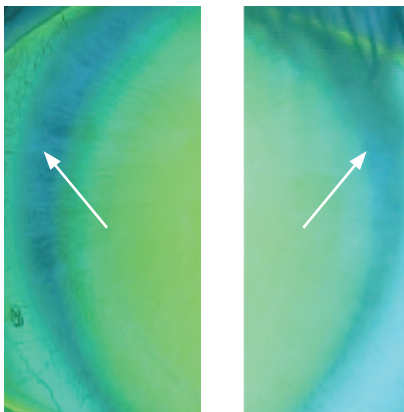


Fig. 2. This is a view of the nasal and temporal areas of a scleral lens on the eye. There is no fluorescein present in these areas, representing the lens compressing that area.

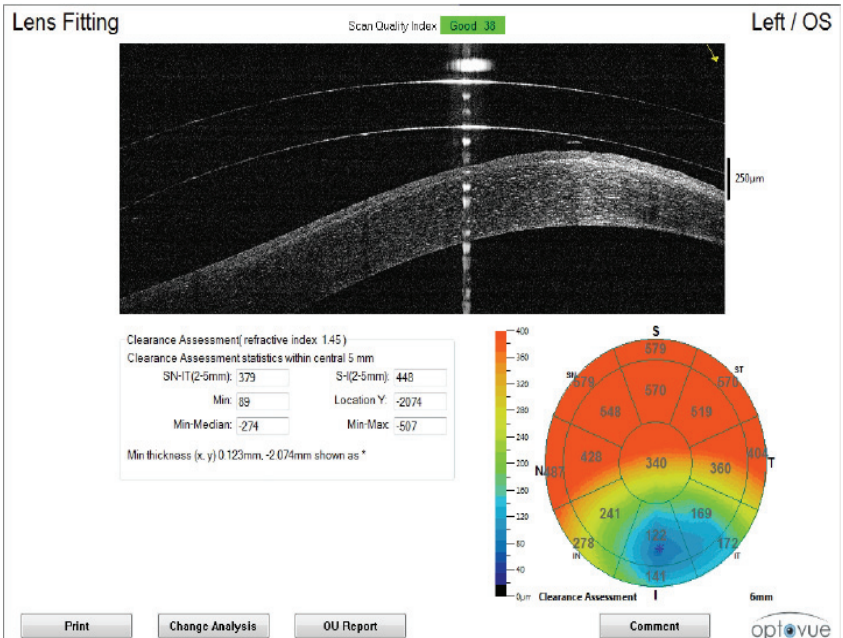


Fig. 3. This is a new software application that allows the clearance of the central 6mm to be seen in one report. The top of the report shows a vertical cross section through the lens and the cornea, while the bottom right side of the report shows the clearance map. Note that the clearance is significantly less in the inferior temporal aspect of the map.


of the cornea and posterior surface of the lens, then use software measurement tools to identify the clearance. Now, software on the OCT can provide a global 6mm diameter view of the clearance of the lens over the cornea in one scan (Figure 3). This provides the examiner with a clearer view of the variation in clearance throughout the central 6mm of the cornea under the lens.

Practitioners wishing for more experience with the fitting process outside of the clinic may want to attend a workshop or find a mentor. Live scleral fitting workshops can provide significant experience and insights from experts; often attendees are given the opportunity to fit patients with help from

some of the best in the industry. It is also important to have someone available for consultation and mentorship as you continue to gain fitting experience. Many GP lens manufacturers have phenomenal consultation departments to provide help during the fitting process.

Scleral lenses have offered a number of patients clear, comfortable vision that they would otherwise not be able to attain. Taking into account these three strategies will help practitioners set themselves up for success when fitting this lens modality. **RECL**

1. van der Worp E. A Guide to Scleral Lens Fitting [monograph online]. Forest Grove, OR: Pacific University; 2010. Available at: commons.pacificu.edu/mono/4/.



Happy Landings

Incorporating toricity into scleral lens designs may improve your fitting success.

Fitting scleral lenses is a fairly straightforward task: simply make sure the lens adequately vaults the cornea and limbal region to land on the bulbar conjunctiva. Achieving this, however, is sometimes more difficult in practice.

Most scleral lens designs consist of three primary zones: optical, transition and landing.¹ The optical and transition zones provide sagittal depth to the lens for proper vault height, while the third zone—the landing zone—rests gently on the bulbar conjunctiva. This area is also commonly known as the haptics or peripheral curves. Proper alignment of this zone with the sclera is a critical component of a successful scleral lens fit, as any degree of misalignment can

negatively impact both comfort and vision. As such, the incorporation of back surface toricity into the landing zone could improve the lens-to-sclera fitting relationship.

UNDERSTANDING SCLERAL SHAPE

Research on the scleral shape of normal eyes has indicated most sclerae to be at least somewhat asymmetric or toric in nature. In the average patient, the nasal sclera is characterized by a flatter curvature, while the temporal sclera typically exhibits steeper curvature.¹ The nasal quadrant is also higher in elevation compared with the temporal quadrant.² This may explain why scleral lenses often decenter inferotemporally, though lid tension and gravity may also contribute.

Common estimates suggest 25 μ m of corneal height differential is equivalent to approximately 1.0D of corneal toricity.³ Extending out to a 15.0mm chord, a similar study found the scleral height difference can range from approximately 50 μ m to more than 500 μ m.³ Though this study did not correlate scleral height difference to scleral toricity in diopters, other data suggests the average scleral toricity is approximately 4.0D.²

IMPROVING PERIPHERAL FIT

Recent technological innovations—including three-dimensional imaging and ocular surface impression molding—allow for more accurate empirical fitting. Despite these options, however, the majority of scleral lenses are still fit diagnostically. As such, placement of the diagnostic lens on the eye can be crucial in determining whether the addition of back surface toricity is beneficial.

Excessive compression of the bulbar conjunctiva via an ill-fitting lens can restrict blood flow, causing blanching of the conjunctival vasculature. A circumferential blanching pattern typically indicates the haptics are too steep, requiring modifications to the entire peripheral curve system to adjust the lens fit. Localized blanching in the absence of conjunctival anomalies like pingueculae can be attributed to scleral toricity. The incorporation of back surface toricity may help alleviate localized

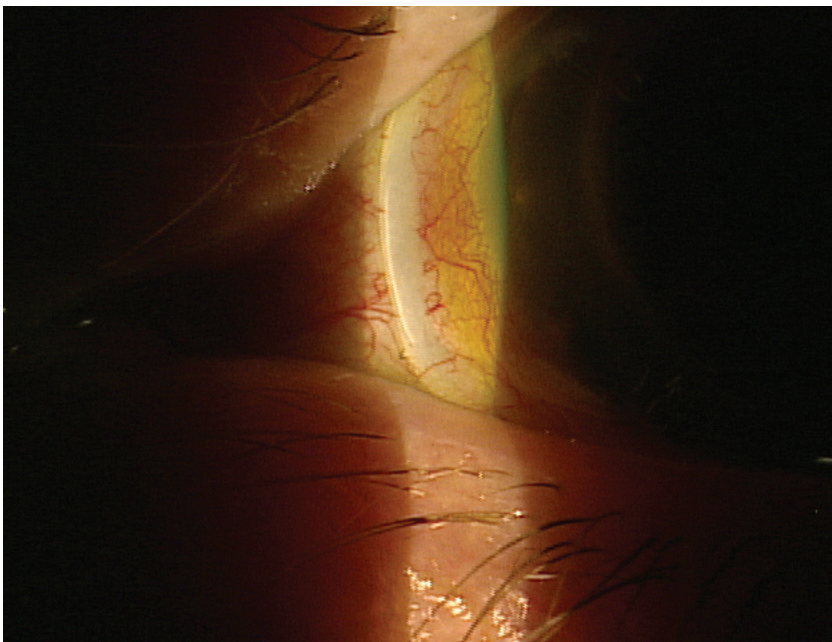

Fig. 1. Tight peripheral curves can cause localized blanching.

pressure by flattening the haptics in the flatter meridian.

When localized edge lift is an issue, steeper toric haptics may be a solution. Excessive edge lift can lead to bubbles and accumulation of debris underneath a lens, as well as increased lens awareness. If these characteristics are suspected but not readily apparent, instilling sodium fluorescein and watching for uptake underneath the lens while on the eye can reveal these issues.

Back surface toric haptics are typically designed with rotational stability in mind. Research has shown it takes approximately six seconds for back surface toric scleral lenses to return to their original position following manual on-eye rotation.⁴ As such, this stability allows for even distribution of weight across the bulbar conjunctiva, resulting in more comfort and a longer wearing time.^{4,5}

WHAT ABOUT VISION?

The fluid reservoir underneath a scleral lens neutralizes both normal and irregular corneal astigmatism. If a spherocylindrical overrefraction yields better vision, performing keratometry readings over the lens can be used to help identify any indication of internal astigmatism or lens flexure. Additionally, if the over-keratometry readings are astigmatic, the lens is either decentered or flexing on the eye.

Lens flexure commonly results from the torsional effect of the lens on a toric sclera; as such, the first step often taken to resolving

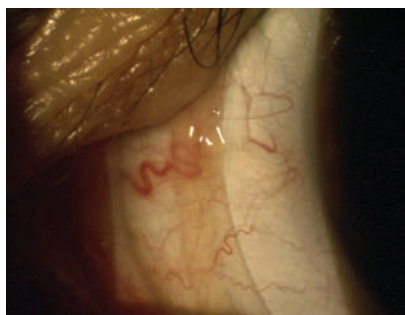

Fig. 2. Early conjunctival hypertrophy secondary to scleral lens impingement.

this issue is to increase the center thickness of the lens.⁶ Though this may ultimately stiffen the lens, it also reduces oxygen transmission and increases the weight of the lens. The inclusion of back surface toric haptics may help reduce this torsional effect by improving lens alignment and centration. Furthermore, reducing the overall diameter may also lessen flexure, since the toricity of the sclera is higher at points further away from the limbus.⁷

In the case of internal astigmatism resulting from the posterior cornea or crystalline lens, front surface toric power can be added to the lens via double slab-off ballasting.¹ Much like soft toric lenses, it is critical for front surface toric sclerals to be rotationally stable. If the lens does rotate, however, the LARS principle (i.e., left: add, right: subtract) that applies to soft lenses can be used to quantify scleral lenses as well. Back surface toric haptics can be used in conjunction with front surface toric power for additional stability and centration.

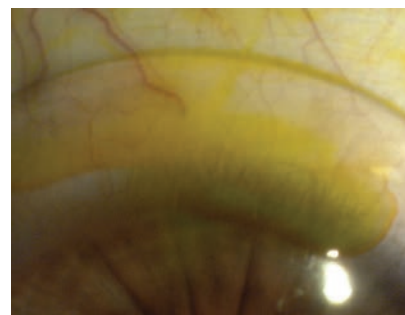


Fig. 3. Instillation of fluorescein over the lens helps reveal mild edge lift in the superior quadrant.

It's clear that the growing popularity of scleral lenses is leading to the proliferation of new and better lens designs. Since recent research has indicated the sclera to be asymmetric, designs that incorporate toric haptics into their diagnostic sets may be increasingly valuable. Familiarizing yourself with both back surface toric haptics and front surface toric power will help improve your scleral lens fitting success. [rcccl](#)

1. van der Worp E. A Guide to Scleral Lens Fitting, Version 2.0 [monograph online]. Forest Grove, OR: Pacific University; 2015. Available from: commons.pacificu.edu/mono/10/.

2. Ritzmann M, Caroline P, Walker M, et al. Understanding scleral shape with the Eaglet Eye Surface Profiler. Scientific Poster presented at the Global Specialty Lens Symposium. Las Vegas. January 2015.

3. Kinoshita B, Morrison S, Caroline P, et al. Corneal toricity and scleral asymmetry...are they related? Scientific Poster presented at the Global Specialty Lens Symposium. Las Vegas. 2016.

4. Visser ES, Visser R, van Lier HJ. Advantages of toric scleral lenses. *Optom Vis Sci* 2006;83:233-236.

5. Visser ES, Visser R, van Lier HJ, Otten HM. Modern scleral lenses. Part II: patient satisfaction. *Eye Contact Lens* 2007;33:21Y5.

6. Michaud L. Beyond irregular: scleral lenses for everyday use. *Contact Lens Spectrum*. 2015. June; 30:30-32,34,36

7. Ritzmann M, Morrison S, Caroline P, et al. Scleral shape and asymmetry as measured by OCT in 78 normal eyes. Scientific Poster presented at the Global Specialty Lens Symposium. Las Vegas. January 2016.

Scleral Lens Fitting:

ONCE RARE,

NOW ROUTINE?

Many practitioners have seen patients who benefit from scleral lens wear, such as those with irregular corneal shapes, ocular surface conditions like severe dry eye or non-healing corneal erosion, or following exposure to chemicals.¹ Few adverse events have been widely linked to the use of these rigid lenses, making them arguably one of the safest options in contact lens practice. As such, most may consider them a valid possibility for patients with “regular” corneas that demonstrate some measure of refractive error but no other obvious abnormalities; however, lingering questions prevent widespread adoption.

First and foremost, there is a certain agreed-upon approach taken when fitting irregular cornea patients with sclerals—but can we use the same principles on those with normal corneas? Are these lenses safe over the long-term as a means to correct refractive error? How does their performance measure up against existing lenses for normal corneal wear? This article will offer an evidence-based approach to answer these questions.

REVIEWING THE RECORDS

The earliest published article on scleral lenses still present in the literature today dates to 1946.⁴ Since then, approximately 219

published works have been added, each serving to increase practitioner knowledge on scleral lens wear. Among these, six publications cover adverse events such as acute red eye, microbial keratitis and fitting complications after surgery. Microbial keratitis in particular was linked to extended and/or noncompliant wear and the presentation of severe ocular surface disease.^{9,24} The safety of sclerals was assessed in eight papers, none of which reported significant negative impacts from wear. Of the 219 papers, 133—including 14 retrospective studies—described the successful placement of scleral lenses on irregular corneas to improve the ocular surface.

Professional publications’ coverage also offers a way to track reports of complications related to scleral lens wear. Few articles have identified significant negative impacts, and none have been published since modern gas-permeable scleral lenses became more widely available. Based on this survey of scientific and professional literature, it can be said that scleral lenses are a relatively safe mode of contact lens wear for the clinical population who requires specialty lenses. A definitive statement on the safety of these lenses for those with normal corneas cannot be made, however, since no long-term, randomized, masked, controlled studies have been conducted on this topic.

MAKING SPACE FOR SCLERALS

Considering whether patients with normal corneas should be fit with scleral lenses to correct refractive error prompts a series of questions. First, who are candidates, and what are the clinical indications for lens wear? Additionally, which mode of lens wear should be prescribed, and how can these lenses differ from other options? Once these questions are answered, an additional one to consider is this: Can the same positive and safe outcome observed with other clinical populations be duplicated in the case of normal cornea patients? Is the risk-to-benefit ratio the same? Let’s discuss.

The clinical population in question is characterized by a prolate cornea that is—in theory—less difficult to vault than an irregular corneal surface. This is because a regular cornea is more uniform in shape, and therefore more predictable to fit. Scleral lenses placed on these corneas should correct existing refractive error, but do not need to restore the regularity

ABOUT THE AUTHOR



Dr. Michaud graduated from École d’optométrie de l’Université de Montréal in 1986, where he also obtained his master’s degree in physiological optics. He is a professor and chief of the contact lens department at the Université de Montréal, as well as a fellow of the AAO, BCLA and SCLS.

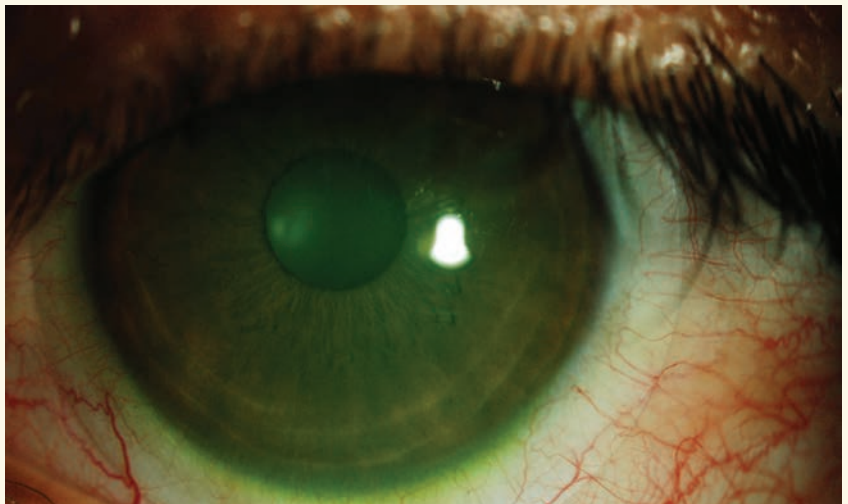
As these specialty lenses continue to gain in popularity, should they be adopted for wear in uncomplicated cases as well?

By **Langis Michaud, OD**

of the ocular surface as they do if covering an irregular or compromised eye. However, in the absence of this traditional indication, one could argue it in essence removes the need for a scleral lens entirely and a more simple, corneal-fit lens may suffice.

In light of this, it can be argued scleral lenses are most likely to be considered for improvement of visual acuity and comfort based on two frequent issues reported by symptomatic wearers.¹⁹ Because their large diameter means a reduced lens-to-lid interaction and because they vault the most sensitive part of the human body—the cornea—without touching it, both lens awareness and mechanical stress are highly reduced in comparison with other lens options. Scleral lenses additionally do not dehydrate as soft lenses do and leave room for a fluid compartment, which contributed to the maintenance of a more properly hydrated ocular surface. This may help reduce symptoms of contact lens induced dry eye.¹

Athletes and those faced with certain occupational hazards may also benefit from scleral lens wear. Once settled on the ocular surface, scleral lenses act as a shield against infiltration of dust and particles, particularly in dry and challenging environments. In some cases, this shielding aspect may also protect the eye from impact that can result in significant damage (off-label



A mini-scleral contact lens. Larger scleral lenses vault the cornea and land further out past the limbus.

usage). The same rationale applies to patients with allergies for whom sclerals prevent encroachment of pollen and other allergens onto the ocular surface. Overall, however, the most notable feature of scleral lenses is that they do not move once fitted to the eye—a key feature for reducing higher-order aberrations or controlling more advanced astigmatism or presbyopia.

ASTIGMATISM CORRECTION

A simple, spherically designed scleral lens can compensate for up to 3.5D of corneal cylinder in an astigmatic patient. This exceeds the range provided by smaller, gas permeable lenses. Additionally, though most soft toric lenses include a 4.5mm to 5mm effective optic zone, this typically shrinks as toricity increases. Sclerals, in

Release Date: April 2016

Expiration Date: April 1, 2019

Goal Statement: This course covers current uses for scleral lenses and discusses their potential for coverage of the normal cornea.

Faculty/Editorial Board: Langis Michaud, OD

Credit Statement: COPE approval for 1 hour of continuing education credit is pending for this course. Check with your state licensing board to see if this counts toward your CE requirements for relicensure.

Joint-Sponsorship Statement: This continuing education course is joint-sponsored by the Pennsylvania College of Optometry.

Disclosure Statement: Dr. Michaud has received honoraria from Valeant, CooperVision, Blanchard Labs and Allergan; is a consultant to Blanchard Labs; and has received grant/research support from Alcon, Johnson & Johnson Vision Care and Genzyme Canada. He is also on the speakers' bureau of the American Academy of Optometry and is an employee of the Université de Montréal.



SCLERAL LENS FITTING: ONCE RARE, NOW ROUTINE?

contrast, feature an 8mm to 9mm optic zone to enhance the field of vision and limit interaction with the pupil diameter and, consequently, the perception of high order aberrations. And as previously stated, scleral lenses do not rotate or dehydrate, keeping the patient's quality of vision optimal for the entire period of time they're worn.

Once the lens is placed on the eye, it's common to assess the amount of residual astigmatism. One source for such findings is the presence of lenticular astigmatism. Patients with this type of astigmatism inherently compensate, in whole or in part, for corneal cylindrical power; fitting them with a scleral lens, however, leads to the fluid layer compensating instead for the toric corneal surface, thus revealing the lenticular astigmatism. The addition of a front-toric design to the scleral lenses can help adjust the visual correction for such a patient.

Residual astigmatism can also come from lens flexure.² This may be a misleading concept to some: the supposed flexure of the lens is a process that is assessed using keratometry or topography over the scleral lens while the eye is open. Flexure cannot happen, however, if the eye does not blink; as such, what is actually measured here using overkeratometry is lens distortion originating primarily from the misalignment of the lens peripheries on the toric conjunctival surface. When this occurs, increasing the lens's thickness—a commonly relied-upon solution—is actually detrimental, as it can penalize oxygen delivery to the cornea and make the lens heavier and easier to decenter. Instead, resolve the issue using a lens with toric haptics to achieve a better lens/conjunctival alignment in all


quadrants. To the contrary, better aligned lenses can certainly be manufactured thinner, which is healthier for the cornea over the long term.

If the scleral lens does decenter or is placed in the presence of a highly irregular cornea, however, the fluid layer between it and the contact lens can lose its symmetrical shape and become prismatic. This is the primary cause of induced residual astigmatism.¹⁷ This decentration can also increase lens bearing on the superior quadrant of the cornea; as such, it can be resolved by reducing the lens's diameter or adding toric peripheral curves to improve centration.

If neither of these solutions can be applied, directing the laboratory to increase the optic zone diameter while keeping the sag value the same is another option. Keep in mind when doing this, however, that other parameters will change accordingly. Of course, whatever method you as a practitioner use, the end goal should remain the same: to increase uniformity of the tear fluid layer and keep the lens centered on the surface of the eye. At last, front-toric designs will resolve this issue.

PRESBYOPIA CORRECTION

Patients entering the presbyopia category this decade number more than ever before, which is why many lens manufacturers are developing new designs to meet their visual needs.³ Several soft lens modalities have been launched in the last few years, most notably in the daily disposable lens market. Despite these new offerings, however, contact lens dropout remains remarkably high in the presbyopic population. This is attributed to the somewhat unstable tear film most aging patients exhibit in



Mini-scleral lenses can be fit with less tear fluid to optimize oxygen delivery to the cornea.

comparison with their younger counterparts, and can thus be considered to have marginal dry eye. Many presbyopic patients also display significant refractive astigmatism that, if not adequately corrected by optic means, can lead to fluctuating and distorted visual acuity at distance and up close. Unfortunately, few new toric multifocal contact lenses to date offer a positive outcome for presbyopes with astigmatism, especially in disposable modalities.

Scleral contact lenses, however, may be an option. The fluid layer underneath the lens keeps the ocular surface moist and hydrated, stabilizing the tear film. Furthermore, these lenses compensate for some amount of refractive astigmatism; additionally, the larger optic zone present in the traditional scleral lens design also means room for larger add power zones with unaffected distance vision. These elements mean lens designers have an easier time manufacturing functional multifocal

contact lenses. Furthermore, sclerals—especially smaller, mini-sclerals that measure less than 15mm in diameter—remain better aligned with a patient's visual axis.¹⁶

FITTING THE NORMAL CORNEA

Successful adaptation of scleral lenses for patients with normal corneas requires more than just the recognition of their optical benefits for current wearers, however. For this broad population to accept sclerals as a modality, the lenses must be made easier to care for and more convenient to wear. Improper lens handling still represents the biggest concern for current wearers and is one of the primary reasons for fitting failures. Unsurprisingly, smaller scleral lenses (i.e., 15mm or less) are better for prolate patients as the size of these lenses is similar to that of soft torics. Sclerals of a larger diameter (i.e., 16.5mm to 17mm) may be more intimidating and less user-friendly compared with their miniature counterparts. The same rationale applies for lens care; use of hydrogen peroxide is one method to improve wear and care compliance.

Are scleral lenses a safe alternative to soft lens modalities, then? Currently, there are no longitudinal studies establishing the safety of scleral lens wear for normal cornea patients. As such, questions remain unanswered in this area, which is why the risk-to-benefit ratio remains under debate at this time. Scleral lenses and the fluid layer under their surface act as a reservoir to keep the ocular surface moist, and it has been demonstrated that the ideal combination of lens and fluid layer thicknesses are 250 μ m and 200 μ m, respectively, in compliance

with the Harvitt-Bonnano criteria for alleviating corneal hypoxia.¹³ Lenses fitted with higher clearance and/or produced with increased thickness are known to be associated with central corneal edema sustained during all wearing hours. Of course, this model has been challenged clinically since its conception because many practitioners have reported no obvious signs that chronic corneal hypoxia had occurred. Additionally, almost no reports of corneal hazing or the presence of microcysts or neovascularization have been collected, and it has also been argued that since scleral lenses have been successfully used to treat ocular surface disease, it would be impossible for hypoxia to be involved.

Clinical studies have since been published confirming that scleral lens wear is associated with induced corneal swelling varying from 2% to 4% in normal corneas, keratoconus and—especially—in cases where the endothelial cell layer is compromised.^{6,12,14,15,18,20} One in vivo study also indicated reduced oxygen diffusion to the cornea correlates with less tear fluid layer thickness.¹⁰ In fact, large scleral lenses with a 400 μ m fluid layer thickness delivered 30% less oxygen to the cornea than a similarly sized lens fitted with a 200 μ m fluid layer thickness.¹⁰ From other studies, we also know that tear exchange is limited once the lens settles at 0.2% per minute.²² This means it takes more than eight hours to replenish the bowl under a scleral lens.

Tear mixing is another factor that should be accounted for, as the tear layer is a dynamic, constantly changing fluid environment. Like water in a washing machine, it was suggested that the

deeper layer of fluid periodically makes contact with the underside of the scleral lens to replenish its oxygen levels. To the contrary, data has suggested that that tear mixing may be limited in the case of lenses fitted with more or less than the optimal level of clearance, which has been established as 200 μ m.²³ Tear exchange may also be inhibited when clearance is particularly excessive. Consequently, the addition of fresh tears and tear mixing may only marginally assist with maintaining the cornea's oxygen supply once the lens settles; as such, this may be a decisive factor in determining whether patients with otherwise healthy, normal corneas should wear scleral lenses.

REMODELING

Considering these factors, it can be argued that the theoretical model for oxygen diffusion should change as follows: Increased lens thickness (i.e., more than 250 μ m) and increased fluid layer thickness or clearance (i.e., more than 200 μ m) triggers corneal hypoxia. This affects the central cornea because the clearance over the limbus never exceeds the critical threshold mentioned above. This hypoxia can be transient in nature if fluid loss in the first hours reduces clearance to below the critical threshold of 200 μ m. As such, this is why hypoxia is not always clinically visible.

Corneal edema manifests when hypoxia reaches 5% to 8%, with clinical signs of the condition correlating with the amount of swelling.⁸ Loss of corneal transparency occurs when the edema reaches 15%.⁷ Neovascularization occurs when hypoxia turns chronic and begins to affect the limbus. Blebs are transient and not easily discernible, except in the



SCLERAL LENS FITTING: ONCE RARE, NOW ROUTINE?

minutes following awakening.²⁴ Additionally, epithelial microcysts are associated with overnight wear of less oxygen-permeable soft lenses. Hypoxia has never been reported in patients who only wear lenses during the day only, even if these lenses' oxygen permeability was below the Holden-Mertz criteria.¹¹ Overnight wear of scleral lenses is not recommended, as it is connected with high levels of corneal hypoxia and the potential for microbial keratitis.²⁵

CLINICAL IMPLICATIONS

Many clinical studies on pachymetry have proven that hypoxia occurs. More convincingly, however, equivalent oxygen percentage (EOP) is reduced when the clearance under scleral lenses is higher. Some authors consider 3% edema to be clinically insignificant comparable to the physiological edema seen upon awakening. They also consider this level to be similar to that encountered when patients were fit with low oxygen-permeable hydrogel lenses in the 1980s. These comparisons are misleading, however. Physiological edema never lasts for more than an hour and, as such, the cornea is never exposed to chronic hypoxic stress during waking hours. As for the aforementioned hydrogel lenses, at that time in history no other soft lens options were available. This pushed the industry to develop higher oxygen-permeable materials.

Epithelial bogging, tear reservoir debris accumulation, conjunctival prolapse and the need to design complicated toric peripheral curves or haptics are just a few of the day-to-day challenges that those who fit scleral lenses face when using larger-diameter lenses.⁵ These occurrences are considered

benign at present. Again, there is no longitudinal study proving the presence or absence of negative impacts from these elements on ocular health or surface structure over time. Additionally, these complications are typically unseen when scleral lenses are fitted with a diameter of 15mm or less, as of this size tend to generate less mechanical impact on the conjunctiva and are fitted with lower clearance over the limbus. It can be said this represents an important element in reducing the pollution of the tear fluid reservoir with lipids and mucin deposits seen when scleral lenses impact the conjunctival cells more significantly.

In summary, there are many clinical indications to consider when fitting scleral lenses on patients with 'normal' corneas. Though the benefits of these lenses are numerous, practitioners must first evaluate the risk/benefit ratio of wear. In particular, long-term safety should be explored. Additionally, the lower rate of complications associated with smaller sclerals may also influence the practitioner's selection. Lastly, in order to consider fitting normal cornea patients with scleral lenses, an easier and more convenient approach to the fitting process much be developed. For all of these reasons, mini-scleral lenses, with their limited thickness and clearance, may be the best and safest alternative at present; however, further research and consideration is necessary. **RCCL**

1. Alipour F, Kheirkhah A, Jabarvand Behrouz M. Use of mini scleral contact lenses in moderate to severe dry eye. *Cont Lens Anterior Eye*. 2012 Dec;35(6):272-6.
2. Barnett, M. 10 Tips for Smarter Scleral Lens Fitting. *Review of Cornea and Contact Lenses*. Oct. 2012.
3. Barnett M. Multifocal scleral lenses. *Contact Lens Spectrum*, Dec. 2015.
4. Carlson JJ, Silbert M. The technique of fitting scleraform contact lenses; determination of the

shape of the human eye by insertion of spherical contact lenses. *Opt J Rev Optom*. 1946 Oct;83(20):34-6.

5. Caroline P. Managing corneal-scleral lenses and scleral lenses complications. *Global Specialty Lens Symposium*, 2014.
6. Compañ V, Oliveira C, Aguilera-Arzo M, et al. Oxygen diffusion and edema with modern scleral rigid gas permeable contact lenses. *Invest Ophthalmol Vis Sci*. 2014;55:6421-6429.
7. Efron N. Contact lens-induced changes in the anterior eye as observed in vivo with the confocal microscope. *Prog Retin Eye Res*. 2007 Jul;26(4):398-436.
8. Efron N, Ed. *Stromal edema. Contact Lens Complications*. 2nd ed. Edinburgh: Butterworth-Heinemann, 2004:132-140.
9. Fernandes M, Sharma S. Polymicrobial and microsporidial keratitis in a patient using Boston scleral contact lens for Sjogren's syndrome and ocular cicatricial pemphigoid. *Cont Lens Ant Eye*. 2013 Apr;36(2):95-7.
10. Giasson C.J, Morency J, Michaud L. Measuring oxygen levels under scleral lenses of different clearances. *Investigative Ophthalmology & Visual Science*. June 2015;56:6074.
11. Holden BA, Sweeney DF. The significance of the microcyst response: a review. *Optom Vis Sci*. 1991 Sep;68(9):703-7.
12. Lau J, Reeder R. Localized corneal graft rejection from scleral lens wear with excessive limbal clearance. Poster presented at the GCLS meeting, Las Vegas, 2015.
13. Michaud L, van der Worp E, Brazeau D, et al. Predicting estimates of oxygen transmissibility for scleral lenses. *Cont Lens Anterior Eye*. 2012 Dec;35(6):266-71.
14. Miller WL, Vance K, Johnson L, Bergmanson JP. Scleral contact lens effect on central and peripheral corneal thickness. *Investigative Ophthalmology & Visual Science*. June 2015;56:6103.
15. NG LH, Wang Z, Chan CY, Yueng WN. Corneal physiological changes after short-term scleral lens wear. Paper presented at BCLA meeting, Liverpool, UK, 2015.
16. Plainis S, Atchison DA, Charman WN. Power profiles of multifocal contact lenses and their interpretation. *Optom Vis Sci*. 2013 Oct;90(10):1066-77.
17. Ramdass S, Rosen C, Norman C, Buckingham R. Clinical analysis of scleral lenses on normal corneas. Poster presented at Global Specialty Lens Symposium, 2016.
18. Riff B, Lasby A, Pack L. Corneal decompensation after scleral lens wear in a compromised cornea. Poster presented at the GCLS meeting, Las Vegas, 2015.
19. Rumpakis J. New data on contact lens dropouts: An international perspective. *Rev Optom*. 2010 Jan;147(1):37-42.
20. Soeters N, Visser ES, Imhof SM, Tahzib NG. Scleral lens influence on corneal curvature and pachymetry in keratoconus patients. *Cont Lens Anterior Eye*. 2015 Aug;38(4):294-7.
21. Van der Worp E, Bornman D, Ferreira DL, et al. Modern scleral contact lenses: A review. *Cont Lens Anterior Eye*. 2014 Aug;37(4):240-50.
22. Vance KD, Miller W, Bergmanson J. Measurement of tear flow in scleral contact lens wearers. Poster presented at the American Academy of Optometry meeting, 2015.
23. Yuan T, Tan B, May A, et al. Lin M. Peripheral tear mixing under scleral lenses fitted with various clearances. Paper presented at the AAO Meeting, 2015.
24. Holden BA, Williams L, Zantos SG. The etiology of transient endothelial changes in the human cornea. *Invest Ophthalmol Vis Sci*. 1985 Oct;26(10):1354-9.
25. Zimmerman AB, Marks A. Microbial keratitis secondary to unintended poor compliance with scleral gas-permeable contact lenses. *Eye Contact Lens* 2014, Jan;40(1):e1-4.

CE TEST ~ APRIL 2016

1. Scleral lenses' diameter, vault and hydration characteristics mean what is reduced in comparison with other lens types?
 - a. Lens awareness and mechanical stress.
 - b. Ocular surface dryness.
 - c. Keratitis risk.
 - d. A and B.

2. Which complication has been linked to extended or noncompliant wear of scleral lenses?
 - a. Scleral melt.
 - b. Microbial keratitis.
 - c. Epithelial basement membrane dystrophy.
 - d. Dry eye.

3. Residual astigmatism can result from which of the following?
 - a. Lenticular astigmatism.
 - b. Inadquate lens vault.
 - c. Lens flexure.
 - d. A and C.

4. Which of the following is true with regards to scleral lenses and presbyopic correction?
 - a. The fluid layer underneath helps stabilize the tear film.
 - b. Sclerals reshape the eye to help prevent progression of myopia.
 - c. Scleral designs offer a more limited range of correction than other modalities.
 - d. Scleral lenses are contraindicated in patients over age 50.

5. Scleral contact lens wear is associated with induced corneal swelling varying from what to what?
 - a. 2% to 4%.
 - b. 1% to 3%.
 - c. 5% to 7%.
 - d. 8% to 10%.

6. A simple, spherically designed scleral lens can compensate for up to how many diopters of corneal cylinder in an astigmatic patient?
 - a. 1D.
 - b. 3.5D.
 - c. 4.5D.
 - d. 3D.

7. What is considered to be the ideal combination of lens thickness/tear fluid layer thickness to alleviate hypoxic stress in the central cornea?
 - a. 250µm/300µm.
 - b. 250µm/200µm.
 - c. 200µm/300µm.
 - d. 200µm/400µm.

8. Loss of corneal transparency occurs at what level of corneal edema?
 - a. 3%.
 - b. 8%.
 - c. 10%.
 - d. 15%.

9. Which of the following is not considered a day-to-day challenge associated with fitting large-diameter scleral lenses?
 - a. Corneal ulceration.
 - b. Epithelial bogging.
 - c. Conjunctival prolapse.
 - d. Tear reservoir debris accumulation.

10. Which of the following is true with regards to mini-scleral lens wear?
 - a. Mini-scleral lenses are associated with a higher rate of complications.
 - b. Mini-scleral lenses are less stable and more difficult to handle.
 - c. Mini-sclerals may be the safest scleral lens alternative at present to fit on normal corneas.
 - d. Mini-scleral lenses are manufactured with higher thicknesses to increase dimensional stability.

EXAMINATION ANSWER SHEET

Scleral Lens Fitting: Once Rare, Now Routine?

Valid for credit through April 1, 2019

Online: This exam can also be taken online at www.reviewofcontactlenses.com. Upon passing the exam, you can view your results immediately. You can also view your test history at any time from the website.

Directions: Select one answer for each question in the exam and completely darken the appropriate circle. A minimum score of 70% is required to earn credit.

Mail to: Jobson Optometric CE, Canal Street Station, PO Box 488 New York, NY 10013

Payment: Remit \$20 with this exam. Make check payable to Jobson Medical Information LLC.

Credit: COPE approval for 1 hour of CE credit is pending for this course.

Sponsorship: Joint-sponsored by the Pennsylvania College of Optometry

Processing: There is an eight-to-10 week processing time for this exam.

Answers to CE exam:

- | | |
|----------------------------------------------------------------------------------------------------|-----------------------------------------------------------------------------------------------------|
| 1. <input type="radio"/> A <input type="radio"/> B <input type="radio"/> C <input type="radio"/> D | 6. <input type="radio"/> A <input type="radio"/> B <input type="radio"/> C <input type="radio"/> D |
| 2. <input type="radio"/> A <input type="radio"/> B <input type="radio"/> C <input type="radio"/> D | 7. <input type="radio"/> A <input type="radio"/> B <input type="radio"/> C <input type="radio"/> D |
| 3. <input type="radio"/> A <input type="radio"/> B <input type="radio"/> C <input type="radio"/> D | 8. <input type="radio"/> A <input type="radio"/> B <input type="radio"/> C <input type="radio"/> D |
| 4. <input type="radio"/> A <input type="radio"/> B <input type="radio"/> C <input type="radio"/> D | 9. <input type="radio"/> A <input type="radio"/> B <input type="radio"/> C <input type="radio"/> D |
| 5. <input type="radio"/> A <input type="radio"/> B <input type="radio"/> C <input type="radio"/> D | 10. <input type="radio"/> A <input type="radio"/> B <input type="radio"/> C <input type="radio"/> D |

Evaluation questions (1 = Excellent, 2 = Very Good, 3 = Good, 4 = Fair, 5 = Poor)

Rate the effectiveness of how well the activity:

11. Met the goal statement: ① ② ③ ④ ⑤
12. Related to your practice needs: ① ② ③ ④ ⑤
13. Will help improve patient care: ① ② ③ ④ ⑤
14. Avoided commercial bias/influence: ① ② ③ ④ ⑤
15. How do you rate the overall quality of the material? ① ② ③ ④ ⑤
16. Your knowledge of the subject increased: Greatly Somewhat Little
17. The difficulty of the course was: Complex Appropriate Basic
18. How long did it take to complete this course? _____
19. Comments on this course: _____

20. Suggested topics for future CE articles: _____

Identifying information (please print clearly):

First Name

Last Name

Email

The following is your: Home Address Business Address

Business Name

Address

City State

ZIP

Telephone # - -

Fax # - -

By submitting this answer sheet, I certify that I have read the lesson in its entirety and completed the self-assessment exam personally based on the material presented. I have not obtained the answers to this exam by fraudulent or improper means.

Signature: _____ Date: _____

Please retain a copy for your records.

LESSON 112574, RO-RCCL-0416

SCLERAL LENSES IN ACTION

Solving Problems WITH Specialty Lenses

These lenses are good for more than just the irregular cornea. Five cases illustrate their potential.

By Marsha Malooley, OD, and Jeffrey Sonsino, OD

You can hardly read an optometric journal or attend a continuing education event today without hearing some mention of scleral contact lenses. As their popularity has continued to increase, so too have their clinical applications: once indicated only for unique cases, scleral lenses are now used in the treatment of ocular surface disease, post-surgical visual rehabilitation and correction of refractive error that is otherwise refractory to conventional approaches. This article will discuss several clinical cases that exemplify these lenses' benefits in practice.

1. FILAMENTARY KERATITIS

A 26-year-old white male presented for follow-up one week after undergoing collagen cross-linking OD and a contact lens fitting OS. During the appointment, the patient stated his left eye was sensitive to light and had felt irritated over the last four days. His history was significant for advanced keratoconus OS, with no signs of the disease OD. Penetrating keratoplasty had been performed OS three months prior to the visit. The patient also had a history of corneal gas permeable (GP) lens wear but reported discontinuation, as he had found the lenses to be irritating. Additionally,

he reported trying scleral lenses previously, but had discontinued them as well, having considered them to be cumbersome.

The patient's uncorrected visual acuity was 20/25 OD and 20/200 OS, improving to 20/60 OS with pinhole. A biomicroscopy performed OS revealed the presence of a clear graft with intact running suture. Two filaments were also present outside the graft-host junction on the superior cornea. The patient was informed of contact lens options for his left eye, and elected to be fit with an intralimbal GP contact lens. He was also given preservative-free artificial tears to instill every half hour OS, in addition to an artificial tear ointment to apply prior to bed.

The patient was seen in clinic five more times over a two-and-a-half month period for a case of recurrent filamentary keratitis that prevented him from wearing contact lenses. Despite repeated removal of the filaments and adherence to the prescribed lubrication therapy, he could not achieve symptomatic relief. At this point, the patient said he regretted undergoing corneal transplant surgery, as his quality of life had severely decreased since the procedure.

A diagnostic scleral lens fitting was performed. The patient confirmed the contact lens offered relief of symptoms and a more

permanent one was ordered.

Biomicroscopy of his left eye performed at the scleral lens dispensing visit revealed the presence of filaments at 9 o'clock, 11 o'clock and 12:30. The patient also complained of a consistent irritative feeling and photophobia; both improved upon insertion of the prescribed scleral lens. Vision with the lens was 20/25, improving to 20/20 with -0.50 overrefraction. At the one-week follow-up visit, the patient reported wearing the lens on average 14 hours a day (*Figure 1*). He added that his quality of life improved since adopting this lens modality. Biomicroscopy performed at that visit indicated no signs of staining or the presence of filaments. Observation of the patient lasted for another six

ABOUT THE AUTHORS



Dr. Malooley is an optometrist with Chicago Cornea Consultants and serves as adjunct assistant professor for the department of community based-education at the Illinois College of Optometry. She is also an advisory board member for the Gas Permeable Lens Institute.



Dr. Sonsino is a partner in a private practice in Nashville, TN. He is also a diplomate in the cornea and contact lens section of the AAO, chair-elect of the contact lens and cornea section of the AOA and an advisory board member for the GPLI. Dr. Sonsino is board-certified by the ABO and consults for a number of vision companies.

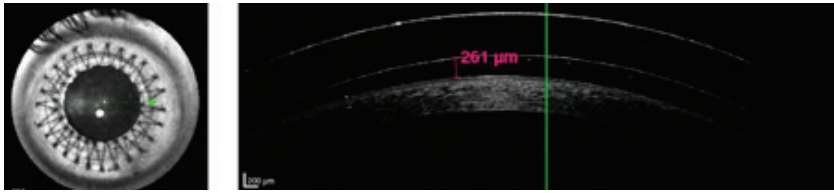


Fig. 1. OCT of scleral contact lens at a follow-up visit.

weeks before the fit of the lens was finalized. One year later, the patient is wearing the scleral lens daily, with no recurrence of filamentary keratitis.

Generally, symptoms of filamentary keratitis range from mild ocular discomfort to extreme photophobia, tearing and pain, as was the case with this patient.¹ The underlying cause of the filamentary keratitis is likely due to ocular surface dryness in relation to the penetrating keratoplasty; as such, frictional stress from blinking and reduced tear volume contribute to filament formation.² In this example, the scleral contact lens formed a barrier between the lid and the ocular surface while creating a moisture chamber over the cornea. The patient had an almost immediate improvement of ocular comfort and quality of life after beginning to wear the lens, with eventual resolution of the filamentary keratitis.

2. INTRALIMBAL LENSES

A 67-year-old white female with a history of radial keratotomy surgery performed in 1995 presented to the clinic with intralimbal gas permeable lenses fit at another location. Her entering visual acuity with the lenses was 20/50+2 OD and 20/50 OS. She also exhibited spectacle refraction of +6.00 -3.75x98 OD and +5.50 -4.75x77 OS that yielded 20/40-OD and OS. Biomicroscopy was remarkable for six radial slits with astigmatic keratometry inferiorly and superiorly (i.e., 4mm into the cornea), with neovascular-

ization and four radial slits OD and pannus 4mm into the cornea, encroaching on the visual axis OS (Figure 2). The final diagnosis for this patient: corneal neovascularization secondary to superior bearing of an intralimbal lens (Figure 3).

At a subsequent visit, the patient was refit into an oblate-shaped, full scleral lens that landed outside the limbal stem cells. Visual acuity with overrefraction was 20/25-2 OD, 20/25 OS. OCT images taken upon initial fit demonstrated an optimal fitting relationship centrally and peripherally. Interestingly, in looking at the mid-peripheral zone of the lens, it lands outside the cornea and, presumably, past the limbal stem cells (Figure 4). At the final follow-up appointment,

the patient reported increased comfort and overall happiness at the outcome. Visual acuity measurements were 20/25-2 OD, 20/25-1 OS, 20/25-1 OU. The patient was directed to return every six months to photo-document the neovascularization.

It is well known that mechanical irritation from contact lens wear can lead to limbal stem cell deficiency.³ This condition is characterized by corneal epithelial vortex keratopathy, neovascularization and loss of corneal clarity. In this case, there is no loss of corneal clarity, so it's likely that the process of limbal stem cell deficiency was arrested by removal of the ill-fitting lens.

In general, with a presentation of corneal neovascularization, it is important to create a high Dk/t condition with the scleral lens. The best existing guidelines to achieve this dictate that, in order to provide adequate oxygen to the corneal surface, the lens should be manufactured with the highest Dk material available, and include

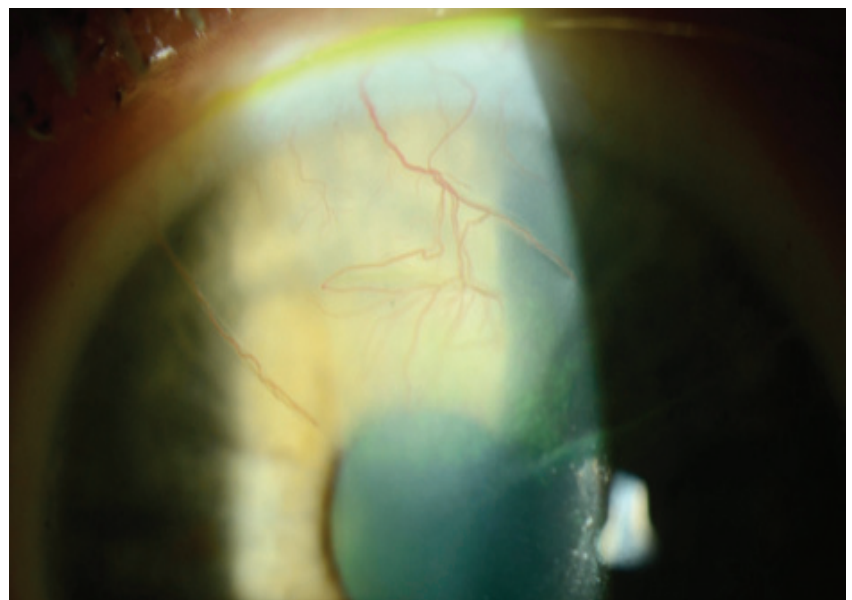


Fig. 2. Biomicroscopic image of the superior neovascularization of the right eye. Of note is the neovascular vessel that occupies the potential space of the superior temporal radial RK slit.

SOLVING PROBLEMS WITH SPECIALTY LENSES

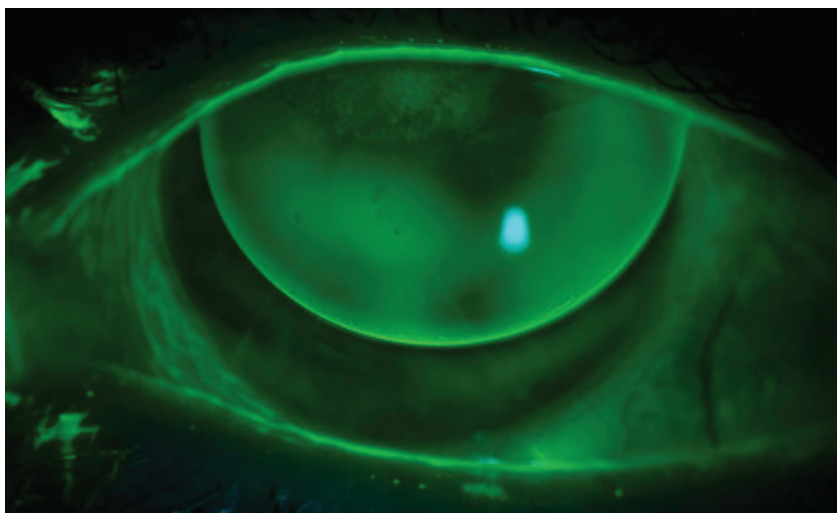


Fig. 3. Biomicroscopic evaluation of habitual intralimbal lens OD. The lens bears on the superior cornea. Also visible is superficial punctate keratitis at the site of bearing.

a maximum center thickness of 250 μ m and maximum vault of 200 μ m.⁴ In this instance, the neovascularization was managed with topical corticosteroids and she was refit into a scleral lens where the above criteria was met.

3 KERATOCONUS WITH FRONT TORIC

A 30-year-old white male presented for a contact lens fit complaining of ghosting. Additionally, he desired better vision and reported that previous attempts at contact lens wear had been unsuccessful. He was currently wearing glasses to achieve BCVA and presented with a history significant for keratoconus, for which had undergone collagen crosslinking OU three months prior. The patient's visual acuity with glasses was 20/30 OD and 20/40 OS, which improved to 20/30 with pinhole. Lensometry indicated a current prescription of -1.75 +1.75 x 175 OD and -1.75 +2.00 x 10 OS.

On external examination, the patient was noted to have small fissures. Biomicroscopy examination revealed partial Fleischer ring OU and early central corneal

thinning, but no corneal scarring OU. The patient was fit into a hybrid contact lens design, but returned shortly to the clinic having ripped three lenses in the first 13 days of wear. He reported difficulty with insertion and removal despite repeated in-office training. He was subsequently refit into a mini-scleral lens during the second follow-up appointment, where he noted an immediate improvement in handling ability and a reduction in ghosting compared with the glasses. He added that his overall visual acuity remained similar, however, at 20/30 OD and 20/40 OS with the lenses in place. A spherocylindrical overrefraction of +0.50 +1.50 x 53 OD and -1.00 +2.00 x 155 OS improved his vision to 20/20 OD and 20/25 OS.

Topography over the mini-scleral lenses revealed approximately 1D of toricity in both eyes in the same axis of the corresponding overrefraction. Contact lens flexure was

suspected to be the culprit for the majority of the residual astigmatism, so the lenses were reordered with increased center thickness. Unfortunately, the new lenses yielded a similar visual result—overrefraction and overtopography—leading the attending doctor to reorder them for the second time in a front toric prism ballast design to incorporate the residual cylinder correction found on overrefraction.

At the patient's one-week follow up visit, visual acuity with the toric mini-scleral lenses was 20/20 OD and 20/20 OS (Figures 5 and 6). The patient reported seeing the best he had in years. Though some patients may report scleral contact lenses to be cumbersome due to intimidation from their size, reluctance to fill the bowl of the lens or dependence on a plunger for removal, this patient reported better ease of handling that allowed for more successful wear. Additionally, the scleral lens's rotational and translational stability improved the patient's blurry vision resulting from residual astigmatism.⁵

Historically, corneal front toric gas permeable lenses have had problems with decentration and vision instability.⁶ These problems are easy to overcome in a scleral lens, however: in cases where residual astigmatism exists despite attempts to address flexure or other causes, adding a front toric correction to a scleral contact lens can result in high fitting success.

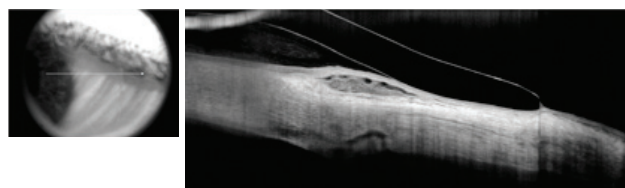


Fig. 4. Peripheral anterior segment OCT image of the left eye. The demarcation of the clear cornea and opaque sclera is visible. This lens lands on the sclera outside of the limbus.

4. OCULAR CICATRICAL PEMPHIGOID

A 77-year-old white male with a history of ocular cicatricial pemphigoid (OCP) symblepharon OU and severe dry eye OU was referred to the clinic by his corneal specialist for evaluation. His conjunctiva demonstrated significant symblepharon to within 1mm of the limbus OD (*Figure 7*). The patient was designated for a scleral lens fitting to treat the dry eye and modulate the progression of symblepharon. The first fitting included a notch at the site of conjunctival elevation (*Figure 8*); however, the notch rotated inconsistently and allowed air to enter the chamber, negating the attempt to treat the symblepharon (*Figure 9*). Subsequently, the lens diameter was reduced from 18.2mm to 15.0mm to try and “slot the gap” between the limbus and the symblepharon. This second attempt proved more successful and the patient was able to leave wearing the lenses comfortably.

Three years after the fitting, the patient returned to the clinic with a largely unchanged presentation, other than drying on the front surface of the lenses (*Figure 10*). Corrected visual acuity was 20/70 OD and 20/40+2 OS, while the appearance of the major site of symblepharon remained unchanged. The patient was subsequently refitted into a duplicate lens with a new,

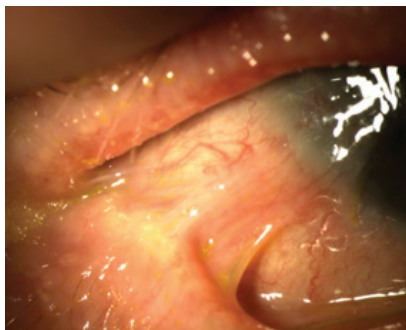


Fig. 7. Symblepharon appearing inferotemporally in the right eye.

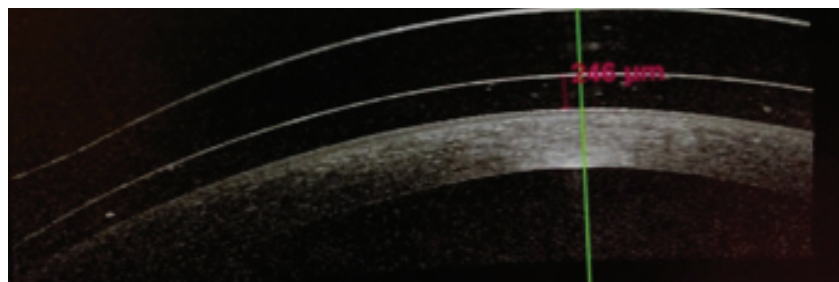


Fig. 5. OCT of the left lens showing central vault of 246 μ m.

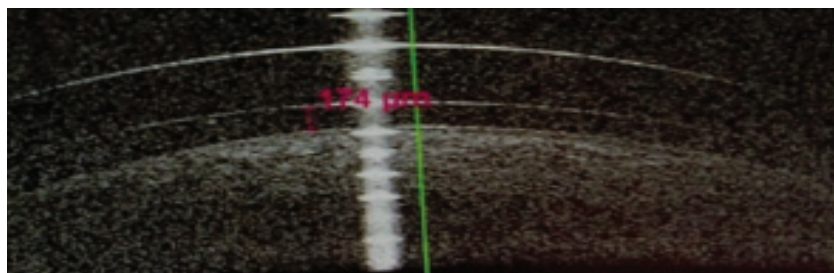


Fig. 6. OCT of the right lens showing central vault of 174 μ m.

wettable surface that improved visual acuity. Vision at dispensing was 20/30- OD, 20/25 OS and an OCT scan of the lenses demonstrated good alignment with just over 200 μ m of vault. The patient agreed to the proposed annual follow-up schedule to continually observe further changes.

The presence of OCP is correlated with severe dry eye, limbal stem cell deficiency and symblepharon.⁷ Literature reports have indicated contact lens use may be one method to prevent the progression of symblepharon; it's possible that rigid scleral lenses can act as retainers to form a physical barrier to the immune-complex deposition believed to be responsible for the formation of symblepharon.^{8,9} In our experience, notching lenses can yield variable results: for example, in this case the notch was unstable and rotated. However, the lens used in this case was also fit before peripheral toricity became available. With the recent ability to stabilize lenses using peripheral toricity, notching may now be a more viable option to manage symblepharon.

5. BILATERAL PENETRATING KERATOPLASTY

A 27-year-old Hispanic male with a history of bilateral corneal transplants for keratoconus was referred to the clinic for a spectacle prescription. He reported spending the majority of the day with unaided vision, but wearing soft contact lenses when using the computer. These provided only minimal visual improvement. He did not own glasses and expressed a desire for better vision, as he was getting married in two months and wanted to pursue a career in law enforcement.

Entering visual acuity uncorrected was 20/200 OD and 20/80 OS with pinhole improvement to 20/30 OD and OS. Manifest refraction was OD -2.50 +6.00 x 180 20/25 and OS -6.25 +4.75 x 130 20/25. The patient was unable to tolerate the prescription when trial-framed in office; a discussion regarding contact lenses ensued.

Based upon previous contact lens experience, scleral lenses were identified as the best option. On

SOLVING PROBLEMS WITH SPECIALTY LENSES

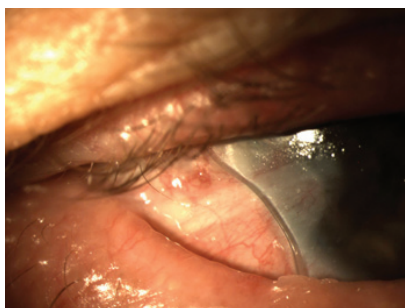


Fig. 8. Full-scleral fit on the right eye with a notch inserted at the site of conjunctival elevation.

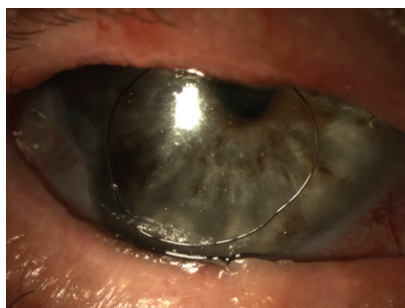


Fig. 9. Air injected into the post-lens reservoir when the notched lens rotated.

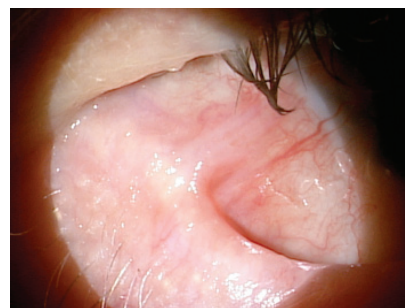

Fig. 10. The symblepharon remained unchanged three years after the initial presentation.

follow-up, vision with the scleral lenses was 20/20 OD and 20/20 OS. A broken running suture was noted on the left corneal transplant and subsequently removed; fit of the left lens was subsequently adjusted slightly to account for the change in corneal curvature. OCT over the lenses revealed minimal vault, so a new lens was ordered (*Figure 11*). Following fitting, the patient had been comfortably wearing his new contact lenses 12 to 14 hours a day for the past month. He commented that he “could not remember the last time his vision was this good,” and is currently waiting to hear back from law enforcement programs to which he had submitted his employment applications.

The visual correction provided by scleral lenses for irregular

corneas is well documented. In the case of this patient, the improvement in visual acuity allowed him to pursue a career path that would otherwise have been closed to him.

It should be noted, however, that concerns exist regarding possible scleral lens-induced corneal hypoxia; in fact, there are still many unanswered questions regarding scleral lenses.^{4,10,11} When fitting corneal transplant patients with GP lenses, we recommend considering a corneal design before moving to a scleral lens approach. This patient’s history of previous contact lens failures played an important role in determining scleral lenses to be the lens of choice; a patient with different experiences may benefit from a different approach.

Scleral contact lenses are clearly a mainstay in our arsenal of tools when considering clinical management. Candidates spanning a broad range of complexity, from the most extreme cases to those with simple refractive error correction, benefit from scleral contact lenses. The cases presented illustrate only a small portion of the potential uses for sclerals—namely, ocular surface rehabilitation and improved ocular comfort and acuity. All of these, however, achieve the ultimate goal: enhancing the patient’s quality of life. **CCCL**

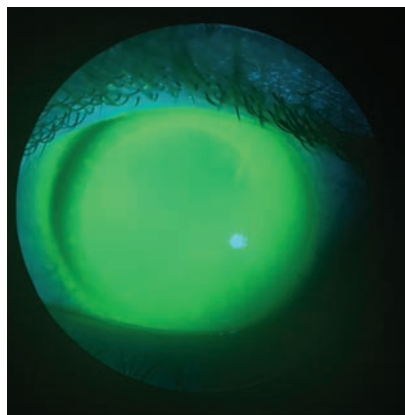
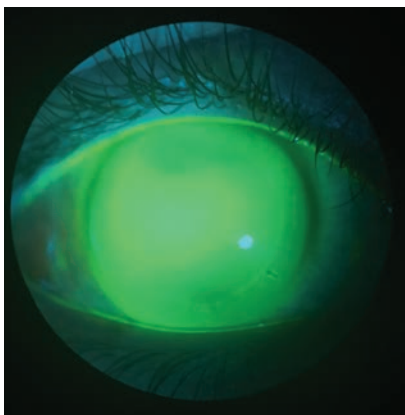


Fig. 11. Fluorescein evaluation of the right and left eye, respectively, at the initial follow-up visit.

1. Diller R, Sant S. A case report and review of filamentary keratitis. *Optometry*. 2005 Jan;76(1):30-6.
2. Tanioka H, Yokoi N, Komuro A, et al. Investigation of the corneal filament in filamentary keratitis. *Invest Ophthalmol Vis Sci*. 2009 Aug;50(8):3696-702.
3. Kim BY, Riaz KM, Bakhtiar P, et al. Medically reversible limbal stem cell disease: clinical features and management strategies. *Ophthalmology*. 2014 Oct;121(10):2053-8.
4. Michaud L, van der Worp E, Brazeau D, et al. Predicting estimates of oxygen transmissibility for scleral lenses. *Cont Lens Anterior Eye*. 2012 Dec;35:266-271.
5. Schornack MM. Scleral lenses: a literature review. *Eye Contact Lens*. Jan;41(1):3-1
6. Bennett E. Bending the Curve: How to Improve Toric Lens Success. *Review of Cornea and Contact Lenses*, 2013 Apr;150(3):31-4.
7. Schornack MM, Baratz KH. Ocular cicatricial pemphigoid: the role of scleral lenses in disease management. *Cornea*. 2009 Dec;28(10):1170-2.
8. Dunnebie EA, Kok JH. Treatment of an alkali burn-induced symblepharon with a Megasoft Banded Lens. *Cornea*. 1993 Jan;12(1):8-9.
9. Proia AD, Foulks GN, Sanfilippo FP. Ocular cicatricial pemphigoid with granular IgA and complement deposition. *Arch Ophthalmol*. 1985 Nov;103(11):1669-72.
10. Pullum KW, Stapleton FJ. Scleral lens induced corneal swelling: What is the effect of varying Dk and lens thickness? *CLAO J*. 1997;23:259-263.
11. Caroline P, Mark Andre. Using a Corneal Design to Manage Keratoconus. *Contact Lens Spectrum*. 2016 Jan;31(1):56.

San Antonio

Up to
19 CE Credits
(COPE approval pending)

REVIEW OF OPTOMETRY®
EDUCATIONAL MEETINGS OF CLINICAL EXCELLENCE



May 20-22, 2016

Superior Education with 3 Interactive Workshops

San Antonio Marriott Riverwalk

In the Heart of Downtown San Antonio

889 East Market Street | San Antonio, Texas 78205 | 210-224-4555

Discounted room rate \$189/NIGHT

Program Chair: **Paul Karpecki, OD**



REGISTER NOW!

www.ReviewofOptometry.com/SanAntonio2016

Or Email **Lois DiDomenico**: ReviewMeetings@Jobson.com | Call: 866-658-1772

REGISTRATION: 3 DAYS - 19 CE CREDITS* - \$495



Please see registration website for a list of sponsors and meeting agenda.

Administered by
Review of Optometry®


*Approval pending

By Stephanie L. Woo, OD

Off on the Right Foot:

Preparing the Patient for Scleral Lens Wear

A patient walks into the clinic desiring to try scleral lenses for the first time, or when evaluating a new patient you determine it's the best approach and recommend this design. After some time spent with the diagnostic fitting set, you find the perfect lens for them. Congratulations! Now it's time to teach the patient how to care for their lenses and send them on their way, right? Wrong! Fitting a patient with a scleral lens for the first time can be an exciting experience for both the practitioner and patient. However, even more than soft lens wearers, scleral lens patients require thorough training and practitioner follow-up care to ensure wearing success.

BATTLE PLANS

During the scleral lens dispensing visit, I first insert the patient's lenses and allow them to settle on the ocular surface for 20 minutes before assessing vision and lens fit. The waiting time is essential to properly evaluate the fit of the lens after it has settled into the conjunctiva. Evaluating the lens too soon will yield inaccurate findings such as central clearance, edge alignment and overrefraction. I usually let the patient relax in the waiting room and see another patient while their lenses are settling.

If the fit is acceptable, the patient proceeds to their scleral lens training session. Scleral lenses are applied and removed differently than soft contacts and even corneal gas permeable lenses, so it is essential that all new wearers be provided with appropriate training. This can either be achieved through individual means or using online resources. For example, a free video on sclerallens.org reviews the basics of scleral lens care. All new scleral lens patients in my practice watch this video before their lens care lesson. In addition to providing training, this video also serves to further highlight the benefits of scleral lenses, helping to overcome any remaining reservations regarding wear.

At the contact lens lesson, the patient is shown tools and techniques for proper lens insertion and removal. Typically, they attempt lens removal first, as the lens is most often already in the eye. A mirror is first placed on the desk so the patient can view their eye and the surrounding periphery with a straight gaze. At this point, different scleral lens plungers can be used based on practitioner and patient preference: I prefer the non-vented small DMV plunger, for example.

When removing the lens for the first time, place a small drop of saline solution on the plunger and adhere the tool directly to the lens,

making sure it is located towards the edge of the lens and not directly in the center. Once the plunger is firmly attached, twist and pull it at a tangential angle to remove the lens. A scleral lens that is fit properly will not be difficult to remove; however, if a large amount of suction occurs when attempting to remove the lens, the fit should be re-evaluated.

Be sure to inform patients that as they continue to wear their lenses more (i.e., for longer periods of time), they may become more challenging to remove due to the lens settling that occurs on the conjunctiva. This is to be expected, and should not result in any serious issues. Patients fit with small diameter scleral lenses may be able to remove the lens with their eyelids instead of the DMV plunger; however, only a few of my patients have had success with this method.

Once the patient has demonstrated adequate removal technique, it's

ABOUT THE AUTHOR



Dr. Woo graduated with honors from the Southern California College of Optometry and completed a cornea and contact lens residency in St. Louis, Missouri. She is a fellow of the American Academy of Optometry and a fellow and treasurer of the Scleral Lens Society. She enjoys lecturing around the world on the topic of contact lenses and anterior segment diseases. Dr. Woo practices at Havasu Eye Center in Arizona.

Are you fitting a first-timer? Keep these tips in mind for a smoother process.

time to teach them proper lens insertion. I typically ask my patients to remove their lenses from the case and rinse them with nonpreserved saline. Then, they can place the lens on an insertion device, such as a large plunger, O-ring, EZI scleral lens inserter or tripod with fingers. The lens is then filled to the brim with nonpreserved saline and the mirror is placed on the table. Tucking their chin to their chest so their nose points to the floor, the patient should open the eyelids with one hand and place the lens directly onto the eye, then release their eyelids and, subsequently, the insertion device. Scleral lens insertion is typically more difficult than removal, so consider demonstrating a variety of insertion techniques to the patient.

Following lens removal education, lens care is reviewed. Scleral lenses can be cleaned with approved GP lens cleaners like multipurpose solutions; most of my scleral lens patients use a hydrogen peroxide system. Following the lens care lesson, patients are provided with a scleral lens “goodie bag” containing a sample of their selected care system, several insertion and removal devices, vials of nonpreserved saline and a prescription, written step-by-step care instructions and a scleral lens brochure (gpli.info provides up to 100 to practitioners for free). I ask them to trial their lenses for a week, record any issues and return for a follow-up appointment.

FOLLOWING UP

Each practitioner has their own follow-up schedule that varies depending on patient condition, complexity of the case and experience

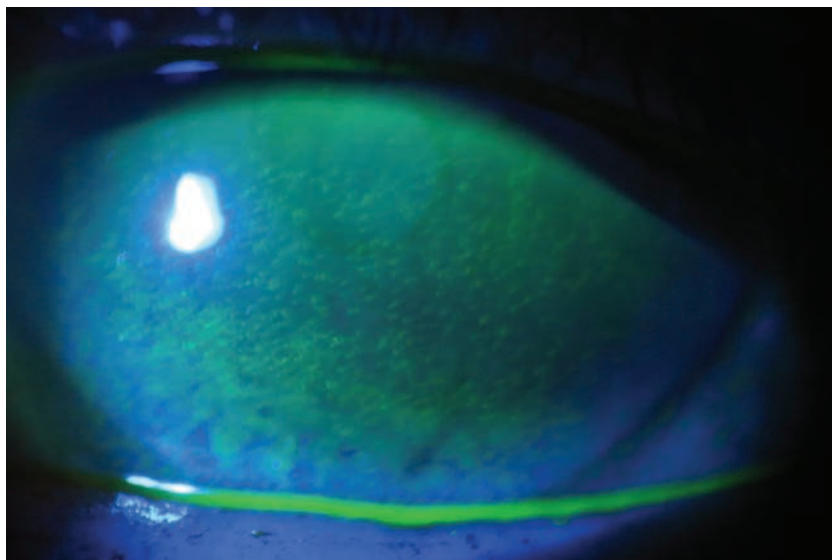
level. For example, when I first began fitting scleral lens patients, I would ask them to return once a month for the first six months so I could evaluate both corneal health and lens fit. Now, however, I am more comfortable allowing longer intervals of time in between appointments, though if the patient has a more severe condition like Stevens-Johnson syndrome, I will ask them to return on a more regular basis to evaluate ocular health.

Be sure to ask your patients which lens care system they are using and what they are filling their lenses with at each follow-up appointment. Some patients try to cut corners by using regular multipurpose solution, neutralized hydrogen peroxide or even plain tap water to fill their lenses. Also, make sure to evaluate the lens fit at the beginning of the appointment, before it is removed for closer examination of the ocular surface. Examining the scleral lens on the

eye is critical to identifying any wettability issues or evidence of scratches or deposits.

Additionally, assess central clearance, limbal clearance and edge alignment prior to lens removal. Conjunctival prolapse may also be visible during follow up appointments. Scheduling these visits later in the day can also help with gaining a true assessment of how the lens is interacting with the eye, as viewing the lens after it has been worn for several hours can leave room for identifying possible problems before the patient becomes symptomatic.

During all follow-up visits, we examine OCT images of central clearance and edge alignment, along with vision and slit lamp evaluation. One trick is to “paint” the front surface of the lens with sodium fluorescein, then evaluate it with a slit lamp to see if any of the chemical seeps underneath the lens edge. If you see sodium fluorescein



Diffuse corneal staining due to a patient filling his scleral lens with a generic multipurpose solution containing preservatives instead of a preservative-free saline.

PREPARING THE PATIENT FOR SCLERAL LENS WEAR

in the tear chamber of the lens, you can assume there is adequate tear exchange throughout the day. No presence of the fluorescein may mean adjustments to the lens fit are necessary.

Additionally, when attempting to decide whether a toric peripheral curve may be needed, keep this in mind: as the lens settles throughout the day, it sits on the flat meridians of the sclera (mostly at 3 o'clock and 9 o'clock). When you see a patient after they have been wearing their scleral lenses for a few hours, you may notice blanching at the edges of the flatter meridian. The patient may also complain that their eyes become red or sore after wearing the lens for a few hours. Such a patient could benefit from a toric peripheral curve system.

Always remove the scleral lens during the follow-up appointments. The condition of the patient's cornea and conjunctiva can give the practitioner valuable data about the success of the lens, but only if these areas are visible. For example, if staining is observed in one portion of the cornea, it

is possible that the lens is touching in that area, but not in others. In this case, the fit will need to be adjusted to achieve proper vault.

If there is a ring of staining around the limbus, it's likely that the lens is settling onto the limbus during the day; as such, the limbal curves of the lens will need to be altered. Steepening the limbal curves helps the lens vault over the mid-peripheral/limbal area to gain extra clearance. Some lens designs can alter the limbal area without affecting other areas of the lens fit, while others will need to alter the entire lens design when making a small change. Understanding how the lens works is critical because each manufacturer is different. If you observe diffuse superficial keratitis, there is a good chance that the patient is not rinsing their lenses prior to insertion, or is using a contraindicated filling solution. If any of these situations are observed, the practitioner must identify the necessary treatments and other relevant factors. A patient with glaucoma or a corneal transplant may need more frequent monitoring than a high astigmat, for example. As you fit more scleral lenses and see more patients for follow-up, you will likely develop your own rhythm.

PARTING WORDS

Direct the patient to only use the prescribed products given to them during the scleral lens lesson. If they want to change products for any reason, it is imperative that they contact you to discuss these decisions, as use of an incorrect care system or filling solution can damage the eye, the lens or both. For example, preservative-free




Give patients a variety of methods to insert their scleral lenses to help maximize success.

saline is the only liquid that should be used to fill the bowl of a scleral lens. Many patients may experience a strange feeling on the eye for the first few weeks of wear, especially if they are first-time wearers, as the ocular surface gets used to the new lens.

Drawing up a scleral lens contract with the patient is advisable before beginning the fitting and training process. Outlining all fees associated with the lenses can assist the patient with understanding what they are paying for. Be sure to include a clause stating what happens if the lenses do not work (i.e., do they receive any money back?) This is up to the practitioner to decide based on what they feel is fair. Also, review responses to other scenarios such as lens damage or loss.

Having a system in place for your scleral lens wearers can help with their success tremendously. Proper education prior to regular lens wear can save you from unnecessary phone calls or extraneous patient visits, and your patients from complications down the road. Additionally, investing time and energy into scleral lens education can help you further gain patient trust and respect, potentially leading to more referrals. Everyone loves to feel special, and helping patients feel cared for can create patient loyalty and a great relationship with their eye care practitioner. **RCCL**



Scleral lens training can include informative videos, paperwork and brochures.

2016

MEETINGS

REVIEW OF OPTOMETRY®

EDUCATIONAL MEETINGS OF CLINICAL EXCELLENCE



SAVE THESE DATES!

3 WAYS TO REGISTER

www.reviewofoptometry.com/conferences

Email **Lois DiDomenico**:
ReviewMeetings@Jobson.com

Call: **866-658-1772**

REGISTER EARLY



Program Chair:
Paul Karpecki, OD

San Antonio
Marriott Riverwalk
May 20 - 22, 2016



Interactive
CE Workshops

Bermuda
The Fairmont
Hamilton Princess
June 9 - 12, 2016

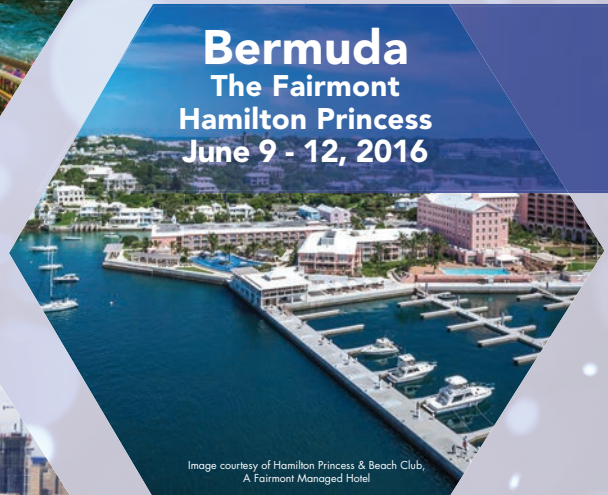
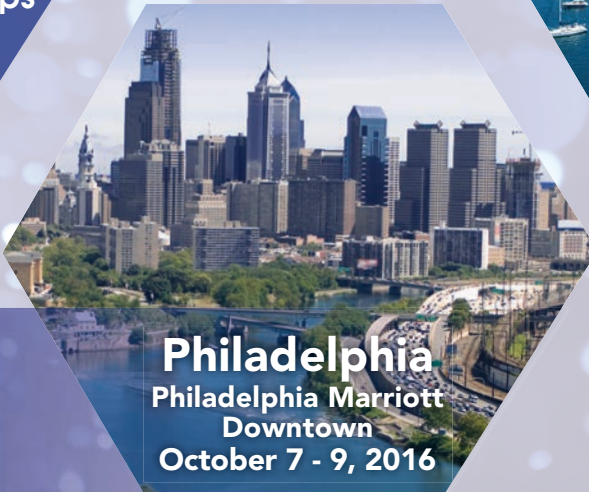
Image courtesy of Hamilton Princess & Beach Club,
A Fairmont Managed Hotel

Philadelphia
Philadelphia Marriott
Downtown
October 7 - 9, 2016



Administered by

Review of Optometry®



Approval pending

16-19 CE Credits

(COPE approval pending)

SIMPLE TIPS for

Troubleshooting Sclerals

By: Chandra Mickles, OD, MS,
and Melissa Barnett, OD

These lenses can pose unique challenges, especially for newcomers to the modality. Here's how to improve chances of success.

Scleral lens use has increased exponentially in the last decade—beyond being indicated for irregular corneas—to a broad range of contact lens patients, including those with normal corneal curvature.¹ However, though these specialty lenses are beneficial and even life-changing in some cases, their unique fitting characteristics mean there are also inherent challenges that make lens wear more difficult. This article will discuss several concepts practitioners should remain aware of when fitting scleral lenses.

REMOVING THE CLOUD

Non-wetting lenses and post-lens tear debris are two relatively common occurrences during scleral lens wear that can result in suboptimal or “cloudy” vision.² Mucins and lipids are attracted to the hydrophobic oxygen permeable scleral lens material, forming deposits and resulting in poor wettability. Research has shown that post-lens tear debris consists of a high concentration of lipids; unsurprisingly, lens surface and tear reservoir clouding issues are common in patients with ocular surface disease.³

In the case of a non-wetting lens, the first step is to aggressively treat the patient's ocular surface disease. Despite changing the lens

design and material, the surface of the lens itself may remain compromised if the condition isn't appropriately managed.

Don't forget to look for the presence of *Demodex* as well: these mites infest the eyelash follicle and/or meibomian glands, and often trigger the accumulation of cylindrical dandruff around the base of the eyelashes.⁴ Infestations can lead to inflammation of the meibomian glands and subsequent meibomian gland dysfunction (MGD), disruption of the tear film and a non-wetting lens. However, conventional MGD treatments like warm compresses and lid hygiene are often ineffective in treating the infestation; instead, tea tree oil in the form of wipes or eyelid scrubs should be considered. Keeping this condition in mind and treating it appropriately can help reduce its effects on a non-wetting lens.

Selecting a material with a low wetting angle can help improve the wettability of the lens and reduce the hydrophobic areas that attract deposits. Plasma treatments can also help achieve sufficient wettability. Recommend that patients wash their hands with non-oily soaps such as those made for contact lens wearers or acne sufferers. Oils in many soaps can leave a residue on the lenses that may affect lens wetting. Optimum by Lobob's Contact Lens Wearer

Hand Soap and Ocusoft's hand Soap are good examples; neither contains oils that can transfer from the patient's hands to the contact lens. Similarly, residue left on plungers used for insertion can also compromise the lens surface upon contact. Instead of disinfecting the face of the plunger with alcohol, which can further compromise the hydrophilic surface, soak it in gas permeable contact lens conditioner to remove residue. Frequent replacement of plungers is also beneficial. For patients who wear makeup or face cream, recommend they use oil-free products and apply them following lens insertion to prevent debris or residue from affecting the lens.

Use a cotton swab soaked in gas

ABOUT THE AUTHORS



Dr. Mickles is an associate professor at Nova Southeastern University College of Optometry in Fort Lauderdale, Fla. She lectures and publishes on a variety of topics with special interest in contact lenses and dry eye disease. She is a fellow of the American Academy of Optometry.



Dr. Barnett is a principal optometrist at the UC Davis Eye Center in Sacramento, Calif. She lectures and publishes extensively on topics including dry eye, anterior segment disease and contact lenses. Dr. Barnett serves on the board of Women of Vision, the Gas Permeable Lens Institute and the Ocular Surface Society of Optometry. She is president of the Scleral Lens Education Society.

permeable contact lens conditioner or nonpreserved saline to wipe away any deposits while rewetting the lens surface. Conditioner can also be placed on a plunger to gently scrub the front lens surface much like a squeegee (*Figure 1*). Cleaning the lens with a two-component cleaner of sodium hypochlorite and potassium bromide (Progent, Menicon) for 30 minutes once a week or biweekly can help with eliminating surface deposits. Miraflow, an alcohol-based cleaner can be used for 30 seconds to remove additional deposits.

Use of artificial tears containing a more viscous agent like nonpreserved carmellose sodium (Celluvisc, Allergan) or carboxymethylcellulose sodium (Optive, Allergan or Theratears) in place of saline to fill the lens bowl can act as an obstacle to prevent debris from moving through and underneath the lens. Decreasing sagittal depth or changing scleral lens designs is beneficial to reduce debris. In addition, achieving optimal peripheral lens alignment can also reduce the chance of debris traveling underneath the lens. This can be accomplished by moving to a smaller diameter scleral lens or use of toric peripheral curves. Squirting nonpreserved saline parallel to the edge of the lens can rinse off debris from underneath; patients can also remove and reinsert the scleral lens with fresh nonpreserved saline mid-day.

While non-wetting lenses and post-lens tear debris can result in suboptimal or “cloudy” vision, reduced vision can arise as result of contact lens flexure. Flexure can be managed by increasing the center thickness, flattening the base curve

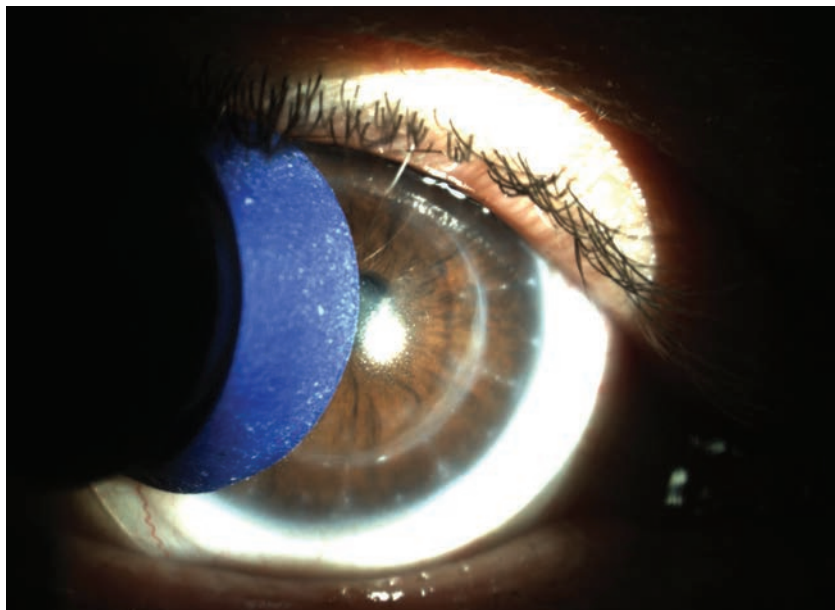


Fig. 1. A plunger soaked in gas permeable contact lens conditioner can be used to gently scrub away lens surface deposits and improve wettability.

radius, or changing to a stiffer material (typically from a higher to a lower oxygen permeability [Dk]).⁵ Prior to making these lens changes, it is important to verify that the reduced vision is due to flexure instead of true uncorrected astigmatism. Flexure can be diagnosed by performing keratometry over the patient's scleral lenses.⁵ Front surface toric scleral lens options are available for patients who have true residual astigmatism.

DERAILING DISCOMFORT

Patients can report lens awareness for several reasons, including the presence of air bubbles, excessive edge lift, a tight lens or corneal touch. Check for tear exchange by dabbing sodium fluorescein on the bulbar conjunctiva (*Figure 2*). If the dye cannot be detected underneath the lens, its peripheral curves should be flattened since the lens is likely too tight. Conversely, if

excessive edge lift is the problem, rectify the situation by steepening the peripheral curves.

Air bubbles are the result of spillage of the filling solution during lens application or insufficient filling of the bowl of the lens. If bubbles are an issue, re-educate on proper application technique, including filling the lens bowl adequately. Additionally, suggest consideration of a more viscous agent such as Celluvisc to fill the lens bowl (*Figure 3*).

Useful tools that can assist patients with lens application include the See Green Lens Inserter (Dalsey Adaptives), which is available with and without a stand. The stand holds the plunger and lens in place prior to application. This is especially helpful for patients who have unsteady hands or for those who require both hands to hold their eyelids open. A second tool, the EZi Scleral Lens Applicator

SIMPLE TIPS FOR TROUBLESHOOTING SCLERALS

(Q-Case), is placed on the finger like a ring, with a base for scleral lens application. This design provides stability and allows patients to apply scleral devices with one finger. No. 8 O-rings can be obtained at the hardware store with dimensions measuring 3/8" x 9/16" x 3/32." These hold the scleral lens on the patient's finger to allow for stable application. Alternatively, single-use sterile orthodontic rings placed on the patient's hand can be used for lens insertion. These are available in packages of 100.

Check for corneal touch after three to four hours of lens wear, as corneal touch may be missed during the initial visit. If corneal touch is noted, increase the sagittal depth of the lens. For practitioners new to fitting scleral lenses, try first evaluating the lens at the lens dispense visit and then again at four

hours after the initial lens dispense. This additional visit is helpful to determine if any corneal touch is present. If so, reorder the lens prior to dispensing for further wear.

hours after the initial lens dispense. This additional visit is helpful to determine if any corneal touch is present. If so, reorder the lens prior to dispensing for further wear.

In some cases, attempt piggy-backing with a silicone hydrogel daily disposable lens underneath the scleral lens for improved

comfort and to prevent epithelial disruption. In most cases, corneal touch can be avoided by incorporating different diameters or altering specific quadrants of the lens if needed.

When fitting more complex cases, consider using EyePrintPro, an optically clear scleral cover shell that is created by taking a three-dimensional impression of the unique irregularities of an individual's eye. A scleral lens with the exact impression of the ocular surface and individualized front surface optics may help optimize vision and comfort for each patient while preventing further issues.

MINIMIZING COMPLICATIONS

Similar to other contact lenses, scleral lenses, if fit or worn improperly, can lead to conjunctival hyperemia and corneal or conjunctival staining. Conjunctival hy-

peremia can be an indication of a tight periphery or a toxic reaction to preservatives. In cases like this, refit the patient with a flatter periphery and confirm they are using nonpreserved saline (and disposing after a single use) and the recommended cleaning solutions. Advise patients to bring their supplies to

the office, including plungers or other insertion tools, to review product compliance.

Conjunctival hyperemia can result from conjunctival vascular impingement, which occurs when the lens edge pinches the conjunctival tissue; as such, a flatter scleral landing zone may minimize this issue.⁶ Asymmetrical back surface lens designs with quadrant specific technology or toric landing zones can also address localized conjunctival impingement. Conversely, scleral lens compression—excessive bearing of the scleral lens on the conjunctiva—can result in conjunctival blanching.⁶ However, rebound hyperemia may occur at the location of the compression following lens removal.⁶ Scleral lens compression can result from midperipheral curves that are too steep.⁷ Therefore, flattening the midperipheral curves should resolve this problem.

If localized conjunctival and/or corneal staining is present, consider not only the possibility of an improper lens fit but also mechanical involvement due to handling issues as the cause of the staining. If handling issues are a concern, re-educate the patient on proper removal to prevent mechanical injury. Any diffuse staining observed is likely due to a toxic reaction to the preservatives. Move the patient to 0.9% sodium chloride inhalation solution or the recently FDA-approved LacriPure (Menicon) in a single-use vial, and advise the patient to dispose of the vial after a single use.

Scleral lens-induced conjunctival prolapse appears to be a relatively benign complication. It occurs when conjunctival tissue is pulled under the lens and onto the peripheral cornea or limbus in areas of significant lens clearance, especially inferiorly.⁸ Significant inferior lens

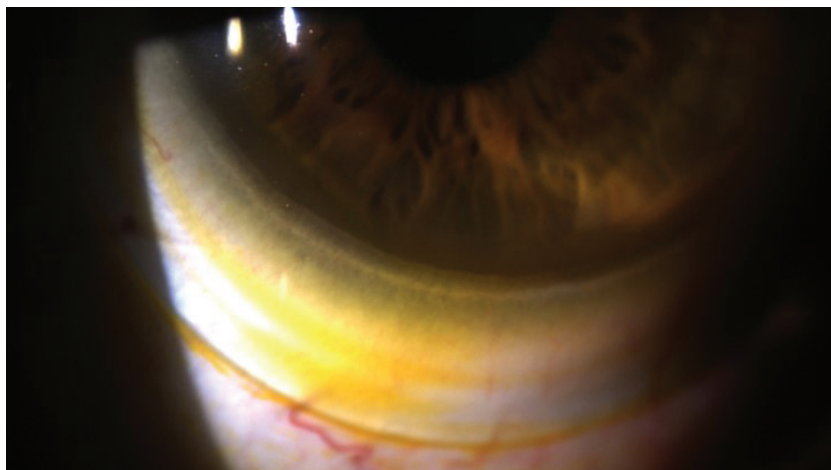


Fig. 2. Sodium fluorescein tear exchange at the edge of a scleral lens.



Fig. 3. Overfill the lens bowl with nonpreserved saline to prevent application bubbles.

clearance is most frequently present when the scleral lens positions inferiorly or in cases of inferior corneal depression, most often seen in keratoconus and pellucid marginal degeneration. Though transient conjunctival prolapse appears to be benign, the long-term effects of chronic conjunctival prolapse are unknown. However, the conjunctival tissue may impede fluid exchange beneath the lens.⁹ Additionally, the prolapsed conjunctiva can eventually adhere to the corneal surface such that it cannot be easily manipulated. Therefore, we recommend addressing this issue early on. Making use of non-rotationally symmetrical designs may help minimize areas of excessive limbal or edge clearance. If conjunctival prolapse is present, anesthetize the eye and use a cotton tip applicator or forceps to pull back the conjunctiva from the cornea.⁸

Though little is known about the long-term effects of scleral lenses on corneal physiology, recent studies suggest the presence of an excessively deep fluid reservoir along with thick lenses may lead to hypoxia-induced corneal swelling.^{10,11} To avoid this, researchers have proposed to incorporate

lens materials of the highest Dk available and design the lens with a maximum central thickness of 250 μ m and an apical clearance of 200 μ m.^{10,11} Nonetheless, to our knowledge, larger diameter gas permeable lenses with apical clearances greater than 200 μ m have worked successfully in patients. We believe as we learn more about scleral lens hypoxia-induced corneal edema with future research, we will be better able to design scleral lenses with less concern regarding this potential complication.

As with any lenses, challenges may arise with scleral lens wear. These simple tips can help address patient concerns and ensure success with these designs. Above all, however, communicate the how and why of scleral lens selection, use and complications to your patient. Doing so can earn your practice a patient for life. **RCCL**

1. Nichols J. Contact lenses 2015 annual report. *Contact Lens Spectrum*. Jan 2016;31:18-23.
2. Visser ES, Visser R, Van Lier HFF, Otten HM. Modern scleral lenses part II: patient satisfaction. *Eye & Contact Lens*. 2007;33(1):21-25.
3. Walker M, Morrison S, Caroline P, et al. Laboratory analysis of scleral lens tear reservoir clouding. Poster presented at the 2014 Global Specialty Lens Symposium, Las Vegas, Jan 2014.
4. Liu J, Sheha H, Tseng SCG. Pathogenic role of *Demodex* mites in blepharitis. *Curr Opin Allerg Clin Immunol*. 2010;10:505-510.
5. Bennett, ES, Scheid, T, Morgan, BW. "Gas-Permeable Lens Problem Solving." *Clinical Manual of Contact lenses*. Philadelphia: Lippincott Williams & Wilkins; 2014:203-228.
6. van der Worp E. A Guide to Scleral Lens Fitting, Version 2.0 [monograph online]. Forest Grove, OR: Pacific University; 2015.
7. Denaeyer, GW. The scleral vault. *Contact Lens Spectrum*. Mar 2015;30:40
8. Caroline, PJ, Andre, MP. A potential effect of conjunctival prolapse. *Contact Lens Spectrum*. Sep 2013;28(9):56.
9. Severinsky B, Behrman S, Frucht-Pery J, Solomon A. Scleral contact lenses for visual rehabilitation after penetrating keratoplasty: Long term outcomes. *Cont Lens Anterior Eye*. 2014 Jun;37:196-202.
10. Jaynes JM, Edrington TB, Weissman BA. Predicting scleral GP lens entrapped tear layer oxygen tensions. *Cont Lens Anterior Eye*. 2015 Feb;38:44-47.
11. Michaud L, van der Worp E, Brazeau D, et al. Predicting estimates of oxygen transmissibility for scleral lenses. *Cont. Lens Anterior Eye*. 2012 Dec;35(6):266-71.



Go Further Without Leaving Home




Expand your clinical skills and catch up on your CE requirements, all from the comfort of your own home.

Review offers **nearly 100 hours** of COPE-approved continuing education — right now! It's **just a click away**. Our extensive library of exams runs the gamut from keratoconus to fundus autofluorescence, and everything in between.

[www.reviewofoptometry.com/
continuing_education](http://www.reviewofoptometry.com/continuing_education)

RCCL

REVIEW OF CORNEA
& CONTACT LENSES



Complications from a Corneal Issue

How should one respond when immune deficiency disrupts the corneal healing response?

A 52-year-old Caucasian female with a history of ocular surface dysfunction presented with severe pain and decreased vision in her left eye. The patient's medical history included an instance of severe corneal involvement while vacationing overseas that resulted in hospitalization and successful treatment with autologous serum. She also had a history of autoimmune disease relating to systemic lupus but no ocular trauma, and reported undergoing an evaluation for medical concerns in the past, none of which were positive.

Initial examination demonstrated a relatively normal right eye with acuity of 20/25+ sans correction. The left eye displayed an area of epithelial loss inferiorly measuring 6mm horizontally by 1.5mm to 2mm vertically. Additionally, the anterior chamber demonstrated trace cellular reaction. No evidence of infiltrative keratopathy or neutrophil activity was present in either the abnormal zone or the area surrounding it. Tear osmolarity measured 316 in the right eye and 298 in the left.

The corneal area with epithelial damage stained actively with Fluress; however, no significant adjacent tissue involvement with the dye was identified. Lissamine stain showed notable bilateral conjunctival involvement, and the left eye also demonstrated a mild superior limbic keratoconjunctivitis. Applanation pressure in the right eye measured 16mm Hg and was deferred in the left side due to the corneal issue. The patient was di-

lated at the evaluation and demonstrated normal posterior poles in both eyes at 0.3 cup-to-disc ratios, flat optic nerves and non-remarkable posterior poles and peripheral retinas.

The patient reported she had awakened with the painful issue, which had been preceded by several days of a notable foreign body sensation in the left eye. Potential causes for the presentation included her history of severe dry eye for which she had been treated chronically over the years, recurrent corneal erosion, corneal dystrophy, trauma or toxicity; however, currently, she was not using any topical lubrication or active therapeutic agents. A bandage contact lens and a therapeutic regimen consisting of one drop of Ciloxan (ciprofloxacin 0.3%, Alcon) QID was initiated, and homatropine 5% was also administered twice in the chair. The patient was advised to use non-preserved artificial tears QID in alternation with the antibiotic.

THE TWIST

The patient returned to the office on day three with a visual acuity of light perception. The involved eye was 4+ injected with intense ciliary flush and the epithelial lesion was unchanged from the previous examination. Additionally, the patient's contact lens was no longer present and she reported avoiding use of the topical antibiotic, as her dog had "chewed the bottle" the day after it was prescribed.

Slit lamp examination revealed a 6mm by 2mm corneal wound consistent with the initial evaluation. The patient also demonstrated an

anterior chamber hypopyon, which was accompanied by a 4+ cellular reaction and early fibrinoid activity. Dilation was performed with tropicamide, phenylephrine and homatropine 5% to maximize pupillary activity, and homatropine 5% was administered again 45 minutes later to relieve the patient's discomfort.

The dilated fundus exam did not show a view of the posterior pole, in part due to the hypopyon and anterior chamber reaction and secondary to a dense vitreous response. The cornea demonstrated multiple infiltrates approximately 1mm in size in an arc above the primary lesion, extending from 4 o'clock to approximately 10 o'clock. None of the infiltrates stained actively. B-scan ultrasonography demonstrated a 3+ cellular reaction in the posterior vitreous. A sonolucent zone was also present posterior to the hyaloid face with a crescent-like area of clarity.

The patient was advised that the decline of her condition was significant and that her noncompliance with the treatment could be contributory. The keratouveitic response was a particularly notable point of concern and the possibility that an endophthalmitis was present should not be ruled out. In a somewhat comforting finding, the area posterior to the hyaloid face was sonolucent; a typical endophthalmitis would not respect an anatomic boundary that acutely. At this point, the patient was placed on Zymaxid (gatifloxacin, Allergan) q1hr and atropinized in the chair.

A consultation for the notable vitritis present yielded the conclusion that the presentation was

not endophthalmitis. Instead, the problem was identified as a remarkable keratouveitic response to the primary lesion and subsequent corneal involvement. At this point, a Prokera amniotic membrane was placed on the eye and alternate dosing therapy with Zymaxid and vancomycin was initiated to provide full antibiotic coverage. The patient was also placed on a regimen of 500mg of oral Valtrex (valacyclovir, GlaxoSmithKline) PO TID, since the lesion was nonresponsive in the first four days and the etiology was unclear as to onset. The patient was also advised to use atropine QD to quiet the ciliary body.

The patient continued to be monitored daily for the next three days, during which the hypopyon began to resolve and comfort improved by approximately 50%. The lesion itself was difficult to evaluate, so the membrane was removed under sterile conditions and stored in a sterile solution while the cornea was assessed. Observation demonstrated a 60% to 70% improvement in the size of the lesion and epithelial cellular development in the margins. A notable reduction in the hypopyon, as well as the overall level of inflammatory cellular activity, was also noted in the anterior chamber.

The Prokera was replaced using a sterile technique and the patient continued with current therapy. She returned to the clinic two days later exhibiting a completely sealed corneal defect with intensive staining at the margins, but good healing response. At this point, the hypopyon had cleared by over 90% and the anterior chamber had significantly improved. A B-scan assessment also

revealed marginal improvement in the posterior segment and vitreous fluid. Visual acuity at this visit was 20/300, which did not improve on pinhole. This was consistent with the last several visits, including the assessment of visual function at the time when the Prokera was removed for review of the cornea.

Given this good response, the decision was made to begin tapering the topical antibiotic therapy. The oral Valtrex regimen was maintained, however, as there was notable improvement in the patient's condition following initiation. One drop of Durezol (difluprednate, Alcon) QID was also added. The patient was directed to return on a two-day cycle for the next 10 days. During this period, the cornea continued to improve, with a further decrease in staining; the infiltrates remained stable and nonprogressive; the hypopyon dissipated; and the anterior chamber reaction reduced to trace findings. Intraocular pressure measured on several occasions was within the normal range. Visual acuity improved to approximately 20/200, and pinholed to 20/150; there was also a substantial decrease in the number of vitreous cells present.

RESOLUTION

By the tenth day following intensive therapy, the antibiotics were being taken QID, the Valtrex had been reduced to QD and the Prokera membrane had been removed. The patient was also directed to use Refresh PM (Allergan) TID following application of the antibiotic and steroid drops. The patient was subsequently scheduled to return

on a weekly basis. During her most recent examination, visual acuity was 20/40 in the treated eye, which pinholed to 20/25-. The epithelial lesion was completely closed and the re-epithelialization process had produced a relatively smooth epithelial surface. Stromal infiltrates were still present, but inactive. Additionally, the anterior chamber was quiet and there was a significant reduction in vitreous cells. At this point, all topical antibiotic therapy was discontinued and the patient was directed to continue taking oral antiviral therapy QD and Refresh PM TID, interspersed with nonpreserved artificial tears. She also continued using one drop of Durezol daily, with the expectation that the posterior cellular activity would clear more rapidly as a result.

This case shows a remarkable response with relatively ordinary initial factors, in that the patient's history of dry eye and compromised autoimmune status likely produced a recurrent erosive episode and possible atypical HSK presentation. Subsequently, either of these—or both—ignited a 4+ keratouveitic cascade that progressed to a hypopyon and vitritis, ultimately requiring a month-long healing process back to improved visual function.

Overall, it is important to remember that autoimmune deficiencies can induce a wide variety of unexpected responses, including the type seen in this patient. Other patients to keep an eye on for this type of response include those undergoing cataract or refractive surgery. **RCCL**



To Do or Not to Do?

Start something new or stop doing something old? A three-question test to determine the right answer.

When speaking on the subject of practice management, I often refer to a truism from the book *The Four Disciplines of Execution* that says something along the lines of this: more good ideas will exist than the capacity to execute them. It's likely that many of us have a similar ever-expanding list of practice improvement ideas that we can never seem to find adequate time to explore. Just as no one can escape gravity or the Pareto principle (i.e., the 80/20 rule), consultants are also often the victim of this scenario. As such, though we cannot escape it, we can instead find ways to work

being removed? Putting the focus on what you can eliminate or change, instead of what you can add or expand, can have positive effects.

OPEN YOUR MIND

As is the case with nearly any practice improvement idea, start by first considering why you do a certain thing the way you do. Typically, the answer is one of three possibilities.

1. "We've always done it that way. The guy I bought the practice from did it that same way, too."
2. "Everyone else I know of does it this way, so it must be the best way to do it."
3. "How else would we do it?"

and competition in our industry and the viral spreading of ideas in the digital world, just when you believe you have something solved, it becomes time to revisit it again.

For example, ask yourself why patients have their pretest procedures (like autorefraction, topography and fundus photography) done in Room No. 1. You'd likely agree that all of the three previous answers apply here—and since they do, we should ask why! So, involve your staff. Discuss eliminating or altering something to help avoid the bottleneck in Room No. 1. This does not mean eliminating a procedure like autorefraction—the question was, why are those tests done in Room #1?, not why are they done at all?

“WHAT PROCESS, SYSTEM, TECHNIQUE OR STRATEGY CURRENTLY EXISTS IN THE PRACTICE THAT WOULD BE BETTER OFF BEING REMOVED?”

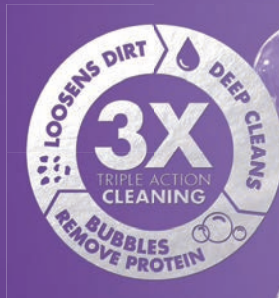around it. The secret—instead of continually stressing over never having time to implement something new, take a moment to pare things down and remember what you already have. Ask yourself, what process, system, technique or strategy currently exists in the practice that would be better off

Each task in your office—no matter how small and whether involving patients or not—should be analyzed this way. Given there are approximately 20 million items that could be reviewed, recognize that you could spend several lifetimes attempting to do this and never finish. And, given the rapid rate of change

With this fix, you are freer to take tests out of Room #1. That might mean something as simple as putting some of the technology in a second available room, if you have the rare luxury of extra space. If not, what about seeing whether some of the technology is available in a portable equivalent that would allow you to move it, instead of the patient?

Or, look into whether an at-home version of the process is available. For example, does your staff ask any history questions in this room as part of the procedure? If so, could they be added to your web site and effectively moved, not only out of Room No. 1, but out of the office entirely? This could mean the difference between seeing 10 patients a day or 12 patients—or more. **RCCL**

Help your patients
LOVE
their lenses.



The next level of lens care:

- Exclusive HydraGlyde® technology for long-lasting moisture
- Unsurpassed disinfection¹
- Preservative free to be more like natural tears

Introduce your patients to CLEAR CARE® PLUS formulated with the unsurpassed cleaning and disinfection of CLEAR CARE® – featuring our **exclusive HydraGlyde® Moisture Matrix** to provide soft lenses with long-lasting moisture. Ask your Alcon rep for more information or learn more at CLEARCARE.com.

CLEAR CARE® PLUS
formulated with



PERFORMANCE DRIVEN BY SCIENCE™

Alcon
a Novartis company

¹Gabriel M, Bartell J, Walters R, et al. Biocidal efficacy of a new hydrogen peroxide contact lens care system against bacteria, fungi, and Acanthamoeba species. Optom Vis Sci. 2014; 91: E-abstract 145192.
© 2016 Novartis 1/16 US-CCS-15-E-1395

The most comprehensive GP lens care system available.

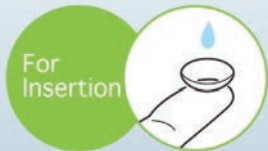

Introducing LacriPure

Menicon's new rinsing and insertion saline solution.



Indicated for use with soft, hybrid and rigid gas permeable lenses, LacriPure is a sterile, non-preserved saline which provides an alternative to tap water rinsing.



Packaged in a 5ml unit-dose vial, LacriPure has been cleared as a scleral lens insertion solution and provides the patient with exceptional sterility.

Menicon LacriPure joins Menicon Unique pH® multi-purpose solution and Menicon PROAGENT protein remover to complete the industry's most comprehensive GP lens care system.



800-636-4266 | meniconamerica.com | information@menicon.com