jmi

Review of Cornea & Contact Lenses

APRIL 2012

The Irregular Cornea

INSIDE THIS ISSUE:

Supplement to REVIEW OF OPTOMETRY

April 2012

Earn 1 CE credit in this issue. See "AS-OCT Technology: Analyzing the Anterior Segment," p. 23.

Your patients can

SAVE UP TO $100**

On DAILIES® AquaComfort Plus® and FOCUS® DAILIES® Toric contact lenses. Visit dailies.com for more details.

A fresh experience for about the same price.*

With DAILIES® brand contact lenses, you can give your patients that new-lens feeling all day, every day, for about the same cost to wear as the leading 2-week replacement lens.[1]

A great price combined with outstanding comfort and built-in single-use compliance completes the DAILIES® brand experience.

Great experience. Great price.

*For about the same cost as the leading 2-week lens, lens care, and the rebate included.
**After manufacturer's mail-in rebate. Limited time offer. While supplies last. Must meet certain criteria to be eligible for full rebate.

See package insert for complete product information.

Reference: 1. Ciba Vision data on file, 2011.

Alcon®

contents

Review of Cornea & Contact Lenses | April 2012

The Irregular Cornea Issue

ON THE COVER

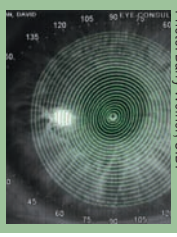

Photo: Barry Weiner, O.D.

Departments

VOL. 149, No. 3

In The News

• **Vistakon** announced the U.S. launch of 1-Day Acuvue Moist for Astigmatism, a daily disposable soft toric contact lens for individuals with astigmatism. The product features a proprietary Blink Stabilized design, which harnesses the natural pressures of a blinking eye to help keep the lens in place and quickly realign the lens if it rotates out of position. It uses the Lacreon technology to embed a water-holding ingredient into the etafilcon A material of the lens. For more information, visit www.jnjvisioncare.com.

• **Bausch + Lomb** is expanding the range of powers of its PureVision2 For Astigmatism line of contact lenses. The first wave, on March 1, extended the sphere powers offered from plano to -9.00D (0.50D steps above -6.00D) and cylinder powers of -0.75D, -1.25D, -1.75D and -2.25D in 10° increments around the clock. The second wave, planned for May 1, will increase plus powers to +6.00D (0.25D steps) and the entire range will be available in the same four cylinder powers. For more information, visit www.purevision2.com.

• **OcuSoft, Inc.** and **Essentia Pharma, LLC** will jointly introduce and market the OcuSoft Lens Care System, a three-in-one system that deep cleans, stores and disinfects with 3% hydrogen peroxide. The system also has a lubricating agent and no added preservatives. For more information, visit www.ocusoft.com.

• **Allergan** announces the launch of Refresh Optive Advanced, a new over-the-counter artificial tear option for patients suffering from dry eye. This product is a lipid-enhanced tear with the low blur and comfort of an aqueous tear. It features a triple-action formulation to reduce tear evaporation, hydrate and lubricate for dry eye symptom relief, the company says. For more information, visit www.refresh-brand.com.

ABO Accepts 281 New Diplomates

The American Board of Optometry (ABO) said that of the 297 active candidates completing the November-December 2011 examination, 281 (94.6%) were successful in becoming diplomates. This group represents 42 states across the country. All new diplomates will be added to the listing of board-certified optometrists on the ABO website.

The Board will discuss low participation in the pediatrics/binocular vision/vision therapy and vision rehabilitation/low vision/neuro-ophthalmic rehabilitation areas of emphasis.

For more information, visit www.americanboardofoptometry.org.

VTI Introduces Single Universal Add Lens

Visioneering Technologies Inc. (VTI) announces the development of a new approach to contact lenses for presbyopia. The new design uses a single universal add, which the company says will simplify the patient fitting process for both practitioners and patients.

In a marketplace study conducted by Jobson Optical Research in November 2011, more than 77% of 262 eye care professionals stated that they would increase the number of presbyopic patient fittings with contact lenses if offered a single "universal add" multifocal control lens design.

According to Sally Dillehay, O.D., VTI's vice-president of Clinical and Regulatory, the lens delivers up to four diopters of equivalent near power covering the near vision requirements of most presbyopic patients with add power between +0.75D and +3.50D. The single universal add allows practitioners to fit the contact lens like a distance-only lens.

Clinical testing conducted by VTI reports that up to 90% of patients may be fitted successfully the first time with the single universal add lens design.

For more information, visit www.vtivision.com.

Heidelberg's Spectralis Receives FDA Clearance

Heidelberg Engineering GmbH announces FDA clearance for the new Spectralis Anterior Segment Module (ASM). The ASM provides high-resolution images of cornea, anterior chamber angle and sclera by using Heidelberg's Noise Reduction technology for enhanced detail. Clinicians can assess both chamber angles at the same time using a 16mm-wide angle-to-angle OCT scan.

For more information, visit www.heidelbergengineering.com.

Review of Cornea & Contact Lenses

JOBSON MEDICAL INFORMATION LLC
11 Campus Blvd., Suite 100
Newtown Square, PA 19073
Telephone (610) 492-1000
Fax (610) 492-1049

Editorial inquiries (610) 492-1003
Advertising inquiries (610) 492-1011
E-mail rcl@jobson.com

Dispatch: San Diego Specialty Contact Lens Symposium

This past February 24-26, the San Diego Specialty Contact Lens Symposium hosted its second annual event with record attendance from 24 states and 11 countries. Eye care practitioners traveled from as far as Saudi Arabia, India, Australia and China to benefit from the 20 hours of lecture and 32 hours of industry-sponsored workshops.

The 2012 symposium featured basic and advanced course blocks, including a five-hour session on keratoconus options featuring Ed Boshnick, O.D., Dianne Anderson, O.D., Robert Gordon, O.D., Greg DeNaeyer, O.D., and Barry Eiden, O.D., Ph.D., who lectured on corneal gas-permeable lenses, hybrid lenses, tandem lens systems, scleral lenses and custom soft lenses respectively.

Christine Sindt, O.D., Dr. DeNaeyer and Muriel Schornack, O.D., represented the Scleral Lens Education Society as they provided state-of-the-art education and training on the full continuum of large diameter lenses and their multiple clinical applications for the irregular cornea and ocular surface disease.

Jeffery Walline, O.D., Cary Herzberg, O.D., Nick Despotidis and Michael Lipson, O.D., spoke on corneal reshaping and refractive error regulation, and case management for children and adolescents. The presbyopia block was lead by Tom Quinn, O.D. and Dr. Lipson.

Dr. Eiden presented on custom silicone hydrogel lenses and provided the attendees with excellent tools to incorporate the newest additions to the specialty contact lens armament. Dr. Anderson presented on technology-driven contact lens prescribing.

Jerry Legerton, O.D., M.S., M.B.A., closed the lecture series with a comprehensive overview of smart contact lenses. He discussed strategies for using wavefront aberrometers for optimizing vision with currently available lenses, methods for using auto-refractors for peripheral refraction and the role of peripheral refraction in lens selection.

Clark Chang, O.D., Renee Reeder, O.D., Peter Wilcox, O.D., Peggy Achenbach, O.D., and Doug Becherer, O.D., joined the symposium faculty for industry-sponsored workshops.

Two pre-symposium events complemented the formal program. A four-hour session by Mr. Despotidis, "Supercharge Your Practice," outlined tools for building a specialty lens practice. In addition, SynergEyes offered a guided tour of its facility.

The San Diego County Optometric Society first envisioned the symposium in 2010 to fill the need for increased clinical expertise in the area of specialty contact lenses. There was a desire to provide a forum to provide a clinical "how to" approach for optometrists and their ancillary personnel. Plans for the 2013 meeting are currently underway.

Advertiser Index

Editorial

By Joseph P. Shovlin, O.D.

Are All Biofilms Bad?

We should look to nature to understand how best to address biofilm.

The truth is that all biofilms are not bad. We can even look to nature to provide fine examples of biofilms, such as fuel cells and marine engineering systems. Recently however, there has been a lot of attention on biofilm formation on contact lenses and lens storage cases. Let's discuss.

By definition, a biofilm is an aggregate or community of microorganisms where cells adhere to each other on a surface, frequently embedded within a self-produced matrix of extra-cellular polymeric substance (slime).[1,2] Scientists now know that 99% of all microbial activity in an open ecosystem occurs in biofilms.[3] Biofilms permit communication among organisms with quorum sensing between species, thereby allowing for a sense in numbers. With all of this, specific organisms pass genetic material to other species.[2]

Biofilm Management

Dental plaque is an example of biofilm deposit on the surface of teeth. Inner ear, bladder and prostate infections, and even acne, are all examples of biofilm infections.[1,3,4] The significance of biofilms is just now being fully investigated. Biofilms can grow on medical devices, such as implants, catheters, cardiac valves, intrauterine devices and contact lenses, creating an opportunity for infections to stem. In cases where microbes resist antibiotics and evade the immune system, death can occur.[1,2,4]

Bacterial biofilm formation on contact lenses and lens storage cases clearly poses risk for infection of the cornea and sterile corneal responses.[5,6] Microorganism variability includes species/strains, gene expression and inoculum. We know that biofilms decrease the effectiveness of multipurpose disinfecting solutions. However, there are currently no FDA guidelines on biofilm disinfection. Research suggests that proper lens care and scheduled disposable lens replacement may decrease the risk of infection by reducing the buildup of bacterial biofilms in lens storage cases and contact lens surfaces.[6]

Yvonne Wu, Ph.D., and colleagues at the Brien Holden Vision Institute have provided some intuitive recommendations for the care of lens storage cases—including digital rubbing and rinsing; wiping the lens storage case with tissue; air-drying the case; and avoiding recapping the lens case lid after use without additional cleaning methods.[5] Although recommended hygiene practices do not necessarily ensure a case free from contamination, tissue wiping alone was shown to remove a significant amount of biofilm.[5,6] Another study found that air-dying biofilm for 10 hours can decrease the recovery of microorganisms.[6] Rubbing and rinsing not only reduced or dislodged bacteria, but also reduced nutrients that promoted growth of bacteria.[5,6]

Regardless of selected cleaning routine, it is easier to remove biofilm from a smooth polypropylene case, rather than a case with ridges.[6,7] However, using a silver-impregnated lens storage case likely is the best defense for reducing the potential for biofilm formation.[8]

Take a Step Back

As we look for new ways to help battle biofilms, it might be helpful to turn back to nature. We know that bacteria will leave the colony when there is biofilm crowding and aging. Several scientists have employed strategies using certain molecules that, when introduced into the biofilm colonies, provoke genetic and physiologic changes in the bacteria to make them disperse and return to their planktonic state.[3,9]

By breaking apart the scaffolding that encases the organisms, the bacteria are very susceptible to viable treatment. Cellular debris from the immune system fighting infection actually provides raw material for the biofilm-DNA, actin and histones. Using the enzyme DNase, together with negatively charged poly aspartic acid to break down the bonds that support biofilms, seems to effectively render biofilms less significant.[3] In fact, research shows that this treatment reduces biofilms on contact lenses by 79.2% and reduces corneal infection in animal models by 41%.[3]

Incorporating the aforementioned regimen recommendations in daily practice will help reduce the chance of corneal infection from pathogenic organisms and the inflammatory changes that occur as a result of endotoxins that collect on lenses and in storage cases. RCCL

References available at www.reviewofcontactlenses.com.

By Jason Jedlicka, O.D.

Part III: Scleral Lens Therapy

When you ask your scleral lens manufacturer to alter the design, you may find new therapy options.

In the previous two columns, Brooke Messer, O.D., discussed innovative scleral lens applications. In the series' final column, I will introduce a non-traditional way that scleral lenses can be prescribed.

A Case Study

JJ is a 59-year-old female with a history of dry eyes and ocular allergies. Her history is significant for hard lens use many years ago and a facelift three years prior to her visit with me. She was referred to my office after expressing an interest in wearing contact lenses again. She reported using lubricating eye drops as needed and started Restasis (Allergan) at her recent exam. She said she wore her eyeglasses for driving, but otherwise did not use corrective lenses because she could not see at near very well with them.

Her entering acuity without correction was 20/70 O.D. and 20/150 O.S. Her near vision was 20/40 O.D. and 20/30 O.S., again without correction. Keratometry showed a K of 43.00 x 45.50 O.U. Her refraction was -4.25 + 2.75 x 30 to 20/25-2 and -5.00 + 2.50 x 135 to 20/20-2. Slit lamp exam revealed corneal staining in both eyes.

After examining JJ, my initial impression was that she was not a good candidate for contact lenses due to her complex RX, her minimal use of glasses and her ocular health. Soft torics, in the form of monovision or multifocals, would likely not work for the above-mentioned reasons. GP lenses might correct her vision acceptably, but would she tolerate them and would they have a negative impact on her ocular health? Although we could have launched her on a regimen to improve her dry eyes, follow up to gauge improvement and then consider contact lenses, this treatment plan did not seem ideal.

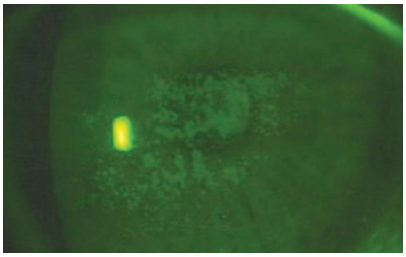

1. Corneal staining O.D.

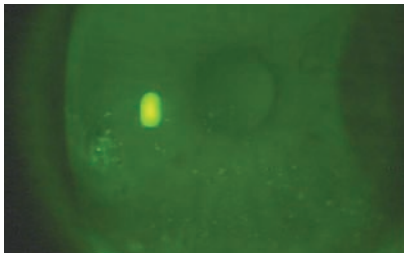

2. Corneal staining O.S.

Contact Lens Therapy

Most practitioners who treat ocular disease likely consider contact lenses to be another complication. I suggest prescribing contact lenses as part of the therapy. I talked with JJ about the option of using scleral lenses to both help her dry eye and correct her refractive error. She was intrigued. When I suggested that perhaps we could add a bifocal to her lenses as well, she was excited.

I chose the Digiform scleral lens N series (Truform) for normal corneas, and achieved a nice fit in each eye with the following parameters: 7.65 base curve, 15.0mm diameter, standard peripheral curves, +2.25 add and 2.0mm near add zone all parameters O.U. in Boston XO. The base prescription was -1.62 in the right eye and 3.00 in the left eye.

I selected the 15.0mm diameter to make sure the lens was optimally centered. With larger lenses, inferior decentration can be more common, which could create problems with a small central near zone.

The Result

JJ reported good comfort and vision—specifically improvement in her distance vision, while maintaining her ability to read. Her acuity was 20/20-2 O.D. and 20/20-1 O.S., 20/20 O.U. at distance. Her near vision was 20/25 in each eye. She was managing to apply and remove the lenses properly, and scheduled a two-week return visit.

At the follow-up, she reported that she was able to wear the lenses for most of the day with good vision and comfort. Her corneal staining, while not resolved completely, showed improvement compared to her pre-fitting condition. Overall, she was doing quite well and was happy.

This case demonstrates the versatility of scleral lenses, and the success you can achieve when you think outside the box. Keep in mind that scleral and corneoscleral lens manufacturers can make bifocal or multifocal design lenses on request.

This series on getting creative with scleral lenses is based on a simple motto: If you can imagine it, you can do it. As the manufacturing capabilities continue to advance, the number of opportunities to use these lenses multiplies. RCCL

Derail Dropouts

By Mile Brujic, O.D., and Jason Miller, O.D., M.B.A.

Taking Stock in Your Astigmatic Options

Understanding the alternative lens options for astigmats.

Astigmatic contact lens wearers are some of the most challenging—and most rewarding—patients to fit with contact lenses. There are a number of astigmatic contact lens designs that work remarkably well for most patients. These include the prism ballasted design of Air Optix for Astigmatism (Alcon), Biofinity Toric (CooperVision) and Purevision 2 for Astigmatism (Bausch + Lomb), all of which can correct up to 2.25D of astigmatism.[1-4] The Acuvue Oasys for Astigmatism (Vistakon) has an accelerated stabilization design that also corrects for up to 2.25D of astigmatism. All of the lenses have large diagnostic fitting sets that allow for most prescriptions to be fit with lenses at the initial office visit.

However, we do occasionally see patients whose astigmatism falls out of the range of parameters for these lenses, or who may benefit from other modalities of astigmatic lenses. This month we will review lens options for these patients who do not conform to traditional toric lens options.

The Daily Disposable Lens

Daily disposable lenses are a one-time only option available to patients requiring spherical lens powers for several years. They are now also available for astigmatics in a wide range of parameters. This lens is an excellent option for part-time wearers, those who suffer from ocular allergies, have sensitivities to lens care solutions or those who prefer the convenience of a new lens everyday.

Dailies Toric (Alcon) lenses are available in the following axes: 180, 020, 070, 090, 110 and 160. They come in both -0.75D and -1.50D of astigmatic power, with spherical power ranging from +4.00D to -8.00D. The lens has markings at both three o'clock and nine o'clock, and the dual thin lens is designed to optimize stability.[5]

Recently released 1-Day Acuvue Moist for Astigmatism (Vistakon) is available in the following axes: 180, 020, 070, 090, 110, 160 and 180, and includes the -0.75D, -1.25D and -1.75D astigmatic powers. For those patients needing 2.25D of astigmatic correction, it is available at the following axes: 180, 020, 090 and 160, and in sphere powers between +4.00 and -9.00D. This lens features an accelerated stabilization design and has lens markings at the six o'clock and 12 o'clock positions.[4]

The Low Toric Option

For patients who have astigmatism less than 0.75D but notice a blur to their vision when fit with single-vision contact lenses, a low toric contact lens option exists. Hydrogel Vision Corporation's Extreme H2O 54% Toric LC features a prism ballasted lens design, made of hioxifilcon D material, that provides 0.65D of cylinder correction.[6] It is available in 30° increments around the clock starting at 30°. These lenses work well for highly acute observers that have less than 0.75D of cylinder correction, and are unsatisfied with the visual acuity they obtain with a spherically equivalent lens.

Specialty Soft Toric Lenses

There are a number of laboratories that can produce custom lathed soft toric contact lens options. Many of the these laboratories specialize in difficult to fit patients and provide the ability to offer a wide array of astigmatic patients optimal correction of their astigmatism through novel hydrogel materials. New to the market within the last year, Definitive material (produced by Contamac) provides the only custom silicone hydrogel material. This material works well for high astigmatic patients wishing to wear soft lenses. This material is available from Art Optical, Metro Optics, Unilens and XCel.[7-10] This breakthrough is an important advancement in custom soft contact lenses as these patients usually have the highest prescriptions, and thus require the benefits of higher oxygen permeability that silicone hydrogel material can offer.

Hybrid Lens Technology

The Duette lens (SynergEyes) is a hybrid produced of a high Dk rigid gas-permeable center surrounded by a silicone hydrogel skirt. It has a number of improvements over its predecessor, Synergeyes A. With the Duette lens, you can assess the fit with regular fluorescein without concerns of it absorbing into the soft skirt component of the lens. The modified design of the Duette lens resembles a more aligned fit with respect to the central RGP portion, compared to it's predecessor, the A lens. The fit is manipulated by

altering the base curve of the soft skirt portion as opposed to the base curve of the RGP portion.[11]

This lens works remarkably well for those astigmatic patients that prefer the quality of vision offered by an RGP with on-eye awareness more similar to that of a soft lens. This lens should be replaced every six months.

The Rigid Gas-Permeable Alternative

There is a place for RGP lenses in any practice that sees astigmatic patients. At times, you will find that your patients do remarkably well with a spherical back surface RGP; the tear lens in these instances will compensate for corneal astigmatism.

Unfortunately, as the amount of astigmatism increases, it becomes harder to correct corneal astigmatism with spherical RGP due to lens flexure. Lens flexure will cause the RGPs to contour to the cornea, decreasing the effective tear lens power created between the posterior surface of the lens and the cornea. In these instances, patients will need additional astigmatic correction because of under-correction secondary to the tear lens.

Either a back surface toric lens or a bitoric lens work remarkably well under these circumstances. In these instances, the posterior surface of the RGP contours more to the curvature of the cornea. This stabilizes the lens on the surface of the eye and also delivers much of the astigmatic power directly through the contact lens, which makes it less dependent on the tear lens. (*Additional information and resources for fitting toric patients with RGP lenses can be found at www.rgpli.org.*)

Corneoscleral lenses are an alternative to traditional small-diameter RGPs. These lenses range from 13mm to 15mm in diameter and are designed to distribute their weight over the cornea and sclera. This weight distribution, plus the fact that these lenses move very little with the blink, helps significantly reduce lens awareness when properly fit. They provide the benefit of an RGP lens correction option for patients with high amounts of corneal cylinder. This is a remarkable option for those patients who benefit from RGP optics, but have a difficult time with adaptation to the lens.

Although we can fit most of our astigmatic patients with traditional soft toric lenses, we are lucky to have a number of viable options for those patients who need alternative options. Taking the time to familiarize yourself with the current market options will help you keep more of your astigmatic patients successfully wearing contact lenses, and reduce the rate of dropouts. RCCL

A Case Study

A 31-year-old Caucasian female wears a two-week replacement toric hydrogel contact lens with the following parameters: 8.6/-6.50-0.75x010/14.4 O.D., 8.6/-5.50-1.25x120 O.S. Subjective refraction results at her most recent visit were: -7.25-1.00x027 20/20 O.D., O.S. -6.50-1.00x170. Her keratometry readings were: 43.00/43.50 @ 105 O.D., 43.00/44.87 @ 070 O.S. Her anterior and posterior segment examination findings were normal.

Over the last several years, we unsuccessfully attempted to refit the patient in a number of silicone hydrogel contact lenses. At her most recent visit she complained of unstable vision with her current lenses. She was considering simply wearing glasses to avoid the issue entirely. We discussed her options and she liked the idea of trying a hybrid lens.

We fit her with Duette contacts with the following parameters: 7.7/med/-7.25/14.5 O.D., 7.7/med/-6.75/14.5 O.S. Initial subjective contact lens awareness was slightly more than with her soft toric lenses. After the lenses were allowed to settle on the eyes for approximately five minutes, the visual acuities were: 20/20 O.D., 20/15-2 O.S. The patient was given the new contact lenses and scheduled for a two-week follow up.

At the next visit, her visual acuities and over-refraction were consistent with our initial measurements. The patient said her quality of vision with the new hybrid lenses was significantly better than her current soft contact lenses.

1. Air Optix. Available at: www.airpoptix.com (accessed Feb 2012).
2. CooperVision. Available at: www.coopervision.com (accessed Feb 2012).
3. Bausch + Lomb. Available at: www.bausch.com (accessed February 2012).
4. Vistakon. Available at: www.jnjvisioncare.com (accessed February 2012).
5. Ciba Vision. Available at: www.dailies.com (accessed Feb 2012).
6. Hydrogel Vision Corporation. Available at: www.hydrogelvision.com (accessed February 2012).
7. Art Optical. Available at: www.artoptical.com (accessed Feb 2012).
8. Metro Optics. Available at: www.metro-optics.com (accessed Feb 2012).
9. Walman Optical. Available at: www.xcelcontacts.com (accessed Feb 2012).
10. Unilens. Available at: www.unilens.com (accessed Feb 2012).
11. Duette. Available at: www.synergeyes.com/duette (accessed Feb 2012).

By Christine Sindt, O.D.

Finding the Right Balance

By increasing tear film stability, we can better treat conditions like dry eye.

To build a better lubricant is the holy grail of ocular surface science. Ideally, a lubricant should address all the components of the natural tears—mucin, water and lipid layers. The lipid layer protects against evaporation. The aqueous portion forms a gel with soluble mucins, and the mucin layer helps spread the aqueous gel over the ocular surface. Finding the right combination of agents in an artificial tear, in a long-lasting formulation, is not an easy task.

How It Works

Some liquids molecules won't mingle because of the difference in attractions. For example, the attractions between water molecules are very strong, whereas oil particles are only weakly held together. The oil molecules can't overcome the strong attractions between the water molecules, so the oil will sit on top of the water. Liquids that do not mix with each other, such as oil and water, are immiscible.

Although some pairs of liquids are immiscible, we can force them together in an emulsion. Instead of forming two separate layers with a clear boundary between them, small droplets of one liquid are spread throughout the other liquid. This can be either a water-in-oil or an oil-in-water mixture.

The theory here is that a few, bigger droplets will have less surface area than many little ones. The less surface area, the less the two liquids have to touch each other—their preferred state. When an emulsion is shaken very hard, the droplet size is made smaller (i.e., salad dressing). Shaking, however, is an inefficient way of making an emulsion. Instead, to keep an emulsion from separating, we add a surfactant—a surface active agent, otherwise known as an emulsifying agent.

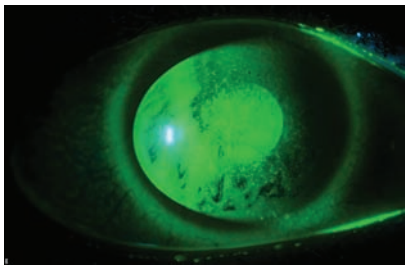

A rapid tear break up time due to insufficient lipid layer.

A surfactant includes a hydrophilic and a hydrophobic portion. The hydrophilic end is water-soluble, while the hydrophobic end is water insoluble or lipophilic. Surfactants align accordingly between the water and oil interfaces, and reduce surface tension. These emulsifying agents absorb quickly around dispersed drops as a condensed, non-adherent film, which prevents coalescence. They impart adequate electric potential so that mutual repulsion occurs.

The small droplets in an emulsion scatter the light passing through it. The result is that the emulsion appears to be either an opaque grey or white. This effect is similar to a bowl of sugar: each individual grain is transparent, but a collection of grains appears white. Emulsion lubricating drops quickly separate upon instillation in the eye, producing only a momentary visual blur. The oil and water components merge with the natural tear layers.

In addition to the air and tear interface, the cornea and tear interface is also important to tear coverage. A hydrophobic ocular surface will cause tear film instability and rapid tear break-up times. A demulcent is an agent that forms a film over a mucous membrane, and is sometimes referred to as mucoprotective or mucomimetic agent. Mucomimetic agents include polyethylene glycol, propylene glycol, hydroxymethyl cellulose, sodium hyaluronate and guar.

Tear-film break-up time (TBUT) is a common clinical test of dry eye conditions. A quick TBUT has been implicated as a mechanism of ocular surface damage. The TBUT positively correlates with the lipid layer thickness and ocular surface hydrophilicity.[1]

There are currently only two emulsion products available on the market: Systane Balance (Alcon) and FreshKote (Focus). We, as practitioners, should be clinically prudent and focus dry eye treatment on increasing tear film stability. RCCL

1. Isreb MA, Greiner JV, Korb DR, et al. Correlation of lipid layer thickness measurements with fluorescein tear break up time and Schirmer's test. Eye. 2003 Jan;17(1):79-83.

By Gary Gerber, O.D.

What Does Success Look Like?

A simple test can help you determine whether your next move is a good business plan.

The Fit

Say you fit your next 10 patients with a new toric contact lens, and one of them says the lenses are uncomfortable or that she can't see as well as she could with her previous lenses. Would you continue to use the lens?

What if two patients complain? Three? Four?

At what point do you make the clinical decision that the lens is a success or a failure, and something you're willing to use or drop from your armamentarium?

As clinicians, we have our own personal definitions of clinical success. We create this based on our particular practice model and experience. For example, a practice that concentrates on extremely difficult fits might consider a patient wearing a lens for five hours each day a smashing success. Meanwhile, a general practice with a normal bell curve of patients would consider five hours of wear an abysmal failure.

The Practice

We recently had a client ask us if he should use a patient appointment reminder service. We told him that these services work well for most of our clients, but not all of them—as is the case with most practice building initiatives.

First, we suggested that he set up a test by turning the plan on for two months and measuring how well it worked.

Gauging the success was the most difficult part of this test and required determining the parameters in advance. This included determining what percentage of patients responding to the reminders would be considered worthwhile.

I suggested using the success rate of their current method of reminding patients as a baseline. In the above client scenario, we set a goal to either increase the response rate or decrease the practitioner's current cost by at least 20%.

> *"Defining your parameters for success prior to starting a new venture is a smart strategy, and can be applied to just about any area of your practice."*

When Failure Means Success

After two test months, we determined that while the cost of the new technique was slightly lower than the old method, the response rate was also less. We decided to table the initiative and try another provider of a similar service. The results were nearly the same. We concluded that his current method was the most successful—according to our previously defined parameters.

In this case, it was clear that the technology wasn't in our client's practice best interest. Although the technology was a failure, the test was successful.

Defining your parameters for success prior to starting a new venture is a smart strategy, and can be applied to just about any area of your practice. For example, I suggest defining your practice's overall growth at the beginning of each fiscal year. Set concrete milestones. Is a 3% increase of your collections considered good? If they grow 10% and your net increases 4%, is that acceptable? What about patient count? If your net increases 20%, and patient count increases 6%, what does that mean?

The same thoughts apply to staff. If a staff member is paid $14 per hour and asks for a $2 an hour raise, how does this affect your practice? If you let an employee go and are forced to cut your patient care schedule back by three hours per week, will that negatively impact your practice?

Just as with clinical cases, the answers to the above questions aren't always straightforward. Therefore, I strongly advise creating a pre-determined range of what you would consider acceptable, taking into account all the variables before outlining your test strategy.

Ultimately, this will help you effectively decide whether you are making the right move. RCCL

Down on the Pharm

By Jill Autry, R.Ph., O.D., and Elyse Chaglasian, O.D.

Ease the Frustration: Treating RK

Try these pharmaceutical pearls on your next radial keratotomy patient.

Dealing with an irregular cornea can be frustrating for both the patient and doctor. Unfortunately, little compares to the frequency of irregular corneas and the associated complaints found in the post-radial keratotomy (RK) patient. The once young, myopic patient is now older—usually hyperopic, presbyopic, with irregular astigmatism and mild to moderate lenticular changes. They often report glare and/or halos, daily fluctuating Rx changes, distorted vision and dry eye. As eye care practitioners, we have all seen these patients in our offices as they seek answers to alleviate their particular visual complaints.

In addition to the usual RK armamentarium of glasses, soft contact lenses and/or RGP lenses, we have gathered a few pharmaceutical pearls to offer some relief for the disheartened RK patient. Keep in mind that studies in this patient population are rare, and there is little printed support for these recommendations. Each patient may report a different success rate. These treatments are considered off-label, but then again, so are many of the indications for which we pharmaceutically treat on a daily basis.

Glare and Halos

Glare and halos are some of the most common complaints from the post-RK patient whose irregular cornea creates a multitude of surgically induced aberrations, including spherical aberrations, coma and trefoil. As you would expect, these complaints are most intense with night driving and other low light activities. Many practitioners use brimonidine off-label for its alpha-agonist effect on the dilator muscle, which keeps the pupil smaller and can decrease the glare and halo in patients with increased aberrations from RK.

One study found the use of brimonidine 0.15% would produce a 1.0mm or more pupillary constriction in a majority of patients under both scotopic and mesopic conditions with less of an effect on photopic pupil size.[1]

This treatment has also been successful with post-LASIK patients with similar glare complaints and with multifocal patients who complain of halos postoperatively. We recommend Alphagan-P 0.1% (brimonidine tartare ophthalmic solution, Allergan), one drop 30 minutes to one hour before night driving. Literature also suggests the use of brimonidine for night vision complaints.[2]

Any of the brimonidine products will work, however the 0.1% formulation has the lowest risk of ocular allergy documented at 10%. Alphagan P 0.1% also has the fewest systemic side effects of the product line including somnolence, a concern when recommending its use before driving at night.[3] We do not recommend diluting pilocarpine for miosis as the parasympathomimetic side effects such as brow ache and accommodative spasm are not found with an alpha-agonist.

Dry Eye

Many RK corneas not only exhibit surgically induced aberrations and irregular astigmatism, but exhibit changes due to the loss of normal corneal nerve architecture.[4] Depending on the number of radial incisions the number of transverse incisions, subsequent laser refractive treatments and the age and gender of the patient, dry eye can exacerbate the fluctuating vision and irregular topography characteristic of RK. One study using interferometry demonstrated irregular epithelial and topographical changes post-LASIK and post-RK, which may account for the poor tear stability and increased tear break-up times (TBUT) noted clinically in this patient population.[5]

The tear film is the most anterior refractive surface of the eye and must be adequate even in normal, non-surgical patients. In RK patients, the tear film proves even more important to avoid exacerbating an already compromised optical system. Don't forget to treat even mild tear deficiencies in production and/or quality. Restasis (cyclosporine ophthalmic emulsion 0.05%, Allergan), punctual plugs and omega-3 fatty acids are a few examples of treatments that can be paramount in helping your patient's post-RK quality of vision and ability to comfortably wear contact lenses.

Prescription Variation

Prescription changes throughout the day are well documented in post-RK patients, and are believed to correlate with normal diurnal changes in IOP.[6,7] What is negligible

to an intact cornea, however may cause profound changes in Rx for some post-RK patients. This raises the question: If we stabilize or maintain a consistent IOP throughout the day, would the Rx also stabilize? In patients who self report a varying Rx over the course of the day and may present to you two separate morning and afternoon pairs of glasses, consider once-daily latanoprost off-label to stabilize IOP.

We all know prostaglandins have a great pharmacological profile in regards to decreasing mean IOP, as well as variations in IOP throughout a 24-hour period. It is used once-daily with few side effects—now available in generic with little hyperemia compared to its counterparts. Patients with ocular hypertension, suspected glaucoma cases or already diagnosed with glaucoma tend to have the largest IOP fluctuations and may benefit the most from this treatment in more ways than one.

It has been proposed that diurnal variations are worsened by nighttime corneal edema. Although this occurs naturally (to a small amount) in non-surgical corneas, corneal edema may produce a more pronounced effect in an RK patient. The use of an osmotic agent such as Muro-128 5% (sodium chloride hypertonicity ophthalmic ointment 5%, Bausch + Lomb) at bedtime may also help to stabilize the hyperopic to myopic diurnal prescription shift that is typical post-RK.

Although RK patients can be challenging, we hope these pharmaceutical pearls might make dealing with their complaints less frustrating. RCCL

1. Thordsen JE, Bower KS, Warren BB, Stutzman R. Miotic effect of brimonidine 0.15% ophthalmic solution in normal eyes. J Cataract Refract Surg. 2004 Aug;30(8):1702-6.
2. Edwards JD, Burka JM, Bower KS, et al. Effect of brimonidine tartrate 0.15% on night-vision difficulty and contrast testing after refractive surgery. J Cataract Refract Surg. 2008 Sept;34(9):1538-41.
3. Allergan. Alphagan P 0.1%. Available at: www.alphaganp.com (accessed March 2012).
4. Namavari A, Chaudhary S, Sarkar J, et al. In vivo serial imaging of regenerating corneal nerves after surgical transection in transgenic Thy1-YFP mice. Invest Ophthalmol Vis Sci. 2011 Oct 11;52(11):8025-32.
5. Szczesna DH, Kulas Z, Kasprzak HT, Stenevi U. Examination of tear film smoothness on corneae after refractive surgeries using a noninvasive interferometric method. J Biomed Opt. 2009 Nov-Dec;14(6):064029.
6. Schanzlin DJ, Santos VR, Waring GO, et al. Diurnal change in refraction, corneal curvature, visual acuity and intraocular pressure after radial keratotomy in the PERK study. Ophthalmology. 1986 Feb;93(2):167-75.
7. Kemp JR, Martinez CE, Klyce SD, et al. Diurnal fluctuations in corneal topography 10 years after radial keratotomy in the prospective evaluation of radial keratotomy study. J Cataract Refract Surg. 1999 July;25(7):904-5.

By Gina M. Wesley, O.D., M.S.

OPTI-FREE® PureMoist® MPDS and CLEAR CARE® Cleaning and Disinfecting Solution: Two Great Solutions

Our contact lens patients today expect comfort, a lens that doesn't dry out and great vision. With the multitude of contact lens care options available to us today, gone are the days of plugging in the heating unit and hoping the care system be gentle enough to make the lens last the year, or longer. Today's lenses and lens care products have greatly simplified the process. Lens care can be almost effortless, as long as the right lens care system is recommended.

As the technology of contact lenses has advanced to allow greater oxygen breathability, new challenges arise. In order to make the silicone hydrogel lens wettable, new surface treatments and material technologies have been developed. Yet it is reasonable to expect that special materials and surfaces may not be ideal with older lens care products.

Two products that emerge as great companions to silicone hydrogel lenses are Clear Care® Cleaning and Disinfection Solution, and OPTI-FREE® PureMoist® MPDS.

Two great solutions and two excellent options for patients—but which solution should you use and when? The newest in the OPTI-FREE® line of solutions, PureMoist® MPDS represents the most advanced science in multipurpose soft contact lens care systems that we have today. The proprietary HydraGlyde® Moisture Matrix was specifically created to optimize the wear of silicone

hydrogel lenses. This makes it an ideal first choice for neophyte lens wearers in your practice. Studies with OPTI-FREE® PureMoist® MPDS have clinically shown to provide comfort and moisture from morning to night.[1,2] This solution assists the practitioner in giving the new contact lens wearer a successful lens wearing experience.

OPTI-FREE® PureMoist® MPDS draws moisture from the solution itself, and maintains that moisture on the lens while being worn in the ocular environment. In a clinical study, OPTI-FREE® PureMoist® MPDS has improved the wearing experience of even asymptomatic contact lens wearers.[2] It has also been proven to reduce lipid deposition,[3] which can be an issue with some silicone hydrogel lenses. An eye care professional can have a huge impact on even the most seasoned lens wearer by simply prescribing the newest in lens care technology. Increased comfortable wear time may reduce contact lens dropouts, which could have a significant financial impact on a practice.

While OPTI-FREE® PureMoist® MPDS is a recent addition that has been specifically formulated for use with silicone hydrogel lenses, CLEAR CARE® Cleaning and Disinfection Solution has been the trusted leader of hydrogen peroxide lens care for the last 10 years. This solution can be confidently recommended to patients with sensitive eyes, those who may demonstrate moderate conjunctival hyperemia and those who report awareness of lenses with routine wear. Additionally, CLEAR CARE® Cleaning and Disinfection Solution is an ideal option for those who suffer from solution-related sensitivities, as the neutralized peroxide contains no added preservatives. The one-step hydrogen peroxide system is also ideal for patients who experience significant deposition and build-up on their lenses. The triple-action cleaning system makes it an excellent and versatile option for daily lens care as it is ideal for traditional soft, silicone hydrogel, and even RGP lens wearers.

Recommending the appropriate care system for our patients has never been easier. Educate your patients on how to appropriately care for their new lens technology. You have not one, but two great options to meet the needs of the majority of your patients.

1.Garofalo R, Lemp J. Clinical Trial Experience with Opti-Free PureMoist MPDS. Contact Lens Spectrum. September 2011.
2.Campbell R, Kame G, Leach N, et al. Clinical benefits of a new multi-purpose disinfecting solution in silicone hydrogel and soft contact lens users. Eye & Contact Lens 2012; Publish-ahead-of-print.
3. Senchyna M, Stauffer P, Davis J, et al. Characterization of a multi-purpose lens solution designed for silicone hydrogel materials. Invest Ophthalmol Vis Sci. 2010;51:E-Abstract 3426

How Technology Can Help the Irregular Cornea

Recent advances can significantly improve the practitioner's ability to treat corneal irregularities.

By Gregory W. DeNaeyer, O.D., and S. Barry Eiden, O.D.

Corneal irregularity can be an unfortunate result of corneal disease, trauma or surgery. Depending on severity, an irregular cornea will reduce a patient's best-corrected visual acuity with glasses or standard soft contact lenses. However, patients are often able to regain functional vision with the use of specialty soft or gas-permeable (GP) designs. Recent advances in instrumentation have significantly improved practitioners' ability to diagnose, measure and manage patients with corneal irregularity. The four primary categories of advanced technology include: topography, aberrometry, optical coherence tomography and Scheimpflug imaging.

Topography

The ability to measure the corneal front surface is an essential component of irregular corneal diagnosis and management. Taking measurements with a keratometer is insufficient, as it is limited to a 3mm to 4mm central zone and curvature measurement of two primary meridians. In addition, the mires of a keratometer are often unreadable as corneal irregularity worsens.

The gold standard for measuring front surface corneal irregularity is videokeratography or corneal topography. Corneal topographers are able to, in some cases, measure in excess of 10,000 data points across the entire corneal surface. A dioptric map of the corneal surface is the primary evaluative tool that a topographer offers the contact lens practitioner. Dioptric values are represented by a relative color-coded scheme. The clinician can use the resultant pattern to interpret, diagnose and classify the corneal irregularity.

There are two basic types of dioptric maps: sagittal and tangential. Sagittal maps, also called axial maps, are set up with algorithms that assume the cornea is spherical, which makes them less accurate for peripheral corneal evaluation and measurement. Tangential maps are based upon instant radius of curvature, making them inherently more accurate for diagnostic and lens fitting purposes.[1]

Corneal classification based upon topography allows the practitioner to more efficiently fit an eye with irregularity because the shape of the cornea plays a critical role in determining the type of design that will work best for the patient. For example, a patient with an oblate cornea will probably do

Dr. DeNaeyer is the clinical director for Arena Eye Surgeons in Columbus, Ohio. His primary interests include specialty contact lenses. He is also a consultant and advisor to Visionary Optics, Bausch + Lomb and Aciont.

Dr. Eiden is the president and medical director of North Suburban Vision Consultants, Ltd., co-founder and president of Eye-Vis Eye and Vision Research Institute and teaches at the University of Illinois at Chicago Medical Center and Indiana, Illinois, Salus and UMSL colleges of optometry.

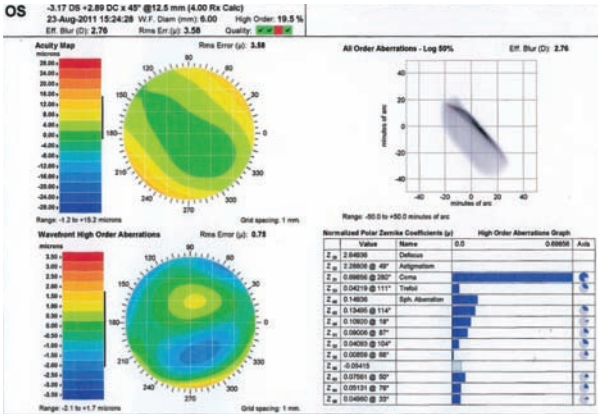

1. Wavescan measurement.

best with a reverse geometry design or a patient with mild keratoconus may do best with an aspheric back surface corneal GP design.

Practitioners often use corneal topographic data to help predict the first diagnostic lens to trial after choosing a specific lens design. It is customary for a manufacturer's fitting guide to recommend an initial diagnostic lens based upon a formula that uses simulated keratometry measurements taken from corneal topography.

In a 2010 study, Luigina Sorbara, O.D., M.Sc., showed improved success by using tangential topographic data in determining the back optic zone diameter in tandem with the overall diameter when fitting corneal GP lenses for keratoconus.[2] However, keep in mind that many specialty lens designs are based upon sagittal depth of the anterior ocular surface (cornea and sclera) and dioptric topographical results are probably not much help when choosing the first diagnostic lens. For example, in another 2010 survey, Graeme Young, B.Sc., M.Phil., and colleagues, found that although placido-based topography was a better predictor of base curve for soft lens fitting compared to keratometry, topography still wasn't reliable enough for accurate base curve selection.[3] Muriel M. Shornack, O.D., and Sanjay V. Patel, M.D., found only a weak predictive relationship between base curve selection for a scleral lens design and topography.[4] So, although topographical dioptric results are essential for diagnosing and classifying the type of corneal irregularity, they may not be always useful in base curve selection for diagnostic lens fitting.

Some topographers are able to produce an elevation map of the cornea based on a reference sphere, which helps to predict areas of potential clearance or bearing for corneal GP lenses. In addition, many topographers have software that will allow the clinician to virtually fit a cornea GP lens based upon topographical results. Empirically fitting GP lenses this way has the potential to dramatically improve fitting efficiency. With this technology, the practitioner can virtually alter design parameters and observe how changes might affect the lens fit.

Christine Sindt, O.D., and colleagues conducted a study to evaluate virtual fittings of keratoconus.[5] The aim of the study was to determine how close virtually produced fluorescein patterns correlated with actual fluorescein patterns in 31 keratoconous patients who were fit using a bi-aspheric keratoconic design. They found that 74% of eyes showed a good match between theoretical and actual fluorescein patterns.[5] Ultimately, the success of these results hinged on the ability of the topographer to produce a quality ring reflection from the placido disc. In fact, when looking at the cases where a quality ring image was produced, there was a 95% accuracy between the virtual prediction and the actual results.[5]

Keratoconic severity, corneal scarring and tear break-up can all contribute to poor ring quality. It's also important to remember that virtual fitting patterns do not account for lid interaction, which can significantly affect the fitting relationship of a corneal GP lens.

Aberrometry

Irregular corneal astigmatism induces higher aberrations to the visual system that are not corrected for by glasses or standard contact lenses. Depending on severity, these aberrations can lead to significant visual disability. With modern instrumentation, we can quantify aberrations that fall outside the lower bounds—such as defocus and astigmatism—that practitioners routinely measure.

One of the primary methods of measuring higher-order aberrations

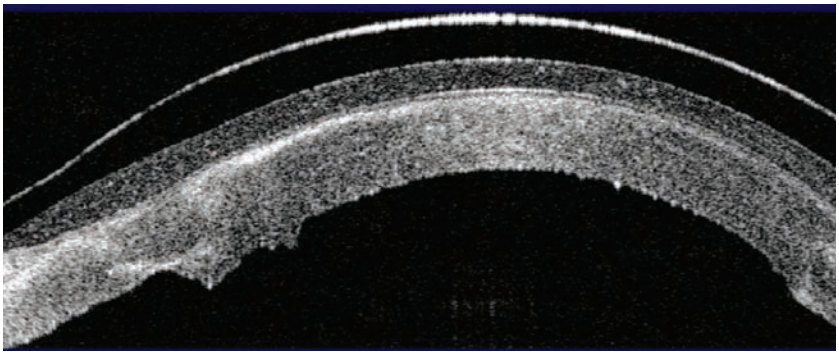

Photo: Bruce Baldwin, O.D., Ph.D.

2. OCT image of a scleral lens vaulting the corneal surface.

3. Oculus Pentacam.

involves Shack-Hartmann principles, which produces a measurable wavefront. For an emmetropic eye without any aberrations, the resulting wavefront of light will be flat.[6] Any lower- or higher-order aberration will cause the wavefront to distort, which can then be represented mathematically as root mean square (RMS), color-coded map or point spread function (*figure 1*).

Each specific type of aberration can be mathematically represented by what is known as a Zernike polynomial. The common higher-order Zernike polynomials have names such as spherical, coma and trefoil. Typically, contact lens practitioners rely on GP or specialty soft contact lenses that are able to mask higher-order aberrations caused by front surface corneal irregularity.

Although most irregular corneal patients are able to achieve functional vision with these specialty lens designs, many of them will still have less than perfect visual acuity. Some patients, especially those with keratoconus, may complain of ghosting, halos and/or glare resulting from uncorrected back surface corneal irregularity that is not corrected for by their specialty lens.[7,8]

Current technology can produce custom contact lenses that incorporate residual higher aberration control for individual patients. In 2007, Jason D. Marsack, M.S., and colleagues reported on a case of a habitual soft lens-wearing patient with moderate keratoconus who was fit with wavefront-guided soft contact lenses.[9] The patient showed 1.5 lines of visual acuity improvement and a 50% reduction in higher-order aberrations. Costas F. Katsoulos and colleagues showed improvement in visual performance for two keratoconic patients who wore customized hydrogel contact lenses implementing correction for vertical coma.[10]

Although the technology to measure and implement higher-order aberration correction into contact lenses is currently available, there are three hurdles that must be accounted for in order to maximize success.

• *A successfully fit GP or soft contact lens is going to have on-eye translation and rotation that can induce higher aberrations*. For example, a decentered lens that incorporates aspheric optics to control for spherical aberration can induce coma, which can nullify expected improvement.

John De Brabander, Ph.D., and colleagues advise that translation errors should not exceed 0.5mm, after reporting translation errors significantly affected performance on a simulated optical performance of custom wavefront soft contact lenses for keratoconus.[11] Because it is expected that contact lenses will experience these translations and rotations, Antonio Guirao, Ph.D., and colleagues suggest partial correction of every aberration term in order to minimize induced wavefront aberrations.[12]

• *Not all aberrations affect the eye equally*. For example, coma negatively affects vision by a factor of two as compared to spherical aberration.[6] Some Zernike modes may interact when combined to improve visual acuity despite increasing the total wavefront error.[13,14] Therefore, trying to completely reduce one or all aberrations may not maximize the patient's success.

• *Patients may build up tolerance*. Patients who have a long-standing history of uncorrected higher-order aberrations may have neurally adapted to their visual blur and may not be able to immediately appreciate the improved optics.[15,16]

Optical Coherence Tomography

Optical coherence tomography (OCT) is able to produce two-dimensional cross-sectional images of the anterior ocular surface. These high-resolution images allow for detailed analysis of the corneal layers. Diagnostically, this provides magnified visualization and biometric measurement. The OCT instruments being developed today have the ability to perform both anterior and posterior segment measures, which means that practitioners only need to purchase one instrument to gain two highly useful technologies. Examples of these combination systems include the Cirrus (Carl Zeiss Meditec), the RTVue (Optovue) and the 3D OCT (Topcon). Anterior segment OCT is still pending FDA approval.

OCT imaging of the cornea and sclera has the potential to improve the evaluation and design of contact lenses (*figure 2*).[17,18] Greg Gemoules, O.D., reported on nine patients that were successfully fit with scleral GP lenses utilizing sagittal depth and chord measurements obtained taken from a Visante OCT (Carl Zeiss Meditec).[18]

For the ICD scleral lens design, the practitioner can use either sagittal depth measurement from an OCT or weighted height measurement from a Medmont topographer

to choose the initial diagnostic lens. The future of this technology will someday allow for a single measurement that will profile the anterior segment, so that an empirical soft or scleral lens can be customized directly from the collected data.

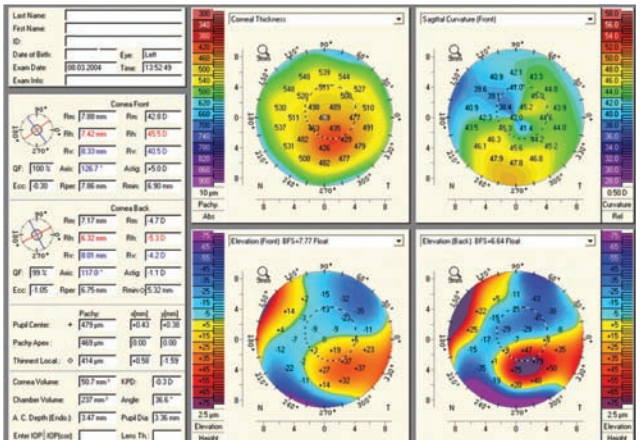

4. Pentacam readout of a keratoconus patient.

Scheimpflug Imaging

Tomography is the creation of a 2-D image from a slice or section through a 3-D object. Certain instruments utilize a specific technique of imaging called Scheimpflug imaging, which has the advantage of extending the depth of focus—a 2-D image capture can create a 3-D construct. The most widely used example of such technology is the Pentacam (Oculus); other devices include the Galilei (Ziemer) (*figure 3*).

This technology is quite diverse in its clinical applications. Advantages include the ability to collect 360º imaging of the anterior segment, both anterior and posterior corneal elevation-based topography, global corneal pachymetry, anterior chamber analysis, anterior segment optical densitometry, IOL planning and contact lens design based on anterior segment tomography. As such, the applications are far reaching into areas of corneal analysis, cataract management, glaucoma analysis and IOL planning.

The most widely used application of Scheimpflug technology is the ability to detect corneal ectasia (*figure 4*). Due to the measurement of posterior corneal elevation and global pachymetry, abnormalities associated with ectasia are exquisitely detected, quantified and monitored. Specific software programs such as the Belin/Ambrosio II on Pentacam have the ability to clearly differentiate normal from ectatic corneas, thus allowing for earlier detection of ectasia and avoidance of performing keratorefractive procedures on patients who may be poor candidates (*figure 5*). Belin has recently utilized Pentacam to differentiate pellucid marginal degeneration from keratoconus with a pseudo-PMD anterior corneal topography through the analysis of global pachymetry.[19]

Advances in instrumentation have significantly improved the diagnostic and fitting success for irregular corneal management. Practitioners can utilize topography-based software that enables virtual contact lens fitting. Ultimately this can improve efficiency, especially for the novice contact lens practitioner.

Scheimpflug tomography allows for comprehensive corneal and anterior segment analysis with unique evaluation of the posterior corneal surface and global pachymetry, while aberrometry can quantify corneal irregularity. These measurements can then be used to add higher-order aberration control to contact lenses to improve visual outcomes. Ocular coherence tomography will improve design and fitting success for soft and scleral type lenses used for difficult cases. RCCL

Dr. Eiden is a consultant for Oculus.

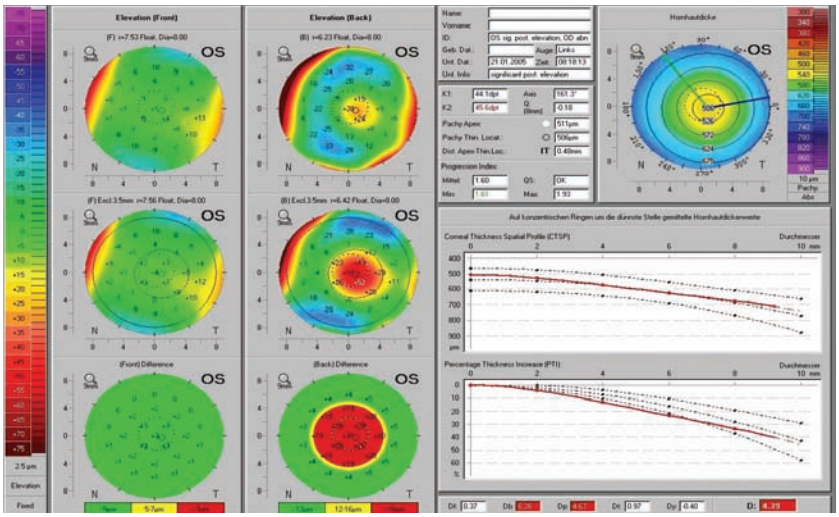

5. Bellin ambrosion BAD II ectasia.

1. Rabinowitz YS. Tangential vs sagittal videokeratographs in the "early" detection of keratoconus. Am J Ophthalmol. 1996 Dec;122(6):887-9.
2. Sorbara L, Dalton K. The use of video-keratoscopy in predicting contact lens parameters for keratoconic fitting. Cont Lens Anterior Eye. 2010 Jun;33(3):112-8.
3. Young G, Schnider C, Hunt C, Efron S. Corneal topography and soft contact lens fit. Optom Vis Sci. 2010 May;87(5):358-66.
4. Schornack MM, Patel SV. Relationship between corneal topographic indices and scleral lens base curve. Eye Contact Lens. 2010 Nov;36(6):330-3.
5. Sindt CW, Grout TK, Kojima R. Evaluating virtual fitting for keratoconus. CL Spectrum. 2011 May. Available at: www.clspectrum.com/articleviewer.aspx?articleid=105575 (accessed March 2012).

Additional references at www.reviewofcontactlenses.com.

Taking a Wholistic Approach to Refractive Therapy

The standard of care for our myopic patients is evolving and, as practitioners, it is our responsibility to collect and present all the information we have available.

By Jerome A. Legerton, O.D., M.S., M.B.A.

There is an expressed need today to create new evidence-based standards of practice to manage the development of refractive error around the globe. Due to the growing prevalence and the far-reaching economic impact and sequelae of myopia, the primary emphasis has been on what some call myopia control, which may only be a subset of the greater field of refractive therapy.[1,2] While the bulk of the work concentrates on myopia, some of the strategies also appear to have value in regulating the development of hyperopia and astigmatism.[3,4]

A group has been formed with the purpose to gather all evidence relating to myopia control in an effort to establish a recommended standard of care and educate practitioners. The ultimate mission is to reduce the incidence and prevalence of myopia through timely intervention by eye care practitioners worldwide. Under the leadership of Richard Anderson, O.D., the group is working to generate a document entitled, "Evidence-Based Clinical Practice Guideline for Juvenile Myopia."

Pick Your Clinical Strategy

Jeffery Walline, O.D., Ph.D., compiled a useful table for reporting the results of a number of randomized, controlled and published studies investigating the impact of clinical strategies for myopia control (*figure 1*).[5] This table shows that the strategies which appear to have value are the use of muscarinic antagonists, bifocal soft lenses and corneal refractive therapy. Single-vision spectacle, bifocal spectacle, progressive addition spectacle, single-vision rigid gas-permeable and single-vision hydrogel contact lenses have all failed to show significant ability to regulate myopia development. Myopia development may be exacerbated or accelerated by under-correction and GP lenses.

Because the current standard of prescribing single vision spectacle lenses may be contraindicated as being neither protective or preventive, there is an interest to define a new standard of care. In fact, a recent study concluded that 0.01% atropine appears to be as effective as the previously prescribed 1%, while eliminating the side effects of long-term use

Dr. Legerton is an author, lecturer, inventor and consultant to the ophthalmic industry. He is a cofounder of SynergEyes and Innovega, and has 32 issued U.S. patents for contact lens technology including SynergEyes, Paragon CRT, myopia progression control, presbyopic laser refractive surgery, and novel multifocal contact lenses. His most recent patent is assigned to Innovega for the iOptik contact lens enabled wearable computer. He has no financial interest in the technology discussed as all patents are assigned royalty free.

of the higher concentration.[6] The discovery unveils a new treatment option for patients with emerging myopia.

Peri-Form and Peri-Focus Lenses

There are two related contact lens strategies at the center of the myopia control discussion. Peri-form results from reshaping the cornea following corneal refractive therapy for myopia. The peri-form cornea is oblate, rather than the normal prolate corneal shape (*figure 2*). The mid-periphery of the cornea has a shorter radius of curvature than the central or apical radius. A close examination of the topography of post-treatment peri-form corneas demonstrates an increase in the spherical aberration of the eye compared to the pre-treatment measure of spherical aberration.[7,8]

Peri-form myopia control can be addressed through an increase in positive spherical aberration or from the relative myopic peripheral defocus resulting from the post-treatment cornea. There may be other mechanisms involved in the apparent positive effect in regulating the development of myopia from corneal refractive therapy.

There is evidence that supports a correlation between peri-form treatment and the regulation of myopia.

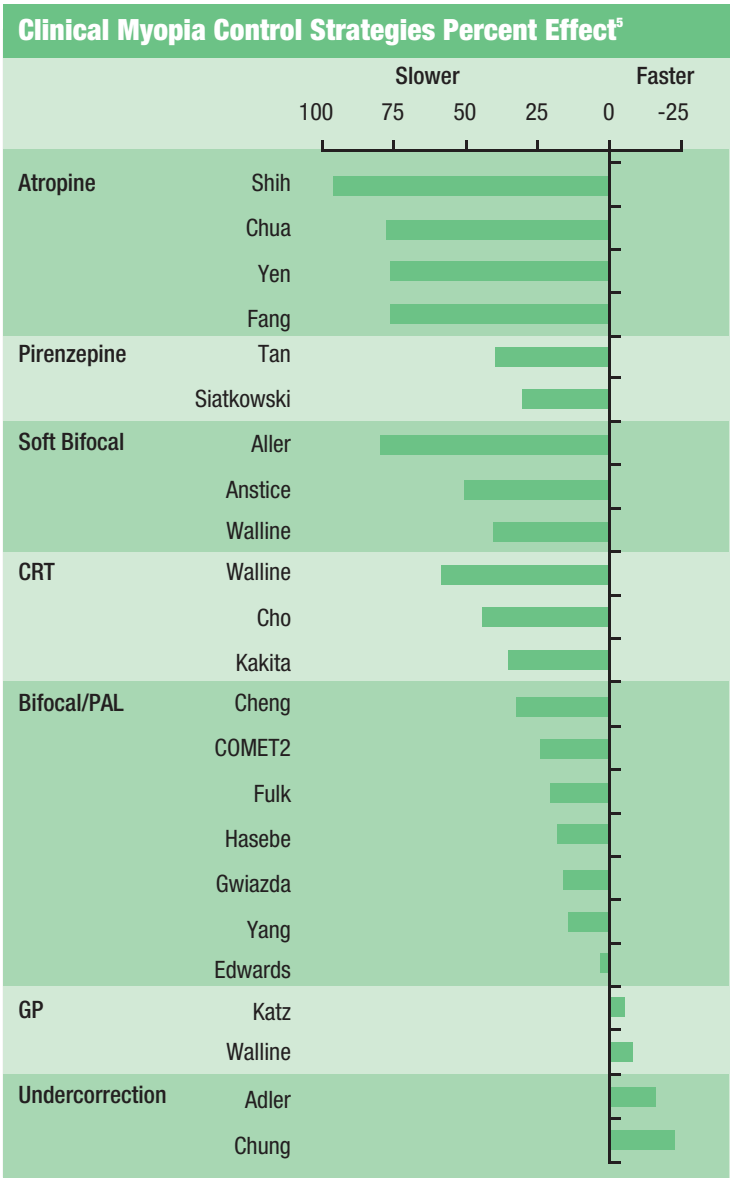

1. Literature summary of the effects of clinical strategies on the progression of myopia, summarized by Dr. Walline, but formatted from most positive to most negative.

Three independent reported longitudinal studies by Pauline Cho, Ph.D., Dr. Walline and Tetsuhiko Kakita, M.D., share the same conclusions of reduced vitreous chamber depth growth in eyes undergoing corneal refractive therapy compared to control groups wearing conventional spectacle or contact lenses.[9-11] In each case, the standard deviation of the corneal reshaping group is relatively high, indicating that some eyes enjoy better control of the growth than others. The mean growth in the corneal reshaping groups remained significantly lower than the control groups; however, some eyes did show myopia progression.

Dr. Kakita further observed that the control of growth was greater the higher the initial refractive error. This raises concerns for the effectiveness of current corneal reshaping lenses for eyes with low or emerging myopia. William Meyers, Ph.D, and I have described lens design requirements for forming the peripheral cornea of an eye with emerging myopia without changing the central cornea.[12] Causation, along with the precision of the treatment for all eyes, has not been established.

Earl Smith, O.D., Ph.D., and colleagues used an animal study to support the clinical observations of reduced axial length growth and reduced progression of myopia in patients who have continued in programs of overnight corneal reshaping.[13] Research using foveal ablation and peripheral defocus demonstrates promise for a peri-focus strategy, where the peripheral defocus is controlled by the optics of spectacle or contact lenses.

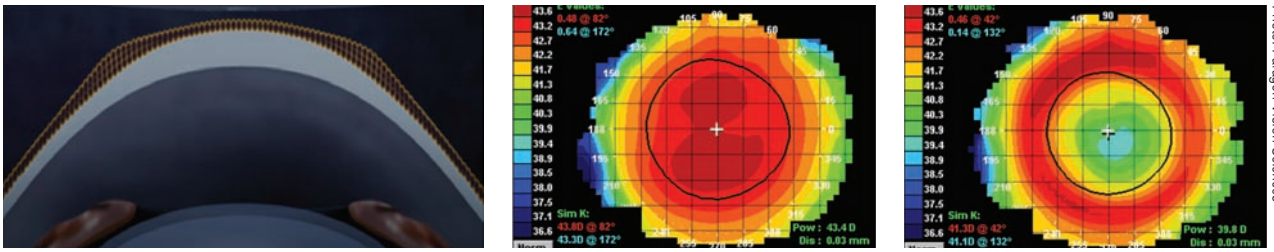

Photo: Paragon Vision Sciences

2. Change in shape and optics of anterior cornea from prolate to oblate with corneal refractive therapy.

The first peri-focus spectacle lens study reported weak, yet positive, results in controlling the development of myopia and suggested the need for further investigation.[14] Another early peri-focus contact lens study also reported weak, but positive, results in controlling the development of myopia.[15] Dr. Smith recently reported concern for the peripheral defocus model alone, and suggested that concern for the foveal optics may also be an issue.[16] The role of spherical aberration may also be an important element, along with peripheral defocus.

Even so, clinicians have an opportunity to prescribe peri-focus contact lenses in the form of distance-center multifocal contact lenses. They should pay particular attention to understanding the lens designs of current multifocal lenses. Many of the lenses available today are center-near multifocal designs. These would not have the optics that approximate the peri-focus lenses indicated for correcting peripheral hyperopic defocus. The intention, as taught by the proponents of peripheral defocus is to have central optics that focus axial light onto the fovea, while having peripheral optics which focus off axis light in front of the retina.[17] Hence, a distance center multifocal is required to meet this intended strategy; a center-near multifocal would do the exact opposite and would be contraindicated.

The role of measuring the peripheral refraction is a key element of modulating peripheral focus. Auto-refractors can be harnessed to measure the peripheral refraction (*figure 3*). Keep in mind that if you have 10 eyes with 3.00D of myopia, each may have a different peripheral refraction. The peripheral refraction is a function of the shape of the globe and the crystalline lens. The equatorial diameter can be larger or smaller while the axial length may be the same. Often, myopic eyes are more prolate, which is understandable because they have a smaller equatorial diameter but a longer axial length. This prolate shape can cause the resultant peripheral hyperopic defocus. Hyperopic eyes are known to be less prolate, or more round, when comparing the equatorial diameter to the length.

The peripheral crystalline lens geometry also contributes to peripheral defocus. A crystalline lens that decreases in power peripherally will contribute to the peripheral hyperopic defocus. Because each eye can be unique, there will not be one peri-focus lens design and one add power capable of providing the same peripheral focus relative to the peripheral retinal location and/or crystalline lens geometry for all eyes.

The region of primary concern for peripheral refraction is about 30º from the fovea. A peripheral refraction can be conducted with an auto-refractor and by creating eccentric fixation targets that are 30º nasal and temporal from the straight-ahead fixation of the instrument. In this manner, a central refraction can be conducted in the conventional manner and then a 30º nasal refraction and a 30º temporal refraction would follow. The comparison of the values will give an estimate of the peripheral defocus for the individual eye. It is easier to have patients turn their heads to allow their eyes to point straight at the eccentric fixation targets.

This procedure also can be conducted with a contact lens in place. There is value in measuring the central refraction and higher order aberrations with contact lenses. This will allow testing different brands of single vision lenses for the desired lens-eye spherical aberration. Then a peripheral refraction can be measured in the nasal and temporal 30º fields to measure the peripheral defocus. The same procedure can be conducted with a distance center multifocal lens in place (*figure 4*). Each eye may require a different optical design to achieve a desired spherical aberration and/or a desired peripheral focus.

It should be noted that several patents have been issued that claim the use of contact lenses and spectacle lenses for myopia progression control. The order and supply of lenses for this purpose could infringe the issued patents as the lenses and methods of prescribing are specified and claimed.[18-21]

The Importance of Outdoor Activity

Lisa Jones, O.D., Ph.D., and colleagues reported a correlation of

3. IProfiler Plus (Carl Zeiss Vision) combination instrument can measure on axis spherical aberration, off-axis peripheral refraction and corneal topography for peri-form and peri-focus refractive therapy clinical intervention.

decreased myopia with increased outdoor activity.[22] The protective relationship is significant and supports the importance of recommending outdoor daytime activity when consulting with parents about their children before myopic onset.

Remember that correlation and causation may not be the same. There may be continued work to study the finite elements of the multifactorial phenomenon of outdoor vs. indoor activity and lifestyle (i.e., the roles of the higher light level alone, ultraviolet light, physical activity and ocular motility, accommodation, gaze, saccades and vergence, and near-centered task differential between activities).

Historically, the role of form deprivation—where the peripheral retina of test eyes was occulted—resulted in the rapid development of myopia with concomitant increased vitreous chamber depth. Early animal studies by Christine Wildoset, O.D., Ph.D., and colleagues, as well as recent studies by Dr. Smith and colleagues, reported the ability to modulate eye growth by regulating the retinal luminance in indoor studies.[23,24] This discovery is consistent with the above mentioned outdoor activity correlation and may suggest a mechanism for the role of outdoor activity in regulating myopia as increased light passing into the eye.

Donald Mutti, O.D., Ph.D., and colleagues reported myopic patients were found to have lower vitamin D intake and vitamin D blood serum levels than those without myopia.[25] Research is being conducted to evaluate whether there is a connection between outdoor activity and vitamin D blood serum levels, as well as to connecting vitamin D with ocular growth.

Indications for Contemporary Clinical Practice

Generally, myopia is a nuisance and reduces the quality of life of our patients. Specifically, higher myopia is associated with secondary ocular disease. The earlier the onset, the higher the myopia is forecast to become.[26] For this reason, we should intervene early and consult with parents and patients with myopia. Literature reinforces the following recommendations: increased outdoor daytime activity, increased vitamin D intake, atropine 0.01%, corneal refractive therapy, and peri-focus contact lenses.

At the 2012 Global Specialty Lens Symposium, panelists responded that they believed it was proper to recommend corneal refractive therapy or center distance contact lenses for patients who were progressing in myopia—that it may do good and it would do no harm.[16] What we clearly see is that the standard of care for prescribing single-vision spectacle lenses to myopic patients holds no value in protecting or preventing progression. Today, our patients can turn to the web to learn about wholistic approaches to regulating the myopia of their children. At a minimum, we should offer our patients basic education on the importance of outdoor daytime activity and vitamin D. There is mounting evidence to support treatment plans including the prescription of muscarinic antagonists and the prescription of peri-form or peri-focus contact lenses. RCCL

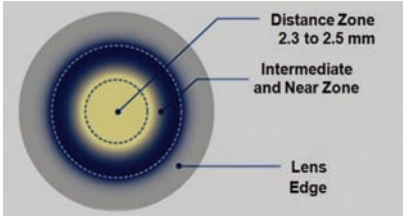

4. Center distance multifocal contact lenses are a form of peri-focus lens design for myopia control. Customized design and visual axis registration may be required to optimize refractive therapy.

1. Vitale S, Sperduto RD, Ferris FL 3rd. Increased prevalence of myopia in the United States between 1971-1972 and 1999-2004. Arch Ophthalmol. 2009 Dec;127(12):1632-9.
2. Rein DB, Zhang P, Wirth KE, et al. The economic burden of major adult visual disorders in the United States. Arch Ophthalmol. 2006;124(12):1754-60.
3. Aller T. Manipulation of retinal defocus to stimulate axial elongation in hyperopia. Optometry Vis Sci. 2010 Jan;88:395-403.
4. Legerton JA, Meyers WE. Methods and therapeutic optical devices for the regulation of astigmatism. US Patent 8128223; March 6, 2012.
5. Walline J, Lindsley K, Vedula S, et al. Interventions to slow progression of myopia in children. Cochrane Database Syst Rev. 2011 Dec 7;(12):CD004916.
6. Chia A, Chua WH, Cheung YB, et al. Atropine for the treatment of childhood myopia: safety and efficacy of 0.5%, 0.1% and 0.01% doses (Atropine for the Treatment of Myopia 2). Ophthalmology. 2012 Feb;119(2):347-54.
7. Joslin CE, Wu SM, McMahon TT, Shahidi M. Higher-order wavefront aberrations in corneal refractive therapy. Optom Vis Sci. 2003 Dec:80(12):805-11.
8. Asbell PA. Corneal refractive therapy and the corneal surface. Eye Contact Lens. 2004 Oct:30(4):236-7; discussion 242-3.
9. Cho P, Cheung SW, Edwards M. The longitudinal orthokeratology research in children (LORIC) in Hong Kong: a pilot study on refractive changes and myopia control. Curr Eye Res. 2005 Jan;30(1):71-80.
10. Walline JJ, Jones LA, Sinnott LT. Corneal reshaping and myopia progression. Br J Ophthalmol. 2009 Sep;93(9):1181-5.
11. Kakita T, Hiraoka T, Oshika T. Influence of overnight orthokeratology on axial length elongation in childhood myopia. Invest Ophthalmol Vis Sci. 2011 Jan;10.1167/iovs.10-5485.
12. Legerton, JA, Meyers WE. Systems and methods for the regulation of emerging myopia. U.S. Patent Application 20110153012; December 17, 2009.
13. Smith EL III, Ramamirtham R, Qiao-Grider Y, et al. Effects of foveal ablation on emmetropization and form-deprivation myopia. Invest Ophthalmol Vis Sci. 2007 Sep;48(9):3914-22.
14. Sankaridurg P, Donovan L, Varnas S, et al. Spectacle lenses designed to reduce progression of myopia: 12-month results. Optom Vis Sci. 2010 Sep;87(9):631-41.
15. Sankaridurg P, Holden B, Smith E, et al. Decrease in rate of myopia progression with a contact lens designed to reduce relative peripheral hyperopia: one-year results. Invest Ophthalmol Vis Sci. 2011 Dec 9;52(13):9362-7.

Additional references at www.reviewofcontactlenses.com.

AS-OCT Technology: Analyzing the Anterior Segment

New breakthroughs in OCT technology now offer practitioners an in-depth glimpse into the anterior segment.

By Alissa Coyne, O.D., and Joseph Shovlin, O.D.

Optical coherence tomography (OCT) has proven to be a useful tool in diagnosing and managing retinal and optic nerve disease. Recent technology has progressed to include examining the anterior segment. Anterior segment OCT (AS-OCT) generates in vivo, cross-sectional scans of the tissue to assist in analyzing the cornea, anterior chamber angle, iris and lens.[1] Exceptional quality images, captured at a high speed rate, allow practitioners to embrace the new technology once reserved for the posterior segment.

Alissa Coyne is a graduate of the Pennsylvania College of Optometry and completed her residency at The Eye Institute. She is currently an optometrist in Philadelphia and consultant at the Pennsylvania College of Optometry at Salus University.

Dr. Joseph Shovlin is a clinical editor for RCCL and a senior optometrist at the Northeastern Eye Institute in Scranton, Pa. He is past chair of the American Academy of Optometry section on Cornea and Contact Lenses and of the American Optometric Association's Contact Lens and Cornea section.

What is an OCT?

OCT utilizes near-infrared light waves to measure distances of anatomical structures. A beam of light is directed onto the structure and the echo time delay of light is then recorded. Employing low-coherence interferometry, the reflected light from the eye is compared to a reference value of a known length.[2] A series of axial scans (A-scans) are combined to form two-dimensional images of the ocular structures in a process similar to ultrasound biomicroscopy; however, light (as opposed to sound waves) is used in OCT. Cross-sectional images are then generated by scanning the incident optical beam. The resultant scans are displayed in a color scale.[2]

Using these principles, two OCT platforms have been developed: time domain and spectral (or Fourier) domain. Time domain OCT (TD-OCT) instrumentation utilizes a moveable reference mirror. The mirror moves for each A-scan to determine the ocular structure's depth, thereby limiting the speed at which the image is acquired.[3] Spectral domain OCT (SD-OCT) has a fixed reference mirror to measure the depth information and uses a Fourier transformation algorithm of the spectral interferogram to produce the A-scan, which results in faster acquisition and better image quality.[1-3]

AS-OCT resolution is based on wavelength and bandwidth. A 1,310nm wavelength captures data at a rate 20 times faster than the original 820nm wavelength utilized in posterior segment examination by TD-OCT.[4] The longer wavelength also allows for better penetration into the sclera, iris and anterior chamber angle.

Release Date: April 2012
Expiration Date: March 1, 2015
Goal Statement: This article will offer a synopsis of the new breakthroughs in OCT technology and give practitioners an in-depth glimpse into the anterior segment.
Faculty/Editorial Board: Alissa Coyne, O.D., and Joseph Shovlin, O.D.
Credit Statement: This course is COPE approved for 1 hour of CE credit. COPE ID 34138-AS. Check with your local state licensing board to see if this counts toward your CE requirement for relicensure.
Joint-Sponsorship Statement: This continuing education course is joint-sponsored by the Pennsylvania College of Optometry.
Disclosure Statement: Dr. Shovlin is a paid consultant to Abbott Medical Optics.

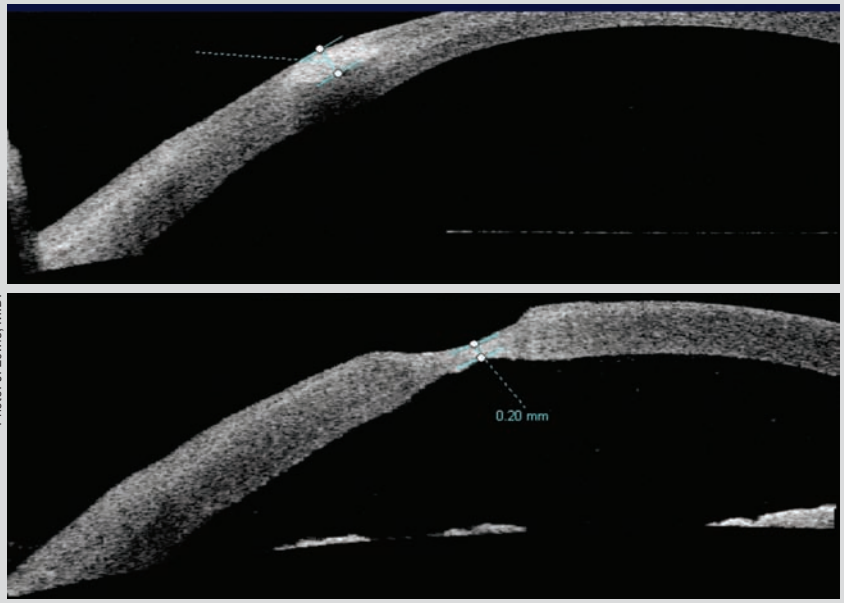

Photo: J. Lewis, M.D.

1. Corneal infiltrate extent depth (above). Ulceration depth is clearly shown on this Visante AS-OCT image (below).

AS-OCT is a non-contact procedure and is more user-friendly when compared to ultrasound biomicroscopy (UBM).[5]

Limitations still exist with the advancing technology. AS-OCT cannot completely image beyond the pigmented epithelium of the iris due to light absorption by this layer.[5] Comparatively, UBM can clearly image the ciliary body, lens and zonules. However, AS-OCT can capture the crystalline lens, posterior chamber intraocular implants or phakic implantable lens.[5]

The fastest TD-OCT on the market continues to be the Visante AS-OCT (Carl Zeiss Meditec). This system acquires 2,000 A-scans per second. The market currently has a few choices of SD-OCT systems with both posterior and anterior segment imaging capabilities. The RTVue and iVue (Optovue) as well as the Cirrus (Carl Zeiss Meditec) acquire approximately 26,000 A-scans per second while the Spectralis (Heidelberg Engineering, Inc.) obtains 40,000 A-scans per second. Each of the SD-OCTs has a wavelength in the range of 820nm to 879nm. While the Visante is slower, its longer wavelength (1,310nm) penetrates deeper through turbid structures, thereby visualizing the anterior chamber in more detail. Each design has its advantages and clinical application can assist in determining the better choice.[1-3]

AS-OCT is widely applicable in the ophthalmic practice. Each platform allows imaging of the cornea, anterior chamber, lens and iris that can assist in diagnosing and managing anterior segment disease, refractive surgery and glaucoma.

AS-OCT and the Cornea

AS-OCT can assist in diagnosis and documentation of corneal conditions such as dystrophies and degenerations, as well as assorted inflammatory pathologies. This technology can be used to diagnose and manage corneal infiltrates, ulcers, dellen or scars (*figure 1*). The depth and extent as obtained by AS-OCT are superior to that of anterior segment photography.[6] Monitoring of corneal infection is possible especially when deep, aggressive infection occurs. Hypopyon or hyphema involvement can also be monitored as a result of severe infection or trauma. AS-OCT has the capability to determine the depth of a foreign body or the presence of residue once removed.

Corneal dystrophies affect one or more layers of the cornea.[6] High definition images obtained by AS-OCT allow the practitioner to visualize the epithelium, stroma and endothelium with clear differentiation. Monitoring Fuchs' endothelial dystrophy is another capability of this technology. Descemet's detachment, corneal guatta and edema can be imaged and observed (*figure 2*). In some severe cases, Fuchs' results in bullous keratopathy.[7] AS-OCT can document corneal topography pre- and post- Descemet's stripping automated endothelial keratoplasty (DSAEK) in the treatment of Fuchs' or pseudophakic bullous keratopathy (PBK). Surgeons can visualize the interface

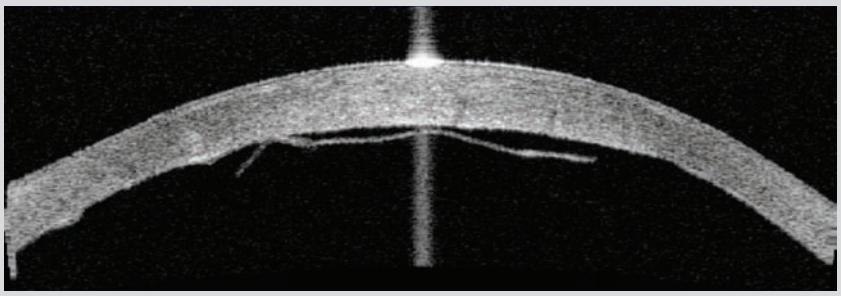

Photo: Dr. M. Packer

2. A detachment of Descemet's membrane is seen following cataract extraction.

and document its depth in DSAEK patients. AS-OCT can also document thickness changes over time. Corneal inlay position with possible resultant refractive effect can also be monitored by OCT imaging.[8]

AS-OCT has the capability to image keratoconus and other ectastias to determine and document the severity of thinning and scarring. While moderate to severe keratoconus can be identified via slit lamp examination and topography, subclinical or form fruste keratoconus and other thinning conditions can be recognized with pachymetry maps.[9] These cases are especially important to identify prior to refractive laser surgeries.[1]

AS-OCT pachymetry maps scan areas from the central cornea to 10mm, calculating a global thickness measurement in both clear and opacified corneas. This measurement is useful in both glaucoma work-ups and refractive or cataract surgery. Pachymetry maps allow the practitioner to create accurate and repeatable flap thicknesses in LASIK surgical planning. Postoperatively, residual bed thickness can be imaged utilizing these thickness maps.

AS-OCT and Refractive Surgery

Refractive surgery has benefitted greatly from AS-OCT technology. Preoperatively, patients can be scanned for any abnormalities. Postoperatively, LASIK epithelial ingrowth can be monitored closely (*figure 3*). Not all epithelial ingrowths need to be treated, therefore measuring thickness of the epithelium and the LASIK flap help differentiate between the cases that must be treated by lifting the flap and those that can be monitored. A thinning flap due to epithelial ingrowth, especially centrally, warrants significant concern. AS-OCT also images the architecture of the flap and the thickness of the residual corneal bed. When considering post-LASIK enhancement, proper assessment of the flap and residual bed thickness can easily be made with accurate measurement using the caliper tools.[9] Unexpected corneal ectasia postoperatively can also be assessed.

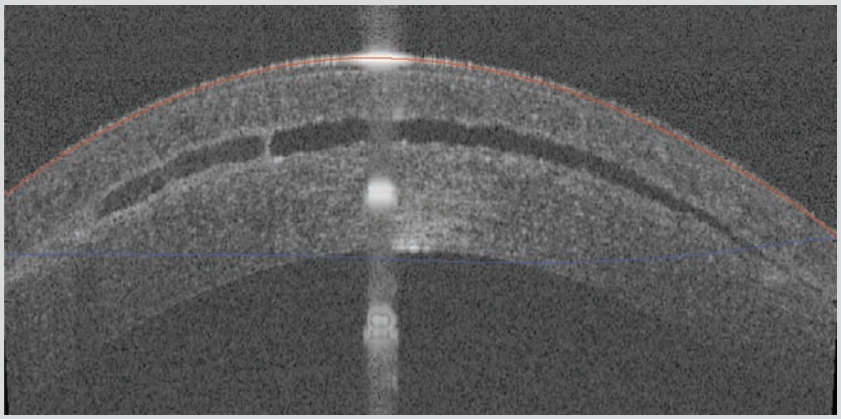

3. Interface fluid and epithelial ingrowth are observed with anterior segment OCT in a LASIK patient.

AS-OCT has been utilized in monitoring the epithelial healing progression under therapeutic contact lenses (TCL) following lamellar keratoplasty and epi-LASIK.[10] Visualizing the epithelium postoperatively allows the practitioner to remove the TCL at the appropriate time without traumatizing the new epithelium or risking a secondary infection by leaving the TCL in longer than necessary. OCT imaging of the anterior segment can also be beneficial in difficult RGP fits. AS-OCT can measure the curvature of the peripheral cornea and sclera, giving practitioners better insight to a successful fit.[11]

AS-OCT and Glaucoma

AS-OCT provides direct visualization of the anterior chamber angle including the scleral spur, ciliary body and ciliary sulcus. Schlemm's canal can also be observed on some scans. Studies have shown AS-OCT analysis of the angle is accurate, repeatable, and correlated to findings of traditional gonioscopy.[12,13] Traditional gonioscopy suffers from artifact due to light and indentation errors.[14] AS-OCT allows the practitioner to view the anatomical angle features in both light

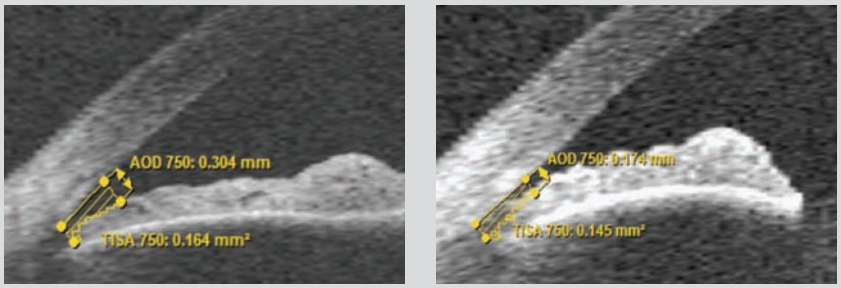

4. This Optovue RTVue image of the angle shows different angle measures in light and dark.

Photo: I. Ahmed

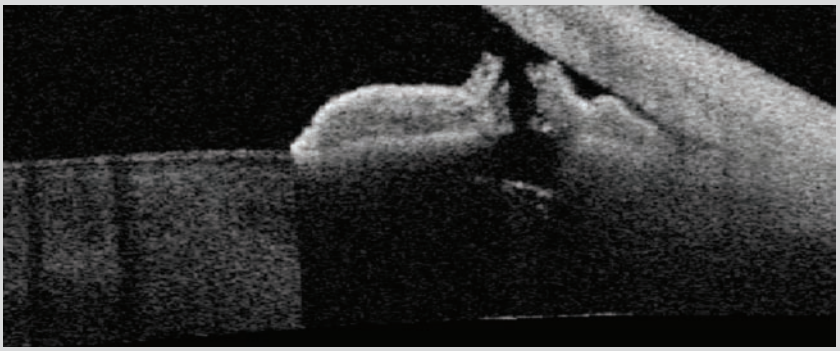

5. A patent iridotomy is clearly seen with an increase in chamber depth following laser intervention for a narrow angle/shallow chamber.

and dark conditions, thereby allowing a better evaluation for possible angle closure (*figure 4*). AS-OCT can identify the different mechanisms responsible for angle closure glaucoma including pupillary block, plateau iris syndrome and lens-related mechanisms. The scleral spur insertion landmark is located where the less reflective ciliary muscle contacts the more reflective sclera. By first identifying the scleral spur, the trabecular meshwork distance can be measured in addition to viewing the ciliary body's curvature and the depth of the anterior chamber.[14]

Properly identifying patients in need of an iridotomy is an important responsibility of eye care practitioners. Iridotomy procedures have shown dramatic improvement of the angle structure when pupillary block mechanisms are present (*figure 5*). However, when certain patients' angles do not improve as expected following iridotomy, non-pupillary block mechanisms (i.e., plateau iris, lens-related anterior rotation of the iris) can be easily identified. The characteristic iris configuration and thick profile in plateau iris syndrome is visualized by the AS-OCT.[15] Practitioners can also observe blebs and implants by scanning the affected tissue. A limitation of the AS-OCT during angle imaging is the inability to visualize pathology causing primary or secondary glaucoma including trabecular pigment or narrow bands of peripheral synechiae.[15]

Other Applications

AS-OCT is a valuable tool in surgical planning. Preoperative assessment of phakic IOL patients—as well as those who have undergone corneal transplant, LASIK, DSAEK and other corneal procedures—can assist in obtaining accurate measurements. These measurements include angle recess-to-angle recess distance estimates, measurements of posterior phakic lens vault and predicting potential for iris pigmentary dispersion.[16]

The risk of pigment dispersion is calculated using crystalline lens rise (CLR). CLR is an indirect measurement of iris convexity found by using the distance between the anterior pole of the crystalline lens and the horizontal line joining the iridocorneal recesses.[17] This measurement can also be utilized in determining whether laser peripheral iridotomy (LPI) or crystalline lens extraction is appropriate in treatment of narrow angle patients.[17] Lensectomy is indicated in patients with a CLR of 0.8mm, a chamber depth less than 2mm, and angles less than 15º. Eye care practitioners can also use AS-OCT to examine the density of nuclear sclerosis or subcapsular cataracts and the centration of phakic or pseudophakic implants (*figure 6*).[17]

AS-OCT can also be useful in helping surgeons determine the proper ablation for phototherapeutic keratectomy (PTK). By establishing the opacity depth and the epithelial thickness, the practitioner can properly remove the opacity and estimate the amount of induced refractive change.[9] It also allows the practitioner to determine if the scar is too deep for PTK to be as effective as with deep posterior stromal scars.[5]

Use of the Intralase laser (Abbott Medical Optics) as part of different corneal procedures is becoming more popular in the surgical arena.[18-21] AS-OCT maps the cornea to determine the areas thick enough to create the channels for

Photo: Dr. G. Baikoff

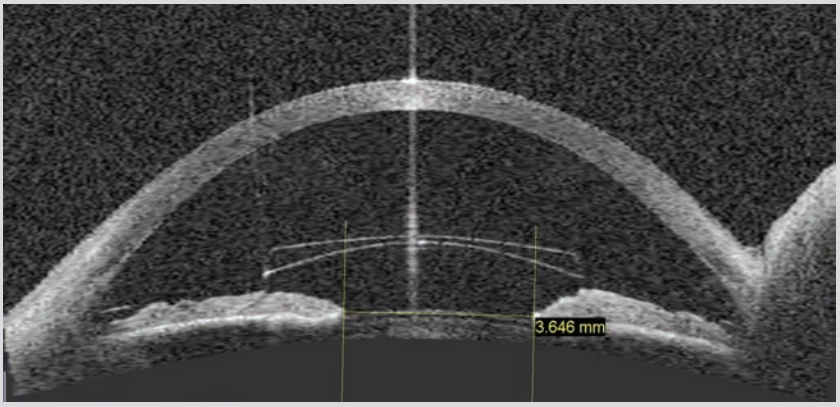

6. An angle-supported phakic IOL with a clearance measurement can be visualized.

proper Intacs implantation inferiorly. OCT imaging of corneal depth is also useful in Intralase-enabled keratoplasty (IEK) by determining the depth of ablation of the recipient tissue (*figure 7*).

OCT imaging of the anterior segment can quantitatively monitor pigmented lesions of the iris, sclera, and angle. Changes of these lesions, including seeding into the angle or enlargement, can be easily identified.[4]

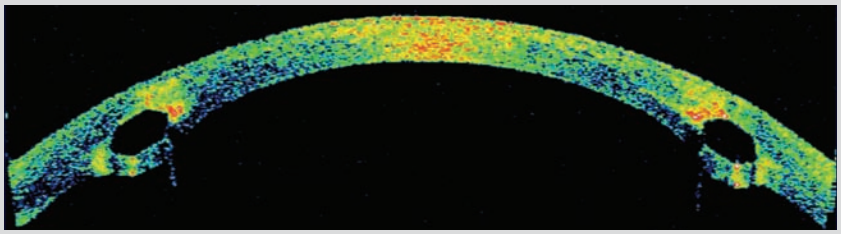

Photo: Dr. J. Güell

7. Intacs channels can be assessed for depth and location on anterior segment OCT.

The Future of AS-OCT

AS-OCT is currently being utilized in dry eye studies. Measuring tear meniscus height (TMH) and conjunctivochalasis are among some of the newer elements being studied utilizing AS-OCT capabilities during diagnosis and management.[22-24] Using OCT imaging to determine effectiveness in dry eye treatment during clinical trials looks to be promising and encompasses another capability of this technology.

As post-LASIK patients age, determining proper corneal power for cataract surgery can be an issue. AS-OCT measures both the anterior and posterior corneal curvature—the relationship affected by LASIK. Specific software for this measurement is being studied and released in some of the SD-OCT systems. SD-OCT has dramatically increased speed acquisition and improved anatomical detail in both the posterior and anterior segment. Use of AS-OCT has allowed for better and more efficient diagnosis, improved disease monitoring, enhanced surgical planning and superior monitoring of response to treatment.

Future OCT technology includes imaging of microscopic structures and those located posterior to the iris. Achieving this result can someday result in biopsy-like images of corneal pathogens including protozoa and fungi. Future swept-source models with a longer wavelength allowing better penetrance of anterior segment tissue morphology may also enhance the role of OCT imaging on the eye-care profession. RCCL

1. Ramos JL, Li Y, Huang D. Clinical and research applications of anterior segment optical coherence tomography-a review. Clin Experiment Ophthalmol. 2009 Jan;37(1):81-9.
2 Kalayoglu MV. Advances in ocular coherence tomography: Technology spotlight. Medcompare. 2007;5:1-4.
3.Kiernan DF, Mieler WF, Hariprasad SM. Spectral-domain optical coherence tomography:a comparison of modern high resolution retinal imaging systems. Am J Ophthalmol. 2010 Jan;149(1):18-31.
4. Steinert RF, Huang D, eds. Anterior segment optical coherence tomography. Slack Incorporated: Thorofare, USA; 2008.
5. Dorairaj S, Lebmann JM, Ritch R. Quantitative evaluation of anterior segment parameters in the era of imaging. Trans Am Ophthalmol Soc. 2007 Dec;105:99-110.
6. Vajzovic L, Karp C, Haft P, et al. Ultra high-resolution anterior segment optical coherence tomography in the evaluation of anterior corneal dystrophies and degenerations. Ophthalmol. 2011 Jul;118(7):1291-6.
7. Ratanasit A, GorovoyMS. Long-term results of Descemet stripping automated endothelial keratoplasty. Cornea. 2011 Dec;30(12):1414-8.
8. Esquenazi S, Rand W. Effect of the shape of the endothelial graft on the refractive results after Descemet's stripping with automated endothelial keratoplasty. Can J Ophthalmol. 2009 Oct;44(5):557-61.
9. Kent C. Making the most of anterior segment OCT. Review Ophthalmology. 2011 Apr;18(4):39-46.
10. Pang CE, Vanathi M, Tan D, Mehta J. Evaluation of corneal epithelial healing under contact lens with spectral domain anterior segment optical coherence tomography. Open Ophthalmol J. 2011 Jun;5:51-4.
11. Sobara L, Maram J, Fonn D, et al. Metrics of the normal cornea: anterior segment imaging with the Visante OCT. Clin Exp Optom. 2010 May;93(3):150-6.
12. Goldsmith JA, Li Y, Chalita MR, et al. Anterior chamber width measurement by high-speed optical coherence tomography. Ophthalmology. 2005 Feb;112:238-44.
13. Muller M, Dahmen G, Porksen E, et al. Anterior chamber angle measurement with optical coherence tomography: intraobserver and interobserver variability. J Cataract Refract Surg. 2006 Nov;32:1803-08.
14. Ahmed II, Teichman JC. OCT's applications for the cataract surgeon. Cataract Refract Surg Today (Suppl). 2007 Aug;7:3-5.
15. Dul MW. Glaucoma imaging: getting closer. Optometric Management. 2006 Jul;41(7):49-52,71.
16. Baikoff G, Bourgeon G, Jodai HJ, et al. Pigment dispersion and Artisan phakic intraocular lenses: crystalline lens rise a safety criterion. J Cataract Refract Surg. 2005 Apr;31(4):674-80.
17. Teichman JC, Ahmed IIK. AS-OCT upgrades advance glaucoma care. Rev Ophthalmol E-News. 2007 Nov;14(11):1-4.
18. Sansanayudh W, Bahar I, Kumar NL, et al. Intrastromal corneal ring segment SK implantation for moderate to severe keratoconus. J Cataract Refract Surg. 2010 Jan;36(1):110-3.
19. Pinero, DP, Alio JL, El Kady B, et al. Refractive and aberrometric outcomes of intracorneal ring segments for keratoconus: mechanical versus femtosecond-assisted procedures. Ophthalmology. 2009 Sept;116(9):1675-87.
20. Slade SG. Applications for the femtosecond laser in corneal surgery. Curr Opin Ophthalmol. 2007 Jul;18(4):338-41.
21. Mashor RS, Rootman DB, Bahar I, et al. Outcomes of deep anterior lamellar keratoplasty versus intralase enabled penetrating keratoplasty in keratoconus. Can J Ophthalmol. 2011 Oct;46(5):403-7.
22. Ibrahim OM, Dogru M, Takano Y, et al. Application of Visante optical coherence tomography tear meniscus height measurement in the diagnosis of dry eye disease. Ophthalmology. 2010 Oct;117(10):1923-9.
23. Veres A, Tapaszto B, Kosina-Hagyo K, et al. Imaging lid-parallel conjunctival folds with OCT and comparing its grading with the slit lamp classification in dry eye patients and normal subjects. Invest Ophthalmol Vis Sci. 2011 May;52(6):2945-51.
24. Gumus K, Crockett CH, Pflugfelder SC. Anterior segment optical coherence tomography: a diagnostic instrument for conjunctivochalasis. Am J Ophthalmol. 2010 Dec;150(6):798-806.

CE TEST FOR AS-OCT TECHNOLOGY: ANALYZING THE ANTERIOR SEGMENT

1. How does the optical coherence tomography (OCT) work?

a. Utilizes near-infrared light waves to measure distances of anatomical structures.
b. Works on sound wave principles to detect images.
c. Measures depth by using a difference in light reflection on various objects.
d. Utilizes ultraviolet light waves to capture space differences between objects.

2. What is anterior segment optical coherence tomograhy (AS-OCT) resolution based on?

a. Shorter wavelength capture.
b. Wavelength and bandwidth.
c. Light rays and reference mirror.
d. Microscope strength and ultrasound waves.

3. What is a limitation of AS-OCT technology compared to ultrasound biomicroscopy (UBM)?

a. A full-contact procedure compared to the non-contact UBM.
b. Cannot capture the crystalline lens, posterior chamber intraocular implants or phakic implantable lens.
c. Does not accurately measure corneal thickness.
d. Cannot completely image beyond the pigmented epithelium of the iris due to light absorption by this layer.

4. An AS-OCT can be used on the cornea to…
a. Monitor Fuchs' endothelial dystrophy.
b. Document corneal topography pre- and post- Descemet's stripping automated endothelial keratoplasty.
c. Image keratoconus and other ectastias to determine and document the severity of thinning and scarring.
d. All of the above.

5. How can AS-OCT technology help postoperative epithelial healing?
a. Can accurately assess the wound healing response.
b. Allows the practitioner to remove the therapeutic contact lenses (TCL) at the appropriate time without traumatizing the new epithelium or risking a secondary infection by leaving the TCL in longer than necessary.
c. Allows for macrophage and Langerhans cell counts.
d. Helps to determine when to allow patients to wear contact lenses.

6. Why choose the AS-OCT over the traditional gonioscopy findings?
a. Allows for a better determination of iris detail including pigmentation.
b. Can easily see narrow bands of synechiae.
c. Allows the practitioner to view the anatomical angle features in both light and dark conditions, thereby allowing a better evaluation for possible angle closure.
d. None of the above.

7. AS-OCT is a valuable tool in the surgical planning of…
a. Corneal transplants.
b. LASIK.
c. DSAEK.
d. All of the above.

8. AS-OCT can calculate measurements for…
a. Angle recess-to-angle recess distance estimates.
b. Posterior phakic lens vault.
c. Predicting potential for iris pigmentary dispersion.
d. All of the above.

9. How can AS-OCT help practitioners use the Intralase laser?
a. Maps the cornea to determine the areas thick enough to create the channels for proper Intacs implantation inferiorly.
b. Measures the anterior curvature of the crystalline lens, which aids in Intacs placement.
c. Allows for direct measures of lens vault that assist in segment placement.
d. None of the above.

10. What is NOT a current or future AS-OCT technology utilization?
a. Measuring tear meniscus height.
b. Assessment of the posterior lamina cribosa.
c. Biopsy-like images of corneal pathogens including protozoa and fungi.
d. Measuring both the anterior and posterior corneal curvature in LASIK patients.

Examination Answer Sheet

Valid for credit through March 1, 2015

This exam can be taken online at www.reviewofcontactlenses.com.
Upon passing the exam, you can view your results immediately.
You can also view your test history at any time from the website.

AS-OCT Technology: Analyzing the Anterior Segment

Directions: Select one answer for each question in the exam and completely darken the appropriate circle. A minimum score of 70% is required to earn credit.

Mail to: Jobson - Optometric CE, PO Box 488, Canal Street Station, New York, NY 10013

Payment: Remit $20 with this exam. Make check payable to Jobson Medical Information LLC.

COPE approval for 1 hour of CE credit. COPE ID 34138-AS

This course is joint-sponsored by the Pennsylvania College of Optometry

There is an eight-to-ten week processing time for this exam.

1.	Ⓐ	Ⓑ	Ⓒ	Ⓓ
2.	Ⓐ	Ⓑ	Ⓒ	Ⓓ
3.	Ⓐ	Ⓑ	Ⓒ	Ⓓ
4.	Ⓐ	Ⓑ	Ⓒ	Ⓓ
5.	Ⓐ	Ⓑ	Ⓒ	Ⓓ
6.	Ⓐ	Ⓑ	Ⓒ	Ⓓ
7.	Ⓐ	Ⓑ	Ⓒ	Ⓓ
8.	Ⓐ	Ⓑ	Ⓒ	Ⓓ
9.	Ⓐ	Ⓑ	Ⓒ	Ⓓ
10.	Ⓐ	Ⓑ	Ⓒ	Ⓓ

1 = Excellent 2 = Very Good 3 = Good 4 = Fair 5 = Poor

Rate the effectiveness of how well the activity:

21. Met the goal statement: ① ② ③ ④ ⑤
22. Related to your practice needs: ① ② ③ ④ ⑤
23. Will help you improve patient care: ① ② ③ ④ ⑤
24. Avoided commercial bias/influence: ① ② ③ ④ ⑤
25. How would you rate the overall quality of the material presented? ① ② ③ ④ ⑤
26. Your knowledge of the subject was increased:
◯ Greatly ◯ Somewhat ◯ Little
27. The difficulty of the course was:
◯ Complex ◯ Appropriate ◯ Basic

How long did it take to complete this course?

Comments on this course:

Suggested topics for future CE articles:

Please retain a copy for your records. Please print clearly.

You must choose and complete one of the following three identifier types:

① SS # ___ - __ - ____

Last 4 digits of your SS # and date of birth ② ____ - _____

State Code and License #: (Example: NY12345678) ③ _____

First Name

Last Name

E-Mail

The following is your: ☐ Home Address ☐ Business Address

Business Name

Address

City State

ZIP

Telephone # ___ - ___ - ____

Fax # ___ - ___ - ____

By submitting this answer sheet, I certify that I have read the lesson in its entirety and completed the self-assessment exam personally based on the material presented. I have not obtained the answers to this exam by any fraudulent or improper means.

Signature _____ Date _____

Lesson 108148 RO-RCCL-PCO0412

Troubleshooting Keratoconus

Here is a visual breakdown of the common issues facing keratoconus patients.

By Shawna L. Hill Vanderhoof, O.D., and Dora Sztipanovits Mathe, O.D., M.S.

Is there a perfect fit? For a keratoconic, the fit of a contact lens could always be tweaked just a little bit. The question, however, is deciding which health and/or vision factors would make this a beneficial and worthwhile change. Any design changes made to affect the gas-permeable (GP) fitting relationship should be significant in nature. For a fitting tip checklist, visit www.gpli.info.

Patients that present with keratoconus almost always have a list of problems and visual concerns. In this article, we will troubleshoot the most common complications with keratoconus that present with GP lenses.

Corneal Abrasions and Erosions

A common issue that our patients face is recurrent corneal abrasions and/or chronic epithelial erosions. The classic histopathology in keratoconus includes iron deposition in the epithelium, thinning of the stromal layer and breaks in Bowman's layer. The average epithelial thickness is approximately 52µm.[1] The epithelium over the cone in corneas with keratoconus can be much thinner, around 25µm, and this can be surrounded by epithelial thickening to compensate for stromal thinning and steepening.[2]

Recurrent abrasions and epithelial breaks start with the pathogenesis of keratoconus, but will be exacerbated by contact lens wear. Low levels of the protein α-enolase in the epithelial cells in keratoconus affect cell migration during wound closure and therefore, a loss of interactions with the proteins of the cell matrix.[3] This will lead to disassembly of that matrix and might result in corneal thinning.

An additional theory is that epithelial trauma and persistent damage can produce inflammatory cytokines, which result in stromal thinning from keratocyte apoptosis (*see "Chronic Epithelial Abrasions" p 30*).[4] Although chronic epithelial issues will lead to discomfort, there

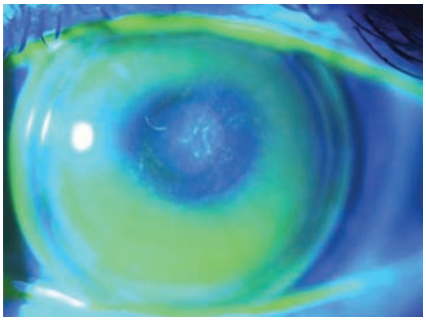

1. Apical bearing and subsequent swirl staining.

Dr. Hill Vanderhoof graduated from University of Missouri College of Optometry and completed a residency in ocular and refractive surgery. A fellow in the American Academy of Optometry, she has transitioned to primary care in Denver, Colo. but still specializes in complicated contact lens fittings.

Dr. Sztipanovits graduated from UC Berkeley School of Optometry and completed a residency in ocular and refractive surgery. A diplomate of the American Board of Optometry, she is an instructor in ophthalmology and visual Sciences at Vanderbilt University, specializing in complicated contact lens fittings.

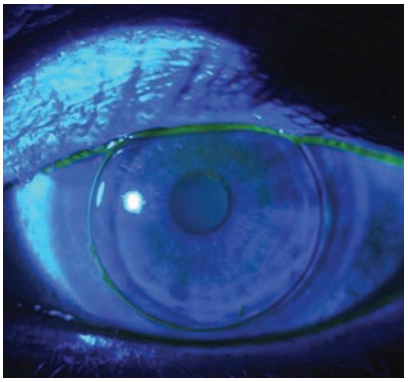

2. This patient needs a flatter and wider peripheral curve.

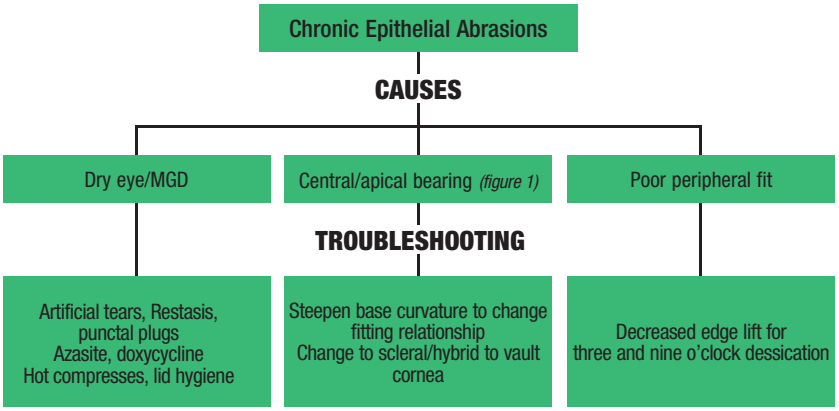

are other causes that may prohibit day in and day out comfort, leading to a limited wear schedule (*see "Discomfort," below*).

Glare and Halo

Another major challenge is visual aberrations including glare, ghosting or multiple images, and halos (*see "Visual Aberrations" p 31*). There are some patients who seem to have comfort or lens stabilization issues, regardless of what GP lens style or design you select. Patients who tend to get recurrent abrasions from the mechanical bearing of the lens on the apex of their cone are always losing lenses or finding them painfully displaced on the eye, which presents additional challenges.

One option is piggybacking (soft lens placed under the hard lens), a technique that does not always solve the problem and counterproductively, may even cause additional concerns stemming from multiple hands touching the lens.

An Alternative to Consider

A great alternative for our patients may be hybrid lenses, which would allow for greater stability and often times increased comfort. Although it can be costly, ClearKone (SynergEyes) is one particular lens that seems to work well for keratoconus. Similar to scleral lenses, this particular hybrid lens is great at relieving the mechanical pressure the average GP contact lens places on the apex of a cone by vaulting entirely over the cornea. In fact, it is generally able to clear most keratoconic cones.

The design is such that the soft skirt—RGP junction—is inside the limbus with the skirt extending on the sclera at a typical soft lens diameter of 14.5mm. The junction is defined by two areas: the outer landing zone (the region of the soft lens) and the inner landing zone (the RGP lens portion).[5] Unlike standard GP fitting practice, these lenses are fit not by base curvature, but

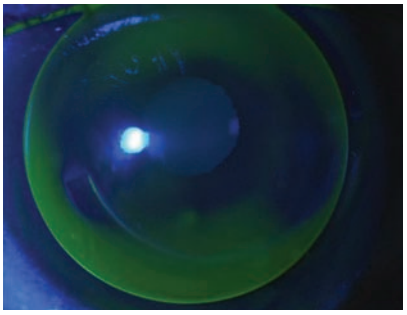

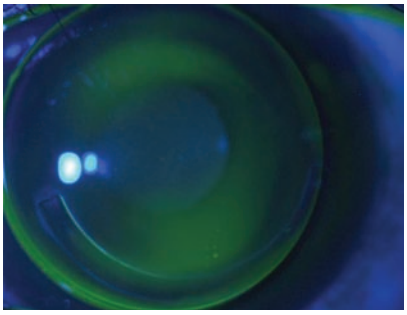

3a. Inferior edge lift in a keratoconus patient post-Intacs.
3b. Asymmetric corneal technology applied to inferior 6 o'clock edge lift with improved fit.

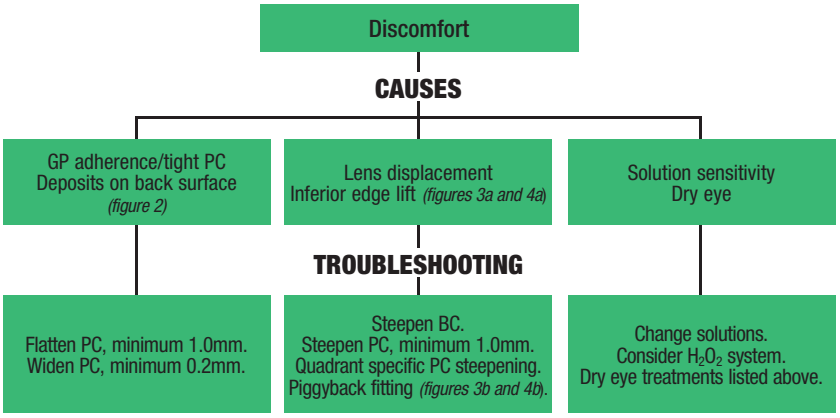

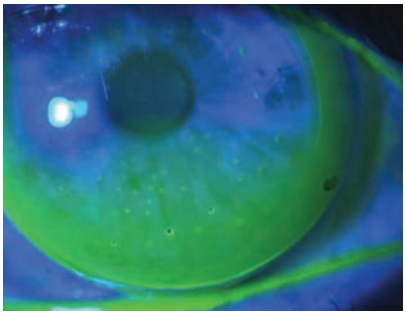

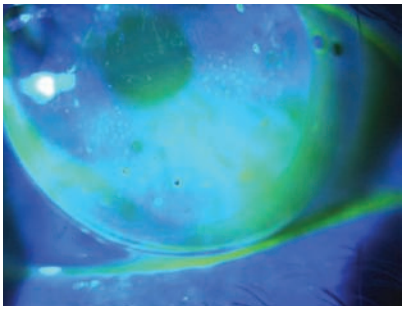

4a. Inferior edge lift with dimple veiling. 4b. Quadrant specific edge lift inferiorly with the further steepening of mid-peripheral fit. Another option is to make the lens smaller.

rather vault—which describes the relative depth of the lens. The parameter that can be altered is the soft skirt curvature, which comes in flat, medium and steep options (*see "Poor Fitting Hybrid," below*).

Even with this straightforward approach, it is not always possible to avoid fitting problems. One of the most common obstacles with these lenses is the development of a tight fitting lens which can cause corneal edema, pain, and difficulty removing the lens. There are also cases of such advanced keratoconus that there simply isn't a hybrid lens manufactured which can adequately clear the corneal apex. In failed hybrid cases such as these, scleral lenses may be an excellent alternative. Greater availability of parameter ranges allow for more flexible fitting options. And, larger diameters (15mm to 18mm) tend to result in increased comfort due to less lid interaction.

If, despite best efforts, the patient fails with rigid lenses of any modality in the eye, whether to due fitting issues or simply intolerance, there is a new wave of soft lenses specifically for the use of keratoconus. Soft K (Accu-lens) and KeraSoft IC (UltraVision) are examples of two such keratoconus soft lenses recently on the market. These lenses are designed with a thick optic zone to create structural stability for improved vision, yet maintain the comfort of soft lenses. Time will tell how these lenses perform in the world of keratoconic lenses.

GP contact lenses offer good vision for those with keratoconus and irregular corneas. Troubleshooting your patient's contact lens and visual problems by providing GP lens changes or alternatives such as piggybacking, hybrid lenses, scleral lenses and custom soft lenses will help them achieve good, comfortable vision. And, they will thank for all your patient and effort. RCCL

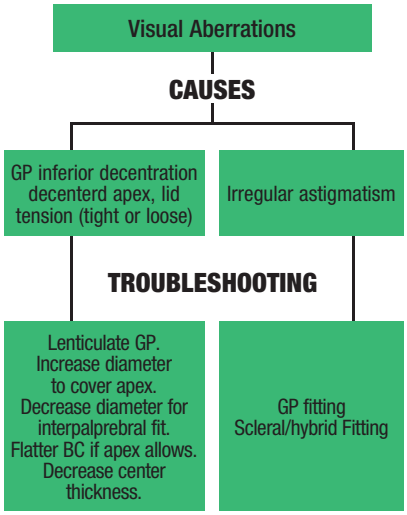

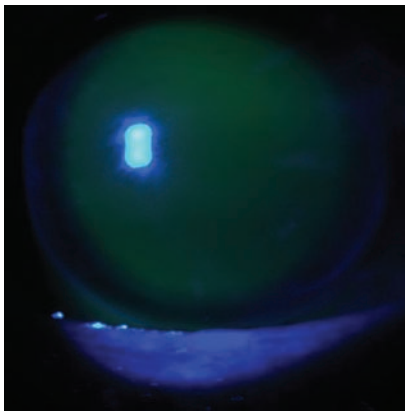

5. Excessive central pooling is seen with OLZ bearing and ILZ pooling. Two changes to improve this fit: reduce the vault by 100 µm or flatten the skirt curvature.

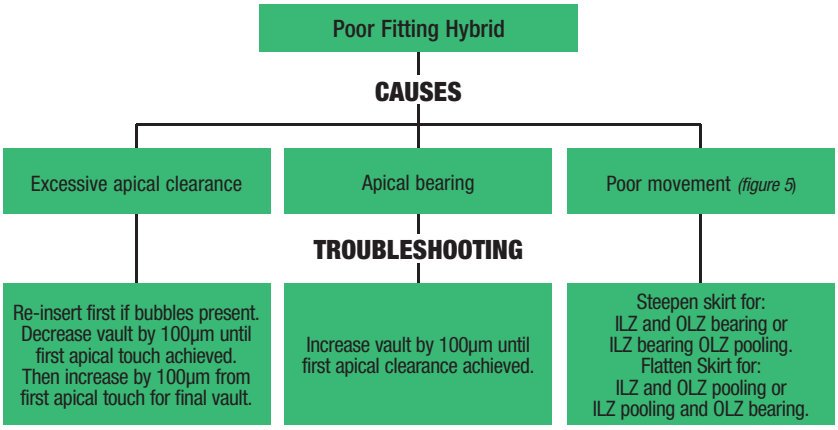

1. Wang M. Keratoconus and Keratoectasia. Thorofare, NJ: Slack Incorporated, 2010.
2. Reinstein DZ, Archer TJ, Gobbe M. Corneal epithelial thickness profile in the diagnosis of keratoconus. J Refract Surg. 2009 Jul;25(7):604-10.
3. Srivastava OP, Chandrasekaran D, Pfister R. Molecular changes in selected epithelial proteins in human keratoconus compared to normal corneas. Mol Vis. 2006 Dec 20;12:1615-25.
4. Hwang JS, Lee JH, Wee WR, Kim MK. Effects of multicurve RGP contact lens use on topographic changes in keratoconus. Korean J Ophthalmol. 2010 Aug;24(4):201-6.
5. SynergEyes. ClearKone Fitting Information. 2010 Sep. Available at: www.synergeyes.com/ClearKoneContent.htm (accessed March 2012).

AS-OCT and the Specialty Contact Lens

Advanced imaging technology helps practitioners better manage specialty lens wear.

By Bruce Baldwin, O.D., Ph.D., and Sarah Moyer, C.R.A., O.C.T.-C.

Dr. Baldwin is a clinical assistant professor at the University of North Carolina Department of Ophthalmology. He manages a specialty contact lens practice and trains optometry and ophthalmology residents and optometry externs.

Sarah Moyer is the director of ophthalmic imaging at the University of North Carolina. She is also a member of the Board of Education for the Ophthalmic Photographers' Society and has lectured for the past several years at national OPS meetings.

There are numerous applications for anterior segment optical coherence tomography (AS-OCT), including research and clinical applications for glaucoma, phakic IOLs, tear height, LASIK, cataract surgery, corneal transplant, pachymetry and corneal disease.[1-8] AS-OCT is also used for custom design and evaluation of specialty contact lenses, especially large-diameter scleral lenses.[9] Investigations of scleral shape with AS-OCT have explained how large-diameter contact lenses interact with the peripheral cornea and sclera.[10,11]

The Ideal Fit

Proper fitting of scleral lenses includes three principles: vaulting over the cornea, including the limbus (related terms are clearance, sagittal height or fluid chamber); ensuring a proper landing zone (also known as the haptic or scleral zone); and maintaining adequate tear exchange under the lens.

A well-designed lens with respect to the vault and landing zone usually will result in good tear exchange and corneal physiology. Evaluating the lens vault and landing zone is done clinically through slit lamp observation—with and without fluorescein. However, from teaching scleral lens education workshops, we know that some beginners have a very difficult time learning to estimate parameters like central and limbal corneal vault. Furthermore, manual or SIMK keratometry values are often not very useful for selecting an initial trial lens with the proper sagittal height for adequate vault during scleral lens fittings.[12]

Clearance, or vault, can be judged during slit lamp biomicroscopy by using the known or estimated corneal thickness and comparing that slit width to the width of the space between the lens and the cornea (*figure 1*). Scleral lenses typically are fit with vault equal to 25% to 100% of the corneal thickness (150µm to 600µm). The vault of a scleral lens is more dependent on the total sagittal height of the lens than the base curve, and AS-OCT is a powerful tool for calculation and observing sagittal height.[11]

Using the AS-OCT

While not required, correlating slit lamp observations with AS-OCT

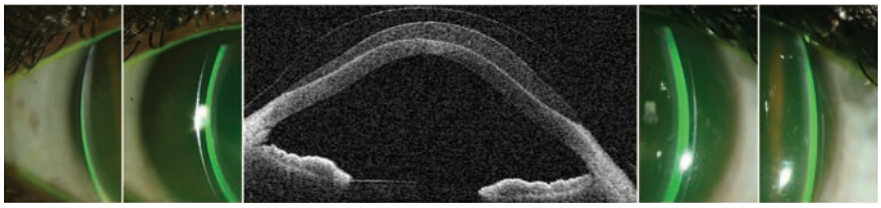

1. Horizontal AS-OCT scan with corresponding slit lamp images.

Anterior Segment OCT Specifications

Manufactuer	Model	Domain	Scans/sec	Axial Res	Trans Res	Scan Depth	Scan Length	Lens	FDA clearance*
Bioptigen	Envisu R2300	Spectral	32000	<4 µm	21µm, 11µm, 7.5µm*	2.5mm	20mm	Ext	pending on C2300
Heidelberg	Spectralis	Spectral	40,000	3.9 µm	14 µm	1.9mm	16mm	Ext	Yes
Optos	Optos OCT/SLO	Spectral	27,000	<6.0 µm	20 µm	2.0-2.3mm	6mm	Ext	Yes
Optovue	iVue	Spectral	26000	5.0 µm	15 µm	2-2.3mm	12mm	Ext	Yes
Optovue	RT-Vue	Spectral	26,000	5.0 µm	15 µm	2-2.3mm	12mm	Ext	Yes
Zeiss	Cirrus	Spectral	27,000	5 µm	15 µm	2mm	4mm	Int	Yes
Zeiss	Visante	Time	2,000	18 µm	60 µm	6mm	16mm	Int	Yes

*Not currently FDA approved with AS-OCT from the following manufactures: Nidek, Optopol and Tomey.

measurements can be a very valuable learning tool for the practitioner fitting specialty contact lenses. The fit relationships seen in digital images can be compared with slit lamp observations. After a few patient encounters, a novice scleral lens fitter can become very confident with judging an appropriate fit. In figure 1, the slit lamp images show that there is more corneal vault on the right side, and this is clearly the case in the horizontal scan of this severe keratoconus patient.

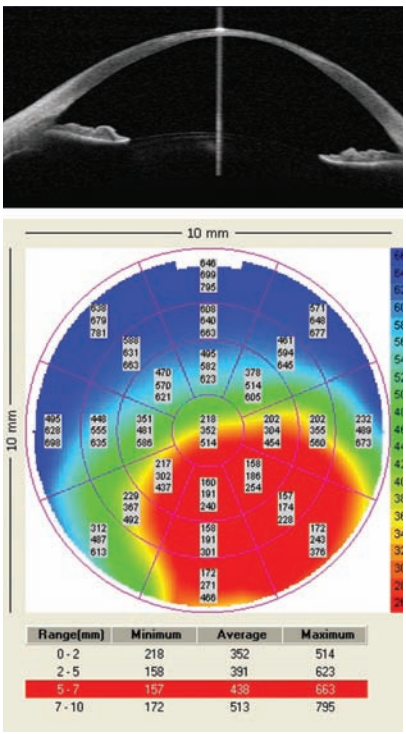

2. Visante pachymetry.

AS-OCT is especially useful for observing how parameter changes (sagittal height, base curve and diameter) affect the lens fit during a fitting or refit process. Unlike standard-size rigid gas-permeable lenses, large changes in some parameters are often required to make a significant change in the way a scleral lens fits. Caliper tools in the instrument software allow for precise eye measurements, which can then be correlated to slit lamp observations.

Even very experienced practitioners can have difficulty determining limbal clearance with the slit lamp. Human observers may not be able to detect a very thin fluorescein layer under a lens that may actually have some clearance. A scleral lens will often fit with deep (e.g., 300µm), clearance centrally, but minimal clearance or touch at the limbus. The resolution of modern AS-OCT can be as good as a few microns (*see "Anterior Segment OCT Specifications," above*), and there are cases where imaging can confirm a patient has just enough limbal clearance to avoid starting a refit in a lens that seems to fit well otherwise.

Another use for AS-OCT is to evaluate the landing zone. Landings that are too tight or loose can result in hypoxia or bubble formation. Scleral lens design is becoming very precise and customizable with the programing capabilities of manufacturing lathes. It is now possible to design varying landing profiles in different lens quadrants. AS-OCT will likely become a very important tool in highly customizable lens designs, including custom values for corneal and limbal vault, and peripheral curve design.

Case Studies

Before fitting a diseased, traumatized or post-surgical eye, you must first conduct a very thorough evaluation of corneal integrity. AS-OCT can plot pachymetry over a large area of the cornea rather than just a single point. Here are three AS-OCT case reports:

- A 24-year-old white male presented with corneal thinning from

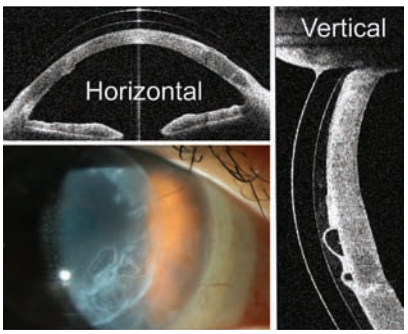

3. Epithelial bullae under scleral lens.

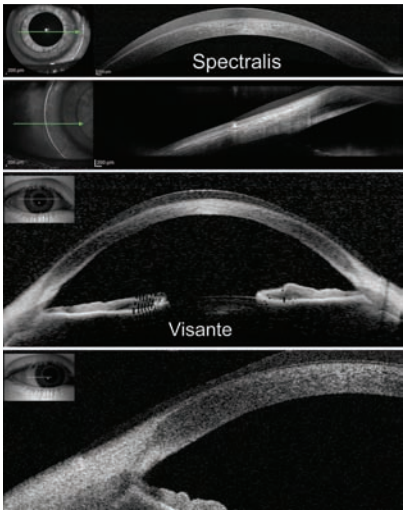

4. Large diameter scans of an individual wearing a contact lens.

severe atopic keratoconjunctivitis. A horizontal OCT scan and pachymetry was used to evaluate the patient (*figure 2*); an area of extreme thinning might alert the practitioner to arrange more frequent follow up after beginning lens wear. This patient had a remarkable improvement in acuity with a diagnostic scleral lens. However, after viewing the AS-OCT, he was concerned about his corneal health and elected not to be fit.

• A 69-year-old white male is a radiologist with a failing corneal graft. He elected to manage his failing corneal graft conservatively after AS-OCT documentation showed that scleral lens wear worsened the bullous keratopathy even though the lens fit very well (*figure 3*).

• Sometimes, after acute corneal hydrops, a severe keratoconus patient will have fortuitous flattening and strengthening of the cornea. A 49-year-old white female presented wearing an old, flat-fitting scleral lens at the time of acute hydrops. The AS-OCT imaging was very valuable in monitoring the healing process; she was recently refit in a new scleral lens where she achieved 20/25 acuity.

Digital Image Comparisons

We captured AS-OCT images for every instrument available during the Ophthalmic Photographers' Society annual program at the American Academy of Ophthalmology meeting (*see "Anterior Segment OCT Specifications," p 33*). To image a contact lens on the cornea, one individual wore a commercially available hydrogel (+13.50, 14.2mm, omafilcon A, 62% water). Images were exported from the instrument using the standard software available at the time. Some images have been minimally formatted for better side-by-side comparison. We cropped and resized in an attempt to standardize the total thickness of the cornea/soft lens, but no digital enhancements were made except some minor brightness changes. All of the six instruments we discuss have numerous scan parameters and digital output choices.

There are differences in the maximum size of the horizontal scan length for different instruments. Spectralis (Heidelberg Engineering) and Visante (Carl Zeiss Meditec) are able to capture the entire cornea and limbus in one horizontal or vertical scan of at least 15mm (*figure 4*). Wide scans can be useful for evaluating fit characteristics of large-diameter scleral lenses. We also imaged the edge of the soft lens and placed those scans alongside the horizontal scans. Edge design can be very important for scleral lens fitting.

The iVue (Optovue), RT-Vue (Optovue), Cirrus (Carl Zeiss Meditec) and Envisu R2300 (Bioptigen) are instruments that have smaller horizontal scan lengths. The horizontal and edge scans can still be used to image the entire cornea by making overlapping scans and stitching the images with some digital imaging software (*figure 5*).

Diagnosing a Poor Fit

AS-OCT images helped confirm that one patient's initial 18.2mm lens did not have clearance or vault over the limbus. He developed a severe keratitis/iritis while wearing the lens. The patient was refit to a 19.0mm lens with a reverse geometry design that produced a larger sagittal depth, allowing for vaulting over the limbus that was clearly evident in the repeated AS-OCT.

Many scleral lens patients have significant eye conditions that require close monitoring, which can be done with an AS-OCT. This technology is very useful for fitting large-diameter scleral lenses, evaluating the fit and problem solving. Keep in mind that some insurance carriers will reimburse for imaging certain eye conditions using CPT code 92132: scanning computerized ophthalmic diagnostic imaging, anterior segment, with interpretation and report, unilateral or bilateral (the old 0187T code). Undoubtedly, hardware and software upgrades on current instruments and new models with advanced imaging capabilities will improve the practitioner's ability to manage specialty contact lens patients. RCCL

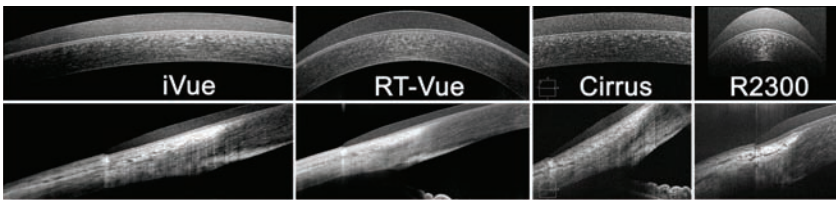

5. Smaller diameter scans of individual wearing a contact lens.

References available at www.reviewofcontactlenses.com.

The History of the Irregular Cornea

Over the years, practitioners have found new ways to help restore visual function to patients in need.

By Barry Weiner, O.D.

The early history of contact lenses can also double as a history of treatment for irregular corneas. In a 1827 publication of the journal *Light*, Sir John Herschel suggested that a lens could be ground to the surface shape of the cornea. "Should any very bad cases of irregular cornea be found, it is worthy of consideration whether at least a temporary distinct vision could not be procured by applying in contact with the surface of the eye some transparent animal jelly contained in a spherical capsule of glass, or whether an actual mold of the cornea might not be taken and impressed on some transparent medium," he wrote.

The first actual contact lenses, produced by Adolf Fick and Edouard Kalt, were designed as blown glass shells and introduced in 1887. The goal was to improve vision in keratoconus patients and to protect the corneas from the ravages of trachoma.

In 1888, August Muller produced the first lens with refractive power. Other major developments in contact lens technology include William Feinbloom's use of PMMA for scleral lenses in 1936, the first commercially successful PMMA corneal lenses by Kevin Tuohy in 1949, George Butterfield's first corneal lenses in 1950, Otto Wichterle's development of HEMA materials in the 1960s and the development of gas-permeable rigid lenses in the late 1970s.

Undoubtedly, the most satisfying part of any contact lens practice is the ability to restore that most precious sense—sight. Each new breakthrough has given us the ability to help those with visually compromising corneal irregularity and distortion so they function normally.

Treating Keratoconus

Almost any condition that causes an irregular corneal surface in the absence of any active infectious process can be helped optically and in many instances therapeutically by the application of some type of contact lens.

The earliest use of contacts was for the treatment of keratoconus—a non-inflammatory, usually bilateral, progressive asymmetric ectasia of the cornea resulting in poor vision due to the distortion produced by the disease. It was thought early on that applying a lens, which gently touched the apex of the cone, would retard the progression of the disease and improve visual function. Later studies showed that this use could cause scarring of the cone.

There have been many lens options to treat keratoconus over the years: glass, PMMA scleral lenses, RGP corneal lenses, soft toric lenses, specially

Dr. Weiner is a graduate of the Pennsylvania College of Optometry. He has served as an assistant professor of ophthalmology at the University of Maryland Medical School and currently serves as ancillary faculty at the Wilmer Eye Clinic. He is the past chair of the American Optometric Association's Cornea and Contact Lens section and is a fellow of the American Academy of Optometry.

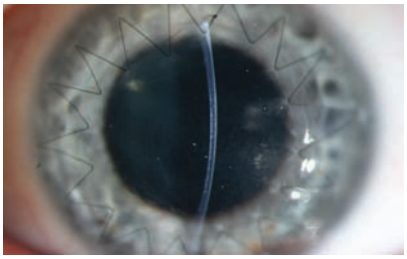

PK with sutures still in place.

designed soft lenses, hybrids and high dk scleral lenses.

• ***GP***. These remain the most prescribed modality for this condition: spherical designs and aspherics for early cones, and specialty designs (such as Soper Cone, McGuire Cone and various Rose Cone lenses) for more advanced cases.

• ***Disposables***. Piggyback techniques, such as using a disposable soft lens with a GP lens, can provide added comfort for the patient who cannot tolerate a rigid lens due to sensitivity issues. There are a number of soft lenses designed to hold the rigid lens in place, but in many cases a standard disposable lens will work as well.

• ***Specialty Lenses***. Another option to improve comfort is the use of specialty keratoconus soft lenses such as the NovaKone (Alden Optical), KeraSoft IC (UltraVision) or HydroKone (Visionary Optics). These lenses can be made with steep base curves (4.1mm) and are thicker than average to help mask the corneal irregularity. The sphere or spherocylinder power is placed on the front surface. These are the most advantageous when used for spherical, more central cones; decentered or sagging cones see less success with these lenses.

• ***Hybrids***. These lenses have long been used to treat keratoconus—with fairly poor results due to the limited parameter range. With the development of SynergEyes hybrids, we now have a wide variety of design options, central curvatures and variable peripheral curves. Early cones are best fitted with the standard A series or Duette lens, while more advanced cones are better suited to the KC series or the Clear Kone design.

The Use of Bandage Lenses

Epithelial, stromal and endothelial dystrophies can cause corneal surface irregularity, which can be treated with therapeutic contact lenses and concomitant drug therapy. This treatment plan will increase vision, relieve pain and decrease photophobia that often accompanies these conditions.

Recurrent corneal erosions will heal faster with the use of a bandage lens; extended use may reduce the incidence of recurrence. The lens reduces pain and the foreign body sensation that many patients describe, along with reducing glare and photophobia. Concomitant antibiotic therapy and lubricating drops reduce the chance of secondary infections and keep the lens moist.

Soft bandage lenses can also ease the foreign body sensation and photophobia caused by epithelial basement membrane disease, Reis-Bucklers' corneal dystrophy and Meesmann dystrophy. They can also be used to reduce recurrent erosions, foreign body sensation, and pain and light sensitivity for stromal dystrophies such as granular dystrophy and lattice dystrophy. Large bullae associated with Fuchs' endothelial dystrophy or aphakia can cause severe pain and blurred vision, which can be greatly helped with bandage lenses.

Post-Surgical Lens Applications

• ***RK***. Radial keratotomy (RK) was a popular treatment in the 1980s, but is rarely used today due to wound healing problems and post-surgery side effects that may leave patients hyperopic and with distorted corneas. Many of RK patients can't or won't wear glasses, and are instead returning for contact lens correction. However, the oblate nature of these corneas makes them a difficult fit for standard GP lenses. Soft lenses may promote neovascularization into the RK cuts, and due to the vaulting affect over the flattened central cornea, may not give the patient good visual acuity.

Standard GP designs center around the steepest area of the cornea, which has moved post-surgery. Instead, large diameter intralimbal designs, or even semi- and mini-scleral lenses, may be needed to attain good lens centration.

To start a fitting, use the flattest K reading prior to the RK procedure as your base curve. The final lens Rx will be similar to the preoperative Rx since you are vaulting the flatter central area. Keep in mind that you are looking for peripheral alignment. If the original K readings are not available, gauge the curvature of the cornea through topography—4mm lateral to the center of the cornea is where you want to start your trial fitting. Highly oblate corneas may need to be fitted with reverse geometry lenses for better alignment and more centration.

• ***PRK, LASIK***. PRK and LASIK are generally highly successful refractive procedures, but the small percentage of failures can be catastrophic to the patient, resulting in blurred or distorted vision, monocular diplopia, photophobia or corneal ectasia. Decentered ablations can cause high degrees of irregular astigmatism. Standard large diameter lenses are needed on these usually oblate corneas; intralimbal designs with 11mm to 13mm diameters work well. Semi- and mini-scleral lens from 13mm to 18mm can provide even better centration. Patients with significant dioptric

Three Keratoconus Case Studies

• Advanced Monocular Keratoconus

MW, a 24-year-old white male, was referred to my care for treatment of advanced monocular keratoconus. This diagnosis was confirmed by corneal topography. His SimK reading was 64.10 @ 115 /55.60 @ 25. His spectacle Rx was -5.50-6.00x29 VA 20/400 in the right eye and plano-0.50x70 VA 20/20 in the left eye.

His right eye was fitted with a Rose K GP lens. Base curve 6.15mm, 8.7mm diameter and -8.25. His visual acuity with the lens was 20/30, but he could not achieve full-time wear.

He was refitted with a SynergEyes KC lens: base curve 6.50 Rx -5.00 and peripheral curve 8.2mm. Today, he continues to comfortably wear the lenses during his waking hours and has a 20/30 acuity.

• Advanced Keratoconus with No Refractive Endpoint

JJ, a 28-year-old Asian male, presented with advanced keratoconus. He was unsuccessfully fitted with GP lenses. His SimK with topography was 58.95 @ 129/50.00 @ 39 O.D. and 62.20 @ 132/56.30 @ 42 O.S. His spectacle Rx was -3.50-5.75x 47 O.D. No refractive endpoint could be obtained for the left eye.

He was fitted with SynergEyes ClearKone lenses O.U. The O.D. and O.S. had vault values of 250µ. The Rx was -1.50 VA 20/25 O.D. and +0.25 VA 20/25 O.S. He was able to comfortably wear these lenses throughout the day.

• Advanced Keratoconus with Central Scarring

GS, a 36-year-old white male, presented with advanced keratoconus O.U. with central scarring of his left eye. His best-corrected acuity was 20/50- O.S. with reported sensitivity to headlights when driving at night and 20/30 O.D. with a GP lens. A DALK was performed on the left eye. His spectacle Rx was +2.25-6.00x25 VA 20/50 nine months postoperatively.

He was first fitted with NovaKone soft lenses. The lenses were comfortable but best-corrected vision was 20/40 in each eye, which was not acceptable to the patient. He was refitted with a SynergEyes KC lens in the right eye and a PS lens in the left. His visual acuity was 20/25 O.D. and O.S. He is wearing the lenses full time with good comfort.

differences between the central cornea and periphery who find that bubbles may be trapped over the central cornea in standard lenses may do well with the reverse geometry designs.

Hybrids can also be used if comfort with GP lenses is an issue. Patients with ectasia will benefit from the SynergEyes KC series; more oblate corneas do well with the reverse geometry design of the SynergEyes PC lens. The ClearKone also seems to work well when other designs fail. The ultimate goal is to have a well centered lens that gives good endpoint vision with no central bubbles and no vessel impingement of conjunctival vessels along with good movement and tear exchange.

• ***PK, DALK.*** Penetrating keratoplasty (PK) or deep anterior lamellar keratoplasty (DALK) is usually indicated for advanced keratoconus that cannot be corrected with contacts, central corneal scars secondary to trauma or severe corneal disease such as herpes kerititis, corneal ulcers or dystrophic conditions. Possible post-surgery side effects include corneal distortion or high degrees of regular or irregular astigmatism. The fitting process can start as early as three months after surgery, even with the sutures in place. If a patient's sutures have been removed to limit the possibility of blood vessel growth along the suture lines and across the host donor junction, soft spherical or toric lenses are recommended. Deep vessel invasion of the graft could cause clouding, edema or graft rejection.

Rigid lenses of 11mm and larger can vault the host donor junction and usually give good optical and physiological results. The fit will have to be closely monitored for six to nine months postoperatively as the healing process may cause reshaping of the cornea.

When fitting a lens early in the healing process, the donor button may be depressed in relation to the host cornea. Standard lens designs may vault the central cornea and large bubbles may be trapped centrally. In these cases, reverse geometry lenses may give a better response. As the button steepens with time, a change to a standard base curve lens may be necessary. Be sure to carefully explain the course of the healing process to the patient before starting the fitting process so as to avoid any misunderstandings. The patient also needs to know that if and when the sutures are removed, the fitting process may need to be repeated since the cornea can change significantly.

Scleral lenses (from 18mm to 24mm) are having a significant impact in cases where standard size lenses fail. These larger diameter lenses are fitted so that a fluid reservoir is maintained under the lens, which will mask any corneal irregularity. Here, trial lens fittings are essential to get the best results. Use these lenses for severe keratoconus, post-surgical cases where smaller lenses have failed and to aid patients with severe ocular surface disease.

As we continue to address complications that stem from irregular corneas and their subsequent treatment, we are fortunate to see the development of new technology to better fit the patient. RCCL

Kids and Contact Lenses

Proceedings from a live interactive webinar event, attended by several of the industry's most renowned contact lens practitioners.

Moderated by Joseph Shovlin, O.D.

CONTROVERSIES IN CARE POLL

Do you think that kids who consistently lose or break their glasses should be fit with contact lenses?

Poll Results:

Yes.	65%
No.	35%

CONTROVERSIES IN CARE

On The Web >> To register for our next event, go to www.reviewofcontactlenses.com/controversies-in-care.

What parameters should we consider when fitting kids in contact lenses? Do you prefer daily disposables or silicone hydrogels? These were just a few of the topics our panelists, Christine Sindt, O.D., and Jeffrey Walline, O.D., Ph.D., tackled at last month's "Controversies in Care" event, which drew in an audience of nearly 50 eye practitioners from across the country.

The evening's first poll revealed that 50% of our respondents believed seven years was the appropriate age to fit kids with elective contact lenses. Dr. Sindt agreed, though she cited a recent study that said most practitioners are very comfortable fitting children in the 10 to 12 year age group.[1]

"I always say that we shouldn't say what age people can be fit. We all know a five-year-old who is capable of contact lens wear and we all know a lot of 25-year-olds who are not," said Dr. Walline.

The panelists argued that, since each patient is different, age shouldn't be the deciding factor, but instead we should look at the parent involvement, maturity of the child and the motivation. When asked whether they would fit children who routinely lose or break their glasses, 35% of the audience respondents said they wouldn't. This sparked a lively conversation on responsibility.

"I personally find that whether they clean their room or not has nothing to do with their motivation to wear lenses or their success with lenses," said Dr. Sindt. "Usually all it requires is to sit down and have a very frank talk with the kid and see if they are willing to take on the responsibilities of having lenses."

Drawing from a recent study that recorded the amount of time it took seven to 10 year olds versus teenagers to learn insertion and removal, Dr. Walline said he found a difference only at the extremes. "We shouldn't not fit children in contact lenses because we think it'll slow down the productivity of our office," he said.

After discussing a few case studies, the panelists tackled the question of self-perception. Dr. Walline and colleagues did a study that ultimately found that contact lenses provided children with value-added benefits beyond simple vision correction, such as improved self-perception in the areas of athletic competence, physical appearance and peer interactions.

Dr. Sindt said that myopia control is the key issue for the next couple years and will help change the way practices work to capture patients who are not currently contact lens wearers. With every company having soft myopia control lenses launched worldwide, the U.S. market will soon follow. In the meantime, the panelists cited the connection between increased outdoor activity and decreased myopia.

The introduction and acceptance of daily disposable lenses as an option for kids, the availability of improved materials, the increase in requests from kids and parents for lenses and the flexibility allowed for activities and sports are all factors that account for a growing young contact lens wearing population.

Stay tuned next month for a lively discussion on daily disposables. We also welcome you to join the conversation live. You can register for upcoming online events at www.reviewofcontactlenses.com. RCCL

1. Sindt C, Riley C. Practitioners attitude on children and contact lenses. Optometry. 2011 Jan;82(1):44-5.

July 26-29, 2012

SECO International and Review of Optometry Present

VANCOUVER 2012

This summer, SECO International and Review of Optometry invite optometrists to Vancouver for an exciting four-day continuing education event featuring leading experts in the profession and compelling courses. This unique program, held at the Westin Bayshore Hotel, begins the evening of July 26th and continues during the mornings of July 27th through 29th. This allows attendees plenty of time to spend the remainder of those days with family and friends touring the city of Vancouver and the majestic regions of British Columbia. Group tours will be available.

Featuring 14 Hours of Optometric Continuing Education and Unique Networking and Sight-seeing Opportunities.

Nine courses (8 CEE/TQ Hours) — covering topics such as Cataract surgery, Glaucoma, OCT and corneal crosslinking — will be presented by Dr. Paul Karpecki, Dr. Paul Ajamian, Dr. Kim Reed, Dr. Steven Ferrucci, and Dr. Michael Chaglasian. The conference also features many opportunities for networking and socializing at the Welcome Reception on Thursday, July 26th and the Sponsors' Reception on Saturday, July 28th. Group tours will also be available. Don't let this wonderful opportunity to learn some of the latest developments in optometry while enjoying the international city of Vancouver, BC, pass you by. **Register now!**

Visit seco2012.com/Vancouver

Produced by SECO International, LLC® Providing world-class education for optometry since 1924. REVIEW OF OPTOMETRY

INTRODUCING

BAUSCH + LOMB

KERASOFT® IC

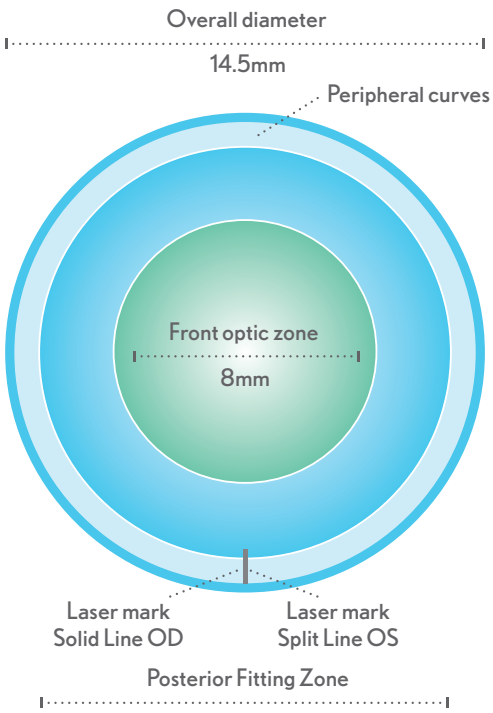

A revolutionary design for keratoconus and other irregular corneas.

KeraSoft IC soft contact lenses feature a patented design with:

- A front surface asphere or aspheric toric design
- Balanced overall thickness with spherical aberration control and two sectors of independently modifiable periphery
- Adjustable periphery which fits any corneal shape
- Silicone hydrogel for longer wearing comfort and a higher level of oxygen

Available from authorized KeraSoft IC laboratories:

Art Optical Contact Lens, Inc.	800-253-9364
Metro Optics	800-223-1858